

# UC Irvine

## UC Irvine Previously Published Works

### Title

Clinical response to adjunctive platelet-rich plasma injections in a patient with alopecia universalis on oral tofacitinib

### Permalink

<https://escholarship.org/uc/item/2rb5n87x>

### Authors

Ederaine, Sophia A  
Kushner, Carolyn J  
Shapiro, Jerry  
et al.

### Publication Date

2022-02-01

### DOI

10.1016/j.jdcr.2021.11.019

### Copyright Information

This work is made available under the terms of a Creative Commons Attribution License, available at <https://creativecommons.org/licenses/by/4.0/>

Peer reviewed

# Clinical response to adjunctive platelet-rich plasma injections in a patient with alopecia universalis on oral tofacitinib



Sophia A. Ederaine, BA,<sup>a</sup> Carolyn J. Kushner, MD,<sup>b</sup> Jerry Shapiro, MD,<sup>b</sup> and Kristen I. Lo Sicco, MD<sup>b</sup>  
*Scottsdale, Arizona and New York, New York*

**Key words:** alopecia areata; alopecia universalis; Janus kinase inhibitors; tofacitinib; platelet-rich plasma.

## INTRODUCTION

Alopecia areata (AA) is one of the most common autoimmune causes of nonscarring hair loss in children and adults.<sup>1</sup> The most severe form of AA, alopecia universalis (AU), manifests as complete hair loss over the body and scalp. AA, particularly AU, is challenging to treat, often showing only transient responses to topical and oral corticosteroids and other standard interventions. Recent novel treatments, including systemic Janus kinase inhibitors, such as tofacitinib and ruxolitinib, as well as platelet-rich plasma therapy (PRP), have shown promise against AA.<sup>2-4</sup> PRP, an autologous blood product, is thought to enhance hair growth, assist with cell repair, prolong the hair anagen phase, promote cell differentiation, and exert anti-inflammatory effects attributed to the presence of growth factors and chemokines.<sup>5-7</sup> We describe a 31-year-old woman with AU that did not improve with oral tofacitinib plus adjuvant intralesional corticosteroids but responded significantly with the addition of PRP to oral tofacitinib.

## CASE REPORT

Our patient began to exhibit her first episode of hair loss 1 year before presentation to our clinic. She initially lost scalp hair in patches, which continued to progress to alopecia totalis, with the loss of all scalp hair, eyebrows, eyelashes, and, ultimately, all other body hair. She had no response to 2 30-day prednisone tapers starting at 50 mg, which were completed 7 and 8 months before starting PRP injections. Treatment was, therefore, changed to 11 mg of extended-release oral tofacitinib with adjunctive

### Abbreviations used:

AA: alopecia areata  
 AU: alopecia universalis  
 PRP: platelet-rich plasma therapy

intralesional triamcinolone scalp injections. After 7 months of this treatment regimen with no response, she was referred to our clinic. Her only significant past medical history included plaque psoriasis, which was not active during her treatment for AU. The patient had no known history of asthma, nail involvement, or thyroid disease. She had no family history of hair loss and denied new medications, life stressors, or recent illness. After discussing multiple treatment options, she opted to continue daily oral tofacitinib and initiate 5 mL of monthly PRP therapy (Regen system) instead of additional intralesional corticosteroids and demonstrated a significant response to this combination therapy (Fig 1).

## DISCUSSION

We present a report of AU recalcitrant to 7 months of oral tofacitinib and adjunctive intralesional corticosteroids that responded immediately to the addition of PRP to the systemic regimen.

Previous studies on oral tofacitinib AA have demonstrated a majority response within 4 to 18 months of treatment and a further improvement in others after an increase in dosage of tofacitinib, with or without the addition of adjuvant corticosteroids.<sup>2,3</sup> However, a recent meta-analysis focusing on Janus kinase inhibitors for alopecia areata reported that the mean times to initial and complete hair

From Mayo Clinic Alix School of Medicine, Scottsdale,<sup>a</sup> and the Ronald O. Perleman Department of Dermatology, New York University Grossman School of Medicine.<sup>b</sup>

Funding sources: None.

IRB approval status: Not applicable.

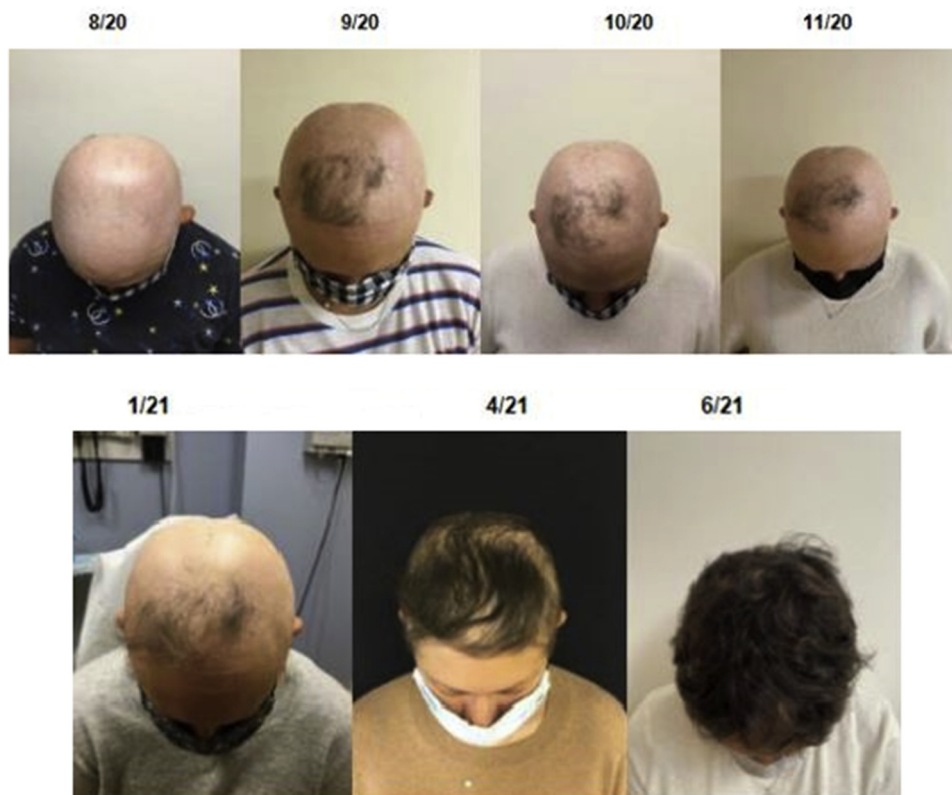Correspondence to: Kristen I. Lo Sicco, MD, 240 E 38th St, 11th floor, New York, NY 10016. E-mail: [kristen.losicco@nyulangone.org](mailto:kristen.losicco@nyulangone.org).

JAAD Case Reports 2022;20:34-6.

2352-5126

© 2021 by the American Academy of Dermatology, Inc. Published by Elsevier, Inc. This is an open access article under the CC BY-NC-ND license (<http://creativecommons.org/licenses/by-nc-nd/4.0/>).

<https://doi.org/10.1016/j.jdc.2021.11.019>



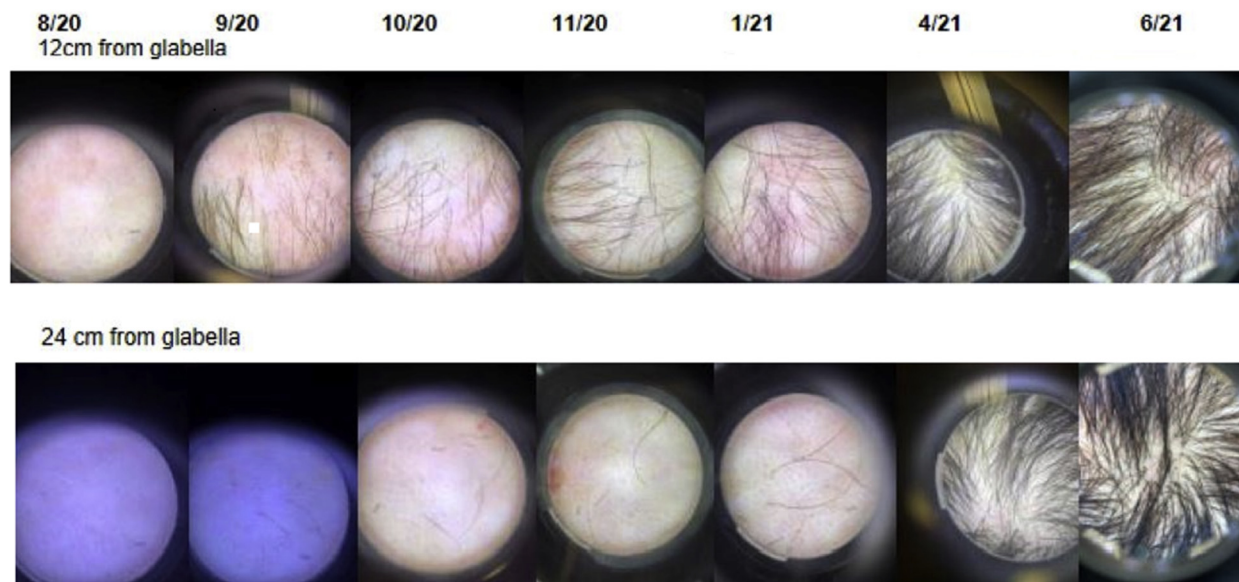
**Fig 1.** Photographs of frontal scalp and vertex over 10 months.

growth were 2.2 months and 6.7 months, respectively.<sup>4</sup> Initial hair growth for our patient did not begin until after PRP therapy was added to the systemic regimen, and significant regrowth was noted after 4 months of monthly adjunctive PRP therapy.

The patient's clinical history included several factors that could have accounted for the initial lack of response to tofacitinib. With AU being the most severe form of AA, the 7-month duration of tofacitinib alone, before adjunctive PRP, is relatively short. In a study conducted by Lew et al,<sup>8</sup> patient-participants showed a 20.0% complete response rate to tofacitinib after a median of 15 months, 38.4% had an intermediate response after a median of 14 months, and 18.5% had a moderate response after a median of 11 months; 23% of patients were nonresponders but were only treated for a median of 7 months. These statistics reveal that tofacitinib often needs more than 7 months to demonstrate efficacy. Of note, the majority of the patients in this study were treated with 5 mg of tofacitinib twice daily, while our patient was treated with 11 mg of extended-release tofacitinib. It is also possible that the patient's AU may have spontaneously remitted at the same time we initiated PRP; however, spontaneous remission is less likely in patients with

alopecia totalis than less severe forms of AA, such as patch type.<sup>8</sup> It is also noteworthy that our patient began to regrow hair on areas distant from her scalp PRP therapy, including the eyebrows (not lashes) and axillae (Fig 2). Although limited and mostly outside of dermatologic literature, studies suggest that local PRP injections can have systemic effects, which may have contributed to our patient's hair regrowth in areas distant from the PRP injection sites on her scalp.<sup>5</sup> A study by Wasterlain et al<sup>5</sup> found that vascular epithelial growth factor was systemically elevated in patients after intratendinous PRP injections compared with those without. The study suggested that PRP may trigger biological pathways rather than just serve as local presynthesized growth factors. This systemic effect may have contributed to the patient's overall improvement rather than the anti-inflammatory effect of oral tofacitinib alone.

Further studies are warranted to compare patients with refractory AA on oral tofacitinib versus those on oral tofacitinib plus adjuvant PRP therapy. Our case report illustrates the effectiveness of systemic tofacitinib with PRP scalp therapy after 7 months of failed response to tofacitinib alone, with no increase in dosage. This clinical course points to increased therapeutic options against AA and flexibility in



**Fig 2.** Dermoscopic images 12 cm and 24 cm from the glabella over 10 months (original magnification,  $\times 10$ .)

treatment duration for patients with poor or no response to commonly used interventions. Dermatologists should be aware of PRP injections as adjuvant therapy with tofacitinib for initially treatment-resistant AU, and further studies are needed to assess the systemic effects of PRP. In addition, while PRP therapy may be cost-prohibitive, it is well-tolerated, causing localized pain but no major toxicities.

#### Conflicts of interest

Dr Shapiro is a consultant for Lilly, Pfizer, Eirion, Applied Biology, DS Laboratories, and [keeps.com](https://www.keeps.com). He holds stock in Replicel Life Sciences. He has been an investigator for Regen Lab and is an investigator for Pfizer. Dr Lo Sicco is a consultant and an investigator for Pfizer. She is also an investigator for Regen Labs. Drs Ederaine and Kushner have no conflicts of interest to declare.

#### REFERENCES

- Safavi KH, Muller SA, Suman VJ, Moshell AN, Melton LJ III. Incidence of alopecia areata in Olmsted County, Minnesota, 1975 through 1989. *Mayo Clin Proc.* 1995;70(7):628-633. <https://doi.org/10.4065/70.7.628>
- Liu LY, Craiglow BG, Dai F, King BA. Tofacitinib for the treatment of severe alopecia areata and variants: a study of 90 patients. *J Am Acad Dermatol.* 2017;76(1):22-28. <https://doi.org/10.1016/j.jaad.2016.09.007>
- Craiglow BG, King BA. Killing two birds with one stone: oral tofacitinib reverses alopecia universalis in a patient with plaque psoriasis. *J Invest Dermatol.* 2014;134(12):2988-2990. <https://doi.org/10.1038/jid.2014.260>
- Phan K, Sebaratnam DF. JAK inhibitors for alopecia areata: a systematic review and meta-analysis. *J Eur Acad Dermatol Venereol.* 2019;33(5):850-856. <https://doi.org/10.1111/jdv.15489>
- Wasterlain AS, Braun HJ, Harris AH, Kim HJ, Dragoo JL. The systemic effects of platelet-rich plasma injection. *Am J Sports Med.* 2013;41(1):186-193. <https://doi.org/10.1177/0363546512466383>
- Hesseler MJ, Shyam N. Platelet-rich plasma and its utility in medical dermatology: a systematic review. *J Am Acad Dermatol.* 2019;81(3):834-846. <https://doi.org/10.1016/j.jaad.2019.04.037>
- Rodrigues BL, Montalvão SAL, Cancela RBB, et al. Treatment of male pattern alopecia with platelet-rich plasma: a double-blind controlled study with analysis of platelet number and growth factor levels. *J Am Acad Dermatol.* 2019;80(3):694-700. <https://doi.org/10.1016/j.jaad.2018.09.033>
- Lew BL, Shin MK, Sim WY. Acute diffuse and total alopecia: a new subtype of alopecia areata with a favorable prognosis. *J Am Acad Dermatol.* 2009;60(1):85-93. <https://doi.org/10.1016/j.jaad.2008.08.045>