

UCSF

UC San Francisco Previously Published Works

Title

Medial Femoral Condyle Free Flap Reconstruction of Complex Foot and Ankle Pathology

Permalink

<https://escholarship.org/uc/item/2v18q9b4>

Journal

Foot & Ankle Orthopaedics, 4(4)

ISSN

2473-0114

Authors

Stranix, John T
Piper, Merisa L
Azoury, Said C
et al.

Publication Date

2019-10-01

DOI

10.1177/2473011419884269

Peer reviewed

Medial Femoral Condyle Free Flap Reconstruction of Complex Foot and Ankle Pathology

John T. Stranix, MD¹ , Merisa L. Piper, MD², Said C. Azoury, MD³, Geoffrey Kozak, MD³, Oded Ben-Amotz, MD³, Keith L. Wapner, MD⁴, and L. Scott Levin, MD^{3,4}

Abstract

Background: Complex hindfoot pathology may benefit from vascularized bone flap reconstruction rather than traditional bone grafting techniques. Medial femoral condyle (MFC) flaps provide vascularized periosteum, skin, and corticocancellous bone.

Methods: A retrospective, single-institution cohort study of consecutive MFC flaps performed for complicated hindfoot reconstruction between 2013 and 2019 was reviewed. Radiologic follow-up assessed osseous union and clinical outcomes were evaluated with the American Orthopaedic Foot & Ankle Society (AOFAS) hindfoot score. Thirty MFC flaps were performed in 28 patients for complex hindfoot pathology. Twenty-seven flaps had adequate clinical and radiographic follow-up (mean 15.8 months).

Results: The majority presented with avascular necrosis (83%) and failed prior operations (67%, mean 3.1). Most hindfoot procedures involved arthrodesis (n = 24, 80%); tibiototalcalcaneal (n = 11) and talonavicular (n = 7) most frequently. Mean osseous flap volume was 10.3 cm³ (range 1.7-18.4 cm³); one flap required takeback for venous congestion but no total flap losses occurred. Primary osseous union was initially achieved in 20 patients (74%, mean 217 days). Six flaps developed interface nonunion; 5 underwent revision arthrodesis and ultimately achieved union in 24/27 flaps (89%, mean 271 days). Risk factors for nonunion were body mass index (BMI) >30 (P = .017) and prior arthrodesis (P = .042). Mean AOFAS hindfoot scores increased significantly from 52.3 preoperatively to 70.7 postoperatively (P < .001). Subscore analysis demonstrated significant improvement in postoperative pain scores from 14.2 to 27.3 out of 40 (P < .001).

Conclusion: The MFC free flap provided vascularized bone for complicated foot and ankle reconstruction with relatively low donor site morbidity, promising osseous union results, and improved functional outcomes.

Level of Evidence: Level IV, retrospective case series.

Keywords: ankle fusion, avascular necrosis, failed arthrodesis, hindfoot, MFC, orthoplastic, vascularized bone

Introduction

Normal foot and ankle function does rely on the large articular surfaces of the navicular and talus, which results in a relatively tenuous blood supply and significant stress during ambulation. This combination predisposes them to arthrosis, avascular necrosis (AVN), and nonunion, which can present a challenging problem for foot and ankle surgeons and often leaves arthrodesis as the only possible option.¹⁴ If revision arthrodesis is required, this further exacerbates the problem by resulting in greater bone loss, soft tissue compromise, and less consistent fusion rates.⁷

¹ Department of Plastic Surgery, University of Virginia Health System, Charlottesville, VA, USA

² Division of Plastic and Reconstructive Surgery, Department of Surgery, University of California, San Francisco, San Francisco, CA, USA

³ Division of Plastic Surgery, Department of Surgery, University of Pennsylvania Health System, Philadelphia, PA, USA

⁴ Department of Orthopedic Surgery, University of Pennsylvania Health System, Philadelphia, PA, USA

Corresponding Author:

John T. Stranix, MD, Department of Plastic Surgery, 1300 Jefferson Park Avenue, 4th Floor, Charlottesville, VA 22908, USA.

Email: jts3v@virginia.edu



Standard bone grafting techniques require a well-vascularized recipient bed to maintain osteocyte viability and allow for successful osseous union. When a significant intercalary defect results from resection of diseased bone, successful arthrodesis with limb length preservation requires osseous structural support to bridge the gap in combination with rigid compressive fixation.^{1,2,15,21} Structural bone grafts require progressive healing through the interfaces between the graft and native bone margins, with larger grafts at higher risk of failure to incorporate and subsequent collapse. Compromised vascularity of the recipient site and comorbidities such as diabetes or smoking further increase the risk of graft failure.^{16,20}

Vascularized bone grafts have the advantage of preserving osteocyte viability within the structural bone graft transferred. These have traditionally been recommended for significant intercalary defects (typically >6 cm) or in the setting of a hostile wound bed and/or comorbid patient at high risk of nonvascularized bone graft failure. The medial femoral condyle (MFC) free flap, first described by Doi et al,⁶ enables transfer of vascularized periosteum with viable corticocancellous bone and skin if required to promote osseous union in bone defects that are unlikely to achieve successful union with standard bone grafting techniques.^{6,10} Although the MFC is unable to provide the length of a free fibula or iliac crest often required for segmental long bone defects, it has relatively minimal donor site morbidity and provides adequate bone stock to serve as a structural graft for many salvage foot and ankle procedures.

Preoperative patient selection, intraoperative tailoring of the MFC flap to the anticipated defect, and postoperative care requires close cooperation between the orthopedic and plastic surgery teams. Anecdotally, we have found that this coordinated orthoplastic approach of specialized teams working together to provide orthopedic and microvascular expertise improves the likelihood of success and streamlines delivery of care in this challenging patient population. In order to critically evaluate our outcomes, we report our series of orthoplastic foot and ankle reconstructions with the MFC free flap.

Methods

A retrospective review of medial femoral condyle free flaps performed for foot and ankle reconstruction by the senior author at a single institution between 2013 and 2019 was completed following institutional review board approval. All patients were initially evaluated by the senior foot and ankle surgeon and subsequently referred to the plastic surgery service for evaluation if their pathology warranted vascularized bone graft transfer in order to optimize the potential for osseous healing and successful orthopedic treatment. Factors that were considered indications for performing MFC reconstruction included (1) symptomatic pathology with significant functional impairment warranting surgical intervention; (2) severely compromised bone vascularity from AVN and/

or multiple prior operations based on preoperative imaging, examination, and history; (3) anticipated osseous defect approximately 2-4 cm in length; (4) poor surrounding soft tissue quality; and (5) presence of comorbidities associated with standard bone graft failure such as smoking, diabetes, or steroid use. Although smoking and diabetes were not a reason for exclusion, multiple significant comorbidities that resulted in a poor surgical candidate for free flap reconstruction was a contraindication. In addition, if there were no recipient vessels available for microvascular anastomosis due to peripheral vascular disease or trauma, we were unable to offer the patient free flap reconstruction. If a larger osseous defect was anticipated, a free fibula was chosen as the vascularized bone flap for reconstruction; however, for borderline defects, patients were consented for both MFC and fibula flaps, with the ultimate decision made intraoperatively after the defect was fully defined.

Patient demographics, operative details, and postoperative outcomes were obtained for analysis; comorbidities were evaluated using the Charlson Comorbidity Index (CCI) for comparison.⁵ Preoperative and postoperative American Orthopaedic Foot & Ankle Society (AOFAS) Ankle-Hindfoot Scores were calculated for functional outcomes comparison.¹⁹ The orthopedic clinic documentation for pre- and postoperative evaluations were recorded in accordance with the AOFAS scoring system which enabled retrospective evaluation with this outcomes instrument. Unfortunately, other validated foot and ankle scores were not able to be reliably calculated and were not included in our analysis.

Over the 6-year study period, 30 MFC free flap reconstructions were performed in 28 patients for complex hind-foot pathology (Table 1). Mean age was 47.8 years with a range from 17 to 77 years with an even gender distribution. Obesity was common with an average body mass index (BMI) of 31 (range 19-45); however, there was a relatively low incidence of comorbidities such as diabetes (n = 2) and peripheral vascular disease (n = 1), with a median Charlson Comorbidity Index score of 1 (range 0-5).

Osseous union was assessed with serial radiographic or computed tomography, with complete union defined as date of imaging study when complete union was noted within the radiology report.

Orthoplastic Surgical Technique and Postoperative Flap Care

A 2-team, orthoplastic approach was utilized in all cases to ensure that all flaps were tailored to the reconstructive requirements of each individual defect. The included radiographic and intraoperative images. (Figures 1-4 provide an illustrative case example.) On completion of the orthopedic portion of each procedure (Figure 2), the MFC flap was harvested under tourniquet control as described previously (Figure 3).¹⁰ Flap fixation was determined intraoperatively according to the defect size, orthopedic fixation technique,

Table 1. Patient Demographics and Hindfoot Pathology.^a

Total flaps, n	30
Age, y, mean \pm SD (range)	47.8 \pm 19.4 (17-77)
Male	14 (47)
BMI, mean \pm SD (range)	30.8 \pm 7.5 (19-45)
Diabetes mellitus	2 (6.7)
Peripheral vascular disease	1 (3.3)
Charlson Comorbidity Index, median (range)	1 (0-5)
Corticosteroid use	2 (6.7)
Chronic pain syndrome	4 (13)
Smoking history	13 (43)
Current	5 (17)
Former	8 (27)
Etiology of hindfoot pathology	
Trauma	22 (73)
Idiopathic	5 (17)
Arthritis	1 (3.3)
Vascular	2 (6.7)
Medication	3 (10)
Prior hindfoot surgery	20 (67)
No. of prior hindfoot operations, mean \pm SD (range)	3.1 \pm 1.9 (1-10)
Prior ORIF	13 (43)
Prior arthrodesis	17 (57)
Prior bone grafting	11 (37)
Arthritis	23 (77)
Nonunion	22 (73)
Avascular necrosis	25 (83)
Navicular	13 (43)
Talus	12 (40)
Distal tibia	2 (6.7)
Calcaneus	1 (3.3)
Multiple	4 (13.3)
Osteomyelitis	1 (3.3)

Abbreviations: BMI, body mass index; ORIF, open reduction internal fixation.

^aValues are n (%), unless otherwise noted.

flap design, and pedicle orientation. At the conclusion of the operation, all patients were placed in a posterior splint with leg elevation and strict nonweightbearing. Flap monitoring was most commonly performed using an external Doppler probe on the skin paddle or directly over the pedicle in 28 cases; however, an implantable Cook Doppler probe was used in 2 cases (1 arterial, 1 venous). On discharge, the patient was instructed to maintain strict nonweightbearing status in the posterior splint and to keep the leg in an elevated position as often as possible until seen in clinic.

Statistical Analysis

Data were analyzed using Pearson chi-square or Fisher exact tests to examine categorical variables and *t* test for continuous variables to assess for significance between surgical site infection, wound breakdown, and nonunion (dependent variables) and comorbidities and prior orthopedic procedures (independent variables). All variables with a *P* < .10

on univariate analysis were included in multivariate analysis logistic regression model to assess independent predictive factors of non-union. Results with a *P* < .05 were considered to be statistically significant. Analyses were performed using Stata IC 11.0 (StataCorp, College Station, TX).

Results

A history of trauma was the most common etiology (73%) followed by idiopathic avascular necrosis (17%). Avascular necrosis of 1 or more hindfoot bones was present in 83% of patients, with the navicular (*n* = 13) and talus (*n* = 12) most commonly affected. Arthritis (76%) and osseous nonunion (73%) were also common on presentation. The majority of patients had undergone previous hindfoot surgery (*n* = 20, 67%), with an average of 3.1 prior operations (range 1-10). Most patients with surgical history (*n* = 17, 57%) had ultimately failed at least 1 arthrodesis procedure prior to referral.

Orthopedic interventions performed concomitantly with MFC flap reconstruction are listed in Table 2 along with the respective bone flap insertion sites. The majority of hindfoot procedures involved arthrodesis of at least 1 joint (*n* = 24, 80%), with tibiototalcalcaneal (*n* = 11) and talonavicular (*n* = 7) fusions the most common. K-wire fixation of the MFC flap was used most frequently (*n* = 17), followed by press-fit (*n* = 5), K-wire and screw (*n* = 4), screw (*n* = 2), plate and screw (*n* = 1), and plate only (*n* = 1).

The ipsilateral knee was used as the MFC donor site in all but 2 cases. The mean osseous volume was 10.3 cm³ (range 1.7-18.4 cm³). Bone-only free flaps were used in 14 cases. A chimeric skin paddle was performed with 15 of the flaps (50%), and a segment of vastus medialis muscle was incorporated in 1 case for soft tissue coverage in the setting of inadequate skin perforators. The descending geniculate artery supplied the flap in the majority of cases (*n* = 26). However, in 4 cases, the MFC pedicle arose from the superior condylar branch of the medial geniculate artery. The anterior tibial (AT) vessels were the most common recipient vessels (*n* = 25) followed by the posterior tibial (PT) vessels in 5 cases. End-to-end arterial anastomoses were performed in 23 cases and either 1 or 2 venae comitans were used for venous outflow.

Average postoperative length of hospital stay was 4.9 days (range 3-11 days). Length of stay longer than 5 days was associated with older age (mean 60.4 years vs 37.9 years, *P* = .001) and higher CCI scores (mean 2.3 vs 0.62, *P* = .002). Flap complications occurred in 6 patients. There were 3 partial skin paddle losses and 2 total skin paddle failures; however, the underlying bone flap was noted to be viable in all cases during operative debridement. One patient required a takeback for venous thrombosis related to pedicle kinking on postoperative day 1 with successful flap salvage. One patient developed a donor site seroma that required operative drainage.

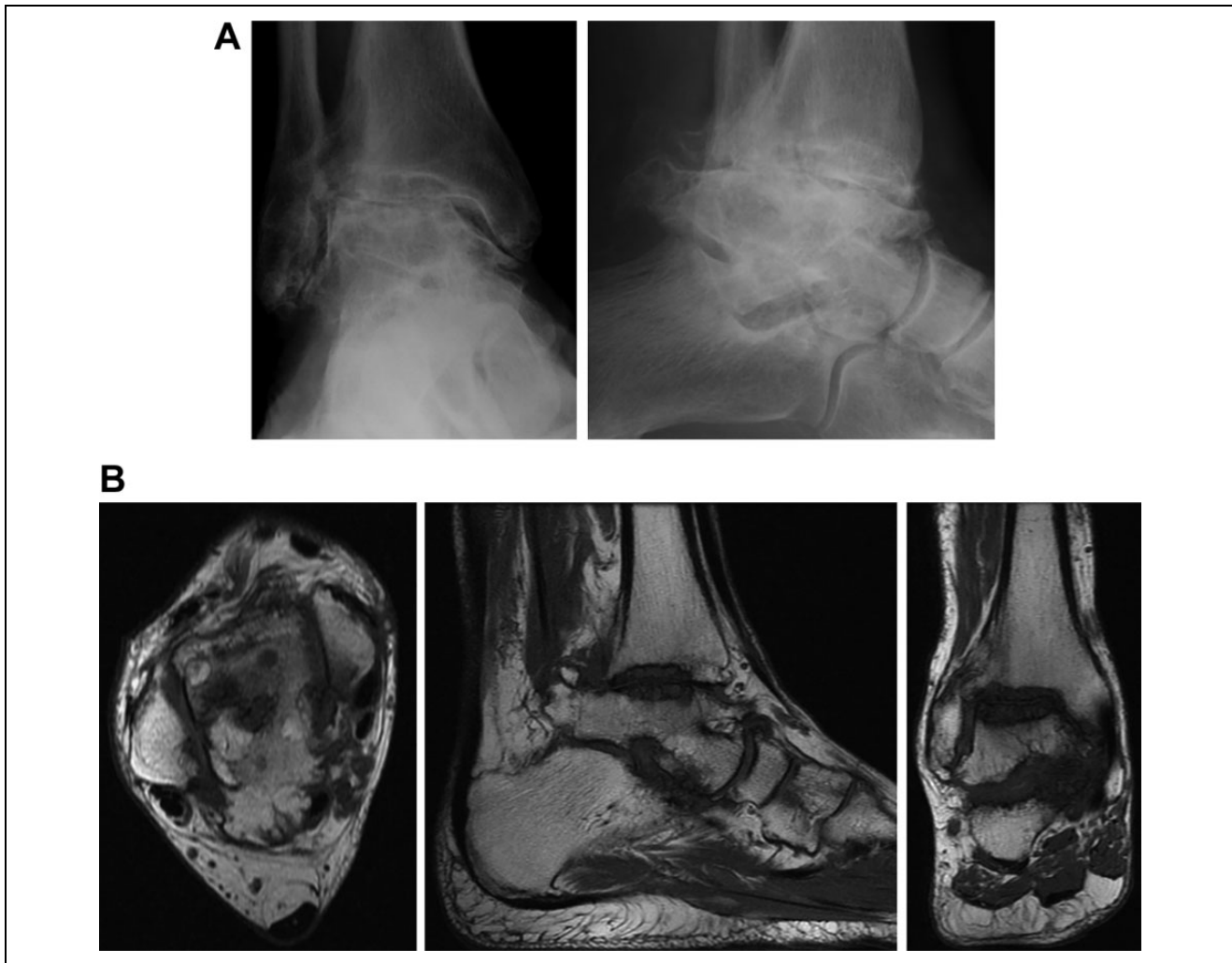

Figure 1. (A) Preoperative anteroposterior and lateral weightbearing radiographs of a 76-year-old man with a remote history of right ankle trauma without prior surgical intervention. There is severe ankle arthropathy with flattening of the talar dome suggestive of avascular necrosis. (B) Axial, sagittal, and coronal T1-weighted 1.5-tesla magnetic resonance images of the same patient demonstrating severe osteoarthritis of the tibiotalar and subtalar joints with loss of articular cartilage and marked cystic changes in the periarticular subchondral bone of the tibia and talus.

Out of 30 patients, 27 had adequate clinical and imaging follow-up to be included for outcomes analysis with a mean follow-up duration of 15.8 months (range 4-33 months) (Table 3). Average time to partial weight bearing was 49 days (range 26-100 days) and time to full weight bearing was 99 days (range 57-208 days). Primary osseous union was initially achieved in 20 patients (74%) by an average of 217 days (range 110-475 days). CT imaging follow-up was available for 16 patients, including 4 nonunions, and was obtained 2-24 months postoperatively (mean 12.3 ± 8.0 months). One patient developed an asymptomatic partial union with no functional limitation and did not warrant additional intervention.

Of the 6 patients who developed an interface nonunion, 5 were symptomatic and underwent revision arthrodesis with bone grafting and 4 of these patients achieved subsequent union. One patient who developed an asymptomatic chronic

nonunion refused any consideration for additional surgery. Ultimately, complete osseous union was achieved in 24 patients (89%) with an average time to union of 271 days (range 110-628 days).

Fifteen patients required additional procedures subsequent to their MFC flap reconstruction (6 soft tissue, 9 orthopedic). Flap soft tissue debulking was performed in 4 patients, and 2 required operative debridement for delayed wound healing at the recipient site. Revision arthrodesis for nonunion was required in 5 patients. Two patients underwent pin removal, 1 patient had tibial screw removal for rod dynamization, and 1 required excision of heterotopic bone.

Risk factors for the development of nonunion following MFC reconstruction were evaluated (Table 4). Nonunion demonstrated a significant association with increased BMI ($P = .001$), specifically with a BMI cutoff greater than 30 ($P = .017$). On multivariate regression, BMI >35 was

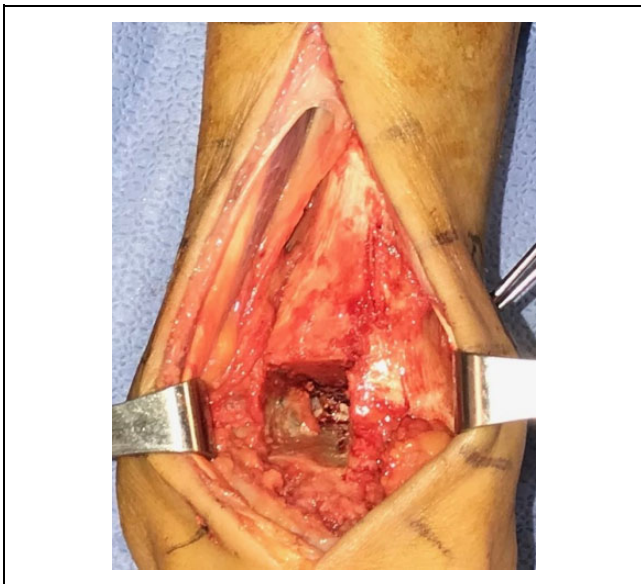


Figure 2. Intraoperative anteroposterior view of the ankle demonstrating the 2×2×2-cm bone defect between the tibia and talus for insertion of the MFC bone flap. MFC, medial femoral condyle.

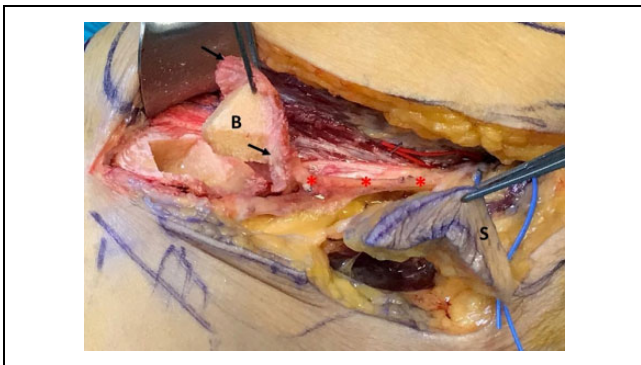


Figure 3. Intraoperative view of the MFC flap isolated on the descending genicular artery pedicle (asterisks). The 2×2×2-cm bone flap (B) has been harvested from the medial femoral condyle with a large cuff of periosteum (arrows). A chimeric 4×2-cm fasciocutaneous paddle (S) was also included in the flap based off of a perforating vessel to provide additional soft tissue and allow primary closure of the recipient site. MFC, medial femoral condyle.

independently predictive of MFC nonunion ($P = .004$). No other medical comorbidities were associated with the development of nonunion.

Although prior hindfoot surgery in general was not associated with subsequent MFC nonunion ($P = .367$), history of previous failed arthrodesis did correlate with MFC interface nonunion ($P = .042$). Moreover, although there was a relatively higher incidence of nonunion observed with talonavicular arthrodesis (4 of 7, $P = .110$), talonavicular flap insertion site (3 of 8, $P = .713$), and hardware failure (2 of 3, $P = .108$), this did not reach significance. Flap complications ($P = .252$), bone flap fixation method ($P = .901$), and

bone flap volume ($P = .789$) also did not correlate with subsequent nonunion. Additionally, bone flap volume did not correlate with time to union.

In order to measure functional outcomes, AOFAS Hind-foot Scores were calculated for patients (Table 5). Mean preoperative scores were 52.3 (range 26-72). When evaluated at least 6 months postoperatively, average AOFAS scores had increased significantly to 70.7 (range 28-96) ($P < .001$). Adjusting for the large number of arthrodesis patients, the sagittal and hindfoot motion subscores were removed and demonstrated an even larger difference between mean preoperative (43.8 ± 12.6) and postoperative (65.8 ± 16.4) AOFAS scores ($P < .001$). Subgroup analysis within the scoring system demonstrated a significant improvement in pain scores from 14.2 to 27.3 out of 40 ($P < .001$). Although the overall functional improvement score increased postoperatively 30.3 to 34.2 out of 50, this trend did not reach significance ($P = .063$). Within the functional outcomes score, however, significant improvement was seen in activity limitations ($P < .001$), walking distance ($P = .027$), walking surfaces ($P = .002$), gait abnormality ($P = .030$), and hindfoot motion ($P = .001$). Sagittal motion trended downward ($P = .095$), consistent with the majority of our cohort having an arthrodesis performed (88%). There was significant improvement in ankle alignment scores as well postoperatively ($P = .004$).

Discussion

In the setting of compromised vascular supply to the bones of the foot and ankle related to trauma, surgery, or other mechanisms, the risk of AVN and arthrodesis nonunion may be as high as 30% to 40%.⁷ Trauma was the most common antecedent etiology for the presented patients above, resulting in avascular necrosis, arthritis, and osseous nonunion in the vast majority of those patients.

Structural bone grafting with autograft or allograft is an option for bone defects and has been used to treat multiple different foot and ankle defects with varying success rates according to the degree of pathology present. For calcaneal injuries, subtalar distraction arthrodesis with an autologous intercalary bone block have demonstrated union rates between 86% and 95%.¹⁵ A series of 44 structural allograft reconstructions for a heterogeneous cohort of tumor resections demonstrated a 79% allograft survival rate at 5 and 10 years, with a complication rate of 36%.¹ Salvage ankle arthrodesis for severe talus AVN or failed total ankle arthroplasty has traditionally been treated with a cortical structural allograft such as a bulk femoral head to bridge the defect; however, successful fusion rates in these studies have ranged from 50% to 93% with reported amputation rates as high as 16% to 19%.^{4,16,21}

This third cohort of studies examining success rates of nonvascularized structural bone graft in salvage arthrodesis cases provides a similar literature cohort comparison to our series of salvage cases given the severity of pathology

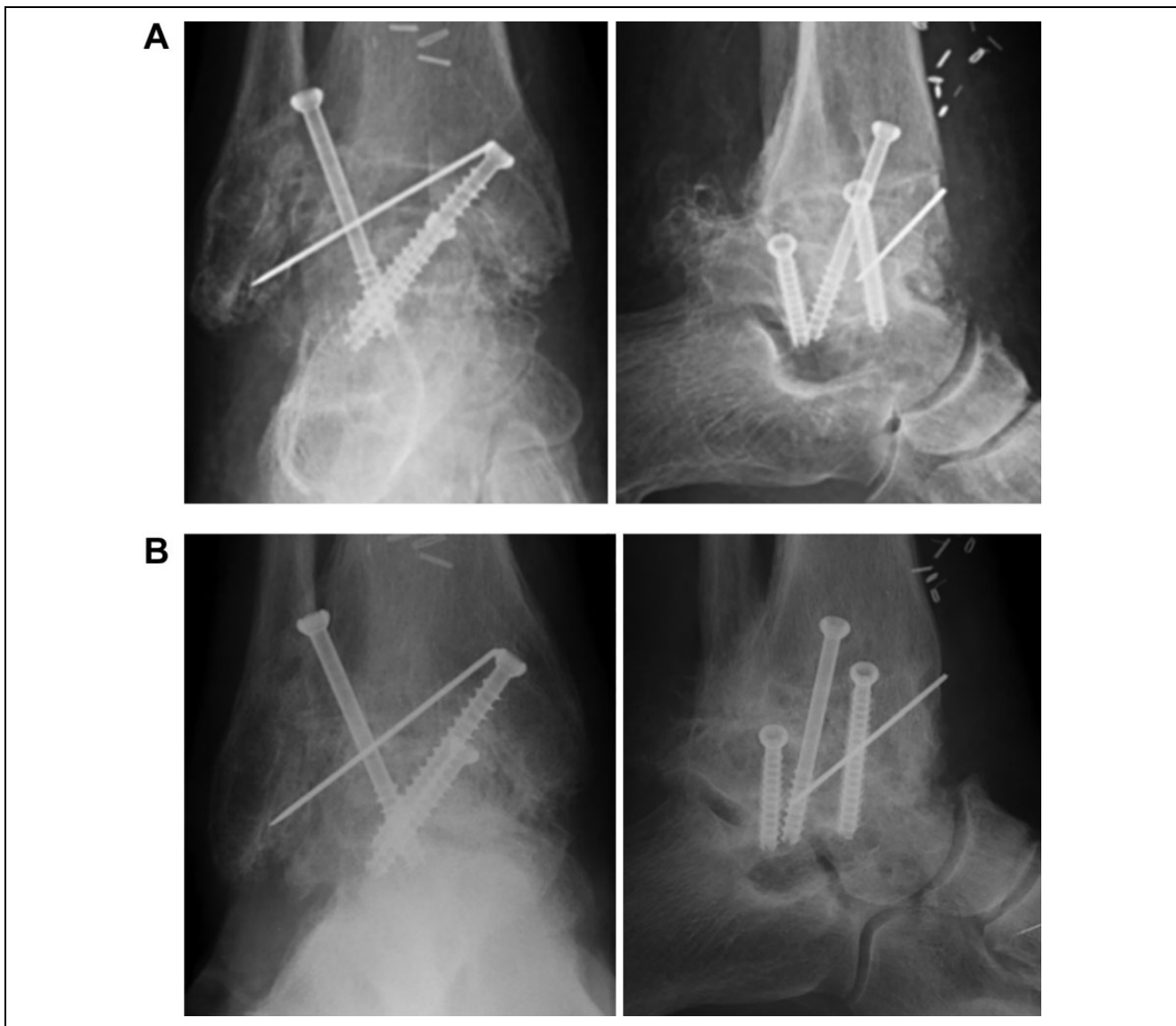

Figure 4. (A) Anteroposterior and lateral radiographs of the patient obtained 4 weeks status post tibiotalar arthrodesis with 3 screws transfixing the tibiotalar joint. The MFC bone flap is well opposed to the tibia and talus and secured in the defect seen in Figure 2 with Kirschner wire fixation. (B) Anteroposterior and lateral weightbearing radiographs obtained 1 year postoperatively demonstrating successful ankle fusion with full incorporation of the vascularized bone graft. MFC, medial femoral condyle.

present in both groups. Within our series of challenging patients where AVN was present in 83% of patients and more than 50% had failed prior arthrodesis, MFC-vascularized bone transfer ultimately achieved osseous union in 89% of patients. The 3 patients who did not achieve complete union nonetheless were ambulatory and not interested in pursuing further surgery. Ultimately, our reported success rate is at the reported upper end of the nonvascularized structural allograft success rates and, importantly, all patients in our cohort avoided amputation.

Functional status was also significantly improved after MFC reconstruction, with AOFAS Hindfoot Scores increasing from 52 preoperatively to 71 in the postoperative period ($P = .001$). This finding is largely driven by the significant

improvement in the pain subscore from an average of 14 to 27 postoperatively. Although the overall function subscore increase was not statistically significant, 5 of the 7 score components demonstrated significant improvement and the alignment subscore increased as well. When scores are adjusted to remove the sagittal and hindfoot motion components due to the postoperative immobilization of the arthrodesis patients, there is an even larger difference between mean preoperative (43.8 ± 12.6) and postoperative (65.8 ± 16.4) AOFAS scores ($P < .001$).

Although our AOFAS scores were significantly improved, the mean postoperative score of 71 was slightly worse than the mean of 81 achieved by Hintermann et al in their series of 14 MFC flaps performed for extended

Table 2. Operative Details of MFC Hindfoot Procedures.

Orthopedic Procedure	MFC Insertion n Site	n Bone Flap Fixation Method	Bone Flap Volume, cm ³	Recipient Artery
Tibiotalocalcaneal arthrodesis	11 Tibiotalar joint Sinus tarsi	9 K-wire (n = 8); screw (n = 1) 2 K-wire (n = 2)	12.2 (6.5-18.4)	AT (n = 10); PT (n = 1)
Talonavicular arthrodesis	7 Talonavicular joint	7 K-wire (n = 4); K-wire and screw (n = 1); plate and screw (n = 1); press-fit (n = 1)	7.8 (2-16)	AT (n = 5); PT (n = 2)
ORIF navicular nonunion	4 Navicular waist	4 K-wire and screw (n = 3); K-wire (n = 1)	3.8 (1.7-6)	AT (n = 4)
Triple arthrodesis	4 Talonavicular joint Navicular (excised)	2 Press-fit (n = 2) 2 K-wire (n = 1); plate (n = 1)	14.4 (10.5-17.5)	AT (n = 3); PT (n = 1)
Subtalar arthrodesis	2 Sinus tarsi	2 K-wire (n = 1); screw (n = 1)	10.5 (9-12)	AT (n = 2)
Tibia saucerization	2 Tibia metaphysis	2 Press-fit (n = 2)	9.8 (9-10.5)	AT (n = 1); PT (n = 1)

Abbreviations: AT, anterior tibial; MFC, medial femoral condyle; ORIF, open reduction internal fixation; PT, posterior tibial.

Table 3. MFC Reconstructive Outcomes.^a

Patients, n	27
Length of stay, d, mean \pm SD (range)	4.9 \pm 2.2 (3-11)
Follow-up, mo, mean \pm SD (range)	15.8 \pm 7.7 (4-33)
Complications	
Wound breakdown	2 (7)
Hardware failure	3 (11)
Nonunion	6 (22)
Osteomyelitis	0 (0)
Additional procedures performed	15 (56)
Soft tissue	6 (22)
Flap debulking	4 (15)
Wound debridement	2 (7)
Orthopedic	9 (33)
Revision arthrodesis	5 (19)
Hardware removal	3 (11)
Heterotopic bone excision	1 (37)
Time to weight bearing	
Partial weight bearing, d, mean \pm SD (range)	49.3 \pm 22.0 (26-100)
Full weight bearing, d, mean \pm SD (range)	98.7 \pm 38.6 (57-208)
Orthopedic outcomes	
Primary osseous union	20 (74)
Time to primary union, d, mean \pm SD (range)	217 \pm 114 (110-475)
Secondary osseous union	4 (15)
Chronic nonunion	2 (7.4)
Asymptomatic partial union	1 (4)
Overall bony union achieved	24 (89)
Overall time to union, days, mean \pm SD (range)	271 \pm 165 (110-628)

Abbreviation: MFC, medial femoral condyle.

^aValues are n (%), unless otherwise noted.

osteocondral lesions (OCLs) of the talus.¹³ Their preoperative score was also higher than ours (65 vs 52), however, which is suggestive of more severe baseline hindfoot pathology within our cohort. This pathologic heterogeneity precludes direct functional outcomes comparison between the 2 studies; however, their work comprises the next largest MFC series after this current work and serves only as a

comparison of flap outcomes. Interestingly, both studies demonstrated identical 13-point improvements in pain subscores postoperatively and no significant difference in overall functional subscores. As those authors point out, these score results need to be considered within the limitations of the scoring system and the relatively heavy weighting of pain. Despite the limitations, our AOFAS score results demonstrate significant improvements in both pain and functional components postoperatively.

Average time to bony union in our cohort was 7.2 months, which is quicker than other documented union rates using free fibular and iliac-crest flaps.^{3,28} Additionally, average time to full weight-bearing in our patients was 3 months shorter than previously reported.^{11,26} In their series of MFC flaps for talus OCLs, however, Hintermann et al demonstrated complete incorporation of the bone flap within 8-13 weeks.¹³ Similar to their higher AOFAS scores, the longer time to union observed in our cohort likely reflects more severe baseline pathology among our patients. Their mean flap volume was 3.36 cm³ compared with 10.4 cm³ in our patients indicating significantly larger defect size; however, flap volume was not found to correlate with time to union in our cohort.

Previous studies have demonstrated the use of other vascularized bone flaps, like the free fibula or iliac crest, to augment ankle arthrodesis with varying rates of success.^{3,26,28} The MFC flap adds to the foot and ankle reconstructive armamentarium as another possible source of vascularized periosteum and corticocancellous bone for defects up to 3 to 4 cm in length.¹⁷ Importantly, the MFC offers reduced donor site morbidity compared with other options.^{8,23,27} After harvest of the medial femoral condyle, studies have demonstrated that the femur has minimal reparative bone formation and no new degenerative joint disease, with the most frequently sited complication being altered sensation. The stability of the knee is preserved through visualization and protection of the medial collateral ligament. This is corroborated by our patients who reported no functional compromise in the donor leg and only one donor site complication (seroma requiring operative

Table 4. Risk Factors for Nonunion After MFC Reconstruction.^a

	Union	Nonunion	P value
Total	21	6	
Age, y, mean \pm SD	51.9 \pm 19.9	41.4 \pm 10.2	.229
Gender			.088
Male	12	1	
Female	9	5	
BMI, mean \pm SD	28.6 \pm 5.6	40.0 \pm 7.1	.001
BMI >30	9	6	.017
BMI >35	2	4	.011
Charlson Comorbidity Index, mean \pm SD	1.7 \pm 1.6	0.8 \pm 1.0	.230
Current smoker	5	0	.252
Prior hindfoot surgery	15	5	.367
Prior ORIF	10	3	.352
Prior arthrodesis	11	6	.042
Prior bone grafting	9	2	.338
Arthritis	16	6	.252
Nonunion	15	6	.183
AVN present	17	5	.445
Orthopedic procedure			.110
ORIF navicular nonunion	2	0	
Subtalar arthrodesis	1	1	
Talonavicular arthrodesis	3	4	
Tibial metaphysis saucerization	2	0	
Tibiotalocalcaneal arthrodesis	9	1	
Triple arthrodesis	4	0	
Bone flap insertion site			.713
Navicular	4	1	
Sinus tarsi	3	1	
Talonavicular	5	3	
Tibia metaphysis	2	0	
Tibiotalar	7	1	
Bone flap fixation method			.901
K-wire	11	4	
Screw	2	0	
Press-fit	4	1	
Plate	1	0	
Multiple	3	1	
Hardware failure	1	2	.108
Flap complication	5	0	.252
Flap volume, cm ³ , mean \pm SD	10.6 \pm 5.2	9.9 \pm 4.3	.789

Abbreviations: AVN, avascular necrosis; BMI, body mass index; MFC, medial femoral condyle; ORIF, open reduction internal fixation.

^aAll values are n, unless otherwise noted.

drainage). In contrast, both the iliac crest and fibula donor sites have the potential to leave the patient with marked pain, sensory, and functional deficits.^{12,19,22,24} Specific to iliac crest harvest, injury to ilioinguinal and iliohypogastric nerves, iliac wing fracture, and incisional hernias have been reported.¹¹

Soft tissue loss can be a concern with osteocutaneous flaps.³ Although it is possible to frequently find a perforator to supply a skin paddle with the MFC flap, there is variability in the potential size of the skin paddle. Fifteen flaps were taken with a skin paddle, and only 2 paddles were completely lost. Fortunately, this did not negatively impact the overall bony healing, as all bone flaps were noted to be viable. Although the rate of partial and total skin paddle loss was relatively high at 10% and 7%, respectively, this is

consistent with published literature on lower extremity free flap complications.²⁹

Previously, factors associated with ankle arthrodesis nonunion include tobacco use, diabetes, noncompliance, and substance abuse.^{6,9,14,25} Smoking, diabetes, and steroid use were not contraindications for MFC reconstruction; however, patients were encouraged to quit smoking 6 weeks prior to surgery and to follow up with their endocrinologist to ensure optimal perioperative glucose control. Out of all the comorbidities evaluated, we found that interface nonunion after MFC flap reconstruction was associated with obesity (BMI >30). More specifically, a BMI >35 was independently predictive of MFC nonunion on multivariate regression analysis. This may be related to increased stress transmitted across the vulnerable hindfoot bones with

Table 5. AOFAS Hindfoot Score Outcomes.

	Maximum Score	Preoperative, Mean \pm SD	Postoperative, Mean \pm SD	P Value
AOFAS Hindfoot Score	100	52.3 \pm 13.6	70.7 \pm 18.5	<.001
Adjusted ^a AOFAS score	86	43.8 \pm 12.6	65.8 \pm 16.4	<.001
Pain	40	14.2 \pm 9.9	27.3 \pm 11.5	<.001
Function	50	30.3 \pm 10.2	34.2 \pm 9.5	.063
Activity limitations	10	3.4 \pm 2.8	7.0 \pm 2.9	<.001
Walking distance	5	3.3 \pm 1.6	4.1 \pm 1.1	.027
Walking surfaces	5	3.0 \pm 1.3	4.0 \pm 1.0	.002
Gait abnormality	8	4.8 \pm 2.3	6.0 \pm 2.0	.030
Sagittal motion	8	4.8 \pm 3.2	3.4 \pm 3.5	.095
Hindfoot motion	6	3.7 \pm 2.3	1.5 \pm 2.3	.001
Ankle stability	8	7.4 \pm 2.2	8.0 \pm 0.0	.161
Alignment	10	7.7 \pm 2.9	9.4 \pm 1.6	.004

Abbreviation: American Orthopaedic Foot & Ankle Society.

^aAdjusted score removed sagittal and hindfoot motion scores to remove bias from arthrodesis patients in the cohort who would be immobile postoperatively.

ambulation in the setting of increased body weight. The talus and navicular bones are particularly at risk and this correlates with our observation that talonavicular arthrodesis and talonavicular bone insertion sites trended towards a higher incidence of nonunion. Although sufficient data is lacking, it has also been hypothesized that obesity may compromise casting and lead to difficulty maintaining a nonweightbearing status, thus leading to unwanted motion at the arthrodesis site.³⁰

A history of failed hindfoot arthrodesis was associated with subsequent MFC nonunion as well. A recent study showed that previous surgery is a risk factor for nonunion following MFC reconstruction of both the upper and lower extremity.¹⁸ History of prior failed arthrodesis as a risk factor for nonunion after MFC reconstruction likely reflects a higher degree of compromised blood supply to the residual hindfoot bones as a result of the significant prior surgical intervention(s).

This study is limited by the retrospective nature, low sample size, lack of a control group, and heterogeneity of orthopedic procedures performed. The vascularized bone flap insertion site varied according to the area of avascular bone and required tailoring to each specific defect in terms of flap size and fixation method. Longer follow-up duration would also have been preferable; however, all patients included in outcomes analysis had documented osseous outcomes and adequate clinical examination for relevant AOFAS score calculation postoperatively. Unfortunately, a validated functional outcome measure was not able to be calculated because of the retrospective nature of the study. Nonetheless, this study reports on the largest series of patients following MFC flap reconstruction of the foot of ankle. Despite limitations, we were able to demonstrate significant improvement in AOFAS functional outcomes and achieve relatively high fusion rates in a challenging patient population.

In conclusion, complex hindfoot pathology often warrants reconstruction with vascularized bone flaps rather than traditional bone grafting techniques. Additionally, prior failed reconstructive and arthrodesis attempts further compromise the hindfoot osseous vascularity and surrounding soft tissue. The MFC corticocancellous flap provided an option for complicated foot and ankle reconstruction with relatively low donor site morbidity, promising osseous union results, and improved functional outcomes. The results of this investigation will be used in the development of future prospective studies to further evaluate outcomes and better elucidate indications for the use of vascularized bone flaps in foot and ankle reconstruction.


Declaration of Conflicting Interests

The author(s) declared no potential conflicts of interest with respect to the research, authorship, and/or publication of this article. ICMJE forms for all authors are available online.

Funding

The author(s) received no financial support for the research, authorship, and/or publication of this article.

ORCID iD

John T. Stranix, MD,  <https://orcid.org/0000-0002-9770-6127>

References

1. Ayerza MA, Piuze NS, Aponte-Tinao LA, Farfalli GL, Muscolo DL. Structural allograft reconstruction of the foot and ankle after tumor resections. *Musculoskelet Surg*. 2016; 100(2):149-156.
2. Backus JD, Ocel DL. Ankle arthrodesis for talar avascular necrosis and arthrodesis nonunion. *Foot Ankle Clin*. 2019; 24(1):131-42.
3. Bishop AT, Wood MB, Sheetz KK. Arthrodesis of the ankle with a free vascularized autogenous bone graft. *Reconstruction*

- of segmental loss of bone secondary to osteomyelitis, tumor, or trauma. *J Bone Joint Surg Am.* 1995;77(12):1867-1875.
4. Bussewitz B, DeVries JG, Dujela M, McAlister JE, Hyer CF, Berlet GC. Retrograde intramedullary nail with femoral head allograft for large deficit tibiototalcalcaneal arthrodesis. *Foot Ankle Int.* 2014;35(7):706-711.
 5. Charlson M, Szatrowski TP, Peterson J, Gold J. Validation of a combined comorbidity index. *J Clin Epidemiol.* 1994;47:1245-1251.
 6. Doi K, Sakai K. Vascularized bone graft from the supracondylar region of the femur. *Microsurgery.* 1994;15(5):305-315.
 7. Frey C, Halikus N, Vu-Rose T, Ebramzadeh E. A review of ankle arthrodesis: predisposing factors to nonunion. *Foot Ankle Int.* 1994;15(11):581-584.
 8. Giladi AM, Rinkinen JR, Higgins JP, Iorio ML. Donor-site morbidity of vascularized bone flaps from the distal femur: a systematic review. *Plast Reconstr Surg.* 2018;142(3):363e-372e.
 9. Goebel M, Gerdsmeyer L, Muckley T, et al. Retrograde intramedullary nailing in tibiototalcalcaneal arthrodesis: a short-term, prospective study. *J Foot Ankle Surg.* 2006;45(2):98-106.
 10. Haddock NT, Alesh H, Easley ME, Levin LS, Wapner KL. Applications of the medial femoral condyle free flap for foot and ankle reconstruction. *Foot Ankle Int.* 2013;34(10):1395-1402.
 11. Haddock NT, Wapner K, Levin LS. Vascular bone transfer options in the foot and ankle: a retrospective review and update on strategies. *Plast Reconstr Surg.* 2013;132(3):685-693.
 12. Hakim SG, Tehrani AS, Wendlandt R, Jacobsen HC, Trenkle T, Sieg P. The impact of harvest length and detachment of the interosseous membrane on donor-site morbidity following free fibula flap surgery—a biomechanical experimental study. *J Craniomaxillofac Surg.* 2018;46(11):1939-1942.
 13. Hintermann B, Wagener J, Knupp M, Schweizer C, Schaefer DJ. Treatment of extended osteochondral lesions of the talus with a free vascularized bone graft from the medial condyle of the femur. *Bone Joint J.* 2015;97(9):1242-1249.
 14. Horst F, Gilbert BJ, Nunley JA. Avascular necrosis of the talus: current treatment options. *Foot Ankle Clin.* 2004;9(4):757-773.
 15. Jackson JB 3rd, Jacobson L, Banerjee R, Nickisch F. Distraction subtalar arthrodesis. *Foot Ankle Clin.* 2015;20(2):335-351.
 16. Jeng CL, Campbell JT, Tang EY, Cerrato RA, Myerson MS. Tibiototalcalcaneal arthrodesis with bulk femoral head allograft for salvage of large defects in the ankle. *Foot Ankle Int.* 2013;34(9):1256-1266.
 17. Katz RD, Parks BG, Higgins JP. The axial stability of the femur after harvest of the medial femoral condyle corticocancellous flap: a biomechanical study of composite femur models. *Microsurgery.* 2012;32(3):213-218.
 18. Kazmers NH, Thibaudeau S, Gerety P, Lambi AG, Levin LS. Versatility of the medial femoral condyle flap for extremity reconstruction and identification of risk factors for nonunion, delayed time to union, and complications. *Ann Plast Surg.* 2018;80(4):364-372.
 19. Kitaoka HB, Alexander IJ, Adelaar RS, Nunley JA, Myerson MS, Sanders M. Clinical rating systems for the ankle-hindfoot, midfoot, hallux, and lesser toes. *Foot Ankle Int.* 1994;15(9):349-353.
 20. Kitaoka HB, Patzer GL. Arthrodesis for the treatment of arthrosis of the ankle and osteonecrosis of the talus. *J Bone Joint Surg Am.* 1998;80(3):370-379.
 21. Lachman JR, Adams SB. Tibiototalcalcaneal arthrodesis for severe talar avascular necrosis. *Foot Ankle Clin.* 2019;24(1):143-161.
 22. Ling XF, Peng X. What is the price to pay for a free fibula flap? A systematic review of donor-site morbidity following free fibula flap surgery. *Plast Reconstr Surg.* 2012;129(3):657-674.
 23. Mehio G, Morsy M, Cayci C, et al. Donor-site morbidity and functional status following medial femoral condyle flap harvest. *Plast Reconstr Surg.* 2018;142(5):734e-741e.
 24. Myeroff C, Archdeacon M. Autogenous bone graft: donor sites and techniques. *J Bone Joint Surg Am.* 2011;93(23):2227-2236.
 25. Perlman MH, Thordarson DB. Ankle fusion in a high risk population: an assessment of nonunion risk factors. *Foot Ankle Int.* 1999;20(8):491-496.
 26. Piccolo PP, Ben-Amotz O, Ashley B, Wapner KL, Levin LS. Ankle arthrodesis with free vascularized fibula autograft using saphenous vein grafts: a case series. *Plast Reconstr Surg.* 2018;142(3):806-809.
 27. Rao SS, Sexton CC, Higgins JP. Medial femoral condyle flap donor-site morbidity: a radiographic assessment. *Plast Reconstr Surg.* 2013;131(3):357e-362e.
 28. Repo JP, Barner-Rasmussen I, Roine RP, Sintonene H, Tukiainen E. Role of free iliac crest flap in foot and ankle reconstruction. *J Reconstr Microsurg.* 2016;32(5):386-394.
 29. Stranix JT, Lee ZH, Jacoby A, et al. Forty years of lower extremity take-backs: flap type influences salvage outcomes. *Plast Reconstr Surg.* 2018;141(5):1282-1287.
 30. Thevendran G, Younger A, Pinney S. Current concepts review: risk factors for nonunions in foot and ankle arthrodeses. *Foot Ankle Int.* 2012;33(11):1031-1040.