

## UC Davis

### UC Davis Previously Published Works

**Title**

Use of Hypothermic Machine Perfusion to Identify Anatomic Variation Before Transplantation of a Pancake Kidney: A Case Report

**Permalink**

<https://escholarship.org/uc/item/2vg4v1f0>

**Journal**

Transplantation Direct, 5(5)

**ISSN**

2373-8731

**Authors**

Galganski, Laura A  
Perez, Richard V  
Troppmann, Christoph  
[et al.](#)

**Publication Date**

2019-05-01

**DOI**

10.1097/txd.0000000000000891

Peer reviewed

## OPEN

# Use of Hypothermic Machine Perfusion to Identify Anatomic Variation Before Transplantation of a Pancake Kidney: A Case Report

Laura A. Galganski, MD,<sup>1</sup> Richard V. Perez, MD,<sup>1</sup> Christoph Troppmann, MD,<sup>1</sup> John P. McVicar, MD,<sup>1</sup> Chandrasekar Santhanakrishnan, MD, MPH,<sup>1</sup> Bradley Mortimer,<sup>2</sup> Beau Kelly, MD,<sup>3</sup> and Junichiro Sageshima, MD<sup>1</sup>

**P**ancake kidneys are rarely used in transplantation due to their low incidence (<1/50 000) and complex anatomy.<sup>1-3</sup> Unrecognized vasculature can lead to bleeding or partial graft infarction if inappropriately managed, and unrecognized ureters can lead to urine leak or obstruction. Although the number may be small, fused kidneys doubtlessly contribute to deceased donor kidney discards that are categorized as anatomical abnormalities.<sup>4</sup>

Hypothermic machine perfusion (HMP) is used for kidney preservation to improve posttransplant outcome;<sup>5</sup> HMP is also used to evaluate graft quality.<sup>6</sup> Thus, we often use HMP in our deceased donor kidneys. In addition, we have shown the potential benefit of HMP use in the assessment of anatomically complex grafts, such as pediatric en bloc kidneys.<sup>7,8</sup>

In this report, we describe a transplant of a pancake kidney graft, for which we used HMP to help with the surgical pre-implantation management of this rare anomaly.

## CASE DESCRIPTION

The donor was a 37-year-old brain-dead man from head trauma. He had no significant medical history except for resection of a benign brain tumor 20 years prior. The kidney donor profile index was 43%. Kidney function was normal with negative urine protein and a serum creatinine level of 1.06 mg/dL. There was no known history of urological abnormalities; however, abdominal computed tomographic scan taken for trauma care demonstrated probable fused pelvic kidneys (Figure 1). The fused kidney graft was recovered, as a part of a multiorgan retrieval, en bloc with the abdominal aorta, inferior vena cava (IVC), and iliac vessels to preserve aberrant vasculature (Figure 2A and B).

At the transplant center, after back table examination and rough trimming of excessive tissue, the abdominal aorta was cannulated and the distal iliac arteries were ligated. The kidney graft was placed on HMP (RM3; Waters Medical Systems, Rochester, MN) and perfused with KPS-1 (Organ Recovery Systems, Itasca, IL) (Figure 2C-E). The pulsatile perfusion pressure was set to 47/24 mmHg, and the back table preparation was continued while the graft remained on HMP. Multiple areas of pulsatile arterial “bleeding” of the perfusate were observed. Small branches of the iliac arteries that did not course toward the kidney graft were meticulously ligated, whereas four main renal arteries (easily identified with pulsation on HMP) taking off from the bilateral iliac arteries were preserved. Multiple renal veins were identified draining into the iliac veins; however, it was more difficult to identify small venous branches that were “bleeding” because of the slower oozing of the transparent and colorless perfusate. Two ureters were identified and preserved. The graft remained on HMP until transplantation for 4 hours 11 minutes with a terminal flow of 144 mL/min and resistance of 0.20 mmHg/mL/min.

The recipient was a 57-year-old predialysis woman with a panel-reactive antibody level of 46%. The graft was implanted into the right iliac fossa. To position the bilateral donor ureters posteriorly near the recipient urinary bladder, the graft was flipped 180° around its craniocaudal axis. The donor abdominal aorta and IVC were anastomosed end-to-side to the recipient’s right common iliac artery and vein, respectively. Total cold ischemia time was 8 hours 2 minutes and warm ischemia time was 47 minutes. The graft perfused homogeneously

Received 14 February 2019. Revision received 5 March 2019.

Accepted 6 March 2019.

<sup>1</sup> Department of Surgery, University of California Davis Health, Sacramento, CA.

<sup>2</sup> University of California Davis Medical Center, Sacramento, CA.

<sup>3</sup> Sierra Donor Services, West Sacramento, CA.

The authors declare no conflicts of interest.

L.A.G. was supported by the National Center for Advancing Translational Sciences, National Institutes of Health (grant UL1 TR001860).

The content is solely the responsibility of the authors and does not necessarily represent the official views of the National Institutes of Health.

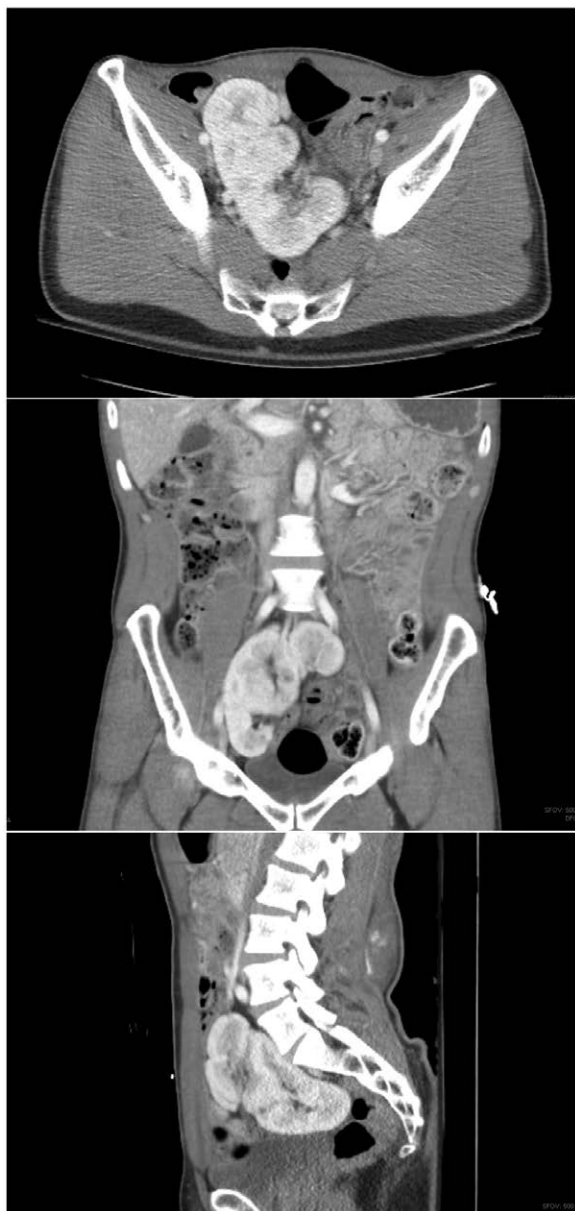L.A.G., C.T., and J.S. participated in the writing of the paper. L.A.G., R.V.P., C.T., J.P.M., C.S., B.M., B.K., and J.S. participated in the performance of the research.

Correspondence: Junichiro Sageshima, MD, University of California Davis Medical Center, 2315 Stockton Blvd, Sacramento, CA 95817. (jsageshima@ucdavis.edu).

Copyright © 2019 The Author(s). Transplantation Direct. Published by Wolters Kluwer Health, Inc. This is an open-access article distributed under the terms of the Creative Commons Attribution-Non Commercial-No Derivatives License 4.0 (CCBY-NC-ND), where it is permissible to download and share the work provided it is properly cited. The work cannot be changed in any way or used commercially without permission from the journal.

ISSN: 2373-8731

(Transplantation Direct 2019;5:e445; doi: 10.1097/TXD.0000000000000891. Published online 15 April, 2019.



**FIGURE 1.** Abdominal computed tomographic scan taken for trauma care demonstrated fused pelvic kidneys.

(Figure 2F and G). Following the reperfusion, there was no arterial bleeding; however, there was significant venous bleeding from branches not identified on back table preparation (off or on HMP) that resulted in an approximately 600 mL intraoperative blood loss that required transfusion of packed red blood cells. The 2 ureters were anastomosed separately to the bladder over double-J ureteral stents using the extravesical Lich-Gregoir technique.

The patient was discharged on postoperative day 5 with excellent early graft function (serum creatinine: 1.30 mg/dL). At 16 months, graft function remains excellent (serum creatinine: 0.85 mg/dL).

## DISCUSSION

This report describes the first successful transplant of a pancake kidney graft after HMP preservation. HMP was instrumental in detecting the numerous aberrant arterial

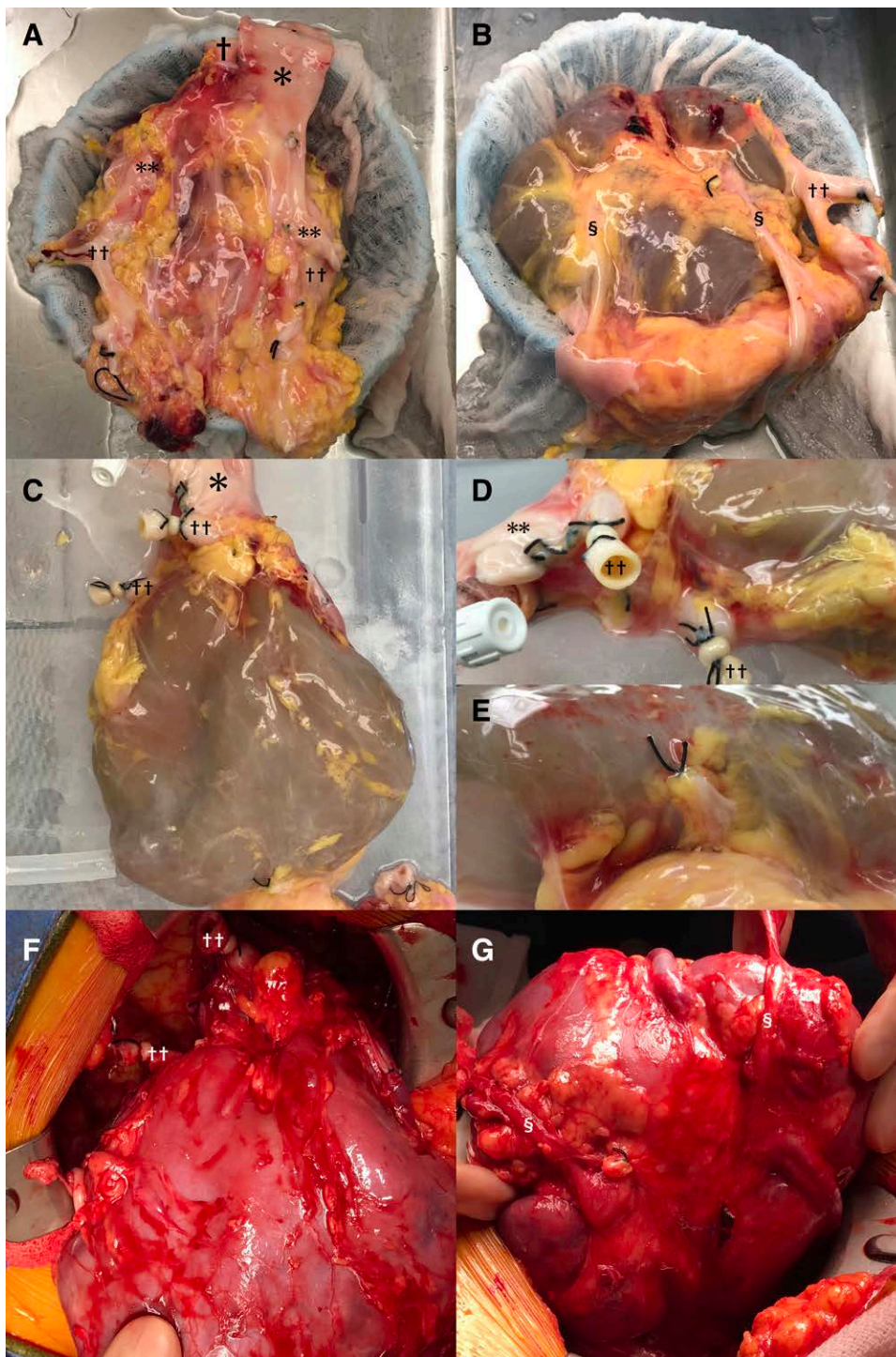
vessels but only partially helpful in venous detection. Fused kidney grafts may not be recovered or may be discarded due to their complex anatomy; however, transplanting a fused kidney graft is functionally akin to performing a dual kidney transplant as the donor's entire nephron mass is transplanted into 1 recipient. Therefore, a fused graft even from a marginal donor should be considered for transplant.

Pancake kidneys result from failed ascent from the pelvis with an extensive fusion of 2 kidneys. Unlike lump or disc kidney of crossed fused renal ectopia, they usually sit in the mid-pelvic area. Importantly, these kidneys retain their fetal vascular anatomy (ie, multiple renal arterial branches from the iliac arteries or distal aorta and a corresponding pattern for the renal venous drainage).<sup>1</sup> Two (or only occasionally 1) ureter(s) are present on the anterior aspect.<sup>2</sup> Although horseshoe kidneys are relatively common, other fusion anomalies with ectopia have an overall incidence of <0.1% in adults. Pancake kidneys represent only 2% of fused kidneys with an estimated incidence of 1/65 000 to 1/375 000.<sup>2,9,10</sup>

Several centers have successfully transplanted grafts with rare forms of congenital fusion anomaly (eg, crossed fused renal ectopia).<sup>3,11-15</sup> Reported techniques to improve vascular identification of such anatomically complex grafts include preoperative donor imaging.<sup>3</sup> However, without prior imaging, one may not identify a fusion anomaly until organ recovery, because these patients are often asymptomatic. It is thus important for a donor surgeon to understand possible anatomical variations of such ectopic and fused kidneys. Warm phase dissection can help identify aberrant vessels but may need to be limited in the case of multiorgan recovery. As it is crucial to preserve all arteries, veins, and ureters of the graft, it is advisable to recover these kidneys en bloc with the abdominal aorta, IVC, and iliac vessels. To that end, arterial cannulation before cross-clamp is often done through the iliac artery (instead of the more common cannulation of the lower abdominal aorta). The antegrade aortic cannulation may also be possible, but it is usually limited to abdominal organ-only recovery.

HMP was valuable in our case to precisely identify the arterial anatomy. After placing the kidney on the pump, we were able to identify multiple renal arterial branches by their evident distention and pulsation, which led to the decision to use the donor aorta and iliac arteries as an arterial conduit. Pulsatile leakage of the perfusate easily identified small untied branches. This important operative step would have been more difficult and less effective if HMP had not been used or nonpulsatile HMP had been used. Because of the continuous circulation of perfusate, HMP provided enough time to detect multiple small branches. This process might have been difficult by conventional gravity-fed perfusion of the graft. HMP also proved to be helpful for the venous preparation during the on-pump phase as it confirmed the majority of the venous drainage and helped create an IVC and iliac venous conduit. Nonetheless, given the complexity of the venous drainage of the pancake kidney, HMP was not able to identify all the numerous smaller venous branches—in particular, those that did not drain into the venous conduit. This was a consequence of the low venous flow coupled with the transparent perfusate. Because the HMP flow was approximately 145 mL/min during back table preparation, even the main renal vein had a flow rate of <2.5 mL/s. Slow leakage from small venous branches was not readily identifiable.





**FIGURE 2.** Anatomy of fused pelvic kidneys. A (back view), A fused pelvic pancake kidney was recovered with lower abdominal aorta (†), inferior vena cava (\*), and iliac vessels. Note the complex anatomy of iliac arteries (††) and iliac veins (\*\*). B, Two ureters (§) were identified in each side on the anterior aspect of the graft. C, The graft was cannulated through the abdominal aorta and placed on the pulsatile perfusion machine. D, Small arterial branches and distal ends of iliac arteries (††) were ligated. Access to the posterior vessels was accomplished by lifting (instead of flipping) the graft. E, One small venous branch directly draining from the inferior pole was ligated. F, Homogeneous reperfusion of the graft was observed. Note the overturned positioning of the graft. The back side of the graft is facing anteriorly. G, The front side of the graft is facing posteriorly.

Future efforts must, therefore, be directed at refining identification of these venous side branches. This could, for example, be accomplished by injecting fluorescein, methylene blue, or indigo carmine into the perfusion circuit. Alternatively, ex vivo normothermic perfusion (EVNP) might prove helpful in this setting as well. EVNP has gained popularity in various organs, including kidney preservation before transplantation.<sup>16-19</sup> To

date, the use of EVNP has focused mainly on viability testing and reduction of ischemic organ damage. Theoretically, use of EVNP may also be beneficial in the setting of complex graft anatomy because it mimics in vivo reperfusion of the graft; both arterial and venous bleeding would be visible when red blood cells or whole blood are used as perfusate. Although it has yet to be tested in this setting, EVNP use should thus also

be considered, if available, for the back table preparation of an anatomically complex graft (as this case) or in an ex vivo procedure that reproduces the procedure often performed in vivo (eg, liver graft splitting).

## CONCLUSIONS

HMP can play an important role in the identification of aberrant vascular anatomy during back table preparation of congenitally fused kidneys. It may optimize utilization of anatomically complex organs.

## REFERENCES

1. Cinman NM, Okeke Z, Smith AD. Pelvic kidney: associated diseases and treatment. *J Endourol.* 2007;21:836–842.
2. Babu CSR, Sharma V, Gupta OP. Renal fusion anomalies: a review of surgical anatomy. *Anat Physiol.* 2015;5:1–9.
3. Uzzo RG, Hsu TH, Goldfarb DA, et al. Strategies for transplantation of cadaveric kidneys with congenital fusion anomalies. *J Urol.* 2001;165:761–765.
4. Mohan S, Chiles MC, Patzer RE, et al. Factors leading to the discard of deceased donor kidneys in the United States. *Kidney Int.* 2018;94:187–198.
5. Moers C, Smits JM, Maathuis MH, et al. Machine perfusion or cold storage in deceased-donor kidney transplantation. *N Engl J Med.* 2009;360:7–19.
6. Jochmans I, O’Callaghan JM, Pirenne J, et al. Hypothermic machine perfusion of kidneys retrieved from standard and high-risk donors. *Transpl Int.* 2015;28:665–676.
7. Troppmann C, Daily MF, McVicar JP, et al. Hypothermic pulsatile perfusion of small pediatric en bloc kidneys: technical aspects and outcomes. *Transplantation.* 2009;88:289–290.
8. Sageshima J, Ciancio G, Chen L, et al. Pulsatile perfusion preservation of en bloc kidneys from small pediatric donors. *Transplantation.* 2009;87:782.
9. Kaufman MH, Findlater GS. An unusual case of complete renal fusion giving rise to a ‘cake’ or ‘lump’ kidney. *J Anat.* 2001;198(pt 4):501–504.
10. Miclaus GD, Pupca G, Gabriel A, et al. Right lump kidney with varied vasculature and urinary system revealed by multidetector computed tomographic (MDCT) angiography. *Surg Radiol Anat.* 2015;37:859–865.
11. Mekeel KL, Daley SM, Andrews PE, et al. Successful transplantation of a split crossed fused ectopic kidney into a patient with end-stage renal disease. *J Transplant.* 2010;2010:383972.
12. Lee SK, Mwipatayi BP, Abbas M, et al. Transplantation of crossed fused renal ectopia. *Asian J Surg.* 2007;30:82–84.
13. Bailey SH, Mone MC, Nelson EW. Transplantation of crossed fused ectopic kidneys into a single recipient. *J A Coll Surg.* 2002;194:147–150.
14. Ojo P, Ranga KV, Brown M, et al. Transplantation of a unilateral fused kidney with inferior ectopia: revascularization utilizing donor aorta and vena cava. *Conn Med.* 2008;72:585–588.
15. Salahi H, Salehipour M, Bahador A, et al. Transplantation of a lump or cake kidney: a case report. *Saudi J Kidney Dis Transpl.* 2006;17:577–578.
16. Nicholson ML, Hosgood SA. Renal transplantation after ex vivo normothermic perfusion: the first clinical study. *Am J Transplant.* 2013;13:1246–1252.
17. Kathis JM, Hamar M, Echeverri J, et al. Normothermic ex vivo kidney perfusion for graft quality assessment prior to transplantation. *Am J Transplant.* 2018;18:580–589.
18. Blum MF, Liu Q, Soliman B, et al. Comparison of normothermic and hypothermic perfusion in porcine kidneys donated after cardiac death. *J Surg Res.* 2017;216:35–45.
19. Kabagambe SK, Palma IP, Smolin Y, et al. Combined ex vivo hypothermic and normothermic perfusion for assessment of high-risk deceased donor human kidneys for transplantation. *Transplantation.* 2019;103:392–400.