

UC Davis

UC Davis Previously Published Works

Title

Extended Fasciocutaneous Flaps for Autologous Augmentation Mastopexy With Upper Body Lift After Massive Weight Loss

Permalink

<https://escholarship.org/uc/item/2vh7m8z7>

Journal

Annals of Plastic Surgery, 74(&NA;)

ISSN

0148-7043

Authors

Patel, Nirav B
Wong, Michael S

Publication Date

2015-05-01

DOI

10.1097/sap.0000000000000413

Peer reviewed

Extended Fasciocutaneous Flaps for Autologous Augmentation Mastopexy With Upper Body Lift After Massive Weight Loss

An Early Experience

Nirav B. Patel, MD, MS, JD, and Michael S. Wong, MD

Introduction: Common upper body findings after massive weight loss (MWL) include breast ptosis, projection loss, flattening, inframammary fold descent, and back rolls. Although implants address volume loss, manifestations of circumferential excess (ie, back rolls) are ignored. We review our experience with extended lateral fasciocutaneous flaps incorporating circumferential excess tissue, typically removed in upper body lifts (UBLs), for autologous augmentation mastopexy.

Methods: We reviewed all cases of simultaneous autoaugmentation mastopexy and UBL, using extended lateral chest wall fasciocutaneous flaps, performed after MWL. Donor sites were designed with scars residing within the bra line (UBL) or midaxillary line [modified UBL (mUBL)]. We analyzed demographics, clinical indications, and complications.

Results: Between 2007 and 2013, 7 patients underwent 13 extended fasciocutaneous flap reconstructions for autoaugmentation mastopexy, combined with UBL or mUBL. All patients underwent procedures with flaps taken from the back or from the midaxillary line. Mean initial body mass index (BMI) was 50.1 kg/m² with a preoperative, post-MWL BMI of 28.5 kg/m², weight loss of 58 kg, and BMI decrease of 21.6 kg/m². Among 6 patients who underwent bariatric surgery, the average interval between gastric bypass and autoaugmentation mastopexy was 41 months. Five patients underwent these procedures for aesthetic reasons, whereas 2 patients underwent breast reconstruction. Follow-up averaged 18 months. Complications occurred in 3 patients, with only 1 requiring reoperation.

Conclusions: Massive weight loss patients frequently present with breast volume loss and ptotic upper body soft tissue excess. Simultaneous mastopexy augmentation can be safely and reliably performed using extended fasciocutaneous flaps to autologously may be placed in aesthetically acceptable locations. Patients undergoing mUBLs with midaxillary line donor scars may conceal them with arms at their sides. Patients choosing back donor scars may conceal them within the bra line while having greater volumes available for augmentation. As is true with all flaps, one should assess distal tip perfusion before final inset, especially when using a flap extending to the midline back.

Key Words: breast reconstruction, fasciocutaneous flap, autologous, mastopexy, massive weight loss, upper body lift

(*Ann Plast Surg* 2015;74: S41–S45)

Common upper body contour changes after massive weight loss (MWL) include breast flaccidity and ptosis, loss of projection, flattening, inframammary fold (IMF) and nipple descent, and back rolls.^{1,2} Although volume loss can be readily addressed using an implant-based strategy, the often-present circumferential ptosis and back rolls are ignored. Additionally, despite the many implant options regarding

volume, shape, texture, and fill, numerous shortcomings exist with implants, including the possibility of mechanical failure, capsular contraction, rippling, migration, and malposition. Some patients may complain of an unnatural appearance and feel. For others, price may become prohibitive, especially when taking into consideration the need for periodic replacement requiring additional surgery.

Autologous breast reshaping and augmentation in the MWL population result in reconstructions that can age more naturally while avoiding all the implant-related complications. In addition, further upper body contour improvement may be achieved through the utilization of excess tissue for autoaugmentation.^{1–3} Using a lateral chest wall flap designed to selectively augment the breast can improve contour by reducing the lateral bra roll excess.^{4,5} Although this fasciocutaneous flap can provide some mild volume enhancement and improve lateral chest wall contour, the degree of augmentation may not entirely meet the patient's goal for enhancement, nor does it address the often circumferential excess commonly present after MWL.

With the development of a large body habitus, these patients develop a robust blood supply to their excess tissue with enlargement of their nutrient blood vessels. After weight loss, there is interval loss of fat without concomitant shrinkage of these nutrient vessels.⁵ We have begun taking advantage of these sizeable intercostal artery perforators to create extended fasciocutaneous flaps for autologous augmentation of the breast. By designing these extended fasciocutaneous flaps to lie within typical upper body lift (UBL) or modified UBL (mUBL) excisions, patients can achieve better circumferential upper body contour improvement while simultaneously enhancing breast size and shape. We review our early experience with extended fasciocutaneous flaps for autologous augmentation mastopexies in conjunction with completion UBLs in MWL patients.

PATIENTS AND METHODS

A retrospective review was performed of 7 patients who underwent simultaneous mastopexy autoaugmentation and UBL, using an extended lateral chest wall fasciocutaneous flap, performed at UC Davis Medical Center after MWL.

Planning the Extended Fasciocutaneous Flap UBL Donor Site

An UBL places the donor scar in the bra line. Preoperatively, standard Wise pattern mastopexy marks are made. Attention is turned to the back where the patient is placed in her bra to mark its borders in the standing position. This allows for accurate placement of the back scar within the confines of the bra line. Skin pinch around the anchor line from the back to the midaxillary lines bilaterally allows for accurate estimation of what would normally be discarded in a standard completion UBL, or in this case, what becomes the extended fasciocutaneous flap. The patient is then turned laterally and the midaxillary excision is then blended anteriorly with the standard Wise pattern, completing the preoperative marks (Fig. 1).

Received July 7, 2014, and accepted for publication, after revision, October 31, 2014. From the Division of Plastic Surgery, University of California, Davis, Sacramento, CA. Conflicts of interest and sources of funding: none declared.

Reprints: Michael S. Wong, MD, University of California Davis Medical Center, 2221 Stockton Blvd, Room 2123, Sacramento, CA 95817. E-mail: michael.wong@ucdmc.ucdavis.edu. Presented at the 64th Annual Meeting of the California Society of Plastic Surgeons, May 25, 2014, Newport Beach, CA.

Copyright © 2015 Wolters Kluwer Health, Inc. All rights reserved.

ISSN: 0148-7043/15/7401–S041

DOI: 10.1097/SAP.0000000000000413

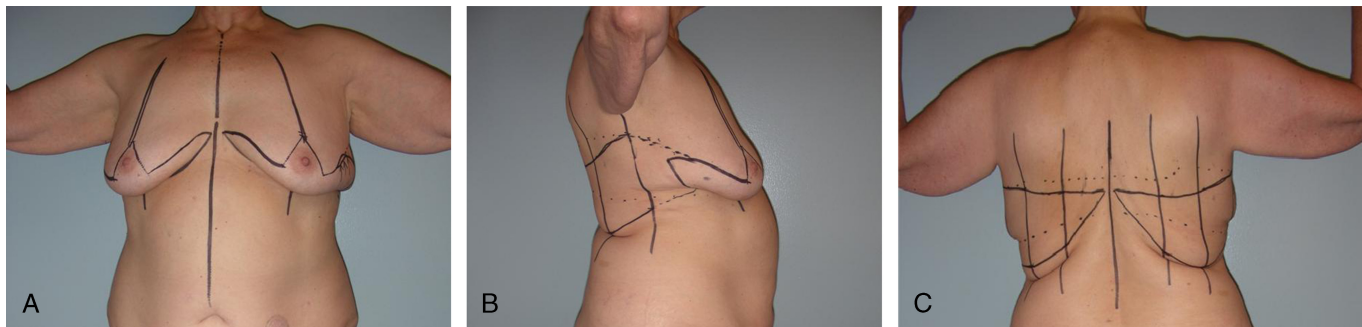


FIGURE 1. Preoperative markings for Patient 7 undergoing UBL: frontal (A), posterior (B), and right lateral (C) views.

mUBL Donor Site

With a mUBL, donor sites are designed such that the scar resides within the midaxillary line, resulting in smaller flaps and hence smaller volume enhancements. A Wise pattern mastopexy is modified laterally to create fasciocutaneous flaps extending laterally and superiorly into the axillary vault. The standard Wise pattern mastopexy marks are made first and then blended with a planned midaxillary line excision to end in the axillary vault. The extended flap is designed so the planned line of closure will lie within the midaxillary line. Anterior redundancy is pulled posteriorly to the midaxillary line and marked. Posterior redundancy is pulled anteriorly to the midaxillary line and similarly marked (Fig. 2).

Surgical Procedure

Positioned prone for the UBL, all marks are confirmed with towel clamps to ensure the wound can be closed. The fasciocutaneous flaps are then elevated from medial to lateral. The donor site is closed, completing the UBL (Fig. 3A). The flaps are temporarily stapled closed, wrapped in lap pads, and covered with OpSite dressings. The patient is then positioned supine and re-prepared for de-epithelialization of the medial and lateral flaps. The mastopexy skin flaps are elevated and the flap elevation is continued until the lateral intercostal artery perforators are seen. The flap is inset by rotating the flap superiorly and medially over the breast, adding superior pole fullness (Fig. 3B). This superior medial transposition of the flap also improves the lateral

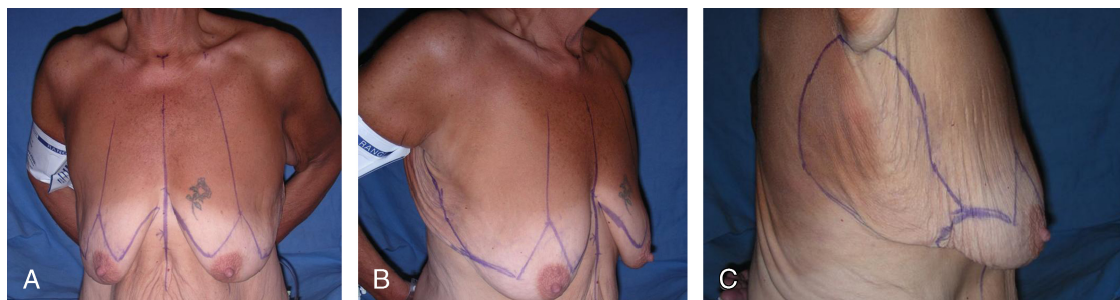


FIGURE 2. Preoperative markings for Patient 2 undergoing mUBL: front (A), right oblique (B), and right lateral (C) views.

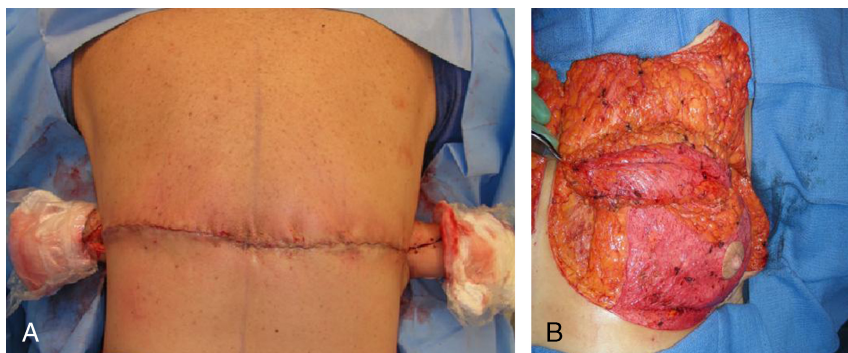


FIGURE 3. A, Representative intraoperative appearance of an UBL donor-site scar harvested from the back. B, Inset of a lateral pedicled fasciocutaneous flap harvested via an UBL procedure for autoaugmentation mastopexy.

sweep of the breast, often obliterated with weight loss. The medial breast flap is also elevated medial to lateral and rotated superior and laterally toward the breast meridian. Dermal plication sutures are placed to shape the augmented breast mound. Typical skin closure over the breast mound is performed.

For the mUBL, the entire procedure is performed in the supine position. Before flap elevation, the marks are confirmed using towel clamps to ensure ability to close the donor site. The extended fasciocutaneous flap is de-epithelialized in continuity with the breast and medial triangle of the Wise pattern. It is then raised beginning in the axillary vault proximally to the level of the lateral intercostal perforators. The flap inset and contouring is the same as with the flap obtained from the closure of the UBL, but shorter in length. For both UBL and mUBL approaches, adequate vascularity of the flaps is assessed intraoperatively by sharply trimming the flaps until bleeding is encountered. Standard closure of skin flaps follows.

Data collected and analyzed included demographics, clinical indications, and complications (ie, flap or fat necrosis; seroma; hematoma; wound dehiscence; infection; hypertrophic or other poor scarring; and inadequate volume).

RESULTS

Between June 2007 and August 2013, 7 patients averaging 54.9 years (range, 29–64 years) underwent 13 extended fasciocutaneous flap reconstructions for simultaneous mastopexy autoaugmentation, combined with UBL (9) or mUBL (4). All patients (1 unilateral and 6 bilateral) underwent mastopexy autoaugmentation with extended fasciocutaneous flaps taken from the back (5 patients, 9 flaps) or from the midaxillary line (2 patients, 4 flaps). Although 5 patients had these procedures for aesthetic reasons, 2 patients underwent procedures for breast cancer reconstruction. One had a unilateral mastopexy autoaugmentation from the back after undergoing contralateral pedicled transverse rectus abdominis myocutaneous flap breast reconstruction, whereas the other had reconstruction of her lumpectomy defect with bilateral mastopexy autoaugmentation and UBL. Both patients who underwent mastopexy autoaugmentation and mUBL had brachioplasty, one performed simultaneously whereas the other staged.

Mean initial body mass index (BMI) was 50.1 kg/m² (range, 43.3–69.1 kg/m²), with a mean preoperative, post-MWL BMI of 28.5 kg/m² (range, 23.1–34.7 kg/m²), mean weight loss of 58 kg (range, 28.9–101 kg), and mean BMI decrease of 21.6 kg/m² (range, 10.6–39.3 kg/m²). One patient had comparable weight loss and BMI changes after diet and exercise alone. Among the 6 patients who underwent bariatric surgery, all had laparoscopic Roux-en-Y gastric bypass surgery, and the average interval between bariatric procedure and mastopexy autoaugmentation was 41 months (range, 19–101 months). Sternal notch to nipple distance ranged from 23.5 to 29.5 cm preoperatively and 20.5 to 27 cm postoperatively, with no greater than a 1.5-cm discrepancy between postoperative breasts. No patients were diabetic or smokers, although 1 patient had a remote history of smoking 36 pack-years (Table 1).

Average length of follow-up was 18 months (range, 3–48 months). Complications occurred in 3 patients: a small (1 × 1 cm) chest wall dehiscence; a small (3 × 1.5 cm) unilateral breast dehiscence, combined with a small (1 mL) volume of distal flap necrosis; and one immediate postoperative, unilateral hematoma (after bilateral mastopexy autoaugmentation with completion UBL) that was promptly treated with operative evacuation and drain placement. The patient with both dehiscence and distal flap necrosis was prone to poor scar formation, as evidenced by hypertrophic scarring involving the left breast, umbilicus, and abdomen. Only the hematoma constituted a major complication requiring additional surgical intervention. The remaining complications were minor and resolved with expectant, nonoperative management.

TABLE 1. Patient Characteristics and Outcome

Patient	Age, y	History	Procedure	Interval Between		Post-MWL BMI, kg/m ²	Weight Loss, kg	Preoperative SN-N, cm	Postoperative SN-N, cm	Complications/Comments	Follow-up, mo
				Gastric Bypass	Mastopexy, mo						
1	63	Lap GB	B UBL	101		29.8	101	29.5 R, 29.0 L	24.5 R, 23.0 L	N/A	12
2	64	Lap GB, BL brachioplasty	B mUBL	19		30.2	61.4	28.0 R, 28.5 L	NR	1 × 1-cm chest wall dehiscence	7
3	57	Diet and exercise	B mUBL and brachioplasty	N/A		25.4	62.7	27.0 R, 27.5 L	25.0 R, 26.0 L	N/A	3
4	29	Lap GB	B UBL	23		23.1	55.0	28.5 R, 28.0 L	22.0 R, 23.0 L	N/A	48
5	54	L lumpectomy, ALND, and XRT; lap GB	B UBL	23		24.3	51.5	23.5 R, 23.5 L	20.5 R, 20.5 L	Partial thickness L breast ischemia below prior biopsy scar	5.5
6	53	Lap GB; TRAM	R UBL	53		34.7	28.9	26.5 R, 22.0 L	21.0 R, 22.0 L	R breast dehiscence (3 × 1.5 cm); R superior and medial pole fat necrosis	40
7	64	Lap GB	B UBL	24		31.8	45.5	NR	27.0 R, 27.0 L	Immediate postoperative hematoma—evacuated	12

ALND indicates axillary lymph node dissection; B, bilateral; L, indicates left; lap GB, laparoscopic gastric bypass; LBL, lower body lift; N/A, not applicable; NR, not recorded; R, right; SN-N, sternal notch to nipple distance; TRAM, transverse rectus abdominis myocutaneous flap; XRT, radiotherapy.

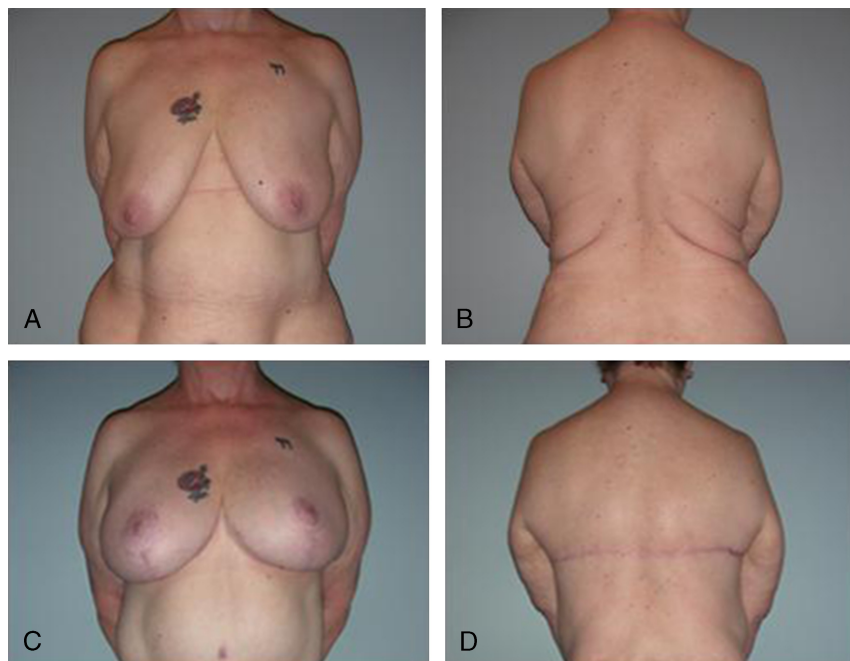


FIGURE 4. Patient 1, a 63-year-old woman presenting for autoaugmentation mastopexy via UBL, approximately 8½ years after undergoing laparoscopic gastric bypass, anterior (A) and posterior (B) views. Patient 1, 12 months after undergoing UBL with autoaugmentation mastopexy, anterior (C) and posterior (D) views.

Case 1

A 63-year-old woman presented with history of morbid obesity. She was treated by the bariatric surgery service with laparoscopic Roux-en-Y gastric bypass. She subsequently experienced a weight loss

of 101 kg with BMI decrease of 39.3 kg/m². She was evaluated by our service approximately 8½ years after her bypass and deemed an appropriate candidate for bilateral autoaugmentation mastopexy with UBL, using extended fasciocutaneous flaps with donor-site scars placed in

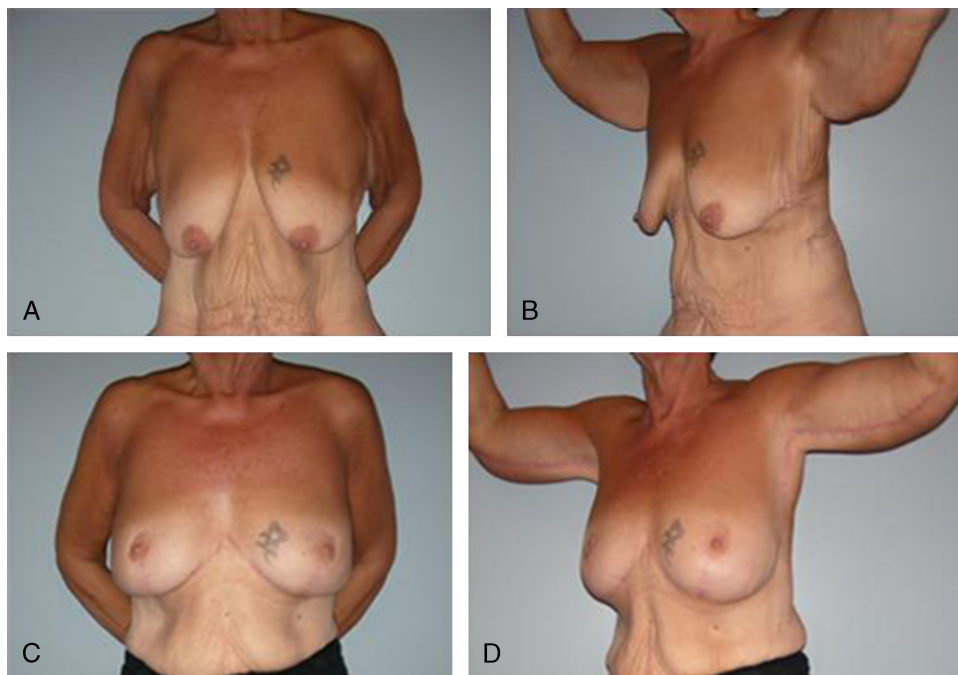


FIGURE 5. Patient 2, a 64-year old woman presenting for autoaugmentation mastopexy via mUBL, 19 months after undergoing laparoscopic gastric bypass, anterior (A) and left oblique (B) views. Patient 2, 7 months after undergoing autoaugmentation mastopexy with mUBL and 5 months from a subsequent bilateral brachioplasty, anterior (C) and left oblique (D) views.

the bra line of the back (Figs. 4A, B). This patient is shown at postoperative month #12 (Figs. 4C, D).

Case 2

A 64-year-old woman presented 19 months after gastric bypass surgery, having lost 61.4 kg with BMI decrease of 24.7 kg/m² (Figs. 5A, B). She subsequently underwent bilateral autoaugmentation mastopexy and mUBL, with her donor-site scars placed in the midaxillary line. She subsequently underwent bilateral brachioplasty at postoperative month #2. She had experienced a right chest wall dehiscence of 1 × 1-cm dimensions but no other wound healing issues. The same patient is depicted postoperative month #7 from autoaugmentation mastopexy and postoperative month #5 from her bilateral brachioplasty (Figs. 5C, D).

DISCUSSION

Massive weight loss patients frequently present with volume loss of the breasts in the presence of ptotic upper body soft tissue excess. The breast often demonstrates a long, deflated appearance with an ill-defined, inferiorly displaced IMF. It also exhibits loss of superior pole volume and ptosis, giving a flattened, pancake appearance. A hallmark of the post-MWL breast is inelastic, lax skin creating a deflated breast mound. Implant-based volume replacement is often an attractive option for both patients and practitioners. It is generally less technically challenging, requires less operative time when compared to autologous techniques, and has more rapid postoperative recovery while avoiding donor-site morbidity.

Breast implants, however, do have shortcomings. Over time, implants can develop capsular contracture, rippling, implant migration, asymmetry, and implant rupture. Autologous reconstruction may avoid these implant-related complications, and thus provides an appealing alternative, particularly in the post-MWL patient with generalized ptosis and redundant lateral, and often circumferential, thoracic soft tissue. In addition, results of autologous techniques can age more naturally with the patient.

Anatomic studies have demonstrated that lateral intercostal perforator-based flaps can be used for breast reconstruction.⁶ Extended fasciocutaneous flaps may be designed, taking advantage of large intercostal perforators often present in MWL patients, to perform autologous mastopexy augmentation safely and reliably while simultaneously improving circumferential upper body contour.⁵⁻⁷ Lateral intercostal artery perforators are based on the costal segment, and can facilitate design of a shorter flap for use in mastopexy. Both options minimize the donor-site morbidity attached to myocutaneous flap reconstructions requiring sacrifice of underlying muscles such as the latissimus dorsi.

Techniques to date have described use of shorter fasciocutaneous flaps.^{4,5} Although a viable reconstructive option in the MWL population, these described techniques limit the volume harnessed for autoaugmentation mastopexy. By contrast, the primary benefit of our extended fasciocutaneous flap is the ability to incorporate greater volumes for autoaugmentation. In what we refer to as a mUBL approach, we have extended the fasciocutaneous flap into the axilla. In addition, patients have the option of choosing an UBL donor scar on the back, enabling concealment within the bra line and providing additional tissue for volume enhancement.

Combined with an UBL, these lateral fasciocutaneous flap reconstructions can more completely address components of the upper torso deformity seen in the post-MWL population. The UBL corrects epigastric laxity, repositions the IMF more superiorly, excises lateral chest and mid-back skin rolls, and combined with mastopexy, reshapes the breast. Moreover, donor scars may be placed in aesthetically acceptable locations. Patients undergoing mUBL with the donor scar placed

in the midaxillary line may conceal their scars with arms positioned at their sides while allowing this scar to blend into a brachioplasty scar. Patients choosing a donor scar on the back may conceal their scar with their bra while concomitantly having a greater volume of tissue available for augmentation. As with any flap, one should assess distal tip perfusion appropriately before final inset, especially when using the entire flap extending to the midline of the back.

Limitations

Generalizing the results of this case series of 7 patients should be met with caution. In thinner patients with little excess circumferential volume, the potential for large volume autoaugmentation is limited. For these patients, a significant augmentation will require breast implants. Our preference is to perform autoaugmentation mastopexy, thus providing maximal soft tissue coverage to better camouflage ultimate placement of implants. The initial autologous augmentation enables use of smaller implants without the need for additional scars. Thus far, none of the patients we have described sought additional implant-based augmentation, and all are satisfied with the volume of autoaugmentation achieved. Caution is warranted in extrapolating this extended fasciocutaneous flap to the non-MWL population as the lateral intercostal perforators may not be robust enough to carry these larger flaps.

CONCLUSIONS

Mastopexy augmentation, coupled with simultaneous upper body lift, can be safely and reliably performed by using extended fasciocutaneous flaps to autologously augment the breast while improving circumferential upper body contour in MWL patients. Donor scars may be placed in aesthetically acceptable locations. Patients undergoing mUBLs with midaxillary line donor scars may conceal them with arms at their sides. Patients choosing a back donor scar associated with a complete UBL may conceal it within the bra line while having greater volumes available for augmentation.

Although the midaxillary donor-site technique is established, use of an extended fasciocutaneous flap is novel, and this preliminary study is the first to describe it in the plastic surgery literature. As is true with all flaps, one should assess distal tip perfusion before final inset, especially when using a flap extending to the midline back. Although the authors currently assess the UBL and mUBL flaps by trimming them until encountering bleeding tissue, intraoperative adjuncts such as SPY, that is, laser-assisted indocyanine green fluorescent dye angiography, may prove useful in assessing distal flap viability for subsequent patients undergoing these approaches to breast reconstruction.

REFERENCES

- Hurwitz DJ, Agha-Mohammadi S. Postbariatric surgery breast reshaping: the spiral flap. *Ann Plast Surg.* 2006;56:481-486.
- Losken A. Breast reshaping following massive weight loss: principles and techniques. *Plast Reconstr Surg.* 2010;126:1075.
- Rubin JP, Gusenoff JA, Coon D. Dermal suspension and parenchymal reshaping mastopexy after massive weight loss: statistical analysis with concomitant procedures from a prospective registry. *Plast Reconstr Surg.* 2009;123:782-789.
- Rubin JP, Khachi G. Mastopexy after massive weight loss: dermal suspension and selective auto-augmentation. *Clin Plast Surg.* 2008;35:123-129.
- Kwei SK, Borud LJ, Lee BT. Mastopexy with autologous augmentation after massive weight loss. *Ann Plast Surg.* 2006;57:361-365.
- Hamdi M, Spano A, Van Landuyt K, et al. The lateral intercostal artery perforators: anatomical study and clinical application in breast surgery. *Plast Reconstr Surg.* 2008;121:389.
- Akyurek M. Vertical mastopexy and lateral intercostal artery perforator (LICAP) flap with pectoralis muscle sling for autologous tissue breast augmentation in the bariatric patient. *Ann Plast Surg.* 2011;66:29-35.