

# UCLA

## UCLA Previously Published Works

### Title

Workshop on Neurobiology of Epilepsy appraisal: New systemic imaging technologies to study the brain in experimental models of epilepsy

### Permalink

<https://escholarship.org/uc/item/2wr184pf>

### Journal

Epilepsia, 55(6)

### ISSN

0013-9580

### Authors

Dedeurwaerdere, Stefanie  
Shultz, Sandy R  
Federico, Paolo  
et al.

### Publication Date

2014-06-01

### DOI

10.1111/epi.12642

Peer reviewed

# Workshop on Neurobiology of Epilepsy appraisal: New systemic imaging technologies to study the brain in experimental models of epilepsy

\*Stefanie Dedeurwaerdere, †Sandy R. Shultz, ‡Paolo Federico, and §Jerome Engel, Jr.

*Epilepsia*, 55(6):819–828, 2014  
doi: 10.1111/epi.12642

## SUMMARY



**Dr. Stefanie Dedeurwaerdere** is a neurobiologist at the University of Antwerp, Belgium.

Modern functional neuroimaging provides opportunities to visualize activity of the entire brain, making it an indispensable diagnostic tool for epilepsy. Various forms of noninvasive functional neuroimaging are now also being performed as research tools in animal models of epilepsy and provide opportunities for parallel animal/human investigations into fundamental mechanisms of epilepsy and identification of epilepsy biomarkers. Recent animal studies of epilepsy using positron emission tomography, tractography, and functional magnetic resonance imaging were reviewed. Epilepsy is an abnormal emergent property of disturbances in neuronal networks which, even for epilepsies characterized by focal seizures, involve widely distributed systems, often in both hemispheres. Functional neuroimaging in animal models now provides opportunities to examine neuronal disturbances in the whole brain that underlie generalized and focal seizure generation as well as various types of epileptogenesis. Tremendous advances in understanding the contribution of specific properties of widely distributed neuronal networks to both normal and abnormal human behavior have been provided by current functional neuroimaging methodologies. Successful application of functional neuroimaging of the whole brain in the animal laboratory now permits investigations during epileptogenesis and correlation with deep brain electroencephalography (EEG) activity. With the continuing development of these techniques and analytical methods, the potential for future translational research on epilepsy is enormous.

**KEY WORDS:** PET, MRI, EEG-fMRI, Tractography.

Current treatment for epilepsy suppresses seizures, but it does not alter the underlying epileptogenic process or associated comorbid conditions. A major priority of current research on epilepsy is disease modification, with a goal to cure or prevent epilepsy and its consequences. Modern neuroimaging now permits visualization of structural and func-

tional abnormalities of the entire brain, noninvasively, and has revolutionized clinical diagnosis. Functional neuroimaging, in particular, also offers the opportunity to elucidate aberrant pathophysiologic mechanisms and neuronal connections that might provide insights into novel therapeutic targets and biomarkers. However, research on animal models remains essential for obtaining correlative invasive electrophysiologic, anatomic, and molecular/cellular data, and for studying the process of epileptogenesis.

Systemic functional neuroimaging is now being performed as a research tool with animal models of epilepsy, and it provides unique opportunities for parallel animal/human investigations needed to develop interventions that will reverse or prevent the causes of disability experienced by people with epilepsy. There are numerous challenges associated with preclinical imaging, including influences of anesthesia, blood sampling, and kinetic evaluation for

Accepted March 25, 2014; Early View publication May 16, 2014.

\*Department of Translational Neuroscience, University of Antwerp, Wilrijk, Belgium; †Department of Medicine, The Royal Melbourne Hospital, The University of Melbourne, Parkville, Victoria, Australia; ‡Departments of Clinical Neurosciences and Radiology, University of Calgary, Calgary, Alberta, Canada; and §Department of Neurology, Neurobiology, and Psychiatry and Biobehavioral Sciences, David Geffen School of Medicine at UCLA, Los Angeles, California, U.S.A.

Address correspondence to Jerome Engel, Jr., Department of Neurology, David Geffen School of Medicine at UCLA, 710 Westwood Plaza, Los Angeles, CA 90095-1769, U.S.A. E-mail: engel@ucla.edu

Wiley Periodicals, Inc.

© 2014 International League Against Epilepsy

positron emission tomography (PET), and limited resolution, which eventually will require a certain degree of standardization if data are to be compared among laboratories and correlated with human investigations.

Herein we review findings from studies in the English literature retrieved from PubMed, as well as those presented by the authors at the **XII** Workshop on Neurobiology of Epilepsy (WONOEP 2013), that have utilized small animal PET, diffusion-weighted magnetic resonance imaging (MRI) and tractography, and functional MRI (fMRI) in animal models of epilepsy. Given that small animal PET is a relatively new technology in the epilepsy field, only a limited number of papers have been published. Therefore, all papers through October 2013 related to PET imaging in rodents and epilepsy are discussed in the review. Considering the extensive number of animal epilepsy studies that have incorporated various MRI methods, a comprehensive review of MRI was beyond the scope of this paper. Rather, this review considered all publications on diffusion-weighted imaging (DWI), tractography, connectomics, and fMRI in rodents and epilepsy through December 2013.

## SMALL ANIMAL POSITRON EMISSION TOMOGRAPHY IMAGING

Since the advent of dedicated small animal PET in the mid-1990s, the use of molecular imaging in preclinical research has increased exponentially and has become a critically important tool for biomedical sciences.<sup>1</sup> First, it allows sensitive quantification of a virtually unlimited range of molecular targets *in vivo*, which is unique for nuclear imaging. Second, it gives noninvasive three-dimensional (3D) brain image information allowing for follow-up and serial scanning in contrast to terminal studies. Third, for the reasons mentioned earlier, implementation into clinical applications is enhanced. This neuroimaging technique has reliably revealed abnormalities in many epilepsy syndromes in preclinical and clinical studies.<sup>2–4</sup>

### Progression in small animal PET of epileptogenesis with <sup>18</sup>F-fluorodeoxyglucose

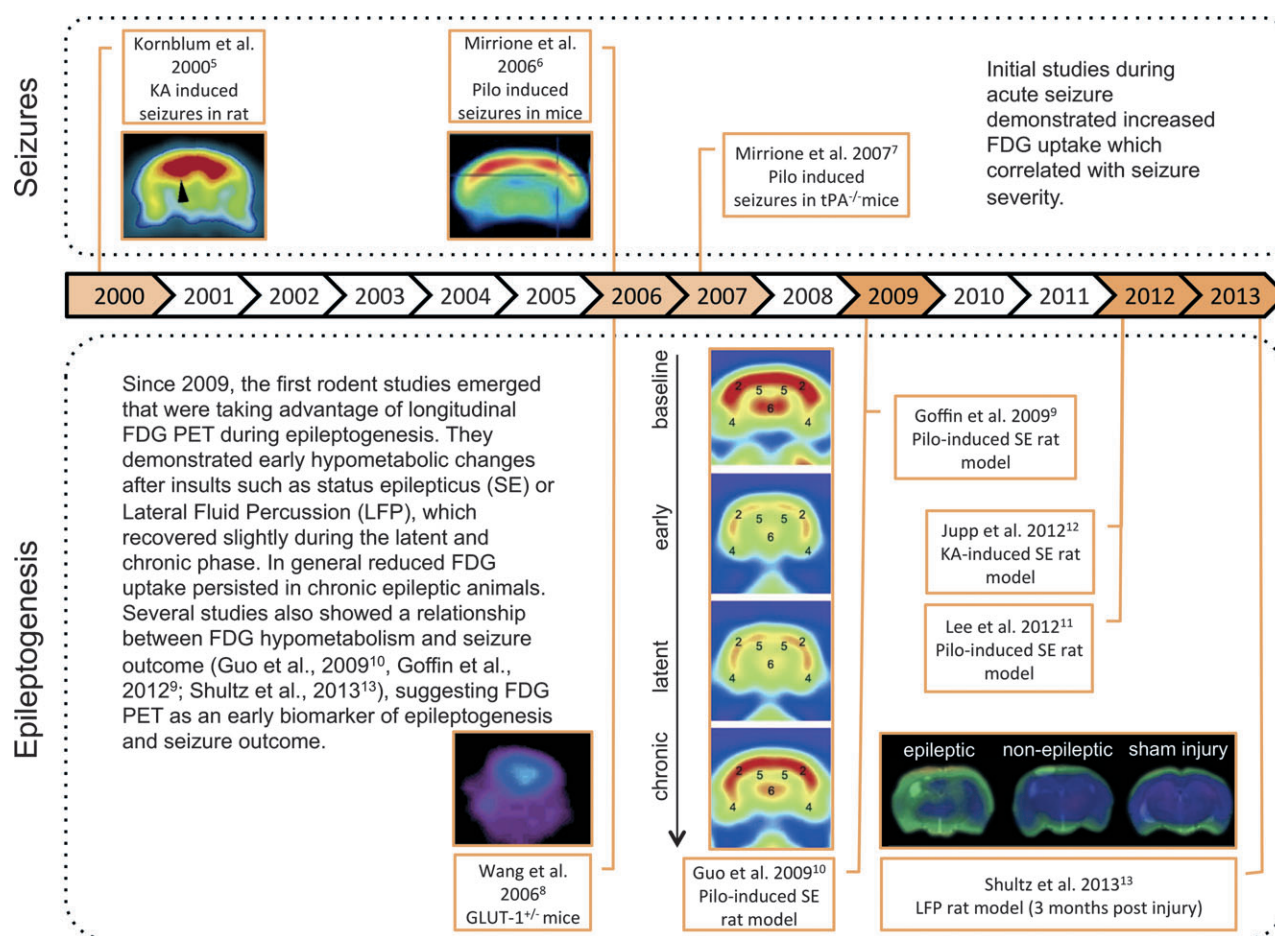
Over the last two decades, small animal PET studies have emerged in the field of epilepsy. In particular, temporal lobe epilepsy (TLE) models have been used widely to study epileptogenesis and chronic epilepsy. Initially, the focus of several studies <sup>18</sup>F-fluorodeoxyglucose (FDG) PET to investigate alterations in brain glucose metabolism related to brain activation. The first studies have demonstrated strong increases in brain glucose metabolism induced by acute seizures provoked by excitotoxins such as kainic acid and pilocarpine in normal rat and mice with FDG small animal PET (Fig. 1, top).<sup>5,6</sup> This technique may help understand mechanisms of seizure generation in models such as transgenic tissue plasminogen activator knockout mice, where a unique pattern of FDG uptake is seen following

pilocarpine administration, possibly explaining the reduced sensitivity to seizures compared to wild-type mice.<sup>7</sup> Furthermore, FDG-PET was used to investigate alterations in chronic epilepsy models. In a mouse model of Glut-1 haploinsufficiency, a human genetic condition associated with epilepsy, reduced FDG brain uptake was found.<sup>8</sup> This is also the general finding in models of TLE such as post-status epilepticus (SE) or models of posttraumatic epilepsy such as lateral fluid percussion injury (LFP),<sup>9–13</sup> in agreement with observations in patients with TLE.

A significant advantage of animal models is that they allow the investigation of different stages of epileptogenesis preceding the manifestation of chronic epilepsy, which is difficult to do in patients. These studies have shown that brain glucose hypometabolism occurs early in the processes of limbic epileptogenesis in post-SE rat models (Fig. 1, bottom).<sup>9–12</sup> Of interest, Guo et al.<sup>10</sup> found that early hypometabolism in the entorhinal cortex correlated with the later development of spontaneous recurrent seizures. Also in the LFP model, hypometabolism in the ipsilateral hippocampus was able to predict the epileptic outcome, whereas cortical structural damage detected on MRI was not related to seizure susceptibility.<sup>13</sup> Jupp et al.<sup>12</sup> investigated potential confounding effects of cell loss in the post-SE model and concluded that the observed hypometabolism does not merely reflect cell loss and brain atrophy but may represent cellular mechanisms occurring early during epileptogenesis.

### New PET ligands for small animal PET studies

Currently, small animal PET studies have taken advantage of the opportunity to study a wide range of biologic processes beyond brain glucose metabolism. Dysfunctional  $\gamma$ -aminobutyric acid (GABA)ergic neurotransmission and more particularly decreased GABA<sub>A</sub>/benzodiazepine receptors (GABA<sub>A</sub>/CBZR) have been demonstrated in patients with TLE using flumazenil PET.<sup>14,15</sup> These findings have been reproduced in the kindling model<sup>16</sup> and in the post kainic acid-induced status epilepticus (KASE) model.<sup>17</sup> In the latter model, Vivash et al.<sup>18</sup> investigated this further using *in vitro* autoradiography and *in vivo* small animal PET. Combining *in vivo* PET imaging techniques with autoradiography allows detailed evaluation of the spatial and temporal changes. Cross-sectional <sup>3</sup>H-flumazenil autoradiography demonstrated time-dependent and subregional hippocampal changes in GABA<sub>A</sub>/CBZR density, with an initial increase 24 h after SE followed by a persistent decrease 2–6 weeks after SE in most hippocampal regions, except for the stratum moleculare of the dentate gyrus. Second, new fluorinated flumazenil radioligands were evaluated,<sup>19</sup> as these offer the practical advantage of more widespread clinical applications because an on-site cyclotron is not required and they allow a more efficient preclinical use as more animals can be scanned from the same radiosynthesis. Next, noninvasive quantification



**Figure 1.**

Progression in small animal PET of epileptogenesis with FDG. KA, kainic acid; LFP, lateral fluid percussion; pilo, pilocarpine; tPA, tissue plasminogen activator; GLUT, glutamate transporter. All images are reproduced with permission of authors cited.

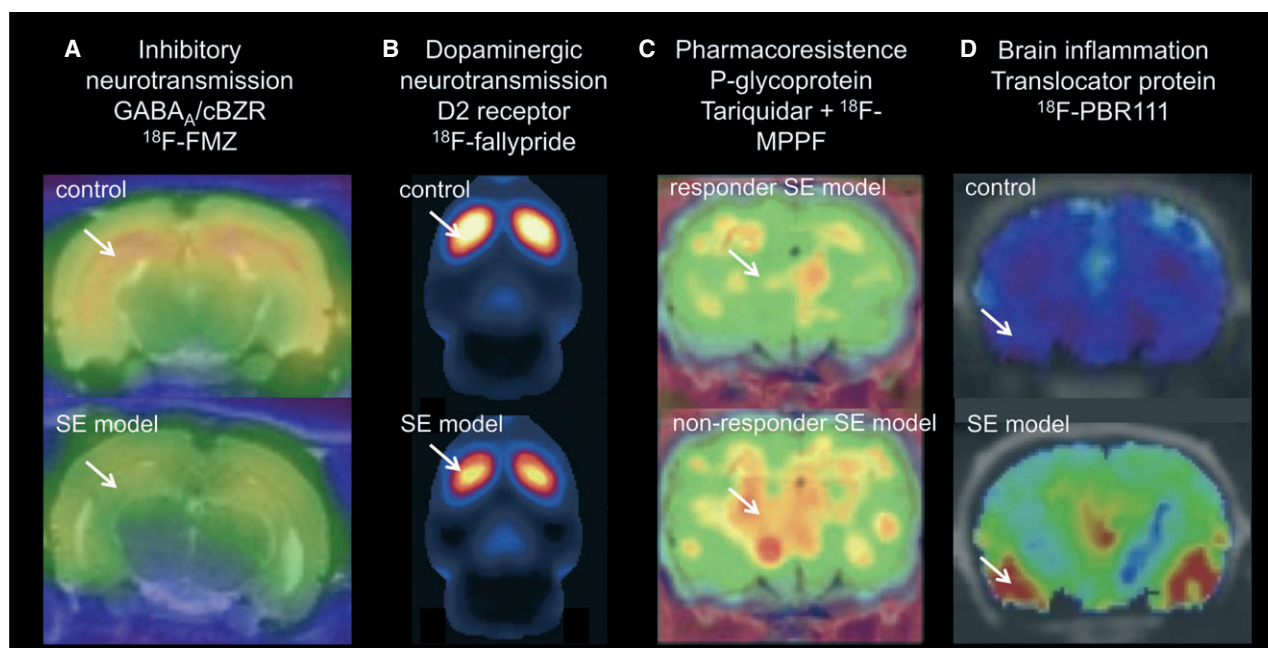
*Epilepsia* © ILAE

methods were developed following validation with invasive protocols employing arterial blood sampling.<sup>20</sup> GABA<sub>A</sub>/CBZDR density ( $B_{max}$ ) and affinity (Kd) were non-invasively measured using the partial saturation method according to Delforge et al.<sup>21</sup> This showed that decreases in GABA<sub>A</sub>/CBZDR density in vivo occurred independent of morphologic brain deformations on MRI or histology 6 weeks after SE (Fig. 2A).<sup>20</sup>

In another application of receptor/ligand imaging, decreased availability of D<sub>2/3</sub> dopamine receptors was recently demonstrated with <sup>18</sup>F-fallypride PET in a post-SE model (Fig. 2B).<sup>22</sup> This study is setting the scene for longitudinal and drug interaction preclinical studies related to dopaminergic neurotransmission.

Pharmacoresistance to antiseizure drugs (ASDs) is a major issue in refractory epilepsy patients. P-glycoprotein (P-gp) has been proposed as an efflux transporter at the blood brain barrier (BBB) that mediates drug resistance. Small animal PET studies in post-SE models have investigated the contribution of P-gp toward this phenomenon

(Fig. 2C). In these studies, several PET tracers that are P-gp substrates or inhibitors (4-<sup>18</sup>F-fluoro-N-{2-[4-(2-methylphenyl)-piperazine-1-yl]-ethyl}-N-pyridin-2-yl-benzamide [18FMPPF], 11C-verapamil, 11C-quinidine, and 11C-laniquidar) were tested.<sup>24–27</sup> Administration of tariquidar, (a P-gp inhibitor) before scanning, enhanced discrimination of group differences in kinetic influx/efflux rate constants ( $k_1$  and  $k_2$ ) of 11C-quinidine and 11C-verapamil between control and epilepsy groups indicating that P-gp activity is altered in epilepsy models.<sup>25,27</sup> In addition, pretreatment with tariquidar allowed differentiation between responders and nonresponders in a model of pharmacoresistent epilepsy with [11C]quinidine and 18FMPPF (Fig. 2C).<sup>25,26</sup> A small difference in baseline unidirectional blood–brain clearance ( $k_1$ ) between control, seizure-free, and patients with pharmacoresistent epilepsy has recently been demonstrated with PET imaging.<sup>23</sup> Whereas in animal studies tariquidar treatment generally augmented the increase in tracer kinetics in pharmacoresistant individuals, this increase was on the contrary attenuated in pharmacoresistant patients. More studies



**Figure 2.**

Application of new PET tracers in epilepsy models. **(A)** Decrease in  $^{18}\text{F}$ -FMZ PET binding in epileptic rats (kainic acid–induced SE model) compared to control rats. Coronal PET/MRI images are shown at the level of the ventral hippocampus. **(B)** Decrease in  $^{18}\text{F}$ -fallypride binding in epileptic animals (pilocarpine-induced SE model) indicative of reduced dopamine  $\text{D}_{2/3}$  receptor availability. Sagittal PET image through the rat striatum. **(C)** Increased  $k_1$  of P-gp substrate  $^{18}\text{F}$ -MPPF in nonresponders to phenobarbital (model for drug resistance) after tariquidar (P-gp inhibitor) treatment compared to responder epileptic rats (electrical-induced SE). Mean parametric map of unidirectional blood–brain clearance ( $k_1$ ) superimposed on a coronal rat brain histological atlas at the level of the dorsal hippocampus. **(D)** Increased  $^{18}\text{F}$ -PBR111 binding 7 days post kainic acid–induced SE. Coronal PET/computed tomography (CT) images of control and SE model. Arrows indicate altered tracer uptake. SE, status epilepticus. Images reproduced with permission.<sup>22,25,26</sup> *Epilepsia* © ILAE

will be needed to corroborate the benefit of these P-gp PET ligands in predicting drug resistance in patients.

Brain inflammation has emerged as an important player in epileptogenesis.<sup>28,29</sup> Dedeurwaerdere et al.<sup>30</sup> have performed studies with autoradiography and PET imaging to define a spatiotemporal pattern of brain inflammation in the post-SE model. For the *in vivo* measurements,  $^{18}\text{F}$ -PBR111 was used; this is a second generation and highly specific PET ligand for the translocator protein (TSPO, formerly known as the peripheral benzodiazepine receptor). Because a definite brain region without TSPO changes (reference region) has not been identified so far, a simplified method was proposed based on the ratio of brain to plasma radioligand activity. Brain inflammatory changes were found with autoradiography and PET in the latent period (1 week post-SE) of epileptogenesis (Fig. 2D). Increased TSPO binding was found in hippocampal, but also extrahippocampal limbic brain regions and olfactory bulb,<sup>30</sup> which although attenuated was persistent up to the chronic phase (6–12 weeks post-SE) (S. Dedeurwaerdere, unpublished data).

These examples underscore the potential of small animal PET for investigating key mechanisms related to brain activation, neurotransmitter systems, drug resistance, and brain

inflammation in both epileptogenesis and established epilepsy. Although the development of new PET ligands is not a final answer, it is anticipated that the number of radioligands for brain targets will continue to increase in the future. Therefore, it is to be expected that small animal PET imaging in epilepsy research will continue to expand in the future. The current and future studies will provide the tools and biomarkers to advance molecular imaging in preclinical epilepsy research toward studying the evolution of these changes over time, investigating the interdependence of these imaging changes with multimodal imaging, and evaluating the effect of disease-modifying interventions on the imaging biomarkers in the same animals.

## DIFFUSION-WEIGHTED IMAGING (DWI) AND TRACTOGRAPHY IN RODENT EPILEPSY MODELS

MRI represents a noninvasive medical and research tool with the ability to identify early pathophysiologic changes involved in epileptogenesis, monitor disease progression, and assess the effectiveness of possible therapies. In particular, advances in DWI-based methods, such as tractography,

may provide sensitive *in vivo* measures of the subtle changes in brain connectivity involved in the epileptogenic process.<sup>31–33</sup>

DWI quantifies the diffusivity of water molecules in brain tissue.<sup>31,32</sup> Because water diffusivity in axons is directionally limited (anisotropic) relative to gray matter, DWI-based approaches are particularly sensitive to changes in white matter.<sup>31</sup> The most common and basic DWI measures include the magnitude of water diffusion in a given direction (apparent diffusion coefficient; ADC), the anisotropy of water diffusion (fractional anisotropy; FA), and the mean diffusivity (MD) of water molecules across a number of directions.<sup>31</sup> Previous studies in rodent models of epilepsy have applied these DWI measures in an attempt to provide insight into epileptogenesis with mixed and sometimes contradicting results. For example, in SE models of TLE, both decreases and increases in ADC have been reported during acute stages post-SE.<sup>34–37</sup> ADC then returns to baseline by 1 week post-SE, with a consequent increase in ADC at more chronic time-points.<sup>36</sup> These ADC abnormalities have been associated with a number of pathophysiologic processes that may be important in epilepsy including edema, metabolic abnormalities, axonal injury, and neuronal loss.<sup>34–36</sup> In addition, acute and chronic changes in ADC have been reported in the hippocampus after rats were given LFP and have been associated with mossy fiber sprouting, EEG abnormalities, and increased seizure susceptibility after a chemoconvulsant challenge.<sup>38,39</sup> Notably, changes in FA have also been reported in rodent models of epilepsy and may have relevance to epileptogenesis.<sup>40,41</sup> However, although these basic DWI measures are capable of detecting changes after brain insult, they may not be sensitive to the more subtle changes in brain connectivity that are thought to occur in epileptogenesis.<sup>32</sup>

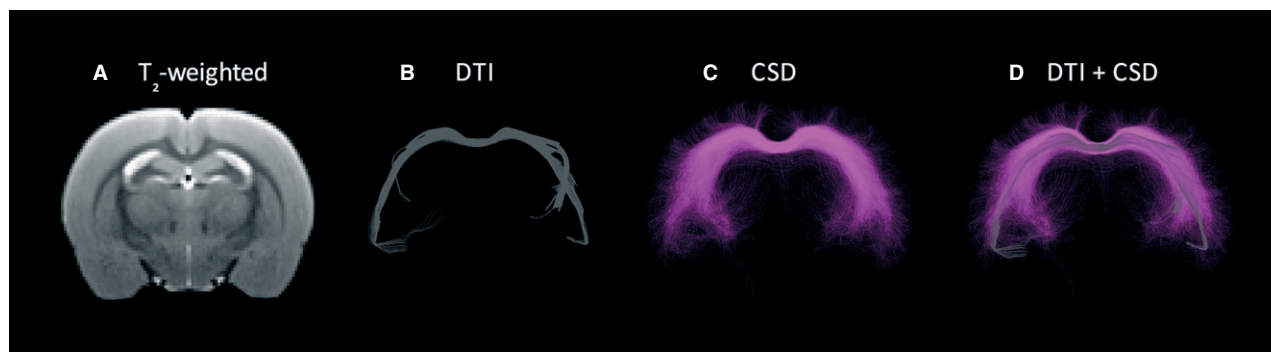
Tractography is an advanced DWI-based imaging method that allows for the detailed 3D reconstruction of brain white matter tracts, and thus holds great promise as a research tool to assess interstructural and intrastructural connectivity changes in epileptogenesis.<sup>32,42</sup> Indeed, an initial study applying tractography in rat models of genetic spike-wave epilepsy, reports changes in corpus callosum and somatosensory cortex connectivity that may be related to the onset of spike-wave discharges.<sup>43</sup> Tractography requires the acquisition of DWI data, the estimation of fiber orientations within each imaging voxel, and the application of a tracking algorithm based on the fiber orientations.<sup>31,42</sup> To date, the large majority of tractography studies utilize the diffusion tensor imaging (DTI) tractography model, including the above-mentioned animal genetic epilepsy study, despite its well-documented limitations.<sup>42</sup> Namely, DTI can determine only a single fiber orientation for each imaging voxel.<sup>42</sup> Given that up to 90% of white matter voxels may contain fibers in different orientations,<sup>42,44</sup> DTI greatly underestimates the degree of connectivity within the brain and often fails to accurately identify major white mat-

ter tracts.<sup>42</sup> This was recently demonstrated by Farquharson et al., where DTI-based tractography methods failed to reconstruct corticospinal pathways.<sup>42</sup> However, constrained spherical deconvolution (CSD)-based tractography, a higher-order tractography model able to estimate numerous fiber orientations for each imaging voxel, was found to be superior to DTI methods, and consistently reconstructed the corticospinal tract as biologically expected.<sup>42</sup> Taken together, although tractography represents a promising research tool in epilepsy, the limitations with DTI must be considered in the design and interpretation of experiments, and future studies are still required to rigorously assess the use of tractography methods as epileptogenic biomarkers.

In light of these needs, Shultz et al.<sup>13,45</sup> have recently utilized serial CSD-based tractography, in conjunction with more conventional neuroimaging techniques, behavioral testing, and video-EEG analysis, to investigate epileptogenesis in rat models of acquired epilepsy. Consistent with the clinical findings comparing CSD and DTI tractography, CSD-based tractography provides more biologically relevant tracts than DTI (see Fig. 3) in the rat brain. Furthermore, in the LFP rat model of posttraumatic epilepsy and the post-SE model of TLE, CSD-based tractography identified clear changes associated with the later development of epilepsy and neurobehavioral deficits. These preliminary results demonstrate the ability of CSD-based tractography to detect alterations in rat models of acquired epilepsy, and support the use of CSD-based tractography in future studies. However, it is important to emphasize that even higher-order tractography methods remain limited (e.g., spatial resolution), require further validation, and must be interpreted with caution.<sup>46</sup>

## FUNCTIONAL MRI (fMRI)

Based on the principle that neural activity leads to increased blood flow and changes in blood oxygenation levels—otherwise known as the blood oxygenation level-dependent (BOLD) signal—fMRI in animal studies allows for the investigation of the location and networks of brain function.<sup>47,48</sup> Because epilepsy involves abnormalities in neural activity and circuitry, EEG-fMRI has been a particularly informative tool in both basic and clinical epilepsy research.<sup>48</sup> Of note, there are several challenges associated with acquiring simultaneous EEG during fMRI image acquisition in animal epilepsy models. These include eliminating MR-induced artifact in EEG recordings, difficulties inducing seizures in anesthetized animals, and choosing the anesthetic that least alters systemic and cerebral physiology.<sup>49</sup> Animal studies offer several advantages over human EEG-fMRI studies. For example, ictal studies are not limited by movement artifact, since they can be performed on anesthetized and paralyzed animals. There is greater control over the specific seizure type and onset. In addition, it is possible to obtain microelectrode recordings simultaneously with



**Figure 3.**

Example of diffusion tensor imaging (DTI)–based versus constrained spherical deconvolution (CSD)–based tractography in the rat corpus callosum.<sup>43</sup> (A) T<sub>2</sub>-weighted MRI demonstrating contrast between gray and white matter structures that can be observed using a more standard volumetric MRI sequence. DTI (B) is the most commonly used tractography method, despite well-documented limitations that result in the underestimation of tracts.<sup>40</sup> Advances in higher-order tractography models, such as CSD (C), provide more sensitive and accurate representations of white matter connectivity (D), and might be applied in future studies investigating brain connectivity in epileptogenesis.

*Epilepsia* © ILAE

fMRI to better understand the mechanisms associated with seizure-induced BOLD responses. Lastly, it is possible to perform more invasive physiologic studies and obtain tissue-whole brain samples to better interrogate underlying physiologic, molecular, and genetic mechanisms.

The use of fMRI in animal models has provided insight into the local and network properties underlying seizure generation. In addition, they have improved our understanding of local and distant effects of interictal and ictal discharges, leading to a better understanding of interictal cognitive impairment associated with epilepsy.

### Generalized epilepsy and generalized seizures

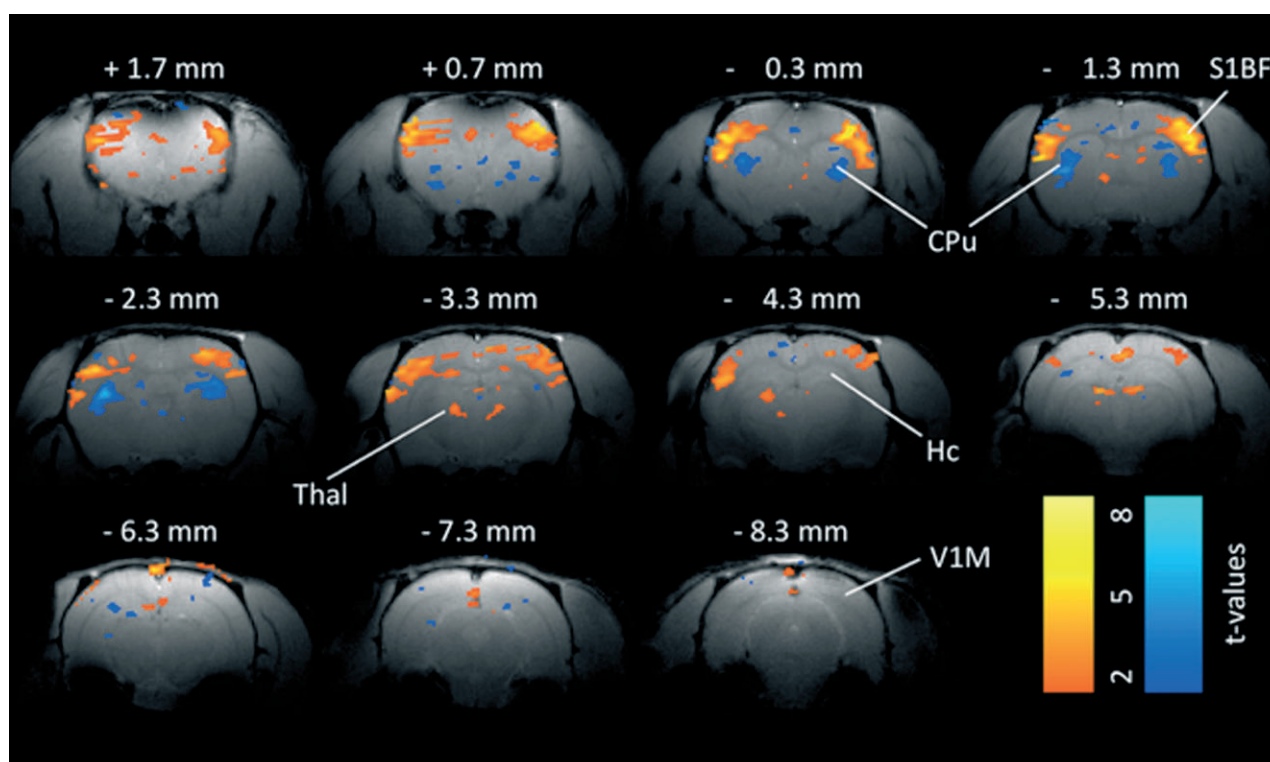
Most animal EEG-fMRI studies of generalized spike-wave seizures have relied on the Wistar Albino Glaxo rat of Rijswijk (WAG/Rij), a model of absence seizures. Spike-wave seizures in this model are associated with BOLD signal increases in bilateral regions in the cerebral cortex and thalamus.<sup>50,51</sup> Notably, anterior cortical areas show the greatest BOLD signal increases; these are also the regions showing the greatest activity of electrophysiologic recordings of spike-wave seizures.<sup>52,53</sup> A more recent study focused on subcortical BOLD signal changes in this model (Fig. 4).<sup>54</sup> In addition to EEG-fMRI, laser Doppler cerebral blood flow, local field potential, and multiunit activity recordings were obtained to better understand the basis of the observed BOLD signal changes. Prominent BOLD signal increases were seen in somatosensory barrel cortex and the thalamus, whereas BOLD signal decreases were seen in basal ganglia, a pattern similar to that seen with human generalized seizures.<sup>55–57</sup> Notably, the observed cortical and thalamic BOLD signal increases were associated with the expected increases in electrophysiologic activity and cerebral blood flow.<sup>54</sup> On the other hand, the basal ganglia BOLD signal decreases were associated with cerebral blood

flow decreases, despite increases in neuronal electrical activity (Fig. 4). This suggests that the BOLD signal reflects electrophysiologic activity in the cerebral cortex and thalamus, whereas this may not be the case in the basal ganglia. Thus caution is warranted when interpreting BOLD signals in the basal ganglia.

Studies of generalized tonic-clonic seizures have primarily used rats and agents such as kainic acid, pentylentetrazole, and bicuculline (reviewed by Blumenfeld<sup>48</sup>). These studies also showed seizure-associated widespread cortical increases, maximal in the somatosensory cortex, as well as in the thalamus and other subcortical structures.<sup>58–60</sup> These findings confirm that “generalized” seizures do not affect the entire brain similarly. Following seizures, widespread BOLD signal decreases were observed.<sup>59</sup> Of interest, one study showed that preictal BOLD signal increases in the somatosensory cortex (S1, S2) and thalamus occur several seconds before seizure onset.<sup>59</sup> This supports the existence of a preictal state that precedes seizure onset, which may serve as a target for future therapeutic intervention in an effort to abort seizures.

### Focal epilepsy

Compared to generalized epilepsies and secondarily generalized seizures, few studies of focal seizures have been performed. Early studies of focal seizures relied on the local application of penicillin to cerebral cortex to produce focal seizures in pigs<sup>61</sup> or rats<sup>62</sup> and associated BOLD signal increases in the same region. In a porcine study of focal interictal discharges, localized BOLD signals were also seen in the location of the discharge; however, they preceded the electrical activity.<sup>63</sup> A study of spontaneous hippocampal seizures produced by intraperitoneal injection of kainic acid showed that robust BOLD signal increases bilaterally in the hippocampus.<sup>64</sup> Notably, a small number of electrographic



**Figure 4.**

Example of BOLD fMRI changes 2–4 s after spike-wave discharge onset in a WAG/Rij rat. Somatosensory cortex and thalamus (Thal) show prominent increases in BOLD signal during the spike-wave discharges. Prominent BOLD decreases are present in the caudate-putamen (CPu). Smaller changes are seen in other areas. Simultaneous EEG acquired during fMRI was used to identify images obtained 2–4 s after SWD onset for comparison with baseline images obtained immediately before start of SWDs. Color bars indicate t values for increases (warm colors) and decreases (cold colors). Threshold value  $t > 2$ . CPu, caudate-putamen; Hc, hippocampus; S1BF, somatosensory barrel cortex; Thal, thalamus; VI, primary visual cortex. Modified from Mishra et al.<sup>51</sup> with permission.

*Epilepsia* © ILAE

seizures did not produce a measurable BOLD response, suggesting that neuronal activity and the BOLD responses may become decoupled at times in this animal model.

Another animal study of focal seizures induced by hippocampal stimulation showed increased BOLD signal in the hippocampus, thalamus, and septum, but decreases in orbitofrontal, cingulate, and retrosplenial cortex during partial seizures.<sup>65</sup> The BOLD signal decreases were associated with cortical slow waves, which were interpreted to reflect a depressed cortical state resembling sleep or coma, thus providing a possible measure of altered awareness during mesial temporal seizures. In the same study, secondarily generalized, convulsive seizures were associated with neocortical fast polyspike activity as well as BOLD signal increases in the regions that showed decreases during mesial temporal seizures, highlighting a different mechanism for altered consciousness during generalized seizures.<sup>65</sup>

### Functional connectivity

Few animal studies have examined resting state functional connectivity in animal models of epilepsy. The first

was performed using genetic absence epilepsy rats from Strasbourg (GAERS), a model of absence seizures.<sup>66</sup> Simultaneous intracranial EEG-fMRI showed discharges originating from primary somatosensory cortex associated with strong BOLD activation in this area. Several functional connectivity measures derived from fMRI data (Granger causality and Dynamic Causal Modeling) failed to show any functional connectivity. It was argued that local hemodynamics vary between cerebral regions in this model, thus making it difficult to find temporal correlations in the fMRI data.

A recent study examined resting state functional connectivity in WAG/Rij rats, a model of absence seizures.<sup>67</sup> In this study, cortical regions showing BOLD signal increases associated with spike-wave discharges were used as seeds for subsequent connectivity analysis. Striking differences between WAG/Rij and nonepileptic control rats (Wistar) were observed, with the strongest connectivity observed in the bilateral somatosensory and adjacent cortices, which was where the spike-associated BOLD signal changes were maximal. These data confirm that long-term changes in epileptic networks are present in this animal model in between



seizures. Such alterations could possibly underlie interictal behavioral and cognitive abnormalities seen in persons with epilepsy.

One study of focal seizures examined resting state functional connectivity following seizures produced by tetanus toxin injection into right primary motor cortex of rats.<sup>68</sup> These animals displayed spontaneous facial motor seizures that persisted for many weeks. Resting state connectivity maps of the right and left sensorimotor cortices were obtained 7, 21, 49, and 70 days following toxin injection. In the epileptic brain, increased interhemispheric functional connectivity of both sensorimotor cortices was seen at day 7, extending into the adjacent secondary somatosensory and medial cingulate cortices as well as other areas. These changes returned to control levels by day 70. In addition, decreased interhemispheric functional connectivity of both sensorimotor cortices was seen, starting at day 21 and recovering later.<sup>68</sup>

## CONCLUSIONS

Epilepsy is an abnormal emergent property of disturbances in neuronal networks, which, even for epilepsies characterized by focal seizures, involve widely distributed systems, often in both hemispheres. Systemic functional neuroimaging now provides opportunities to examine neuronal disturbances in the whole brain that underlie various types of epileptogenesis and epileptic seizure generation.

Although FDG brain uptake is a fairly generic physiologic measurement, recent studies suggest that some characteristic patterns could serve as a biomarker of epileptogenesis. Drug occupancy PET imaging could provide biomarkers for novel drug targets and facilitate clinical trials. Novel PET tracers could provide insights into molecular mechanisms. DWI methods allow for the *in vivo* study of brain connectivity. More basic DWI measures have already been utilized to detect changes in animal models of epilepsy, but tractography in particular holds great promise as a future research tool to assess abnormal interstructural and intrastructural connections in epileptogenesis. Functional MRI studies in animals offer the advantage of performing more invasive studies to better understand network, cellular, molecular, and genetic mechanisms underlying the generation of seizures, as well as the remote effects of seizures on the brain. EEG-fMRI studies in animal models of epilepsy have already provided fundamental insights into the mechanisms underlying the generation of seizures that, to date, have not been possible in human studies.

In our quest to find true disease-modifying therapies, we need noninvasive biomarkers that represent underlying neurobiologic mechanisms. This will require translational animal/human validation at several levels: Does the imaging biomarker reflect a pathologic process, a protective compensatory mechanism, or an epiphenomenon? How does the imaging biomarker correlate with the temporal process of

epileptogenesis? How does the imaging biomarker change following therapy?

The studies described earlier are but a few examples of work that is now underway that will permit extensive animal/human parallel investigations, using patients to identify specific abnormalities of human epilepsy, subsequent studies in animal models to identify fundamental neuronal mechanisms that are not easily examined in a clinical setting, followed by selective studies with patients to validate results of animal research. Given the tremendous advances in understanding the contribution of specific properties of widely distributed neuronal networks to both normal and abnormal human behavior being elucidated by the new field of connectomics, the potential for future research on epilepsy is enormous.

## ACKNOWLEDGMENTS

Dr. Dedeurwaerdere received support from Fonds voor Wetenschappelijk Onderzoek (FWO) (1514412N), European Research Area Network Neuron Epilepsy-traumatic brain injury (G.A009.13N), and Bijzonder Onderzoeksfonds (BOF) Universiteit Antwerpen. Dr. Engel received support from National Institutes of Health (NIH) grants P01 NS02808, R01 NS33310, U01 NS42372, and P20 NS 80181; The Epilepsy Therapy Project; Citizens United for Research in Epilepsy; the Epilepsy Foundation; and the Resnick Foundation. Dr. Shultz received funding from the Australian National Health and Medical Research Council and the Canadian Institutes of Health Research. Dr. Federico received funding from the Canadian Institutes of Health Research and Epilepsy Canada.

## DISCLOSURE

None of the authors has any conflict of interest to disclose. We confirm that we have read the Journal's position on issues involved in ethical publication and affirm that this report is consistent with those guidelines.

## REFERENCES

1. Virdee K, Cumming P, Caprioli D, et al. Applications of positron emission tomography in animal models of neurological and neuropsychiatric disorders. *Neurosci Biobehav Rev* 2012;36:1188–1216.
2. Dedeurwaerdere S, Jupp B, O'Brien TJ. Positron emission tomography in basic epilepsy research: a view of the epileptic brain. *Epilepsia* 2007;48(Suppl. 4):56–64.
3. Goffin K, Dedeurwaerdere S, Van Laere K, et al. Neuronuclear assessment of patients with epilepsy. *Semin Nucl Med* 2008;38:227–239.
4. O'Brien TJ, Jupp B. In-vivo imaging with small animal FDG-PET: a tool to unlock the secrets of epileptogenesis? *Exp Neurol* 2009;220:1–4.
5. Kornblum HI, Araujo DM, Annala AJ, et al. In vivo imaging of neuronal activation and plasticity in the rat brain by high resolution positron emission tomography (microPET). *Nat Biotechnol* 2000;18:655–660.
6. Mirrione MM, Schiffer WK, Siddiq M, et al. PET imaging of glucose metabolism in a mouse model of temporal lobe epilepsy. *Synapse* 2006;59:119–121.
7. Mirrione MM, Schiffer WK, Fowler JS, et al. A novel approach for imaging brain-behavior relationships in mice reveals unexpected metabolic patterns during seizures in the absence of tissue plasminogen activator. *Neuroimage* 2007;38:34–42.
8. Wang D, Pascual JM, Yang H, et al. A mouse model for Glut-1 haploinsufficiency. *Hum Mol Genet* 2006;15:1169–1179.

9. Goffin K, Van Paesschen W, Dupont P, et al. Longitudinal microPET imaging of brain glucose metabolism in rat lithium-pilocarpine model of epilepsy. *Exp Neurol* 2009;217:205–209.
10. Guo Y, Gao F, Wang S, et al. In vivo mapping of temporospatial changes in glucose utilization in rat brain during epileptogenesis: an 18F-fluorodeoxyglucose-small animal positron emission tomography study. *Neuroscience* 2009;162:972–979.
11. Lee EM, Park GY, Im KC, et al. Changes in glucose metabolism and metabolites during the epileptogenic process in the lithium-pilocarpine model of epilepsy. *Epilepsia* 2012;53:860–869.
12. Jupp B, Williams J, Binns D, et al. Hypometabolism precedes limbic atrophy and spontaneous recurrent seizures in a rat model of TLE. *Epilepsia* 2012;53:1233–1244.
13. Shultz SR, Cardamone L, Liu YR, et al. Can structural or functional changes following traumatic brain injury in the rat predict epileptic outcome? *Epilepsia* 2013;54:1240–1250.
14. Vivash L, Gregoire MC, Lau EW, et al. 18F-flumazenil: a gamma-aminobutyric acid A-specific PET radiotracer for the localization of drug-resistant temporal lobe epilepsy. *J Nucl Med* 2013;54:1270–1277.
15. Van Paesschen W. Qualitative and quantitative imaging of the hippocampus in mesial temporal lobe epilepsy with hippocampal sclerosis. *Neuroimaging Clin N Am* 2004;14:373–400, vii.
16. Liefwaard LC, Ploeger BA, Molthoff CF, et al. Changes in GABAA receptor properties in amygdala kindled animals: in vivo studies using [11C]flumazenil and positron emission tomography. *Epilepsia* 2009;50:88–98.
17. Syvanen S, Labots M, Tagawa Y, et al. Altered GABAA receptor density and unaltered blood–brain barrier transport in a kainate model of epilepsy: an in vivo study using 11C-flumazenil and PET. *J Nucl Med* 2012;53:1974–1983.
18. Vivash L, Tostevin A, Liu DS, et al. Changes in hippocampal GABAA/cBZR density during limbic epileptogenesis: relationship to cell loss and mossy fibre sprouting. *Neurobiol Dis* 2011;41:227–236.
19. Dedeurwaerdere S, Gregoire MC, Vivash L, et al. In-vivo imaging characteristics of two fluorinated flumazenil radiotracers in the rat. *Eur J Nucl Med Mol Imaging* 2009;36:958–965.
20. Vivash L, Gregoire MC, Bouillere V, et al. In vivo measurement of hippocampal GABAA/cBZR density with [(18)F]-flumazenil PET for the study of disease progression in an animal model of temporal lobe epilepsy. *PLoS ONE* 2014;9:e86722.
21. Delforge J, Pappata S, Millet P, et al. Quantification of benzodiazepine receptors in human brain using PET, [11C]flumazenil, and a single-experiment protocol. *J Cereb Blood Flow Metab* 1995;15:284–300.
22. Yakushev IY, Dupont E, Buchholz HG, et al. In vivo imaging of dopamine receptors in a model of temporal lobe epilepsy. *Epilepsia* 2010;51:415–422.
23. Feldman M, Asselin MC, Liu J, et al. P-glycoprotein expression and function in patients with temporal lobe epilepsy: a case–control study. *Lancet Neurol* 2013;12:777–785.
24. Syvanen S, Luurtsema G, Molthoff CF, et al. (R)-[11C]verapamil PET studies to assess changes in P-glycoprotein expression and functionality in rat blood-brain barrier after exposure to kainate-induced status epilepticus. *BMC Med Imaging* 2011;11:1.
25. Syvanen S, Russmann V, Verbeek J, et al. [(11)C]quinidine and [(11)C]laniquidar PET imaging in a chronic rodent epilepsy model: impact of epilepsy and drug-responsiveness. *Nucl Med Biol* 2013;40:764–775.
26. Bartmann H, Fuest C, la Fougere C, et al. Imaging of P-glycoprotein-mediated pharmacoresistance in the hippocampus: proof-of-concept in a chronic rat model of temporal lobe epilepsy. *Epilepsia* 2010;51:1780–1790.
27. Bankstahl JP, Bankstahl M, Kuntner C, et al. A novel positron emission tomography imaging protocol identifies seizure-induced regional overactivity of P-glycoprotein at the blood-brain barrier. *J Neurosci* 2011;31:8803–8811.
28. Dedeurwaerdere S, Friedmann A, Fabene PF, et al. Finding a better drug for epilepsy: antiinflammatory targets. *Epilepsia* 2012;53:1113–1118.
29. Vezzani A, French J, Bartfai T, et al. The role of inflammation in epilepsy. *Nat Rev Neurol* 2011;7:31–40.
30. Dedeurwaerdere S, Callaghan PD, Pham T, et al. PET imaging of brain inflammation during early epileptogenesis in a rat model of temporal lobe epilepsy. *EJNMMI Res* 2012;2:60.
31. Jones DK. Studying connections in the living human brain with diffusion MRI. *Cortex* 2008;44:936–952.
32. Engel J Jr, Thompson PM, Stern JM, et al. Connectomics and epilepsy. *Curr Opin Neurol* 2013;26:186–194.
33. Bernhardt BC, Hong S, Bernasconi A, et al. Imaging structural and functional brain networks in temporal lobe epilepsy. *Front Hum Neurosci* 2013;7:624.
34. Engelhorn T, Hufnagel A, Weise J, et al. Monitoring of acute generalized status epilepticus using multilocal diffusion MR imaging: early prediction of regional neuronal damage. *AJNR Am J Neuroradiol* 2008;28:321–327.
35. van Eijsden P, Notenboom RG, Wu O, et al. In vivo 1H magnetic resonance spectroscopy, T2-weighted and diffusion-weighted MRI during lithium-pilocarpine-induced status epilepticus in the rat. *Brain Res* 2004;1030:11–18.
36. Wall CJ, Kendall EJ, Obenaus A. Rapid alterations in diffusion-weighted images with anatomic correlates in a rodent model of status epilepticus. *AJNR Am J Neuroradiol* 2000;21:1841–1852.
37. Zhong J, Petroff OAC, Prichard JW, et al. Changes in water diffusion and relaxation properties of rat cerebrum during status epilepticus. *Magn Reson Med* 1993;30:241–246.
38. Kharatishvili I, Immonen R, Grohn O, et al. Quantitative diffusion MRI of hippocampus as a surrogate marker for post-traumatic epileptogenesis. *Brain* 2007;130:3155–3168.
39. Frey L, Lepkin A, Schickedanz A, et al. ADC mapping and T1-weighted signal changes on post-injury MRI predict seizure susceptibility after experimental traumatic brain injury. *Neurol Res* 2014;36:26–37.
40. Parekh MB, Carney PR, Sepulveda H, et al. Early MR diffusion and relaxation changes in the parahippocampal gyrus precede the onset of spontaneous seizures in an animal model of chronic limbic epilepsy. *Exp Neurol* 2010;224:258–270.
41. Sierra A, Laitinen T, Lehtimäki K, et al. Diffusion tensor MRI with tract-based spatial statistics and histology reveals undiscovered lesioned areas in kainate model of epilepsy in rat. *Brain Struct Funct* 2011;216:123–135.
42. Farquharson S, Tournier JD, Calamante F, et al. White matter fiber tractography: why we need to move beyond DTI. *J Neurosurg* 2013;118:1367–1377.
43. Chahboune H, Mishra AM, DeSalvo MN, et al. DTI abnormalities in anterior corpus callosum of rats with spike-wave epilepsy. *Neuroimage* 2009;47:459–466.
44. Jeurissen B, Leemans A, Tournier JD, et al. Investigating the prevalence of complex fiber configurations in white matter tissue with diffusion magnetic resonance imaging. *Hum Brain Mapp* 2013;34:2747–2766.
45. Shultz SR, Zheng P, Wright DK, et al. Tractography and magnetic resonance spectroscopy in acquired epilepsy models. WONOEP XII meeting planner 2013, QC, Canada.
46. Jones DK, Knösche TR, Turner R. White matter integrity, fiber count, and other fallacies: the do's and don't's of diffusion MRI. *Neuroimage* 2013;73:239–254.
47. Ogawa S, Lee TM, Nayak AS, et al. Oxygenation-sensitive contrast in magnetic resonance image of rodent brain at high magnetic fields. *Magn Reson Med* 1990;14:68–78.
48. Blumenfeld H. Functional MRI studies of animal models in epilepsy. *Epilepsia* 2007;48(Suppl. 4):18–26.
49. Mirsattari SM, Ives JR, Leung LS, et al. EEG monitoring during functional MRI in animal models. *Epilepsia* 2007;48(Suppl. 4):37–46.
50. Nersesyan H, Hyder F, Rothman DL, et al. Dynamic fMRI and EEG recordings during spike-wave seizures and generalized tonic-clonic seizures in WAG/Rij rats. *J Cereb Blood Flow Metab* 2004;24:589–599.
51. Tenney JR, Duong TQ, King JA, et al. FMRI of brain activation in a genetic rat model of absence seizures. *Epilepsia* 2004;45:576–582.
52. Meeren HK, Pijn JP, Van Luijtelaar EL, et al. Cortical focus drives widespread corticothalamic networks during spontaneous absence seizures in rats. *J Neurosci* 2002;22:1480–1495.
53. Nersesyan H, Herman P, Erdogan E, et al. Relative changes in cerebral blood flow and neuronal activity in local microdomains during generalized seizures. *J Cereb Blood Flow Metab* 2004;24:1057–1068.
54. Mishra AM, Ellens DJ, Schridde U, et al. Where fMRI and electrophysiology agree to disagree: corticothalamic and striatal

- activity patterns in the WAG/Rij rat. *J Neurosci* 2011;31:15053–15064.
55. Aghakhani Y, Bagshaw AP, Benar CG, et al. fMRI activation during spike and wave discharges in idiopathic generalized epilepsy. *Brain* 2004;127:1127–1144.
  56. Archer JS, Abbott DF, Waites AB, et al. fMRI “deactivation” of the posterior cingulate during generalized spike and wave. *Neuroimage* 2003;20:1915–1922.
  57. Gotman J, Grova C, Bagshaw A, et al. Generalized epileptic discharges show thalamocortical activation and suspension of the default state of the brain. *Proc Natl Acad Sci USA* 2005;102:15236–15240.
  58. Brevard ME, Kulkarni P, King JA, et al. Imaging the neural substrates involved in the genesis of pentylentetrazol-induced seizures. *Epilepsia* 2006;47:745–754.
  59. DeSalvo MN, Schridde U, Mishra AM, et al. Focal BOLD fMRI changes in bicuculline-induced tonic-clonic seizures in the rat. *Neuroimage* 2010;50:902–909.
  60. Schridde U, Khubchandani M, Motelow JE, et al. Negative BOLD with large increases in neuronal activity. *Cereb Cortex* 2008;18:1814–1827.
  61. Opdam HI, Federico P, Jackson GD, et al. A sheep model for the study of focal epilepsy with concurrent intracranial EEG and functional MRI. *Epilepsia* 2002;43:779–787.
  62. Mirsattari SM, Wang Z, Ives JR, et al. Linear aspects of transformation from interictal epileptic discharges to BOLD fMRI signals in an animal model of occipital epilepsy. *Neuroimage* 2006;30:1133–1148.
  63. Makiranta M, Ruohonen J, Suominen K, et al. BOLD signal increase precedes EEG spike activity—a dynamic penicillin induced focal epilepsy in deep anesthesia. *Neuroimage* 2005;27:715–724.
  64. Airaksinen AM, Hekmatyar SK, Jerome N, et al. Simultaneous BOLD fMRI and local field potential measurements during kainic acid-induced seizures. *Epilepsia* 2012;53:1245–1253.
  65. Englot DJ, Mishra AM, Mansuripur PK, et al. Remote effects of focal hippocampal seizures on the rat neocortex. *J Neurosci* 2008;28:9066–9081.
  66. David O, Guillemain I, Saillet S, et al. Identifying neural drivers with functional MRI: an electrophysiological validation. *PLoS Biol* 2008;6:2683–2697.
  67. Mishra AM, Bai X, Motelow JE, et al. Increased resting functional connectivity in spike-wave epilepsy in WAG/Rij rats. *Epilepsia* 2013;54:1214–1222.
  68. Otte WM, Dijkhuizen RM, van Meer MP, et al. Characterization of functional and structural integrity in experimental focal epilepsy: reduced network efficiency coincides with white matter changes. *PLoS ONE* 2012;7:e39078.