

UCSF

UC San Francisco Previously Published Works

Title

Direct-to-Patient Mobile Teledermoscopy: Prospective Observational Study.

Permalink

<https://escholarship.org/uc/item/2xp66765>

Authors

Fan, Winnie

Mattson, Gunnar

Twigg, Amanda

Publication Date

2024-02-12

DOI

10.2196/52400

Peer reviewed

Research Letter

Direct-to-Patient Mobile Teledermoscopy: Prospective Observational Study

Winnie Fan^{1*}, BS; Gunnar Mattson^{1*}, BS, MPH; Amanda Twigg^{1,2}, MD

¹Department of Dermatology, School of Medicine, University of California San Francisco, San Francisco, CA, United States

²Department of Dermatology, San Francisco Veterans Affairs Health Care System, San Francisco, CA, United States

*these authors contributed equally

Corresponding Author:

Amanda Twigg, MD

Department of Dermatology

School of Medicine

University of California San Francisco

1701 Divisadero St

3rd Floor

San Francisco, CA, 94115

United States

Phone: 1 415 353 7800

Email: amanda.twigg@ucsf.edu

Abstract

Direct-to-patient mobile teledermoscopy is a feasible and useful adjunct to smartphone imaging for monitoring patient-identified lesions of concern, achieving comparable diagnostic and management accuracy as in-office dermatology.

(*JMIR Dermatol* 2024;7:e52400) doi: [10.2196/52400](https://doi.org/10.2196/52400)

KEYWORDS

mobile teledermoscopy; teledermatology; direct-to-patient; full body skin exam; diagnostic concordance; mobile health; mHealth; dermoscopy; dermatology; dermatological; imaging; image; images; smartphone; lesion; lesions; skin; diagnostic; diagnosis; diagnoses; telehealth; telemedicine; eHealth

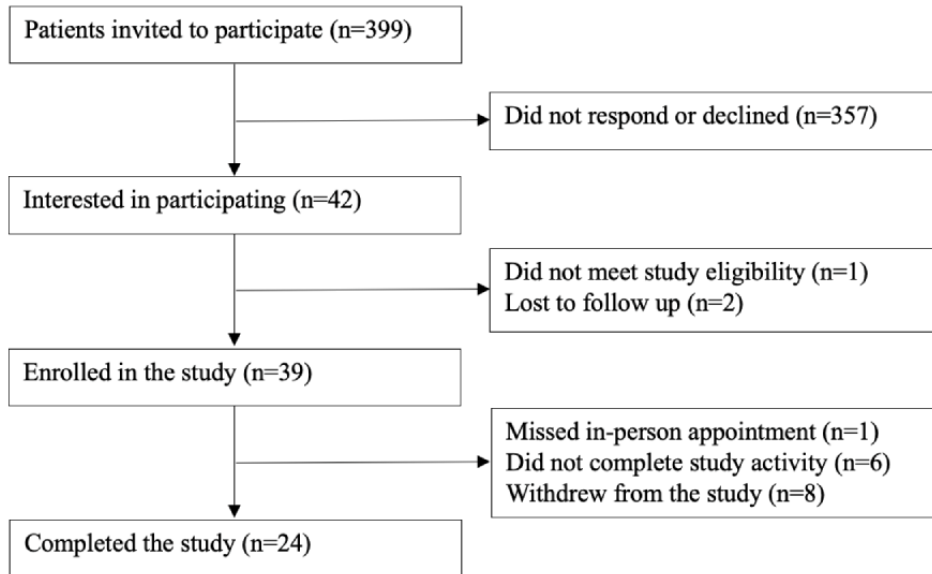
Introduction

Teledermoscopy is promising for improving the diagnostic accuracy of store-and-forward consultations [1]. However, few studies have explored using direct-to-patient mobile teledermoscopy to bypass in-person imaging [2-4]. Within the Veterans Health Administration system, teledermatology involves in-person visits with trained imaging technicians. Dermoscopy is not universally used. This prospective observational study evaluates a direct-to-patient mobile teledermoscopy program at the San Francisco Veterans Affairs Medical Center (SFVAMC) on its effectiveness in diagnosing and managing patient-identified lesions of concern.

Methods

Recruitment and Implementation

Adults scheduled for full-body skin exams between May and August 2022 were recruited (Figure 1) and given a Sklip mobile dermatoscope, valued at US \$99.99. They were instructed to image 1-3 lesions of concern using both smartphones and dermatoscopes. A teledermatologist reviewed all images for diagnosis, management, quality, and clinical utility. Clinical utility was defined as images that increased the teledermatologist's confidence in diagnosis and management. A dermatologist different from the teledermatologist evaluated the same lesions in-office.

Figure 1. Study participant recruitment flow diagram.

Statistical Analysis

The degree of agreement was assessed using the percentage of agreement and Cohen κ (95% CI). Cohen κ values were interpreted using the scale developed by Landis and Koch [5]. Excel (Microsoft Corporation) was used for data collection and analysis.

Ethical Considerations

This study was approved by the institutional review board (IRB) of the UCSF Human Research Protection Program and SFVAMC Research and Development Committee, IRB study number 21-33538. Participants provided informed consent with the option to opt out of the study. Participants were not compensated, and their data was anonymized and stored in a password-protected file.

Results

This study included 24 participants (male: $n=20$, 83%; mean age 65.3, SD 14.9 years). The average distance between their home zip codes and SFVAMC was 54.9 (SD 77.1) miles. A total of 12 (50%) participants had a history of skin cancer: 10 with basal cell carcinoma, 5 with squamous cell carcinoma, 4 with melanoma, and 1 with melanoma in situ.

A total of 56 lesions were imaged: 9 (17%) on the head, 1 (2%) on the neck, 8 (15%) on the posterior trunk, 16 (30%) on the

anterior trunk, 15 (28%) on the arms, and 3 (9%) on the legs. The teledermatologist rated most dermoscopic images ($n=37$, 66%) as acceptable to good quality. There was substantial agreement between the teledermatologist and in-person dermatologist in diagnoses and management (Table 1; $\kappa=0.65$, SE 0.13, 95% CI 0.39-0.91 and $\kappa=0.67$, SE 0.11, 95% CI 0.47-0.88, respectively). Most discordant diagnoses had concordant management ($n=3$, 60%).

Over 85% ($n=48$) of lesions were diagnosed as benign neoplasms. Two participants had additional lesions suspected of malignancy identified by in-office dermatologists, one of which was biopsy-proven basal cell carcinoma. Teledermatologists considered 59% ($n=33$) of smartphone images to have clinical utility, while 66% ($n=37$) of dermoscopic images provided additional utility when used alongside smartphone images.

For 65% ($n=15$) of participants who responded to a questionnaire, nondermoscopy smartphone imaging was easy, whereas 52% ($n=12$) reported mobile teledermoscopy as easy. Most ($n=18$, 78%) were willing to perform mobile teledermoscopy again. Barriers to dermoscopy use included difficulty performing with nondominant hand ($n=1$, 4%) and requiring assistance ($n=5$, 22%). All dermatoscopes were returned undamaged.

Table 1. Distribution of diagnoses and management by the teledermatologist and in-office dermatologists.

	Teledermatologist (n=56), n (%)	In-office dermatologist (n=56), n (%)
Diagnostic category		
Benign	48 (85.7)	48 (85.7)
Premalignant	1 (1.8)	3 (5.4)
Malignant	0 (0.0)	0 (0.0)
Infectious	0 (0.0)	1 (1.8)
Inflammatory	7 (12.5)	4 (7.1)
Neoplasm of uncertain behavior	0 (0.0)	0 (0.0)
Management		
Monitor	44 (78.6)	43 (76.8)
Cryotherapy	1 (1.8)	3 (5.4)
Biopsy or excision	4 (7.1)	2 (3.6)
Antibiotic	1 (1.8)	2 (3.6)
Steroid/anti-inflammatory	6 (10.7)	6 (10.7)

Discussion

Principal Findings

Substantial agreement was found between the teledermatologists and in-office dermatologists, consistent with previous studies [2,6]. However, the wide CIs indicate the need for further studies with larger sample sizes and implementation improvements, especially for identifying life-threatening malignancies. We recommend providing patients' medical history to teledermatologists. In one discordant case, a history of vitiligo could have differentiated from postinflammatory hypopigmentation. A recent study developed a checklist for mobile teledermoscopy image quality [7], which could be shared with patients to improve image quality. Because the teledermatologist had a lower threshold for biopsies, a follow-up office visit should be pursued when a procedure is recommended.

Given the high proportion of benign neoplasms in our study, teledermoscopy implementation for patient-identified lesions could lead to an increased burden for telediagnosis services. To increase the malignancy detection, we recommend providing patient education on high-risk features, such as the ABCDEs

(asymmetry, border, color, diameter, and evolving) of melanoma or the 7-point checklist, before imaging [8].

Limitations

This study is limited by its single-center design, small study population, and voluntary participation. The nonresponse rate to the initial invitation was 89% (n=399), which may be due to mail delivery issues, lack of interest, or time constraints. While premalignant lesions were identified, no malignant lesions were imaged. Future studies that involve larger cohorts, different health care settings, and more teledermatologists could elicit additional information on the efficacy of direct-to-patient mobile teledermoscopy.

Conclusions

Substantial agreement was found between direct-to-patient mobile teledermoscopy and in-office evaluation in the diagnoses and management of patient-identified lesions. Most participants reported ease with mobile teledermoscopy use; however, most lesions were benign, indicating the need for patient education on high-risk features to ensure appropriate lesions are imaged. Providing direct-to-patient mobile teledermoscopy services may expand the reach of existing teledermatology practice.

Acknowledgments

We would like to thank Daniel Butler, MD; Maria Wei, MD, PhD; Yiyin Chen, MD, PhD; Ruby Ghadially, MD; and Bahram Razani, MD, PhD, who participated in the study and provided in-office dermatologic care for the study population. We would also like to thank Dennis Oh, MD, PhD, for his input and review of the publication. This study received funding through the University of California, San Francisco Inquiry Office and San Francisco Veterans Affairs Medical Center Office of Education.

Authors' Contributions

WF wrote the original draft, developed the methodology, and supported in conceptualizing the study. GM conducted the formal analysis, led the project administration, and reviewed and edited the manuscript. AT conceptualized the study, acquired the funding, supervised the study, supported in development of the methodology, supported the project administration, and reviewed and edited the manuscript.

Conflicts of Interest

None declared.

References

1. Barcaui CB, Lima PMO. Application of teledermoscopy in the diagnosis of pigmented lesions. *Int J Telemed Appl*. 2018;2018:1624073. [doi: [10.1155/2018/1624073](https://doi.org/10.1155/2018/1624073)] [Medline: [30405711](https://pubmed.ncbi.nlm.nih.gov/30405711/)]
2. Manahan M, Soyer H, Loescher L, Horsham C, Vagenas D, Whiteman D, et al. A pilot trial of mobile, patient-performed teledermoscopy. *Br J Dermatol*. Apr 2015;172(4):1072-1080. [doi: [10.1111/bjd.13550](https://doi.org/10.1111/bjd.13550)] [Medline: [25418126](https://pubmed.ncbi.nlm.nih.gov/25418126/)]
3. Ackermann DM, Dieng M, Medcalf E, Jenkins MC, van Kemenade CH, Janda M, et al. Assessing the potential for patient-led surveillance after treatment of localized melanoma (MEL-SELF): a pilot randomized clinical trial. *JAMA Dermatol*. Jan 01, 2022;158(1):33-42. [FREE Full text] [doi: [10.1001/jamadermatol.2021.4704](https://doi.org/10.1001/jamadermatol.2021.4704)] [Medline: [34817543](https://pubmed.ncbi.nlm.nih.gov/34817543/)]
4. Jones LK, Oakley A. Store-and-forward teledermatology for assessing skin cancer in 2023: literature review. *JMIR Dermatol*. May 17, 2023;6:e43395. [FREE Full text] [doi: [10.2196/43395](https://doi.org/10.2196/43395)] [Medline: [37632914](https://pubmed.ncbi.nlm.nih.gov/37632914/)]
5. Landis JR, Koch GG. The measurement of observer agreement for categorical data. *Biometrics*. Mar 1977;33(1):159-174. [Medline: [843571](https://pubmed.ncbi.nlm.nih.gov/843571/)]
6. Wu X, Oliveria SA, Yagerman S, Chen L, DeFazio J, Braun R, et al. Feasibility and efficacy of patient-initiated mobile teledermoscopy for short-term monitoring of clinically atypical nevi. *JAMA Dermatol*. May 2015;151(5):489-496. [doi: [10.1001/jamadermatol.2014.3837](https://doi.org/10.1001/jamadermatol.2014.3837)] [Medline: [25629626](https://pubmed.ncbi.nlm.nih.gov/25629626/)]
7. Koh U, Betz-Stablein B, O'Hara M, Horsham C, Curiel-Lewandrowski C, Soyer HP, et al. Development of a checklist tool to assess the quality of skin lesion images acquired by consumers using sequential mobile teledermoscopy. *Dermatology*. 2022;238(1):27-34. [doi: [10.1159/000515158](https://doi.org/10.1159/000515158)] [Medline: [33849022](https://pubmed.ncbi.nlm.nih.gov/33849022/)]
8. Liu W, Hill D, Gibbs AF, Tempany M, Howe C, Borland R, et al. What features do patients notice that help to distinguish between benign pigmented lesions and melanomas?: the ABCD(E) rule versus the seven-point checklist. *Melanoma Res*. Dec 2005;15(6):549-554. [doi: [10.1097/00008390-200512000-00011](https://doi.org/10.1097/00008390-200512000-00011)] [Medline: [16314742](https://pubmed.ncbi.nlm.nih.gov/16314742/)]

Abbreviations

ABCDE: asymmetry, border, color, diameter, and evolving

SFVAMC: San Francisco Veterans Affairs Medical Center

Edited by R Dellavalle; submitted 02.09.23; peer-reviewed by A Oakley, C Horsham; comments to author 17.09.23; revised version received 06.10.23; accepted 22.01.24; published 12.02.24

Please cite as:

Fan W, Mattson G, Twigg A

Direct-to-Patient Mobile Teledermoscopy: Prospective Observational Study

JMIR Dermatol 2024;7:e52400

URL: <https://derma.jmir.org/2024/1/e52400>

doi: [10.2196/52400](https://doi.org/10.2196/52400)

PMID:

©Winnie Fan, Gunnar Mattson, Amanda Twigg. Originally published in *JMIR Dermatology* (<http://derma.jmir.org>), 12.02.2024. This is an open-access article distributed under the terms of the Creative Commons Attribution License (<https://creativecommons.org/licenses/by/4.0/>), which permits unrestricted use, distribution, and reproduction in any medium, provided the original work, first published in *JMIR Dermatology*, is properly cited. The complete bibliographic information, a link to the original publication on <http://derma.jmir.org>, as well as this copyright and license information must be included.