

UC San Diego

UC San Diego Previously Published Works

Title

Wound healing in the vulnerable: A novel case of postauricular wounds caused by mask ties.

Permalink

<https://escholarship.org/uc/item/2xr465ff>

Authors

La Monte, Olivia
Harmon, Matthew
Watson, Deborah
[et al.](#)

Publication Date

2023-06-01

DOI


10.1016/j.jemrpt.2023.100038

Peer reviewed



Since January 2020 Elsevier has created a COVID-19 resource centre with free information in English and Mandarin on the novel coronavirus COVID-19. The COVID-19 resource centre is hosted on Elsevier Connect, the company's public news and information website.

Elsevier hereby grants permission to make all its COVID-19-related research that is available on the COVID-19 resource centre - including this research content - immediately available in PubMed Central and other publicly funded repositories, such as the WHO COVID database with rights for unrestricted research re-use and analyses in any form or by any means with acknowledgement of the original source. These permissions are granted for free by Elsevier for as long as the COVID-19 resource centre remains active.



Wound healing in the vulnerable: A novel case of postauricular wounds caused by mask ties

Andrew Yousef^{*}, Olivia La Monte, Matthew Harmon, Deborah Watson

Department of Otolaryngology-Head and Neck Surgery, University of California, San Diego, CA, USA

ARTICLE INFO

Keywords:

Auricular injury
COVID-19
Otolaryngology
Mask complications

ABSTRACT

Background: The COVID-19 pandemic has made facial masks an essential part of daily life. While protective facial masks are crucial to help the spread of viral infections, they are common causes of facial skin breakdown, acne, and superficial injuries. Masks with elastic ear loops are also particularly likely to cause ear pressure injuries. **Case report:** Herein, we present a case of a patient experiencing homelessness found to have significant post-auricular wounds due to prolonged mask use in the context of the Covid-19 pandemic. These injuries led to bilateral erosion of the helix with partial avulsion of the ear and mask ear loops eroding into cartilage. **Why should an emergency physician be aware of this?:** We describe a rare complication of mask use and highlight the difficulties the COVID pandemic has made in providing adequate care for chronic head and neck wounds amongst the homeless population. While PPE remains an important part of decreasing the risk of the spread of infections, it is important to recognize the vulnerabilities of the homeless population during the COVID pandemic and how best to care for novel auricular wounds.

1. Introduction

Emergency department physicians routinely face the challenge of managing chronic wounds in the homeless population. This population has higher rates of comorbidities including diabetes, hypertension, and human immunodeficiency virus putting these individuals at higher risk of head and neck wound complications in particular [1–3]. Additionally, homeless individuals experience poor access to healthcare, driven by factors that include lack of health insurance coverage, prioritization of other needs (i.e. food and shelter), and previous experiences that were negative or discriminatory within the healthcare system [4,5]. The COVID-19 pandemic has brought on a host of new difficulties associated with caring for the vulnerable. Like pandemics throughout history, the ongoing COVID-19 pandemic has disproportionately affected vulnerable populations and widened the gap in health equity [6].

The pandemic has brought about the regular use of masks. While the risk of complications related to mask use is low, we present a case of a patient experiencing homelessness found to have significant post-auricular wound injuries due to prolonged mask use in the context of the COVID-19 pandemic. We discuss the challenges of providing effective care for these patients in the emergency department and hope that this case will be applicable to future similar encounters in the emergency

department, emphasizing the necessity of providing head and neck care with special attention to the needs of homeless populations.

2. Case presentation

A 31-year-old male with a past medical history notable for schizoaffective disorder and psychosis requiring multiple hospitalizations and homelessness, was brought into the emergency department (ED) for evaluation of bilateral posterior ear wounds from prolonged use of a fabric mask.

The patient presented to the ED with worsening bilateral posterior ear wounds and altered mental status after being found agitated outside a hotel. He was placed on a 5150 for psychiatric grave disability and self-neglect. At that time, his exam was notable for 3 masks matted within his long beard with the elastic ties embedded into the skin behind the ear. His left ear was partially avulsed with one ear loop of a disposable mask buried in 3 cm x 2 cm of granulation tissue at the superior helical attachment of the postauricular skin (Fig. 1). His right ear had three ear loops abrading through the superior aspect of helical root with an area of exposed cartilage. There was friable granulation tissue throughout the approximately 2cm deep wound bed. CT scan completed in the Emergency Department was notable for no evidence of osteomyelitis,

^{*} Corresponding author. University of California, San Diego 200 W Arbor Dr, MC 8895, San Diego, CA, 92103, USA.

E-mail address: adyousef@health.ucsd.edu (A. Yousef).

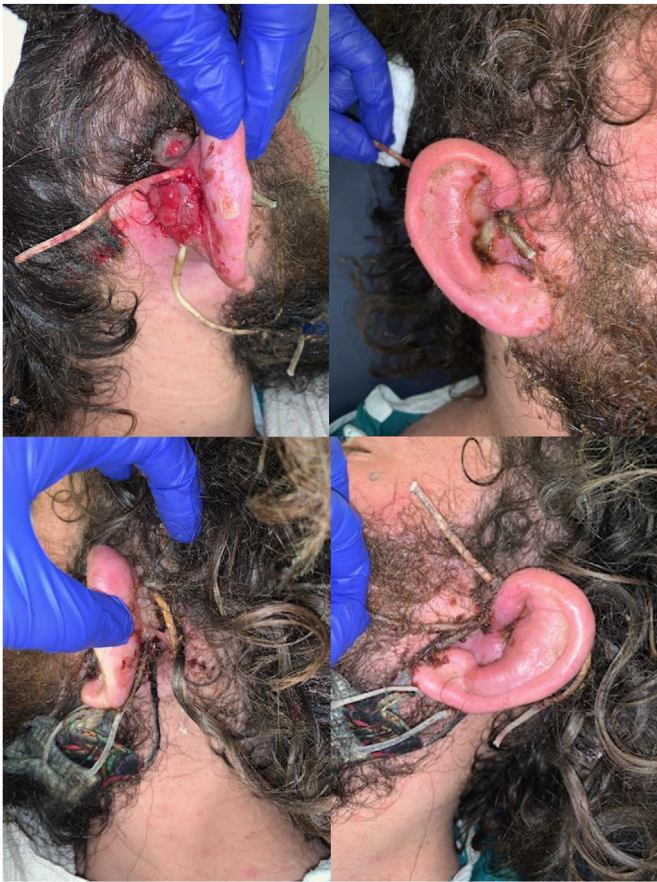

Fig. 1. Top row: right ear showing significant auricular injuries with the elastic ties of the masks eroding through the helical root toward the conchal bowl with postauricular granulation tissue; bottom row: left ear showing multiple elastic ties eroding through the helical root with auricular inflammation and erythema.

cholesteatoma, or other inner or middle ear etiologies. Due to the severity of this patient's wounds, extending through the helix and involving a large portion of the outer ear, the hospital otolaryngology team was consulted and assumed care of the patient.

He remained afebrile with normal vitals, and his lab work was notable for normal WBC count, normal ESR, mildly elevated CRP at 2.22, and CPK of 297. The ear loops were explanted from his skin bilaterally and the wounds were thoroughly cleaned. A single deep 4 -0 vicryl was used to repair the avulsed left auricle. Topical Bactroban was applied and bilateral wounds were dressed with Glasscock dressings to limit auricle mobility.

Wound cultures eventually came back positive for methicillin-sensitive staphylococcus aureus, streptococcus anginosus, and prevotella denticola. The patient was admitted and treated with intravenous antibiotics and topical mineral oil-hydrophil petrolat to maintain moisture and promote wound healing before discharge from the hospital.

3. Discussion

This patient's case is an example of impaired wound healing leading to significant auricular injuries by focal pressure sores from prolonged mask use. As demonstrated in this case, standard masks with tight elastic ties can result in soft tissue compression and skin erosion. Managing chronic head and neck wounds in the homeless population remains a challenge for emergency physicians and otolaryngologists alike. The COVID-19 pandemic has not only illuminated issues of access to healthcare, but it also has contributed to unexpected wound complications presenting to the emergency department. In a case such as the one

presented, the otolaryngology team was consulted to assist with care of the individual at risk of severe otologic damage and infection, potentially requiring detailed surgical intervention to recover anatomy and functionality of the ear.

Using personal protective equipment for prolonged and intensive periods of time can result in superficial skin sores and discomfort [7,8]. However, this level of significant auricular injuries due to mask use has only been described once before in the literature [9]. Protective face masks are common causes of facial skin breakdown, acne, and pressure injuries. Masks with elastic loops are particularly likely to cause ear pressure injuries [10]. Due to its superficial location, the external ear is susceptible to traumatic injuries, ranging from simple lacerations to complete auricular avulsions [11,12]. Postauricular skin is thinner than other areas of the pinna and most other areas of the face [11]. When thin skin is challenged with the effects of aging and coupled with chronic sun exposure, the skin of the ear becomes more susceptible to pressure injuries and other local traumas, in addition to wound healing complications [11,13] Re-epithelialization of the auricle by secondary intention is a several-week process, requiring active wound care and can result in granulating wounds that may limit ear function [12,14]. Repair of hyaline cartilage has been shown to be linked to age, further complicating repair in older individuals [13,15]. A detailed surgical technique and often interdisciplinary surgical team ensure satisfactory functional and aesthetic outcomes [12].

It is important to recognize the vulnerability of the homeless population during the COVID pandemic. These individuals are at increased risk for chronic wound infections and viral transmission. They require adequate PPE due to exposure risk in settings such as large crowds and transportation hubs [16]. Chronic wounds such as ulcers, as well as conditions with frequent wound complications (diabetes, hepatitis, chronic kidney disease and cardiac disease) are more prevalent among homeless individuals [17]. Chronic health conditions associated with this population increase the risk of complications caused by the virus, as well as pressure injuries caused by mask ties.

The COVID pandemic has made providing adequate care for chronic head and neck wounds among the homeless population even more challenging. It created a greater aversion to the timely seeking of healthcare because of transmission concerns in the emergency waiting rooms [18]. A lack of resources and concerns related to virus transmission have disrupted the delivery of routine comprehensive care for chronic patients, resulting in fewer face-to-face consultations [19–21]. Consequently, patients needing chronic care limited community-based support, and disadvantaged individuals without consistent care are more likely to be neglected.

Recommendations are presented to improve the care of chronic head and neck wounds in the homeless population: 1) the establishment of more mobile clinics in strategic areas associated with a larger homeless population; 2) establish clinics inside homeless shelters that can provide basic medical care including wound care; 3) support cost-effective treatments for chronic head and neck injuries that are available to individuals with limited resources and who may have potential barriers to healthcare [22]. As a preventive measure, studies have demonstrated that over-the-counter skin protectants can reduce frictional forces applied to the skin by personal protective equipment [8,23]. In one study, lubricant and tape were used to limit friction, in addition to monitoring mask irritation regularly. These measures reduced facial pressure injuries from 29% to 8% and were found to be inexpensive, easy to use, and safe [8]. By following these healthcare practices and using these medical products, medical organizations and shelters can raise awareness and succeed in preventing chronic infections among patients at risk for pressure-related injuries while maintaining COVID-viral protection.

4. Why should an emergency physician be aware of this?

The coronavirus pandemic has made PPE a necessity in everyday life. However, the pandemic has made providing adequate care for chronic

head and neck wounds among the homeless population even more challenging. We present here one of the first reports of significant auricular injury due to prolonged mask use. While PPE remains an important part of decreasing the risk of the spread of infections, it is important to recognize the vulnerabilities of the homeless population during the COVID pandemic. Maximizing safe access to PPE with innovative ways to provide care to the homeless population is needed moving forward.

Declaration of competing interest

The authors have no financial relationships or conflicts of interest to disclose.

References

- [1] Hwang SW. Homelessness and health. *CMAJ (Can Med Assoc J)* 2001;164(2): 229–33. Jan 23.
- [2] Hwang SW, Bugeja AL. Barriers to appropriate diabetes management among homeless people in Toronto. *CMAJ (Can Med Assoc J)* Jul 25 2000;163(2):161–5.
- [3] Kushel MB, Vittinghoff E, Haas JS. Factors associated with the health care utilization of homeless persons. *JAMA* 2001;285(2):200–6. <https://doi.org/10.1001/jama.285.2.200>. Jan 10.
- [4] Baggett TP, O'Connell JJ, Singer DE, Rigotti NA. The unmet health care needs of homeless adults: a national study. *Am J Publ Health* Jul 2010;100(7):1326–33. <https://doi.org/10.2105/AJPH.2009.180109>.
- [5] Khandor E, Mason K, Chambers C, Rossiter K, Cowan L, Hwang SW. Access to primary health care among homeless adults in Toronto, Canada: results from the Street Health survey. *Open Med* 2011;5(2):e94–103.
- [6] Shadmi E, Chen Y, Dourado I, et al. Health equity and COVID-19: global perspectives. *Int J Equity Health* Jun 26 2020;19(1):104. <https://doi.org/10.1186/s12939-020-01218-z>.
- [7] Yu J, Chen JK, Mowad CM, et al. Occupational dermatitis to facial personal protective equipment in health care workers: a systematic review. *J Am Acad Dermatol* Feb 2021;84(2):486–94. <https://doi.org/10.1016/j.jaad.2020.09.074>.
- [8] Moore Z, McEvoy NL, Avsar P, et al. Facial pressure injuries and the COVID-19 pandemic: skin protection care to enhance staff safety in an acute hospital setting. *J Wound Care* Mar 2 2021;30(3):162–70. <https://doi.org/10.12968/jowc.2021.30.3.162>.
- [9] Koti B, Zaveri S, Shah B, Anand S, Tagliaferri AR. Mask-induced partial transection of the external ear requiring complex surgical reconstruction. *Cureus* May 2022; 14(5):e25390. <https://doi.org/10.7759/cureus.25390>.
- [10] Levine JM, Ayello EA, Persaud B, Spinner R. Medical device-related pressure injury to the ear from a mask. *Adv Skin Wound Care* Jul 1 2021;34(7):380–3. <https://doi.org/10.1097/01.ASW.0000752712.31139.c0>.
- [11] Sand M, Sand D, Brors D, Altmeyer P, Mann B, Bechara FG. Cutaneous lesions of the external ear. *Head Face Med* Feb 8 2008;4:2. <https://doi.org/10.1186/1746-160X-4-2>.
- [12] Sclafani AP, Mashkevich G. Aesthetic reconstruction of the auricle. *Facial Plastic Surgery Clinics of North America* 2006;14(2):103–16. <https://doi.org/10.1016/j.fsc.2006.01.004>.
- [13] Verwoerd-Verhoef HL, ten Koppel PG, van Osch GJ, Meeuwis CA, Verwoerd CD. Wound healing of cartilage structures in the head and neck region. *Int J Pediatr Otorhinolaryngol* May 15 1998;43(3):241–51. [https://doi.org/10.1016/s0165-5876\(98\)00003-2](https://doi.org/10.1016/s0165-5876(98)00003-2).
- [14] Zitelli JA. Wound healing by secondary intention. A cosmetic appraisal. *J Am Acad Dermatol* Sep 1983;9(3):407–15. [https://doi.org/10.1016/s0190-9622\(83\)70150-7](https://doi.org/10.1016/s0190-9622(83)70150-7).
- [15] Silver FH, Glasgold AI. Cartilage wound healing. An overview. *Otolaryngol Clin Oct 1995;28(5):847–64*.
- [16] The Lancet M. US CDC's unexpected change of stance on mask use. *The Lancet Microbe* 2021;2(6):e225. [https://doi.org/10.1016/s2666-5247\(21\)00122-1](https://doi.org/10.1016/s2666-5247(21)00122-1).
- [17] Harper Sutherland MMA, Rosenoff Emily. Health conditions among individuals with a history of homelessness. *ASPE RESEARCH BRIEF*; 2021.
- [18] Gettler E, Stern R, Ni B, et al. Avoidance of emergency care in the southeastern United States during the COVID-19 pandemic. *Open Forum Infect Dis* May 2022; 9(5):ofac161. <https://doi.org/10.1093/ofid/ofac161>.
- [19] Fekadu G, Bekele F, Tolossa T, et al. Impact of COVID-19 pandemic on chronic diseases care follow-up and current perspectives in low resource settings: a narrative review. *Int J Physiol Pathophysiol Pharmacol* 2021;13(3):86–93.
- [20] Danhieux K, Buffel V, Pairon A, et al. The impact of COVID-19 on chronic care according to providers: a qualitative study among primary care practices in Belgium. *BMC Fam Pract* Dec 5 2020;1(1):21. <https://doi.org/10.1186/s12875-020-01326-3>. ARTN 255.
- [21] Kendzerska T, Zhu DT, Gershon AS, et al. The effects of the health system response to the COVID-19 pandemic on chronic disease management: a narrative review. *Risk Manag Healthc Pol* 2021;14:575–84. <https://doi.org/10.2147/RMHP.S293471>.
- [22] Coates SJ, Amerson EH, Chang AY. Dermatologic care of persons experiencing homelessness: key concepts in an era of housing instability. *JAMA Dermatol* Sep 1 2020;156(9):945–6. <https://doi.org/10.1001/jamadermatol.2020.0902>.
- [23] Gefen A, Ousey K. Update to device-related pressure ulcers: SECURE prevention. COVID-19, face masks and skin damage. *J Wound Care* May 2 2020;29(5):245–59. <https://doi.org/10.12968/jowc.2020.29.5.245>.