

UC Irvine

UC Irvine Previously Published Works

Title

Bone and mineral disorders after kidney transplantation: therapeutic strategies.

Permalink

<https://escholarship.org/uc/item/2z11m8j8>

Journal

Transplantation Reviews, 28(2)

Authors

Molnar, Miklos

Naser, Mohamed

Kalantar-Zadeh, Kamyar

et al.

Publication Date

2014-04-01

DOI

10.1016/j.trre.2013.12.003

Peer reviewed



Published in final edited form as:

Transplant Rev (Orlando). 2014 April ; 28(2): 56–62. doi:10.1016/j.trre.2013.12.003.

Bone and mineral disorders after kidney transplantation: therapeutic strategies

Miklos Z. Molnar, MD, PhD^{1,2}, Mohamed S. Naser, MD², Connie M. Rhee, MD, MSc¹, Kamyar Kalantar-Zadeh, MD, MPH, PhD^{1,3}, and Suphamai Bunnapradist, MD⁴

¹Division of Nephrology and Hypertension, University of California Irvine Medical Center, Orange, CA; USA

²Dept. of Medicine, Division of Nephrology, University Health Network, University of Toronto, Toronto, Ontario, Canada

³Departments of Community Health Sciences and Epidemiology, UCLA Fielding School of Public Health, Los Angeles, CA, USA

⁴David Geffen School of Medicine at UCLA, Los Angeles, CA, USA

Abstract

Mineral and bone diseases (MBD) are common in patients with chronic kidney disease who undergo kidney transplantation. The incidence, types and severity of MBD varies according to the duration of chronic kidney disease, presence of comorbid conditions and intake of certain medications. Moreover, multiple types of pathology may be responsible for MBD. After successful reversal of uremia by kidney transplantation, many bone and mineral disorders improve, while immunosuppression, other medications, and new and existing comorbidities may result in new or worsening MBD. Chronic kidney disease is also common after kidney transplantation and may impact bone and mineral disease. In this article, we reviewed the prevalence, pathophysiology, and impact of MBD on post-transplant outcomes. We also discussed the diagnostic approach; immunosuppression management and potential treatment of MBD in kidney transplant recipients.

Keywords

adynamic bone; bisphosphonates; calcineurin inhibitor; fracture; renal osteodystrophy

Introduction

Organ transplantation is considered the most effective treatment for end-stage renal disease (ESRD). Patient survival and graft survival have improved over time because of tremendous

Correspondence: Suphamai Bunnapradist, MD, Professor of Medicine, David Geffen School of Medicine at UCLA, 1033 Gayley Blvd. suite 208, Los Angeles, CA 90095, Phone: 310-794-8516, Fax: 310-794-8589.

Relevant Potential Conflict of Interest:

Dr. Kalantar-Zadeh has received grants and/or honoraria from Abbott, Amgen, DaVita, Fresenius-Kabi, Genzyme, Otsuka, and Shire. Drs. Molnar, Naser, Rhee and Bunnapradist report no conflicts of interest.

advances in immunosuppression regimens and surgical techniques. Many complications of ESRD may be reversed by transplantation; however, bone and mineral metabolism disturbances may persist, while new bone disorders may develop due to transplant medications such as corticosteroids. Renal allograft recipients experience a rapid loss of bone mass specially during the early post-transplantation period (ie, the first 6 months after transplant). Despite mineral and bone diseases (MBD) being a common complication in kidney transplantation, there is still insufficient usage of diagnostic and treatment tools to prevent further bone loss. In this article, we present updated information about the consequences, prevalence, and therapeutic options of MBD in kidney transplant patients.

The prevalence and the different types of renal osteodystrophy in kidney transplant patients

Renal osteodystrophy is classified into four subgroups as follows: hyperparathyroid bone disease, adynamic bone disease, osteomalacia and mixed renal osteodystrophy.(1, 2). The main characteristics of the different types of MBD in kidney transplant recipients are shown in Table 1. The exact prevalence of histological patterns of bone disease after transplantation is not well known as bone biopsy due to sparsity of data among a few past studies. Furthermore, the results of these few past studies are somewhat conflicting. In these early studies, heterogeneity of bone lesions has been observed (3, 4) whereas others reported a high prevalence of: normal bone formation;(4) high bone turnover associated with persistence of secondary hyperparathyroidism;(5) or low bone turnover.(6, 7). In some studies, prolonged mineralization time without osteoid formation has been found in some studies,(6–8) whereas frank osteomalacia has rarely been observed.(3)

According to bone biopsy studies, osteomalacia and the adynamic bone disorders are the two most common findings in kidney transplant recipients. Figure 1 shows the picture of adynamic bone disorders. In one study, cancellous bone volume from 57 kidney transplant patients was examined. Compared to sex and age-matched controls, cancellous bone volume was below normal in more than 50% of patients.(9) Bone turnover was normal in 28%, elevated in 26% and low in 46% of patients. 88% of patients had prolonged mineralization, with 9 patients having osteomalacia and 12 patients having focal osteomalacia.(9) In another study of 20 patients examined before and after kidney transplantation, similar results were observed. Bone histologic diagnoses before the transplant were as follows: adynamic bone disease (n=12); mild disease (n=3); mixed bone disease (n=3); and osteitis fibrosa (n=2). Post-transplantation, most patients had adynamic bone disease (n=11) compared to mild disease (n=8) and osteomalacia (n=1).(10) However, conflicting results were observed in a different study from Germany.(11) The most frequent forms of renal osteodystrophy were osteitis fibrosa, which was observed in 14 patients (24.6%). Seven patients (12.3%) had mixed uremic osteodystrophy, 3 patients (5.3%) had adynamic renal bone disease, and 2 patients (3.5%) had osteomalacia.(11) Moreover, 13 patients (22.8%) were observed to have reduced bone mass and structural damage without typical signs of renal osteodystrophy, such as endosteal fibrosis or osteoclasia, whereas normal histomorphometric parameters was observed in 5 patients (8.7%).(11)

Hence, low turnover bone disease (adynamic bone disease and osteomalacia) is the most common bone disorder in kidney transplant recipients. These patients show delayed mineralization and decreased mineral deposition rate explained by the intense decrease in PTH levels in patients with relatively mild bone disease before transplantation(6) and by the high doses of glucocorticoids.(9) Rojas et al. showed that post-transplant osteoblast surface correlated positively with PTH levels and negatively with glucocorticoid cumulative dose; consequently PTH seems to have a protective effect by preserving osteoblast survival.(12) Moreover, one study conducted by Velasquez-Forero et al. (7) primarily showed changes that were consistent with adynamic bone disease and increased deposition of iron, whereas other studies have shown persistent bone resorption as decreased bone formation and prolonged mineralization lag time (8) There are conflicting data among the findings described in the various studies, but the main pathology in bone remodeling after renal transplantation consists of decreased bone formation and mineralization associated with persistent bone resorption. Likewise, the pathological defective bone formation may be a consequence of decreased osteoblastogenesis, osteoblast function, or increased osteoblast death rate.

Mineral Bone Disorders after Kidney Transplantation and its Consequences

Fractures and Bone Mineral Density (BMD) Disturbances

It is well known that loss of bone mass occurs primarily in the first 12 months after kidney transplantation, predominantly in cortical bone. As shown by dual-energy X-ray absorptiometry (DXA), the most rapid decrease in bone mineral density (BMD) occurs in the first 6 months after transplantation, and seems to slow thereafter, possibly because of decreased use of corticosteroids. A study conducted by Rojas et al. (12) showed that osteoid thickness, osteoid volume, osteoid resorption surface, and osteoclast surface were above the normal range before transplant and remained elevated 35 days after transplantation. However, osteoblast surfaces and osteoid, which were also increased before transplantation, significantly diminished within 35 days post-transplant.(12). There was also inhibition of bone formation after transplantation, mineralization, and apoptosis, which were associated with doses of glucocorticoids.(12). It has been reported that BMD decreases to a mean of 5.5–19.5% during the first 6 months,(13) and only 2.6–8.2% between the 6th and 12th month after transplantation,(14). It is only 0.4–4.5% of the mean thereafter.(15)

There is a 3.6–3.8-fold higher overall fracture risk in renal transplantation patients compared to healthy individuals,(16, 17) and this is 30% higher during the first 3 years post transplantation compared to patients on dialysis.(16) Moreover, several publications have confirmed the heightened fracture risk after renal transplantation as compared with maintenance dialysis. Ball et al. found that 3 years after transplantation, the risk for hip fracture increased by 34% when compared with dialysis patients.(16) Patel et al. evaluated 165 transplant patients and found that 16% of patients had either vertebral deformities or a history of a low trauma fracture after transplantation.(18) A recent systematic review of 262,678 recipients showed fracture sites varied by study resulting in a highly variable incidence rate ranging from 3.3 to 99.6 fractures per 1000 person-years.(19) Similarly, the 5-year cumulative incidence for fracture varied ranging from 0.85% to 27%.(19) Ramsey-

Goldman et al. found that the foot was the most common site of fracture in both premenopausal and postmenopausal women after transplantation.(20) In a retrospective study, which followed patients up to 33 years, diabetic nephropathy and age were independent predictors of fracture risk, while higher activity levels were shown to be protective factors.(17) There are additional risk factors for fracture that include female sex and having had a combined kidney–pancreas transplantation. Compared to waitlisted dialysis patients, there is a 1.34-fold greater relative risk of hip fracture associated with transplantation when compared with dialysis. There was a 1% decrement of risk per month up until 630 days after transplantation at which time the estimated risk became equal for dialysis and transplant recipients.(16) The risk of vertebral fracture is higher in renal transplant recipients; this risk is greater than their risk of lower extremity fractures.(17)

Vitamin D and FGF-23—Low serum 25-OH-vitamin D levels are very common following kidney transplantation, both during the immediate postoperative period and in long-term graft recipients.(21) The KDIGO guidelines suggested that (22) kidney transplant patients should be assessed for the presence of vitamin D deficiency by examining circulating levels of 25-(OH) vitamin D (calcidiol), and vitamin D deficiency and insufficiency should be corrected by applying treatment strategies recommended for the general population. After kidney transplantation, the level of 1,25(OH)₂ vitamin D (calcitriol) usually increases, but it may still be lower compared to the general population.(23) Immunosuppressive therapy, PTH level and residual renal function are the most important predictors of low 1,25(OH)₂ vitamin D levels.(24) Pre-transplantation PTH levels and low post-transplantation levels of FGF-23 were observed to be additional predictors of improved post-transplantation 1,25(OH)₂ vitamin D levels, although these were weaker than renal graft function.(24) However, more recently Sanchez Fructuoso showed serum FGF-23 concentrations remain increased in long-term kidney graft recipients, even in the early stages of CKD.(25) In addition, FGF-23 appears to be a strong and independent predictor of mortality in prevalent kidney transplant recipients.(26)

What are the Contributors to MBD in Kidney Transplantation?

There are numerous contributing factors, but the main factors are as follow: (1) pre-existing renal osteodystrophy at time of renal transplantation, (2) transplantation-specific therapies, and (3) reduced GFR.

1. Pre-existing renal osteodystrophy prior to renal transplantation

As all patients undergoing kidney transplant suffer from chronic renal insufficiency, they all experience pre-existing MBD. Consequently, post-transplant bone disease cannot be considered as a separate entity; rather its course is influenced by changes in mineral metabolism and bone structure before the transplant.

There has been a considerable change in the spectrum of osteodystrophy in dialysis patients in the past several years. There is an increment in the incidence and the prevalence of low bone turnover, particularly adynamic bone disease. It is becoming the primary type of bone alteration. A National Kidney Foundation (NKF) group studying renal osteodystrophy published a review suggesting that renal bone disease should be characterized by three

histologic features: mineralization, turnover, and volume. In a survey of 544 bone biopsy samples from with CKD stage 5 patients, bone turnover was normal in only 21%, low in 52%, and high in 27% of biopsies. Three percent were found with defective mineralization. (27) Cancellous bone volume was normal in only 30%, low in 32%, and high in 38%. (28)

It is important to differentiate between cortical and cancellous bone in the assessment of bone volume abnormalities. High turnover bone disease patients have mainly loss of cortical bone while patients with low bone turnover have mainly loss of cancellous bone. (27) Cortical bone provides the mechanical function of the bone, whereas cancellous bone provides the metabolic function. While abnormal metabolic activity results in the inability to maintain mineral metabolism, decreased bone strength results in fracture. The former is well known to be associated with vascular and soft tissue calcification.

Only a few studies analyzed the change of aluminum-related bone disease (ARBD) after successful renal transplantation. David-Neto et al. examined 11 adult patients after transplantation. (29) ARBD remarkably improves 1 year following successful kidney transplantation. (29) The same authors showed that in 13 patients with adynamic bone disorders, no bone aluminum was detected at 12 months post-transplant in any of the 5 patients who had pre-transplant aluminium deposition. (30)

1.2 Pre-existing CKD-MBD and post-transplant outcomes—Pre-existing renal osteodystrophy and markers of renal osteodystrophy, such as serum phosphorous, parathyroid hormone (PTH), and alkaline phosphatase are also associated with post-transplant mortality. Using a large dialysis organization (LDO) database, we found that more than 14,000 kidney transplant recipients have CKD-MBD data before transplantation. Using this data, we observed that there is a U-shaped association between serum phosphorous level and post-transplant mortality, with only high pre-transplant serum phosphorous levels demonstrating an association with a higher risk of graft loss. (31) Interestingly, there were no associations between serum PTH levels and post-transplant outcomes, while serum alkaline phosphatase showed a strong, linear association with post-transplant mortality and graft loss. (32)

2. Effect of transplantation-specific therapies on bone

A major factor in the pathogenesis of post-transplant bone disease is post-transplantation immunosuppressive therapy. (33) Glucocorticoid-induced acceleration in bone remodeling occurs during the first 6 months after transplantation. (6) A study that involved bone biopsies at 22 days and 160 days after transplantation depicted early osteoblast apoptosis and impaired osteoblastogenesis. (12) Numerous factors play a role in the etiology of glucocorticoid induced bone disorder. Steroids are toxic to osteoblasts and lead to increased osteoclast activity. (34) They also promote osteopenia and calcium loss. Other mechanisms include reduced gonadal hormone production, decreased calcium absorption from the gut, decreased insulin-like growth factor-1 production, diminished PTH sensitivity, increased osteoclastogenesis and increases in receptor activator of NF-kappa beta ligand (RANKL).

Both cyclosporine and tacrolimus have been linked to osteoporosis in clinical studies; (35, 36) however, population-based studies focused on fracture risk could not establish an

association between use of calcineurin inhibitors and fracture risk.(17, 18) In addition, the Calcineurin-inhibitor Induced Pain Syndrome (CIPS) is a rare but severe side effect of cyclosporine and tacrolimus. This syndrome is accurately diagnosed by its typical presentation, magnetic resonance imaging and bone scans.(37) Although mycophenolate mofetil, sirolimus, and azathioprine did not affect bone volume in rodents, a recent in vitro study suggests sirolimus might interfere with the proliferation and differentiation of osteoblasts. Furthermore, (38) everolimus reduced cancellous bone loss in ovariectomized rats by decreasing osteoclast-mediated bone resorption.(39)

3. The effects of decreased GFR after renal transplantation

Patients who are between CKD stages 3–5 post-transplantation are at increased risk for the development of hyperparathyroidism.(40) There was a negative correlation between intact PTH and estimated GFR in a study, which examined more than 900, transplant patients ($\rho = -0.289$, $p < 0.001$). (40) Additionally, high PTH values correlated well with bone loss at the hip area.(41)

Therapy of MBD in kidney transplant recipients

There are no randomized controlled trials in transplant recipients examining bone-specific therapies on patient-level outcomes such as mortality or fractures. Moreover, there is insufficient data to recommend bone-specific-therapies within the first year of kidney transplantation. In Table 2 we show the major clinical trials and observational studies in renal transplant recipients. Several potential treatment options are as follows:

I. Glucocorticosteroid avoidance or withdrawal

One study found beneficial effects on BMD after early tapering of prednisolone.(42) The rationale for minimizing corticosteroid use relates to its established risks of osteoporosis, avascular necrosis and other side effects.

II. Bisphosphonates

There are four studies that used multiple doses of bisphosphonates (pamidronate) during the early months after renal transplantation. Prevention of bone loss occurred even after the treatment was discontinued.(43) All of these studies showed the administration of pamidronate prevented bone loss in the short period after transplantation. The studies also showed that most of the patients already had or developed de novo low turnover bone disease.(43) When other bisphosphonates were administered, similar results were found. (44–48) In comparison to vitamin D therapy, administration of bisphosphonate significantly improved the bone mineral density specially at the femoral neck and lumbar spine in kidney transplant recipients.(49)

Bone biopsy was not used for diagnostic purposes in most of these trials. However, Coco et al. published a recent study in which they performed baseline and 12 month post-transplant bone biopsies after randomly assigning 42 new living-donor kidney recipients to either 35 mg of risedronate weekly or placebo for 12 months. Treatment with risedronate did not affect BMD in the overall cohort of the study.(50) In subgroup analyses, risedronate

preserved BMD in females, but did not significantly affect BMD in male participants. Risedronate was associated with increased trabecular thickness and osteoid volume in male participants. Moreover, there was no evidence for the development of adynamic bone disease.(50)

Recently, Smerud et al. performed a double-blinded, placebo-controlled trial of 129 renal transplant recipients with early stable renal function.(51) Patients were randomized to receive intravenous ibandronate 3 mg or intravenous placebo every 3 months for 12 months in addition to oral calcitriol 0.25 mcg/day and calcium 500 mg twice a day. BMD was assessed at baseline, 10 weeks and 12 months after transplantation, and biochemical markers of bone turnover were measured. The primary endpoint was relative change in BMD.(51) BMD at the lumbar spine from baseline to 12 months was not different (+1.5% for ibandronate versus +0.5% for placebo). Ibandronate demonstrated a significant improvement of BMD in total femur (+1.3% versus -0.5%) and in the ultradistal radius (+0.6% versus -1.9%).(51) In addition, ibandronate suppressed biomarkers of bone turnover. Calcium, calcitriol supplementation and ibandronate showed an excellent efficacy and safety profile. (51) After this study, Brandenburg and Floege highlighted some potential limitations.(52) There are definitively concerns about the use of bisphosphonates, particularly given the unresolved issues of renal safety, the unknown effects on fracture rates, and the potential exacerbation or induction of adynamic bone disease.(52) We agree(53) with Brandenburg and Floege's(52) opinion that bisphosphonate therapy should be limited to patients who have a particularly high fracture risk and, ideally, adynamic bone disease should be excluded via bone biopsy prior to the administration of bisphosphonate therapy in kidney transplant recipients. An individualized approach is necessary for the prevention of post-transplantation bone loss.(53)

III. Vitamin D analogs and vitamin D receptor activators

Josephson et al. showed in a controlled, blinded study that kidney transplant recipients who were given calcium and calcitriol had less bone loss specifically in the lumbar spine and increased BMD in the distal radius compared with transplant patients given calcium alone or placebo.(54) There was no hypercalcaemia or deterioration of kidney function in patients given calcium and calcitriol. Unfortunately, there was no evaluation of fracture rates in these studies.(54) Therapy with low-dose calcium supplements over the course of 1 year, plus intermittent calcitriol for 3 months after transplantation is safe, decreases PTH levels more rapidly, and prevents bone loss at the proximal femur. Torres et al. also showed similar results.(55) Compared to placebo, calcidiol and oral calcium increased BMD at the lumbar spine and femoral neck.(56) Paricalcitol, a selective vitamin D receptor activator, is indicated in the prevention and treatment of secondary hyperparathyroidism. The profile of urinary peptide changes occurred due to treatment with paricalcitol as shown by preliminary results of this randomized controlled trial,(57) however, no study was published to assess administration of paricalcitol and the risk of bone fracture, BMD or outcomes. Hence, the treatment of calcitriol significantly improves the bone mineral density at femoral neck and lumbar spine without significantly increasing the risk of hypercalcaemia.(49)

IV. Calcimimetics

Some post-transplant trials showed that cinacalcet successfully reduced elevated serum calcium and PTH levels with no adverse effects on renal function. A favorable effect of cinacalcet on BMD in renal transplant patients was reported by a few small studies.(58)

V. Other treatments

Teriparatide, also known as recombinant human PTH, is another therapeutic agent that has been studied in kidney transplantation. In one study, it was administered to kidney transplant patients for 6 months; although shown to be safe, it did not alter BMD in the lumbar spine or distal radius compared with the placebo group.(59) However, BMD at the femoral neck remained unchanged in those given teriparatide, compared with a decrease in the placebo group. In addition, there was no significant difference in fractures, PTH levels, vitamin D levels, kidney function, bone histology or serologic bone markers between the two groups after 6 months.(59)

Our personal approach

In our practice the management of bone and mineral disorders in kidney transplantation is divided into perioperative phase and post-operative long-term follow-up care. The perioperative phase focuses on the correction of calcium and phosphorus disarrays that are common,(60–63) treatment of hyperparathyroidism based on serum PTH and alkaline phosphatase and correction of other fluid and electrolyte problems including hyponatremia, which may be associated to bone disorders and higher fracture rates.(64) The management strategies include the use of electrolyte and mineral supplements, diuretic therapy, Vitamin D supplement(65) and in some cases calcimimetics, especially if PTH levels remain elevated. During the long-term follow up, we often follow the conventional guidelines of CKD care according and is accordance with the CKD staging. Because Vitamin D deficiency is common in kidney transplant recipients, we routinely check 25-(OH) Vitamin D level and correct the deficiency as indicated. We do not routinely check for bone density and perform bone biopsy very rarely. However, we prescribe bisphosphonate as needed and as described in this review paper. We reserve parathyroidectomy in patients with persistently severe hyperparathyroidism after the first year post-transplant after the trial of calcimimetics.

Conclusions

Bone disease after kidney transplantation is characterized mainly by loss of bone volume and the presence of mineralization problems, which result in low turnover bone disease in most of these patients. There are many contributing factors but the three main factors are: pre-existing renal osteodystrophy at time of renal transplantation, transplantation-specific therapies and reduced renal function. At this time, there are no well-established therapeutic approaches that provide bone anabolic effects in renal transplant recipients. Vitamin D and bisphosphonates can be used for the treatment of MBD after transplantation; however, since the most frequent abnormality after transplantation is adynamic bone disease, bone biopsy should be considered before the administration of bisphosphonates.

Acknowledgments

Funding Source:

The study was supported by Dr. Kalantar-Zadeh's research grants from the National Institute of Diabetes, Digestive and Kidney Disease of the National Institute of Health (R01 DK078106 and K24 DK091419), and a philanthropic grant from Mr. Harold Simmons.

The authors thank for Dr. Isidro B Salusky for providing the images for Figure 1.

References

1. Hruska KA, Teitelbaum SL. Renal osteodystrophy. *N Engl J Med.* 1995; 333(3):166–74. Epub 1995/07/20. [PubMed: 7791820]
2. Wang M, Hercz G, Sherrard DJ, Maloney NA, Segre GV, Pei Y. Relationship between intact 1–84 parathyroid hormone and bone histomorphometric parameters in dialysis patients without aluminum toxicity. *Am J Kidney Dis.* 1995; 26(5):836–44. Epub 1995/11/01. [PubMed: 7485142]
3. Bonomini V, Feletti C, Di Felice A, Buscaroli A. Bone remodelling after renal transplantation (RT). *Adv Exp Med Biol.* 1984; 178:207–16. Epub 1984/01/01. [PubMed: 6391096]
4. Sanchez CP, Salusky IB, Kuizon BD, Ramirez JA, Gales B, Ettenger RB, et al. Bone disease in children and adolescents undergoing successful renal transplantation. *Kidney Int.* 1998; 53(5):1358–64. Epub 1998/05/09. [PubMed: 9573553]
5. Parfitt AM. Hypercalcemic hyperparathyroidism following renal transplantation: differential diagnosis, management, and implications for cell population control in the parathyroid gland. *Miner Electrolyte Metab.* 1982; 8(2):92–112. Epub 1982/08/01. [PubMed: 6762496]
6. Julian BA, Laskow DA, Dubovsky J, Dubovsky EV, Curtis JJ, Quarles LD. Rapid loss of vertebral mineral density after renal transplantation. *N Engl J Med.* 1991; 325(8):544–50. Epub 1991/08/22. [PubMed: 1857390]
7. Velasquez-Forero F, Mondragon A, Herrero B, Pena JC. Adynamic bone lesion in renal transplant recipients with normal renal function. *Nephrol Dial Transplant.* 1996; 11(Suppl 3):58–64. Epub 1996/01/01.
8. Carlini RG, Rojas E, Arminio A, Weisinger JR, Bellorin-Font E. What are the bone lesions in patients with more than four years of a functioning renal transplant? *Nephrol Dial Transplant.* 1998; 13(Suppl 3):103–4. Epub 1998/05/06.
9. Monier-Faugere MC, Mawad H, Qi Q, Friedler RM, Malluche HH. High prevalence of low bone turnover and occurrence of osteomalacia after kidney transplantation. *J Am Soc Nephrol.* 2000; 11(6):1093–9. Epub 2000/05/23. [PubMed: 10820173]
10. Cruz EA, Lugon JR, Jorgetti V, Draibe SA, Carvalho AB. Histologic evolution of bone disease 6 months after successful kidney transplantation. *Am J Kidney Dis.* 2004; 44(4):747–56. Epub 2004/09/24. [PubMed: 15384027]
11. Lehmann G, Ott U, Stein G, Steiner T, Wolf G. Renal osteodystrophy after successful renal transplantation: a histomorphometric analysis in 57 patients. *Transplant Proc.* 2007; 39(10):3153–8. Epub 2007/12/20. [PubMed: 18089342]
12. Rojas E, Carlini RG, Clesca P, Arminio A, Suniaga O, De Elguezabal K, et al. The pathogenesis of osteodystrophy after renal transplantation as detected by early alterations in bone remodeling. *Kidney Int.* 2003; 63(5):1915–23. Epub 2003/04/05. [PubMed: 12675872]
13. Mikuls TR, Julian BA, Bartolucci A, Saag KG. Bone mineral density changes within six months of renal transplantation. *Transplantation.* 2003; 75(1):49–54. Epub 2003/01/25. [PubMed: 12544870]
14. Brandenburg VM, Politt D, Ketteler M, Fassbender WJ, Heussen N, Westenfeld R, et al. Early rapid loss followed by long-term consolidation characterizes the development of lumbar bone mineral density after kidney transplantation. *Transplantation.* 2004; 77(10):1566–71. Epub 2004/07/09. [PubMed: 15239623]
15. Cruz DN, Wysolmerski JJ, Brickel HM, Gundberg CG, Simpson CA, Mitnick MA, et al. Parameters of high bone-turnover predict bone loss in renal transplant patients: a longitudinal study. *Transplantation.* 2001; 72(1):83–8. Epub 2001/07/27. [PubMed: 11468539]

16. Ball AM, Gillen DL, Sherrard D, Weiss NS, Emerson SS, Seliger SL, et al. Risk of hip fracture among dialysis and renal transplant recipients. *JAMA*. 2002; 288(23):3014–8. Epub 2002/12/17. [PubMed: 12479766]
17. Vautour LM, Melton LJ 3rd, Clarke BL, Achenbach SJ, Oberg AL, McCarthy JT. Long-term fracture risk following renal transplantation: a population-based study. *Osteoporos Int*. 2004; 15(2):160–7. Epub 2003/12/11. [PubMed: 14666400]
18. Patel S, Kwan JT, McCloskey E, McGee G, Thomas G, Johnson D, et al. Prevalence and causes of low bone density and fractures in kidney transplant patients. *J Bone Miner Res*. 2001; 16(10):1863–70. Epub 2001/10/05. [PubMed: 11585351]
19. Naylor KL, Li AH, Lam NN, Hodsman AB, Jamal SA, Garg AX. Fracture risk in kidney transplant recipients: a systematic review. *Transplantation*. 2013; 95(12):1461–70. Epub 2013/04/19. [PubMed: 23594857]
20. Ramsey-Goldman R, Dunn JE, Dunlop DD, Stuart FP, Abecassis MM, Kaufman DB, et al. Increased risk of fracture in patients receiving solid organ transplants. *J Bone Miner Res*. 1999; 14(3):456–63. Epub 1999/02/23. [PubMed: 10027911]
21. Stein EM, Shane E. Vitamin D in organ transplantation. *Osteoporos Int*. 2011; 22(7):2107–18. Epub 2011/01/06. [PubMed: 21207011]
22. KDIGO clinical practice guideline for the care of kidney transplant recipients. *Am J Transplant*. 2009; 9(Suppl 3):S1–155. Epub 2009/10/23.
23. Malluche HH, Monier-Faugere MC, Herberth J. Bone disease after renal transplantation. *Nat Rev Nephrol*. 2010; 6(1):32–40. Epub 2009/11/18. [PubMed: 19918255]
24. Evenepoel P, Naesens M, Claes K, Kuypers D, Vanrenterghem Y. Tertiary ‘hyperphosphatoninism’ accentuates hypophosphatemia and suppresses calcitriol levels in renal transplant recipients. *Am J Transplant*. 2007; 7(5):1193–200. Epub 2007/03/16. [PubMed: 17359508]
25. Sanchez Fructuoso AI, Maestro ML, Perez-Flores I, Valero R, Rafael S, Veganzones S, et al. Serum level of fibroblast growth factor 23 in maintenance renal transplant patients. *Nephrol Dial Transplant*. 2012; 27(11):4227–35. Epub 2012/11/13. [PubMed: 23144073]
26. Wolf M, Molnar MZ, Amaral AP, Czira ME, Rudas A, Ujszaszi A, et al. Elevated fibroblast growth factor 23 is a risk factor for kidney transplant loss and mortality. *J Am Soc Nephrol*. 2011; 22(5):956–66. Epub 2011/03/26. [PubMed: 21436289]
27. Malluche H, Lee J, Wang G, Herberth J, Faugere MC. Usefulness of the new TMv classification of renal osteodystrophy. *J Am Soc Nephrol*. 2008; 19:38A.
28. Moe S, Drueke T, Cunningham J, Goodman W, Martin K, Olgaard K, et al. Definition, evaluation, and classification of renal osteodystrophy: a position statement from Kidney Disease: Improving Global Outcomes (KDIGO). *Kidney Int*. 2006; 69(11):1945–53. Epub 2006/04/28. [PubMed: 16641930]
29. David-Neto E, Jorgetti V, Soeiro NM, Pereira RC, Borelli A, Ianhez LE, et al. Reversal of aluminum-related bone disease after renal transplantation. *Am J Nephrol*. 1993; 13(1):12–7. Epub 1993/01/01. [PubMed: 8322836]
30. Abdallah KA, Jorgetti V, Pereira RC, Reis LM, Pereira LM, Correa PH, et al. Improvement of adynamic bone disease after renal transplantation. *Braz J Med Biol Res*. 2006; 39(1):31–41. Epub 2006/01/10. [PubMed: 16400462]
31. Sampaio MS, Molnar MZ, Kovesdy CP, Mehrotra R, Mucsi I, Sim JJ, et al. Association of pretransplant serum phosphorus with posttransplant outcomes. *Clin J Am Soc Nephrol*. 2011; 6(11):2712–21. Epub 2011/10/01. [PubMed: 21959597]
32. Molnar MZ, Kovesdy CP, Mucsi I, Salusky IB, Kalantar-Zadeh K. Association of pre-kidney transplant markers of mineral and bone disorder with post-transplant outcomes. *Clin J Am Soc Nephrol*. 2012; 7(11):1859–71. Epub 2012/09/08. [PubMed: 22956265]
33. Epstein S. Post-transplantation bone disease: the role of immunosuppressive agents and the skeleton. *J Bone Miner Res*. 1996; 11(1):1–7. Epub 1996/01/01. [PubMed: 8770690]
34. Lukert BP, Raisz LG. Glucocorticoid-induced osteoporosis: pathogenesis and management. *Ann Intern Med*. 1990; 112(5):352–64. Epub 1990/03/01. [PubMed: 2407167]

35. Ugur A, Guvener N, Isiklar I, Turan M, Erdal R, Haberal M. Osteoporosis after renal transplantation: single center experience. *Transplantation*. 2001; 71(5):645–9. Epub 2001/04/09. [PubMed: 11292294]
36. Marcen R, Caballero C, Pascual J, Teruel JL, Tenorio M, Ocana J, et al. Lumbar bone mineral density in renal transplant patients on neoral and tacrolimus: a four-year prospective study. *Transplantation*. 2006; 81(6):826–31. Epub 2006/03/30. [PubMed: 16570003]
37. Grotz WH, Breitenfeldt MK, Braune SW, Allmann KH, Krause TM, Rump JA, et al. Calcineurin-inhibitor induced pain syndrome (CIPS): a severe disabling complication after organ transplantation. *Transpl Int*. 2001; 14(1):16–23. Epub 2001/03/27. [PubMed: 11263551]
38. Singha UK, Jiang Y, Yu S, Luo M, Lu Y, Zhang J, et al. Rapamycin inhibits osteoblast proliferation and differentiation in MC3T3-E1 cells and primary mouse bone marrow stromal cells. *J Cell Biochem*. 2008; 103(2):434–46. Epub 2007/05/23. [PubMed: 17516572]
39. Kneissel M, Luong-Nguyen NH, Baptist M, Cortesi R, Zumstein-Mecker S, Kossida S, et al. Everolimus suppresses cancellous bone loss, bone resorption, and cathepsin K expression by osteoclasts. *Bone*. 2004; 35(5):1144–56. Epub 2004/11/16. [PubMed: 15542040]
40. Ambrus C, Molnar MZ, Czira ME, Rosivall L, Kiss I, Rempfort A, et al. Calcium, phosphate and parathyroid metabolism in kidney transplanted patients. *Int Urol Nephrol*. 2009; 41(4):1029–38. Epub 2009/08/25. [PubMed: 19701690]
41. Akaberi S, Lindergard B, Simonsen O, Nyberg G. Impact of parathyroid hormone on bone density in long-term renal transplant patients with good graft function. *Transplantation*. 2006; 82(6):749–52. Epub 2006/09/29. [PubMed: 17006320]
42. van den Ham EC, Kooman JP, Christiaans ML, van Hooff JP. The influence of early steroid withdrawal on body composition and bone mineral density in renal transplantation patients. *Transpl Int*. 2003; 16(2):82–7. Epub 2003/02/22. [PubMed: 12595969]
43. Coco M, Glicklich D, Faugere MC, Burris L, Bognar I, Durkin P, et al. Prevention of bone loss in renal transplant recipients: a prospective, randomized trial of intravenous pamidronate. *J Am Soc Nephrol*. 2003; 14(10):2669–76. Epub 2003/09/30. [PubMed: 14514747]
44. Nowacka-Cieciura E, Cieciura T, Baczkowska T, Kozinska-Przybyl O, Tronina O, Chudzinski W, et al. Bisphosphonates are effective prophylactic of early bone loss after renal transplantation. *Transplant Proc*. 2006; 38(1):165–7. Epub 2006/03/01. [PubMed: 16504693]
45. Grotz W, Nagel C, Poeschel D, Cybulla M, Petersen KG, Uhl M, et al. Effect of ibandronate on bone loss and renal function after kidney transplantation. *J Am Soc Nephrol*. 2001; 12(7):1530–7. Epub 2001/06/26. [PubMed: 11423583]
46. Haas M, Leko-Mohr Z, Roschger P, Kletzmayer J, Schwarz C, Mitterbauer C, et al. Zoledronic acid to prevent bone loss in the first 6 months after renal transplantation. *Kidney Int*. 2003; 63(3):1130–6. Epub 2003/03/13. [PubMed: 12631097]
47. Torregrosa JV, Fuster D, Gentil MA, Marcen R, Guirado L, Zarraga S, et al. Open-label trial: effect of weekly risedronate immediately after transplantation in kidney recipients. *Transplantation*. 2010; 89(12):1476–81. Epub 2010/04/16. [PubMed: 20393402]
48. Schwarz C, Mitterbauer C, Heinze G, Woloszczuk W, Haas M, Oberbauer R. Nonsustained effect of short-term bisphosphonate therapy on bone turnover three years after renal transplantation. *Kidney Int*. 2004; 65(1):304–9. Epub 2003/12/17. [PubMed: 14675064]
49. Palmer SC, McGregor DO, Strippoli GF. Interventions for preventing bone disease in kidney transplant recipients. *Cochrane Database Syst Rev*. 2007; (3):CD005015. Epub 2007/07/20. [PubMed: 17636784]
50. Coco M, Pullman J, Cohen HW, Lee S, Shapiro C, Solorzano C, et al. Effect of risedronate on bone in renal transplant recipients. *J Am Soc Nephrol*. 2012; 23(8):1426–37. Epub 2012/07/17. [PubMed: 22797188]
51. Smerud KT, Dolgos S, Olsen IC, Asberg A, Sagedal S, Reisaeter AV, et al. A 1-year randomized, double-blind, placebo-controlled study of intravenous ibandronate on bone loss following renal transplantation. *Am J Transplant*. 2012; 12(12):3316–25. Epub 2012/09/06. [PubMed: 22946930]
52. Brandenburg VM, Floege J. Transplantation: An end to bone disease after renal transplantation? *Nat Rev Nephrol*. 2013; 9(1):5–6. Epub 2012/11/14. [PubMed: 23147757]

53. Kalantar-Zadeh K, Molnar MZ, Kovesdy CP, Mucsi I, Bunnapradist S. Management of mineral and bone disorder after kidney transplantation. *Curr Opin Nephrol Hypertens*. 2012; 21(4):389–403. Epub 2012/05/23. [PubMed: 22614626]
54. Josephson MA, Schumm LP, Chiu MY, Marshall C, Thistlethwaite JR, Sprague SM. Calcium and calcitriol prophylaxis attenuates posttransplant bone loss. *Transplantation*. 2004; 78(8):1233–6. Epub 2004/10/27. [PubMed: 15502727]
55. Torres A, Garcia S, Gomez A, Gonzalez A, Barrios Y, Concepcion MT, et al. Treatment with intermittent calcitriol and calcium reduces bone loss after renal transplantation. *Kidney Int*. 2004; 65(2):705–12. Epub 2004/01/14. [PubMed: 14717945]
56. De Sevaux RG, Hoitsma AJ, Corstens FH, Wetzels JF. Treatment with vitamin D and calcium reduces bone loss after renal transplantation: a randomized study. *J Am Soc Nephrol*. 2002; 13(6):1608–14. Epub 2002/06/01. [PubMed: 12039990]
57. Perez V, Sanchez A, Bayes B, Navarro-Munoz M, Lauzurica R, Pastor MC, et al. Effect of paricalcitol on the urinary peptidome of kidney transplant patients. *Transplant Proc*. 2010; 42(8):2924–7. Epub 2010/10/26. [PubMed: 20970572]
58. Bergua C, Torregrosa JV, Fuster D, Gutierrez-Dalmau A, Oppenheimer F, Campistol JM. Effect of cinacalcet on hypercalcemia and bone mineral density in renal transplanted patients with secondary hyperparathyroidism. *Transplantation*. 2008; 86(3):413–7. Epub 2008/08/14. [PubMed: 18698244]
59. Cejka D, Benesch T, Krestan C, Roschger P, Klaushofer K, Pietschmann P, et al. Effect of teriparatide on early bone loss after kidney transplantation. *Am J Transplant*. 2008; 8(9):1864–70. Epub 2008/09/13. [PubMed: 18786230]
60. Lertdumrongluk P, Lau WL, Park J, Rhee CM, Kovesdy CP, Kalantar-Zadeh K. Impact of age on survival predictability of bone turnover markers in hemodialysis patients. *Nephrol Dial Transplant*. 2013 Epub 2013/08/02.
61. Li J, Molnar MZ, Zaritsky JJ, Sim JJ, Streja E, Kovesdy CP, et al. Correlates of parathyroid hormone concentration in hemodialysis patients. *Nephrol Dial Transplant*. 2013; 28(6):1516–25. Epub 2013/01/26. [PubMed: 23348879]
62. Lukowsky LR, Molnar MZ, Zaritsky JJ, Sim JJ, Mucsi I, Kovesdy CP, et al. Mineral and bone disorders and survival in hemodialysis patients with and without polycystic kidney disease. *Nephrol Dial Transplant*. 2012; 27(7):2899–907. Epub 2011/12/31. [PubMed: 22207323]
63. Kovesdy CP, Kalantar-Zadeh K. Diuretics and secondary hyperparathyroidism in chronic kidney disease. *Nephrol Dial Transplant*. 2011; 26(4):1122–5. Epub 2011/04/05. [PubMed: 21460359]
64. Ayus JC, Negri AL, Kalantar-Zadeh K, Moritz ML. Is chronic hyponatremia a novel risk factor for hip fracture in the elderly? *Nephrol Dial Transplant*. 2012; 27(10):3725–31. Epub 2012/11/02. [PubMed: 23114899]
65. Miller JE, Molnar MZ, Kovesdy CP, Zaritsky JJ, Streja E, Salusky I, et al. Administered paricalcitol dose and survival in hemodialysis patients: a marginal structural model analysis. *Pharmacoepidemiol Drug Saf*. 2012; 21(11):1232–9. Epub 2012/09/22. [PubMed: 22996597]
66. Jeffery JR, Leslie WD, Karpinski ME, Nickerson PW, Rush DN. Prevalence and treatment of decreased bone density in renal transplant recipients: a randomized prospective trial of calcitriol versus alendronate. *Transplantation*. 2003; 76(10):1498–502. Epub 2003/12/06. [PubMed: 14657693]
67. Walsh SB, Altmann P, Pattison J, Wilkie M, Yaqoob MM, Dudley C, et al. Effect of pamidronate on bone loss after kidney transplantation: a randomized trial. *Am J Kidney Dis*. 2009; 53(5):856–65. Epub 2009/04/28. [PubMed: 19393473]
68. Huang WH, Lee SY, Weng CH, Lai PC. Use of alendronate sodium (Fosamax) to ameliorate osteoporosis in renal transplant patients: a case-control study. *PLoS One*. 2012; 7(11):e48481. Epub 2012/11/28. [PubMed: 23185261]
69. El-Agroudy AE, El-Husseini AA, El-Sayed M, Ghoneim MA. Preventing bone loss in renal transplant recipients with vitamin D. *J Am Soc Nephrol*. 2003; 14(11):2975–9. Epub 2003/10/22. [PubMed: 14569109]

70. Lopez V, Toledo R, Sola E, Gutierrez C, Suján S, Rodríguez MA, et al. Treatment with cinacalcet in 29 kidney transplant patients with persistent hyperparathyroidism. *Transplant Proc.* 2009; 41(6): 2394–5. Epub 2009/09/01. [PubMed: 19715930]
71. Cho ME, Duan Z, Chamberlain CE, Reynolds JC, Ring MS, Mannon RB. Cinacalcet improves bone density in post-kidney transplant hyperparathyroidism. *Transplant Proc.* 2010; 42(9):3554–8. Epub 2010/11/26. [PubMed: 21094814]
72. Copley JB, Germain M, Stern L, Pankewycz O, Katznelson S, Shah T, et al. Evaluation of cinacalcet HCl treatment after kidney transplantation. *Transplant Proc.* 2010; 42(7):2503–8. Epub 2010/09/14. [PubMed: 20832532]
73. Schwarz A, Merkel S, Leitolf H, Haller H. The effect of cinacalcet on bone remodeling and renal function in transplant patients with persistent hyperparathyroidism. *Transplantation.* 2011; 91(5): 560–5. Epub 2010/12/31. [PubMed: 21192318]

Figure 1A:

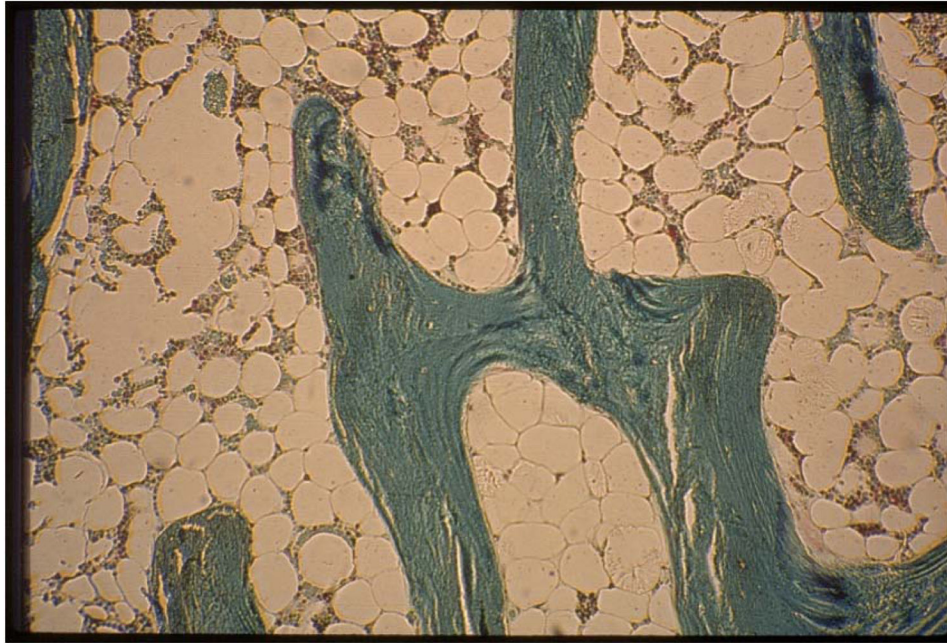


Figure 1B:

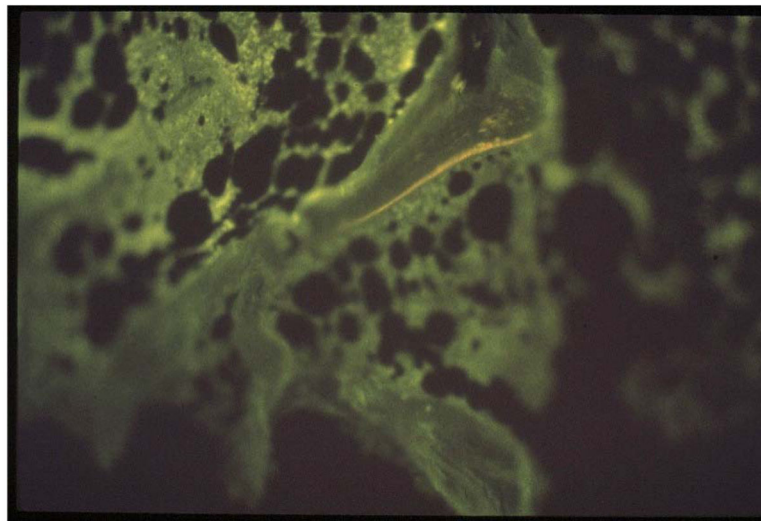


Figure 1.
Light microscopy (A) and tetracycline labeling (B) pictures of adynamic bone disease in a kidney transplant recipient

Table 1

Main characteristics of different type of mineral bone disease in kidney transplant recipients

Type of bone disease	Main characteristics	Potential harm effects
High turnover: Hyperparathyroid	It is characterized by marked increase in bone turnover, irregularly shaped trabecules displaying numerous abnormal remodeling sites, and an unusually high number of bone cells with irregular arrangement and shape	Increased risk of fracture? Increased risk of mortality and graft loss?
Low turnover: Adynamic	It is characterized by reduced bone volume, and mineralization is paralleled by a decrease in bone formation. It is also characterized by presence of few osteoid seams and few osteoblasts. Osteoclast number may be low, normal, or high.	Increased cardiovascular risk/ calcifications Increased risk of fracture?
Osteomalacia	It is characterized by accumulation of unmineralized matrix in which a decrease in mineralization precedes or is more pronounced than the inhibition of collagen deposition.	Increased risk of fracture? Increased risk of mortality and graft loss?
Mixed renal osteodystrophy	It is primarily caused by defective mineralization with or without increased bone formation and by increased parathyroid hormone activity in bone. These features coexist to varying degrees in different patients. Bone volume is extremely variable and depends on a dominant pathogenic cause. Other features of mixed uremic osteodystrophy include increased numbers of heterogeneous remodeling sites and, typically, an increase in osteoclast number.	Increased risk of fracture? Mortality and graft loss risk?

Author Manuscript

Author Manuscript

Author Manuscript

Author Manuscript

Table 2

Summary of the most important clinical trials and observational studies in renal transplant recipients

Trial	Type of study	Intervention	Number of patients	Outcome
Bisphosphonates				
Jeffery et al.(66), 2003	RCT	<i>Alendronate and calcium</i> vs calcitriol and calcium	117	One year of treatment with alendronate or calcitriol, both with calcium supplementation, resulted in significant increases in BMD. The average lumbar BMD increased from 0.984±0.149 to 1.025±0.143 g/cm ² with alendronate and from 1.014±0.15 to 1.034±0.146 g/cm ² with calcitriol. BMD at the femur increased from 0.809±0.092 to 0.836±0.107 g/cm ² with alendronate and from 0.830±0.144 to 0.857±0.125 g/cm ² with calcitriol.
Schwarz et al.(48), 2004 (follow up of study by Haas et al. (46), 2003)	RCT	<i>Zoledronate + calcium</i> vs placebo + Calcium	20	The early bone-sparing effect of short-term Zoledronate therapy confers no sustained benefit versus placebo at three year post-transplantation. Femoral neck bone mineral density z-scores increased statistically significantly from -1.3 (2.6) to -0.2 (3.6) in the placebo group and from -1.6 (2.9) to -1.2 (1.9) in the Zoledronate group.
Walsh et al.(67), 2009	RCT	<i>Pamidronate + calcium + Vit D</i> vs Calcium + Vit D	93	Lumbar spine BMD was preserved in the Pamidronate group and decreased in the control group. Pamidronate protected BMD at the lumbar spine; bone mineral density increased by 2.1% in the treatment group and decreased by 5.7% in the control group at 12 months. Protection was also seen in Ward's area of the hip and the total hip.
Grotz et al.(45), 2001	RCT	<i>Ibandronate + calcium</i> vs Calcium	72	BMD was preserved in the Ibandronate group and decreased in the control group. Changes of bone mineral density (ibandronate versus controls) were as follows: lumbar spine, -0.9±6.1% versus -6.5±5.4%; femoral neck, +0.5±5.2% versus -7.7±6.5%; and mid-femoral shaft, +2.7±12.2% versus -4.0±10.9%.
Torregrosa et al.(47), 2010	RCT	<i>Risedronate + calcium + Vit D</i> vs Calcium + Vit D	101	Administration of risedronate immediately after renal transplantation contributes to an improved BMD, particularly in the femoral neck at 6-months follow-up, without major side effects.
Smerud et al.(51)	RCT	<i>Ibandronate + calcium + calcitriol</i> vs calcium and calcitriol	129	Ibandronate demonstrated a significant improvement of BMD in total femur, +1.3% versus -0.5% (p = 0.01) and in the ultradistal radius, +0.6% versus -1.9% (p = 0.039)
Coco et al.(50)	RCT	<i>Risedronate + calcium + Calcitriol</i> vs Calcium + Calcitriol	42	Baseline and 12 months bone biopsy was done. Treatment with risedronate did not affect BMD in the overall cohort. In subgroup analyses, it tended to preserve BMD in female participants but did not significantly affect the BMD of male participants. Risedronate was associated with increased osteoid volume and trabecular thickness in male participants, however.
Huang et al.(68)	Case-controll	<i>Alendronate</i>	76	After a 14-month period, the BMD of lumbar spine increased significantly (from 0.9 g/cm ² to 0.92 g/cm ² , p<0.001), whereas that of the hip and femoral neck did not.

Trial	Type of study	Intervention	Number of patients	Outcome
Nowacka-Cieciura et al.(44), 2006	Observational	<i>Alendronate/Risedronate</i> vs drug free	66	BMD was preserved in treated group. Mean T-scores L(2)-L(4) in treatment group at 1, 6, and 12 months were: (-)2.22±1.06; (-)2.07±1.25; (-)1.89±1.07, respectively. The relative rise in BMD L(2)-L(4) between 1 and 12 months was 2.26%.
Vitamin D metabolites and vitamin D receptor activators				
El-Agroudy et al. (69), 2003	RCT	<i>Alfacalcidol</i> vs placebo	40	In the treated group BMD increased and PTH decreased, whereas BMD decreased in control group. In the treated group, BMD was increased by 2.1%, 1.8%, and 3.2% in the lumbar spine, femoral neck, and forearm, respectively, whereas in the control group it decreased by 3.2%, 3.8%, and 1.8% at the same sites.
Torres et al.(55), 2004	RCT	<i>Calcium + Calcitriol</i> vs Calcium	86	Therapy with low-dose calcium supplements during 1 year, plus intermittent calcitriol for 3 months after transplantation, is safe, decreases PTH levels more rapidly, and prevents bone loss at the proximal femur; a more pronounced effect is seen in recipients with at least one at-risk allele of the VDR genotype. Treated patients preserved their BMD at the total hip significantly better than those on placebo (3 months: 0.04±3.3 vs. -1.93±3.2%; 12 months: 0.32±4.8 vs. -2.17±4.4%); significant differences were noted at the inter-trochanter, trochanter, and Ward's triangle.
Perez et al.(57), 2010	RCT	<i>Paricalcitol</i> vs drug free	42	Profile of urinary peptides was changed due to treatment with paricalcitol.
Calcimimetics				
Lopez et al.(70), 2009	Observational	<i>Cinacalcet</i> vs drug free	29	Serum calcium decreased, whereas serum phosphate increased and PTH did not change.
Cho et al.(71), 2010	Observational	<i>Cinacalcet</i> vs drug free	23	Cinacalcet therapy was associated with significant reduction of serum calcium compared to controls. Cinacalcet therapy was associated with greater BMD increase at the hip over the 36-month post-transplant period.
Copley et al.(72), 2010	Observational	<i>Cinacalcet</i> vs drug free	41	Serum calcium and PTH decreased, whereas serum phosphate increased, but estimated GFR did not change.
Schwarz et al.(73), 2011	Observational	<i>Cinacalcet</i> vs drug free	58	Serum calcium, estimated GFR and PTH decreased, whereas serum phosphate increased.