

# UCSF

## UC San Francisco Previously Published Works

### Title

A pathophysiology-based approach to the management of early priapism.

### Permalink

<https://escholarship.org/uc/item/2zg0x2j0>

### Journal

Asian Journal of Andrology, 15(1)

### ISSN

1008-682X

### Authors

Kovac, Jason R  
Mak, Siu K  
Garcia, Maurice M  
[et al.](#)

### Publication Date

2013

### DOI

10.1038/aja.2012.83

Peer reviewed

## REVIEW

# A pathophysiology-based approach to the management of early priapism

Jason R Kovac<sup>1</sup>, Siu K Mak<sup>2</sup>, Maurice M Garcia<sup>3</sup> and Tom F Lue<sup>3</sup>

Priapism is a rare condition that involves persistent penile erection for greater than 4 h. Distinct variants exist, each with unique characteristics. Ischemic priapism is a painful medical emergency that may occur as a result of veno-occlusion leading to hypoxia and tissue death. Recurrent bouts of ischemic priapism, or stuttering priapism, require treatment for individual attacks as well as long-term prevention. Non-ischemic priapism is associated with trauma and may be managed conservatively. Recent advances into the pathophysiology of priapism have allowed the development of treatment algorithms that specifically target the mechanisms involved. In this review, we outline the basics of smooth muscle contraction and describe how derangement of these pathways results in priapism. A pathophysiological approach to the treatment of priapism is proposed with duration-based algorithms presented to assist in management.

*Asian Journal of Andrology* (2013) 15, 20–26; doi:10.1038/aja.2012.83; published online 3 December 2012

**Keywords:** algorithm; ischemic; management; priapism; T-shunt; tunneling

## INTRODUCTION

First described in 1845,<sup>1</sup> priapism is defined as an erection that continues for longer than 4 h either related to, or separated from, sexual activity.<sup>2</sup> As a result, the mechanisms which underlie smooth muscle contraction, and thus the basics of erectile physiology, are fundamentally altered. Ischemic, non-ischemic and recurrent/stuttering variants exist; however, the underlying pathophysiology involved is not completely understood. The need for a clear management strategy in dealing with acute, as well as delayed presentations is essential. By combining what is known about erectile physiology in both health and disease, we propose a pathophysiology-based approach to the management of priapism.

Ischemic priapism is the most common type and constitutes a medical emergency requiring urgent treatment.<sup>3,4</sup> Recurrent, or stuttering priapism, is an ischemic variant whose prevalence depends on the population studied since it typically occurs in patients with sickle cell disease (SCD).<sup>3,5</sup> The basis underlying the ischemic variant is obstruction of the penile venous outflow and stasis which results in hypoxia and microvascular thrombosis of the corpora cavernosa.<sup>6</sup> On a molecular level, decreases in phosphodiesterase (PDE) 5<sup>7</sup> and RhoA/Rho kinase<sup>8</sup> contributes to cavernous smooth muscle paralysis and resultant priapism.

In all cases, management begins with a proper history and physical examination. Ischemic priapism is painful with rigid corpora cavernosa that are tender to palpation.<sup>2</sup> A history of repeated episodes suggests a recurrent priapism. In these situations, colour duplex ultrasound identifies a veno-occlusive, no-flow state.<sup>9</sup> Cavernosal blood gases may also be obtained with pO<sub>2</sub>, pCO<sub>2</sub> and pH values of <30 mmHg, >60 mmHg and <7.25, respectively.<sup>2</sup> Initial management involves evacuation of stagnant blood from the corporal bodies followed by injection of

diluted phenylephrine.<sup>2</sup> Traditionally, surgical shunts were only considered following failure of these initial interventions.<sup>2</sup> Previous algorithms have suggested the caverno-glanular shunt as first choice treatment with either a large biopsy needle (Winter shunt), a scalpel (Ebbehøj shunt) inserted through the glans or surgical creation of a shunt (Al Ghorab shunt). Resolution rates of 66% and 73%, respectively have been reported;<sup>2</sup> however, the time to intervention was not previously considered, or reported. Moreover, distal shunts have difficulty in draining the proximal aspect of the penis which leads to poor results in episodes that have lasted for long duration. Indeed, in some of our previous experiences, patients presenting with priapism of duration >24 h experienced long delays during treatment.<sup>10</sup> Patients were usually initially given repeated irrigations and phenylephrine injections followed by smaller, less invasive shunts that eventually proved unsuccessful.<sup>10</sup> One is led to wonder that if immediate resolution could be obtained, would erectile function be preserved? A recently published study has detailed that in ischemic priapism episodes of long duration, shunts are effective in achieving flaccidity.<sup>11</sup> The resultant tissue damage was irreversible and placement of a penile prosthesis was recommended.<sup>11</sup> Indeed, given that the adverse outcomes of priapism are partially related to delayed recognition and failure to institute immediate management, an improvement in the current treatment algorithm may improve outcomes.

Non-ischemic priapism was first described in 1960 and is almost exclusively the result of perineal or penile trauma.<sup>3,12</sup> The resultant disruption of the cavernous artery<sup>13</sup> may evoke an immediate, or more frequently, delayed (up to 72 h) priapism.<sup>14</sup> The primary mechanism by which this variant occurs is excessive and unregulated arterial inflow into the sinusoids of the corpora cavernosa.<sup>13</sup> Primary management

<sup>1</sup>Scott Department of Urology, Baylor College of Medicine, Houston, TX 77030, USA; <sup>2</sup>The Chinese University of Hong Kong, Department of Surgery, Prince of Wales Hospital, Hong Kong, China and <sup>3</sup>Department of Urology, University of California, San Francisco, CA 94143, USA  
Correspondence: Dr TF Lue (tlue@urology.ucsf.edu)

Received: 11 July 2012; Revised: 11 August 2012; Accepted: 11 September 2012; Published online: 3 December 2012

has traditionally been observation with arteriography and embolization preferred for those who do not spontaneously resolve.<sup>2</sup> Recent work has postulated that the initial trauma-induced damage may be worsened by sleep-related erections (SREs) that rupture the cavernous artery or its branches.<sup>13</sup> Indeed, treatment with androgen blockade to suppress SREs has been successful in resolving non-ischemic priapism with minimal consequences.<sup>13</sup>

Limited attention has been placed upon elucidating the pathophysiology and molecular effects occurring both during, and after, episodes of priapism. As such, therapies based on the actual mechanisms are limited.<sup>8</sup> In this review, we discuss smooth muscle physiology and propose algorithms for treatment with an emphasis on the pathophysiological basis underlying the ischemic and non-ischemic priapism.

## SMOOTH MUSCLE PHYSIOLOGY

Penile corpora cavernosa are specialized vascular structures that consist of trabeculated smooth muscle as well as an extracellular matrix of collagen and elastin. Endothelial and neuronal cells regulate penile responses through a balance of smooth muscle contraction (flaccidity) and relaxation (erection).<sup>15</sup> Contraction occurs *via* sympathetic neural input through release of noradrenaline from nerve terminals in a tonic fashion. The resultant binding to  $\alpha$ 1-adrenergic receptors on smooth muscle increases activity of phospholipase C which converts phosphatidylinositol bisphosphate to inositol triphosphate and diacylglycerol. Inositol triphosphate then binds to receptors on the sarcoplasmic reticulum to release calcium ( $\text{Ca}^{2+}$ ) and diacylglycerol acts on protein kinase C<sup>15,16</sup> to open L-type  $\text{Ca}^{2+}$  channels,<sup>17</sup> leading  $\text{Ca}^{2+}$  influx from the extracellular milieu<sup>18</sup>—common pathways seen in several different types of smooth muscles.<sup>17,18</sup> Intracellular  $\text{Ca}^{2+}$  binds to calmodulin forming a complex that activates myosin light chain kinase to phosphorylate the myosin light chain (MLC) of myosin II allowing the associated ATPase to be activated by actin for contraction.<sup>16</sup>

Interestingly, intracellular  $\text{Ca}^{2+}$  concentrations do not equal MLC phosphorylation and contraction strength. Indeed, sensitization of the contractile apparatus may contribute to sustained contractions at fixed  $\text{Ca}^{2+}$  concentrations; a process known as  $\text{Ca}^{2+}$  sensitization.<sup>19–21</sup> Agonist activation of certain G-protein-coupled receptors activates RhoA that then interacts with Rho kinase (of which there are two isoenzymes: ROCK1 and ROCK2) leading to inhibition of MLC phosphatase activity.<sup>19,22</sup> Indeed, specific Rho kinase inhibitors like Y27632 have been shown to cause an increase in corpora cavernosa pressure as well as erections independent of nitric oxide (NO, see below).<sup>21</sup>

Erection is dependent on the parasympathetic system in which NO is the principle neurotransmitter. NO is released from the cavernosal vascular endothelium or parasympathetic nerve endings.<sup>15</sup> Once diffused into smooth muscle cells, NO stimulates guanylate cyclase (GC) to convert guanosine triphosphate into cyclic guanosine monophosphate (cGMP).<sup>24</sup> Through protein kinase G, cGMP decreases  $\text{Ca}^{2+}$  to cause smooth muscle relaxation. cGMP is inactivated by the PDE enzyme.<sup>16</sup> The most important PDE isoenzyme in the penis is PDE5.<sup>25,26</sup> Decreases in intracellular  $\text{Ca}^{2+}$  inactivate myosin light chain kinase allowing dephosphorylation of the light chain by MLC phosphatase resulting in relaxation.<sup>16</sup>

Adenosine is another potent vasodilator contributing to erection that has recently been implicated in priapism.<sup>27</sup> Adenosine acts directly on the smooth muscle cells of corpora cavernosa *via* cell surface  $\text{A}_{2\text{B}}$  receptors. These G-protein-coupled receptors stimulate adenylyl cyclase and increase intracellular cyclic adenosine monophosphate.<sup>27</sup> Subsequent protein kinase A activation decreases  $\text{Ca}^{2+}$ -calmodulin-dependent MLC phosphorylation causing relaxation

and erection. Adenosine has also been shown to act through adjacent endothelial cells to stimulate NO production. The resultant diffusion to cavernosal smooth muscle cells activates GC to raise cGMP resulting in further relaxation and erection.<sup>27</sup>

## ISCHEMIC PRIAPISM

### Epidemiology

Ischemic priapism has been previously referred to as penile compartment syndrome. Overall, ischemic priapism has an overall incidence of 1.5 cases per 100 000 person years.<sup>28</sup> Being the most common of the priapism variants, it accounts for ~95% of all diagnosed episodes<sup>3</sup> with a significant portion due to the intracavernosal injections used to treat erectile dysfunction.<sup>5</sup>

### Pathogenesis

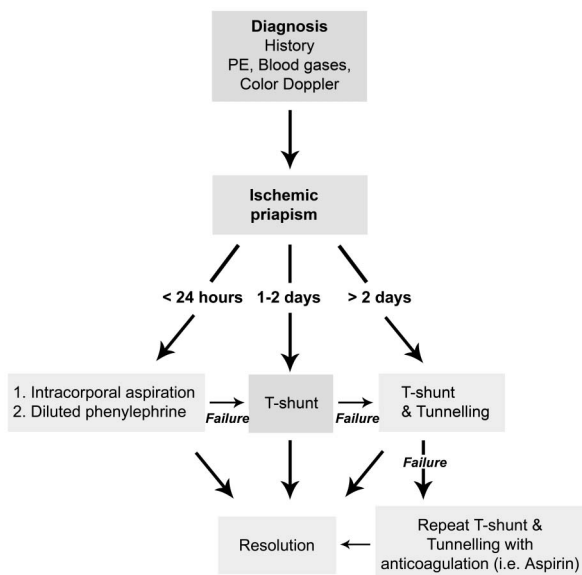
The pathogenesis of ischemic priapism can be the result of venous outflow occlusion and the resultant cessation of arterial inflow. Iatrogenic smooth muscle relaxation *via* intracavernosal injection contributes; however, multiple factors play a role. For example, as first described by Klein *et al.*,<sup>29</sup> priapism may be induced by total parenteral nutrition.<sup>30</sup> Elevated concentrations of fats and lipids in emulsion along with increased platelet activity result in erythrocyte aggregation and adhesion along with the creation of *in vivo* aggregates which subsequently embolize.<sup>29,30</sup> Occlusion of venous outflow creates an acidotic and hypoxic environment that eventually results in cellular destruction. Indeed, smooth muscle tissue strips and cultured smooth muscle cells, when exposed to hypoxic conditions, exhibit significant decreases in contractility<sup>31</sup> and apoptosis.<sup>32</sup> However, a proportion of cases are not caused by venous occlusion but rather deregulation of molecular factors that may affect erectogenic tissue responses.

On a molecular level, when erectile tissue ultrastructure is examined with histological studies, damage appears to be time-dependent.<sup>33</sup> During the early stages (<12 h) of priapism, interstitial edema and thickening predominate.<sup>33</sup> After 24 h have elapsed, cavernous muscle necrosis and fibroblast proliferation are observed.<sup>33</sup> The combination of endothelial destruction and corpus cavernosum fibrosis leads to erectile dysfunction.<sup>33</sup> No treatment algorithm has taken into account these pathophysiological changes with time.

Cavernosal smooth muscle and vascular endothelial cells are affected. A significant source of NO, the vascular endothelium is critical in the regulation of smooth muscle tone in general, and penile erection in particular.<sup>8</sup> In cases of NO deregulation, smooth muscle contraction is altered. Indeed, in response to stimulation of the cavernous nerve, endothelial nitric oxide synthase knockout mice exhibit exaggerated erectile responses.<sup>34</sup> Transgenic SCD mice also demonstrated enhanced erectile response with an increased frequency of spontaneous erections compared to wild-type mice.<sup>35</sup> Furthermore, in these SCD mice, RhoA and its downstream effector, Rho kinase had significantly reduced activities. Specifically, ROCK2 protein expression (a Rho kinase isotype) was reduced and ROCK1 was unchanged.<sup>35</sup>

### Management

In our algorithm, history and physical examination is combined with initial imaging, if available, and blood gases to determine the type of priapism involved. In ischemic priapism (**Figure 1**), the history is consistent with progressive penile pain. Past medical history and medications should also be assessed and a physical examination involving inspection and palpation of penis to assess the extent and degree of pain and penile rigidity is critical. Urine for toxicology and a sickle cell screen are optional. Color Doppler ultrasound to examine flow in



**Figure 1** Pathophysiology and duration based algorithm for the treatment of ischemic priapism. A supplementary video of the T-Shunt and Tunnelling procedure can be accessed at the Asian Journal of Andrology's website (<http://www.nature.com/aja>). PE, physical exam.

the cavernous arteries both prior to and following treatment is very helpful.<sup>4</sup> The ultrasound is a key component in that it clearly demonstrates the lack of blood flow to the corpora in ischemia priapism.<sup>36</sup> Assessment of penile blood gases will yield values of:  $pO_2 < 30$  mmHg,  $pCO_2 > 60$  mmHg and  $pH < 7.25$  in ischemic cases.

Once it has been determined that the patient has an ischemic priapism of less than 24-h duration, our algorithm states that the initial management should involve evacuation of old blood and injection of diluted phenylephrine (Figure 1). In these cases, evacuation alone may resolve the priapism in 36%.<sup>3</sup> Diluted phenylephrine is the agent of choice since it is  $\alpha 1$ -adrenergic receptor selective with minimal ionotropic and chronotropic effects.<sup>2</sup> However, in patients with hypertension and heart disease, continuous vital signs monitoring during administration is important.<sup>37,38</sup> Phenylephrine is diluted in normal saline to a concentration of  $500 \text{ mcg ml}^{-1}$  and given in 1-ml dose every 3–5 min until the penis has detumesced or 60 min has elapsed.<sup>2</sup>

There is no sufficient evidence that aspiration followed by saline irrigation is more effective than aspiration alone.<sup>2</sup> One study describes 100% success if procedure is used within 12 h of the onset of priapism.<sup>39</sup> It is hypothesized that the decreased efficiency noted with longer durations is probably the result of impaired smooth muscle response due to hypoxia and acidosis<sup>40</sup> as discussed above. Indeed, if on history, the duration of erection is between 1–2 days, hypoxic damage to the muscle has already occurred leading to poor smooth muscle response to phenylephrine. Previous studies have concluded that priapism episodes of greater than 24 h were associated with a 90% rate of erectile dysfunction.<sup>41–43</sup> Further work<sup>39</sup> identified a 92% chance that erectile function could be preserved if the priapism episode lasted less than 24 h—with results worsening with increased time.<sup>39,43</sup> Thus, as per our algorithm (Figure 1), recommended management for an ischemic priapism episode of  $> 24$  h is to proceed directly to a surgical T-shunt. The T-shunt creates a wide and patent shunt that is simple and easy to perform under local anaesthesia.<sup>10</sup>

The primary objective is to reestablish corporal blood flow and reoxygenation with removal of old blood *via* creation of a fistula

between the corpus cavernosum and the glans. The T-shunt is a distal shunt that is easy to perform and yields excellent results.<sup>4,5</sup> Described in brief here, and in the initial portions of the supplementary video, a #10 blade scalpel is inserted through glans penis into the ipsilateral corpus cavernosum. The blade is inserted until the hub of the scalpel contacts the glans penis. It is then rotated  $90^\circ$  laterally, away from the urethra, before pulling out, to create a large fistula. A #10 blade is preferred as previous experience has found the #11 blade to be too small with potential to close spontaneously.<sup>10</sup> A 4-0 chromic suture closes the skin and the patient is observed for 15–30 min.<sup>10</sup> If the priapism resolves, the patient can be discharged but if the priapism recurs, the procedure should be repeated on the other side (the TT-shunt).

This type of distal cavernoglanular shunt is the first choice for shunting procedures following failed intracorporeal aspiration and phenylephrine irrigation, given its less invasive nature and good success rates.<sup>43</sup> We also suggest its immediate use in priapism cases of 24–36 h duration. While the authors prefer the immediate use of the T-shunt and have found it to have the best chance of success, the current American Urological Association guidelines still suggest the initial use of aspiration, irrigation and phenylephrine.<sup>2</sup> Furthermore, the Winter shunt or Ebbehoj technique have also been described as minimally invasive, distal, percutaneous shunts.<sup>43</sup> Characterized by placement of a large-bore needle or angiocatheter into the distal glands and corpus cavernosum, the Winter shunt is minimally invasive but carries with it a high failure rate.<sup>43</sup> The Ebbehoj technique consists of a simple straight incision into the corpora cavernosa and spongiosum through the distal glans.<sup>43</sup> The Al-Ghorab shunt has also been described as an open corporoglanular shunt in which one excises a circular cone of distal tunica albuginea allowing a large shunt to be created.<sup>43</sup> However, according to historical beliefs, open distal shunting should only be considered if percutaneous shunting (i.e., T-shunt or Winter shunt) fails.<sup>43</sup>

In our experiences however, in cases of TT shunt failure, or if the priapism has been present for longer than 2–3 days, we suggest to proceed directly to bilateral T-shunts followed by insertion of a 20–22 French urethral sound or dilator through the glandular incisions into the ipsilateral corpus cavernosum (i.e., tunnelling) (Figure 1, Supplementary surgery video). Typically, old blood will ‘ooze out’ rather than ‘gush out’ after the scalpel is pulled out of the penis indicative of severe tissue edema/death of the entire corpora cavernosa. The tunnel allows blood to flow from the proximal to the distal end of the penis to keep the shunt open.<sup>44</sup> The entire procedure is detailed, along with the initial steps, in the appended video. The video details the placement of bilateral T-shunts in an episode of priapism which has been present for 3 days. It is important to note that we do not advocate for bilateral shunts in erections present  $< 2$  days since, during this initial period of time, a unilateral T-shunt may render the penis immediately flaccid. If this happens, the bilateral T-shunt should not be placed given the increased risk of urethral injury. Indeed, in all cases, the placement of a bilateral T-shunt in a flaccid penis should be avoided. Our institution reserves the placement of immediate bilateral T-shunts for erections present for  $> 2$  days only.

A similar technique has been previously described by Burnett and Pierorazio.<sup>45</sup> This procedure, known as the ‘corporal snake’, is a modified Aj-Ghorab shunt that involves passage of a 7/8 Hegar dilator proximally through the excised tunical windows for ‘several centimeters’.<sup>43,45</sup> In the past 6 years, we have treated more than 50 patients with our T-shunt and tunnelling procedure. Resolution of priapism is quick with minimal penile pain (Supplementary surgery video). We have previously reported success with this procedure in the recovery of

erectile function;<sup>10</sup> however, this return of function occurs to varying degrees. While we anticipate that this management strategy will make proximal shunts unnecessary, further follow-up needs to be conducted to properly determine the outcomes of this procedure—research that is currently being conducted.<sup>4,10</sup>

With respect to postoperative management, the patient should periodically squeeze penis within first 24 h to ensure that it remains patent. Compressive dressings should be avoided because they may impede the blood flow through the dorsal veins resulting in recurrence. Glans suture sites are dressed with antibiotic ointment for 5 days.<sup>10</sup> The presence of hematuria may suggest a urethral injury which can be managed by placement of a urethral catheter for several days with concurrent administration of antibiotics.<sup>10</sup> Some authors have advocated the immediate placement of a penile prosthesis in patients with ischemic priapism of long duration owing to the difficulty of placing these prostheses after corporal fibrosis has occurred.<sup>46,47</sup>

## RECURRENT (STUTTERING) PRIAPISM

### Epidemiology

Recurrent, or stuttering priapism, is an ischemic variant that repeats over time and is distinct from single episodes that do not resolve.<sup>2</sup> First described in 1914,<sup>6</sup> prevalence is influenced by the population studied. Patients with SCD are most commonly affected with a prevalence exceeding 40%.<sup>48</sup> Indeed, the probability that a man with SCD will experience priapism by the age of 20 is 89%.<sup>49</sup> Given erectile dysfunction rates of 30% as a result of these recurrent episodes,<sup>50</sup> a treatment plan for prevention is just as important as dealing with the single episodes.

### Pathogenesis

As a result of sexual stimulation, NO is synthesized from both neuronal and endothelial cells.<sup>15</sup> Following diffusion into corporal smooth muscle cells, NO activates GC converting guanosine triphosphate to cGMP resulting in relaxation that is attenuated by PDE5 acting to degrade cGMP.

Recent work has identified the PDE5 regulatory system as contributing to priapism.<sup>7,24–26,50–53</sup> In cases of recurrent ischemic events, endothelial NO as well as PDE5 activity is downregulated.<sup>26</sup> Thus, at baseline, there is less NO and cGMP produced causing lower basal PDE5 function. In situations of prolonged sexual stimulation or during SREs, there is a surge of NO and cGMP that overwhelms the now reduced PDE5 set-point causing excessive tissue relaxation.<sup>25</sup>

Use of PDE5 inhibitors in this setting can restore a normal PDE5 balance<sup>50</sup> by elevating basal cGMP to progressively reestablish PDE5 expression and activity.<sup>51</sup> In a mouse model, PDE5 inhibitor treatment successfully reduced priapism episodes and normalized PDE5 gene activity.<sup>51</sup> Furthermore, long-term use of PDE5 inhibitors alleviated recurrent episodes without compromising normal erections.<sup>53</sup>

Other factors that have been found to contribute to recurrent bouts of priapism include the use of heparin—an effect that may be due to a rebound that occurs following withdrawal of anticoagulants resulting in thrombosis.<sup>14</sup> Furthermore, heparin has also been found to significantly decrease NO production in human cells which may reset the erectile function cascade as describe above.<sup>54</sup> Moreover, patients with SCD have sickled hemoglobin which results in premature breakdown of the red blood cell.<sup>55</sup> As identified *via* lipid peroxidation, oxidative stress occurs in the penis during and following completion of priapism episodes.<sup>8</sup> Furthermore, following these periods of hypoxia, reperfusion with resultant intravascular hemolysis releases hemoglobin and further causes significant increases in reactive oxygen species.<sup>8</sup> These reactive oxygen species then act to scavenge NO, removing it from

circulation.<sup>55</sup> This depletion of NO yields a blunted vasodilatory response along with higher levels of platelet and coagulation factor activation.<sup>55</sup> The subsequent vasoconstriction and occlusion leads to ischemia and tissue damage.<sup>55,56</sup>

As detailed in a recent review by Bivalacqua *et al.*<sup>56</sup> and mentioned here in brief, recent advances have identified multiple potential mechanisms for recurrent ischemic priapism beyond that of simple hemolysis.<sup>56</sup> For example, upregulation of the hypoxia-inducible growth factor, transforming growth factor-beta (TGF- $\beta$ ) has been shown to occur during hypoxia and in response to oxidative stress.<sup>57</sup> Indeed, prolonged erections in an animal model result in penile TGF- $\beta$  upregulation.<sup>58</sup> TGF- $\beta$  is critical to tissue repair, and has a role in collagen synthesis and fibrosis and induces tissue damage and scarring.<sup>8,59</sup> TGF- $\beta$  may thus act as the cornerstone of priapism-evoked erectile dysfunction, facilitating the progression of corporal tissue to overt fibrosis following recurrent ischemic episodes.

Adenosine also contributes to smooth muscle excitation and accumulates under the hypoxic conditions that occur during priapism.<sup>27,60</sup> These elevations cause increases in cyclic adenosine monophosphate and protein kinase A activation through cell surface A<sub>2B</sub> receptors culminating in decreased intracellular Ca<sup>2+</sup> and relaxation.<sup>27</sup> In addition, adenosine, through endothelial cells, increases NO release. The result is a synergistic effect that contributes to ischemic priapism. Indeed, mouse models of SCD that exhibit recurrent episodes of priapism, have significantly elevated levels of adenosine compared to controls.<sup>61</sup> Adenosine is converted to the inactive molecule inosine *via* deamination by adenosine deaminase. In adenosine deaminase-deficient mice, the high levels of adenosine result in widespread receptor activation and recurrent priapism.<sup>27</sup> Treatment with polyethylene glycol-modified adenosine deaminase, an enzyme replacement therapy that regulates adenosine levels, resolves priapism episodes suggesting a contribution of adenosine to recurrent priapism.<sup>27</sup>

A novel family of peptides, opiorphins, have also recently been demonstrated to contribute to the regulation of penile smooth muscle tone and development of priapism.<sup>56</sup> Overexpression of the genes encoding opiorphins resulted in increased corporal smooth muscle relaxation,<sup>62</sup> enhanced erectile function and priapism-like outcomes.<sup>63,64</sup> Furthermore, intracorporal gene transfer of plasmids expressing opiorphins was shown by microarray to upregulate the ornithine decarboxylase gene.<sup>65</sup> Subsequent treatment of animals with an ornithine decarboxylase inhibitor prevented priapism evoked by opiorphin overexpression, suggesting a direct link and highlighting a novel pathway in recurrent priapism which may be modulated in the future to aid in treatment.<sup>56,65</sup>

### Management

The standard treatment recommendations are that each episode of recurrent priapism be managed as an individual ischemic attack. As such, the focus of management in patients afflicted with recurrent priapism is to prevent occurrences. Furthermore, the treatment should be efficient, safe and easy so as to improve patient compliance. In general, therapies for recurrent priapism may be classified into local or systemic.

The favored local therapy is intracavernosal injection of diluted phenylephrine.<sup>37</sup> The patients, if reliable and intelligent, can perform this at home.<sup>37</sup> Several studies have shown that this is an effective treatment<sup>66,67</sup> but not ideal since priapism is treated, rather than prevented.<sup>2</sup>

A multitude of systemic therapies exist including use of hydroxyurea, gabapentin, digoxin and estradiol; however, good evidence for their use is still lacking.<sup>5</sup> Baclofen, a gamma-aminobutyric acid



derivative that treats skeletal muscle spasms has also been used (at 40 mg once daily) to treat recurrent priapism in patients with neurologic lesions.<sup>68</sup> Antiandrogens or gonadotropin releasing hormones (GnRH agonists) have been used to prevent erections, but prolonged hypogonadism, reduced libido, fatigue, gynecomastia and embolism risks exist.<sup>2,5</sup> In a recent study,<sup>69</sup> 35 patients with recurrent priapism secondary to SCD were given finasteride for 3 months with a significant reduction in priapism recurrences.<sup>69</sup> While effective, androgen ablation is unsafe in young boys given its effects on sexual development.<sup>5</sup>

Following the identification of PDE5 deregulation as a mechanism for recurrent priapism,<sup>34</sup> a strategy for prevention by use of PDE5 inhibitors was pioneered.<sup>50,53</sup> In early studies, PDE5 inhibitors (sildenafil or tadalafil) alleviated priapism recurrences in six of the seven patients.<sup>53</sup> Medications were taken in the mornings under conditions of complete flaccidity and patients abstained from sexual activity for 8 h. Follow-up showed erectile function to be unchanged at 2 years. Recurrences did occur but only in patients who stopped treatment believing that their conditions were cured.<sup>53</sup>

## NON-ISCHEMIC PRIAPISM

### Epidemiology and pathogenesis

Non-ischemic, or high-flow, priapism was first described in 1960 and is almost exclusively the result of perineal or penile trauma.<sup>3,12,70</sup> Rarer than ischemic priapism, it is largely due to trauma lacerating either the small helicine artery or the large cavernous artery. Given that venous channels remain competent, the pain is not significant.<sup>70</sup> Following injury, nocturnal or sexual erections rupture the damaged artery, leading to unregulated arterial inflow into the sinusoidal space<sup>13</sup> and a persistent partial erection<sup>70</sup> with eventual formation of a fistula between the artery and lacunar spaces of the cavernous tissue.<sup>9,71,72</sup>

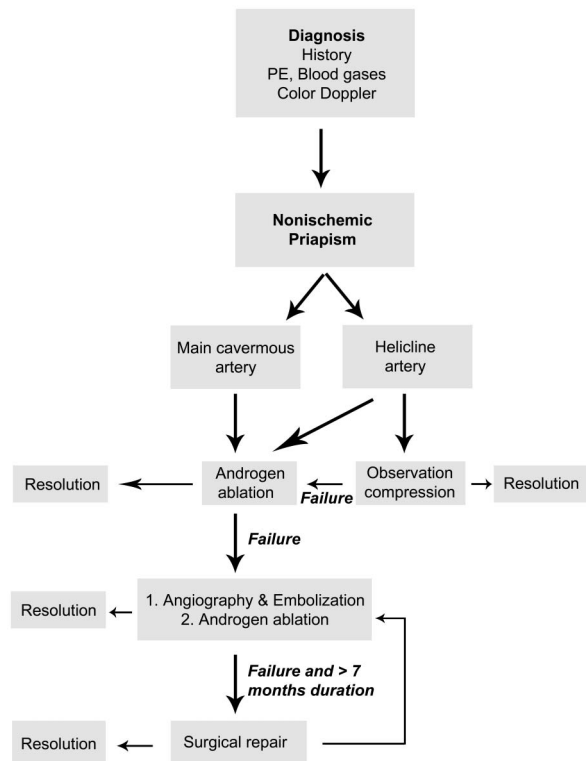
### Management

On history, there should be no pain since tissue ischemia and necrosis does not occur. Physical examination reveals a non-tender, tumescent or partially erect penis. Perineal bruising may be identified in the setting of a straddle injury or blunt penile trauma. Presentation may be immediate, or more frequently, delayed (up to 72 h).<sup>14</sup> Color Doppler ultrasound of the entire penis, including the crura, should be conducted in all cases of suspected high-flow priapism<sup>70</sup> to identify a high flow rate in the cavernous arteries. Corporal aspiration should yield values of  $pO_2 > 90$  mmHg,  $pCO_2 < 40$  mmHg and  $pH > 7.25$ .

Since non-ischemic priapism does not cause end-organ damage, some have advocated conservative management with rest, time and ice;<sup>73</sup> however, in our experience, this rarely proves successful. Traditionally, arteriography followed by embolization has been the preferred treatment.<sup>2</sup> First reported in 1977,<sup>38</sup> embolization can be performed with substances including gel foam, coils, autologous blood clot and microcoils.<sup>5</sup> Success rates are 73%–89% with a 20%–25% incidence of erectile dysfunction being reported.<sup>5</sup>

Recent work has postulated that the initial trauma-induced damage may be worsened by SREs that rupture the cavernous artery or its branches.<sup>13</sup> Indeed, treatment with androgen blockade in the form of leuprolide, bicalutamide and ketoconazole is used to suppress SREs<sup>13</sup> and resolve cases of non-ischemic priapism with minimal side effects.<sup>13</sup>

Based on the known literature and pathophysiology, we have developed an algorithm for treatment of non-ischemic priapism (Figure 2). Initially, Doppler ultrasound is used to determine the blood vessels involved in the trauma. In cases of helicine artery



**Figure 2** Pathophysiological algorithm for the treatment of non-ischemic priapism. PE, physical exam.

rupture, the injury is usually small and amendable to conservative treatment. However, if conservative treatment fails, or the ultrasound reveals a more severe main cavernous artery rupture, we immediately begin androgen ablation to prevent SRE. This should allow the spontaneous closure of these ruptures and subsequent resolution of the non-ischemic, high flow, priapism. If this is successful, it would obviate the need for more invasive and risky procedures such as embolization. Surgical repair would only be considered in cases of long duration (at least 7 months) when a pseudo-capsule has formed. In all cases, erectile tissues become injured and we thus recommend the use of an antifibrotic agent such as pentoxifylline for 3 months to reduce fibrosis.<sup>70</sup>

## DISCUSSION

Variants of priapism exist including ischemic and non-ischemic types. Ischemic priapism leads to hypoxia and tissue death requiring immediate intervention. Traditionally, patients presenting with ischemic priapism of >24 h experienced long delays in treatment. Repeated injections of phenylephrine and saline irrigation further deferred definitive management. If immediate resolution could be achieved, perhaps the outcomes of ischemic priapism could be improved. As such, we propose an algorithm in which patients presenting with an ischemic priapism of >24 h proceed directly to T-shunt and >48 h have the T-shunt followed up with bilateral tunnelling (Supplementary video). Non-ischemic priapism is typically associated with trauma. Modalities in the treatment algorithm include primary conservative management, which, if not successful, it can be followed with androgen ablation to prevent SRE and angiography with embolization.

In this review, we outline the basics of smooth muscle contraction and describe how derangement of these pathways results in priapism. A

pathophysiological approach to the treatment of priapism is proposed with duration-based algorithms presented to assist in management.

## COMPETING FINANCIAL INTERESTS

SK Mak is a Pfizer sponsored research fellow.

The supplementary surgery video accompanies this paper on *Asian Journal of Andrology's* website (<http://www.nature.com/aja>).

- 1 Tripe J. Case of continued priapism. *Lancet* 1845; **2**: 8.
- 2 Montague DK, Jarow J, Broderick GA, Dmochowski RR, Heaton JP *et al*. American Urological Association guideline on the management of priapism. *J Urol* 2003; **170**: 1318–24.
- 3 Broderick GA, Kadioglu A, Bivalacqua TJ, Ghanem H, Nehra A *et al*. Priapism: pathogenesis, epidemiology, and management. *J Sex Med* 2010; **7**: 476–500.
- 4 Brant WO, Garcia MM, Bella AJ, Chi T, Lue TF. T-shaped shunt and intracavernous tunneling for prolonged ischemic priapism. *J Urol* 2009; **181**: 1699–705.
- 5 Huang YC, Harraz AM, Shindel AW, Lue TF. Evaluation and management of priapism: 2009 update. *Nat Rev Urol* 2009; **6**: 262–71.
- 6 Hinman F. Report of case in a clinical study of the literature with reference to its pathogenesis and surgical treatments. *Ann Surg* 1914; **60**: 689–716.
- 7 Lin G, Xin ZC, Lue TF, Lin CS. Up and down-regulation of phosphodiesterase-5 as related to tachyphylaxis and priapism. *J Urol* 2003; **170**: S15–8; discussion S9.
- 8 Bivalacqua TJ, Burnett AL. Priapism: new concepts in the pathophysiology and new treatment strategies. *Curr Urol Rep* 2006; **7**: 497–502.
- 9 Hauri D, Spycher M, Bruhlmann W. Erection and priapism: a new physiopathological concept. *Urol Int* 1983; **38**: 138–45.
- 10 Garcia MM, Porten S, Lue TF. Commentary on refractory ischemic priapism. *Transl Androl Urol* 2011; **1**: 61–5.
- 11 Zheng DC, Yao HJ, Zhang K, Xu MX, Chen Q *et al*. Unsatisfactory outcomes of prolonged ischemic priapism without early surgical shunts: our clinical experience and a review of the literature. *Asian J Androl*. 2012 Aug 27. doi: 0.1038/aja.2012.63. [Epub ahead of print].
- 12 Burt FB, Schirmer HK, Scott WW. A new concept in the management of priapism. *J Urol* 1960; **83**: 60–1.
- 13 Mwamukonda KB, Chi T, Shindel AW, Lue TF. Androgen blockade for the treatment of high-flow priapism. *J Sex Med* 2010; **7**: 2532–7.
- 14 Hatzichristou D, Salpiggidis G, Hatzimouratidis K, Apostolidis A, Tzortzis V *et al*. Management strategy for arterial priapism: therapeutic dilemmas. *J Urol* 2002; **168**: 2074–7.
- 15 Gratzke C, Angulo J, Chitaley K, Dai Y, Kim NN *et al*. Anatomy, physiology and pathophysiology of erectile dysfunction. *J Sex Med* 2010; **7**: 445–75.
- 16 Somlyo AP, Somlyo AV. Signal transduction and regulation in smooth muscle. *Nature* 1994; **372**: 231–6.
- 17 Kovac JR, Preiksaitis HG, Sims SM. Functional and molecular analysis of L-type calcium channels in human esophagus and lower esophageal sphincter smooth muscle. *Am J Physiol Gastrointest Liver Physiol* 2005; **289**: G998–1006.
- 18 Kovac JR, Chrones T, Sims SM. Temporal and spatial dynamics underlying capacitative calcium entry in human colonic smooth muscle. *Am J Physiol Gastrointest Liver Physiol* 2008; **294**: G88–98.
- 19 Fukata Y, Amano M, Kaibuchi K. Rho-Rho-kinase pathway in smooth muscle contraction and cytoskeletal reorganization of non-muscle cells. *Trends Pharmacol Sci* 2001; **22**: 32–9.
- 20 Jaffe AB, Hall A. Rho GTPases: biochemistry and biology. *Annu Rev Cell Dev Biol* 2005; **21**: 247–69.
- 21 Sims SM, Chrones T, Preiksaitis HG. Calcium sensitization in human esophageal muscle: role for RhoA kinase in maintenance of lower esophageal sphincter tone. *J Pharmacol Exp Ther* 2008; **327**: 178–86.
- 22 Somlyo AP, Somlyo AV. Ca<sup>2+</sup> sensitivity of smooth muscle and nonmuscle myosin II: modulated by G proteins, kinases, and myosin phosphatase. *Physiol Rev* 2003; **83**: 1325–58.
- 23 Wang H, Eto M, Steers WD, Somlyo AP, Somlyo AV. RhoA-mediated Ca<sup>2+</sup> sensitization in erectile function. *J Biol Chem* 2002; **277**: 30614–21.
- 24 Burnett AL. Nitric oxide in the penis—science and therapeutic implications from erectile dysfunction to priapism. *J Sex Med* 2006; **3**: 578–82.
- 25 Burnett AL. Molecular pharmacotherapeutic targeting of PDE5 for preservation of penile health. *J Androl* 2008; **29**: 3–14.
- 26 Lin CS. Phosphodiesterase type 5 regulation in the penile corpora cavernosa. *J Sex Med* 2009; **6** (Suppl 3): 203–9.
- 27 Dai Y, Zhang Y, Phatarpekar P, Mi T, Zhang H *et al*. Adenosine signaling, priapism and novel therapies. *J Sex Med* 2009; **6** (Suppl 3): 292–301.
- 28 Eland IA, van der Lei J, Stricker BH, Sturkenboom MJ. Incidence of priapism in the general population. *Urology* 2001; **57**: 970–2.
- 29 Klein EA, Montague DK, Steiger E. Priapism associated with the use of intravenous fat emulsion: case reports and postulated pathogenesis. *J Urol* 1985; **133**: 857–9.
- 30 Hebuterne X, Frere AM, Bayle J, Rampal P. Priapism in a patient treated with total parenteral nutrition. *JPEN J Parenter Enteral Nutr* 1992; **16**: 171–4.
- 31 Saenz de Tejada I, Kim NN, Daley JT, Royai R, Hypolite J *et al*. Acidosis impairs rabbit trabecular smooth muscle contractility. *J Urol* 1997; **157**: 722–6.
- 32 Broderick GA, Gordon D, Hypolite J, Levin RM. Anoxia and corporal smooth muscle dysfunction: a model for ischemic priapism. *J Urol* 1994; **151**: 259–62.
- 33 Spycher MA, Hauri D. The ultrastructure of the erectile tissue in priapism. *J Urol* 1986; **135**: 142–7.
- 34 Champion HC, Bivalacqua TJ, Takimoto E, Kass DA, Burnett AL. Phosphodiesterase-5A dysregulation in penile erectile tissue is a mechanism of priapism. *Proc Natl Acad Sci USA* 2005; **102**: 1661–6.
- 35 Bivalacqua TJ, Ross AE, Strong TD, Gebaska MA, Musicki B *et al*. Attenuated RhoA/Rho-kinase signaling in penis of transgenic sickle cell mice. *Urology* 2010; **76**: 510 e7–12.
- 36 Cecil M, Arslan D, Goktay AY, Esen AA, Dicle O *et al*. The prediction of papaverine induced priapism by color Doppler sonography. *J Urol* 2001; **165**: 416–8.
- 37 Pryor J, Akkus E, Alter G, Jordan G, Lebret T *et al*. Priapism. *J Sex Med* 2004; **1**: 116–20.
- 38 Wear JB Jr, Crummy AB, Munson BO. A new approach to the treatment of priapism. *J Urol* 1977; **117**: 252–4.
- 39 Kulmala RV, Tamella TL. Effects of priapism lasting 24 hours or longer caused by intracavernosal injection of vasoactive drugs. *Int J Impot Res* 1995; **7**: 131–6.
- 40 Broderick GA, Harkaway R. Pharmacologic erection: time-dependent changes in the corporal environment. *Int J Impot Res* 1994; **6**: 9–16.
- 41 Pryor JP, Hehir M. The management of priapism. *Br J Urol* 1982; **54**: 751–4.
- 42 Pryor JP. Priapism. *Practitioner* 1982; **226**: 1873–9.
- 43 Broderick GA. Priapism. In: Kavoussi L, Novick A, Partin A, Peters C, editors. *Campbell-Walsh Urology*. 10th edn. Philadelphia, PA: Elsevier Saunders; 2012. p749–69.
- 44 Garcia MM, Shindel AW, Lue TF. T-shunt with or without tunnelling for prolonged ischaemic priapism. *BJU Int* 2008; **102**: 1754–64.
- 45 Burnett AL, Pierorazio PM. Corporal 'snake' maneuver: corporoglanular shunt surgical modification for ischemic priapism. *J Sex Med* 2009; **6**: 1171–6.
- 46 Rees RW, Kalsi J, Minhas S, Peters J, Kell P *et al*. The management of low-flow priapism with the immediate insertion of a penile prosthesis. *BJU Int* 2002; **90**: 893–7.
- 47 Ralph DJ, Garaffa G, Muneer A, Freeman A, Rees R *et al*. The immediate insertion of a penile prosthesis for acute ischaemic priapism. *Eur Urol* 2009; **56**: 1033–8.
- 48 Adeyoju AB, Olujohunge AB, Morris J, Yardumian A, Bareford D *et al*. Priapism in sickle-cell disease; incidence, risk factors and complications—an international multicentre study. *BJU Int* 2002; **90**: 898–902.
- 49 Mantadakis E, Cavender JD, Rogers ZR, Ewalt DH, Buchanan GR. Prevalence of priapism in children and adolescents with sickle cell anemia. *J Pediatr Hematol Oncol* 1999; **21**: 518–22.
- 50 Burnett AL, Bivalacqua TJ, Champion HC, Musicki B. Long-term oral phosphodiesterase 5 inhibitor therapy alleviates recurrent priapism. *Urology* 2006; **67**: 1043–8.
- 51 Bivalacqua TJ, Champion HC, Mason W, Burnett AL. Long-term phosphodiesterase type 5 inhibitor therapy reduces priapic activity in transgenic sickle cell mice. *J Urol* 2006; **175**: 387.
- 52 Bialecki E, Bridges K. Sildenafil relieves priapism in patients with sickle cell disease. *Am J Med* 2002; **113**: 252.
- 53 Burnett AL, Bivalacqua TJ, Champion HC, Musicki B. Feasibility of the use of phosphodiesterase type 5 inhibitors in a pharmacologic prevention program for recurrent priapism. *J Sex Med* 2006; **3**: 1077–84.
- 54 Beltran A, Concepcion F, Manzanares D, Garrido G, Glaria L *et al*. Heparin and low molecular weight heparin decrease nitric oxide production by human polymorphonuclear cells. *Arch Med Res* 1999; **30**: 116–9.
- 55 Kato G. Priapism in sickle cell disease: a hematologist's perspective. *J Sex Med* 2012; **9**: 70–8.
- 56 Bivalacqua TJ, Musicki B, Kutlu O, Burnett AL. New insights into the pathophysiology of sickle cell disease-associated priapism. *J Sex Med* 2012; **9**: 79–87.
- 57 Jeong WI, Do SH, Yun HS, Song BJ, Kim SJ *et al*. Hypoxia potentiates transforming growth factor-beta expression of hepatocyte during the cirrhotic condition in rat liver. *Liver Int* 2004; **24**: 658–68.
- 58 Ul-Hasan M, El-Sakka AI, Lee C, Yen TS, Dahiya R *et al*. Expression of TGF-beta-1 mRNA and ultrastructural alterations in pharmacologically induced prolonged penile erection in a canine model. *J Urol* 1998; **160**: 2263–6.
- 59 Border WA, Noble NA. Fibrosis linked to TGF-beta in yet another disease. *J Clin Invest* 1995; **96**: 655–6.
- 60 Nolan VG, Wyszynski DF, Farrer LA, Steinberg MH. Hemolysis-associated priapism in sickle cell disease. *Blood* 2005; **106**: 3264–7.
- 61 Mi T, Abbasi S, Zhang H, Uray K, Chunn JL *et al*. Excess adenosine in murine penile erectile tissues contributes to priapism via A2B adenosine receptor signaling. *J Clin Invest* 2008; **118**: 1491–501.
- 62 Tong Y, Tiplitsky SI, Tar M, Melman A, Davies KP. Transcription of G-protein coupled receptors in corporeal smooth muscle is regulated by the endogenous neutral endopeptidase inhibitor sialorphin. *J Urol* 2008; **180**: 760–6.
- 63 Davies KP. The role of opiorphins (endogenous neutral endopeptidase inhibitors) in urogenital smooth muscle biology. *J Sex Med* 2009; **6** (Suppl 3): 286–91.
- 64 Tong Y, Tar M, Melman A, Davies K. The opiorphin gene (ProL1) and its homologues function in erectile physiology. *BJU Int* 2008; **102**: 736–40.
- 65 Kanika ND, Tar M, Tong Y, Kuppam DS, Melman A *et al*. The mechanism of opiorphin-induced experimental priapism in rats involves activation of the polyamine synthetic pathway. *Am J Physiol Cell Physiol* 2009; **297**: C916–27.

- 66 Steinberg J, Eyre R. Management of recurrent priapism with epinephrine self-injection and gonadotropin-releasing hormone analogue. *J Urol* 1995; **153**: 152.
- 67 van Driel M, Joosten E, Mensink H. Intrasorporeal self-injection with epinephrine as treatment for idiopathic recurrent priapism. *Eur Urol* 1990; **17**: 95.
- 68 Rourke KF, Fischler AH, Jordan GH. Treatment of recurrent idiopathic priapism with oral baclofen. *J Urol* 2002; **168**: 2552; discussion-3.
- 69 Rachid-Filho D, Cavalcanti A, Favorito L, Costa W, Sampaio F. Treatment of recurrent priapism in sickle cell anemia with finasteride: a new approach. *Urology* 2009; **74**: 1054-7.
- 70 Wu A, Lue TF. Commentary on high flow, non-ischemic, priapism. *Transl Androl Urol* 2012; **1**: 109-12.
- 71 Brock G, Breza J, Lue TF, Tanagho EA. High flow priapism: a spectrum of disease. *J Urol* 1993; **150**: 968-71.
- 72 Hakim LS, Kulaksizoglu H, Mulligan R, Greenfield A, Goldstein I. Evolving concepts in the diagnosis and treatment of arterial high flow priapism. *J Urol* 1996; **155**: 541-8.
- 73 Kumar R, Shrivastava DN, Seth A. Spontaneous resolution of delayed onset, posttraumatic high-flow priapism. *J Postgrad Med* 2006; **52**: 298-9.