

# UC San Diego

## UC San Diego Previously Published Works

### Title

Female Genital Mutilation/Cutting in Children and Adolescents  
Illustrated Guide to Diagnose, Assess, Inform and Report

### Permalink

<https://escholarship.org/uc/item/3098w40x>

### ISBN

9783030817367

### Authors

Abdulcadir, Jasmine  
Guedj, Noémie Sachs  
Yaron, Michal

### Publication Date

2021

### Copyright Information

This work is made available under the terms of a Creative Commons Attribution-NonCommercial-NoDerivatives License, available at <https://creativecommons.org/licenses/by-nc-nd/4.0/>

Peer reviewed

# Female Genital Mutilation/Cutting in Children and Adolescents

Illustrated Guide to Diagnose,  
Assess, Inform and Report

Jasmine Abdulcadir  
Noémie Sachs Guedj  
Michal Yaron  
*Editors*

OPEN ACCESS



Springer

# Female Genital Mutilation/Cutting in Children and Adolescents

Jasmine Abdulcadir  
Noémie Sachs Guedj • Michal Yaron  
Editors

# Female Genital Mutilation/ Cutting in Children and Adolescents

Illustrated Guide to Diagnose, Assess, Inform  
and Report



**UNIVERSITÉ  
DE GENÈVE**

---

CENTRE MAURICE CHALUMEAU  
EN SCIENCES DES SEXUALITÉS



**UNIVERSITÉ  
DE GENÈVE**

 Springer

*Editors*

Jasmine Abdulcadir  
Department of Pediatrics, Gynecology  
and Obstetrics  
Geneva University Hospitals  
Geneva  
Switzerland

Noémie Sachs Guedj  
Department of Pediatrics, Gynecology  
and Obstetrics  
Geneva University Hospitals  
Geneva  
Switzerland

Michal Yaron  
Department of Pediatrics, Gynecology  
and Obstetrics  
Geneva University Hospitals  
Geneva  
Switzerland



This work was supported by Université de Genève - Centre Maurice Chalumeau en sciences des sexualités, Division de l'Information Scientifique, Département de Pédiatrie Gynécologie et Obstétrique

This book is an open access publication.

ISBN 978-3-030-81735-0      ISBN 978-3-030-81736-7 (eBook)

<https://doi.org/10.1007/978-3-030-81736-7>

© The Editor(s) (if applicable) and The Author(s) 2022

**Open Access** This book is licensed under the terms of the Creative Commons Attribution 4.0 International License (<http://creativecommons.org/licenses/by/4.0/>), which permits use, sharing, adaptation, distribution and reproduction in any medium or format, as long as you give appropriate credit to the original author(s) and the source, provide a link to the Creative Commons license and indicate if changes were made.

The images or other third party material in this book are included in the book's Creative Commons license, unless indicated otherwise in a credit line to the material. If material is not included in the book's Creative Commons license and your intended use is not permitted by statutory regulation or exceeds the permitted use, you will need to obtain permission directly from the copyright holder.

The use of general descriptive names, registered names, trademarks, service marks, etc. in this publication does not imply, even in the absence of a specific statement, that such names are exempt from the relevant protective laws and regulations and therefore free for general use.

The publisher, the authors, and the editors are safe to assume that the advice and information in this book are believed to be true and accurate at the date of publication. Neither the publisher nor the authors or the editors give a warranty, expressed or implied, with respect to the material contained herein or for any errors or omissions that may have been made. The publisher remains neutral with regard to jurisdictional claims in published maps and institutional affiliations.

This Springer imprint is published by the registered company Springer Nature Switzerland AG  
The registered company address is: Gewerbestrasse 11, 6330 Cham, Switzerland

# Foreword

Female Genital Mutilation/Cutting (FGM/C) remains a major public health issue ten years after the United Nation General Assembly adopted a resolution on its elimination. It also remains a neglected topic in pre- and post-graduate curricula of health professionals of many countries of the world.

It is my privilege to write the foreword to this atlas, which is the result of a multidisciplinary long-lasting work, fruit of the collaboration between different institutions and countries. This atlas will significantly contribute to improve the care of girls and women with FGM/C in both high FGM/C prevalence and migration countries. The book is a learning or training tool for health care professionals and a unique representation of the wide diversity of the female external genitals, at different ages and in different ethnic groups.

I express my gratitude to all contributing authors and consultants for this work. As academic institutions, education dissemination should be at the forefront of our activities ensuring that all health care professionals in contact with girls and women having had FGM/C can provide access to appropriate information and care. I am convinced that education of health care providers can also play an important contributing role in ending the practice.

Patrick Petignat  
Head of Gynecology Division  
Department of Pediatrics, Gynecology and Obstetrics  
Geneva University Hospitals  
Geneva, Switzerland

# Contents

## Part I Female Genital Mutilation/Cutting in Infants, Children and Young People

<b>1</b>	<b>Assessing the Infant/Child/Young Person with Suspected FGM/C . . . .</b>	<b>3</b>
	Jasmine Abdulcadir, Noémie Sachs Guedj, Michal Yaron, Omar Abdulcadir, Juliet Albert, Martin Caillet, Lucrezia Catania, Sarah M. Creighton, Céline Deguet, Elise Dubuc, Brian D. Earp, Birgitta Essén, Deborah Hodes, Adriana Kaplan Marcusan, Ranit Mishori, Deborah Ottenheimer, Fabienne Richard, Aida Sy, Moustapha Touré, Amelia Valladolid, Anneke Vercootere, Bilkis Vissandjée, and Janine Young	
1.1	How Does the Child First Present? . . . . .	4
1.2	Clinical Setting . . . . .	5
1.3	Taking the History . . . . .	6
1.4	The Examination . . . . .	7
1.5	When FGM/C Is Confirmed . . . . .	10
1.5.1	Clinical Management . . . . .	10
1.5.2	Legal Proceedings . . . . .	11
1.5.3	Medical Confirmation in the Framework of an Asylum Claim . . . . .	12
1.6	When FGM/C Is Not Identified . . . . .	12
1.6.1	The Need for Cultural Sensitivity and Risks of Stigmatization . . . . .	13
1.7	Conclusion . . . . .	13
<b>2</b>	<b>Consent and Photography . . . . .</b>	<b>15</b>
	Jasmine Abdulcadir, Noémie Sachs Guedj, Michal Yaron, Omar Abdulcadir, Juliet Albert, Martin Caillet, Lucrezia Catania, Sarah M. Creighton, Céline Deguet, Elise Dubuc, Brian D. Earp, Birgitta Essén, Deborah Hodes, Adriana Kaplan Marcusan, Ranit Mishori, Deborah Ottenheimer, Fabienne Richard, Aida Sy, Moustapha Touré, Amelia Valladolid, Anneke Vercootere, Bilkis Vissandjée, and Janine Young	

2.1	Informed Consent . . . . .	16
2.2	Trauma-Informed Care . . . . .	17
2.3	Photography: Technical Tips . . . . .	17
	Appendix: Standardized Form Used at University College London Hospitals as an Example [10] . . . . .	19
<b>Part II Iconography for Female External Genitals of Children with and Without FGM/C</b>		
<b>3</b>	<b>Pictures Without FGM/C . . . . .</b>	<b>27</b>
	Jasmine Abdulcadir, Noémie Sachs Guedj, Michal Yaron, Omar Abdulcadir, Juliet Albert, Martin Caillet, Lucrezia Catania, Sarah M. Creighton, Céline Deguelle, Elise Dubuc, Brian D. Earp, Birgitta Essén, Deborah Hodes, Adriana Kaplan Marcusan, Ranit Mishori, Deborah Ottenheimer, Fabienne Richard, Aida Sy, Moustapha Touré, Amelia Valladolid, Anneke Vercoutere, Bilkis Vissandjée, and Janine Young	
3.1	Vulvar examination . . . . .	31
3.2	Pictures Without FGM/C, with “Ambiguous” Genitals or Mucocolpos . . . . .	40
3.3	Pictures Without FGM/C, with Dermatological Conditions, Infections, and Other Lesions . . . . .	41
3.4	Pictures Without FGM/C, with Urethral Lesions . . . . .	46
3.5	Pictures Without FGM/C, with Genital Trauma . . . . .	48
<b>4</b>	<b>Pictures with Potential Differential Diagnosis of FGM/C . . . . .</b>	<b>49</b>
	Jasmine Abdulcadir, Noémie Sachs Guedj, Michal Yaron, Omar Abdulcadir, Juliet Albert, Martin Caillet, Lucrezia Catania, Sarah M. Creighton, Céline Deguelle, Elise Dubuc, Brian D. Earp, Birgitta Essén, Deborah Hodes, Adriana Kaplan Marcusan, Ranit Mishori, Deborah Ottenheimer, Fabienne Richard, Aida Sy, Moustapha Touré, Amelia Valladolid, Anneke Vercoutere, Bilkis Vissandjée, and Janine Young	
<b>5</b>	<b>Pictures with FGM/C . . . . .</b>	<b>59</b>
	Jasmine Abdulcadir, Noémie Sachs Guedj, Michal Yaron, Omar Abdulcadir, Juliet Albert, Martin Caillet, Lucrezia Catania, Sarah M. Creighton, Céline Deguelle, Elise Dubuc, Brian D. Earp, Birgitta Essén, Deborah Hodes, Adriana Kaplan Marcusan, Ranit Mishori, Deborah Ottenheimer, Fabienne Richard, Aida Sy, Moustapha Touré, Amelia Valladolid, Anneke Vercoutere, Bilkis Vissandjée, and Janine Young	
5.1	FGM/C Type I . . . . .	61
5.2	FGM/C Type II . . . . .	66
5.3	FGM/C Type III . . . . .	73
5.4	FGM/C Type IV . . . . .	85



**6 FGM/C Complications** ..... 89  
Jasmine Abdulcadir, Noémie Sachs Guedj, Michal Yaron,  
Omar Abdulcadir, Juliet Albert, Martin Caillet, Lucrezia Catania,  
Sarah M. Creighton, Céline Deguette, Elise Dubuc, Brian D. Earp,  
Birgitta Essén, Deborah Hodes, Adriana Kaplan Marcusan,  
Ranit Mishori, Deborah Ottenheimer, Fabienne Richard, Aida Sy,  
Moustapha Touré, Amelia Valladolid, Anneke Vercootere,  
Bilkis Vissandjée, and Janine Young

6.1 Acute ..... 91  
    6.1.1 Prepubertal ..... 91  
    6.1.2 Postpubertal ..... 92

6.2 Long Term ..... 93  
    6.2.1 Prepubertal ..... 93  
    6.2.2 Postpubertal ..... 95

6.3 Acute and Long Term ..... 96

6.4 Surgical Treatments of Complications of FGM/C ..... 98

6.5 Defibulation ..... 104  
    6.5.1 Prepubertal ..... 104  
    6.5.2 Postpubertal ..... 105

References ..... 113

# Contributors

**Jasmine Abdulcadir** Department of Pediatrics, Gynecology and Obstetrics, Geneva University Hospitals, Geneva, Switzerland

**Omar Abdulcadir** Past Director and Founder of the Referral Center for Curing and Preventing FGM. AOUC, Florence, Italy

**Juliet Albert** Imperial College Healthcare, NHS Trust, London, UK

**Martin Caillet** CHU Saint-Pierre, Brussels, Belgium

**Lucrezia Catania** Referral Center for Curing and Preventing FGM. AOUC, Florence, Italy

**Sarah M. Creighton** University College London Hospital, London, UK

**Céline Deguette** Department of Forensic Medicine, AP-HP. Centre-University of Paris, Paris, France

**Elise Dubuc** AP-HP. Centre-University of Paris, Montréal, QC, Canada

**Brian D. Earp** Departments of Philosophy and Psychology, Yale University, New Haven, CT, USA

**Birgitta Essén** Women's and Children's Health/IMCH, WHO Collaborating Centre on Migration and Health, Uppsala University, Uppsala, Sweden

**Noémie Sachs Guedj** Department of Pediatrics, Gynecology and Obstetrics, Geneva University Hospitals, Geneva, Switzerland

**Deborah Hodes** University College London Hospital, London, UK

**Adriana Kaplan Marcusan** Department of Social and Cultural Anthropology, UAB, Barcelona, Spain

**Ranit Mishori** Georgetown University Department of Family Medicine, and Physicians for Human Rights, Washington, DC, USA

**Deborah Ottenheimer** Morrisania Diagnostic and Treatment Center, Bronx, NY, USA

**Fabienne Richard** GAMS Belgique, Brussels, Belgium

Ecole de santé publique, Université Libre de Bruxelles, Brussels, Belgium

**Aida Sy** Bamako, Mali

**Moustapha Touré** Malian Society of Gynecology and Obstetrics, Bamako, Mali

**Amelia Valladolid** Universidad del País Vasco, Vizcaya, Spain

**Anneke Vercoutere** Community and Health Project in Guinea Conakry, Conakry, Guinea

Hôpital Erasme, University Hospital ULB, Brussels, Belgium

**Bilkis Vissandjée** Université de Montreal, Montreal, Quebec, Canada

**Michal Yaron** Department of Pediatrics, Gynecology and Obstetrics, Geneva University Hospitals, Geneva, Switzerland

**Janine Young** Department of Pediatrics, Denver Health and Hospitals, University of Colorado School of Medicine, Denver, CO, USA

# Introduction

Female Genital Mutilation/Cutting (FGM/C) comprises all procedures that involve partial or total removal of the external female genitalia or injury to the female genital organs that are medically unnecessary (i.e., performed primarily for cultural or religious reasons), especially when done without the consent of the affected person [1]. Such procedures are widely condemned as a violation of girls' and women's human rights (i.e., the right to bodily integrity) and are illegal in most countries. At least 200 million girls and women have undergone some form of cutting in more than 31 countries worldwide. While the practice is more prevalent in some areas of Africa, the Middle East, and Southeast Asia/the Asia Pacific, it is found in almost every nation as a result of emerging migration patterns [2, 3].

Different types and subtypes of FGM/C (Table 1) are carried out in different settings during infancy and childhood, usually before the age of 15 (Table 2) [4].

Although some pictorial and training tools are available [6, 7], the existing literature has mainly focused on adults. Specific guidelines for the care of infants, children, and young people (I/C/YP) with FGM/C do not exist and iconographic training material is lacking. Some recommendations, good practice, and expert opinions have recently become available [8–10]. In August 2020, a technical report from the *American Academy of Pediatrics* was published. It outlined a standard-of-care approach to FGM/C evaluation in children; encouraged examination of external female genitalia at all health supervision examinations; supported culturally sensitive discussion and counseling approaches; and described the legal and ethical considerations around FGM/C [11].

We herewith provide a visual reference and learning tool containing information and comprehensive iconographic material to be used as a guide for diagnosis of different types, subtypes, and complications of FGM/C, as well as differential diagnosis of pre and postpubertal I/C/YP physiological variations.

This visual reference may be used as a standalone guide for the management of I/C/YP FGM/C and may be consulted by health care professionals (HCPs) working in different countries when examining I/C/YP with equivocal findings. In addition, the guide and accompanying text can be used to facilitate training of HCPs globally in making accurate diagnoses and managing different genital conditions/issues, while enhancing patient–provider communication, and enabling precise recording and reporting to government agencies, where required.

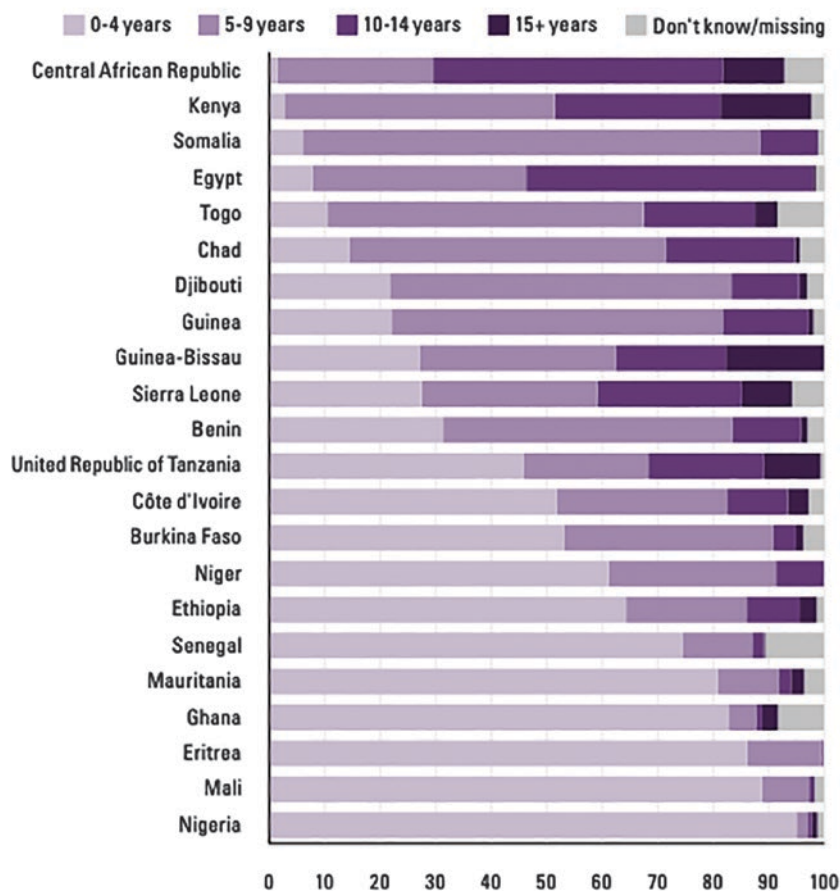
**Table 1** Types and subtypes of FGM/C adapted from WHO [5]

Types	Definitions	Subtypes
Type I	Partial or total removal of the clitoral glans (the visible part of the clitoris, which is a sensitive part of the female genitals, with the function of providing sexual pleasure to the woman), and eventually the body of the clitoris, and/or the prepuce/clitoral hood (the fold of skin surrounding the clitoral glans).	<b>Type Ia.</b> Removal of part or all the prepuce/clitoral hood only. <b>Type Ib.</b> Removal of part or all of the clitoral glans and eventually the body of the clitoris, with the prepuce/clitoral hood.
Type II	Partial or total removal of the clitoral glans, and eventually the body of the clitoris, and the labia minora (the inner folds of the vulva), with or without removal of the labia majora (the outer folds of skin of the vulva).	<b>Type IIa.</b> Partial or total removal of the labia minora only. <b>Type IIb.</b> Partial or total removal of the clitoral glans, and eventually the body of the clitoris, and the labia minora (prepuce/clitoral hood may be affected). <b>Type IIc.</b> Partial or total removal of the clitoral glans, and eventually the body of the clitoris, the labia minora, and the labia majora (prepuce/clitoral hood may be affected).
Type III. (Often referred to as infibulation)	Narrowing of the vaginal opening with the creation of a covering seal. The seal is formed by cutting and repositioning the labia minora or labia majora. The covering of the vaginal opening is done with or without removal of the clitoral prepuce/clitoral hood and glans and body (Type I).	<b>Type IIIa.</b> Removal and repositioning of the labia minora. <b>Type IIIb.</b> Removal and repositioning of the labia majora.
Type IV	All other harmful procedures to the female genitalia for nonmedical purposes, for example, pricking, piercing, incising, scraping and cauterization, labial stretching.	

**Table 2** Percentage distribution of girls who have undergone FGM/C, by age at which cutting occurred by mother's report between 2000 and 2010 [1]

### In half of the countries with available data, the majority of girls were cut before age 5

Percentage distribution of girls who have undergone FGM/C (as reported by their mothers), by age at which cutting occurred



Sources: DHS and MICS, 2000-2010.

**Part I**  
**Female Genital Mutilation/Cutting in**  
**Infants, Children and Young People**

# Chapter 1

## Assessing the Infant/Child/Young Person with Suspected FGM/C



**Jasmine Abdulcadir, Noémie Sachs Guedj, Michal Yaron, Omar Abdulcadir, Juliet Albert, Martin Caillet, Lucrezia Catania, Sarah M. Creighton, Céline Deguette, Elise Dubuc, Brian D. Earp, Birgitta Essén, Deborah Hodes, Adriana Kaplan Marcusan, Ranit Mishori, Deborah Ottenheimer, Fabienne Richard, Aida Sy, Moustapha Touré, Amelia Valladolid, Anneke Vercoutere, Bilkis Vissandjée, and Janine Young**

---

J. Abdulcadir (✉) · N. S. Guedj · M. Yaron  
Department of Pediatrics, Gynecology and Obstetrics, Geneva University Hospitals,  
Geneva, Switzerland  
e-mail: [jasmine.abdulcadir@hcuge.ch](mailto:jasmine.abdulcadir@hcuge.ch); [michal.yaron@hcuge.ch](mailto:michal.yaron@hcuge.ch)

O. Abdulcadir · L. Catania  
Referral Center for Curing and Preventing FGM. AOUC, Florence, Italy

J. Albert  
Imperial College Healthcare, NHS Trust, London, UK  
e-mail: [juliet.albert@nhs.net](mailto:juliet.albert@nhs.net)

M. Caillet  
CHU Saint-Pierre, Brussels, Belgium  
e-mail: [martin\\_caillet@stpierre-bru.be](mailto:martin_caillet@stpierre-bru.be)

S. M. Creighton · D. Hodes  
University College London Hospital, London, UK  
e-mail: [sarah.creighton2@nhs.net](mailto:sarah.creighton2@nhs.net); [deborah.hodes@nhs.net](mailto:deborah.hodes@nhs.net)

C. Deguette  
Department of Forensic Medicine, AP-HP. Centre-University of Paris, Paris, France  
e-mail: [celine.deguette@aphp.fr](mailto:celine.deguette@aphp.fr)

E. Dubuc  
CHU Sainte-Justine, Montréal, QC, Canada  
e-mail: [elise.dubuc.1@umontreal.ca](mailto:elise.dubuc.1@umontreal.ca)

B. D. Earp  
Departments of Philosophy and Psychology, Yale University, New Haven, CT, USA  
e-mail: [brian.earp@yale.edu](mailto:brian.earp@yale.edu)

B. Essén  
Women's and Children's Health/IMCH, WHO Collaborating Centre on Migration and Health,  
Uppsala University, Uppsala, Sweden  
e-mail: [brigitta.essen@kbh.uu.se](mailto:brigitta.essen@kbh.uu.se)

A. K. Marcusan  
Department of Social and Cultural Anthropology, UAB, Barcelona, Spain  
e-mail: [adriana.kaplan@uab.cat](mailto:adriana.kaplan@uab.cat)

© The Author(s) 2022  
J. Abdulcadir et al. (eds.), *Female Genital Mutilation/Cutting in Children and Adolescents*, [https://doi.org/10.1007/978-3-030-81736-7\\_1](https://doi.org/10.1007/978-3-030-81736-7_1)



R. Mishori  
Georgetown University Department of Family Medicine, and Physicians for Human Rights,  
Washington, DC, USA  
e-mail: [mishorir@georgetown.edu](mailto:mishorir@georgetown.edu)

D. Ottenheimer  
Morrisania Diagnostic and Treatment Center, Bronx, NY, USA  
e-mail: [deb@ottenheimerhealth.com](mailto:deb@ottenheimerhealth.com)

F. Richard  
GAMS Belgique, Brussels, Belgium  
Ecole de santé publique, Université Libre de Bruxelles, Brussels, Belgium  
e-mail: [fabienne@gams.be](mailto:fabienne@gams.be)

A. Sy  
Bamako, Mali

M. Touré  
Malian Society of Gynecology and Obstetrics, Bamako, Mali

A. Valladolid  
Universidad del Pais Vasco, Vizcaya, Spain

A. Vercoutere  
Community and Health Project in Guinea Conakry, Conakry, Guinea  
Hôpital Erasme, University Hospital ULB, Brussels, Belgium  
e-mail: [An.Vercoutere@erasme.ulb.ac.be](mailto:An.Vercoutere@erasme.ulb.ac.be)

B. Vissandjée  
Université de Montreal, Montreal, Quebec, Canada  
e-mail: [bilkis.vissandjee@umontreal.ca](mailto:bilkis.vissandjee@umontreal.ca)

J. Young  
Department of Pediatrics, Denver Health and Hospitals, University of Colorado School of  
Medicine, Denver, CO, USA  
e-mail: [janine.young@dhha.org](mailto:janine.young@dhha.org)

## 1.1 How Does the Child First Present?

The majority of HCPs in high-income countries are unlikely to see children with FGM/C who may be acutely unwell on account of cutting (that is, due directly to the procedure itself). Hemorrhage, infection, and sepsis are among the potential acute complications of FGM/C, especially with more severe types and if carried out with non-sterile equipment by a medically unqualified practitioner [12]. Although the absolute likelihood of these complications is not known and depends on the type of cutting, the instruments used, the skill of the person doing the cutting, and the (lack of) clinical adequacy of setting, when complications do occur, they may be life-threatening [13]. If called to see a child immediately after FGM/C, management should include assessment for signs of acute blood loss, infection, or urinary retention and treatment with antibiotics, analgesia, tetanus toxoid, and urinary catheterization, should be administered as clinically indicated. Attention should also be made to local laws regarding the performance of FGM/C in children. The clinician should follow local requirements for reporting the suspected case to the appropriate child protective and child abuse services [14, 15].

An I/C/YP may be referred to an HCP for assessment for FGM/C in various scenarios, depending on the country where the I/C/YP currently resides and local

laws that may dictate the approach. These scenarios may include evaluations simply because the I/C/YP comes from a country where FGM/C is practiced or because FGM/C has been alleged by the child herself or by a family member; or following concerns raised by a teacher, a medical or mental health provider, social service provider or the police. In some high-income countries, a referral might also be a result of an immigration process for individuals seeking asylum, with the request to confirm or exclude the presence of FGM/C. In health care settings, FGM/C may be encountered during evaluation of relevant history and symptoms, including recurrent urinary tract infections; vulvitis or other genitourinary complaints; when a child is referred for a medical assessment of maltreatment or during physical examinations carried out on unaccompanied child migrant or adopted I/C/YP. FGM/C may also be discovered during standard annual physical examinations. When a pregnant female with FGM/C presents for the birth of a child, antenatal, and/or postnatal appointments, she should routinely be asked if any of her children have had FGM/C, whereupon the HCP should assess the immediate and future risk to her children and discuss medical and legal ramifications of having FGM/C performed on any children. If her children have had a history of FGM/C, arrangements should be proposed to have her children evaluated and treated as needed [16].

The primary aim of the clinical assessment is to confirm, if possible, whether FGM/C has been performed. If FGM/C is confirmed then subsequent management includes:

1. Identifying and managing immediate and long-term health consequences for the I/C/YP.
2. Providing culturally sensitive, age-appropriate, and non-stigmatizing information to her and her family.
3. Evaluating the risk to other children in the immediate and extended family and if needed, carrying out an appropriate assessment. This may include linking other children and adults with FGM/C, or at risk for the practice, to appropriate ongoing medical and mental health care, as needed. In some countries, medical corroboration might instigate a police investigation and criminal prosecution.
4. Providing counselling to expectant parents about FGM/C medical complications and illegality.

## 1.2 Clinical Setting

Examining children with suspected FGM/C is a relatively new requirement in several high-income countries and is performed by different specialists [9, 10, 17]. It is considered best practice to assess I/C/YP with suspected FGM/C in a child-centered setting and according to local clinical practices and resources. The setting, professionals involved, and nature of case identification vary between countries. In the UK the I/C/YP is seen by a multidisciplinary team [10, 17, 18]; in Belgium and Switzerland, the I/C/YP is examined by a gynecologist trained in FGM/C and/or a pediatrician or a child-and-adolescent gynecologist; in France, children are seen by a forensic examiner; in the US, girls with or at risk of FGM/C who are seeking asylum may be examined by a medical forensic examiner, may be identified as part of

standard refugee domestic medical screening, or may be diagnosed at standard annual physical examinations, or because of symptoms related to FGM/C. The examining clinician must have experience in the genital examination of children and should be trained in identifying the different types of FGM/C [19]. However, many countries may not have this degree of training available. In such cases, if resources are available, it is recommended to develop specific regional centers with HCPs who can serve as consultants. FGM/C examinations may also be provided by existing clinics such as those that see and perform evaluations on I/C/YP who are alleged victims of acute sexual assault or suspected sexual abuse, or by medical forensic examiners/specialists. Clinicians working in these service areas are highly skilled at genital examination of girls but often have less experience in detecting the physical signs of FGM/C [20]. Close examination of the clitoris and peri-clitoral area is not common when examining for child sexual abuse (CSA) but is essential when performing an evaluation for FGM/C. HCPs should not miss the opportunity during CSA assessments to gain experience in recognizing normal variants of clitoral anatomy [21, 22], which will help in distinguishing such variants from FGM/C.

The lead clinician in the evaluation of a child for FGM/C may be a pediatrician, gynecologist, pediatric gynecologist, general practitioner, urogynecologist, child abuse pediatrician, specialized nurse, sexual health clinician, or forensic examiner. Where resources and services are available, they should work within a multidisciplinary team with access to psychological support for the child and the family, whether or not FGM/C is confirmed. A play therapist can help prepare younger children for the examination using dolls. It is recommended that the service will also offer referrals to local community-based support, if available. In order to prevent repeated, and possibly traumatic examinations, access to a central service which offers an expert review of images and DVDs is recommended after informed consent. If no video recordings or images are available in the country where the evaluation takes place, precise documentation and drawings should be used to detail physical findings.

### 1.3 Taking the History

If the girl is old enough with the developmental capability needed, it is important to first take the history directly from her so that she can understand that the consultation is about her health and well-being. More details of the history can be obtained from the social worker and parents/legal guardians/caregivers, recognizing that the parents/legal guardians/caregivers may have been perpetrators of the FGM/C. At the beginning of the visit, the clinician should explain why the examination has been suggested. The clinician should also obtain information from family members, such as the mother or father, about any family history of FGM/C. A medical history should be taken with the aid of the parents/guardians/caregivers and should include questions about developmental milestones and general health. Place of birth, ethnic group, date of entry to the country, and travel details abroad are relevant. Questions specifically addressing physical or psychological symptoms that may be associated with FGM/C are important (Table 1.1) [16]. A standardized form will ensure that all important questions are being asked (Appendix of chapter “Consent and Photography”) [18,

**Table 1.1** Physical and psychological consequences of FGM/C

Possible short-term health complications of FGM/C	Severe local pain Injury to tissues Hemorrhage Hemorrhagic shock Infection and septicemia Genital tissue swelling Acute urine retention Death
Possible long-term health complications of FGM/C	Chronic vulvar pain Dyspareunia Clitoral neuroma Menstrual difficulties Painful or difficult urination Keloids in the genital area Reproductive tract infections Urinary tract infections Epidermal inclusion cysts in the genital area Post traumatic stress disorder (PTSD) Depression and anxiety Psychosexual dysfunction

23]. It is important to bear in mind that although many medical complaints may be attributed to FGM/C, some symptoms such as dysmenorrhea, obstructed menstrual or urinary flow, genitourinary infections, or dyspareunia may be unrelated and could be due to another medical condition, while psychological symptoms could be related to a wide range of factors unrelated to FGM/C. Many I/C/YP who have experienced FGM/C might be more occupied with their daily life and challenges than they are by their FGM/C, which they may not even remember having gone through. It is important not to cause iatrogenic harm by using terms or questions which might lead children to become ashamed of their bodies, to feel “not normal,” inadequate or subject them to other stigmatization [24, 25]. Medical providers may identify FGM/C in infants, children, and adolescent girls outside of a formal evaluation. In such cases, it is important to discuss the findings with the child (if age-appropriate) and parents/legal guardians. If the patient is an adolescent girl and does not want such findings disclosed or discussed with the legal guardians and there are no urgent medical issues related to the FGM/C, medical providers, should follow local laws regarding protected health information and approach the discussions per those country guidelines.

Age-appropriate language is important and accredited, independent interpreters should take part in the consultation using the language understood by the I/C/YP. Family members and/or friends should never act as interpreters.

### 1.4 The Examination

If a medical provider is examining an infant or a child during the standard physical examination for annual well child care or for medical complaints necessitating an external genital examination, assent of the child should be obtained and documented together with the consent from the parent or legal guardian, who may remain in the room throughout the examination. If the evaluation is for an adolescent female

presenting for a confidential visit, she may provide consent for an external genital examination without parental involvement. Whenever feasible, gender concordance should be optimized between the patient and health provider and all genital examinations should be chaperoned by a medical staff (regardless of gender).

If the evaluation is part of formal investigation, assent should be obtained from the girl (if age-appropriate) and consent from the legal guardian/parent before the examination (see chapter “Consent and Photography”). Written consent should be obtained for any photographic or video images or recordings taken during the examination (DVD, for example). Assent should be obtained in an ongoing fashion throughout the examination, especially before conducting the genital examination. The extent of the physical examination will depend on the age of the girl and her understanding of the examination. Young girls may be told that they are about to have a general “check-up.” After height, weight, an examination of ears, heart, or lungs may precede the genital inspection to help lessen anxiety and normalize the process. Older girls usually have a better understanding of why an examination is needed/being carried out. Genital examination of children for FGM/C should be performed as gently and as speedily as possible in a sensitive age-appropriate manner. A critical part of a trauma-informed and survivor-centered approach is to create a safe environment for the child, clearly describe the purpose of the evaluation, and provide a description of every step of the physical examination. The patient must be reassured that she may pause or even stop the evaluation at any time. In situations where the patient may decline an examination despite counseling, it is advised to create safe spaces; use open bidirectional dialog; reduce stigma; further delineate critical steps that can be taken to facilitate trust-building; guarantee continuity of follow-up care and referral for psychological counseling if appropriate [14, 18].

An internal vaginal examination is almost never required for the assessment of FGM/C, and this should be made clear to the girl and her family from the outset. Full disrobing and undressing is not required and could be traumatizing. In many circumstances pulling one leg out of the knickers [underpants] will permit sufficient exposure and may be more acceptable to some girls and families.

The child may be examined in the frog-legged or in the knee-chest position (Fig. 3.1 of chapter “Pictures Without FGM/C and Without Lesions”). A younger girl can have the nappy [diaper] changed or sit on her parent/guardian/caregiver’s lap.

The genitalia are inspected with gentle labial traction in order to expose the skin folds (Fig. 3.2 of chapter “Pictures Without FGM/C and Without Lesions”). If the girl is able to cooperate, the examiner’s gloved thumbs may be placed on the inner face of the outer labia and gentle traction applied laterally and downwards to reveal the inter labial sulcus and the clitoral eminence [26].

Where available, a colposcope is recommended for adequate lighting and magnification. With specific consent, colposcopic images may be recorded which can be later peer-reviewed when seeking an expert opinion. In addition, in the case of legal proceedings photo documentation of FGM/C is highly recommended but should be obtained without coercion and only with full informed consent of the legal guardian and the child, when appropriate. Images must be labeled and stored, as part of the medical file in a secure platform, as for all storage of intimate images and personal health information as is required for all. Adolescent girls with FGM/C may choose

to watch the colposcopic video screen during the examination, which can be educational and informative and allow for a neutral and open exchange about the genitalia and findings. If video visualization is not available, the adolescent may also be offered a hand mirror in order to demonstrate and explain the findings.

A diagram or photograph with labels should be used to indicate any identified anatomical changes (Fig. 3.5 of chapter “Pictures Without FGM/C and Without Lesions”). The WHO classification may be used to describe the type of FGM/C [4].

HCPs and patients must be aware that FGM/C does not always leave physical traces and that the crura, part of the body of clitoris, and the vestibular bulbs are never removed during FGM/C.

It is assumed by some that FGM/C is easily detected on genital inspection but often this is not true. While Type III FGM/C is easily noted, other types of FGM/C are more difficult to diagnose with confidence. This is particularly true for Type IV FGM/C which may comprise only a prick or a small scratch on (or adjacent to) the clitoral glans or hood. This may heal completely leaving either no scar or a small scar, either of which is difficult to detect upon visual inspection, especially if the examination takes place months to years after the procedure has happened. Thus, a normal genital examination cannot exclude Type IV FGM/C. In this situation, the diagnosis will be based on the girl’s or parents’ history. Examiners must also be familiar with the differences between a pre and postpubertal vulva. The inner labia are underdeveloped prior to pubertal hormonal changes and this must not be mistaken for removed labia. Labial adhesions following inflammatory processes, hypoes-trogenic state, lichen sclerosus, or other vulvar dermatoses can be confused with infibulation. Small irregularities in the skin of the vulva or clitoris can simply be a result of anatomical variation. In addition, examiners must realize that it is impossible to deduce a timeline for an FGM/C procedure based on physical evidence (unless acute) and criminal investigators’ requests for such a timeline should be rejected.

Once the examination is completed, the findings should be discussed with the family and the girl, taking into account the context, confidentiality rules, local laws, and resources. Depending on the situation and the country, some findings might also be discussed with social service providers (i.e., child protective services), forensic examiners, and lawyers with consent/assent by the patient and parent/guardian (i.e., during asylum-seeking procedures or crime investigations). It is best to provide expert assessments and conclusions only in the specific field in which you are trained, experienced, and have expertise for which, regular updates of the sociocultural context and processes of cultural change take place. The process of clinical judgment should be aided by obtaining or by asking for a second opinion in when there are doubtful or equivocal findings; and, when possible, working within a multispecialty/cross-sectoral team is recommended.

It is also necessary to use data, clinical history, and examination findings when evaluating possible future long-term health consequences related to FGM/C to assure that the findings are based on evidence [27].

When age, developmental stage, and level of understanding are appropriate, it is recommended that FGM/C is explained to the girl, including possible consequences to her future health. These explanations should be conveyed in a clear, sensitive and honest manner depending on her age, developmental stage, and her level of

understanding. Diagrams of both FGM/C affected and uncut female genitalia are useful tools when explaining the clinical findings in detail. Audiovisual and/or verbal information, in a language the family is familiar with and providing information about community support organizations are helpful if the family and the girl are literate in a given language. For preliterate families, it is recommended to provide detailed explanations, the provision of information, diagrams, and to also link girls and families to community support organizations, as desired.

A community approach to prevention is key, as some families may not know that FGM/C is illegal in their country of residence [28].

## **1.5 When FGM/C Is Confirmed**

### ***1.5.1 Clinical Management***

If FGM/C is confirmed, testing for blood-borne viruses (BBV) including Hepatitis B and C and HIV should be considered, though data is limited on actual transmission rates. Other tests will depend on clinical findings and history. If the child has urinary symptoms, a midstream specimen of urine for urinalysis, culture, and sensitivity may be indicated. The most common symptoms in children attributed to Type III FGM/C are urinary and some symptomatic I/C/YP may require de-infibulation [23, 29]. However, only 10–15% of FGM/C cases are classified as Type III, therefore most girls with FGM/C will not need de-infibulation [2, 30].

De-infibulation is generally a same-day procedure, often in a pediatric surgical unit and using brief general anesthetic or intravenous sedation. For those who have experienced Type III FGM/C and are asymptomatic, the timing of de-infibulation must be discussed with the girl and her guardian(s). Girls aged 16 years or older may be suitable for an outpatient/day surgery procedure and can be offered this option [6]. Older girls with Type III FGM/C who are asymptomatic often choose to defer de-infibulation until they are ready to consider sexual intercourse. In this case, contact details of the available adult services should be made available to them. Not all adolescent females want their families to know when or if they choose to undergo de-infibulation. Because de-infibulation is an outpatient procedure for older adolescents and adults, in some countries, it can be done without informing the family, though familiarity with local legal codes is recommended. In other countries, child protective services may need to be involved in order to obtain legal consent to proceed [11]. A common fear related to de-infibulation is the loss of premarital virginity [6], often based on a husband's expectation that he will be married to a wife with some type of FGM/C who has not had any partnered sexual experience (especially involving vaginal penetration). Comprehensive information should be given on the nature of the procedure, expressing clearly that the procedure does not involve the hymen or penetration into the vaginal canal and that de-infibulation alone has no bearing whatsoever on whether one has had partnered sexual activity, whatever the symbolic significance of that fact may be in the relevant culture [6].

Other types of FGM/C with complications, such as painful or inflamed vulvar epidermal cysts, scarring, or adhesions, do not always need surgical treatment. There is no conclusive evidence as to the benefit of clitoral reconstruction/re-exposure surgery in adult women with FGM/C and there is no evidence of benefits or risks/harms of clitoral surgery performed before sexual debut [16, 25]. We believe that clitoral reconstruction should never be performed on minors.

For most girls living in a high-income country with access to full medical care who do not have Type III FGM/C, the potential morbidity and mortality associated with future pregnancy and childbirth will not be substantially different from that faced by their peers who have not undergone genital modification, with the possible exception (depending on the type of FGM/C) of a higher risk for perineal tears and episiotomy [31].

The psychological impact on a child of having their genitalia cut is difficult to study scientifically (i.e., isolating causes due to the cutting as opposed to other factors), and there is little to no good-quality evidence to support generalizations in this area [32, 33]. Nevertheless, a wide range of outcomes are possible, depending on the type and timing of the cutting (and hence the age or maturity of the child); how it was carried out and the context in which it was performed; what the child's beliefs, attitudes, or expectations were toward the cutting before, during, and after; and how the cutting is framed or interpreted in the child's community [34]. Some children, for example, may feel proud of having been included in an ancestral tradition, or having fulfilled a culturally significant initiation rite along with others in their peer group; others, by contrast, may experience the cutting as traumatic, violent, involuntary, and/or an infringement on their sexual and bodily integrity, with severely negative consequences (e.g., flashbacks and nightmares have been reported [29]). Again, it is important not to cause iatrogenic harm by assuming that the child feels traumatized or by making the child feel like a victim if that is not how they interpret the cutting themselves. Input from a child psychologist or psychotherapist experienced in working with children with FGM/C and their families should be sought, but may not be available in all settings [16, 33, 35, 36].

### ***1.5.2 Legal Proceedings***

If FGM/C is confirmed, an evaluation by legal authorities and child protective social service agencies might be ongoing to determine the legality of the procedure and the potential criminal charges (e.g., if there is evidence that the child was taken abroad to undergo FGM/C). FGM/C is illegal in most countries although the details and implementation of the legislation can vary [37]. If FGM/C was performed before the child entered the country where the examination is taking place, then criminal proceedings will generally not follow. There are sometimes exceptions to this; in a 2018 Swiss case, a mother was charged for having her two daughters cut in Somalia before leaving for Europe [38]. This legal decision was criticized as judicial overreach by both the Swiss Network against Female Circumcision and the Swiss Human Rights Institutions [39].



### ***1.5.3 Medical Confirmation in the Framework of an Asylum Claim***

FGM/C is considered a form of violence against women and girls and is a violation of human rights law: as such, FGM/C or risk of future FGM/C can serve as a basis for asylum in many receiving countries and can be used as the right to protection per the Geneva Convention [40, 41]. Some families who flee their countries, in part to seek protection for their daughters, can be asked to provide proof (via medical certificates) that the mother has undergone FGM/C and her daughter(s) have not and are therefore at risk of undergoing the procedure if forced to return to their country of origin.

Providing a certificate or affidavit attesting to the presence or absence of FGM/C should be seen as an opportunity to discuss the topic of FGM/C with the girl and her mother, and her father, to screen for potential, current, or eventual complications and to offer treatment, if necessary. Also, it is an opportunity to convey information on health and to raise awareness about other important issues such as hygiene, pubertal development, and sexual health. Adolescents may have questions about their menstruation or first sexual contact. Many children do not know why they left their country (if FGM/C is the main reason), so the conversation can serve to explain the reason for family migration, to raise awareness about the practice of FGM/C, including potential medical and legal complications and risks, and to convey preventive measures. It is also an opportunity to reassure the I/C/YP about their health, specifically around the appearance of their external genitalia to help them not to feel embarrassed about their vulva and to answer any questions that may arise. The certificate should include the medical history of the girl together with a detailed description of the genitalia, the FGM/C type and subtype according to WHO classification.

## **1.6 When FGM/C Is Not Identified**

It is important to understand that in countries where there are laws dictating examination of girls from countries where FGM/C is practiced, a significant proportion of children referred with suspected FGM/C will have no evidence of FGM/C [17]. These children fall into two groups;

- *No physical evidence of FGM/C but risk factors for FGM/C are present.*

Children may be referred because FGM/C is diagnosed in an older sibling (often performed before entry to a high-income country) or in another close family member. The clinical visit can provide an ideal opportunity for health and preventive information. Information and ongoing support can also be provided by connecting families to local peer support groups, if available.

An authoritative source of information, a risk assessment tool, and a “preventive compromise” (a document provided before traveling to the native country in which parents corroborate to prohibit their daughter from undergoing FGM/C and that can be shown to other family members) can be found in some countries such as Belgium and Spain [42, 43].

- *No physical evidence of FGM/C and no risk factors for FGM/C are present.*  
In countries where there are laws dictating examination of I/C/YP from countries where FGM/C is practiced, many referrals for suspected FGM/C are appropriate. In contrast, some are referred inappropriately, which can include anonymous and malicious referrals, or referrals based simply on racial profiling [44]. Referrals may come from a nursery (daycare) or other childcare workers who notice an apparent abnormality when changing the child's nappy (diaper) and immediately attribute this to FGM/C because of the ethnicity or migration status of the child. Genital anomalies may be due to anatomical or congenital variations or due to common conditions such as labial adhesions or lichen sclerosus (Fig. 3.8 of chapter "Pictures with Potential Differential Diagnosis of FGM/C"). In addition, HCPs with inadequate training on FGM/C diagnosis and some caretakers may refer children from communities that generally do not practice FGM/C and thus have no known risk of FGM/C. These referrals may lead to significant psychological stress and stigma for families. The long-term impact of such referrals is unknown. Fear, shame, inadequacy, stigma, and resentment after an inappropriate referral may impact individuals, families, and entire communities, with potentially multiple negative social consequences [45].

### ***1.6.1 The Need for Cultural Sensitivity and Risks of Stigmatization***

In all cases where I/C/YP have their external genitalia examined, whether at annual physical examinations, medical asylum examinations, if there are genitourinary complaints, or if residing in a country where the law dictates such examinations to occur in at-risk I/C/YP, it is essential to acknowledge the possibility of causing fear and stigmatization in the child, her family, and/or the larger community. Such examinations should not be undertaken without the acknowledgment that if only performed on subpopulations with risk factors for FGM/C, this stigmatization will more likely occur. As such, and given that there are many physical findings that may be identified on routine examination of the external genitalia at annual physical examinations, it is recommended that external physical examination of the external genitalia be incorporated into well child visits of all girls.

## **1.7 Conclusion**

An external genital inspection is an essential component of the assessment of all I/C/YP, including those with suspected FGM/C. Examining children with suspected FGM/C may be a requirement in some countries for medical-legal reasons and can be performed by designated specialists. The signs of FGM/C can be very subtle and

the examiner must be trained to identify a wide range of normal pre and postpubertal genitalia (both “cut” and unmodified) and must be familiar with the WHO definitions of FGM/C types and subtypes. Examiners must be familiar with the complications of the procedure and the differential diagnosis associated with the clinical findings. The relatively small number of girls affected by FGM/C in high-income countries presenting for medical evaluation can make it difficult for clinicians to develop adequate skills and competencies and to gain expertise. The adoption of routine pediatric genital examination of girls at well-child visits would help to develop general experience and expertise in identifying unaltered prepubertal and pubertal external genitalia, variations in findings, and clinical diagnoses of significance. Expert review and second opinion services can support learning and enhance the accuracy of the evaluation and determination of the findings. We hope this atlas will enhance HCP confidence in identifying and diagnosing FGM/C types and subtypes in children and adolescents.

**Open Access** This chapter is licensed under the terms of the Creative Commons Attribution 4.0 International License (<http://creativecommons.org/licenses/by/4.0/>), which permits use, sharing, adaptation, distribution and reproduction in any medium or format, as long as you give appropriate credit to the original author(s) and the source, provide a link to the Creative Commons license and indicate if changes were made.

The images or other third party material in this chapter are included in the chapter's Creative Commons license, unless indicated otherwise in a credit line to the material. If material is not included in the chapter's Creative Commons license and your intended use is not permitted by statutory regulation or exceeds the permitted use, you will need to obtain permission directly from the copyright holder.



## Chapter 2

# Consent and Photography



**Jasmine Abdulcadir, Noémie Sachs Guedj, Michal Yaron, Omar Abdulcadir, Juliet Albert, Martin Caillet, Lucrezia Catania, Sarah M. Creighton, Céline Deguette, Elise Dubuc, Brian D. Earp, Birgitta Essén, Deborah Hodes, Adriana Kaplan Marcusan, Ranit Mishori, Deborah Ottenheimer, Fabienne Richard, Aida Sy, Moustapha Touré, Amelia Valladolid, Anneke Vercoutere, Bilkis Vissandjée, and Janine Young**

---

J. Abdulcadir (✉) · N. S. Guedj · M. Yaron  
Department of Pediatrics, Gynecology and Obstetrics, Geneva University Hospitals,  
Geneva, Switzerland  
e-mail: [jasmine.abdulcadir@hcuge.ch](mailto:jasmine.abdulcadir@hcuge.ch); [michal.yaron@hcuge.ch](mailto:michal.yaron@hcuge.ch)

O. Abdulcadir · L. Catania  
Referral Center for Curing and Preventing FGM. AOUC, Florence, Italy

J. Albert  
Imperial College Healthcare, NHS Trust, London, UK  
e-mail: [juliet.albert@nhs.net](mailto:juliet.albert@nhs.net)

M. Caillet  
CHU Saint-Pierre, Brussels, Belgium  
e-mail: [martin\\_caillet@stpierre-bru.be](mailto:martin_caillet@stpierre-bru.be)

S. M. Creighton · D. Hodes  
University College London Hospital, London, UK  
e-mail: [sarah.creighton2@nhs.net](mailto:sarah.creighton2@nhs.net); [deborah.hodes@nhs.net](mailto:deborah.hodes@nhs.net)

C. Deguette  
Department of Forensic Medicine, AP-HP. Centre-University of Paris, Paris, France  
e-mail: [celine.deguette@aphp.fr](mailto:celine.deguette@aphp.fr)

E. Dubuc  
CHU Sainte-Justine, Montréal, QC, Canada  
e-mail: [elise.dubuc.1@umontreal.ca](mailto:elise.dubuc.1@umontreal.ca)

B. D. Earp  
Departments of Philosophy and Psychology, Yale University, New Haven, CT, USA  
e-mail: [brian.earp@yale.edu](mailto:brian.earp@yale.edu)

B. Essén  
Women's and Children's Health/IMCH, WHO Collaborating Centre on Migration and Health,  
Uppsala University, Uppsala, Sweden  
e-mail: [brigitta.essen@kbh.uu.se](mailto:brigitta.essen@kbh.uu.se)

A. K. Marcusan  
Department of Social and Cultural Anthropology, UAB, Barcelona, Spain  
e-mail: [adriana.kaplan@uab.cat](mailto:adriana.kaplan@uab.cat)

R. Mishori  
Georgetown University Department of Family Medicine, and Physicians for Human Rights,  
Washington, DC, USA  
e-mail: [mishorir@georgetown.edu](mailto:mishorir@georgetown.edu)

D. Ottenheimer  
Morrisania Diagnostic and Treatment Center, Bronx, NY, USA  
e-mail: [deb@ottenheimerhealth.com](mailto:deb@ottenheimerhealth.com)

F. Richard  
GAMS Belgique, Brussels, Belgium  
Ecole de santé publique, Université Libre de Bruxelles, Brussels, Belgium  
e-mail: [fabienne@gams.be](mailto:fabienne@gams.be)

A. Sy  
Bamako, Mali

M. Touré  
Malian Society of Gynecology and Obstetrics, Bamako, Mali

A. Valladolid  
Universidad del Pais Vasco, Vizcaya, Spain

A. Vercoutere  
Community and Health Project in Guinea Conakry, Conakry, Guinea  
Hôpital Erasme, University Hospital ULB, Brussels, Belgium  
e-mail: [An.Vercoutere@erasme.ulb.ac.be](mailto:An.Vercoutere@erasme.ulb.ac.be)

B. Vissandjée  
Université de Montreal, Montreal, Quebec, Canada  
e-mail: [bilkis.vissandjee@umontreal.ca](mailto:bilkis.vissandjee@umontreal.ca)

J. Young  
Department of Pediatrics, Denver Health and Hospitals, University of Colorado School of  
Medicine, Denver, CO, USA  
e-mail: [janine.young@dhha.org](mailto:janine.young@dhha.org)

## 2.1 Informed Consent

Informed consent is essential to ensure a trauma-informed, survivor-centered, ethical process that respects the (developing) autonomy of a patient.

If a patient does not (yet) have the developmental capacity to provide their own informed consent (i.e., is not sufficiently autonomous in the relevant sense), but is able to understand the basic ideas about what is being proposed, they should be involved in the decision-making process as much as possible and their “assent” should be obtained, along with the proxy consent of their parents or caretaker(s) (also known as parental permission). It is especially important to engage the patient and/or parents/caretaker(s) in an informed consent process when taking clinical or forensic photographs of sensitive body parts such as the genitalia. Even when informed consent is given by a parent or legal guardian, the clinician should obtain assent from the patient herself throughout the encounter.

Informed consent and assent apply to interviewing, carrying out a medical examination, taking photographs of the physical findings, and the dissemination of information and photos obtained at the visit to third parties (police, legal system, photo atlas, medical books, articles, or case reports).

- You must gather informed assent/consent and confirm the patient is still in agreement, before handling the camera in front of the patient and taking photographs.
- You must ensure that the patient fully understands the benefits and risks of photographing or any other action before they sign the consent form.
- A patient (or a legal guardian in the case of a minor) has the right to refuse any action, at any time, even if he or she has previously consented to the actions. Make sure that the patient understands that refusing to be photographed will not affect their access to medical care or the legal process.
- If you plan on taking photographs while the patient is under anesthesia, informed consent must be obtained before the patient is sedated.
- You must explain that genital photographs will be used for medical education purposes and may be seen by many health professionals. As such, they are not going to be strictly confidential, though you will make sure no identifying information will be included.

## 2.2 Trauma-Informed Care

It is critical to take a trauma-informed approach to the history, physical examination, and photography of individuals with FGM/C. Trauma-informed care is an approach that assumes the person in front of you may have experienced trauma. Its principles emphasize establishing trust, ensuring safety, and yielding control to the patient, while striving to minimize discomfort, potential re-traumatization, and shame. This is particularly important in the context of performing a genital examination and photographing the genitalia of a child, which may elicit strong emotional reactions. A critical part of creating a safe environment for the patient is to clearly describe the purpose of the evaluation and photography, provide a concrete description of each step of the encounter, and reassure the child that she may pause or even stop the evaluation/photography at any time.

Photography is not the essential component of the exam and no pressure should be exerted on the patient or the family [47–52].

## 2.3 Photography: Technical Tips

- Lighting can be critical to the appearance of some injuries/lesions. Bring in natural light if possible; if not, make sure the light source is not directly aimed at the lesion/area you want to photograph. The presence of bright lights or reflective surfaces can produce a washout of the detail (overexposure) and the injury or lesion will become less visible.
- Darker skin reflects more light which can lead to overexposure. Often automatic settings on cameras do not account for this. Manual adjustment for flash and exposure may be needed.

- Angled lighting reveals a higher level of detail than frontal lighting. A light source aimed at 45° angle to the lesion is considered the closest to natural lighting.
- Consider using a ruler, or some other object of standard size (like a coin) to show the size of the anatomy or scars and to provide a scale of reference.
- Take three photographs: a close-up, a medium-distance photo, and another showing the relationship to the rest of the perineum/genitalia/vulva.
- If you are using a phone or tablet to take pictures, always use horizontal shooting.
- Stabilize the device by holding it with both hands. You may need to have a nursing assistant help with the separation of the labia to allow for a full view of the area you wish to photograph. In some cases, it is ok to ask the patient if she is willing to assist.
- Regularly clean the screen and lens BEFORE taking photographs.
- Once the photographs have been taken and transmitted to an appropriate/secure source, DELETE them from your phone, tablet, or camera.

### Appendix: Standardized Form Used at University College London Hospitals as an Example [10]

**Date of Appointment** \_\_\_\_\_

**Child’s Personal Details:**

Name: \_\_\_\_\_

Hospital Number:.....NHS Number:.....

Date of Birth.....

**Who is present at appointment**

*UCLH Clinical staff present at appointment (please circle):*

Other UCLH staff (specify names).....

*Other professionals present at appointment (give name)*

Social Worker \_\_\_\_\_

Police \_\_\_\_\_

Interpreter \_\_\_\_\_

Advocate \_\_\_\_\_

Other \_\_\_\_\_

*Child accompanied by (give name):*

Parent \_\_\_\_\_

Foster Carer \_\_\_\_\_

Sibling \_\_\_\_\_

Other \_\_\_\_\_

**Details of Referral:**

Child referred by.....

Date FGM concern first raised and by whom.....

Date of referral letter.....

Date of appointment at UCLH.....

**Reason for Referral:**

FGM already confirmed on examination in child.....

History of FGM given by child.....

History of FGM in child given by parent

Family member of index case.....

Child may be at risk of FGM.....

Other (specify).....

**FGM History;** Taken from (please circle)

Child Parent Police Social Worker

Other (specify).....

Describe concerns and why referral requested

.....  
.....  
.....  
.....



**Child Medical History**

(History taken from.....)

Country of birth            Date of entry to UK

Ethnicity.....            Religion.....

Birth history including weight.....

Development.....

Special Needs.....

General medical history:

Past medical history

    Operations.....

    Medications.....

Previous genital operations (including labiaplasty)    Yes/No

    If yes, specify.....

Genital Piercings Yes/No

    If yes, specify

Immunisations.....    Allergies.....

**Systems review** (Circle symptoms)

Urinary symptoms Yes/No

    Frequency

    Bed wetting

    Daytime Incontinence

    Recurrent urinary infections

Vulval/vaginal

    Vulval irritation (including nappy rash)

    Vaginal discharge

    Vaginal bleeding (not menstruation)

    Vaginal pain

Gastrointestinal symptoms

    Constipation

    Diarrhoea

    Abdominal pain

Gynaecological history

    Periods Yes/No

    Menarche

    Tampons Yes/No

    Sexually active Yes/No/Unknown

    Contraception.....

    Previous pregnancies.....

**Child Mental Health History**

Under CAMHs Yes/No

If yes—specify why.....

Symptoms (circle)

    Poor appetite

- Poor sleep
- Flashbacks/nightmares
- Self harm
- Suicide attempts
- Mood changes
- Drugs/Alcohol
- Other.....

**History of alleged FGM: Parents Deny**

Parents Deny FGM    Yes    No

Age of FGM.....

Country.....

Where (circle)

- clinic/hospital/home/religious place
- other .....

Who by

- Doctor
- Nurse/midwife
- Other health professional
- Traditional practitioner
- Other

Who organised is (specify).....

Index child alone or group procedures.....

If group, who else.....

Anaesthetic.....

Antiseptic (cleaning).....

Antibiotics.....

How performed?

- Knife/scissors/other

Does the child remember it? Yes/No

Complications after

- Pain/Bleeding/Infection
- Other .....

**Family History of FGM**

Mother    Yes/No

Siblings    Yes/No    If yes, specify.....

Maternal Grandmother    Yes/No

Paternal Grandmother    Yes/No

Other family members, specify.....

**Family**

Address

Phone number

Family composition.....

Parents	Name	Age	Occupation	Country of birth	Year entered UK
Birth Mother					
Birth Father					
Other adult at same address					
Children at same address					

**Previous Child Protection Concerns Yes/No**

If yes, specify.....

**Family Medical History**

Significant medical condition.....

Drugs/alcohol.....

Significant mental health condition.....

Domestic Violence.....

**Medical Examination**

Clinicians present

Others present.....

Consent given for DVD recording      Yes/No

Interaction of child with carer.....

Demeanour of child.....

Clothes.....

Hygiene.....

Position for genital examination.....

**General Examination**

Cardiovascular.....

Respiratory.....

Abdominal.....

Skin (e.g. scars).....

Puberty Stage.....

Other significant findings.....

**Genital Examination**

**Clitoris**

Present/absent

Glans clitoris    Present/absent    Can't tell

Body of clitoris    Present/absent    Can't tell

Clitoral hood    Present/absent    Can't tell

Scarring Yes/no

If clitoris scarred, describe.....

**Inner Labia**

Present/absent  
 Normal/abnormal  
 Symmetrical/asymmetrical  
 Scarring Yes/No  
 If inner labia scarred, describe.....

**Outer Labia**

Present/absent  
 Normal/abnormal  
 Symmetrical/asymmetrical  
 Scarring Yes/No  
 If outer labia scarred, describe.....

**Vaginal Introitus**

Normal/abnormal  
 If abnormal, describe.....

**Other findings**

Piercing  
 Scarring

**Physical evidence of FGM Yes/No**

If yes Type of FGM.....  
 Forensic Samples Taken Yes/No  
 Testing for BBV Yes/No

**Diagram of Findings**

**Management Summary**

FGM confirmed on from clinical history Yes/No  
 FGM confirmed on physical examination Yes/No  
 Investigations;  
 BBV Yes/No  
 Other (specify).....

**Clinical Judgement**

FGM Yes/No  
 Type of FGM.....

**If FGM Confirmed**

Action	Date	Who to do
1. Social services referral		
2. Mandatory reporting to police		
3. Completion of DH enhanced dataset		
4. Medical report dictated		
5. Referral to another health professional		
6. Copied to police because of criminal investigation		

**Medical or Surgical Complications requiring referral Yes/No**

If yes, specify.....

If yes, who referred to.....

**Discharged from FGM Clinic Yes/No**

**Open Access** This chapter is licensed under the terms of the Creative Commons Attribution 4.0 International License (<http://creativecommons.org/licenses/by/4.0/>), which permits use, sharing, adaptation, distribution and reproduction in any medium or format, as long as you give appropriate credit to the original author(s) and the source, provide a link to the Creative Commons license and indicate if changes were made.

The images or other third party material in this chapter are included in the chapter's Creative Commons license, unless indicated otherwise in a credit line to the material. If material is not included in the chapter's Creative Commons license and your intended use is not permitted by statutory regulation or exceeds the permitted use, you will need to obtain permission directly from the copyright holder.



**Part II**  
**Iconography for Female External Genitals**  
**of Children with and Without FGM/C**

# Chapter 3

## Pictures Without FGM/C



**Jasmine Abdulcadir, Noémie Sachs Guedj, Michal Yaron, Omar Abdulcadir, Juliet Albert, Martin Caillet, Lucrezia Catania, Sarah M. Creighton, Céline Deguette, Elise Dubuc, Brian D. Earp, Birgitta Essén, Deborah Hodes, Adriana Kaplan Marcusan, Ranit Mishori, Deborah Ottenheimer, Fabienne Richard, Aida Sy, Moustapha Touré, Amelia Valladolid, Anneke Vercoutere, Bilkis Vissandjée, and Janine Young**

---

J. Abdulcadir (✉) · N. S. Guedj · M. Yaron  
Department of Pediatrics, Gynecology and Obstetrics, Geneva University Hospitals,  
Geneva, Switzerland  
e-mail: [jasmine.abdulcadir@hcuge.ch](mailto:jasmine.abdulcadir@hcuge.ch); [michal.yaron@hcuge.ch](mailto:michal.yaron@hcuge.ch)

O. Abdulcadir · L. Catania  
Referral Center for Curing and Preventing FGM. AOUC, Florence, Italy

J. Albert  
Imperial College Healthcare, NHS Trust, London, UK  
e-mail: [juliet.albert@nhs.net](mailto:juliet.albert@nhs.net)

M. Caillet  
CHU Saint-Pierre, Brussels, Belgium  
e-mail: [martin\\_caillet@stpierre-bru.be](mailto:martin_caillet@stpierre-bru.be)

S. M. Creighton · D. Hodes  
University College London Hospital, London, UK  
e-mail: [sarah.creighton2@nhs.net](mailto:sarah.creighton2@nhs.net); [deborah.hodes@nhs.net](mailto:deborah.hodes@nhs.net)

C. Deguette  
Department of Forensic Medicine, AP-HP. Centre-University of Paris, Paris, France  
e-mail: [celine.deguette@aphp.fr](mailto:celine.deguette@aphp.fr)

E. Dubuc  
CHU Sainte-Justine, Montréal, QC, Canada  
e-mail: [elise.dubuc.1@umontreal.ca](mailto:elise.dubuc.1@umontreal.ca)

B. D. Earp  
Departments of Philosophy and Psychology, Yale University, New Haven, CT, USA  
e-mail: [brian.earp@yale.edu](mailto:brian.earp@yale.edu)

B. Essén  
Women's and Children's Health/IMCH, WHO Collaborating Centre on Migration and Health,  
Uppsala University, Uppsala, Sweden  
e-mail: [brigitta.essen@kbh.uu.se](mailto:brigitta.essen@kbh.uu.se)

A. K. Marcusan  
Department of Social and Cultural Anthropology, UAB, Barcelona, Spain  
e-mail: [adriana.kaplan@uab.cat](mailto:adriana.kaplan@uab.cat)

R. Mishori

Georgetown University Department of Family Medicine, and Physicians for Human Rights,  
Washington, DC, USA

e-mail: [mishorir@georgetown.edu](mailto:mishorir@georgetown.edu)

D. Ottenheimer

Morrisania Diagnostic and Treatment Center, Bronx, NY, USA

e-mail: [deb@ottenheimerhealth.com](mailto:deb@ottenheimerhealth.com)

F. Richard

GAMS Belgique, Brussels, Belgium

Ecole de santé publique, Université Libre de Bruxelles, Brussels, Belgium

e-mail: [fabienne@gams.be](mailto:fabienne@gams.be)

A. Sy

Bamako, Mali

M. Touré

Malian Society of Gynecology and Obstetrics, Bamako, Mali

A. Valladolid

Universidad del Pais Vasco, Vizcaya, Spain

A. Vercoutere

Community and Health Project in Guinea Conakry, Conakry, Guinea

Hôpital Erasme, University Hospital ULB, Brussels, Belgium

e-mail: [An.Vercoutere@erasme.ulb.ac.be](mailto:An.Vercoutere@erasme.ulb.ac.be)

B. Vissandjée

Université de Montreal, Montreal, Quebec, Canada

e-mail: [bilkis.vissandjee@umontreal.ca](mailto:bilkis.vissandjee@umontreal.ca)

J. Young

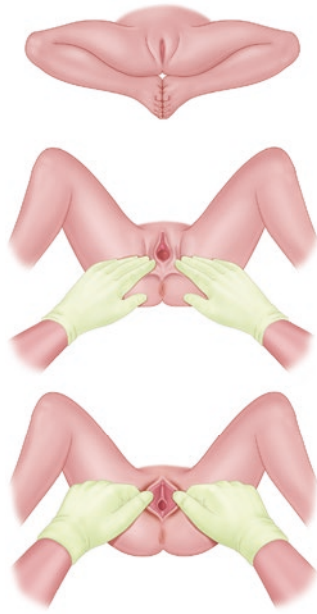
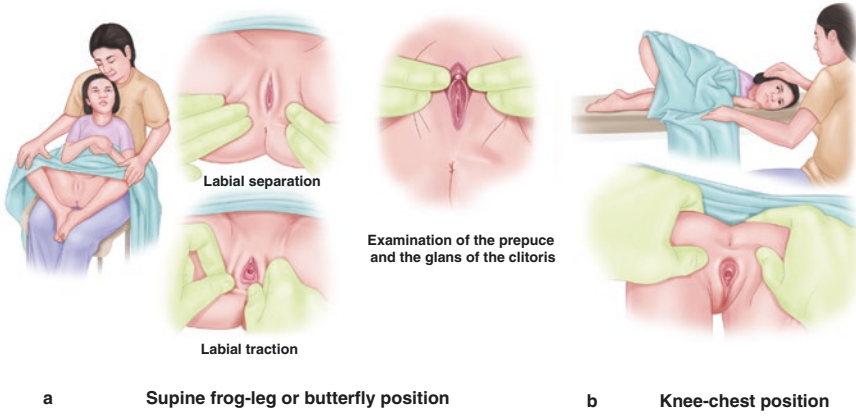
Department of Pediatrics, Denver Health and Hospitals, University of Colorado School of  
Medicine, Denver, CO, USA

e-mail: [janine.young@dhha.org](mailto:janine.young@dhha.org)

Pictures without FGM/C and without lesions. This chapter will help the physician:

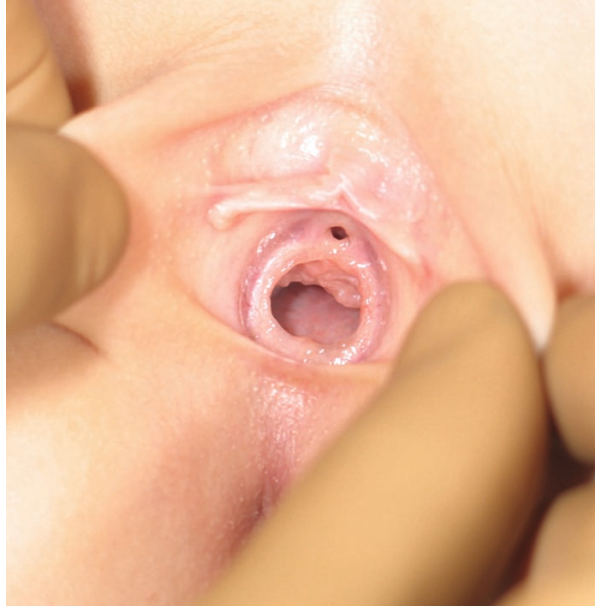- To make a vulvar examination (Figs. 3.1 and 3.2)
- To provide a referential for surgeons undertaking procedures (Figs. 3.3, 3.4, and 3.5)
- To recognize anatomical variations (Figs. 3.6, 3.7, 3.8, 3.9, 3.10, and 3.11).
- To identify “ambiguous” genitals or mucocolpos (Figs. 3.12 and 3.13)





**Fig. 3.1** Prepubertal vulvar examination (a) In supine frog-leg or butterfly position. (b) In knee-chest position [1]

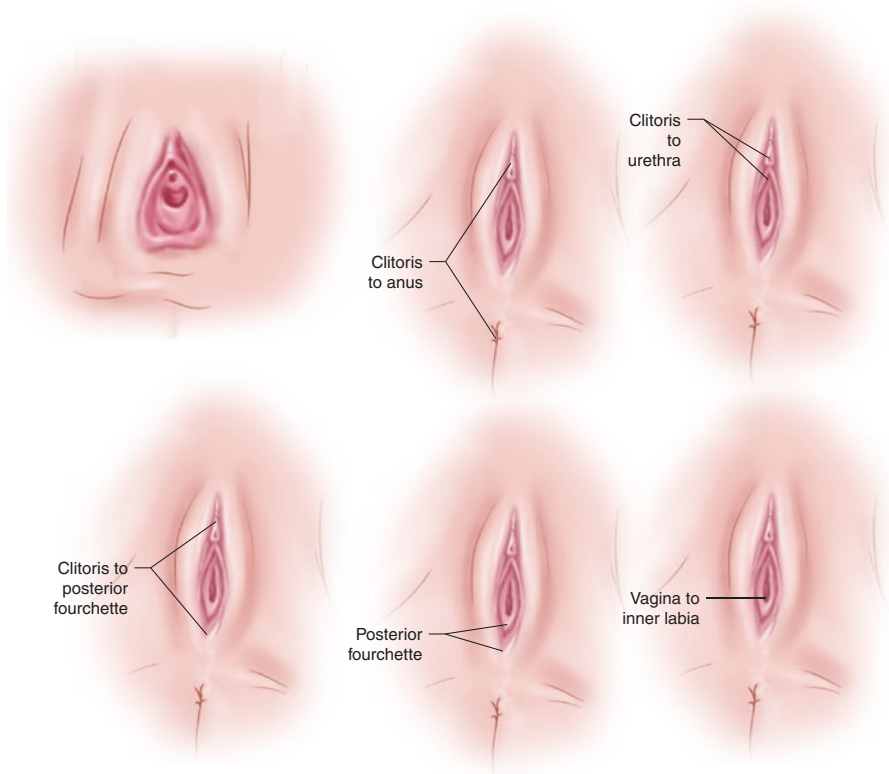
**Fig. 3.2** Prepubertal examination. (Courtesy of Elise Dubuc)



- To identify dermatological conditions (Figs. 3.14, 3.15, 3.16, 3.17, 3.18, 3.19, and 3.20)
- To identify urethral lesions (Figs. 3.21 and 3.22)
- To identify genital trauma (Fig. 3.1 of chapter “Pictures with Potential Differential Diagnosis of FGM/C”)
- To make differential diagnosis of FGM/C (Figs. 3.2, 3.3, 3.4, 3.5, 3.6, 3.7, 3.8, 3.9, 3.10, 3.11 of chapter “Pictures with Potential Differential Diagnosis of FGM/C”, and Fig. 3.1 of chapter “Pictures with FGM/C”)

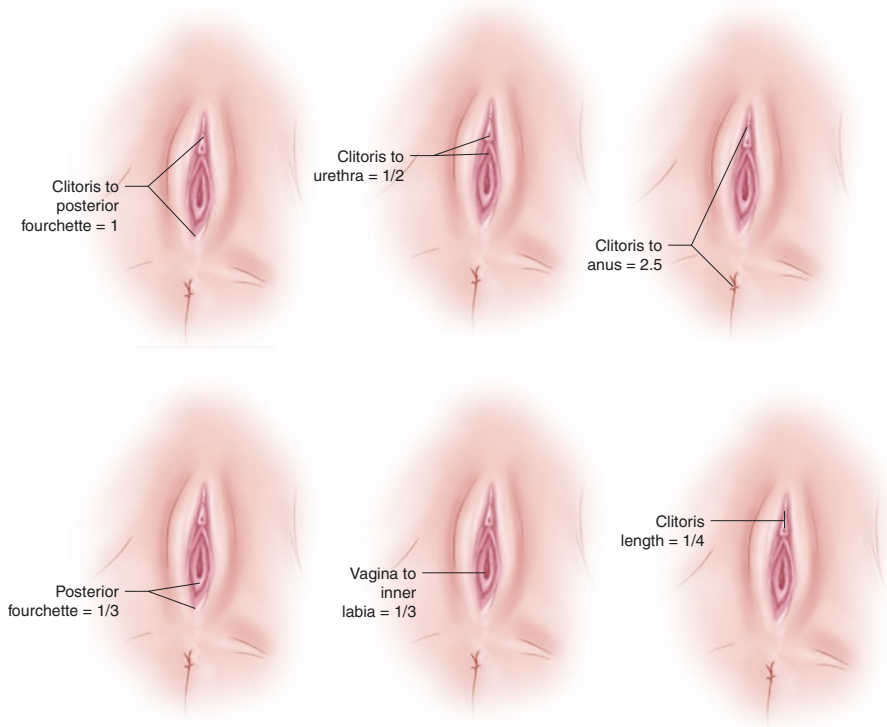
### 3.1 Vulvar examination

Figures 3.3, 3.4, and 3.5 provide a reference for surgeons undertaking genital surgical repair procedures. The clitoral hood and inner labia are anatomically distinct structures.

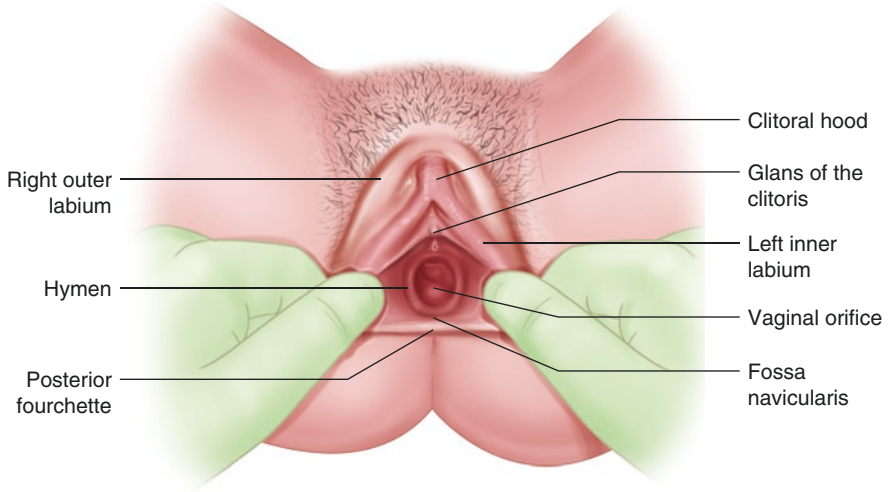


**Fig. 3.3** Possible clinical measurements in prepubertal genitals [55]

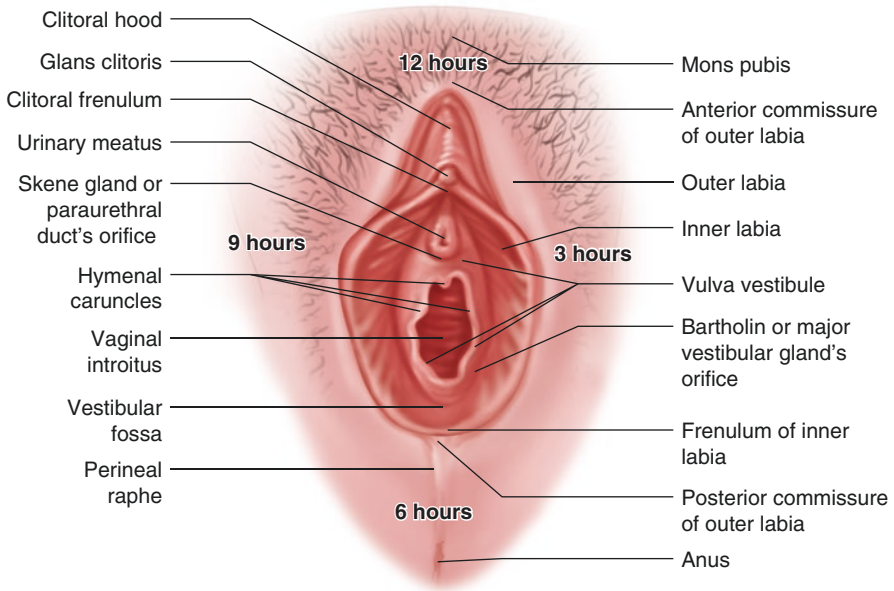
Numerator	Mean $\pm$ SD
Clitoris-Urethra	0.58 (0.18)
Clitoris-Anus	2.53 (1.21)
Posterior Fourchette	0.33 (0.15)
Vaginal introitus to inner labia	0.35 (0.12)
Clitoris Length	0.25 (0.15)



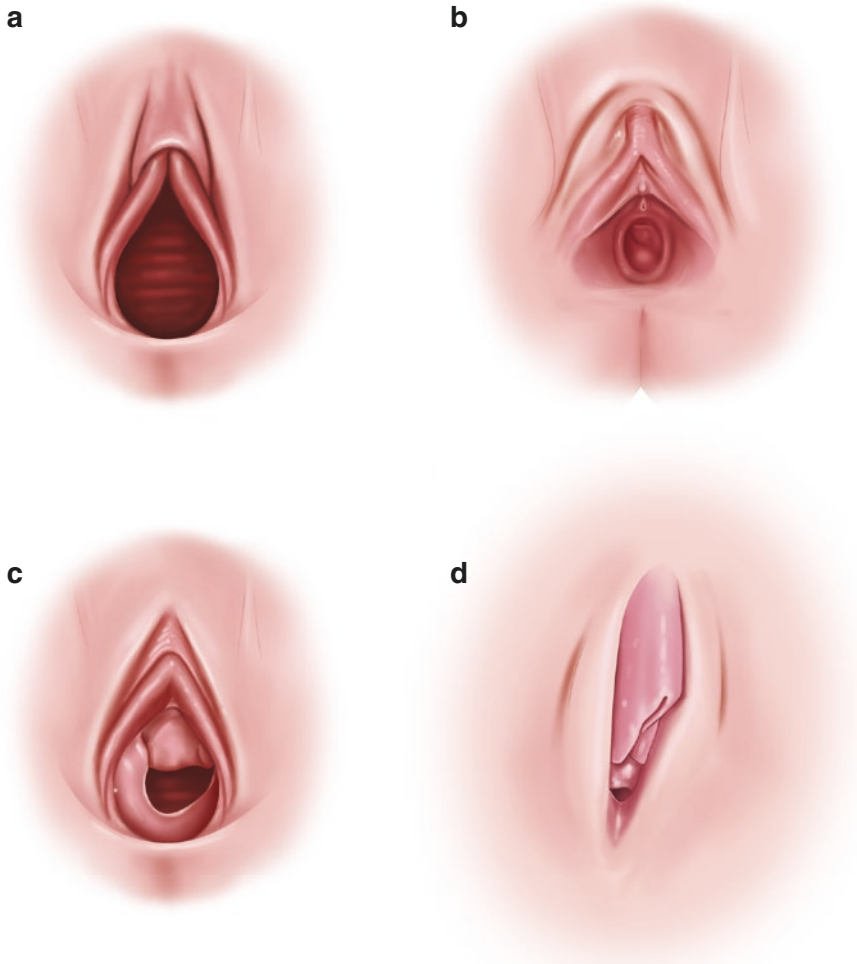
**Fig. 3.4** Ratios of distances measured in subjects younger than 13-years of age, with clitoris-posterior outer labia distance as the denominator [55]



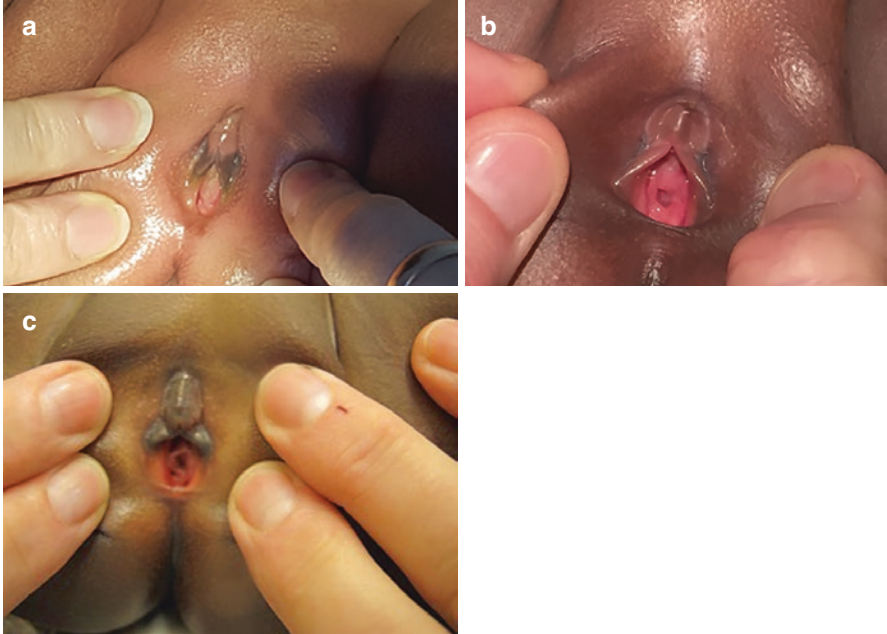
**Vulva**



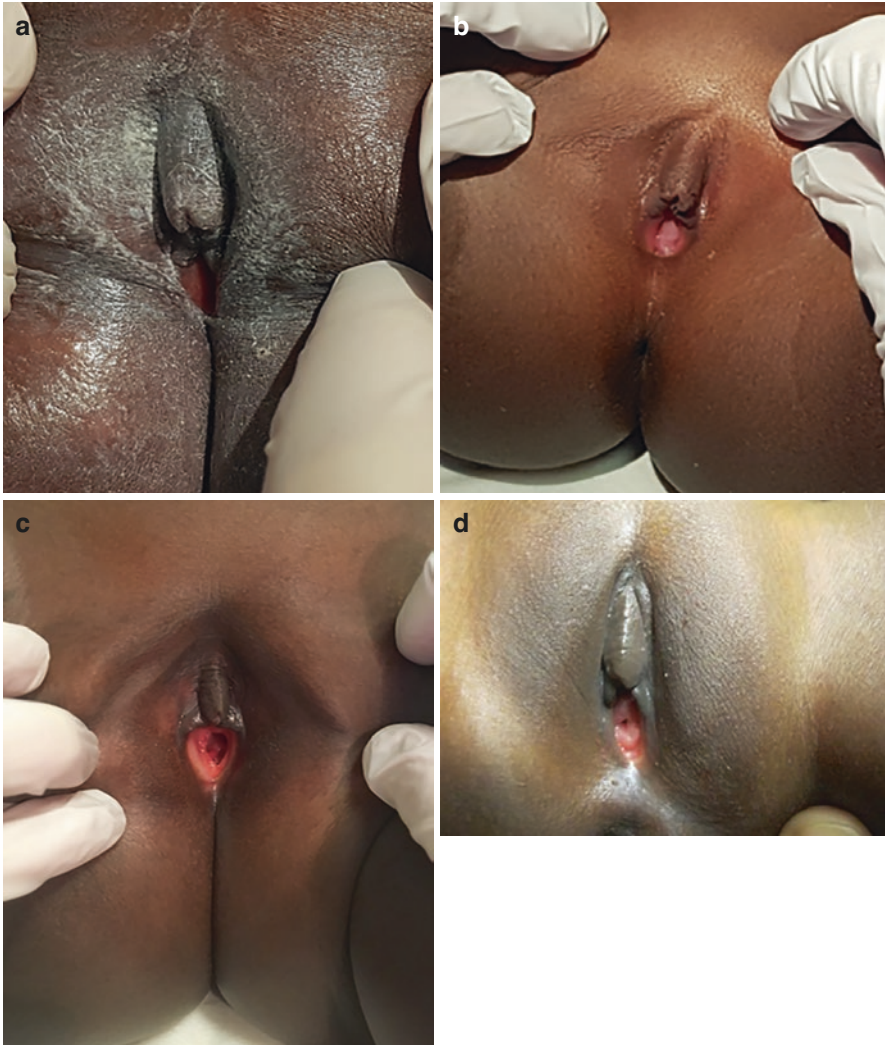**Fig. 3.5** Anatomy of the prepubescent female external genitalia. (Please note that when it is referred to labium minus and major, it is now preferred to use the terms of inner and outer labium)



**Fig. 3.6** Observed variations of the clitoral hood shapes. (a) Horseshoe, (b) Trumpet, (c) tent, (d) coffee bean [23]

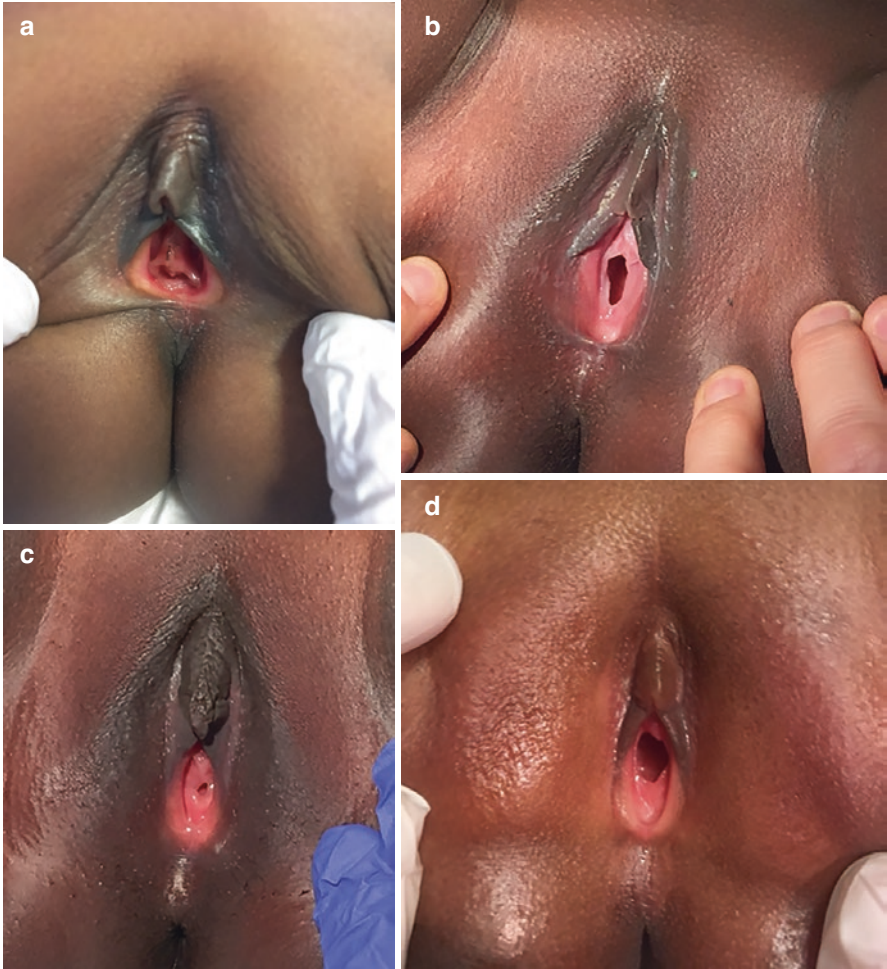

**Fig. 3.7** Physiological, uncut anatomy of the external female genitalia in girls up to 1-year-old referred for assessment of the presence or absence of FGM/C. (a) No FGM/C, age 3 months, from Senegal, ethnic group Malinke. (b) No FGM/C, age 6 months, from Mauritania (Courtesy of Céline Deguet). (c) No FGM/C, age 1 year, parents originally from Gambia (Courtesy of Birgitta Essén)

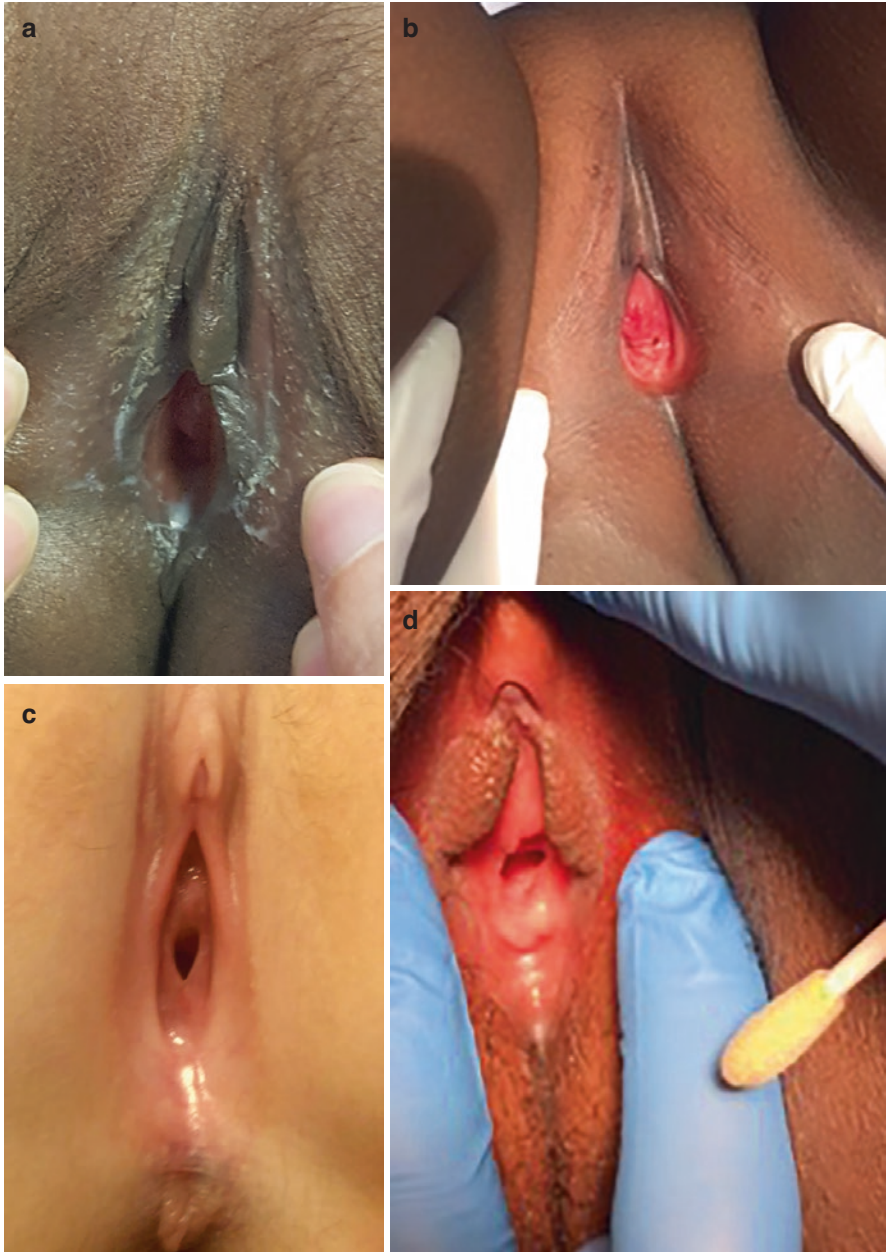

**Fig. 3.8** Physiological, uncut anatomy of the external female genitalia in girls up to 3-years old referred for assessment of the presence or absence of FGM/C. (a) No FGM/C, lichenification, 18-months-old, daughter to a mother from Ivory Coast and a father from Mali. (b) No FGM/C. 20-months old, from Ivory coast. (c) No FGM/C. 24-months old, from Ivory Coast (Courtesy of Céline Deguette). (d) No FGM/C. 3-years old, parents originally from Gambia (Courtesy of Birgitta Essén)

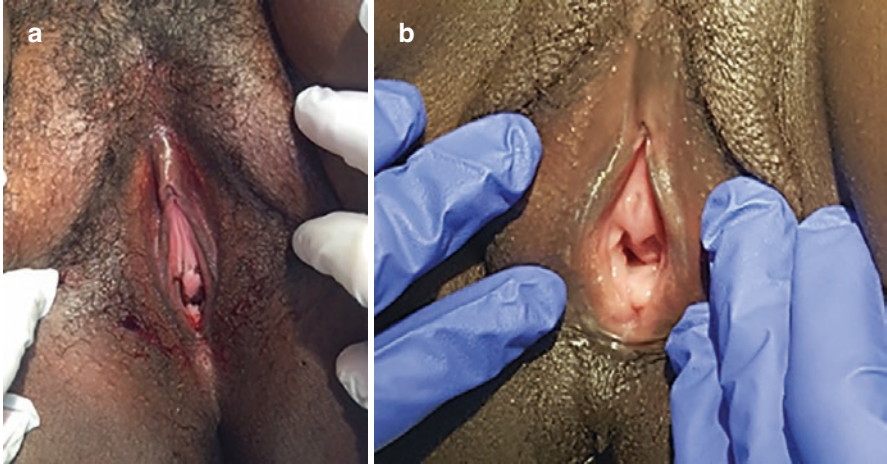




**Fig. 3.9** Physiological, uncut anatomy of the external female genitalia in 6–7 year-old girls referred for assessment of the presence or absence of FGM/C. (a) No FGM/C, 6-years old, from Chad. (b) No FGM/C, 6-years old, from Guinea. (c) No FGM/C, 7-years old, from Ivory Coast, Ethnic group: Dioula. (d) No FGM/C, 7-years old, from Ivory Coast. (Courtesy of Céline Deguette)



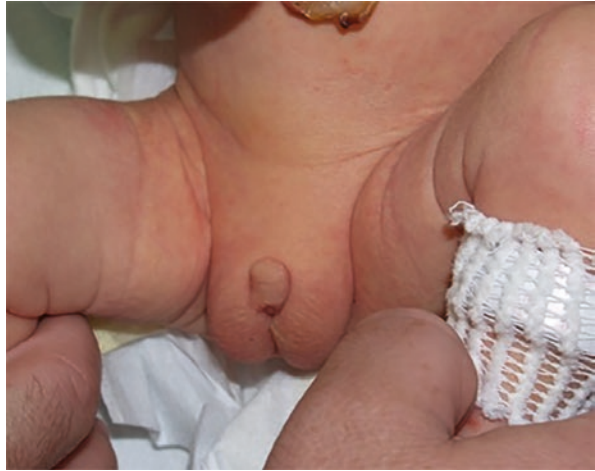**Fig. 3.10** Physiological, uncut anatomy of the external female genitalia in a 10-year-old girl referred for assessment of the presence or absence of FGM/C (**a** and **b**) and part of a well-being exam (**c**). (**a**) No FGM/C, 10-years old, from Ivory Coast, ethnic group: Bambara. (**b**) No FGM/C, 10-years old, from Ivory Coast (Courtesy of Céline Deguette). (**c**) No FGM/C, 10-years old, from Switzerland (Courtesy of Michal Yaron). (**d**) No FGM/C, 11-years old, with Somali ethnic background (Courtesy of Birgitta Essén)



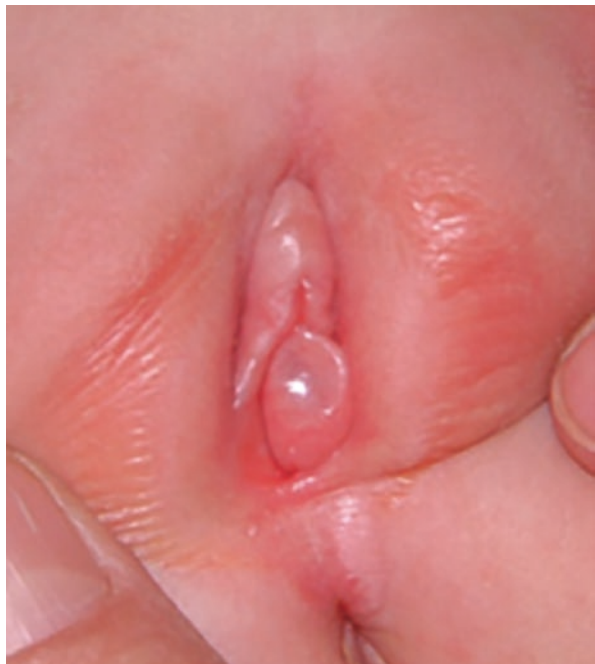**Fig. 3.11** Physiological, uncut anatomy of the external female genitalia postpuberty. **(a)** No FGM/C, 12-years old, from Ivory Coast. During menses. **(b)** No FGM/C, 23-years old, from Ivory Coast, Ethnic group: Gouro. (Courtesy of Céline Deguette)

### 3.2 Pictures Without FGM/C, with “Ambiguous” Genitals or Mucocolpos

**Fig. 3.12** “Ambiguous” genitalia, newborn from Switzerland. (Courtesy of Michal Yaron)

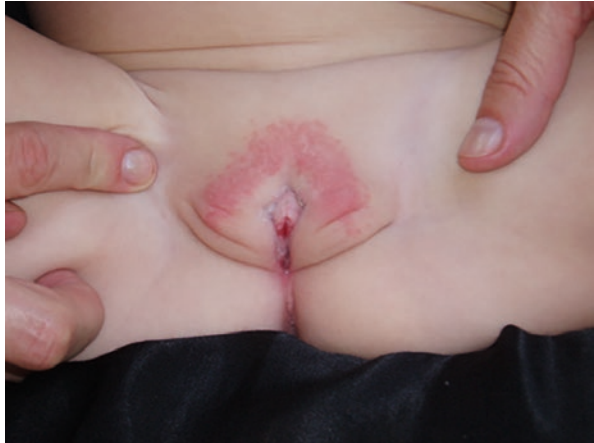

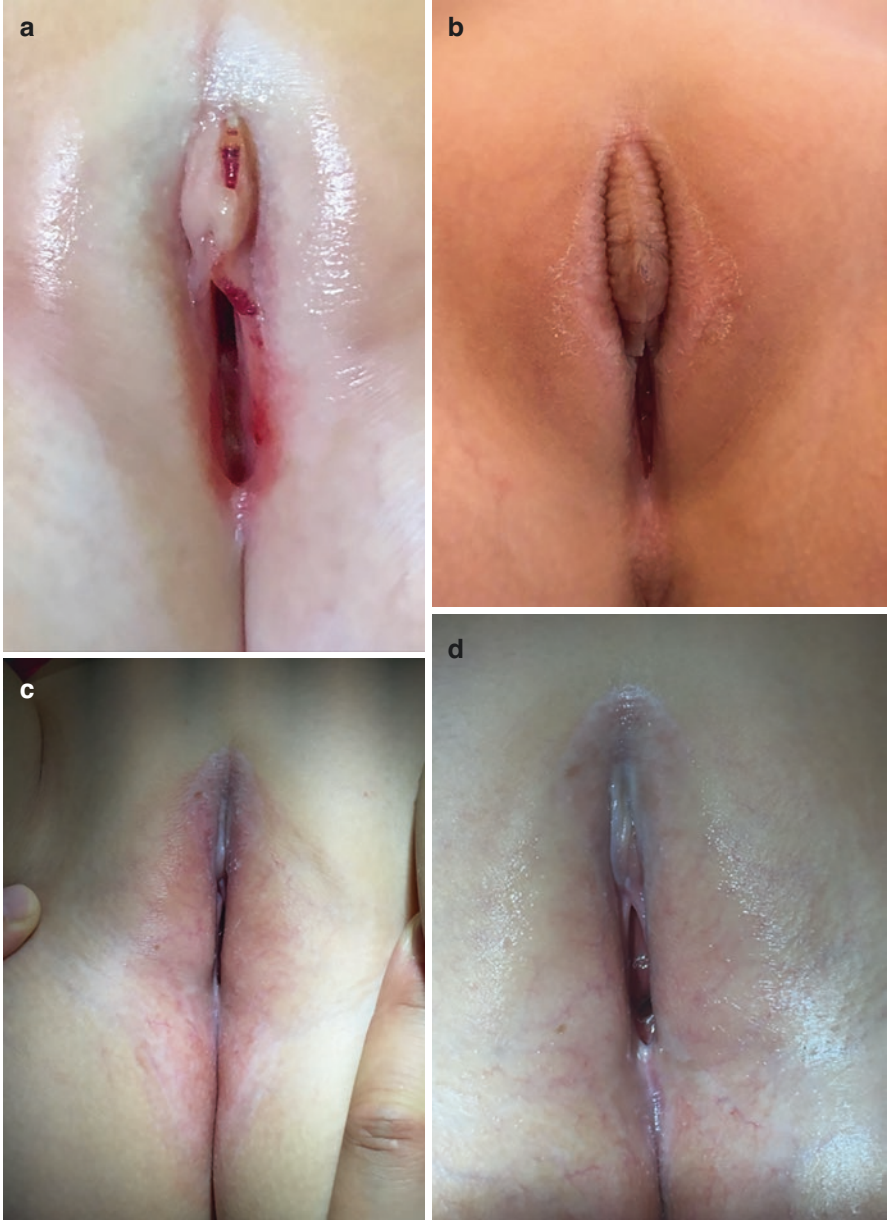**Fig. 3.13** Mucocolpos, newborn with an imperforate hymen from Switzerland. (Springer Nature [9])



### 3.3 Pictures Without FGM/C, with Dermatological Conditions, Infections, and Other Lesions

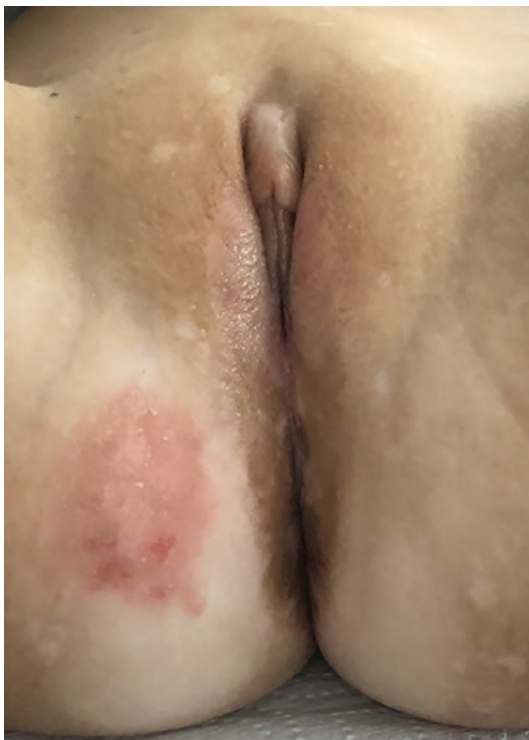**Fig. 3.14** Dermatitis of the genitalia and lichenification of the clitoral hood in prepubertal female from Israel. Contact Dermatitis, 5-years old. (Courtesy of Michal Yaron)



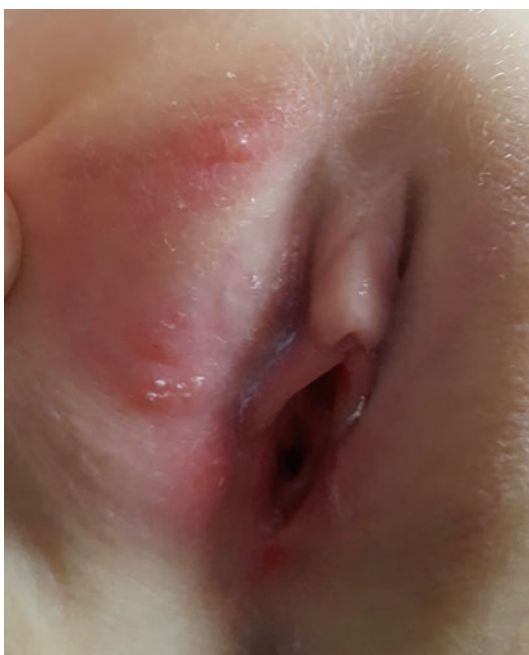

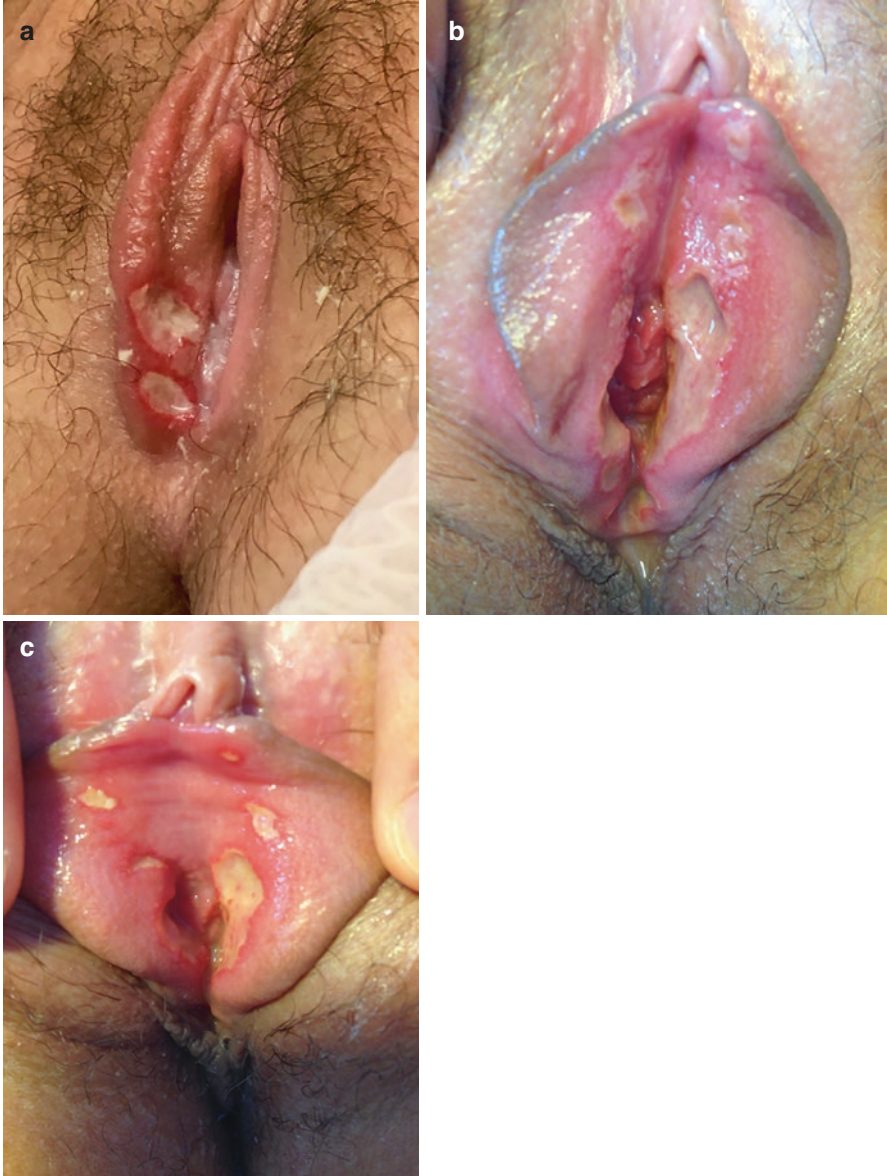**Fig. 3.15** Lichen sclerosus. (a, b) Two different 4-year-old girls, (c) 5-year-old, after 7 days of treatment with clobetasol, and (d) after 14 days of treatment with clobetasol. (Courtesy of Michal Yaron)

**Fig. 3.16** Psoriasis.  
Differential diagnosis is  
Lichen sclerosus, 3-years  
old. (Courtesy of Michal  
Yaron)



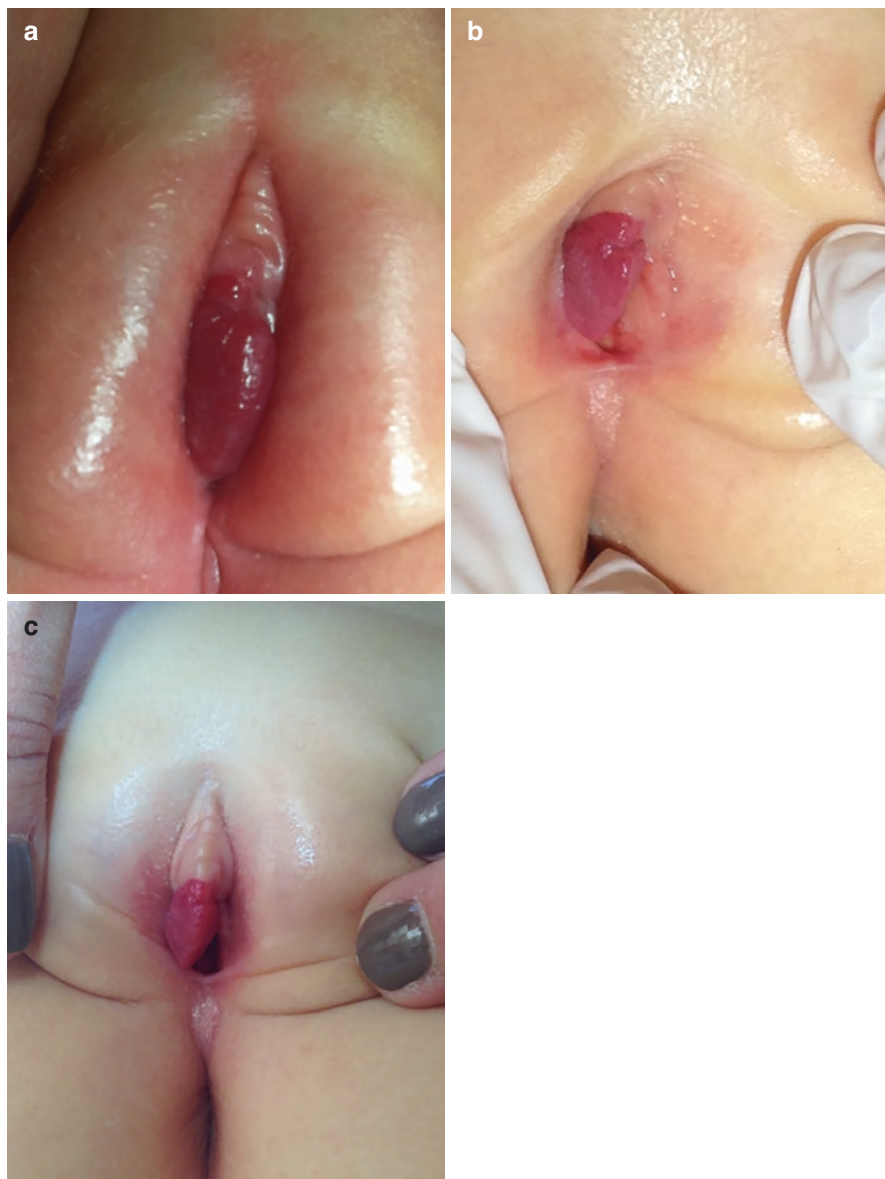**Fig. 3.17** Herpes Simplex  
Virus, 3-years old.  
(Courtesy of Michal Yaron)





**Fig. 3.18** Lipschütz ulcer. (a) 12-years old, (b) 14-years old, (c) Same girl as in (b) after 3 days of treatment with lidocaine gel, and calendula “sitz-baths” and cream. (Courtesy of Michal Yaron)

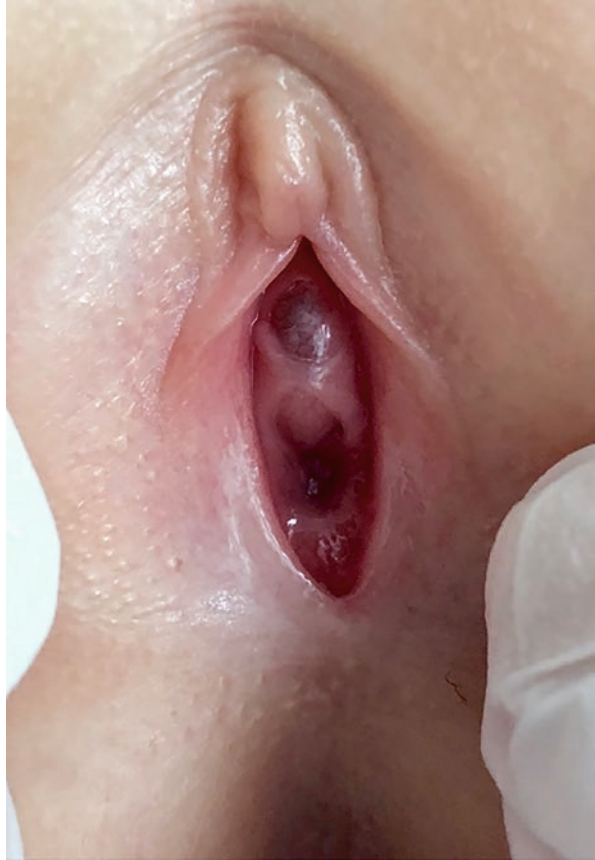

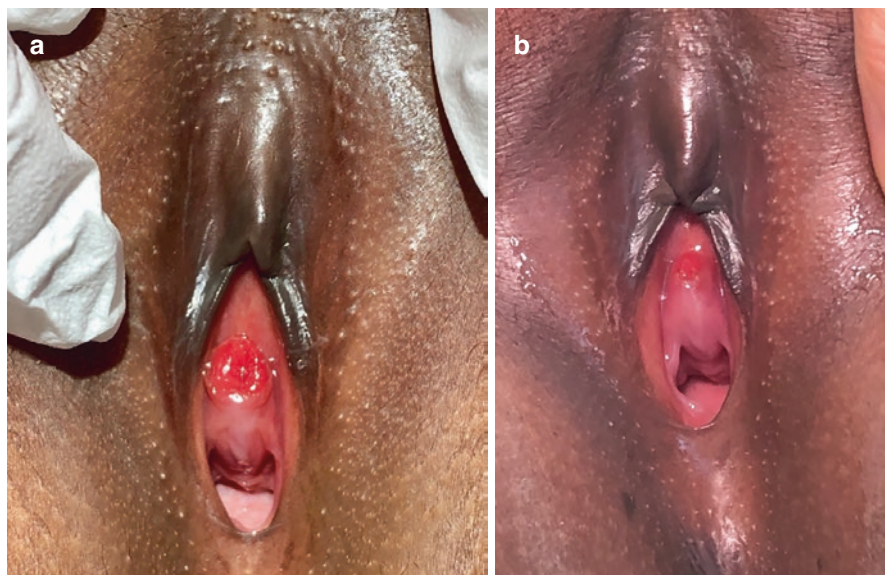


**Fig. 3.19** Vulvar hemangioma in the same girl at (a) 6 weeks, (b) 3 months, (c) 12 months. (Courtesy of Michal Yaron)

### 3.4 Pictures Without FGM/C, with Urethral Lesions

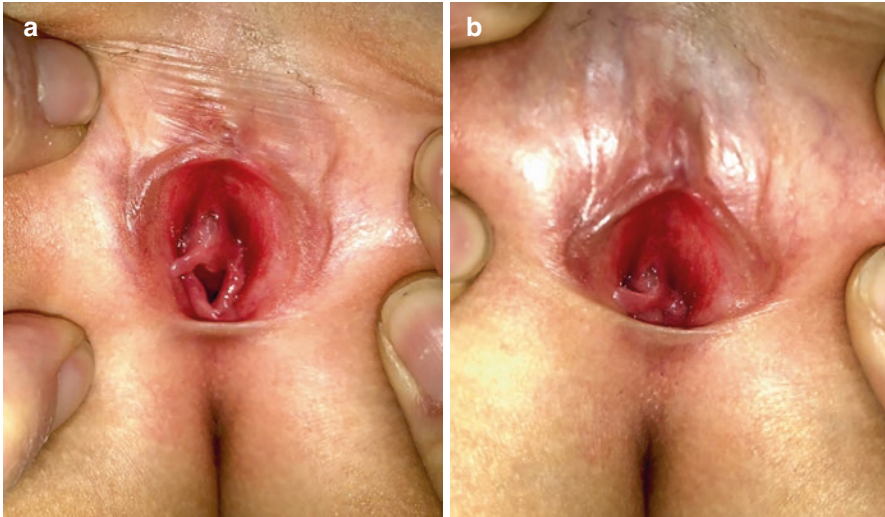
**Fig. 3.20** Paraurethral cyst, 3-years old. (Courtesy of Michal Yaron)





**Fig. 3.21** Urethral prolapse, 7-years old, before (a) and after (b) local estrogen treatment. (Courtesy of Michal Yaron)

### 3.5 Pictures Without FGM/C, with Genital Trauma



**Fig. 3.22** Trauma with toy, 2-years old (a, b). (Courtesy of Michal Yaron)

**Open Access** This chapter is licensed under the terms of the Creative Commons Attribution 4.0 International License (<http://creativecommons.org/licenses/by/4.0/>), which permits use, sharing, adaptation, distribution and reproduction in any medium or format, as long as you give appropriate credit to the original author(s) and the source, provide a link to the Creative Commons license and indicate if changes were made.

The images or other third party material in this chapter are included in the chapter's Creative Commons license, unless indicated otherwise in a credit line to the material. If material is not included in the chapter's Creative Commons license and your intended use is not permitted by statutory regulation or exceeds the permitted use, you will need to obtain permission directly from the copyright holder.



# Chapter 4

## Pictures with Potential Differential Diagnosis of FGM/C



**Jasmine Abdulcadir, Noémie Sachs Guedj, Michal Yaron, Omar Abdulcadir, Juliet Albert, Martin Caillet, Lucrezia Catania, Sarah M. Creighton, Céline Deguette, Elise Dubuc, Brian D. Earp, Birgitta Essén, Deborah Hodes, Adriana Kaplan Marcusan, Ranit Mishori, Deborah Ottenheimer, Fabienne Richard, Aida Sy, Moustapha Touré, Amelia Valladolid, Anneke Vercoutere, Bilkis Vissandjée, and Janine Young**

---

J. Abdulcadir (✉) · N. S. Guedj · M. Yaron  
Department of Pediatrics, Gynecology and Obstetrics, Geneva University Hospitals,  
Geneva, Switzerland  
e-mail: [jasmine.abdulcadir@hcuge.ch](mailto:jasmine.abdulcadir@hcuge.ch); [michal.yaron@hcuge.ch](mailto:michal.yaron@hcuge.ch)

O. Abdulcadir · L. Catania  
Referral Center for Curing and Preventing FGM. AOUC, Florence, Italy

J. Albert  
Imperial College Healthcare, NHS Trust, London, UK  
e-mail: [juliet.albert@nhs.net](mailto:juliet.albert@nhs.net)

M. Caillet  
CHU Saint-Pierre, Brussels, Belgium  
e-mail: [martin\\_caillet@stpierre-bru.be](mailto:martin_caillet@stpierre-bru.be)

S. M. Creighton · D. Hodes  
University College London Hospital, London, UK  
e-mail: [sarah.creighton2@nhs.net](mailto:sarah.creighton2@nhs.net); [deborah.hodes@nhs.net](mailto:deborah.hodes@nhs.net)

C. Deguette  
Department of Forensic Medicine, AP-HP. Centre-University of Paris, Paris, France  
e-mail: [celine.deguette@aphp.fr](mailto:celine.deguette@aphp.fr)

E. Dubuc  
CHU Sainte-Justine, Montréal, QC, Canada  
e-mail: [elise.dubuc.1@umontreal.ca](mailto:elise.dubuc.1@umontreal.ca)

B. D. Earp  
Departments of Philosophy and Psychology, Yale University, New Haven, CT, USA  
e-mail: [brian.earp@yale.edu](mailto:brian.earp@yale.edu)

B. Essén  
Women's and Children's Health/IMCH, WHO Collaborating Centre on Migration and Health,  
Uppsala University, Uppsala, Sweden  
e-mail: [brigitta.essen@kbh.uu.se](mailto:brigitta.essen@kbh.uu.se)

A. K. Marcusan  
Department of Social and Cultural Anthropology, UAB, Barcelona, Spain  
e-mail: [adriana.kaplan@uab.cat](mailto:adriana.kaplan@uab.cat)

© The Author(s) 2022  
J. Abdulcadir et al. (eds.), *Female Genital Mutilation/Cutting in Children and  
Adolescents*, [https://doi.org/10.1007/978-3-030-81736-7\\_4](https://doi.org/10.1007/978-3-030-81736-7_4)

R. Mishori

Georgetown University Department of Family Medicine, and Physicians for Human Rights,  
Washington, DC, USA

e-mail: [mishorir@georgetown.edu](mailto:mishorir@georgetown.edu)

D. Ottenheimer

Morrisania Diagnostic and Treatment Center, Bronx, NY, USA

e-mail: [deb@ottenheimerhealth.com](mailto:deb@ottenheimerhealth.com)

F. Richard

GAMS Belgique, Brussels, Belgium

Ecole de santé publique, Université Libre de Bruxelles, Brussels, Belgium

e-mail: [fabienne@gams.be](mailto:fabienne@gams.be)

A. Sy

Bamako, Mali

M. Touré

Malian Society of Gynecology and Obstetrics, Bamako, Mali

A. Valladolid

Universidad del Pais Vasco, Vizcaya, Spain

A. Vercoutere

Community and Health Project in Guinea Conakry, Conakry, Guinea

Hôpital Erasme, University Hospital ULB, Brussels, Belgium

e-mail: [An.Vercoutere@erasme.ulb.ac.be](mailto:An.Vercoutere@erasme.ulb.ac.be)

B. Vissandjée

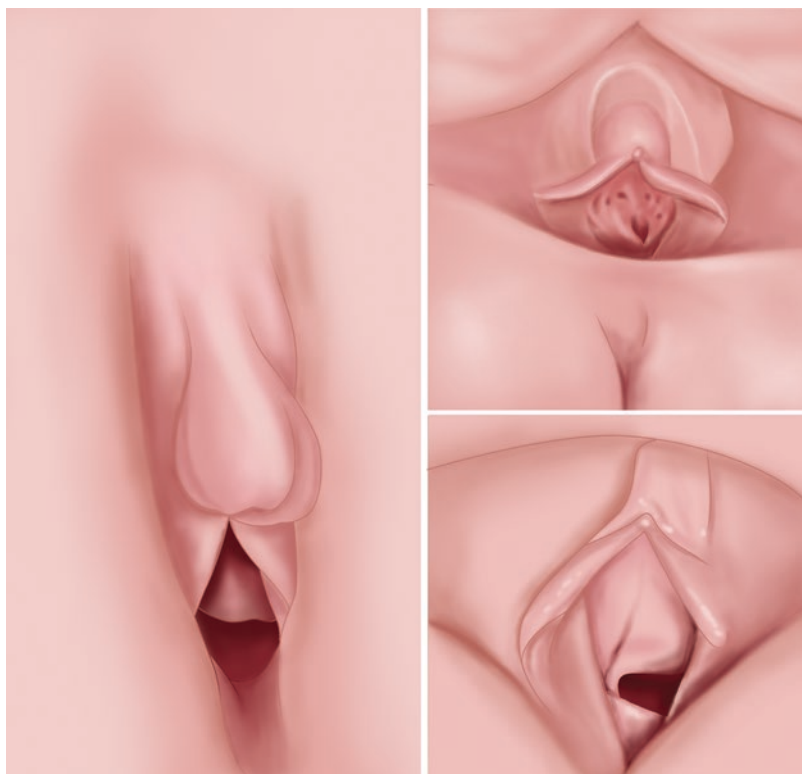
Université de Montreal, Montreal, Quebec, Canada

e-mail: [bilkis.vissandjee@umontreal.ca](mailto:bilkis.vissandjee@umontreal.ca)

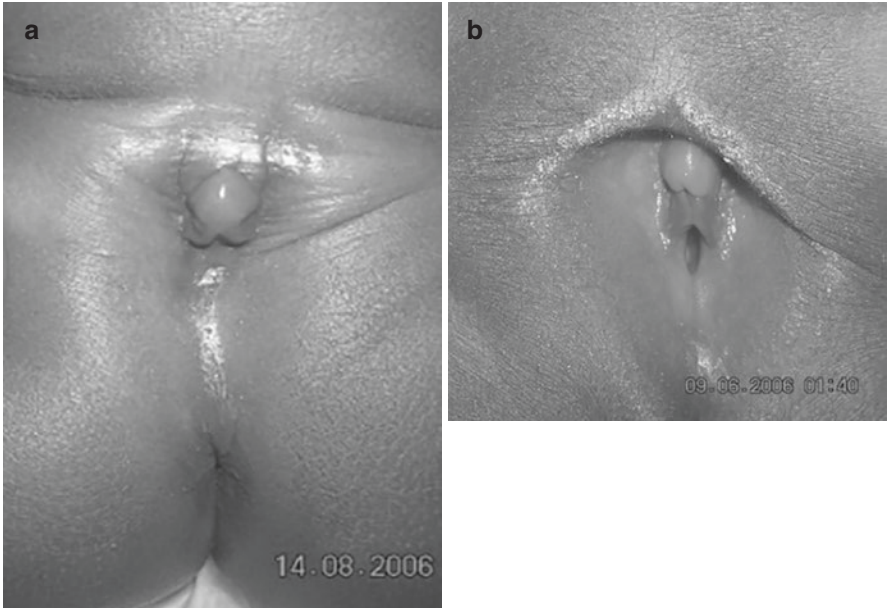
J. Young

Department of Pediatrics, Denver Health and Hospitals, University of Colorado School of  
Medicine, Denver, CO, USA

e-mail: [janine.young@dhha.org](mailto:janine.young@dhha.org)



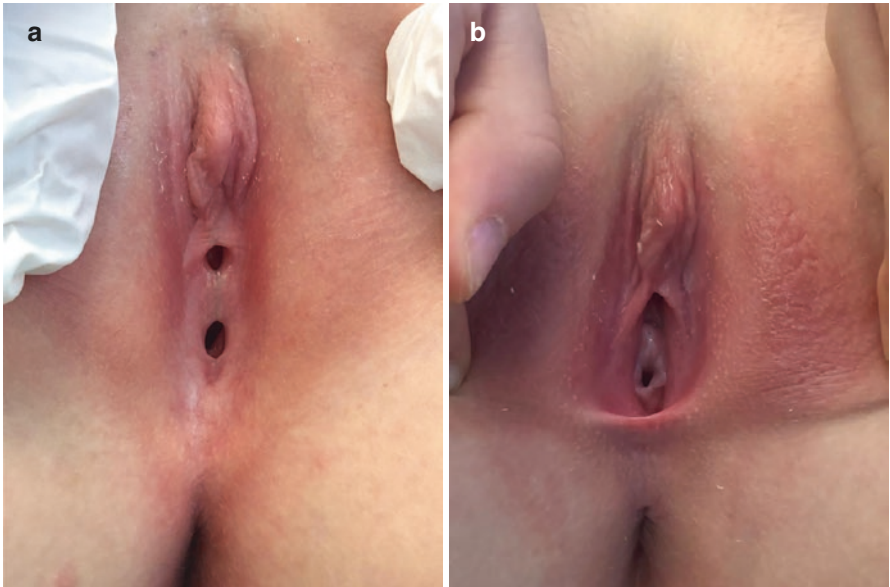
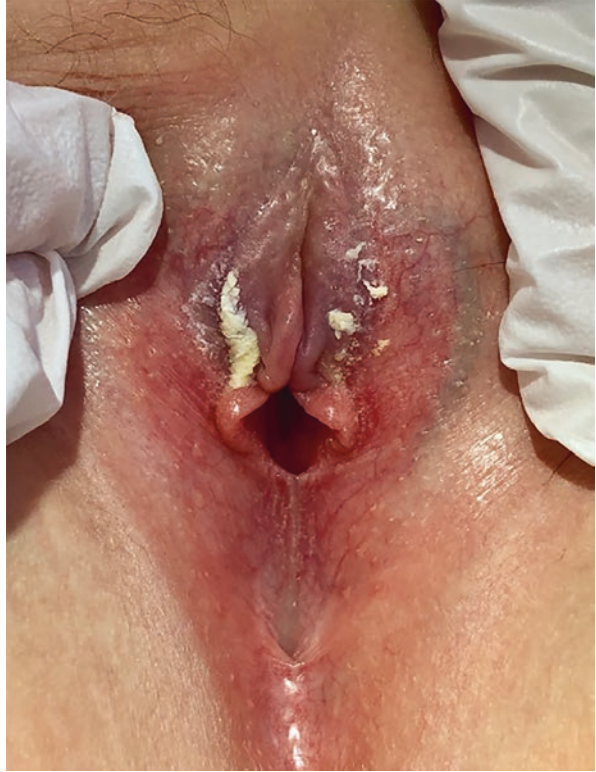**Fig. 4.1** Labial and Clitoral adhesion. Examples of convergence of inner labia under the glans and intersection with clitoral hood [23]



**Fig. 4.2** Total (a) and partial (b) labial adhesion. (Reprinted with permission from John Libbey Eurotext [56])

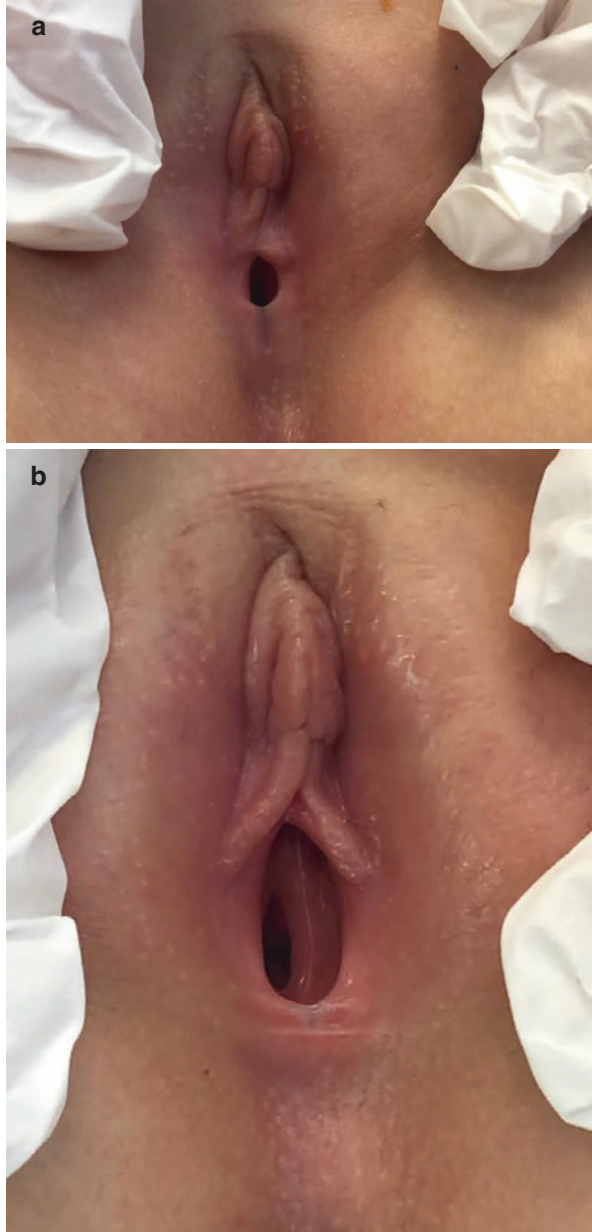


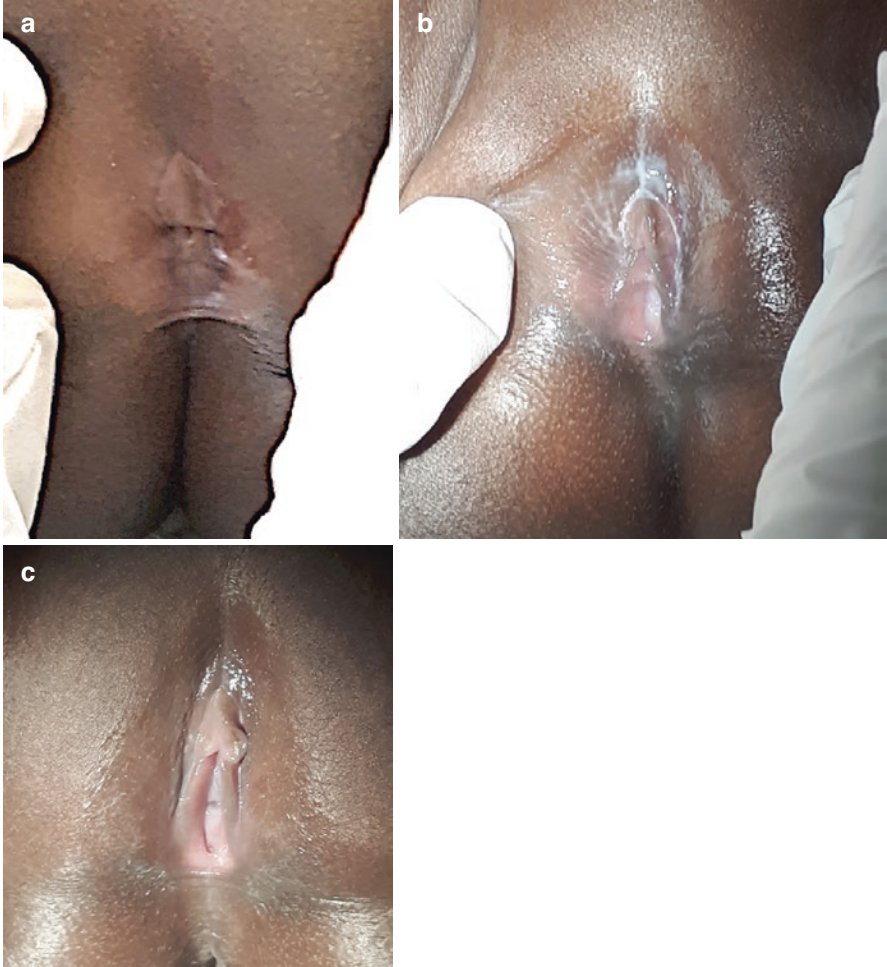
**Fig. 4.3** Partial inferior labial adhesion, 10-years old. (Courtesy of Michal Yaron)



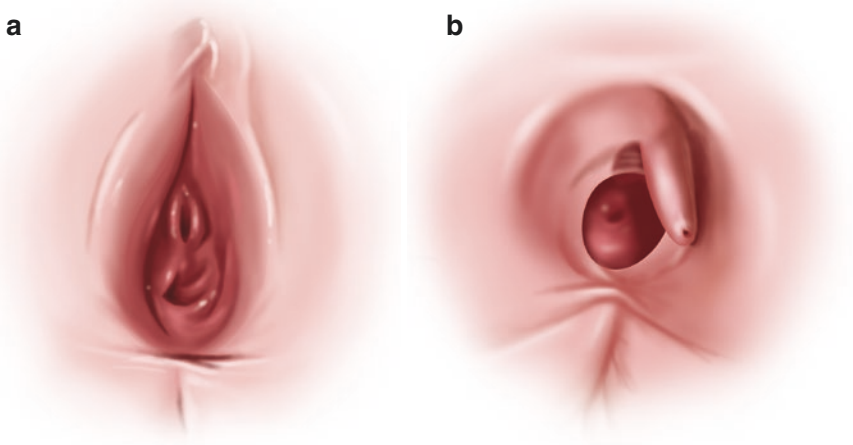
**Fig. 4.4** Partial labial adhesion before (a) and after (b) local estrogen treatment, 7-years old. (Courtesy of Michal Yaron)

**Fig. 4.5** Partial labial adhesion before (a) and after (b) local estrogen treatment, 3.5-years old. (Courtesy of Michal Yaron)



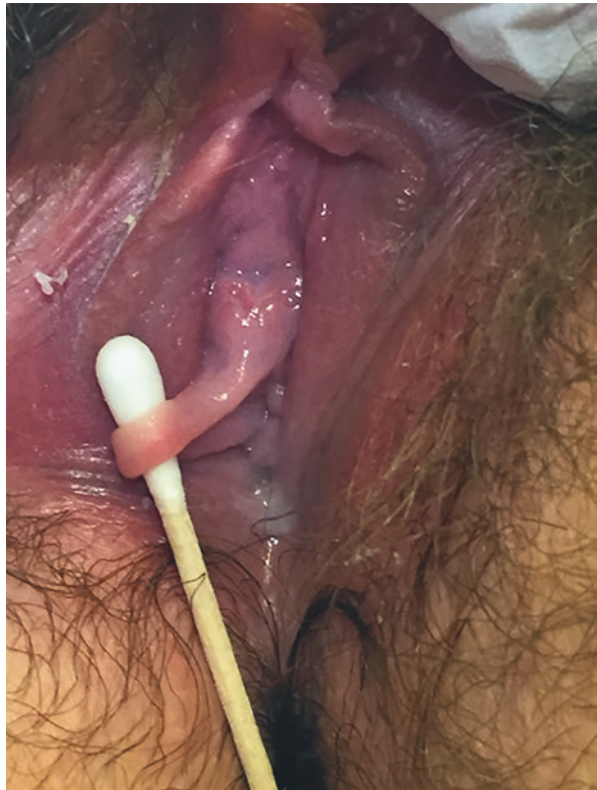

**Fig. 4.6** Labial and clitoral adhesions, 13-months old, from Senegal, referred to exclude FGM/C. Ethnic group: Wolof. (a) First examination, (b) 14 days after local estrogen treatment, (c) 1 month after local estrogen treatment; the labia are not fused anymore and the glans and prepuce of the clitoris are perfectly visible, without any sign of cutting. (Courtesy of Jasmine Abdulcadir and Michal Yaron)

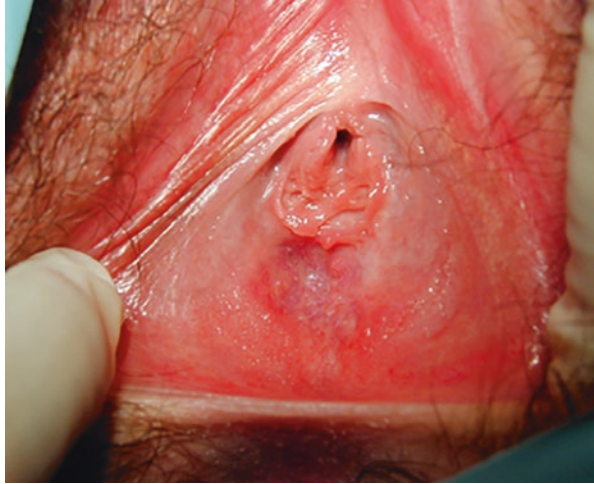


**Fig. 4.7** Clitoris/labial agenesis. (a) Clitoris agenesis. (b) Clitoris and right inner labium agenesis [57]

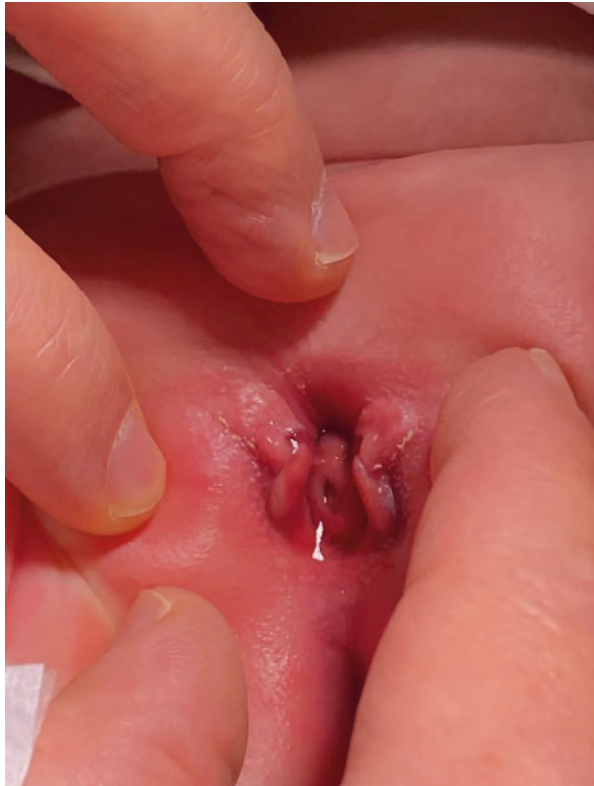**Fig. 4.8** Hymenal bridle, 14-years old. (Courtesy of Michal Yaron)



**Fig. 4.9** Imperforate hymen, 12-years old. (Courtesy of Michal Yaron)



**Fig. 4.10** Female epispadias, 2-months old. The impression of absence of the glans of the clitoris can be misleading and suggest a history of FGM/C. The hemiclitorises are visible at 11 and 1 o'clock. (Courtesy of Michal Yaron)



**Open Access** This chapter is licensed under the terms of the Creative Commons Attribution 4.0 International License (<http://creativecommons.org/licenses/by/4.0/>), which permits use, sharing, adaptation, distribution and reproduction in any medium or format, as long as you give appropriate credit to the original author(s) and the source, provide a link to the Creative Commons license and indicate if changes were made.

The images or other third party material in this chapter are included in the chapter's Creative Commons license, unless indicated otherwise in a credit line to the material. If material is not included in the chapter's Creative Commons license and your intended use is not permitted by statutory regulation or exceeds the permitted use, you will need to obtain permission directly from the copyright holder.



# Chapter 5

## Pictures with FGM/C



**Jasmine Abdulcadir, Noémie Sachs Guedj, Michal Yaron, Omar Abdulcadir, Juliet Albert, Martin Caillet, Lucrezia Catania, Sarah M. Creighton, Céline Deguette, Elise Dubuc, Brian D. Earp, Birgitta Essén, Deborah Hodes, Adriana Kaplan Marcusan, Ranit Mishori, Deborah Ottenheimer, Fabienne Richard, Aida Sy, Moustapha Touré, Amelia Valladolid, Anneke Vercoutere, Bilkis Vissandjée, and Janine Young**

---

J. Abdulcadir (✉) · N. S. Guedj · M. Yaron  
Department of Pediatrics, Gynecology and Obstetrics, Geneva University Hospitals,  
Geneva, Switzerland  
e-mail: [jasmine.abdulcadir@hcuge.ch](mailto:jasmine.abdulcadir@hcuge.ch); [michal.yaron@hcuge.ch](mailto:michal.yaron@hcuge.ch)

O. Abdulcadir · L. Catania  
Ancient Referral Center for Curing and Preventing FGM. AOUC, Florence, Italy

J. Albert  
Imperial College Healthcare, NHS Trust, London, UK  
e-mail: [juliet.albert@nhs.net](mailto:juliet.albert@nhs.net)

M. Caillet  
CHU Saint-Pierre, Brussels, Belgium  
e-mail: [martin\\_caillet@stpierre-bru.be](mailto:martin_caillet@stpierre-bru.be)

S. M. Creighton · D. Hodes  
University College London Hospital, London, UK  
e-mail: [sarah.creighton2@nhs.net](mailto:sarah.creighton2@nhs.net); [deborah.hodes@nhs.net](mailto:deborah.hodes@nhs.net)

C. Deguette  
Department of Forensic Medicine, AP-HP. Centre-University of Paris, Paris, France  
e-mail: [celine.deguette@aphp.fr](mailto:celine.deguette@aphp.fr)

E. Dubuc  
CHU Sainte-Justine, Montréal, QC, Canada  
e-mail: [elise.dubuc.1@umontreal.ca](mailto:elise.dubuc.1@umontreal.ca)

B. D. Earp  
Departments of Philosophy and Psychology, Yale University, New Haven, CT, USA  
e-mail: [brian.earp@yale.edu](mailto:brian.earp@yale.edu)

B. Essén  
Women's and Children's Health/IMCH, WHO Collaborating Centre on Migration and Health,  
Uppsala University, Uppsala, Sweden  
e-mail: [brigitta.essen@kbh.uu.se](mailto:brigitta.essen@kbh.uu.se)

A. K. Marcusan

Department of Social and Cultural Anthropology, UAB, Barcelona, Spain

e-mail: [adriana.kaplan@uab.cat](mailto:adriana.kaplan@uab.cat)

R. Mishori

Georgetown University Department of Family Medicine, and Physicians for Human Rights, Washington, DC, USA

e-mail: [mishorir@georgetown.edu](mailto:mishorir@georgetown.edu)

D. Ottenheimer

Morrisania Diagnostic and Treatment Center, Bronx, NY, USA

e-mail: [deb@ottenheimerhealth.com](mailto:deb@ottenheimerhealth.com)

F. Richard

GAMS Belgique, Brussels, Belgium

Ecole de santé publique, Université Libre de Bruxelles, Brussels, Belgium

e-mail: [fabienne@gams.be](mailto:fabienne@gams.be)

A. Sy

Bamako, Mali

M. Touré

Malian Society of Gynecology and Obstetrics, Bamako, Mali

A. Valladolid

Universidad del Pais Vasco, Vizcaya, Spain

A. Vercoutere

Community and Health Project in Guinea Conakry, Conakry, Guinea

Hôpital Erasme, University Hospital ULB, Brussels, Belgium

B. Vissandjée

Université de Montreal, Montreal, Quebec, Canada

e-mail: [bilkis.vissandjee@umontreal.ca](mailto:bilkis.vissandjee@umontreal.ca)

J. Young

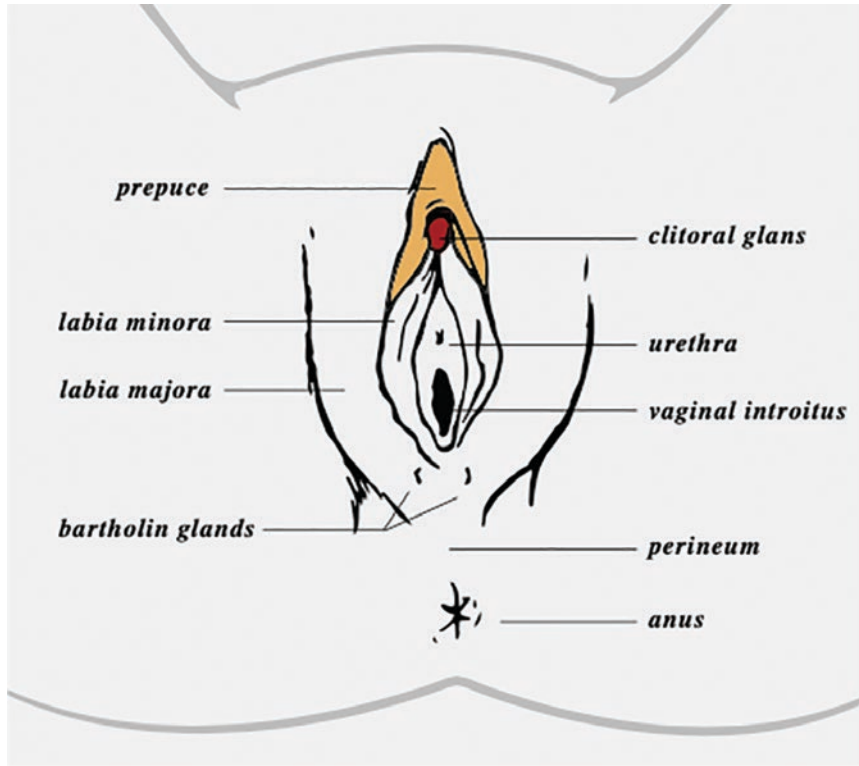
Department of Pediatrics, Denver Health and Hospitals, University of Colorado School of Medicine, Denver, CO, USA

e-mail: [janine.young@dhha.org](mailto:janine.young@dhha.org)

Please note that when WHO refers to labia minora and majora such terms are now replaced by inner and outer labia.



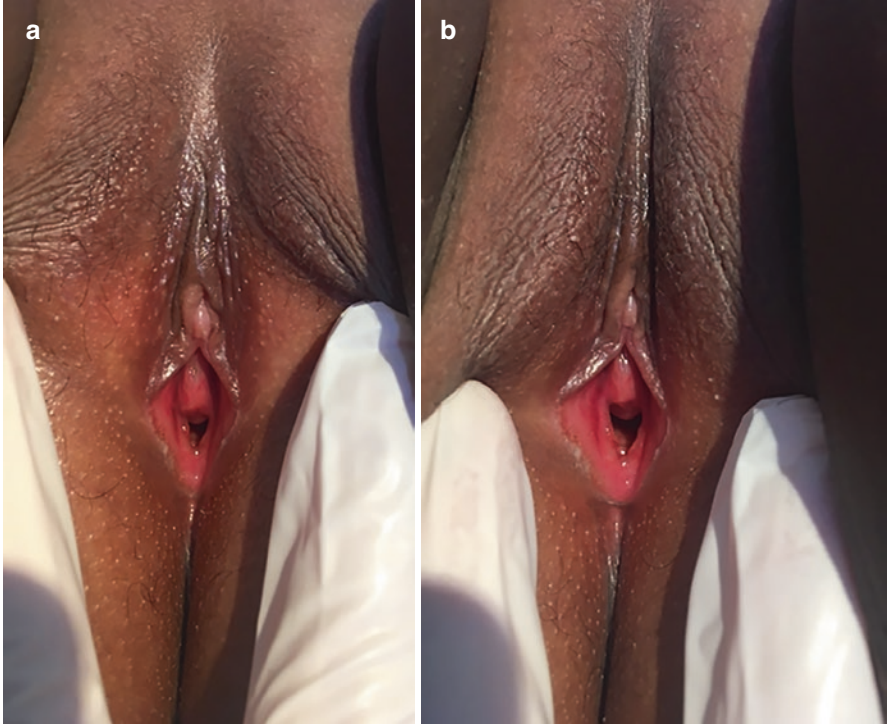
### 5.1 FGM/C Type I



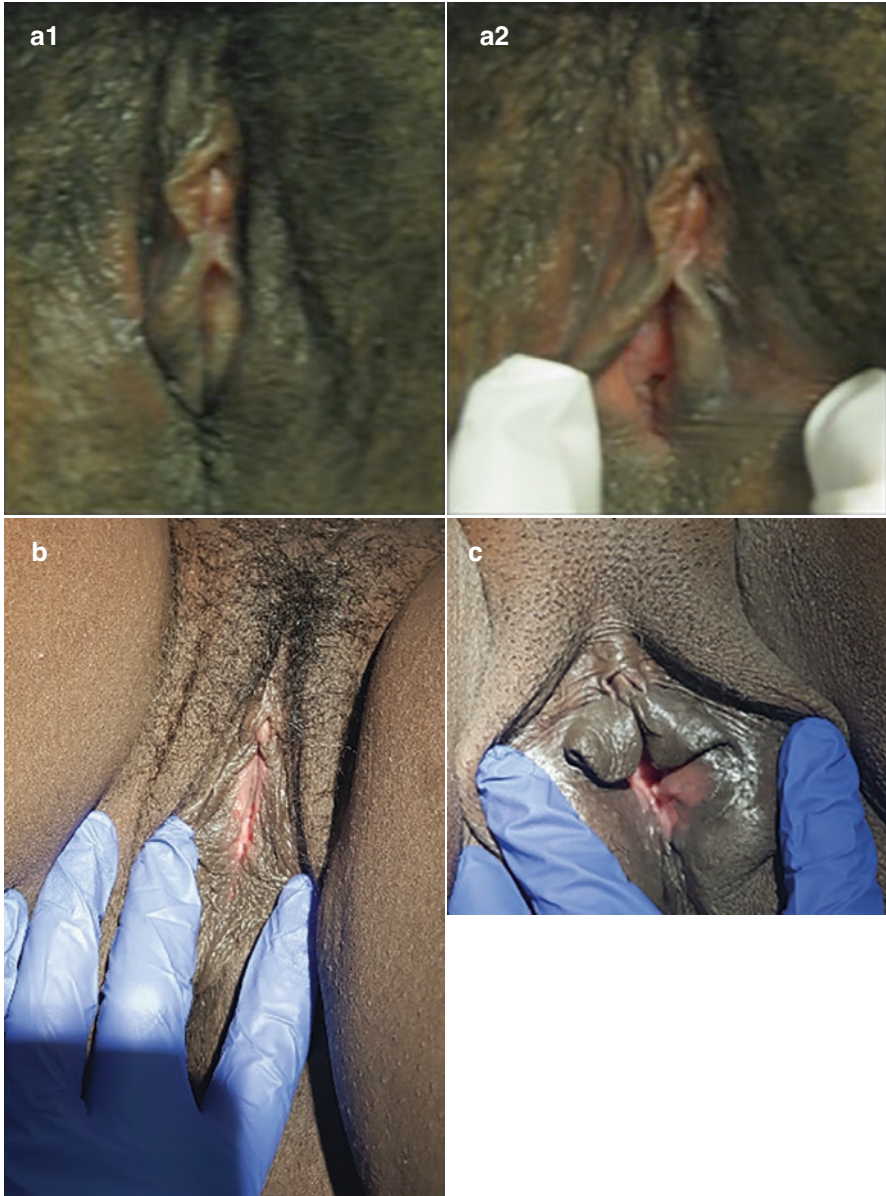**Type Ia:** removal of the prepuce/clitoral hood (circumcision)

**Type Ib:** removal of the clitoral glans with the prepuce (clitoridectomy)

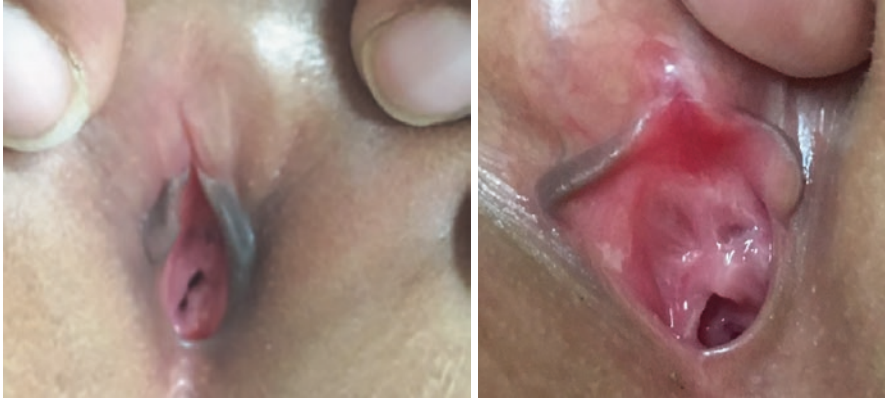**Fig. 5.1** Diagram of FGM/C type Ia (cutting of the prepuce/clitoral hood) and type Ib (cutting of the prepuce/clitoral hood and the visible part of the clitoris). (Reprinted with permission from WHO [17])



**Fig. 5.2** FGM/C type Ia (partial removal of the left side edge of the prepuce), 10-years old, from Ivory Coast (**a, b**). (Courtesy of Céline Deguette)

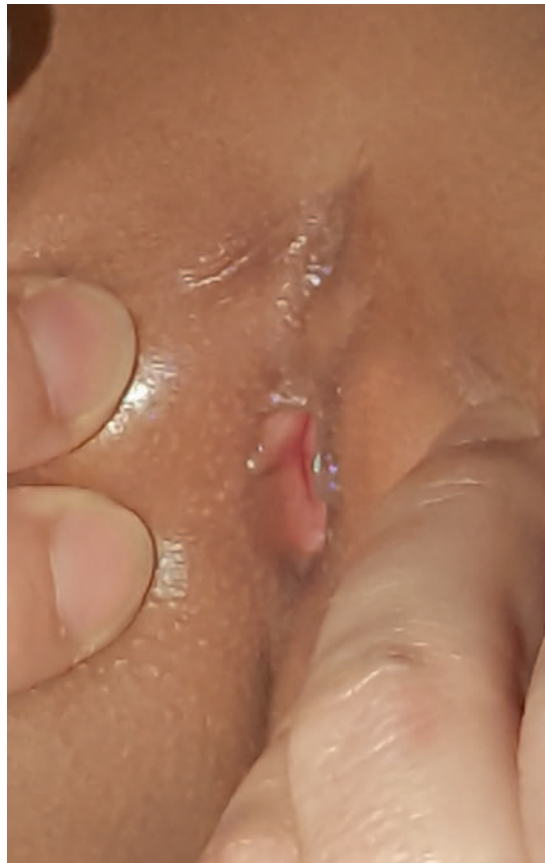

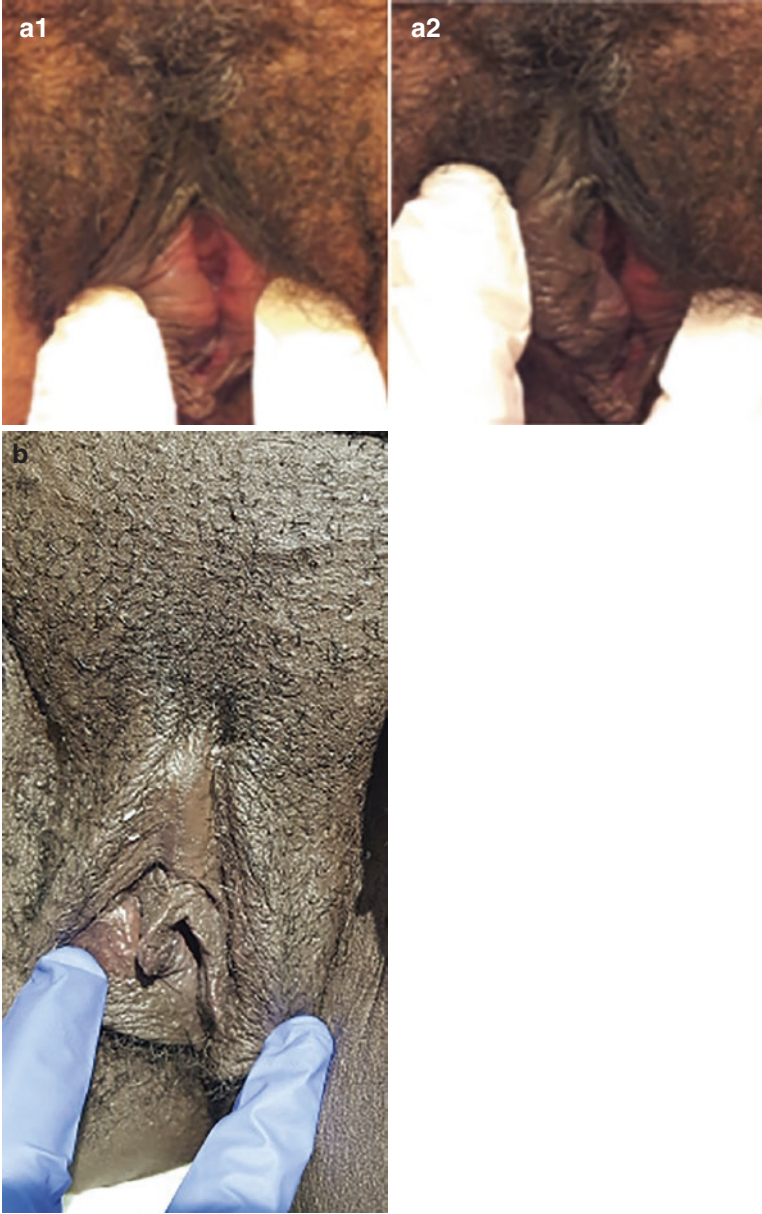**Fig. 5.3** FGM/C type Ia (partial removal of the prepuce) in three adult women (**a1** and **a2**) 28-years old, from Senegal, (**b**) 36-years old, from Nigeria (ethnic group Icha), and (**c**) 44-years old, from Ivory Coast. (Courtesy of Jasmine Abdulcadir [8] (**a**) and Céline Deguette (**b**, **c**)). The woman in figure **a** underwent FGM/C at around the age of 10–12, the woman in figure **b** at 6, the woman in figure **c** at 8



**Fig. 5.4** FGM/C type Ib or no FGM/C in a 2-year-old Ethiopian girl. She had just arrived in the US with her mother and they were being reunited with the father of the child. The mother denied a history of FGM/C. The experts disagreed in the diagnosis. For some, there was FGM/C type Ib. For some others, there was no cutting. Estrogen cream was applied without any changes in the appearance. (Courtesy of Janine Young)

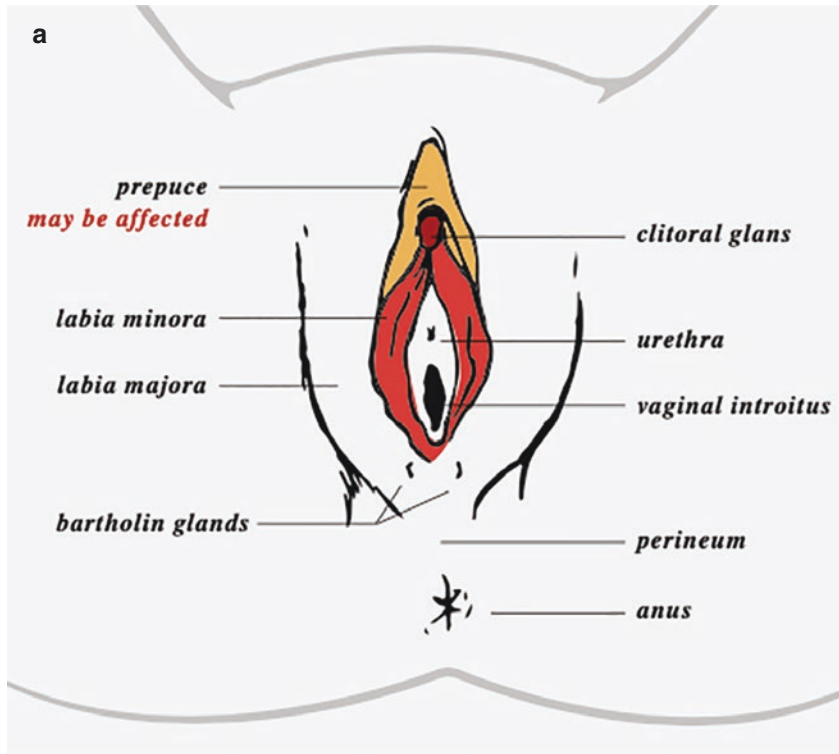
**Fig. 5.5** FGM/C type Ib (cutting of the prepuce and glans of the clitoris), 3-years old, from Mali. Please note that the FGM/C might also be classified as IIb as the scar reaches the right inner labium. (Courtesy of Céline Deguet)





**Fig. 5.6** FGM/C type Ib, (**a1** and **a2**) adult woman, from Nigeria. Courtesy of Jasmine Abdulcadir (8) (**b**) FGM Ib or IIb, 39 years old, from Nigeria, ethnic group: Legos. Total removal of the prepuce of the clitoris and cutting of the clitoris with removal of the posterior right side of the inner labium. The woman in figure b underwent FGM/C when less than 1-year-old. Courtesy of Céline Deguette

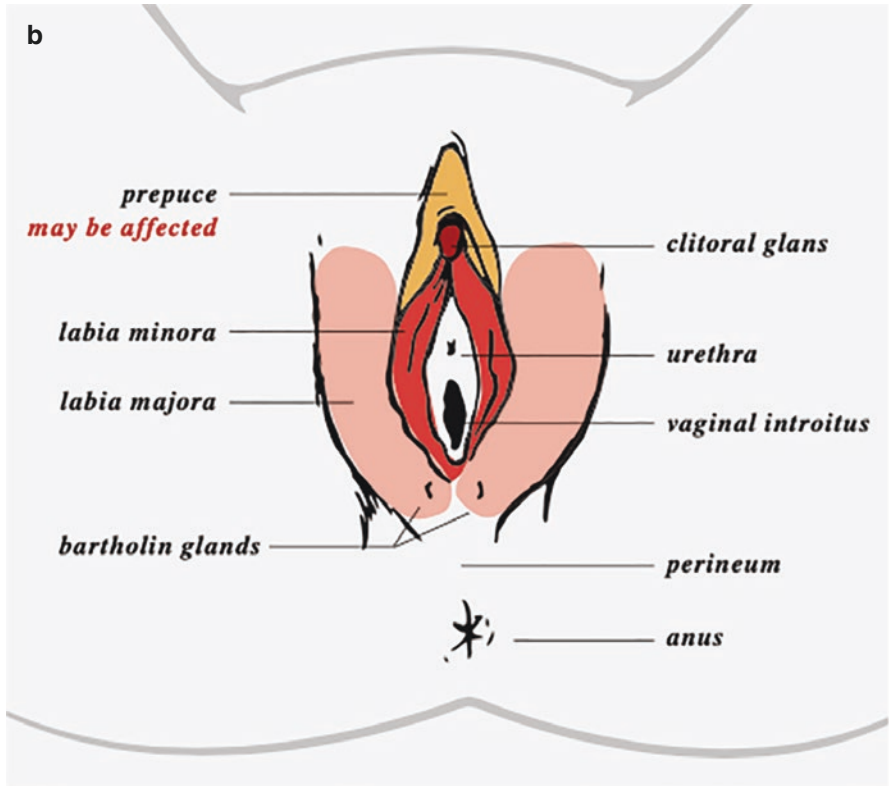
### 5.2 FGM/C Type II



**Type IIa:** removal of the labia minora only

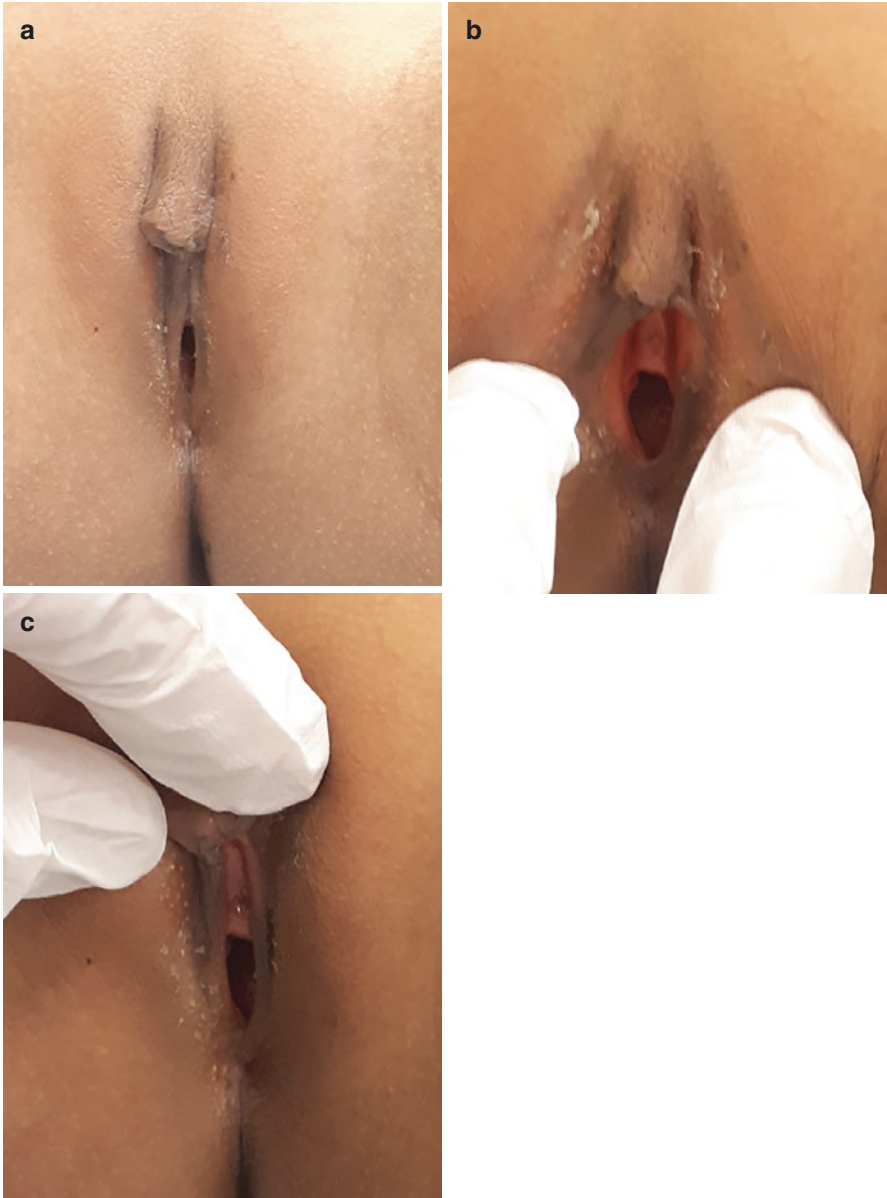**Type IIb:** partial or total removal of the clitoral glans and the labia minora (*prepuce may be affected*)

**Fig. 5.7** Diagram of FGM/C type IIa (cutting of labia minora only) (a); type IIb (cutting of the labia minora and the visible part of the clitoris more or less the clitoral hood) (b); and type IIc (cutting of the labia minora, majora, and the clitoris). (Reprinted with permission from WHO [17])



■ + ■ + ■ + ■ **Type IIc:** partial or total removal of the clitoral glans, the labia minora and the labia majora (*prepuce may be affected*)

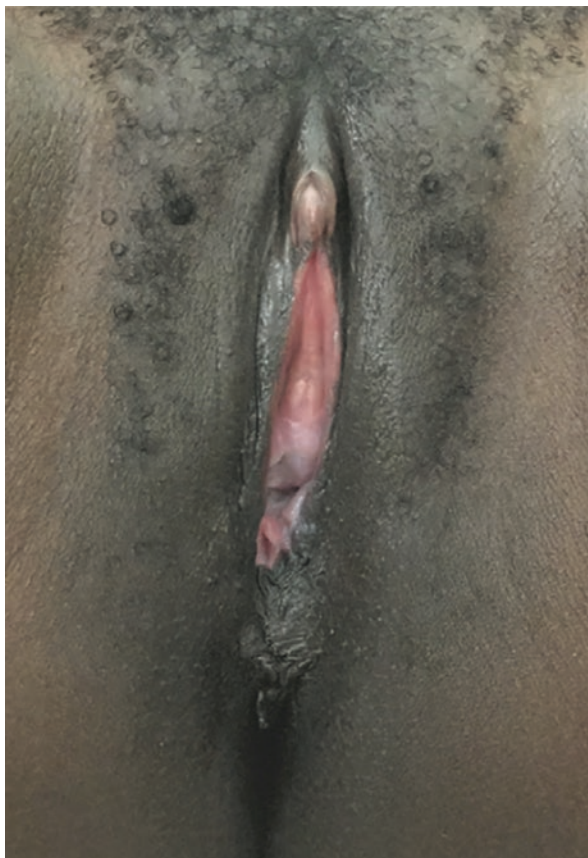
Fig. 5.7 (continued)

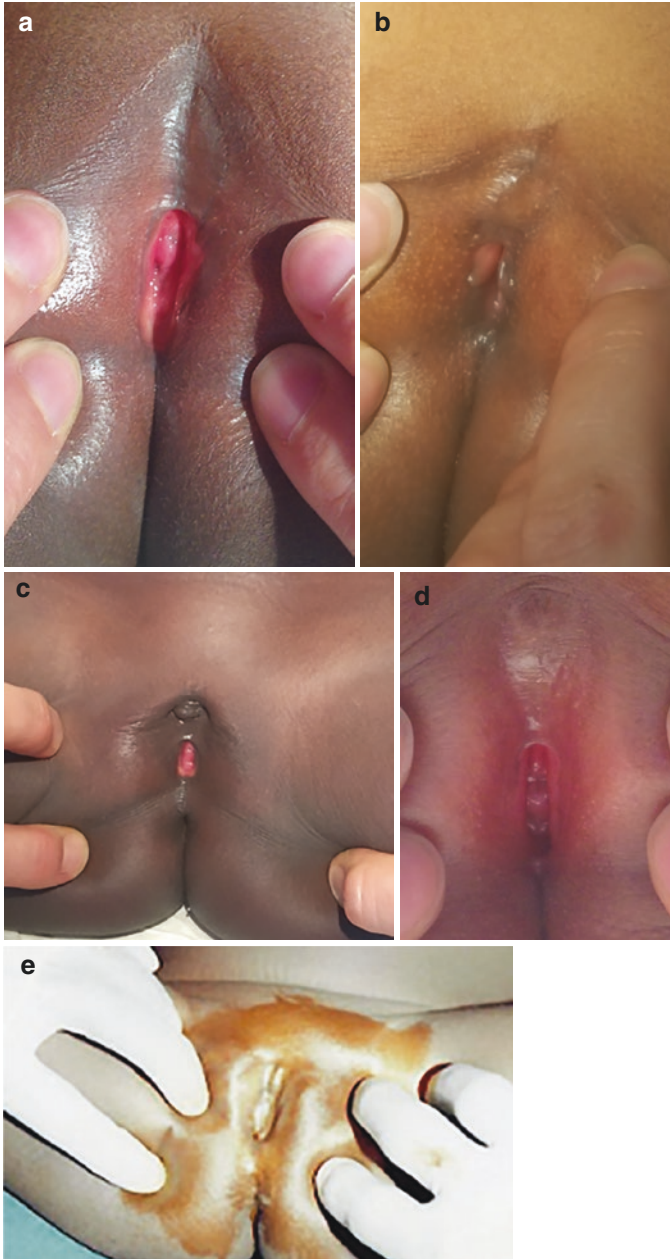


**Fig. 5.8** FGM/C IIa (cutting of the left inner labium) of a prepubertal girl of 9-years old from Eritrea (a–c). She had undergone FGM/C as a newborn. (Courtesy of Jasmine Abdulcadir)

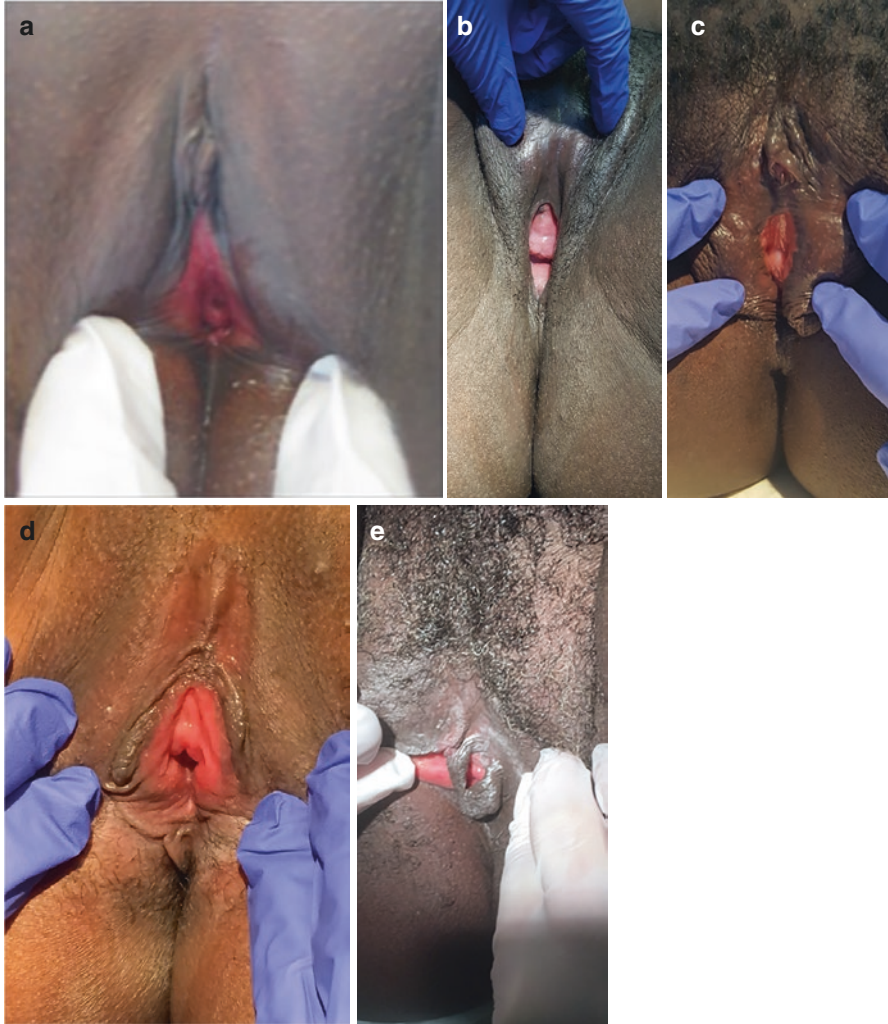

**Fig. 5.9** FGM/C type IIa (cutting of the inner labia), 30-years old, from Senegal. (Courtesy of Jasmine Abdulcadir [8])



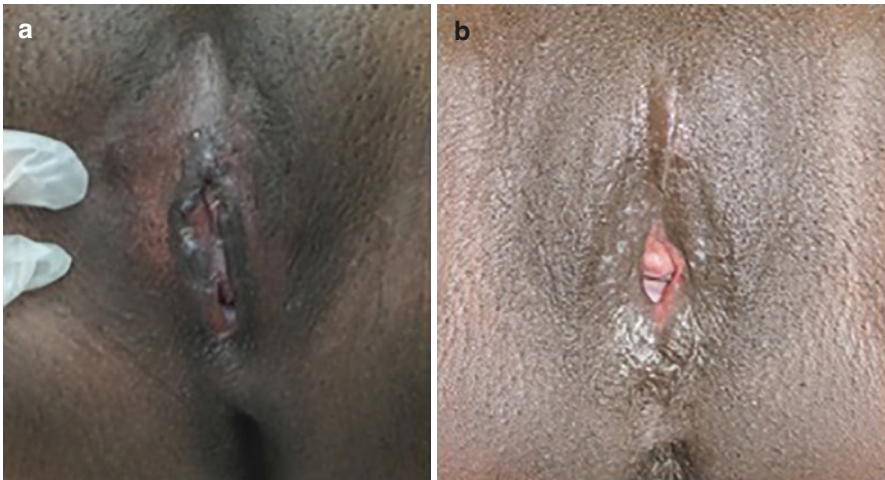
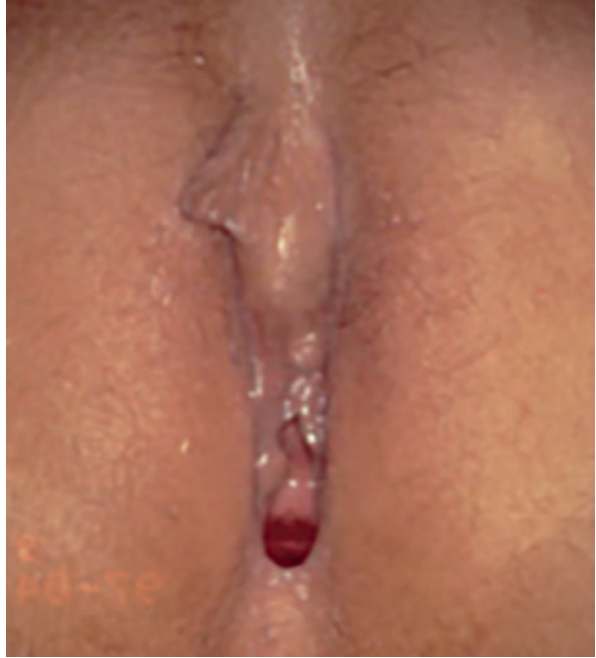

**Fig. 5.10** FGM/C type IIb (a) 4-years old, from Mali, having undergone FGM/C after birth (Courtesy of Céline Deguette). (b) 3-years old, from Mali (Courtesy of Céline Deguette). (c) 4-years old, from Mali, having undergone FGM/C at age 2. A keloid is present above the cut clitoris. (Courtesy of Céline Deguette). (d) 5-years old, from Mali. (Courtesy of Céline Deguette); (e) prepubertal girl, from Mali (Courtesy of Moustapha Touré)



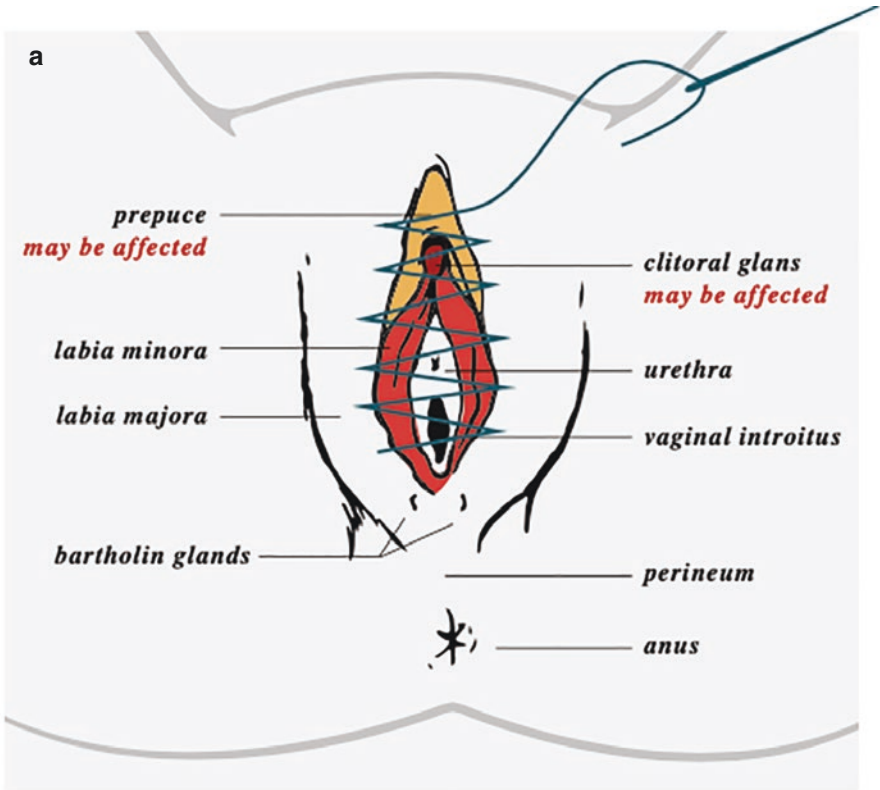
**Fig. 5.11** FGM/C type IIb in adult women. (a) 30-years old, from Eritrea, cutting of the inner labia, the prepuce, and the glans of the clitoris. She had undergone FGM/C as a newborn (Courtesy of Jasmine Abdulcadir [8]). (b) 26-years old, from Senegal, ethnic group: Soninke. Cutting of the clitoris, clitoral hood, and inner labia. She had undergone FGM/C at her birth (Courtesy of Céline Deguette). (c) 25-years old, from Ivory Coast, ethnic group: Dioula. Partial removal of the prepuce of the clitoris and inner labia. She had undergone FGM/C at age 8 (Courtesy of Céline Deguette). (d) 30-years old, from Senegal, she describes pain during sexual intercourse (Courtesy of Céline Deguette). (e) 36 years old, from Ivory Coast, cutting of the prepuce of the clitoris and clitoris with the left inner labium. She underwent FGM/C when less than 4 years old. (Courtesy of Céline Deguette)

**Fig. 5.12** FGM/C type IIb or IIc or IIIa in a prepubertal girl. The experts disagreed in the classification of this FGM/C. For some, there is cutting of the clitoral hood, the clitoris, and the inner labia (FGM/C type IIb). For others, there is cutting of the outer labia too (FGM/C type IIc). Finally, as there is a partial adhesion of the inner labia covering the urethral meatus, some authors would classify this picture as FGM/C type IIIa with cutting of the clitoris. Source: Graham EA. Ritual Female Genital Cutting [RFGC] PowerPoint slides. 2014. Available at: <https://ethnomed.org/resource/ritual-female-genital-cutting-rfgc-powerpoint-slides/> (CC BY-NC-ND 3.0 US) [58]



**Fig. 5.13** FGM/C type IIc (a) 30-years old from Eritrea and (b) 40-years old from Burkina Faso. (Courtesy of Jasmine Abdulcadir [8])

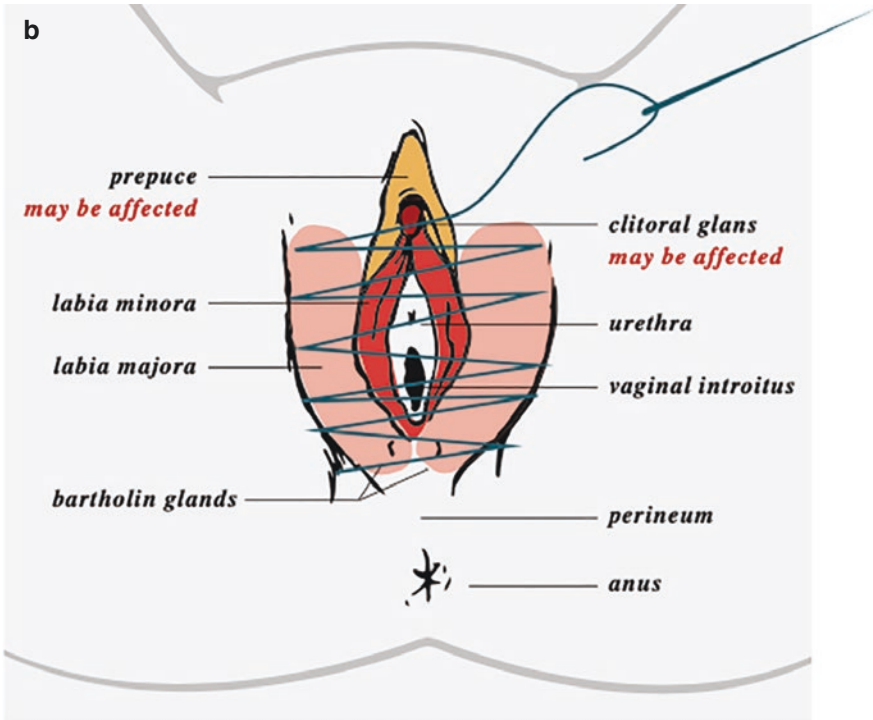
### 5.3 FGM/C Type III



#### Type IIIa:

■ + ■ + ■ + appositioning of the labia minora

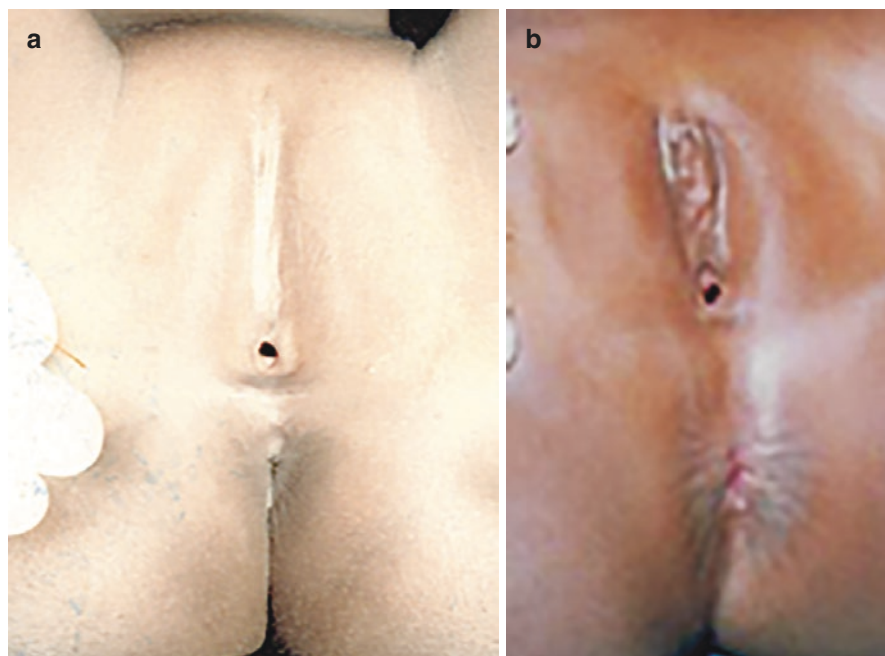
**Fig. 5.14** FGM/C type III. Often referred to as infibulation. Narrowing of the vaginal opening with the creation of a covering seal. The seal is formed by cutting and appositioning the labia minora, or labia majora. The covering of the vaginal opening is done with or without removal of the clitoral prepuce/clitoral hood glans and, part of the body of the clitoris. When it is important to distinguish between variations of Type III FGM/C, the following subdivisions are used: **Type IIIa**. Removal and appositioning of the labia minora (a). **Type IIIb**. Removal and appositioning of the labia majora (b). (Reprinted with permission from WHO [17])



**Type IIIb:**

■ + ■ + ■ + ■ + appositioning of the labia majora

Fig. 5.14 (continued)



**Fig. 5.15** FGM/C Type IIIa in prepubertal girls from Mali (a–e). (Courtesy of Moustapha Touré)

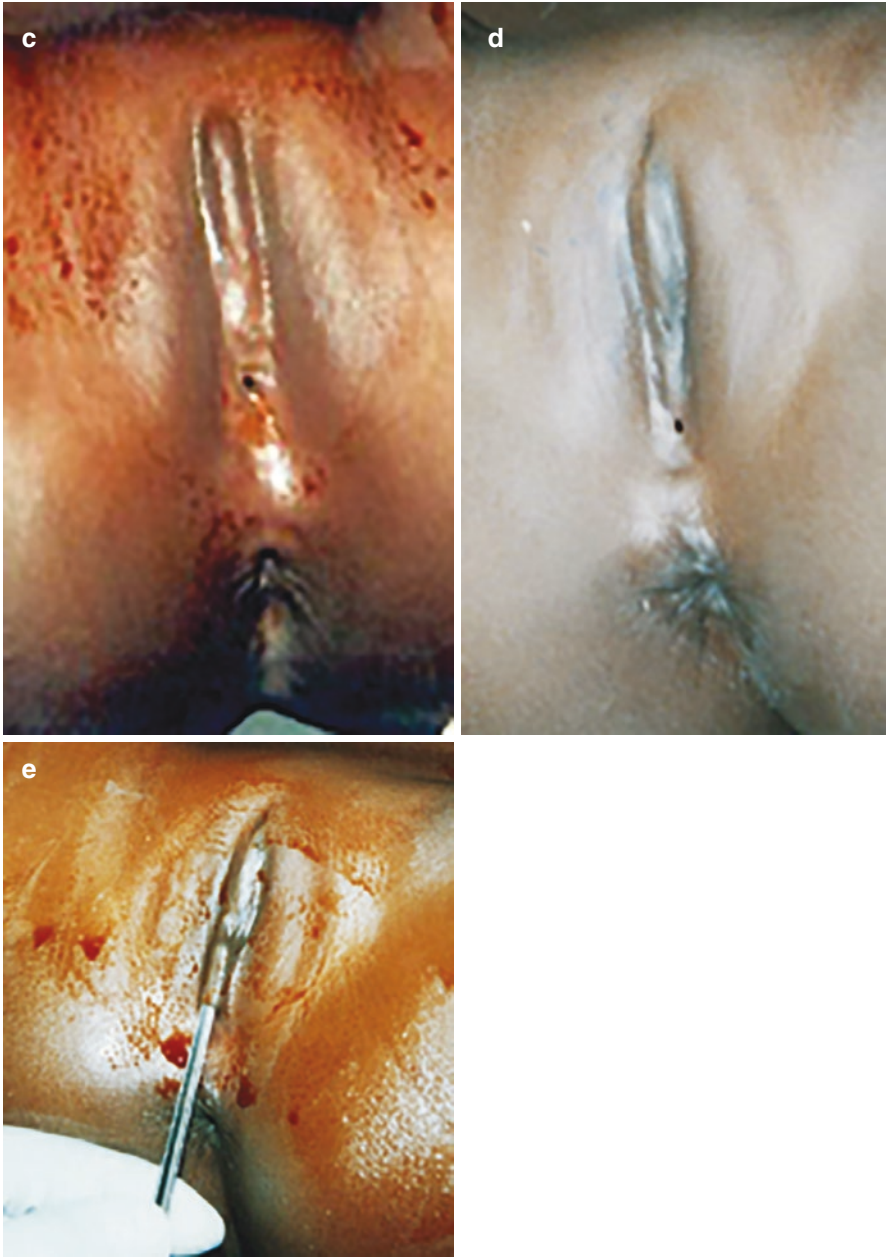
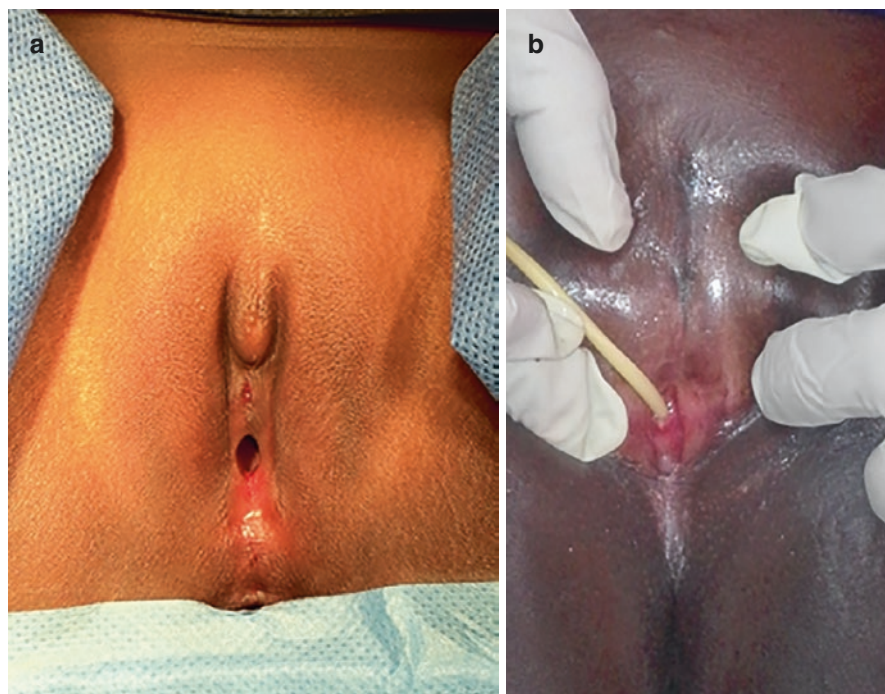
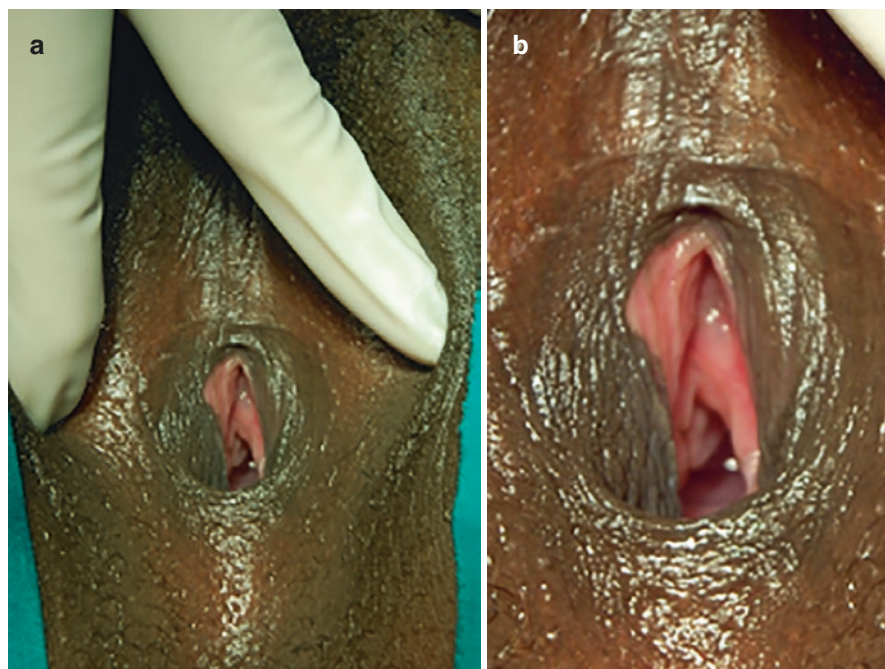


Fig. 5.15 (continued)

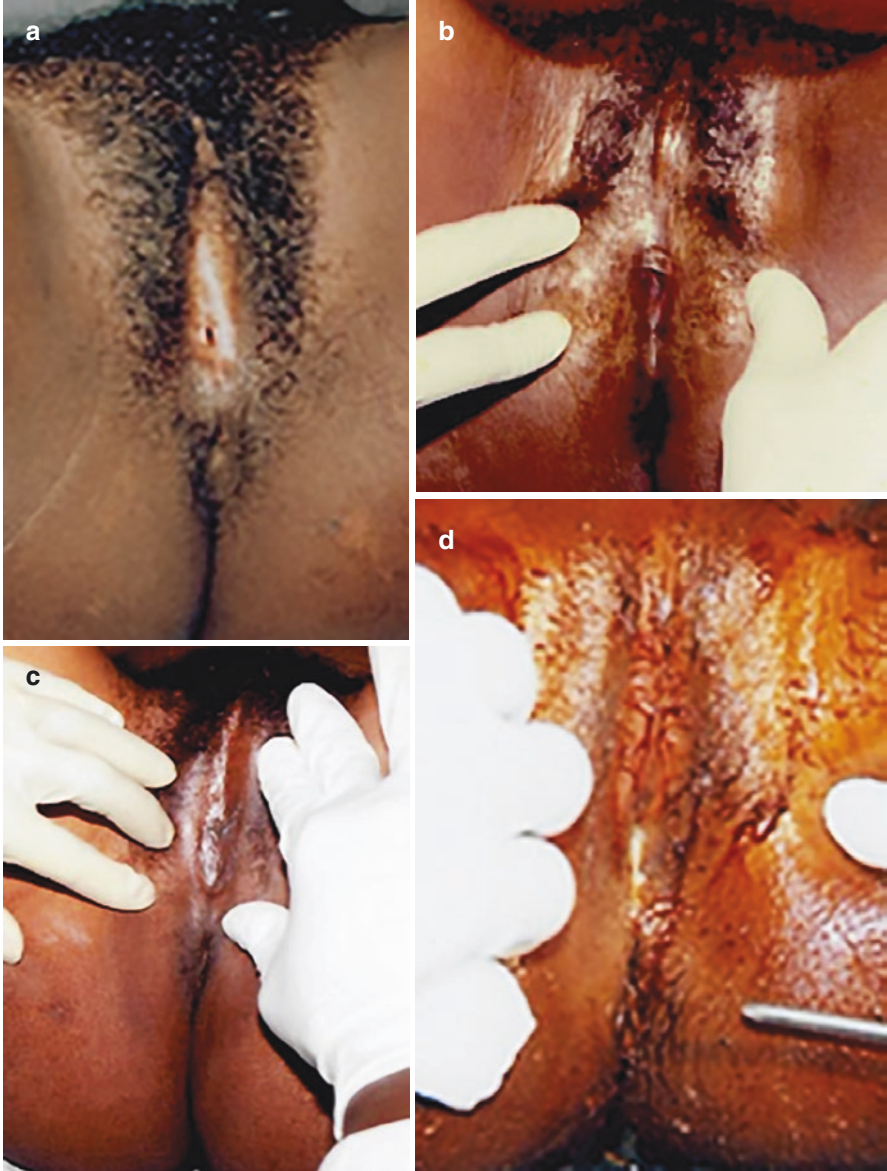



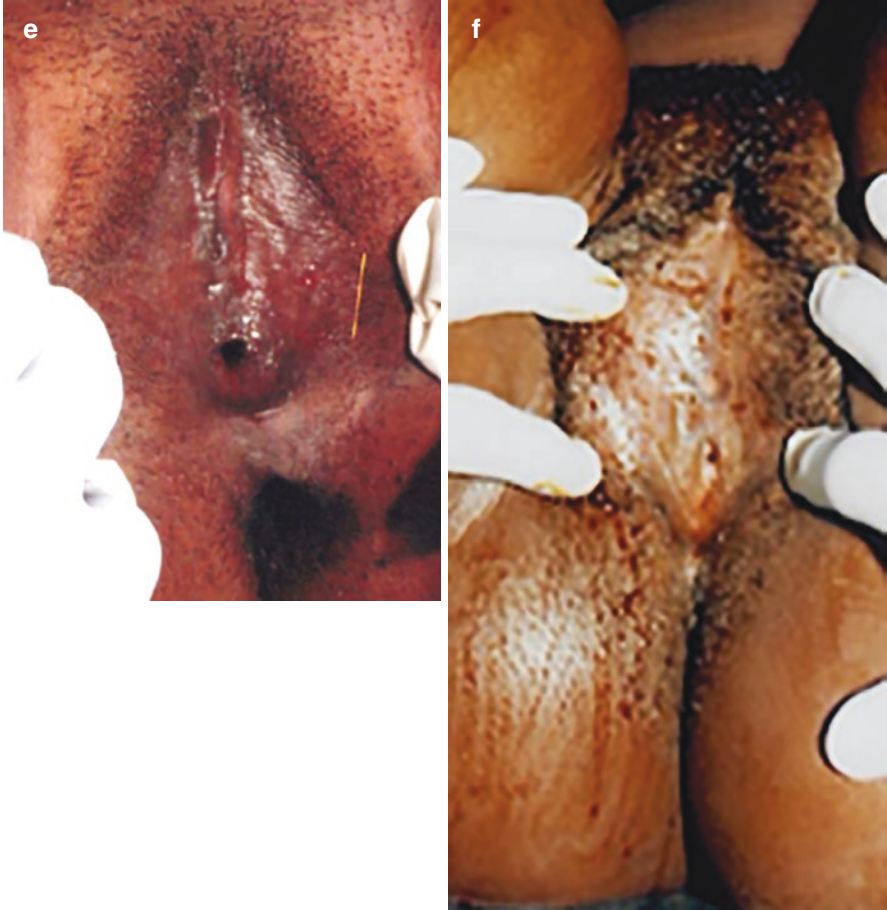
**Fig. 5.16** FGM/C Type IIIa with cutting of the clitoris in a prepubertal girl (a) 11-years old, from Somalia (Courtesy of Martin Caillet). (b) Prepubertal girl, from Gambia. A urinary catheter is inserted (Courtesy of Adriana Kaplan Marcusan)



**Fig. 5.17** FGM/C type IIIa, 12-years old from Ethiopia (a, b). (Courtesy of Amelia Valladolid)



**Fig. 5.18** FGM/C Type IIIa in adult women from Mali (a–i). (Courtesy of Moustapha Touré)



**Fig. 5.18** (continued)

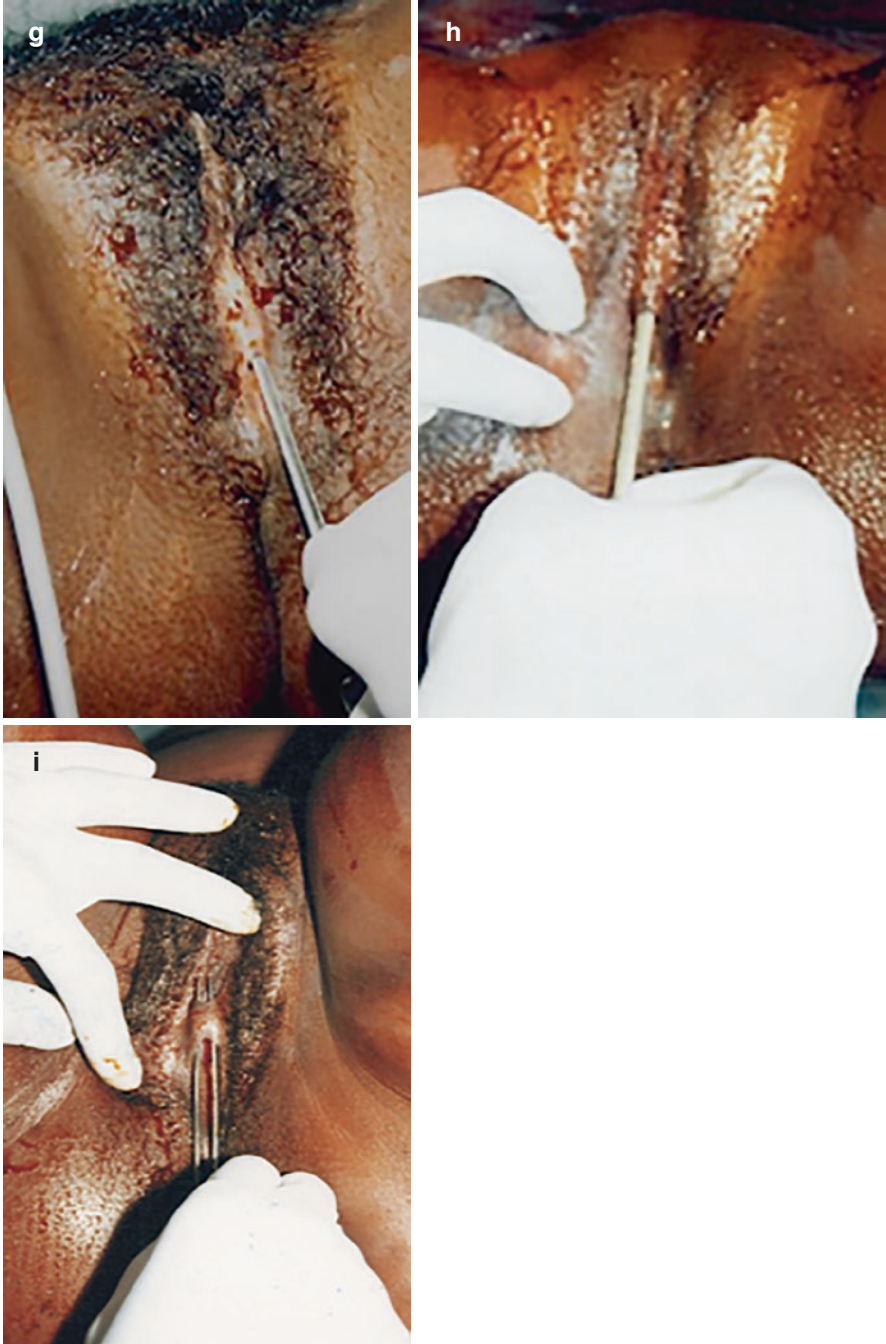
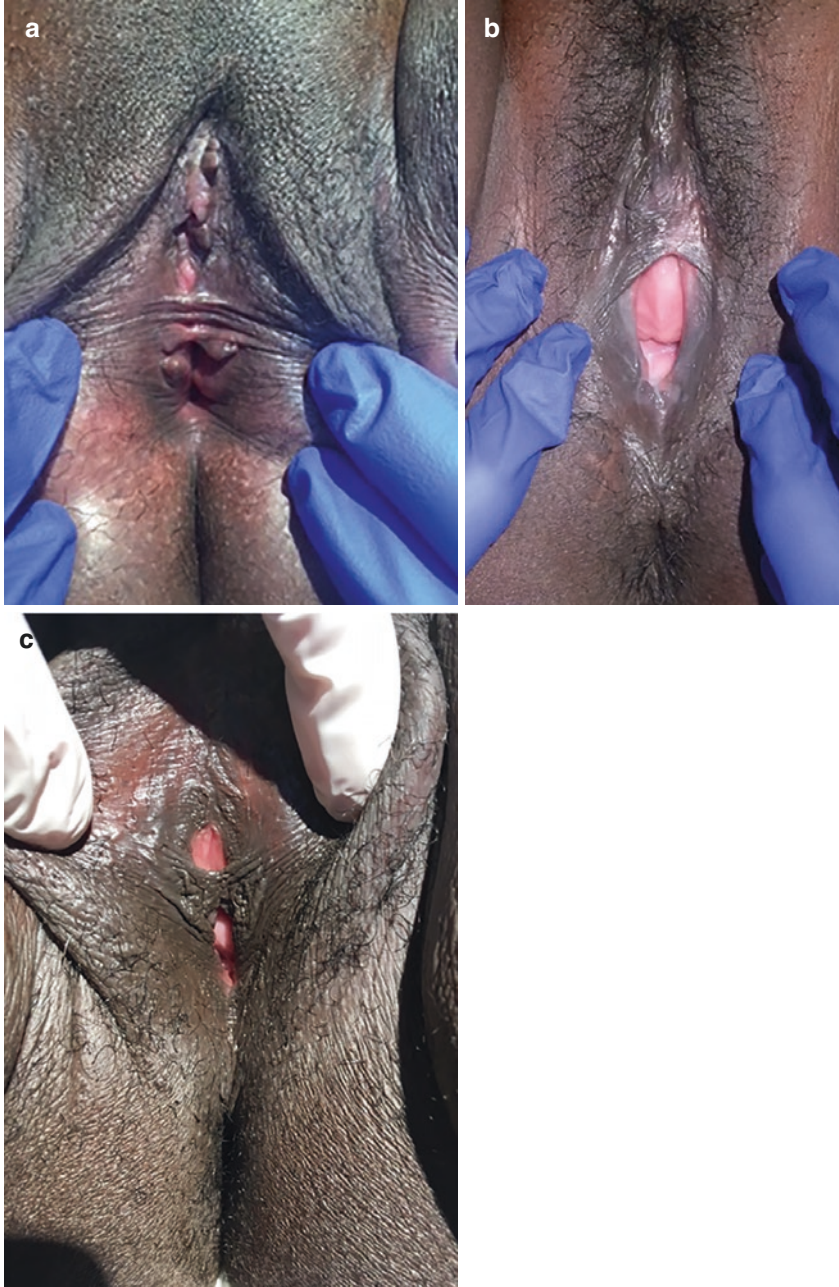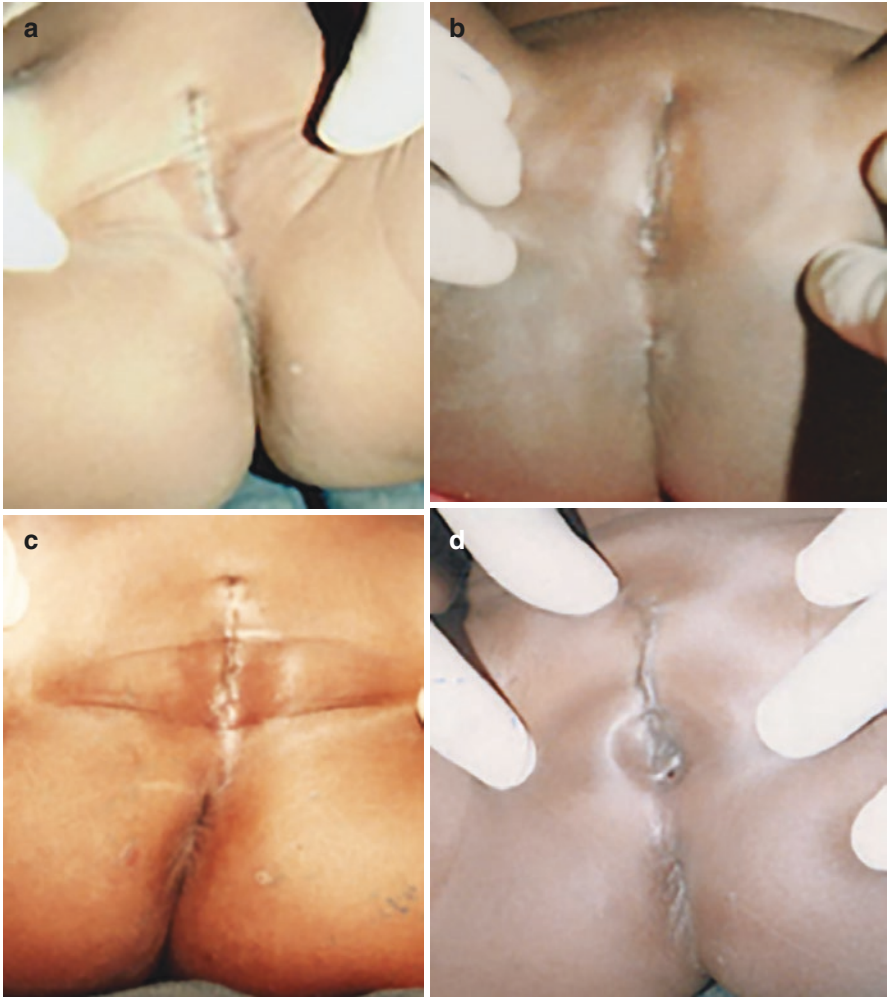


Fig. 5.18 (continued)



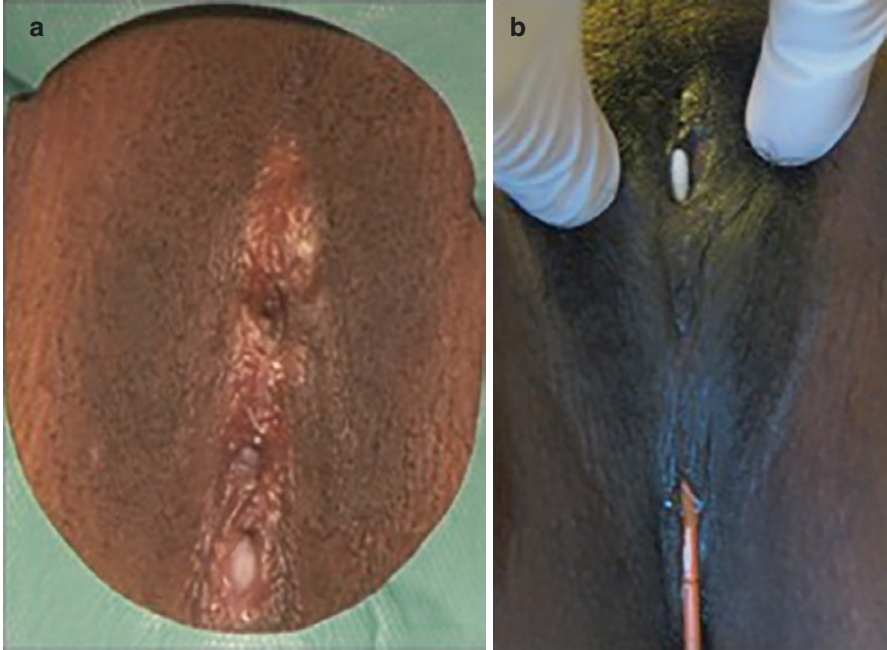
**Fig. 5.19** FGM/C type IIIa. (a) 28-years old, from Somalia with cutting and apposition of the inner labia, and cutting of the clitoral hood. She had undergone FGM/C at the age of 8. (b) 25-years old, from Somalia, narrowing of the vaginal orifice by the apposition of the inner labia after cutting of the inner labia, the clitoral hood, and the clitoris. She had undergone FGM/C at age 7 (Courtesy of Céline Deguette). (c) 33-years old, from Mali, narrowing of the vaginal orifice by the apposition of the inner labia after cutting of the inner labia, the clitoral hood, and the clitoris. She had undergone FGM/C at age 2 (Courtesy of Céline Deguette)



**Fig. 5.20** FGM/C type IIIb in prepubertal girls from Mali (a–g). (Courtesy of Moustapha Touré)

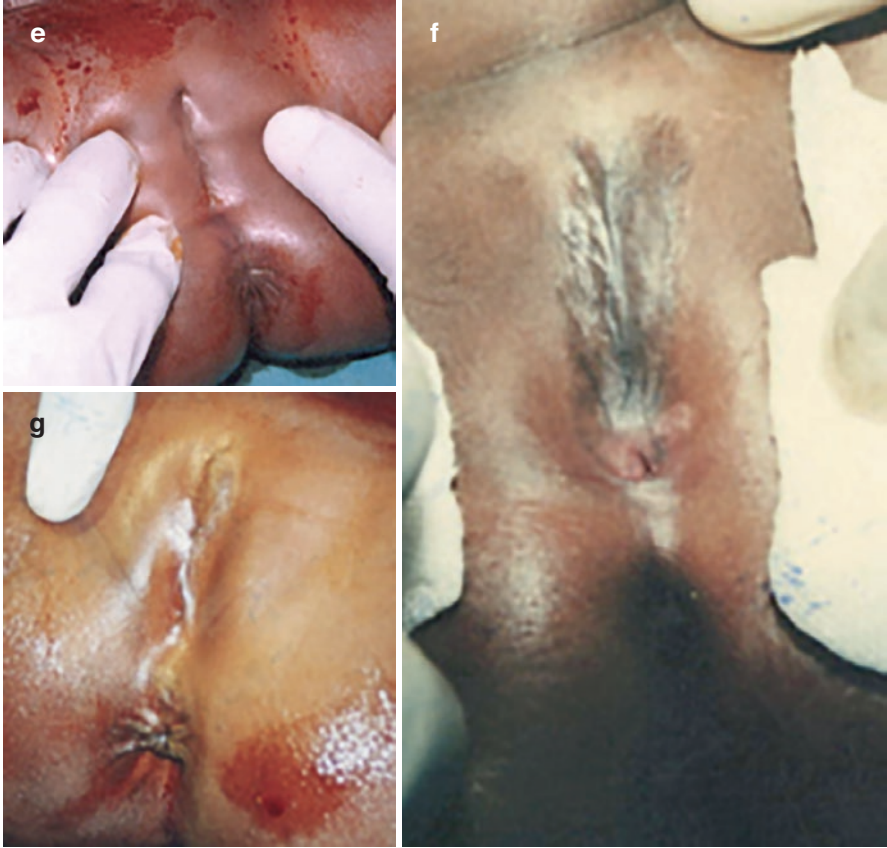

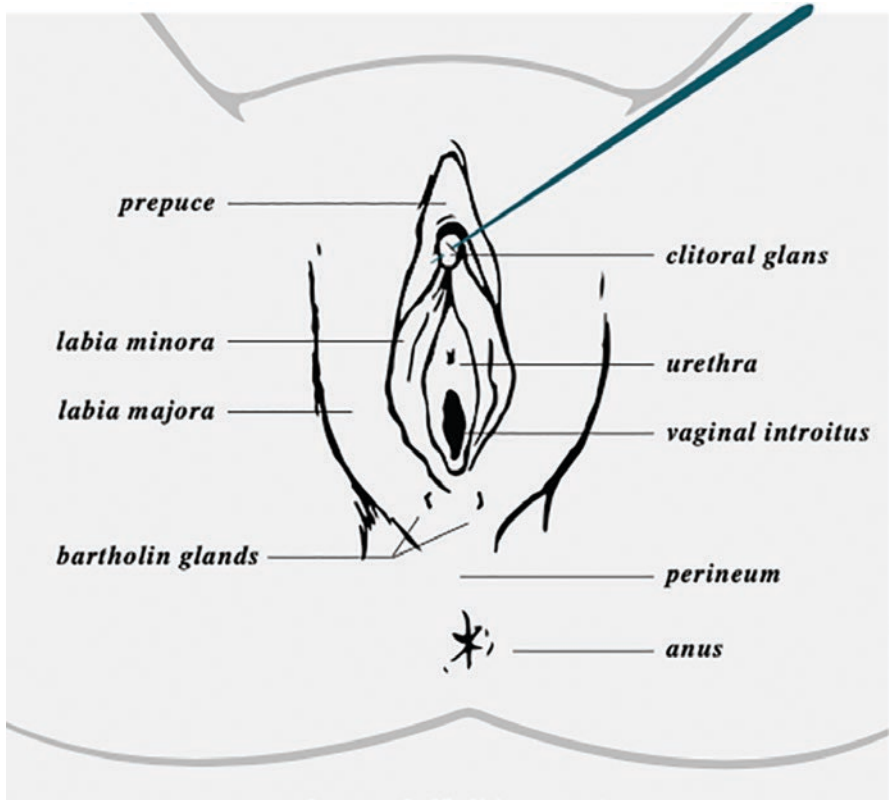
Fig. 5.20 (continued)



**Fig. 5.21** FGM/C type III b in adults (a) from Eritrea and (b) from Somalia. (Courtesy of Jasmine Abdulcadir [8])

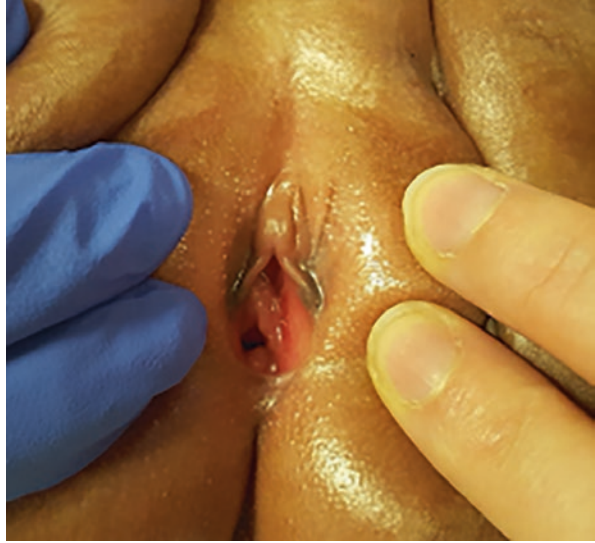

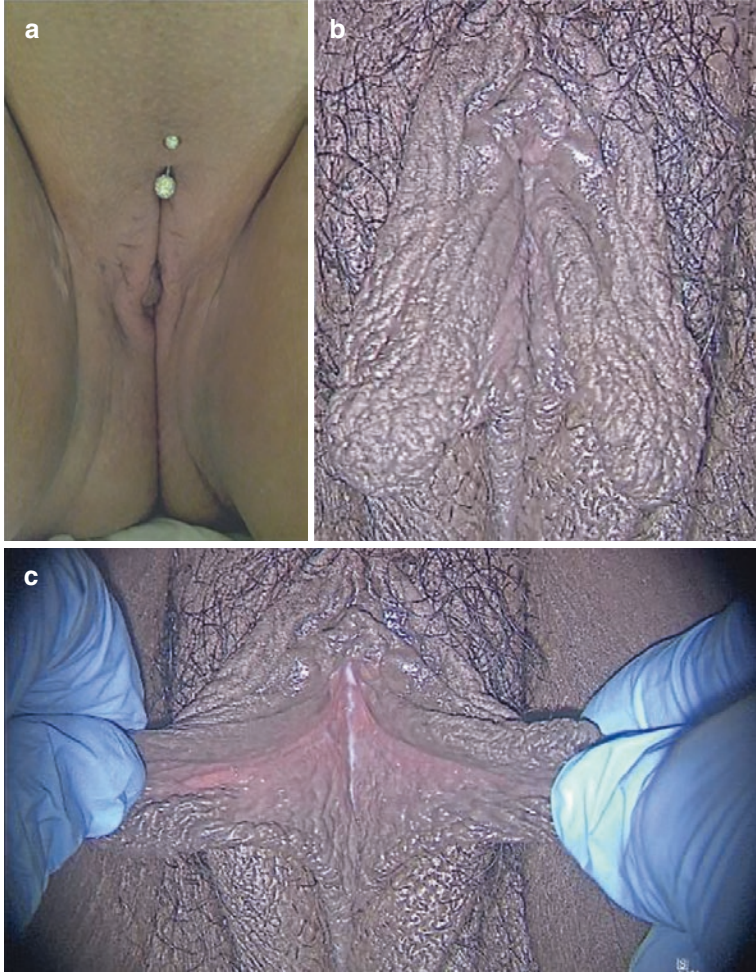
### 5.4 FGM/C Type IV



**Fig. 5.22** FGM/C type IV. Unclassified. All other harmful procedures to the female genitalia for nonmedical purposes, for example, pricking, piercing, incising, scraping, and cauterization and, stretching of the labia minora. (Reprinted with permission from WHO [17])

**Fig. 5.23** FGM/C type IV (nicking), 6-months old, from Ivory Coast, born in France. Linear scar on the left outer labium. (Courtesy of Céline Deguette)





**Fig. 5.24** FGM/C type IV in adult women. (a) Piercing in an adult woman from Switzerland (Courtesy of Jasmine Abdulcadir [8]). (b) and (c) 36 years old from Zambia. Stretching of the inner labia at 12 years old. Asymptomatic. Each time you report (Courtesy of Jasmine Abdulcadir). (d) and (e) *khatna*, nicking. 39 years old, born in France from a mother from a region in India on the border with Pakistan (Dawoodi Bohra community). She underwent FGM/C at age 6 during a trip to India. A linear scar is visible on the left side of the prepuce (white circle). Photo taken with a colposcope (Courtesy of Jasmine Abdulcadir). (f), (g) and (h) Linear scar of nicking of the prepuce of the clitoris in a 41-year-old woman from Kurdistan (black circle). She refers having undergone FGM/C at the age of 6, at home, in Kurdistan with spontaneous healing in 4–5 days after the cutting. Perineal scarring post two vaginal births and hemorrhoids. There is an asymmetry of the inner labia, probably unrelated to the history of FGM/C. For some examiners, there might be a doubt for a differential diagnosis of FGM/C type IIa (cutting of the right inner labium) and an obstetric perineal scar (Courtesy of Jasmine Abdulcadir)

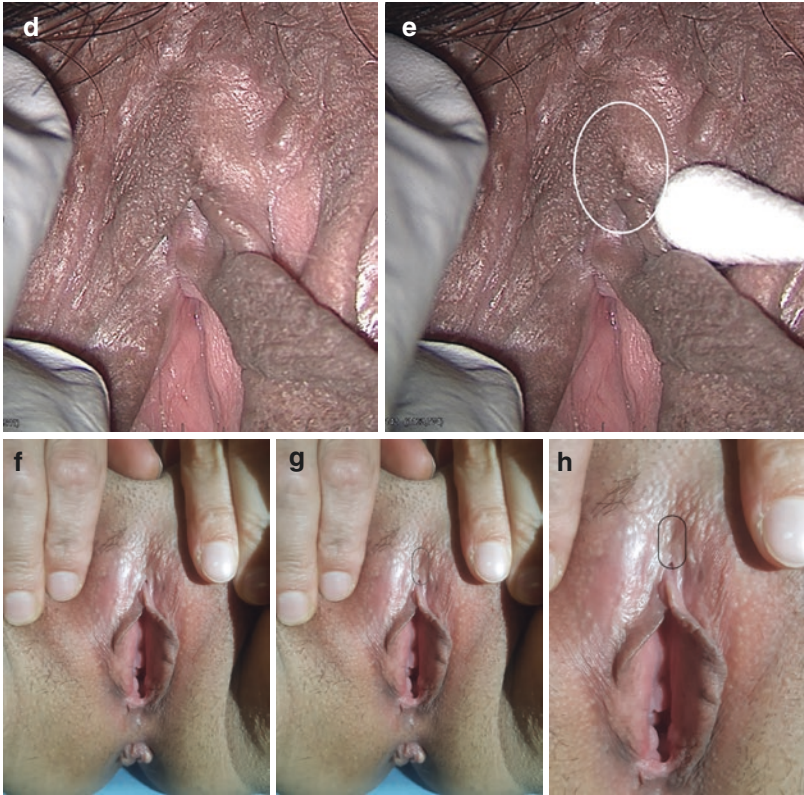

Fig. 5.24 (continued)

**Open Access** This chapter is licensed under the terms of the Creative Commons Attribution 4.0 International License (<http://creativecommons.org/licenses/by/4.0/>), which permits use, sharing, adaptation, distribution and reproduction in any medium or format, as long as you give appropriate credit to the original author(s) and the source, provide a link to the Creative Commons license and indicate if changes were made.

The images or other third party material in this chapter are included in the chapter's Creative Commons license, unless indicated otherwise in a credit line to the material. If material is not included in the chapter's Creative Commons license and your intended use is not permitted by statutory regulation or exceeds the permitted use, you will need to obtain permission directly from the copyright holder.



# Chapter 6

## FGM/C Complications



**Jasmine Abdulcadir, Noémie Sachs Guedj, Michal Yaron, Omar Abdulcadir, Juliet Albert, Martin Caillet, Lucrezia Catania, Sarah M. Creighton, Céline Deguette, Elise Dubuc, Brian D. Earp, Birgitta Essén, Deborah Hodes, Adriana Kaplan Marcusan, Ranit Mishori, Deborah Ottenheimer, Fabienne Richard, Aida Sy, Moustapha Touré, Amelia Valladolid, Anneke Vercoutere, Bilkis Vissandjée, and Janine Young**

---

J. Abdulcadir (✉) · N. S. Guedj · M. Yaron

Department of Pediatrics, Gynecology and Obstetrics, Geneva University Hospitals, Geneva, Switzerland

e-mail: [jasmine.abdulcadir@hcuge.ch](mailto:jasmine.abdulcadir@hcuge.ch); [michal.yaron@hcuge.ch](mailto:michal.yaron@hcuge.ch)

O. Abdulcadir · L. Catania

Referral Center for Curing and Preventing FGM. AOUC, Florence, Italy

J. Albert

Imperial College Healthcare, NHS Trust, London, UK

e-mail: [juliet.albert@nhs.net](mailto:juliet.albert@nhs.net)

M. Caillet

CHU Saint-Pierre, Brussels, Belgium

e-mail: [martin\\_caillet@stpierre-bru.be](mailto:martin_caillet@stpierre-bru.be)

S. M. Creighton · D. Hodes

University College London Hospital, London, UK

e-mail: [sarah.creighton2@nhs.net](mailto:sarah.creighton2@nhs.net); [deborah.hodes@nhs.net](mailto:deborah.hodes@nhs.net)

C. Deguette

Department of Forensic Medicine, AP-HP. Centre-University of Paris, Paris, France

e-mail: [celine.deguette@aphp.fr](mailto:celine.deguette@aphp.fr)

E. Dubuc

CHU Sainte-Justine, Montréal, QC, Canada

e-mail: [elise.dubuc.1@umontreal.ca](mailto:elise.dubuc.1@umontreal.ca)

B. D. Earp

Departments of Philosophy and Psychology, Yale University, New Haven, CT, USA

e-mail: [brian.earp@yale.edu](mailto:brian.earp@yale.edu)

B. Essén

Women's and Children's Health/IMCH, WHO Collaborating Centre on Migration and Health, Uppsala University, Uppsala, Sweden

e-mail: [brigitta.essen@kbh.uu.se](mailto:brigitta.essen@kbh.uu.se)

A. K. Marcusan

Department of Social and Cultural Anthropology, UAB, Barcelona, Spain

e-mail: [adriana.kaplan@uab.cat](mailto:adriana.kaplan@uab.cat)

© The Author(s) 2022

J. Abdulcadir et al. (eds.), *Female Genital Mutilation/Cutting in Children and Adolescents*, [https://doi.org/10.1007/978-3-030-81736-7\\_6](https://doi.org/10.1007/978-3-030-81736-7_6)

R. Mishori

Georgetown University Department of Family Medicine, and Physicians for Human Rights,  
Washington, DC, USA

e-mail: [mishorir@georgetown.edu](mailto:mishorir@georgetown.edu)

D. Ottenheimer

Morrisania Diagnostic and Treatment Center, Bronx, NY, USA

e-mail: [deb@ottenheimerhealth.com](mailto:deb@ottenheimerhealth.com)

F. Richard

GAMS Belgique, Brussels, Belgium

Ecole de santé publique, Université Libre de Bruxelles, Brussels, Belgium

e-mail: [fabienne@gams.be](mailto:fabienne@gams.be)

A. Sy

Bamako, Mali

M. Touré

Malian Society of Gynecology and Obstetrics, Bamako, Mali

A. Valladolid

Universidad del Pais Vasco, Vizcaya, Spain

A. Vercoutere

Community and Health Project in Guinea Conakry, Conakry, Guinea

Hôpital Erasme, University Hospital ULB, Brussels, Belgium

e-mail: [An.Vercoutere@erasme.ulb.ac.be](mailto:An.Vercoutere@erasme.ulb.ac.be)

B. Vissandjée

Université de Montreal, Montreal, Quebec, Canada

e-mail: [bilkis.vissandjee@umontreal.ca](mailto:bilkis.vissandjee@umontreal.ca)

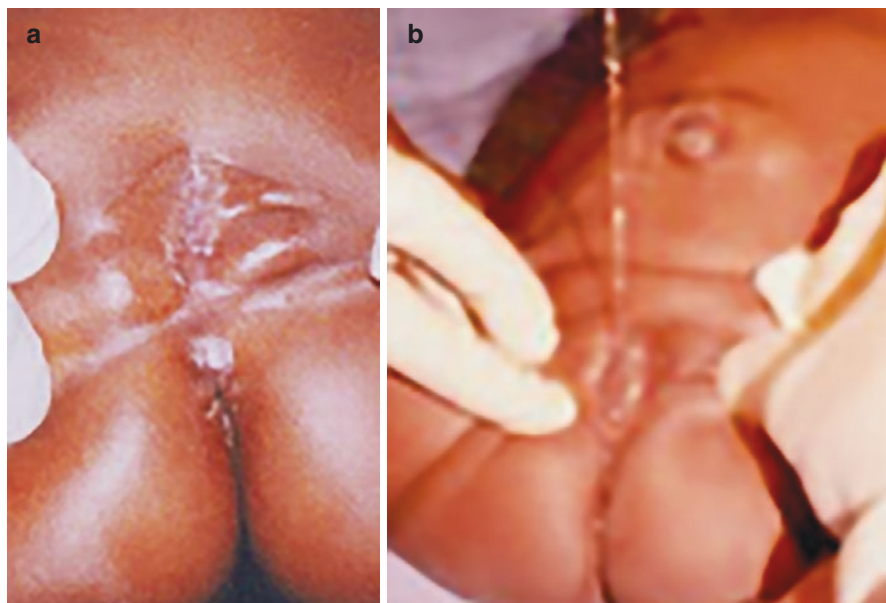
J. Young

Department of Pediatrics, Denver Health and Hospitals, University of Colorado School of  
Medicine, Denver, CO, USA

e-mail: [janine.young@dhha.org](mailto:janine.young@dhha.org)

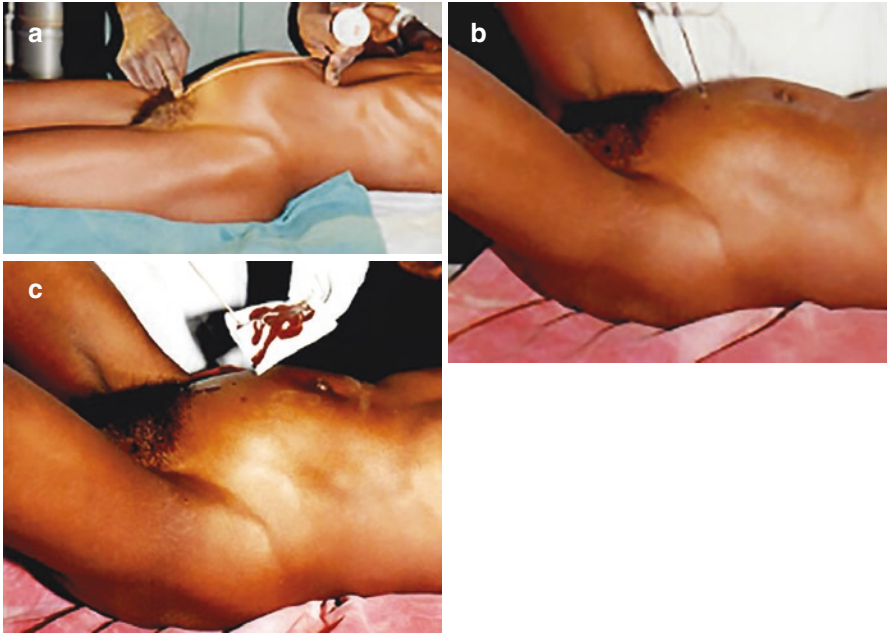## 6.1 Acute

### 6.1.1 Prepubertal



**Fig. 6.1** FGM/C type IIIb in a 16-month old girl from Mali (**a, b**), admitted with acute retention of urine and acute renal failure, Mali. (Courtesy of Moustapha Touré)

**6.1.2 Postpubertal**

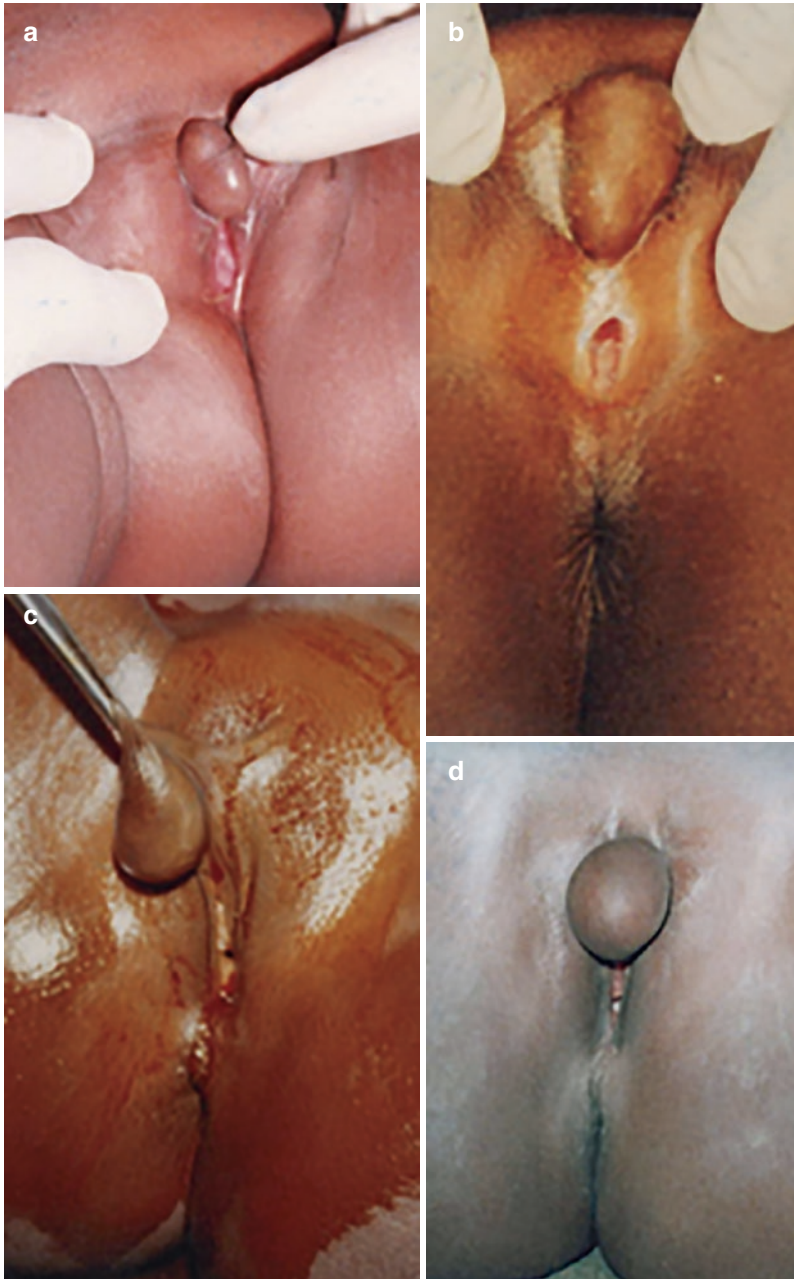

**Fig. 6.2** Hematocolpos and hematometra after FGM/C type III in a girl, from Mali (a–c). (Courtesy of Moustapha Touré)

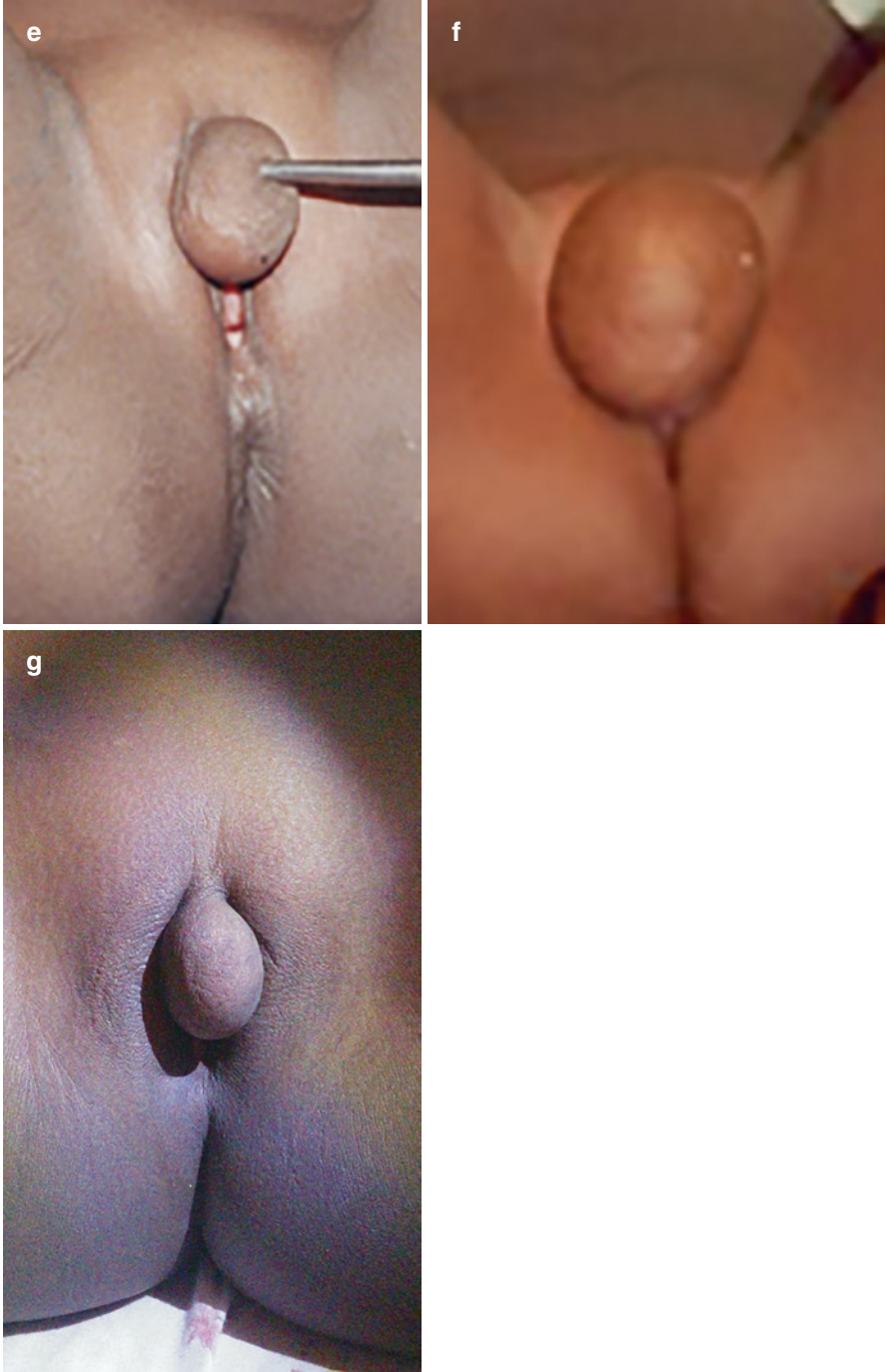

## 6.2 Long Term

### 6.2.1 Prepubertal

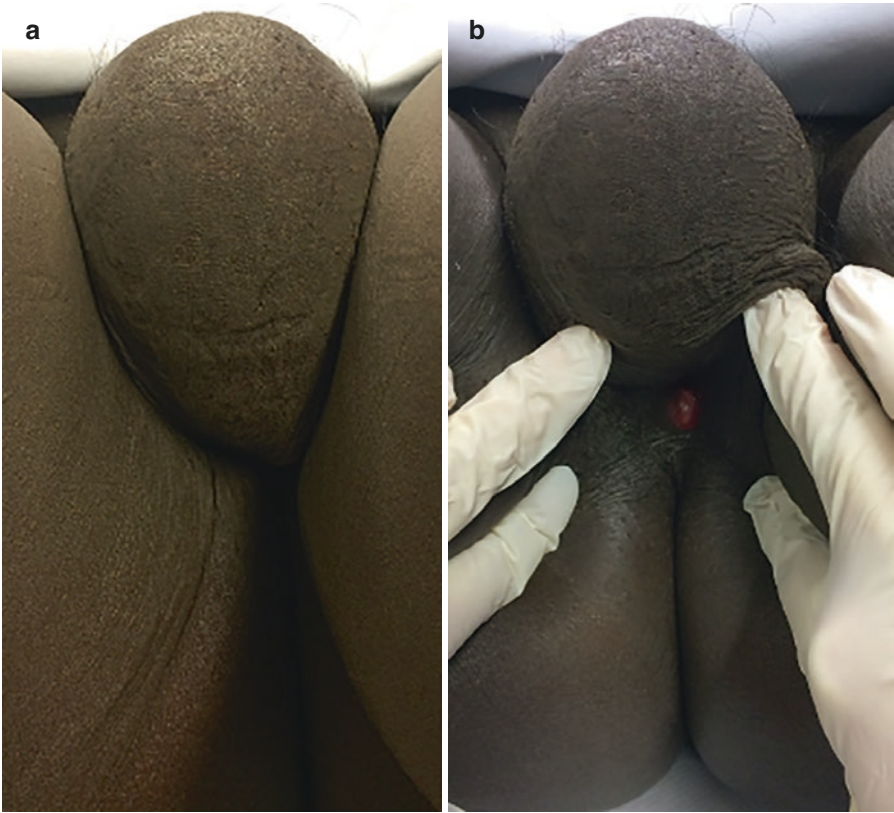


**Fig. 6.3** Epidermal cysts in prepubertal girls from Mali. (a–e Courtesy of Moustapha Touré, f Courtesy of Aïda Sy). (g) 5-years old, cut at 11-months, from Guinea (Courtesy of Anneke Vercoutere)



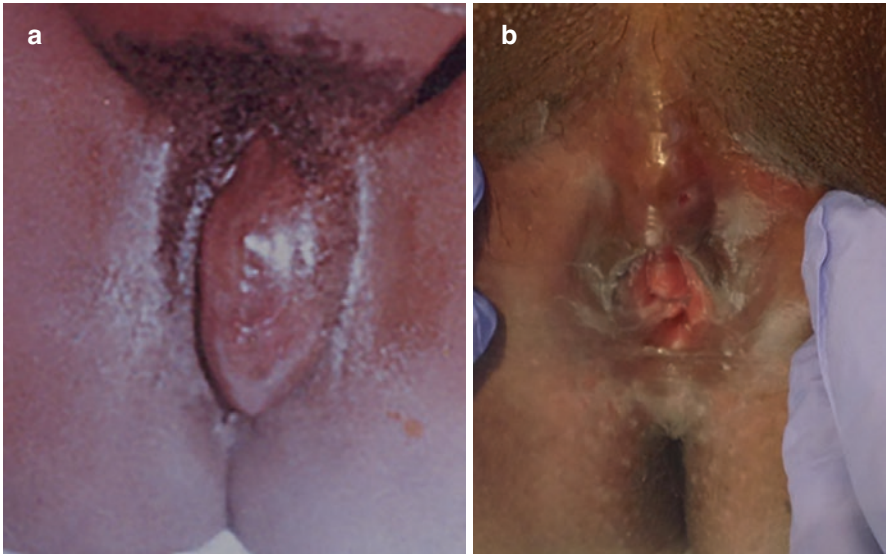
**Fig. 6.3** (continued)

**6.2.2 Postpubertal**



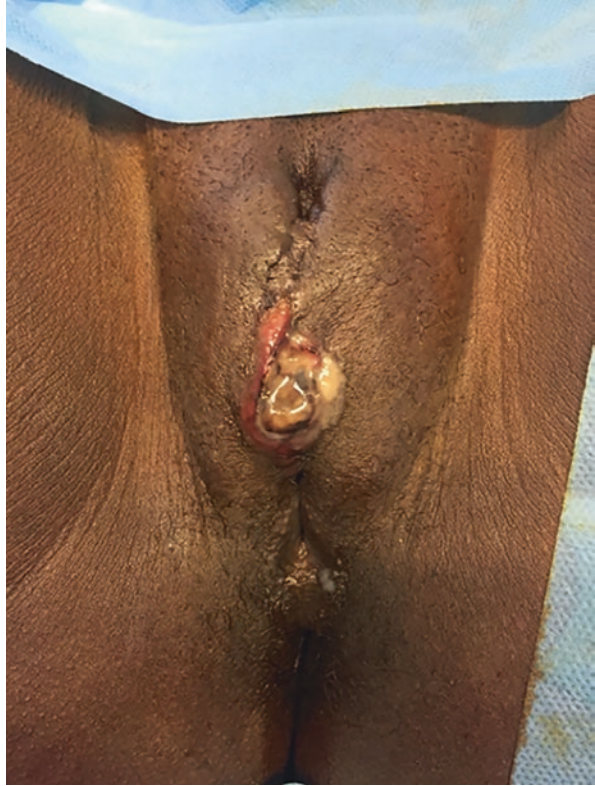**Fig. 6.4** Epidermal cyst in an adult woman from Somalia (a, b). (Courtesy of Juliet Albert)

### 6.3 Acute and Long Term

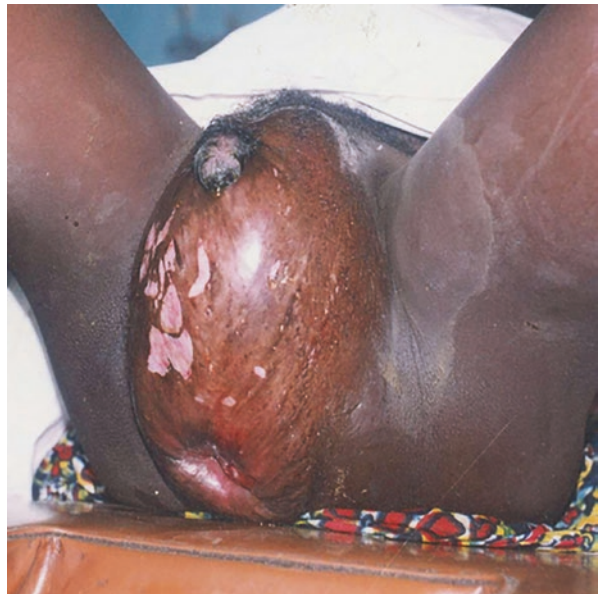

**Fig. 6.5** Abscess in a prepubertal girl shortly after FGM/C in Mali (a) (Courtesy of Moustapha Touré). (b) Third episode of clitoral abscess, 15-year-old girl who was cut at the age of 9 (FGM/C type IIb) (Courtesy of Anneke Vercoutere)

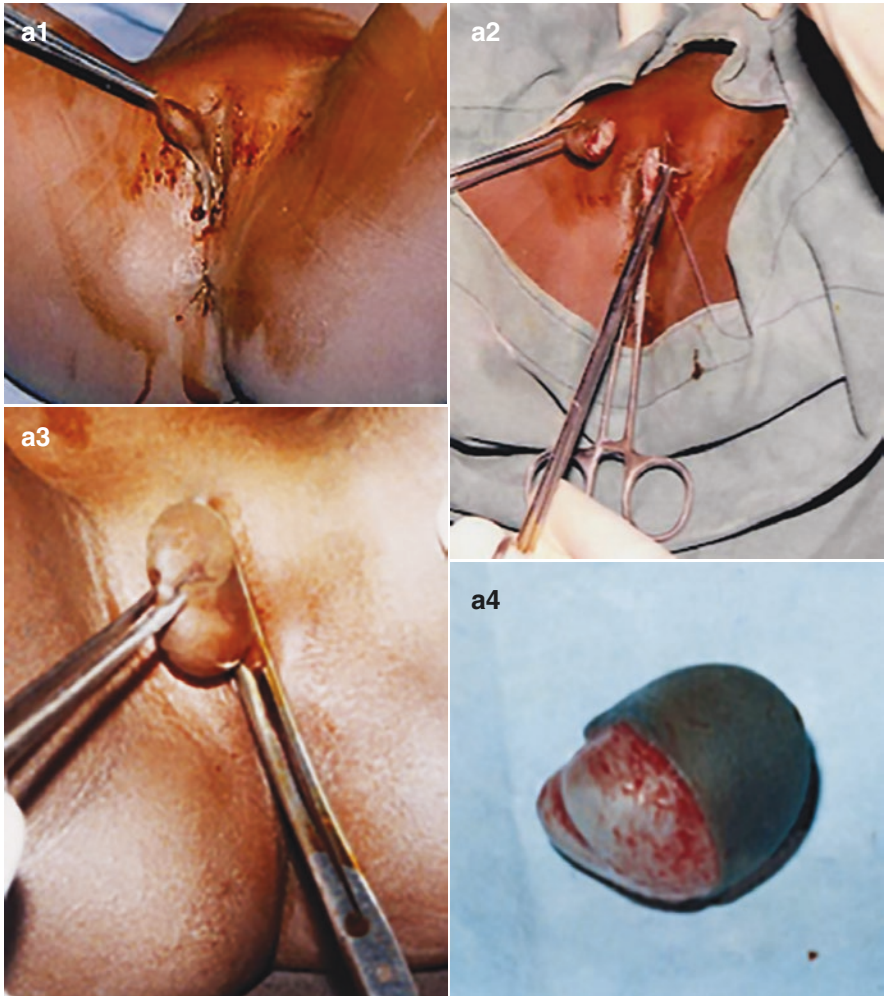
**Fig. 6.6** FGM/C type IIIa in a postpubertal girl of 15-years old from Somalia, presenting with a vulvar abscess of 6 cm. (Courtesy of Martin Caillet)



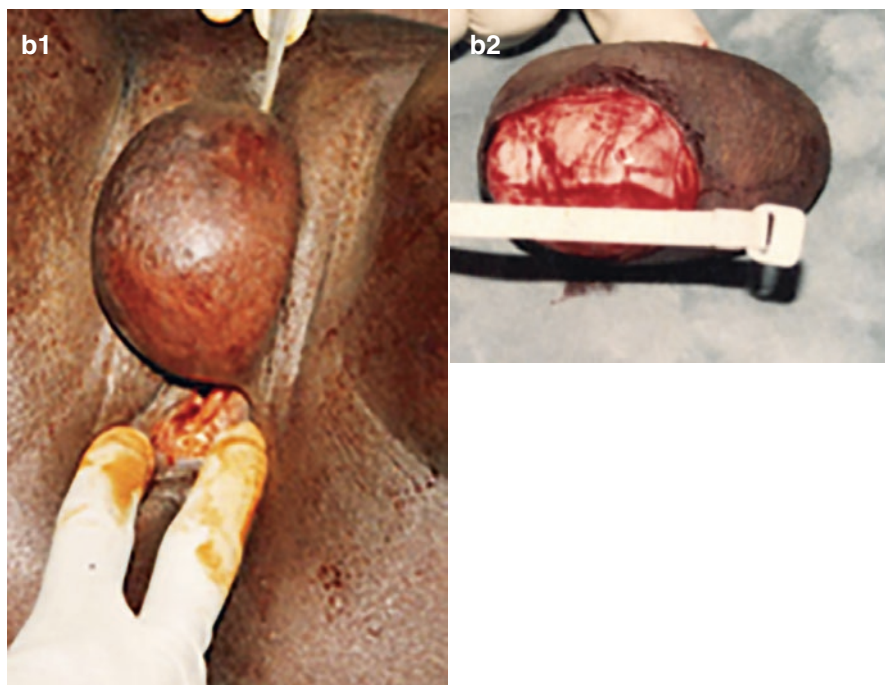
**Fig. 6.7** 16-year-old girl from Mali, with a history of FGM/C type III at the age of 12, married at 15, pregnant at 16. Labour dystocia for 3 days in her rural village. Brought to the hospital with a cart and a pirogue. Received with a dead foetus, vesico-vaginal and recto-vaginal fistulas, and a puerperal psychosis. She remained hospitalized for three months and underwent three surgeries. (Courtesy of Moustapha Touré [13])



### 6.4 Surgical Treatments of Complications of FGM/C



**Fig. 6.8** Vulvar cystectomy in prepubertal girls, from Mali (a1–a4, b1–b2, c1–c3). (Courtesy of Moustapha Touré)

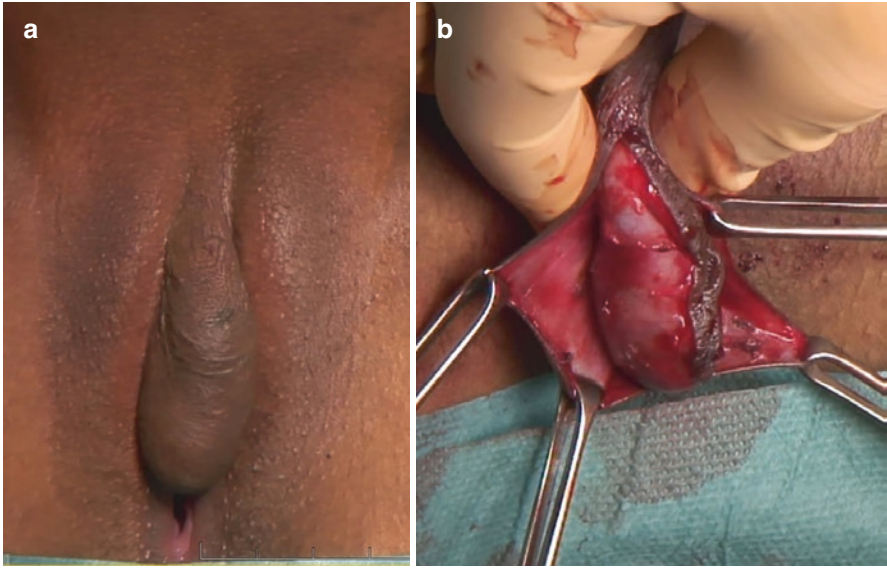


**Fig. 6.8** (continued)

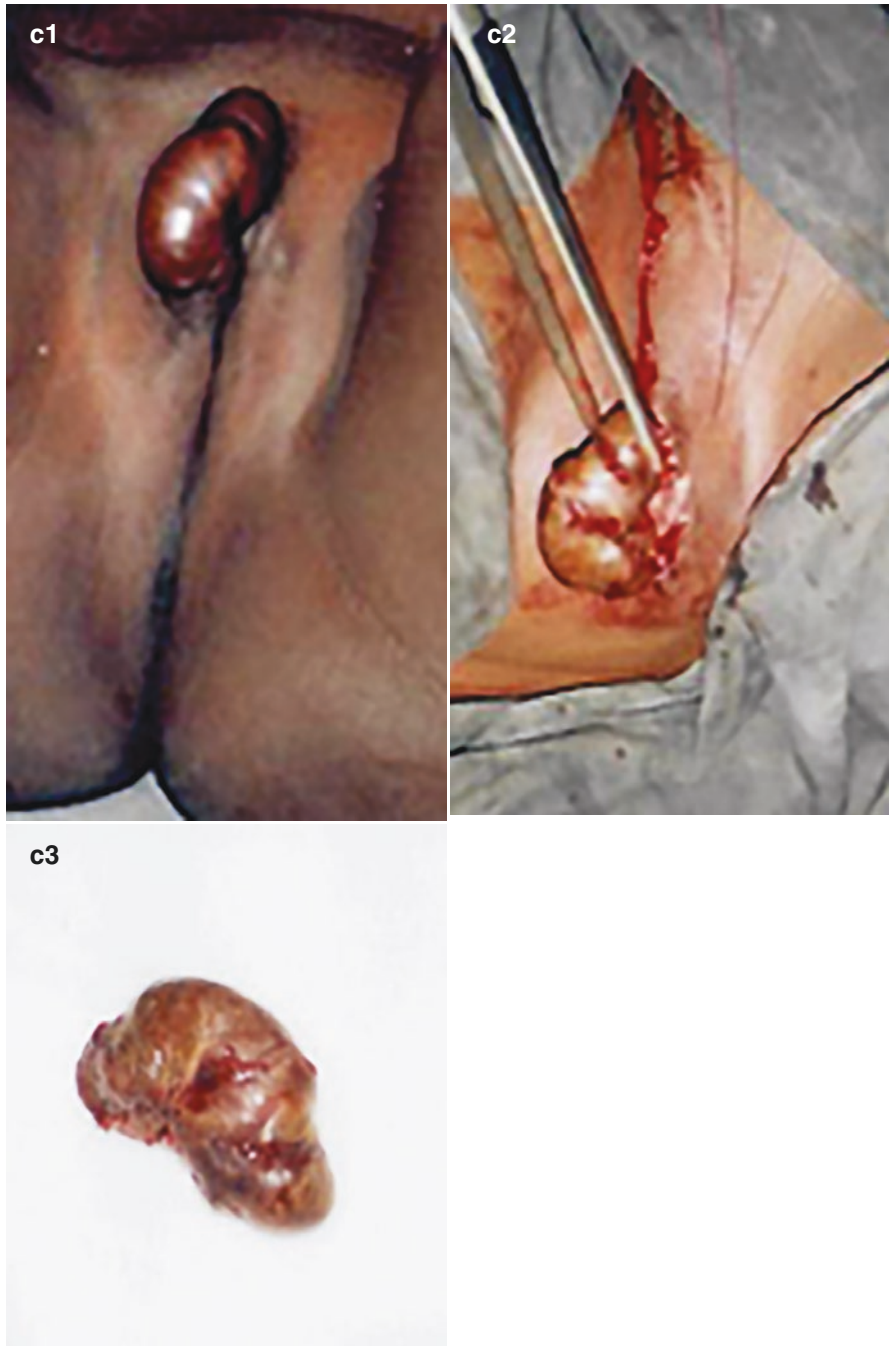

Fig. 6.8 (continued)





**Fig. 6.9** Cystectomy of a clitoral cyst followed by defibulation in a 16-year-old girl from Eritrea (a–e). She had undergone FGM/C type IIIa with excision of the clitoris as a newborn. She was asymptomatic and was followed-up for 2 years until she asked for a cyst removal at around 16, due to its size. (Courtesy of Jasmine Abdulcadir)

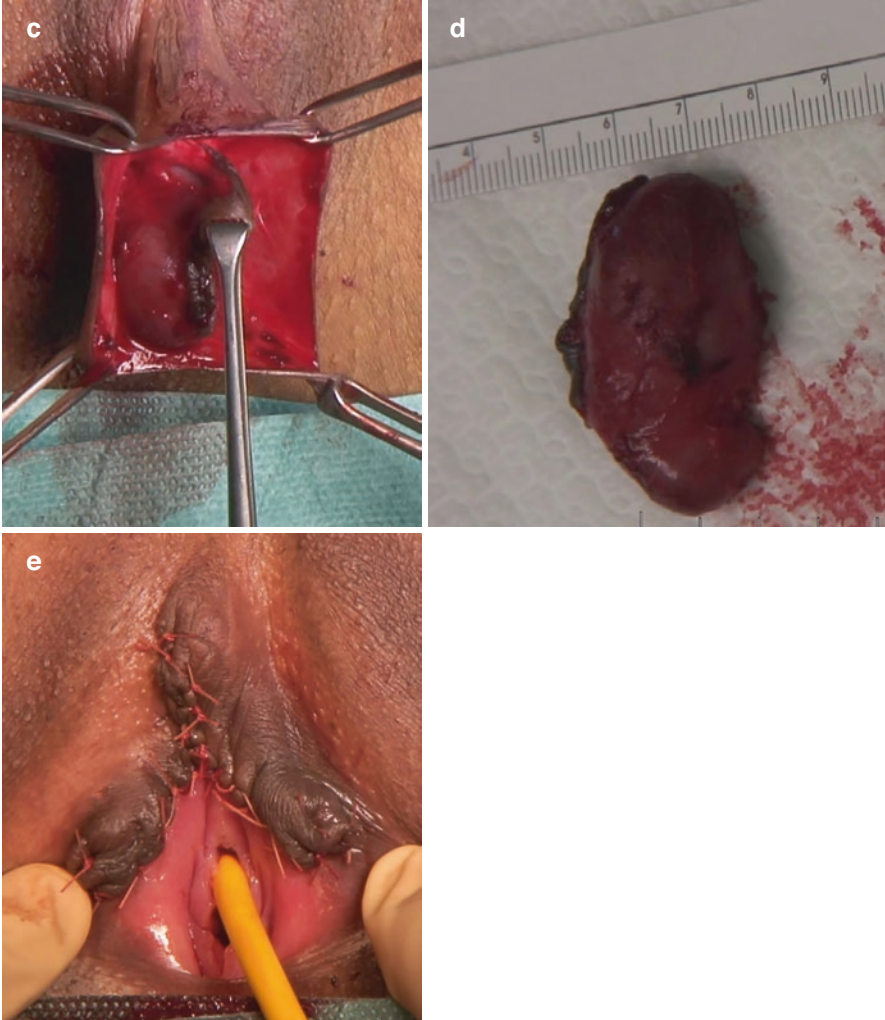
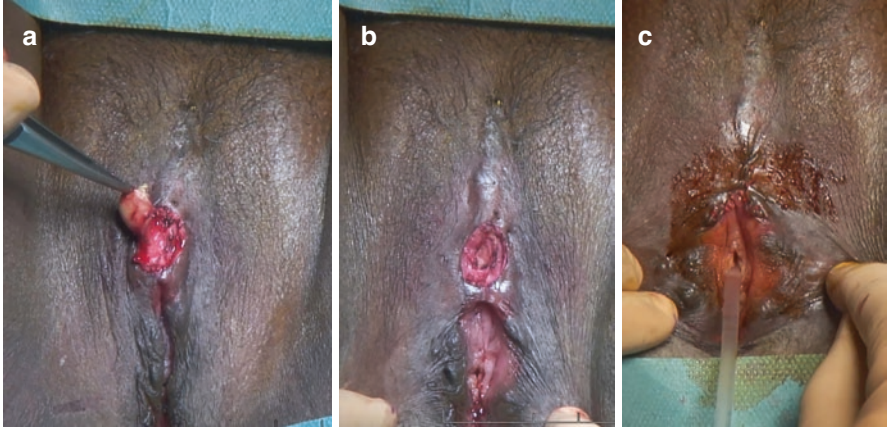


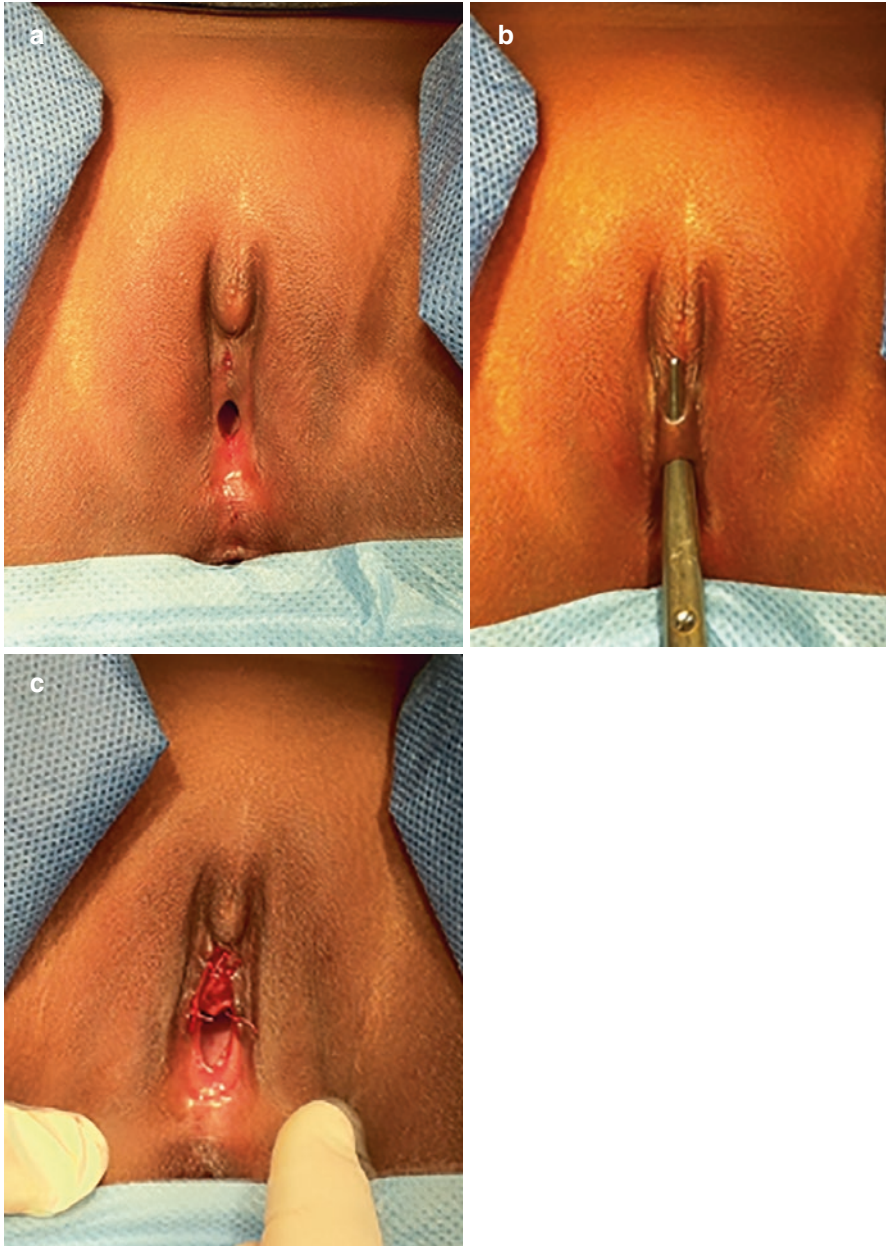
Fig. 6.9 (continued)



**Fig. 6.10** Cystectomy of a small clitoral painful cyst, FGM/C type IIIa, 18-years old, from Somalia (a–c). (Courtesy of Jasmine Abdulcadir)

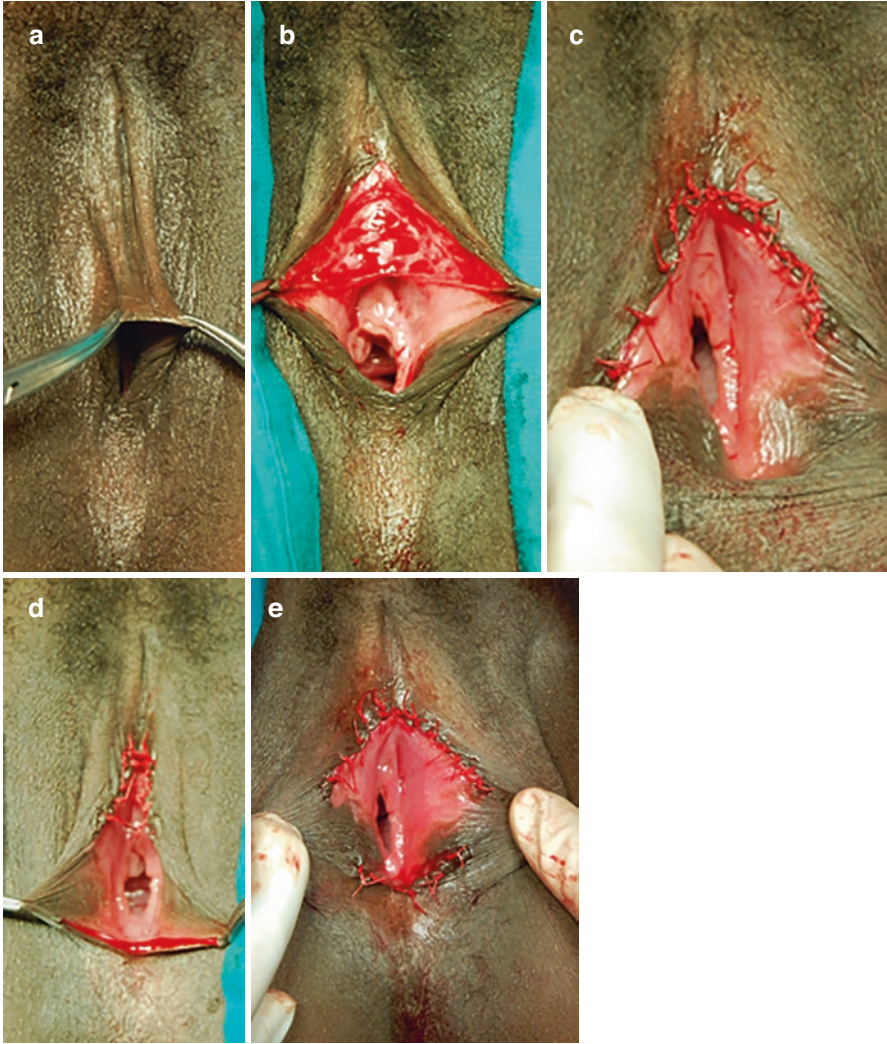
## 6.5 Defibulation

### 6.5.1 Prepubertal

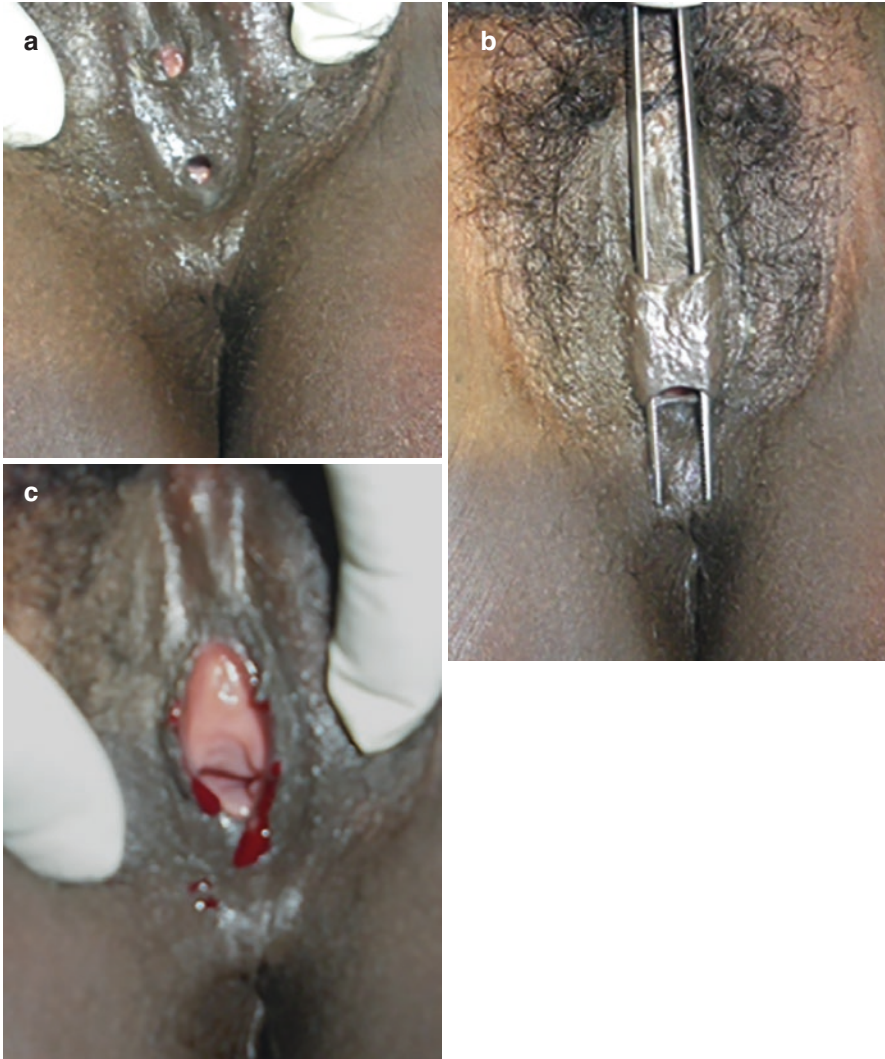

**Fig. 6.11** Defibulation in an 11-year-old girl, from Somalia presenting with FGM/C type IIIa with excision of the clitoris (a–c). (Courtesy of Martin Caillet)

**6.5.2 Postpubertal**

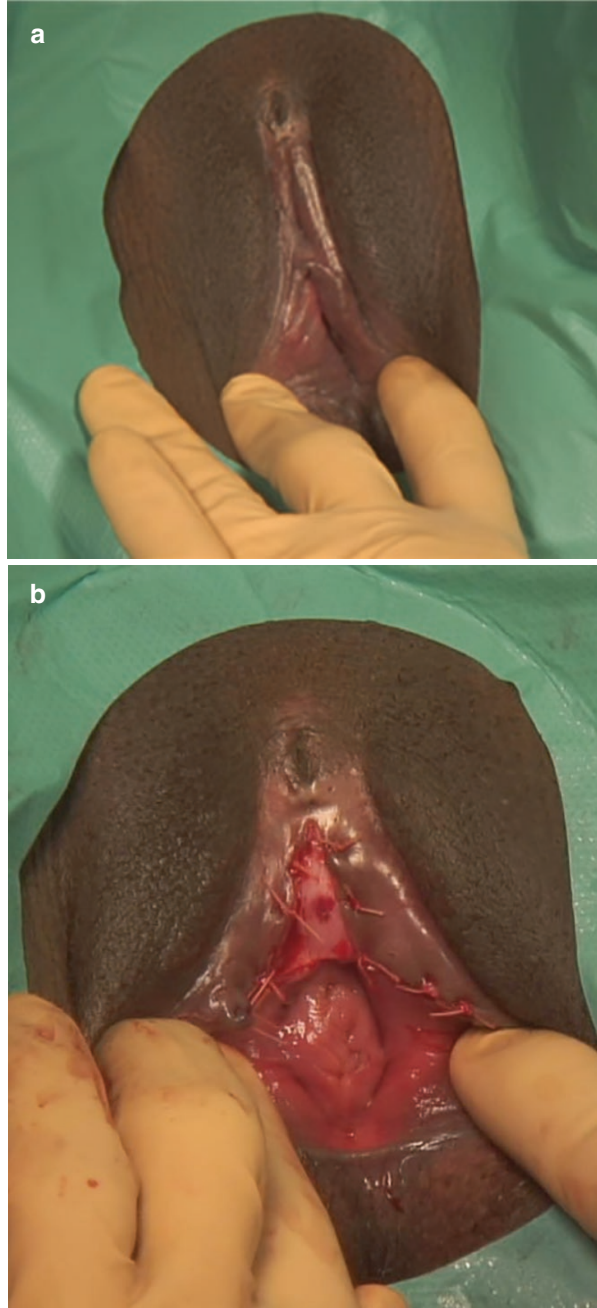


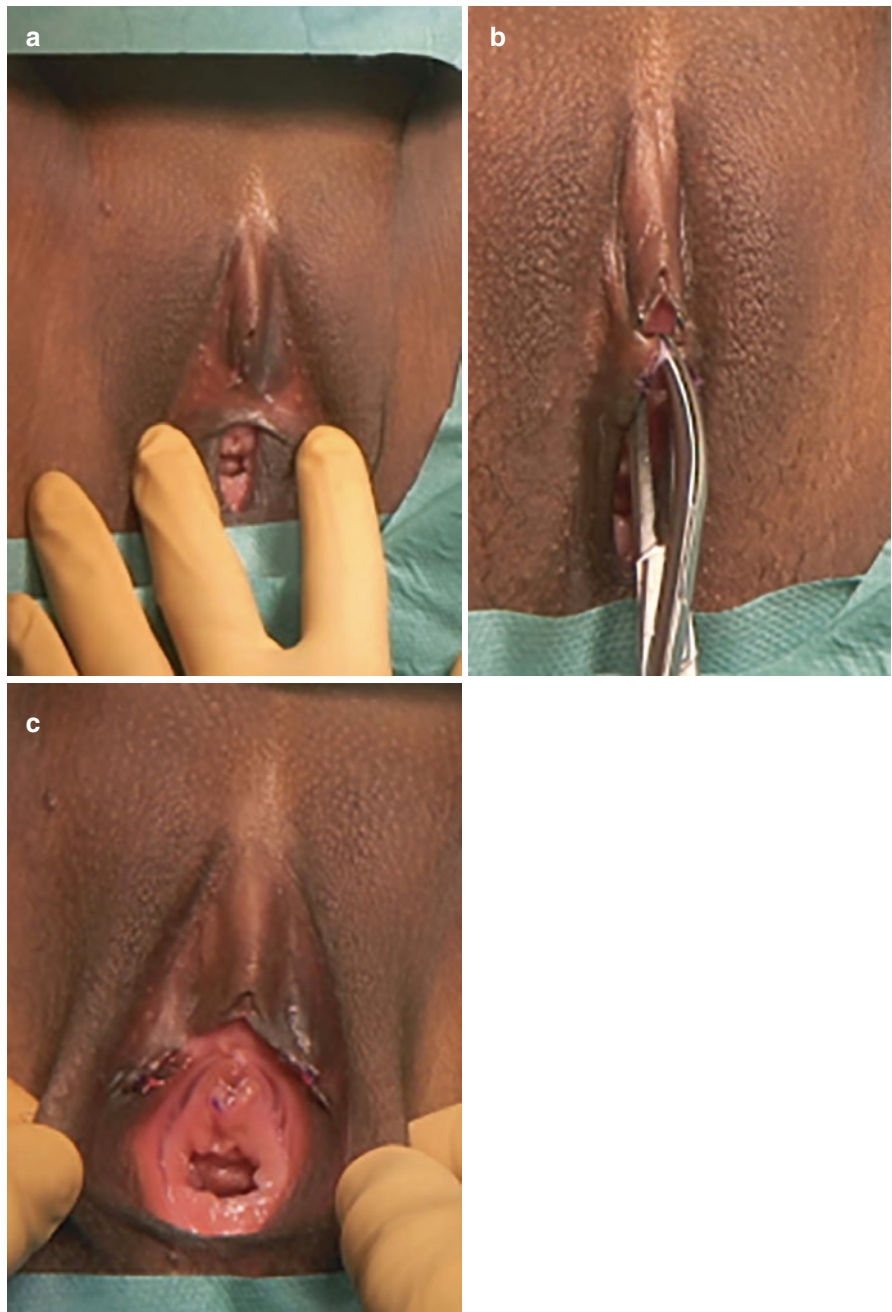**Fig. 6.12** Anterior and posterior defibulation, 12-years old, from Ethiopia with FGM/C type IIIa with excision of the clitoris (a–e). (Courtesy of Amelia Valladolid)



**Fig. 6.13** Defibulation in an adult woman, from Mali, with FGM/C type IIIa (a–c). (Courtesy of Moustapha Touré)

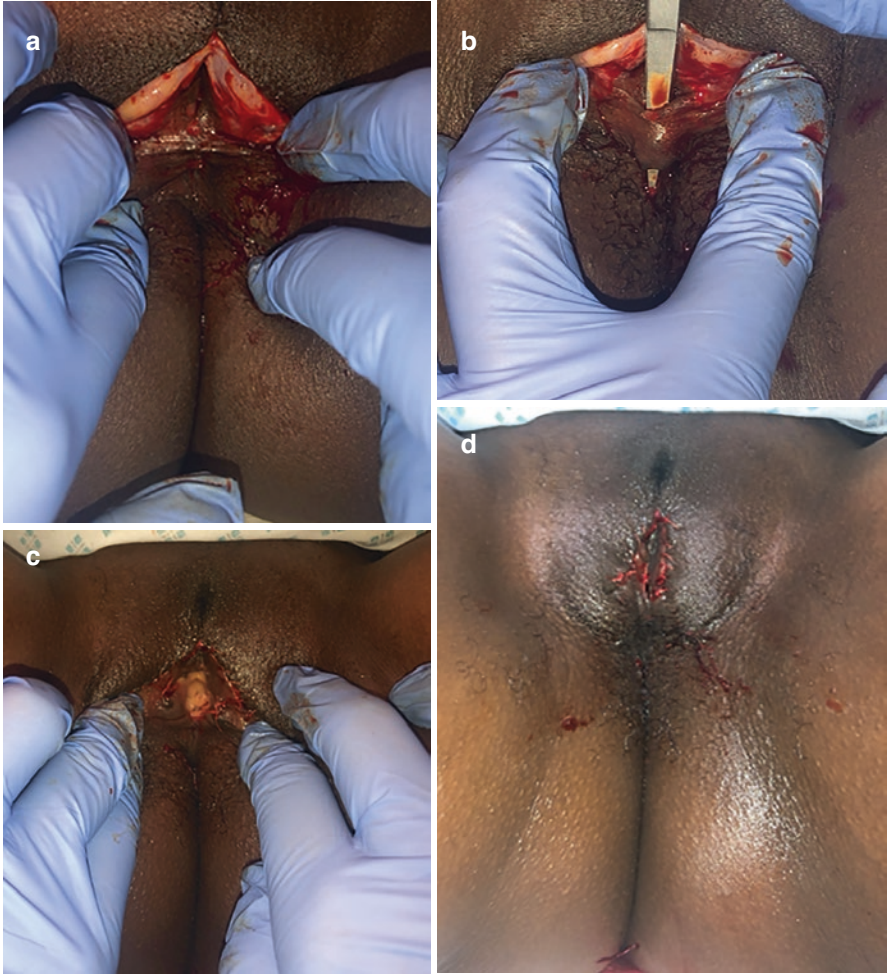**Fig. 6.14** Defibulation in an 18-year-old woman, from Eritrea at 24 weeks of pregnancy (**a** and **b**). (Courtesy of Jasmine Abdulcadir)



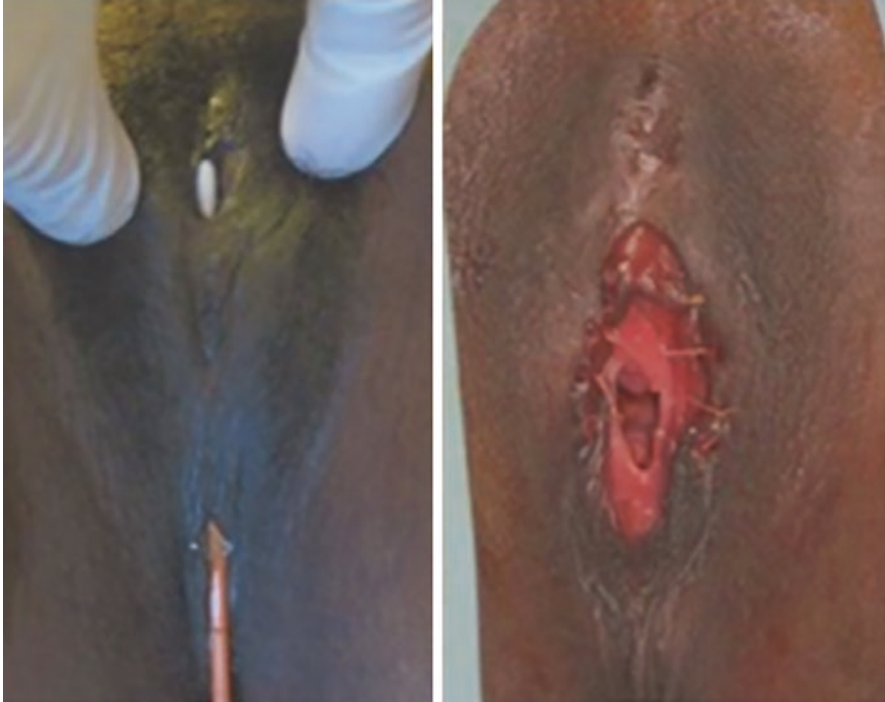

**Fig. 6.15** Defibulation in a 16-year-old girl from Eritrea with FGM/C type IIIa without cutting of the clitoris (a–c). She had been cut before her first birthday and before migration. (Courtesy of Jasmine Abdulcadir)

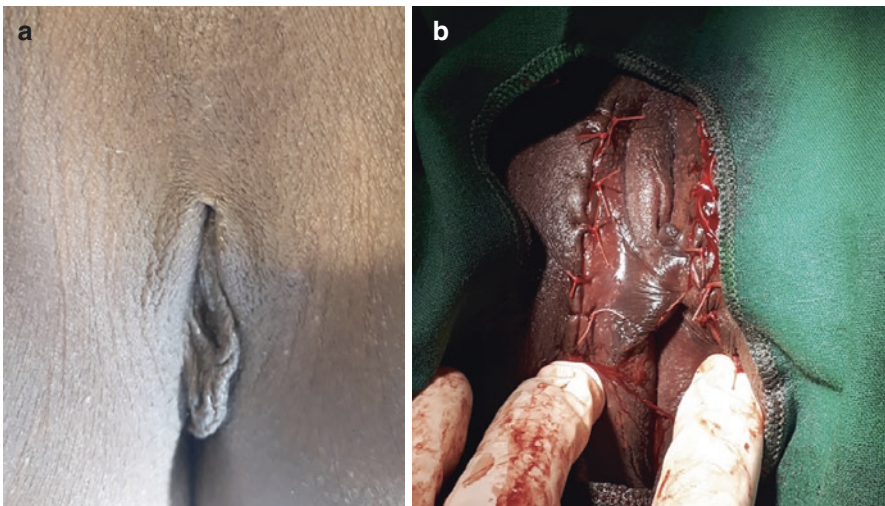




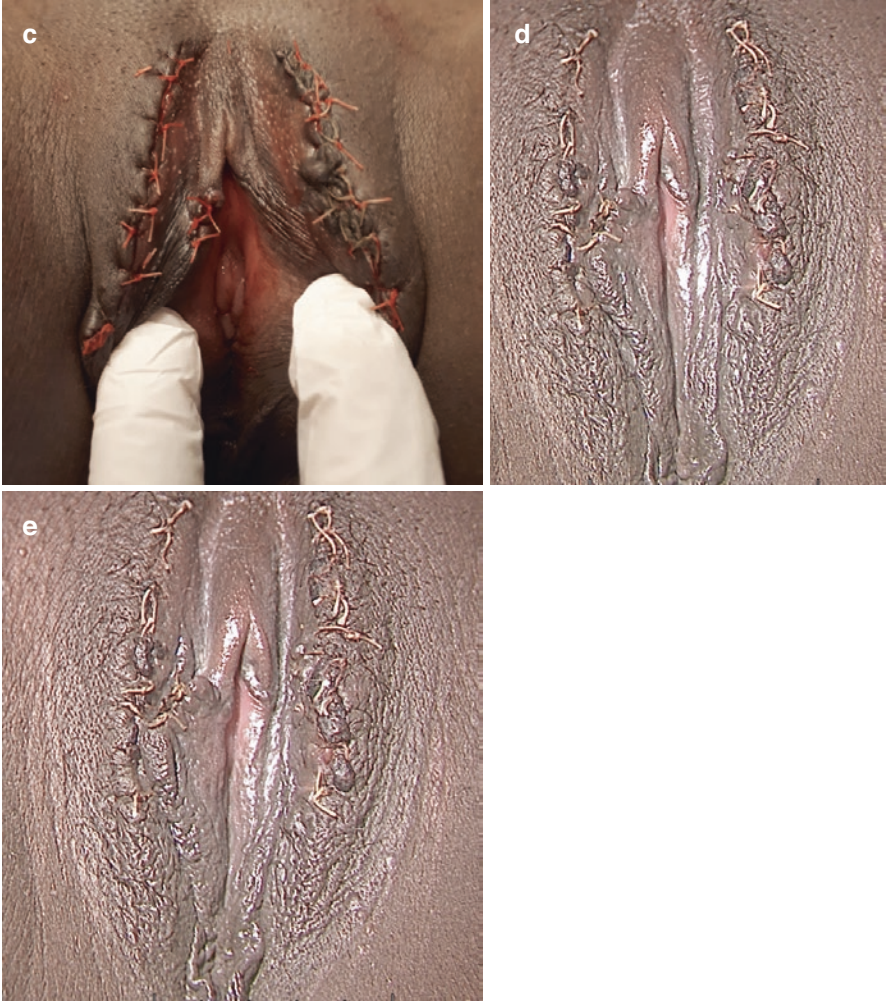**Fig. 6.16** Defibulation in a 23-year-old woman, from Eritrea, with FGM/C type IIIa-b (apposition of both inner and outer labia without cutting of the clitoris) (a-d). (Courtesy of Juliet Albert)



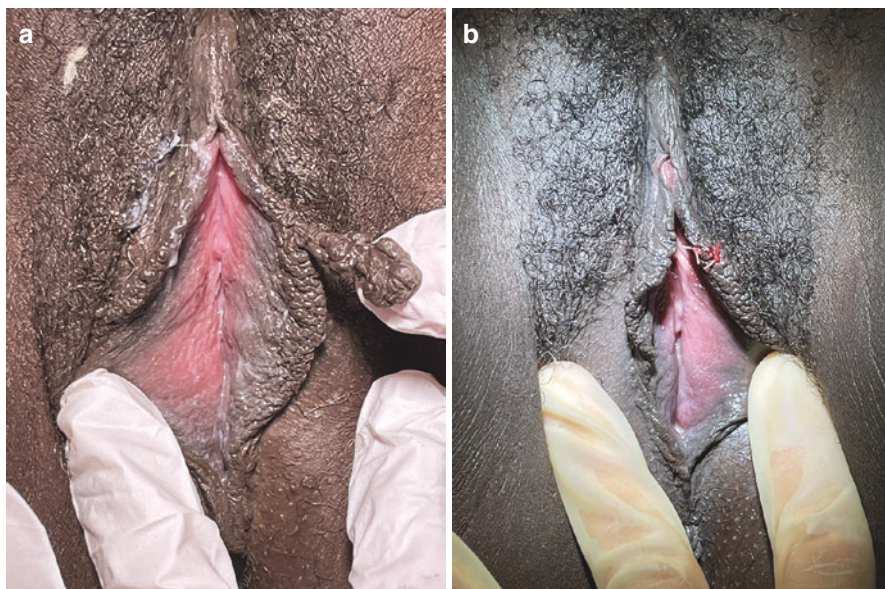
**Fig. 6.17** FGM/C type IIIa with cutting and apposition of the inner labia, and cutting of the clitoral hood in a 28-year-old woman, from Somalia. She had undergone FGM/C before puberty. After defibulation, the intact glans of the clitoris is exposed. (Courtesy of Jasmine Abdulcadir [8])



**Fig. 6.18** FGM/C type IIIa-b with apposition of the inner and outer labia in a 23-year-old woman, from Eritrea (a). Defibulation (b–e). After defibulation, the intact prepuce and glans of the clitoris are exposed. Defibulation of outer (b) and inner (c) labia. Day 7 of defibulation (d–e). (Courtesy of Jasmine Abdulcadir)



**Fig. 6.18** (continued)



**Fig. 6.19** FGM/C type IV in a 35-year-old woman from the African Great Lakes region (she has not consented to share the exact geographical origin in addition to this information) (a). She referred stretching of the inner labia between the age of 12 and 15. She consulted to ask for the excision of the excedentary part of the inner labium as symptomatic during sex and daily life (recurrent fissures, pain due to tissue pulling and superficial dyspareunia). (b) Excision of the excedentary tissue of the left inner labium under local anesthesia. Courtesy of Jasmine Abdulcadir

**Open Access** This chapter is licensed under the terms of the Creative Commons Attribution 4.0 International License (<http://creativecommons.org/licenses/by/4.0/>), which permits use, sharing, adaptation, distribution and reproduction in any medium or format, as long as you give appropriate credit to the original author(s) and the source, provide a link to the Creative Commons license and indicate if changes were made.

The images or other third party material in this chapter are included in the chapter's Creative Commons license, unless indicated otherwise in a credit line to the material. If material is not included in the chapter's Creative Commons license and your intended use is not permitted by statutory regulation or exceeds the permitted use, you will need to obtain permission directly from the copyright holder.



# References

1. World Health Organization, Department of Reproductive Health and Research, Eliminating female genital mutilation. An interagency statement - OHCHR, UNAIDS, UNDP, UNECA, UNESCO, UNFPA, UNHCR, UNICEF, UNIFEM, WHO. [http://apps.who.int/iris/bitstream/handle/10665/43839/9789241596442\\_eng.pdf;jsessionid=82C9AD3108B48D565334E067BDD701BA?sequence=1](http://apps.who.int/iris/bitstream/handle/10665/43839/9789241596442_eng.pdf;jsessionid=82C9AD3108B48D565334E067BDD701BA?sequence=1).
2. Female genital mutilation (FGM). UNICEF DATA. <https://data.unicef.org/topic/child-protection/female-genital-mutilation/>.
3. Prevalence of female genital mutilation in the world. GAMS Belgique, 2017. <http://www.strategiesconcertees-mgf.be/wp-content/uploads/GAMS-carte2017EN-1.pdf>.
4. WHO | Female genital mutilation (FGM). WHO. World Health Organization. <http://www.who.int/reproductivehealth/topics/fgm/prevalence/en/>.
5. Types of female genital mutilation. <https://www.who.int/teams/srh/types-of-female-genital-mutilation>.
6. Female Genital Mutilation/Cutting: a statistical overview and exploration of the dynamics of change. UNICEF DATA. 2013. <https://data.unicef.org/resources/fgm-statistical-overview-and-dynamics-of-change/>.
7. Abdulcadir J, Marras S, Catania L, Abdulcadir O, Petignat P. Defibulation: a visual reference and learning tool. *J Sex Med.* 2018;15(4):601–11.
8. Abdulcadir J, Catania L, Hindin MJ, Say L, Petignat P, Abdulcadir O. Female genital mutilation: a visual reference and learning tool for health care professionals. *Obstet Gynecol.* 2016;128(5):958–63.
9. Fulghesu AM, editor. Good practice in pediatric and adolescent gynecology. Cham: Springer International Publishing; 2018. <http://link.springer.com/10.1007/978-3-319-57162-1>.
10. Prise en charge des mutilations sexuelles féminines par les professionnels de santé de premier recours. Haute Autorité de Santé. [https://www.has-sante.fr/jcms/p\\_3150640/fr/prise-en-charge-des-mutilations-sexuelles-feminines-par-les-professionnels-de-sante-de-premier-recours](https://www.has-sante.fr/jcms/p_3150640/fr/prise-en-charge-des-mutilations-sexuelles-feminines-par-les-professionnels-de-sante-de-premier-recours).
11. Ali S, Patel R, Armitage AJ, Learner HI, Creighton SM, Hodes D. Female genital mutilation (FGM) in UK children: a review of a dedicated paediatric service for FGM. *Arch Dis Child.* 2020. <https://adc.bmj.com/content/early/2020/06/03/archdischild-2019-318336>.
12. Young J, Nour NM, Macauley RC, Narang SK, Johnson-Agbakwu C, Section on Global Health, et al. Diagnosis, management, and treatment of female genital mutilation or cutting in girls. *Pediatrics.* 2020;146(2):e20201012. <https://pediatrics.aappublications.org/content/146/2/e20201012>.
13. Touré M, Excision et santé de la femme. Bamako Mali : Editions Ganndal; 2003.
14. Kaplan A, Hechavarría S, Martín M, Bonhoure I. Health consequences of female genital mutilation/cutting in the Gambia, evidence into action. *Reprod Health.* 2011;8:26.

15. Johnsdotter S. Meaning well while doing harm: compulsory genital examinations in Swedish African girls. *Sexual and Reproductive Health Matters*. 2019;27:2:87–99. <https://doi.org/10.1080/26410397.2019.1586817>.
16. Berer M. Prosecution of female genital mutilation in the United Kingdom: injustice at the intersection of good public health intentions and the criminal law. *Med Law Int*. 2019;19(4):258–81.
17. World Health Organization. *Care of girls and women living with female genital mutilation: a clinical handbook*. Geneva: WHO; 2018.
18. Creighton SM, Dear J, de Campos C, Williams L, Hodes D. Multidisciplinary approach to the management of children with female genital mutilation (FGM) or suspected FGM: service description and case series. *BMJ Open*. 2016;6(2):e010311. <https://www.ncbi.nlm.nih.gov/pmc/articles/PMC4780059/>.
19. Hodes D, Creighton SM. Setting up a clinic to assess children and young people for female genital mutilation. *Archives of Disease in Childhood - Education and Practice*. 2017;102:14–18.
20. Creighton S. M, Hodes D, Female genital mutilation: what every paediatrician should know. *Arch Dis Child*. 2016;101(3):267–71. <https://doi.org/10-1136/archdischild-2014-307234>.
21. Young J, Knuti Rodrigues K, Imam B, Johnson-Agbakwu C. Female genital mutilation/cutting-pediatric physician knowledge, training, and general practice approach. 2020;22(4):668–74. *J Immigr Minor Health*. <https://doi.org/10.1007/s10903-019-00938-x>.
22. Akbiyik F, Kutlu AO. External genital proportions in prepubertal girls: a morphometric reference for female genitoplasty. *J Urol*. 2010;184(4):1476–81.
23. Brodie KE, Grantham EC, Huguélet PS, Caldwell BT, Westfall NJ, Wilcox DT. Study of clitoral hood anatomy in the pediatric population. *J Pediatr Urol*. 2016;12(3):177.e1–5.
24. Hodes D, O'Donnell NA, Pall K, Leoni M, Lok W, DeBelle G, et al. Epidemiological surveillance study of female genital mutilation in the UK. *Arch Dis Child*. 2020. <https://adc.bmj.com/content/early/2020/10/05/archdischild-2020-319569>.
25. Earp BD. Protecting children from medically unnecessary genital cutting without stigmatizing women's bodies: implications for sexual pleasure and pain. *Arch Sex Behav*. <https://doi.org/10.1007/s10508-020-01633-x>.
26. Sharif Mohamed F, Wild V, Earp BD, Johnson-Agbakwu C, Abdulcadir J. Clitoral reconstruction after female genital mutilation/cutting: a review of surgical techniques and ethical debate. *J Sex Med*. 2020;17(3):531–42.
27. Fontana S, Hürlimann R. Examen gynécologique de l'enfant: quand, comment, pourquoi? 2017;28:5.
28. Essén B. One genital, two judgments: why do “expert witnesses” draw different conclusions in suspected cases of illegal cutting of girls' genitals? In Johnsdotter S. (Ed.), *female genital cutting. The global north and south* pp. 259–287. 2021. <https://doi.org/10.24834/isbn.9789178771240>. Malmö University. <https://www.diva-portal.org/smash/get/diva2:1508633/FULLTEXT01.pdf>.
29. Larsson M, Cohen P, Hann G, Creighton SM, Hodes D. An exploration of attitudes towards female genital mutilation (FGM) in men and women accessing FGM clinical services in London: a pilot study. *J Obstet Gynaecol*. 2018;38(7):1005–9.
30. Zurynski Y, Phu A, Sureshkumar P, Cherian S, Deverell M, Elliott EJ, et al. Female genital mutilation in children presenting to Australian paediatricians. *Arch Dis Child*. 2017;102(6):509–15.
31. UNICEF. *Female genital mutilation/cutting: a statistical overview and exploration of the dynamics of change*; 2013.
32. Lurie JM, Weidman A, Huynh S, Delgado D, Easthausen I, Kaur G. Painful gynecologic and obstetric complications of female genital mutilation/cutting: a systematic review and meta-analysis. *PLoS Med*. 2020;17(3):e1003088.
33. Fox KA, Johnson-Agbakwu C. Crime victimization, health, and female genital mutilation or cutting among Somali women and adolescent girls in the United States, 2017. *Am J Public Health*. 2019;110(1):112–8.
34. Berg RC, Denison E, Fretheim A. *Psychological, social and sexual consequences of female genital mutilation/cutting (FGM/C): a systematic review of quantitative studies, NIPH systematic reviews*. Oslo, Norway: Knowledge Centre for the Health Services at The Norwegian Institute of Public Health (NIPH); 2010. <http://www.ncbi.nlm.nih.gov/books/NBK469815/>.

35. Mulongo P, et al. The psychological impact of Female Genital Mutilation/Cutting (FGM/C) on girls/women's mental health: a narrative literature review. *J Reprod Infant Psychol.* 2014;32(5). <https://www.tandfonline.com/doi/abs/10.1080/02646838.2014.949641>.
36. Behrendt A, Moritz S. Posttraumatic stress disorder and memory problems after female genital mutilation. *Am J Psychiatry.* 2005;162(5):1000–2.
37. Vloeberghs E, van der Kwaak A, Knipscheer J, van den Muijsenbergh M. Coping and chronic psychosocial consequences of female genital mutilation in The Netherlands. *Ethn Health.* 2012;17(6):677–95.
38. Earp BD, Why was the U.S Ban on female genital mutilation ruled unconstitutional, and what does this have to do with male circumcision?, 2020, Ethics, Medicine and Public Health. <https://doi.org/10.1016/j.jemep.2020.100533>.
39. Schweizerisches Bundesgericht, 6B\_77/2019, 11.02.2019. [https://www.bger.ch/ext/eurospider/live/de/php/aza/http/index.php?highlight\\_docid=aza%3A%2F%2F11-02-2019-6B\\_77-2019&lang=de&type=show\\_document&zoom=YES&](https://www.bger.ch/ext/eurospider/live/de/php/aza/http/index.php?highlight_docid=aza%3A%2F%2F11-02-2019-6B_77-2019&lang=de&type=show_document&zoom=YES&).
40. Robinson C. Condamnation pour mutilations génitales féminines commises à l'étranger. <https://www.skmr.ch/frz/domaines/genre/nouvelles/condamnation-emgf-etranger.html>.
41. Mishori R. Conducting an asylum evaluation focused on female genital mutilation/cutting status or risk. *Int J Gynecol Obstet.* <https://obgyn.onlinelibrary.wiley.com/doi/10.1002/ijgo.13428>.
42. Freedman J. Gender and asylum in international law — the Geneva Convention Revisited. In: Freedman J, editor. *Gendering the international asylum and refugee debate.* London: Palgrave Macmillan UK; 2015. p. 69–107. [https://doi.org/10.1057/9781137456236\\_4](https://doi.org/10.1057/9781137456236_4).
43. EFE. Madrid planteará un compromiso contra la ablación a padres de niñas en riesgo. *elperiodico.* 2017. <https://www.elperiodico.com/es/sociedad/20170623/madrid-planteara-compromiso-ablacion-padres-6125122>.
44. Kit de prévention des Mutilations Génitales Féminines | Stratégies concertées de lutte contre les mutilations génitales féminines. <http://www.strategiesconcertees-mgf.be/tool/kit-mgf/>.
45. Uso, aplicabilidad e impacto del Compromiso Preventivo, Fundaci n Wassu-UAB, 2019. [https://www.uab.cat/doc/guia\\_esp\\_compromiso-preventivo](https://www.uab.cat/doc/guia_esp_compromiso-preventivo).
46. Karlsen S, Carver N, Mogilnicka M, Pantazis C. “Putting salt on the wound”: a qualitative study of the impact of FGM-safeguarding in healthcare settings on people with a British Somali heritage living in Bristol, UK. *BMJ Open.* 2020;10(6):e035039.
47. Creighton SM, Samuel Z, Otoo-Oyortey N, Hodes D. Tackling female genital mutilation in the UK. *BMJ.* 2019;364:115.
48. SAMHA. SAMHSA's concept of trauma and guidance for a trauma-informed approach. Rockville, MD: Substance Abuse and Mental Health Administration; 2014. p. 27.
49. Ades V, Wu SX, Rabinowitz E, Chemouni Bach S, Goddard B, Pearson Ayala S, et al. An integrated, trauma-informed care model for female survivors of sexual violence: the Engage, Motivate, Protect, Organize, Self-Worth, Educate, Respect (EMPOWER) clinic. *Obstet Gynecol.* 2019;133(4):803–9.
50. Reeves E. A synthesis of the literature on trauma-informed care. *Issues Ment Health Nurs.* 2015;36(9):698–709.
51. Position Paper on Trauma Informed Care for Child Victims of Sexual Abuse, No more Stolen Childhoods, 2019. <https://nomorestolenchildhoods.com/wp-content/uploads/2018/03/Position-Paper.-Trauma-informed-Care-for-Victims-of-Child-Sexual-Abuse-Children-FINAL-8.2019.pdf>.
52. Principles of trauma-informed approaches to child sexual abuse. Australian Institute of Family Studies. 2016. <https://aifs.gov.au/publications/principles-trauma-informed-approaches-child-sexual-abuse>.
53. Trauma-Informed Advocacy and Services Recommended Reading, National Sexual Violence Resource Center and National Sexual Assault Coalition Resource Sharing Project, Resources by NSVRC. <https://www.nsvrc.org/sites/default/files/publications/2018-04/Trauma-Informed-Advocacy.pdf>.
54. Berkoff MC, Zolotor AJ, Makoroff KL, Thackeray JD, Shapiro RA, Runyan DK. Has this prepubertal girl been sexually abused? *JAMA.* 2008;300(23):2779–92.

55. Chalmers DJ, O'Donnell CI, Casperson KJ, Bergard SC, Hou AH, Nuss GR, et al. Normal anatomic relationships in prepubescent female external genitalia. *J Pediatr Urol.* 2014;10(6):1117–21.
56. Gaudens DA, Moh-Ello N, Fiogbe M, Bandre É, Ossoh BM, Yaokreh J-B, et al. La coalescence des nymphes au service de chirurgie pédiatrique du CHU de Yopougon: à propos de 108 cas. *Cah Études Rech Francoph Santé.* 2008;18(1):35–8.
57. Martínón-Torres F, Martínón-Sánchez JM, Martínón-Sánchez F. Clitoris and labia minora agenesis – an undescribed malformation. *Clin Genet.* 2000;58(4):336–8.
58. Graham EA. Ritual Female Genital Cutting [RFGC] PowerPoint slides. 2014. <https://ethnomed.org/resource/ritual-female-genital-cutting-rfgc-powerpoint-slides/>.