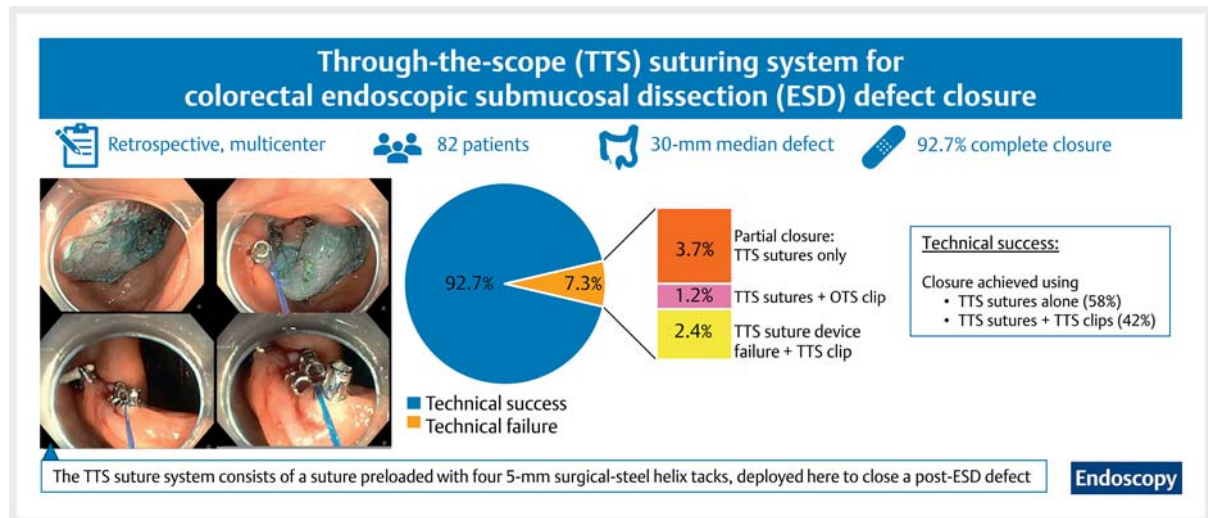


# A novel through-the-scope helix tack-and-suture device for mucosal defect closure following colorectal endoscopic submucosal dissection: a multicenter study ▶

## GRAPHICAL ABSTRACT



### Authors

Jad Farha<sup>1</sup>, Hemchand Rambaran<sup>2</sup>, Hiroyuki Aihara<sup>3</sup>, Linda Y. Zhang<sup>1</sup>, Amit Mehta<sup>1</sup>, Camille Hage<sup>1</sup>, Alexander Schlachterman<sup>4</sup>, Anand Kumar<sup>4</sup>, Brianna Shinn<sup>4</sup>, Andrew Canakis<sup>5</sup>, Raymond E. Kim<sup>5</sup>, Lionel S. D'Souza<sup>6</sup>, Jonathan M. Buscaglia<sup>6</sup>, Andrew C. Storm<sup>7</sup>, Jason Samarasena<sup>8</sup>, Kenneth Chang<sup>8</sup>, Shai Friedland<sup>9,10</sup>, Peter V. Draganov<sup>11</sup>, Bashar J. Qumseya<sup>11</sup>, Salmaan Jawaid<sup>12</sup>, Mohamed O. Othman<sup>12</sup>, Muhammad K. Hasan<sup>13</sup>, Dennis Yang<sup>13</sup>, Mouen A. Khashab<sup>1</sup>, Saowanee Ngamruengphong<sup>1</sup>, ESD-Closure working group

### ESD-Closure working group

Rickisha Berrien-Lopez<sup>1</sup>, Shruti Mony<sup>1</sup>, Zahraa Mohammed<sup>4</sup>, Juan Carlos Bucobo<sup>6</sup>, Tala Mahmoud<sup>7</sup>, Michael Oliver M. Mercado<sup>11</sup>, Mark Radetic<sup>11</sup>

### Institutions

- 1 Division of Gastroenterology and Hepatology, Johns Hopkins Medical Institutions, Baltimore, Maryland, USA
- 2 Division of Gastroenterology and Hepatology, Riverside Regional Medical Center, Newport News, Virginia, USA
- 3 Division of Gastroenterology and Hepatology, Brigham and Women's Hospital, Boston, Massachusetts, USA
- 4 Department of Gastroenterology and Hepatology, Thomas Jefferson University Hospital, Philadelphia, Pennsylvania, USA
- 5 Division of Gastroenterology and Hepatology, University of Maryland School of Medicine, Baltimore, Maryland, USA
- 6 Division of Gastroenterology and Hepatology, Stony Brook University Hospital, Stony Brook, New York, USA
- 7 Division of Gastroenterology and Hepatology, Mayo Clinic, Rochester, Minnesota, USA
- 8 H. H. Chao Comprehensive Digestive Disease Center, University of California, Department of Medicine, Irvine Medical Center, Orange, California, USA
- 9 Division of Gastroenterology and Hepatology, Stanford University, Redwood City, California, USA
- 10 Veterans Affairs Palo Alto Health System, Palo Alto, California, USA
- 11 Division of Gastroenterology, Hepatology, and Nutrition, University of Florida, Gainesville, Florida, USA
- 12 Division of Gastroenterology and Hepatology, Baylor College of Medicine, Houston, Texas, USA
- 13 Division of Gastroenterology and Hepatology, Advent Health, Orlando, Florida, USA

submitted 31.5.2022

accepted after revision 31.10.2022

published online 2.11.2022

### Bibliography

Endoscopy

DOI 10.1055/a-1970-5528

ISSN 0013-726X

© 2022. Thieme. All rights reserved.

Georg Thieme Verlag KG, Rüdigerstraße 14,  
70469 Stuttgart, Germany



Supplementary material

Supplementary material is available under

<https://doi.org/10.1055/a-1970-5528>

### Corresponding author

Saowanee Ngamruengphong, MD, Division of  
Gastroenterology & Hepatology, Johns Hopkins Medicine,  
4940 Eastern Avenue, A Building 5th Floor, Baltimore, MD  
21224, USA  
[sngamru1@jhmi.edu](mailto:sngamru1@jhmi.edu)

### ABSTRACT

**Background** Complete closure of large mucosal defects following colorectal endoscopic submucosal dissection (ESD) with through-the-scope (TTS) clips is oftentimes not possible. We aimed to report our early experience of using a novel TTS suturing system for the closure of large mucosal defects after colorectal ESD.

**Methods** We performed a retrospective multicenter cohort study of consecutive patients who underwent attempted prophylactic defect closure using the TTS suturing system after colorectal ESD. The primary outcome was technical success in achieving complete defect closure, defined as a <5 mm residual mucosal defect in the closure line using TTS suturing, with or without adjuvant TTS clips.

**Results** 82 patients with a median defect size of 30 (interquartile range 25–40) mm were included. Technical success was achieved in 92.7% (n=76): TTS suturing only in 44 patients (53.7%) and a combination of TTS suturing to approximate the widest segment followed by complete closure with TTS clips in 32 (39.0%). Incomplete/partial closure, failure of appropriate TTS suture deployment, and the need for over-the-scope salvage closure methods were observed in 7.3% (n=6). One intraprocedural bleed, one delayed bleed, and three intraprocedural perforations were observed. There were no adverse events related to placement of the TTS suture.

**Conclusion** The TTS suture system is an effective and safe tool for the closure of large mucosal defects after colorectal ESD and is an alternative when complete closure with TTS clips alone is not possible.

## Introduction

Endoscopic submucosal dissection (ESD) has demonstrated effectiveness for the removal of large laterally spreading lesions or complex colorectal polyps with suspected superficial submucosal invasion. The most common adverse events (AEs) related to ESD include perforation and bleeding. Prophylactic closure of large mucosal defects following colorectal ESD has been reported to reduce the incidence of post-procedure AEs [1–5]; however, complete closure of large or irregular mucosal defects with conventional through-the-scope (TTS) clips is technically challenging and oftentimes not possible. Other devices such as over-the-scope (OTS) clips and OTS sutures can also be used for the closure of gastrointestinal mucosal defects; however, they require endoscope removal for device loading, followed by reinsertion to the defect site, which can be technically challenging and time-consuming, particularly for proximally located lesions [6].

Recently, a novel TTS suturing system (X-tack; Apollo Endosurgery, Austin, Texas, USA) has been reported to be effective for the closure of various gastrointestinal defects [7]. A preclinical study in porcine models demonstrated that TTS suturing enabled larger defects to be closed compared with TTS clips

[8]. This prompted us to explore the use of TTS sutures in colorectal ESD, where defects are often large and irregular. The aim of this study was to report our early experience of using TTS sutures for the closure of large mucosal defects after colorectal ESD.

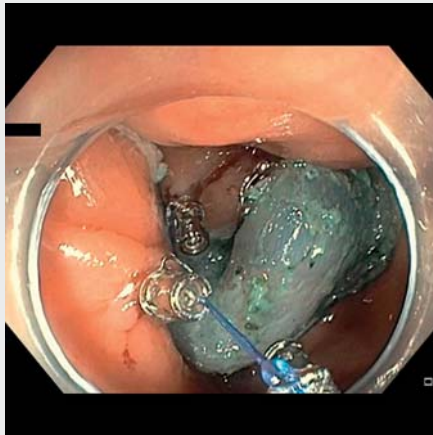
## Methods

### Study design

We performed a retrospective multicenter observational study of all consecutive patients who underwent prophylactic defect closure using TTS suturing as a primary closure device after colorectal ESD from January 2021 to May 2022 at 12 US centers. The inclusion and exclusion criteria are described in **Appendix 1s** (see online-only Supplementary material). Institutional Review Board (IRB) approval was obtained at each participating center.

### Procedure

The decision to perform TTS suture closure was at the discretion of the treating endoscopist. The TTS suture closure procedure is described in **Appendix 2s** and is shown in ►**Video 1**.



**Video 1** The through-the-scope (TTS) suture closure procedure is shown, with four helix tacks deployed (see time points 00:02.8; 00:13.23; 00:25.96; 00:37.66) before the cinch is placed so that it extends approximately 2–3 inches beyond the tacks and is parallel to the tissue (00:52.76), with the suture then tightened until the helix tacks and tissue have been approximated (01:1.33). Another TTS suture set is used to close the remaining defect (1:20.26), before TTS clips are finally deployed (02:37.33).

Online content viewable at:

<https://doi.org/10.1055/a-1970-5528>

Further images and descriptions of the TTS suture device, its use in vivo, and suture patterns are shown in ► **Fig. 1** and **Figs. 1s–4s**.

## Outcomes

The primary outcome was technical success in complete mucosal defect closure using TTS sutures, with or without additional TTS clips. Complete mucosal defect closure was defined as closure of the mucosal defect without substantial visible submucosal areas (<5 mm) in the closure line. Technical failure was defined as: the inability to place the TTS suture device as intended (including but not limited to suture breakage, failure of cinching, misdeployed or dislodged tacks); incomplete defect closure; or the need for a salvage closure method with an OTS suture device or OTS clips. Secondary outcomes were the procedure time, number of devices required, and intraprocedural or delayed AEs relating to ESD or defect closure. Statistical analyses are summarized in **Appendix 3s**.

## Results

### Baseline characteristics

In total, 82 patients (45.1% women; median age 65 [interquartile range (IQR) 55.75–72.0] years) with colorectal lesions underwent ESD followed by defect closure with TTS suturing. Baseline characteristics of the patients and their lesions are described in **Table 1s**. The most common site of application was the ascending colon and the hepatic flexure (n=28; 34.1%), followed by the rectum (n=19; 23.2%), the cecum (n=14;

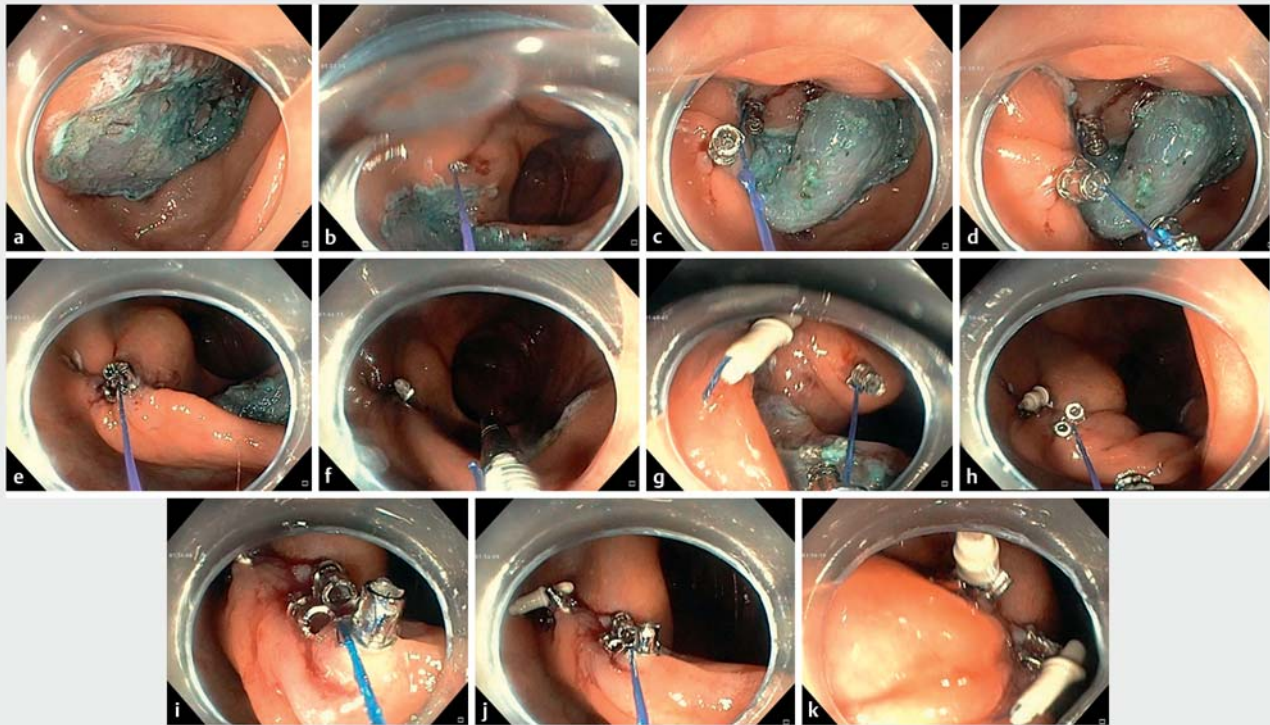
17.1%), the descending colon (n=13; 15.9%), and the transverse colon (n=8; 9.8%). The median (IQR) lesion size was 30 (25–40) mm. The lesions were predominantly adenomatous (n=51; 62.2%), while 30 contained either high grade dysplasia (n=15; 18.3%) or adenocarcinoma (n=15; 18.3%). En bloc resection was achieved in 76 patients (92.7%).

### Technical outcomes

The primary outcome of technical success was achieved in 76 patients (92.7%), with complete closure achieved with TTS sutures ± TTS clips. Technical success was achieved in 44 patients (53.7%) using TTS sutures only and 32 (39.0%) using TTS sutures + TTS clips. In the 32 patients with combined use of TTS sutures and TTS clips, TTS suturing was used to approximate the widest segment of the mucosal defect to facilitate subsequent closure of the remaining mucosal defect with TTS clips (► **Table 1**; ► **Fig. 2**). To better understand whether the need for additional TTS clips was related to location of the defect, we stratified technical success by location (**Table 2s**). There was no significant difference between the size of the defects closed using TTS suture monotherapy (32.9 [SD 14.3] mm) versus TTS sutures + TTS clips (34.4 [SD 13.0] mm;  $P=0.64$ ).

There were six cases of technical failure (7.3%) (► **Fig. 2**). TTS suture monotherapy resulted in only partial closure in two patients (2.4%). In one patient (1.2%), a small perforation occurred during ESD of a 25 mm lesion in the descending colon: the TTS suture closure alone resulted in tenting of the approximated tissue and was insufficient to achieve secure defect closure, and the treating endoscopist preferred to use a single OTS clip instead of multiple TTS clips to achieve successful complete and secure closure. There were three cases (3.7%) of TTS suture device failure. In the first, after placing all four tacks, the suture broke during cinching, after which the ESD site was successfully closed using seven TTS clips. In the second, two tacks dislodged from the mucosa after the initially successful placement of one TTS suture system, and the remainder of the defect was closed with five TTS clips. In the third case, during deployment of the third TTS suture set, the suture broke, and the site was subsequently closed with four TTS clips.

The median (IQR) total procedure time including ESD and defect closure was 108 (80.8–138.0) minutes. The median (IQR) closure time reported was 10 (6.3–17.3) minutes (n=40) (**Table 1s**). Among 47 patients with data available, the most common closure pattern (**Fig. 4s**) was the continuous pattern in 34 patients (72.3%), followed by the figure-of-eight suture in 10 (21.3%), and the interrupted suture in three (6.4%). A median of one TTS suture system (IQR 1–1) was deployed to achieve defect closure. However, 10 patients (12.2%) required more than one TTS suture system to achieve complete closure. Specifically, seven patients required two TTS suture systems and three patients required three TTS suture systems. In cases where adjunctive TTS clips were used, the median number was two (IQR 2–4) clips (► **Table 1**). The majority of patients (n=69, 84.1%) were discharged on the day of the procedure, whereas 9.8% (n=8), 3.7% (n=3) and 2.4% (n=2) stayed for 1, 2, and ≥3 days, respectively.



► **Fig. 1** Endoscopic views of the prophylactic placement of two through-the-scope (TTS) suture sets showing: **a** a mucosal defect; **b** deployment of the first helix tack; **c** deployment of the second helix tack; **d** tightening of the suture after deployment of the second helix tack; **e** tightening of the suture after deployment of the third helix tack; **f** the appearance after deployment of the full TTS suture set, with the cinch seen in white and the residual defect visible on the right; **g** deployment of the first helix tack for the second TTS suture set; **h** deployment of the second helix tack of the second TTS suture set; **i** close-up view of three newly deployed helix tacks; **j** the three newly deployed helix tacks, with the cinch from the first set visible on the right; **k** appearance after the deployment of two full sets, with the cinches visible in white.

## Adverse events

There were four intraprocedural AEs (4.9%). There were three perforations that occurred during ESD, all of which were successfully managed intraprocedurally with no clinical consequences, so were graded mild. One was the previously described case that was treated successfully with TTS suturing and an OTS clip. The other two were successfully closed with TTS suturing and TTS clips.

There was one moderate intraprocedural bleed that was treated during the procedure by a combination of epinephrine injection, coagulation forceps, irrigation with gel-foam slurry, and defect closure with one TTS suture system. Rebleeding was noted within hours of procedure completion however and a decision was made to pursue an angiogram followed by embolization of an actively bleeding branch of the ileocolic artery at the ESD site. The latter was also classified as a delayed bleed because it required radiologic intervention after discharge from the endoscopy unit, giving a delayed bleeding rate of 1.2%.

There were no delayed perforation events over a median (IQR) follow-up period of 98 (30.75–134.0) days ( $n=30$ ). There were no intraprocedural AEs relating to TTS suture placement.

## Discussion

This is the largest multicenter study evaluating the effectiveness and safety of TTS suturing specifically for colorectal post-ESD defect closure. In this study, we demonstrated that complete mucosal defect closure was achieved in over 90% of lesions, despite a large median lesion size of  $\geq 30$  mm. In more than half of cases, TTS suture monotherapy was selected as a method for complete closure. In an additional 39% of cases, TTS suturing was able to reduce or narrow the defect, so that TTS clips could be used to close the residual mucosal defect. Our technical success rate of 92.7% for TTS suturing  $\pm$  TTS clips highlights the efficacy of TTS prophylactic mucosal defect closure. In a retrospective study investigating TTS suturing, Mahmoud et al. reported a similar rate of technical success (89.2%), with supplemental closure methods including TTS and OTS clips for a range of indications not limited to resection defects [7].

The rate of delayed bleeding after colorectal ESD is reported to be 1.5%–11.9% [9]. In this study, the rate of delayed bleeding was 1.2%. This is notable given recent studies that have suggested the role of prophylactic defect closure in possibly reducing the rate of delayed post-ESD bleeding [5,9]. Several studies have identified risk factors for delayed bleeding after colorectal ESD. Notably, lesion size  $>40$  mm, rectal lesions, and

**► Table 1** Closure-related outcomes for the 82 patients who underwent through-the-scope (TTS) suture closure of colorectal post-endoscopic sub-mucosal dissection defects.

Outcome	Value	95%CI
Number of TTS suture systems deployed, n (%)		
▪ 1	72 (87.8)	78.7–94.0
▪ 2	7 (8.5)	3.5–16.8
▪ 3	3 (3.7)	0.8–10.3
Number of adjuvant TTS clips used, median, (IQR)	2 (2–4)	2.0–3.0
Technical success, n (%) <sup>1</sup>	76 (92.7)	84.8–97.3
Type of technical success, n (%)		
▪ TTS suturing alone	44 (53.7)	42.3–64.7
▪ TTS suturing with adjunctive TTS clipping	32 (39)	28.4–50.4
Technical failure, n (%)	6 (7.3)	2.7–15.2
Type of technical failure, n (%)		
▪ Partial closure by TTS suturing alone	2 (2.4)	0.3–8.5
▪ TTS suture device failure + TTS clip rescue	3 (3.7)	0.8–10.3
▪ TTS suturing + OTS clip rescue	1 (1.2)	0.0–6.6
Number of TTS suture systems deployed, median (IQR)	1 (1–1)	
TTS suture pattern, n (%) <sup>2</sup>		
▪ Continuous	34 (72.3)	57.4–84.4
▪ Figure of 8	10 (21.3)	10.7–35.7
▪ Interrupted	3 (6.4)	1.3–17.5
Adverse events, n (%)		
▪ Intraprocedural bleeding	1 (1.2)	0.0–6.6
▪ Intraprocedural perforation	3 (3.7)	0.8–10.3
▪ Delayed bleeding	1 (1.2)	0.0–6.6
▪ Delayed perforation	0 (0)	0.0–4.4
▪ Related to TTS suture placement	0 (0)	0.0–4.4
Hospital stay, median (IQR), days	0 (0–0)	0.0–0.0
Clinic follow-up, median (IQR), days <sup>3</sup>	98 (30.75–134.0)	59.0–126.0

TTS, through-the-scope; IQR, interquartile range

<sup>1</sup> Complete mucosal closure by TTS suturing +/- adjuvant TTS clips

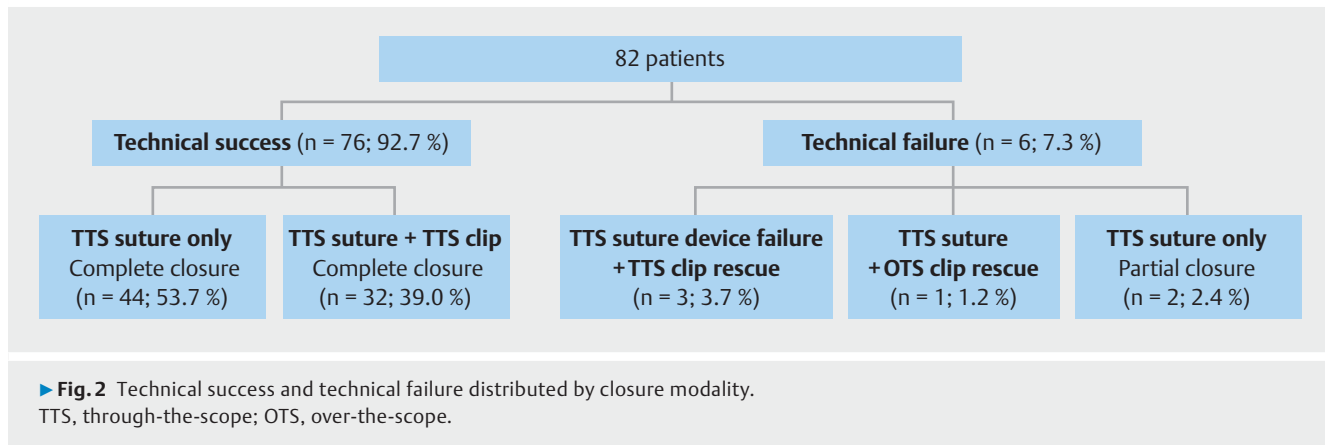
<sup>2</sup> n = 47; data not available in the procedural reports of some patients.

<sup>3</sup> n = 30; numbers limited as some patients were not yet due for a follow-up visit.

antithrombotic therapy (anticoagulant or antiplatelet) have been associated with an increased risk of delayed bleeding [10–12]. In our cohort 53 defects (64.6%) had one or more risk factors, so were considered high risk. Despite this, only one delayed bleed was encountered. This study might be underpowered to determine the risk of bleeding after colorectal ESD with defect closure, but it highlights the need for randomized controlled trials to better understand the role of prophylactic closure.

TTS clipping is the most commonly used closure modality following endoscopic resection. The complete closure rate de-

scribed in the literature for TTS clip monotherapy for large ( $\geq 20$  mm) nonpedunculated colorectal polyps has varied widely from 57% to 68% [13–15]. The largest multicenter study of TTS clip monotherapy post-endoscopic mucosal resection of colorectal lesions of  $\geq 20$  mm reported a complete closure rate of 68.4% [13, 16]. Importantly, this meant that clip closure was not feasible for almost one in three mucosal resection defects. This likely relates to the maximum opening width span of TTS clips, which limits the size of defect they can be used to close [17, 18]. Although larger clips are increasingly available, closure remains a challenge for larger or irregular defects. This has prompted



the use of the TTS suture helix tacks, which are tethered with a single polypropylene suture allowing the endoscopist to span and close an irregularly shaped or large defect.

Our study was not a comparative study, so no specific comments can be made regarding the efficacy of TTS suture closure compared with the efficacy of TTS clip closure. However, we believe that these two TTS modalities can be used synergistically to optimize closure of complex resection defects. A notable point is that we included the use of adjunctive TTS clips within technical success for our study. The data on the reasons for requiring supplemental closure were not available, but the decision to use TTS clips was at the discretion of the endoscopist. A median number of two adjuvant TTS clips were used to achieve complete closure, which suggests that there was often a small residual defect following TTS suture placement. Such a small residual defect in the closure line may not have warranted the use of a new TTS suture system containing four helix tacks, but instead favored the use of extra TTS clips. Moreover, cost-effectiveness considerations could have played a role in situations where a residual defect could be sealed using a single TTS clip, which costs just a fraction of the price of a whole TTS suture set. The latter suggests that TTS sutures and TTS clips are not mutually exclusive closure methods, but are viewed as somewhat interdependent, especially with regards to defects that are difficult to close with monotherapy.

Of note, we had two cases of technical failure due to partial closure with TTS suture monotherapy. It is possible that these could have been completely closed with additional TTS sutures and/or TTS clips; however, given the retrospective nature of our study, it is unclear whether these defects were not possible to close or were deemed unnecessary to close by the treating endoscopist.

In this study, most ESD patients were discharged on the same day, as reflected by the median length of stay of 0 days, thereby sparing patients the cost of hospital admission [2]. The minimal delayed AE rate (1.2%) after prophylactic closure using TTS sutures ± TTS clips is noteworthy and suggests secure defect closure. Similarly, TTS clip monotherapy for closure of a large mucosal defect after colorectal ESD has demonstrated a delayed bleeding rate of 0–6% and a delayed perforation rate of 0% [4,5]. Large prospective studies are needed to confirm

the efficacy of TTS sutures in the prevention of post-ESD bleeding.

This study has several limitations. Inherent to a retrospective review, there are selection biases as multiple decisions, including the choice of closure modality, are at the discretion of the treating endoscopist. Additionally, a second-look endoscopy to confirm whether the sutures remained intact was not performed. Given this was a retrospective review, we may have missed certain AEs if patients presented to centers outside of our system.

In conclusion, this is the first study to demonstrate the feasibility and safety of the endoscopic tack-and-suture device, either alone or in conjunction with TTS clips, for the closure of colorectal defects secondary to ESD. Our results encourage the performance of prospective comparative and cost-effectiveness studies to determine the optimal scenario for the device. Such studies would ultimately guide physicians in implementing the closure method with the most favorable outcome and safety profile.

### Competing interests

H. Aihara is a consultant for Olympus America, Boston Scientific, Fujifilm Medical Systems, Medtronic, and 3D Matrix. P.V. Draganov is a consultant for Olympus, Fujifilm, Boston Scientific, and Cook Medical. L.S. D'Souza is a consultant/speaker for Apollo Endosurgery. S. Friedland is a consultant for Capsovision and Intuitive. M.K. Hasan is a consultant for Olympus and Boston Scientific. S. Jawaid is a consultant for Lumendi and ConMed. M.A. Khashab is a consultant for Boston Scientific, Olympus America, Medtronic, Apollo Endosurgery, Pentax, and GI Supply; he receives royalties from UpToDate and Elsevier. R. Kim is a consultant to Medtronic Inc. and Cook Medical. A. Kumar is a consultant for Olympus. S. Ngamruengphong is a consultant for Boston Scientific, Olympus, and Neptune Medical. M. Othman is a consultant for Olympus, Boston Scientific Corporation, Abbvie, ConMed, Creo Medical, Lumendi, and Apollo; he has received research grants from Lucid Diagnostics, AbbVie, and ConMed. A. Schlachterman is a consultant for FujiFilm, ConMed, Olympus, and Lumendi. A.C. Storm receives research grant support from Apollo Endosurgery, Boston Scientific, Endogenex, Endo-TAGSS, and Enterasense; he is a consultant for Apollo Endosurgery, Boston Scientific, ERBE Elecmomedizin, GI Dynamics, Intuitive Surgical, and Olympus. D. Yang is a consultant for Olympus, Fujifilm, Apollo Endosurgery, and Medtronic. Jonathan M. Buscaglia, Andrew Canakis, Kenneth Chang, Jad Farha, Camille Hage,

Amit Mehta, Bashar J. Qumseya, Hemchand Rambaran, Jason Samarasena, Brianna Shinn, and Linda Zhang declare that they have no conflict of interest.

## References

- [1] Ogiyama H, Tsutsui S, Murayama Y et al. Prophylactic clip closure may reduce the risk of delayed bleeding after colorectal endoscopic submucosal dissection. *Endosc Int Open* 2018; 6: E582–E588
- [2] Kantsevov SV, Bitner M, Mitrov AA et al. Endoscopic suturing closure of large mucosal defects after endoscopic submucosal dissection is technically feasible, fast, and eliminates the need for hospitalization (with videos). *Gastrointest Endosc* 2014; 79: 503–507
- [3] Zhang Q-S, Han B, Xu J-H et al. Clip closure of defect after endoscopic resection in patients with larger colorectal tumors decreased the adverse events. *Gastrointest Endosc* 2015; 82: 904–909
- [4] Fujihara S, Mori H, Kobara H et al. The efficacy and safety of prophylactic closure for a large mucosal defect after colorectal endoscopic submucosal dissection. *Oncol Rep* 2013; 30: 85–90
- [5] Omori J, Goto O, Habu T et al. Prophylactic clip closure for mucosal defects is associated with reduced adverse events after colorectal endoscopic submucosal dissection: a propensity-score matching analysis. *BMC Gastroenterol* 2022; 22: 139
- [6] Yoshikane H, Hidano H, Sakakibara A et al. Feasibility study on endoscopic suture with the combination of a distal attachment and a rotatable clip for complications of endoscopic resection in the large intestine. *Endoscopy* 2000; 32: 477–480
- [7] Mahmoud T, Wong Kee Song LM, Stavropoulos SN et al. Initial multicenter experience using a novel endoscopic tack and suture system for challenging GI defect closure and stent fixation (with video). *Gastrointest Endosc* 2022; 95: 373–382
- [8] Hernandez A, Marya NB, Sawas T et al. Gastrointestinal defect closure using a novel through-the-scope helix tack and suture device compared to endoscopic clips in a survival porcine model (with video). *Endosc Int Open* 2021; 9: E572–E577
- [9] Liu M, Zhang Y, Wang Y et al. Effect of prophylactic closure on adverse events after colorectal endoscopic submucosal dissection: A meta-analysis. *J Gastroenterol Hepatol* 2020; 35: 1869–1877
- [10] Ogasawara N, Yoshimine T, Noda H et al. Clinical risk factors for delayed bleeding after endoscopic submucosal dissection for colorectal tumors in Japanese patients. *Eur J Gastroenterol Hepatol* 2016; 28: 1407–1414
- [11] Okamoto K, Watanabe T, Komeda Y et al. Risk factors for postoperative bleeding in endoscopic submucosal dissection of colorectal tumors. *Oncology* 2017; 93: (Suppl. 01): 35–42
- [12] Chiba H, Ohata K, Tachikawa J et al. Delayed bleeding after colorectal endoscopic submucosal dissection: when is emergency colonoscopy needed? *Dig Dis Sci* 2019; 64: 880–887
- [13] Pohl H, Grimm IS, Moyer MT et al. Clip closure prevents bleeding after endoscopic resection of large colon polyps in a randomized trial. *Gastroenterology* 2019; 157: 977–984.e3
- [14] Albéniz E, Fraile M, Ibáñez B et al. A scoring system to determine risk of delayed bleeding after endoscopic mucosal resection of large colorectal lesions. *Clin Gastroenterol Hepatol* 2016; 14: 1140–1147
- [15] Albéniz E, Álvarez MA, Espinós JC et al. Clip closure after resection of large colorectal lesions with substantial risk of bleeding. *Gastroenterology* 2019; 157: 1213–1221.e4
- [16] Ortiz O, Rex DK, Grimm IS et al. Factors associated with complete clip closure after endoscopic mucosal resection of large colorectal polyps. *Endoscopy* 2021; 53: 1150–1159
- [17] Wong Kee Song LM, Baron TH. Endoscopic management of acute lower gastrointestinal bleeding. *Am J Gastroenterol* 2008; 103: 1881–1887
- [18] Kay MRW. Colonoscopy, polypectomy, and related techniques. Wyllie R, Hyams JS, Kay M. *Pediatric Gastrointestinal and Liver Disease*. Philadelphia, PA: Elsevier; 2011: 662