

UC Irvine

UC Irvine Previously Published Works

Title

Noninvasive thermal evaluation for shunt failure in the emergency room.

Permalink

<https://escholarship.org/uc/item/30k130xx>

Authors

Xu, Jordan

Poole, Cassie

Sahyouni, Ronald

et al.

Publication Date

2019

DOI

10.25259/SNI_324_2019

Peer reviewed



Original Article

Noninvasive thermal evaluation for shunt failure in the emergency room

Jordan Xu¹, Cassie Poole¹, Ronald Sahyouni², Jefferson Chen¹

¹Department of Neurosurgery, University of California, Irvine Medical Center, Orange, California, ²Department of Biomedical Engineering, University of California, Irvine School of Medicine, Irvine.

E-mail: Jordan Xu - jcxu@hs.uci.edu; Cassie Poole - cserio@uci.edu; Ronald Sahyouni - rsahyoun@uci.edu; *Jefferson Chen - jeffewc1@hs.uci.edu



***Corresponding author:**

Jefferson Chen,
Department of Neurosurgery,
University of California, Irvine
Medical Center, Orange,
California.

jeffewc1@hs.uci.edu

Received : 16 November 19

Accepted : 03 December 19

Published : 27 December 19

DOI

10.25259/SNI_324_2019

Quick Response Code:



ABSTRACT

Background: Ventriculoperitoneal shunts (VPSs) have been the mainstay of treating hydrocephalus since the 1950s. However, shunts have a reported complication rate reaching nearly 50%. Devices have been developed that utilize noninvasive thermal transcutaneous diffusion technology. These shunt evaluation devices measure temperature gradients to detect shunt cerebrospinal fluid flow. We assessed the utility using a thermal diffusion technique to work up shunt failure in the emergency room (ER).

Methods: This was a retrospective case series at a single medical center ER. We included consecutive patients with possible VPS malfunction who were evaluated with a thermal sensor. The time period of data collection included September 2015–April 2018.

Results: Eight patients were reviewed, including four males and four females. The average age of reviewed patients was 35.1 (+/- ; 16.5). In our case series, three patients had adequate shunt flow as assessed by the shunt evaluation device, and the decision was made to discharge the patient and follow-up in clinic. In two patients, the flow was diminished, but due to other reassuring signs, the patients were still discharged with follow-up. Two patients were noted to have poor flow and were admitted for shunt revision.

Conclusion: It is important to determine whether a malfunction is present and whether an intervention is necessary for patients who present to the emergency department with possible symptoms of shunt failure. A thermal sensor is a fast and noninvasive tool in the evaluation of shunt flow and helps determine whether it is safe to send a patient home or intervene appropriately.

Keywords: Hydrocephalus, Shunt failure, Thermal sensor, Thermosensitive, Ventriculoperitoneal shunt

INTRODUCTION

Ventriculoperitoneal shunts (VPSs) have been the mainstay of treating hydrocephalus since the 1950s and have become one of the most frequently performed neurosurgical procedures.^[1,2,19,24] However, shunt failure is not uncommon with reported complications rates reaching nearly 50%, and the majority occur within the 1st year of VPS placement.^[25,30] An estimated 30,000 shunts are placed each year in the United States, suggesting that the number of shunt failures presenting to the emergency room (ER) every year is in the tens of thousands.^[2,19] Common causes of shunt failure include infection, catheter obstruction, abdominal pseudocysts, and bowel perforation.^[19,23]

This is an open-access article distributed under the terms of the Creative Commons Attribution-Non Commercial-Share Alike 4.0 License, which allows others to remix, tweak, and build upon the work non-commercially, as long as the author is credited and the new creations are licensed under the identical terms.

©2019 Published by Scientific Scholar on behalf of Surgical Neurology International

The diagnosis of shunt malfunction can be difficult even for experienced clinicians. Classical symptoms of shunt malfunction are nonspecific and include headache, lethargy, nausea, and vomiting.^[27] When patients present to the ER with symptoms of shunt failure, workup of shunt failure typically begins with brain imaging (computed tomography [CT] scans and shunt X-rays). Unfortunately, shunt failures do not necessarily lead to imaging changes, and hydrocephalus itself does not always indicate shunt failure.^[10,17,29] Novel techniques utilizing magnetic resonance imaging can be useful in detecting cerebrospinal fluid (CSF) flow, although this has not been widely validated.^[12,16] Imaging can be followed by more invasive procedures, which include shunt tap, lumbar puncture (LP), and radionuclide scans. However, these procedures are uncomfortable to the patient, carry risk of complications, and can be time consuming.

Cutaneous thermal diffusion techniques are promising noninvasive and quick techniques to assess CSF flow in a shunt. The ShuntCheck (Neuro Diagnostic Devices, Inc., Trevose, Pennsylvania) device uses temperature gradients to detect and quantify shunt CSF flow. The previous studies have shown that the device reliably determines CSF flow, confirmed by flow detection in the OR, with good sensitivity and specificity.^[14] We sought to evaluate and review the utility of using this thermal sensor to aid in the diagnosis of patients that presented to the ER with symptoms of shunt failure. Patients that presented with classical symptoms and/or clear imaging or testing indicative of shunt failure did not need to undergo a thermal sensor examination. The thermal sensor assessments were reserved for patients who had equivocal presentations of shunt failure. We retrospectively analyzed a series of consecutive patients who underwent workup with a thermal sensor in the ER and review whether the results affected clinical decisions.

METHODS

This was a retrospective review at a single medical center ER with the Institutional Review Board approval. Written informed consent was waived for this study given a retrospective analysis of de-identified data. We included consecutive patients with the question of VPS malfunction who were evaluated with the thermal sensor device. The time period of data collection included September 2015–April 2018.

ShuntCheck procedure

Patients are positioned either flat, at 45°, or 90°. The ShuntCheck program provides step-by-step guidance and instruction on the use of their system. The shunt tubing was palpated as it crosses the clavicle, and a thermal sensor device is placed directly over the shunt where the catheter crosses the clavicle in line with the direction of tubing. An

ice pack was placed to cool the skin and underlying catheter “upstream” of the thermal detector per protocol. If CSF is flowing through the shunt, the cooled fluid will preferentially cool the region of skin above the shunt tubing and this differential will propagate “downstream” and be detected by the thermal detector. The program detects CSF flow measuring the difference in cooling of the skin above the shunt tubing relative to the flanking skin. If the device detects a characteristic downstream transcutaneous temperature dip, the computer reports: “Flow confirmed.” A quantitative value based on the temperature curve is also reported as the natural flow amplitude (NFA). If no temperature dip is detected, the unit reports: “Flow not confirmed.” A real-time temperature graph is produced [Figure 1].^[21]

RESULTS

Eight patients were reviewed, including four males and four females. The average age of reviewed patients was 35.1 (± 16.5) years old. The leading presenting symptom was headache, occurring in six of the eight patients. Other symptoms included lethargy, nausea, vomiting, and change in mental status. VPS devices included Medtronic Strata, Medtronic Delta, and Sophysa Polaris. Table 1 summarizes thermal sensor findings and ER outcomes for each patient. The average NFA in assessments resulting in no flow was 0.10, while the average NFA for positive detected flow was 0.46. The ShuntCheck program produces a graph correlating with the change in temperature detected by the sensor.

Five (62.5%) of the patients were discharged home after thermal sensor showed good flow (patients 1, 4, 5, 6, and 7). Three (37.5%) patients required intervention. One patient shunt valve setting was adjusted (patient 2) based on imaging findings showing increased ventricle caliber. Two other patients were admitted for shunt revisions based on a diagnosis of shunt failure (patients 3 and 8). In both of these patients, the thermal sensor revealed inadequate shunt flow.

Example 1 (patient 3)

A 26-year-old female with a history of idiopathic intracranial hypertension and VPS (Medtronic Delta) presented with headaches and blurry vision. Her shunt was placed 1 month before presentation at an outside hospital. CT head imaging revealed slit ventricles. LP revealed an opening pressure of 33 cm H₂O. Ophthalmologic examination showed evidence of bilateral papilledema. Thermal sensor at 90° showed slow flow (NFA: 0.17). Given high suspicion of shunt failure, the patient was admitted for shunt revision. At the time of surgery, the proximal catheter was noted to have obstruction of flow and appeared adherent to the choroid. The proximal catheter was replaced along with a new Medtronic Strata valve. Follow-up appointment revealed the resolution of papilledema although headache persisted.

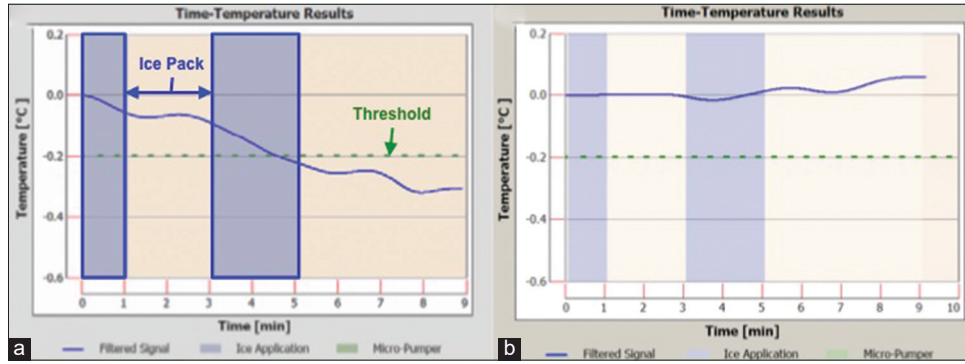


Figure 1: (a) Sample ShuntCheck result demonstrating a temperature gradient indicative of shunt flow; (b) sample ShuntCheck result with no temperature change suggestive of no flow; blue shaded bars represent periods of ice application; green dotted line represents threshold of temperature drop to determine adequate flow.

Table 1: Overview of patients included in this review.

Patient	Age	Gender	Shunt	Reason for VPS	Presentation	NFA	Flow?	Outcome
1	28	F	Strata II	Pseudotumor cerebrii	Headache	0°: 0.10 45°: 0.60	No Yes	Discharged from ED
2	58	F	SPV-70	Trauma → hydrocephalus	Lethargy, CTH with increase in ventriculomegaly	45°: 0.45	Yes	Shunt adjusted from 200 to 70; admitted for encephalopathy workup; repeat CTH with improvement in ventricle caliber
3	26	F	Delta	Pseudotumor cerebrii	Headaches, blurry vision	90°: 0.17	No	Admitted for shunt revision
4	17	M	Strata 1.5	Trauma → hydrocephalus	Lethargy	45°: 0.34	Yes	Discharged from ED
5	61	F	Strata 1.5	Unclear	Headache, leg pain	45°: 0.66	Yes	Discharged from ED
6	28	M	Sophysa	Congenital hydrocephalus	Headache, nausea, vomiting	45°: 0.26	Yes	Discharged from ED
7	22	M	Strata 1.0	Congenital hydrocephalus	Headache	45°: 0.02	No	Discharged after headaches improved
8	41	M	Sophysa	Coccimeningitis	Headaches, CTH with trapped left frontal horn	45°: 0.10 90°: 0.12	No No	LP opening pressure 33 cm H2O. Admitted for shunt revision

Example 2 (patient 6)

A 28-year-old male from Germany with a history of epilepsy and hydrocephalus since infancy secondary to traumatic brain injury, with the first VPS at 5 years of age and extensive subsequent revisions presented with headache, nausea, and vomiting. The patient had lived in Europe until 3 weeks before presentation. The most recent revision was 1 month before presentation. CT imaging showed normal ventricle caliber and shunt series did not show any discontinuity or kinking. Thermal sensor revealed good flow at 45° (NFA: 0.26). It was concluded that the shunt was functioning. Nausea and vomiting had resolved without intervention. Headaches persisted although the patient was agreeable to outpatient neurology follow-up for further headache management. The patient was discharged with instruction to follow up with both neurology and his neurosurgeon for further management of shunt.

For the patients that were discharged home, we reviewed at least 3 months of follow-up data after initial presentation. The previously discussed patient 6 had no follow-up data as the patient returned to Germany to see his original neurosurgeon. Of the remaining four patients, none required intervention in the subsequent 3 months. Patient 1 presented

to the clinic 1 month later and continued to have headaches suggestive of overdrainage, so the Medtronic Strata shunt was dialed from setting 1.0 to 1.5. However, on follow-up 2 months later, this was more uncomfortable to the patient and the shunt setting was returned to 1.0. Patient 4 was seen in the clinic 2 months after the initial visit and had the Strata valve dialed down from 2.0 to 1.5. The patient had reported some improvement at another visit 2 months later. Patient 5 was seen in the clinic 4 months after presentation and noted to be doing well. Patient 7 was seen 2 and 6 months after presentation and noted to be doing well at each visit.

DISCUSSION

We demonstrate that thermal sensor is a clinically useful tool in the initial management and assessment of patients presenting with possible VPS failure. It can be used as a screening tool to either rule out obstruction or prompt further advanced testing. Clinical symptoms suggestive of VPS failure include headache, vomiting, decreased mental status, and fever. The majority of the patients included in this review had reported headaches, and the remaining two presented with a decreased level of consciousness. These symptoms are often vague and have a wide differential in etiology. Conversely, some patients with shunt failure present with none of these

symptoms. There are potentially severe consequences of missing shunt failure, and it is important for the ER provider and/or neurosurgeon to make a careful and timely evaluation.

The routine workup for shunt failure often involves neuroimaging. CT and shunt series X-ray are the most common type of imaging obtained in the initial work-up. Imaging findings alone, however, are not indicative of shunt failure.^[17] In some indications for VPS, such as normal pressure hydrocephalus, postoperative placement will not always change ventricular volume.^[18] Due to this variability in findings, the diagnosis of shunt failure depends on a comprehensive assessment of the patient's complaints, examination findings, imaging, and objective measurements of shunt function.

Tapping the shunt reservoir is one objective measurement that can provide opening pressures and direct CSF analysis.^[26] However, it is an invasive procedure and has theoretical risks of causing bleeding, infection, or CSF leakage from the puncture site.^[6,11,13,22] In many practices, a diagnostic shunt tap is used sparingly to minimize these risks. Alternatively, an LP can also be used to access CSF and obtain pressure measurements. Pressure readings are more accurate and useful when there are signs of communicating hydrocephalus, as proximal obstruction can lead to artificially low estimates of intracranial pressure.^[20] Neither of these techniques, however, are able to assess the degree of flow in the shunt catheter in its natural state.

The thermal sensor tool is useful in distinguishing whether there is flow within the shunt system and aid in the diagnosis of shunt failure. The method of assessing flow through temperature fluctuations has been around for several decades.^[3,5,7,28] Studies suggested that the method could distinguish between proximal and distal blockage and would work in both VPS and lumboperitoneal shunts.^[4,5,9] However, the technology had not been further studied until more recently with the development of a packaged, portable, and easy to use the system named the ShuntCheck.^[21] Madsen *et al.* showed that the ShuntCheck device had good sensitivity and specificity in detecting CSF flow in pediatric patients.^[14] In a more recent study, Hameed *et al.* found that the ShuntCheck results were associated with shunt revisions in pediatric patients and could serve as a diagnostic aid.^[8] A separate group found inconsistent results with the ShuntCheck and reported several technical problems, including use on obese patients and excessive movement.^[15] Few groups have used the ShuntCheck device in the adult population, which may be more tolerable to undergo a thermal sensor examination.

All of the patients reviewed in our study portray scenarios, in which the patient is rapidly evaluated and a point-of-care method and proper disposition can be decided in a shorter amount of time. Figure 2 provides a sample flowchart for integrating the thermal sensor into the workup of shunt failure. When a patient first presents with symptoms of

shunt failure, the first step should still be neuroimaging. The thermal sensor becomes most useful in cases where the information provided by other diagnostic tools is equivocal.

A positive flow detected by a thermal sensor not only can reassure the clinician but also the patient. However, a shunt flow evaluation by itself is not a predictor of the clinical diagnosis of shunt failure, as the previous studies have shown.^[8,14] Patient 7 had a negative result but clinically improved, and no intervention was needed. The clinician can use thermal sensor results in combination with the clinical examination and other diagnostic testings to make the best decision for the patient. This series of patients illustrates a variety of clinical pictures, in which a thermal sensor device provided some insight into shunt function, which provided additional clinical data to help with decision-making.

Limitations

This is a small retrospective review with only eight patients, limiting the generalizability of our findings. The low number of patients is due to the fact that only a subset of patients presenting with symptoms of shunt malfunction will undergo a thermal sensor evaluation. The thermal sensor results are most useful in patients that have inconclusive presentation and imaging findings, and a further diagnostic test can be helpful. The decision tree in Figure 2 is not exhaustive, and the thermal sensor itself can also produce equivocal results when very limited flow is detected. While not represented in our set of patients, there are instances where an equivocal thermal sensor result warrants further investigation through a shunt tap or nuclear medicine study. In the patients included in our study, there is a significant heterogeneity, each patient with different indications for

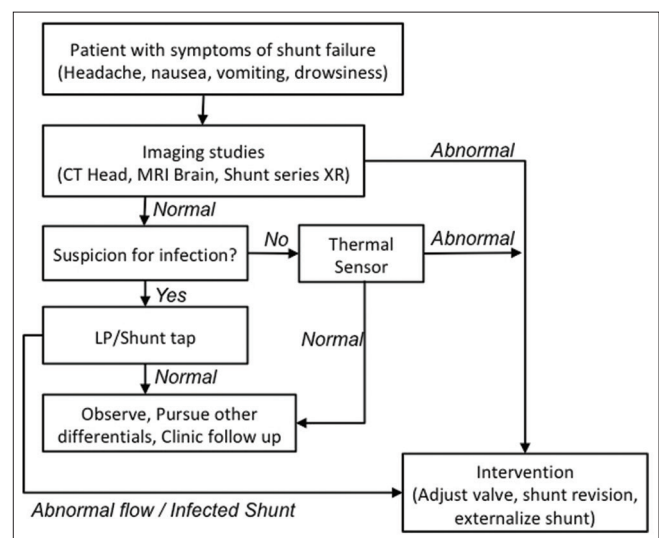


Figure 2: A sample workflow integrating a thermal sensor into evaluation of shunt failure.

VPS and varying presenting symptoms. Further, the use of the device will help elucidate more of its' utility and challenges. It is important to note that the ShuntCheck device has not been widely validated, and its results on their own are not diagnostic of shunt failure.^[15] The results of such studies should be used in adjunct to routine workup of shunt failure.

CONCLUSION

It is important to determine whether shunt dysfunction is present and whether an intervention is necessary for patients who present to the ER with possible symptoms of shunt failure. A thermal sensor device is a useful, fast, portable, and non-invasive tool in the evaluation of shunt flow and can help clinicians determine whether it is safe to send a patient home or intervene appropriately.

Declaration of patient consent

Written informed consent was waived for this study given a retrospective analysis of de-identified data.

Financial support and sponsorship

Funded in part by MSTP (Medical Scientist Training Program) Grant from NIH (T32-GM08620) to RS.

Conflicts of interest

There are no conflicts of interest.

REFERENCES

- Aschoff A, Kremer P, Hashemi B, Kunze S. The scientific history of hydrocephalus and its treatment. *Neurosurg Rev* 1999;22:67-93.
- Bondurant CP, Jimenez DE. Epidemiology of cerebrospinal fluid shunting. *Pediatr Neurosurg* 1995;23:254-8.
- Caldarelli M, Di Rocco C, Cellini N, De Santis M. A technique for evaluation of CSF shunt patency using telethermography. *Neuropediatrics* 1981;12:303-7.
- Chiba Y, Ishiwata Y, Suzuki N, Muramoto M, Kunimi Y. Thermosensitive determination of obstructed sites in ventriculoperitoneal shunts. *J Neurosurg* 1985;62:363-6.
- Chiba Y, Yuda K. Thermosensitive determination of CSF shunt patency with a pair of small disc thermistors. *J Neurosurg* 1980;52:700-4.
- Choux M, Genitori L, Lang D, Lena G. Shunt implantation: Reducing the incidence of shunt infection. *J Neurosurg* 1992;77:875-80.
- Go KG, Melchior HJ, Lakke JP. A thermosensitive device for the evaluation of the patency of ventriculo-atrial shunts in hydrocephalus. *Acta Neurochir (Wien)* 1968;19:209-16.
- Hameed MQ, Zurakowski D, Proctor MR, Stone SSD, Warf BC, Smith ER, *et al.* Noninvasive thermal evaluation of ventriculoperitoneal shunt patency and cerebrospinal fluid flow using a flow enhancing device. *Neurosurgery* 2019;85:240-9.
- Ishiwata Y, Chiba Y, Yamashita T, Gondo G, Ide K, Kuwabara T. Thermosensitive determination of patency in lumboperitoneal shunts. Technical note. *J Neurosurg* 1989;70:143-5.
- Iskandar BJ, McLaughlin C, Mapstone TB, Grabb PA, Oakes WJ. Pitfalls in the diagnosis of ventricular shunt dysfunction: Radiology reports and ventricular size. *Pediatrics* 1998;101:1031-6.
- Kulkarni AV, Drake JM, Lamberti-Pasculli M. Cerebrospinal fluid shunt infection: A prospective study of risk factors. *J Neurosurg* 2001;94:195-201.
- Kurwale NS, Agrawal D. Phase-contrast magnetic resonance imaging of intracranial shunt tube: A valuable adjunct in the diagnosis of ventriculoperitoneal shunt malfunction. *Clin Neurosurg* 2011;58:138-42.
- Maartens NF, Aurora P, Richards PG. An unusual complication of tapping a ventriculoperitoneal shunt. *Eur J Paediatr Neurol* 2000;4:125-9.
- Madsen JR, Abazi GS, Fleming L, Proctor M, Grondin R, Magge S, *et al.* Evaluation of the ShuntCheck noninvasive thermal technique for shunt flow detection in hydrocephalic patients. *Neurosurgery* 2011;68:198-205.
- Marlin AE, Gaskill SJ. The use of transcutaneous thermal convection analysis to assess shunt function in the pediatric population. *Neurosurgery* 2012;70:181-3.
- Martin AJ, Drake JM, Lemaire C, Henkelman RM. Cerebrospinal fluid shunts: Flow measurements with MR imaging. *Radiology* 1989;173:243-7.
- McNatt SA, Kim A, Hohuan D, Krieger M, McComb JG. Pediatric shunt malfunction without ventricular dilatation. *Pediatr Neurosurg* 2008;44:128-32.
- Meier U, Mutze S. Does the ventricle size change after shunt operation of normal-pressure hydrocephalus? *Acta Neurochir Suppl* 2005;95:257-9.
- Merkler AE, Chang J, Parker WE, Murthy SB, Kamel H. The Rate of complications after ventriculoperitoneal shunt surgery. *World Neurosurg* 2017;98:654-8.
- Miller JP, Fulop SC, Dashti SR, Robinson S, Cohen AR. Rethinking the indications for the ventriculoperitoneal shunt tap. *J Neurosurg Pediatr* 2008;1:435-8.
- Neff S. Measurement of flow of cerebrospinal fluid in shunts by transcutaneous thermal convection. Technical note. *J Neurosurg* 2005;103:366-73.
- Noetzel MJ, Baker RP. Shunt fluid examination: Risks and benefits in the evaluation of shunt malfunction and infection. *J Neurosurg* 1984;61:328-32.
- Paff M, Alexandru-Abrams D, Muhonen M, Loudon W. Ventriculoperitoneal shunt complications: A review. *Interdisciplinary Neurosurgery* 2018;13:66-70.
- Park MK, Kim M, Park KS, Park SH, Hwang JH, Hwang SK. A retrospective analysis of ventriculoperitoneal shunt revision cases of a single institute. *J Korean Neurosurg Soc* 2015;57:359-63.
- Reddy GK, Bollam P, Caldito G. Long-term outcomes of ventriculoperitoneal shunt surgery in patients with hydrocephalus. *World Neurosurg* 2014;81:404-10.
- Sood S, Kim S, Ham SD, Canady AI, Greninger N. Useful

- components of the shunt tap test for evaluation of shunt malfunction. *Childs Nerv Syst* 1993;9:157-61.
27. Spirig JM, Frank MN, Regli L, Stieglitz LH. Shunt age-related complications in adult patients with suspected shunt dysfunction. A recommended diagnostic workup. *Acta Neurochir (Wien)* 2017;159:1421-8.
 28. Stein SC. Testing cerebrospinal fluid shunt function: A noninvasive technique. *Neurosurgery* 1980;6:649-51.
 29. Winston KR, Lopez JA, Freeman J. CSF shunt failure with stable normal ventricular size. *Pediatr Neurosurg* 2006;42:151-5.
 30. Wu Y, Green NL, Wensch MR, Zhao S, Gupta N. Ventriculoperitoneal shunt complications in California: 1990 to 2000. *Neurosurgery* 2007;61:557-62.

How to cite this article: Xu J, Poole C, Sahyouni R, Chen J. Noninvasive thermal evaluation for shunt failure in the emergency room. *Surg Neurol Int* 2019;10:254.