## Title
Outcomes of Cephalic Arch Stenosis With and Without Stent Placement after Percutaneous Balloon Angioplasty in Hemodialysis Patients



## Journal
Seminars in Dialysis, 28(1)

## ISSN
0894-0959

## Authors
Dukkipati, Ramanath
Lee, Luani
Atray, Naveen
et al.

## Publication Date
2015

## DOI
10.1111/sdi.12310

Seminars in Dialysis

ASDIN
AMERICAN SOCIETY OF DIAGNOSTIC AND INTERVENTIONAL NEPHROLOGY

# Outcomes of Cephalic Arch Stenosis With and Without Stent Placement after Percutaneous Balloon Angioplasty in Hemodialysis Patients

Ramanath Dukkipati,*† Luani Lee,*† Naveen Atray,‡ Raahil Kajani,* George Nassar,§ and Kamyar Kalantar-Zadeh¶

*Los Angeles Biomedical Research Institute at Harbor-UCLA Medical Center, Sacramento, California, †David Geffen School of Medicine at UCLA, Sacramento, California, ‡Capital Nephrology Associates, Sacramento, California, §Weill Cornell University, Houston, Texas, and ¶University of California at Irvine, Irvine, California

## ABSTRACT

Cephalic arch stenosis is a common complication in maintenance hemodialysis (MHD) patients with brachial artery-cephalic vein fistulas and frequently leads to loss of the functioning brachial artery-cephalic vein fistula. There is paucity of conclusive data to guide appropriate management. We examined the risk of recurrence of cephalic arch stenosis after angioplasty compared to angioplasty after stent placement determined by angiography of the involved upper extremity over time in a contemporary cohort of MHD patients treated in two interventional nephrology practices from March 2008 through May 2011. We retrospectively identified 45 MHD patients with evidence of cephalic arch stenosis (age 60 ± 30 years, 45% men) on elective angiograms. The median number of days until another angioplasty was required decreased, starting with a median of 91.5 days after the first, 70.5 days after the second, 85 days after the third, and 56 days after the fourth. Angioplasty is associated with a faster rate of recurrence of cephalic arch stenosis. The placement of intravascular stent seems to prolong the patency compared to angioplasty alone. Clinical trials with a larger sample size will better elucidate the value and timing of angioplasty versus stent placement in cephalic arch stenosis.

The cephalic arch comprises the portion of the cephalic vein in the shoulder as it traverses the deltopectoral groove through the clavipectoral fascia and passes below the clavicle and joins the axillary vein. Stenosis of the cephalic arch is a common feature in the failure of brachial artery-cephalic vein fistulas in maintenance hemodialysis (MHD) patients. In MHD patients with brachiocephalic fistulas, the cephalic arch is particularly susceptible to develop venous stenosis (1,2). Pathophysiology of cephalic arch stenosis (CAS) is likely multifactorial. The cephalic arch vulnerability to stenosis is thought to be due to the anatomic location in the deltopectoral groove thus limiting remodeling, angulation of the vein, and unfavorable shear stress related to increased blood flow (3–5). The cephalic vein in patients with renal failure display accelerated intimal hyperplasia and wall thickening relative to cephalic veins in patients with normal renal function (6). The anatomy of the arch itself may give rise to turbulent flow causing high wall shear stress that promotes endothelial proliferation, vasoconstriction, and platelet aggregation (7). Venous valves located in the cephalic arch when exposed to high blood flows can hypertrophy, leading to the significant reduction in the luminal diameter of the vein (8). Failure of a vessel to dilate in the face of intimal hyperplasia will result in narrowing of the venous lumen and to obstruction of blood flow. The diameter of the cephalic vein varies from patient to patient, and the pre-fistula-creation diameter of the vein may correlate with the level of venous enlargement after fistula placement. The distal part of the vein dilates in response to the higher flows, but the cephalic arch may not be able to adequately dilate to the extent that is needed to support an arteriovenous fistula (9).

Purcutaneous balloon angioplasty has generally been the initial treatment option for venous stenosis and is considered to be the standard of care. However, CAS is frequently resistant to balloon angioplasty, requiring multiple angioplasty procedures in patients with recurrent stenosis. The use of higher pressure balloons is also often necessary, rendering

*Address correspondence to*: Ramanath Dukkipati, M.D., Division of Nephrology and Hypertension, Harbor-UCLA Medical Center, 1124 West Carson Street, C-1 Annex, Torrance, CA 90509, or e-mail: ramdukkipati@gmail.com.

*Seminars in Dialysis*—Vol 28, No 1 (January–February) 2015 pp. E7–E10
DOI: 10.1111/sdi.12310

**TABLE 1. Demographics and anatomic location of the fistula in study patients**

| Patient # | Age | Sex | Type of access | # PTCA |
|---|---|---|---|---|
| Patient 1 | 28 | F | Right Brachial-Basilic AVF | 2 |
| Patient 2 | 74 | F | L B-C AVF | 3 |
| Patient 3 | 71 | F | L B-C AVF | 4 |
| Patient 4 | 66 | F | R arm AV graft | 1 |
| Patient 5 | 88 | M | Left B-C AVF | 1 |
| Patient 6 | 86 | F | L B-C AVF | 4 |
| Patient 7 | 43 | M | L B-C AVF | 2 |
| Patient 8 | 78 | M | L B-C AVF | 2 |
| Patient 9 | 51 | F | Left B-C AVF | 2 |
| Patient 10 | 61 | F | Left B-C AVF | 1 |
| Patient 11 | 64 | F | R B-C AVF | 2 |
| Patient 12 | 70 | F | L R-C AVF | 1 |
| Patient 13 | 87 | M | R B-C AVF | 6 |
| Patient 14 | 56 | F | L B-C AVF | 5 |
| Patient 15 | 86 | M | R B-C AVF | 1 |
| Patient 16 | 59 | F | L B-C AVF | 4 |
| Patient 17 | 58 | F | L B-C AVF | 2 |
| Patient 18 | 54 | F | L Brachial artery-Basilic Vein AVF | 1 |
| Patient 19 | 62 | F | R B-C AVF | 2 |
| Patient 20 | 42 | M | L B-C AVF | 5 |
| Patient 21 | 64 | M | Left Radial-Cephalic AVF | 1 |
| Patient 22 | 68 | F | R Brachial-Basilic AVF | 1 |
| Patient 23 | 34 | M | L B-C AVF | 1 |
| Patient 24 | 58 | F | R B-C AVF | 5 |
| Patient 25 | 42 | F | L B-C AVF | 3 |
| Patient 26 | 59 | F | L B-C AVF | 2 |
| Patient 27 | 80 | M | L B-C AVF | 3 |
| Patient 28 | 43 | F | L B-C AVF | 3 |
| Patient 29 | 84 | M | L B-C AVF | 4 |
| Patient 30 | 40 | | R B-C AVF | 4 |
| Patient 31 | 58 | M | L B-C AVF | 2 |
| Patient 32 | 59 | M | L forearm Loop graft | 2 |
| Patient 33 | 51 | F | L B-C AVF | 2 |
| Patient 34 | 82 | F | R B-C AVF | 4 |
| Patient 35 | 47 | F | L B-C AVF | 1 |
| Patient 36 | 58 | F | L B-C AVF | 1 |
| Patient 37 | 64 | M | L B-C AVF | 1 |
| Patient 38 | 47 | M | L B-C AVF | 1 |
| Patient 39 | 44 | F | L B-C AVF | 1 |
| Patient 40 | 57 | M | R B-C-AVF | 1 |
| Patient 41 | 64 | F | L B-C-AVF | 2 |
| Patient 42 | 58 | F | R B-C AVF | 2 |
| Patient 43 | 59 | M | L B-C AVF | 1 |
| Patient 44 | 66 | F | R B-C -AVF | 3 |
| Patient 45 | 43 | M | L B-C -AVF | 2 |

AVF is arteriovenous fistula, LBC is left brachial artery-cephalic vein arteriovenous fistula.

the vessel susceptible to rupture (2). Lack of optimal angioplasty outcomes have lead to the use of intravascular stent placement to be used for treatment of cephalic arch stenosis. Stenosis can occur within the stent and frequent recurrence of this stenosis may lead one to consider surgical options such as vein patch angioplasty and transposition of the cephalic vein to axillary or subclavian vein to manage this lesion (10,11). This study examines the value and timing of angioplasty versus angioplasty along with stent placement in management of cephalic arch stenosis.

## Methods

We examined the risk of recurrence of cephalic arch stenosis after angioplasty or after stent placement determined by angiography of the involved upper extremity over time in a contemporary cohort of MHD patients treated in two interventional nephrology practices from March 2008 through May 2011.

## Results

We retrospectively identified 45 MHD patients with evidence of cephalic arch stenosis (age 60 ± 30 years, 45% men) on elective angiograms (Table 1). The median number of days until another angioplasty was required decreased, starting with a median of 91.5 days after the first, 70.5 days after the second, 85 days after the third, and 56 days after the fourth. An association was found between the number of angioplasties and a decreasing median number of days between each subsequent angioplasty. However, the median number of days between stent placement and the subsequent angioplasty was much greater (152 days) than the median number of days between the first two angioplasties of a patient who did not have a stent placed (91.5 days). An association was found between increased patency and stent placement. Of the 20 patients who had stents placed, the mean number of angioplasties required after stent placement was 0.75. In fact, of the patients who had a stent placed, 11 patients did not show any symptoms of cephalic arch stenosis and therefore did not require any subsequent angioplasties (Fig. 1). Of the 25 patients who did not have a stent placed, the mean number of total angioplasties required was 2.76. An association was found between stent placement and a decreased number of angioplasties required (Fig. 2).

## Discussion

Randomized clinical trials that exclusively study CAS are sparse. Our study is one of the largest cephalic arch stenosis-specific studies performed to date.

Standard of care for stenosis in the cephalic arch remains percutaneous balloon angioplasty (PBA) which typically requires higher inflation pressures

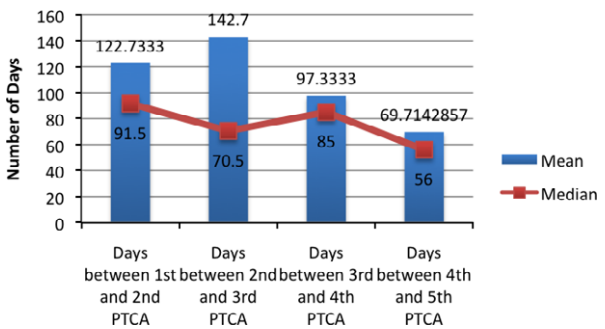


FIG. 1. Interval time between subsequent angioplasty for cephalic arch stenosis.

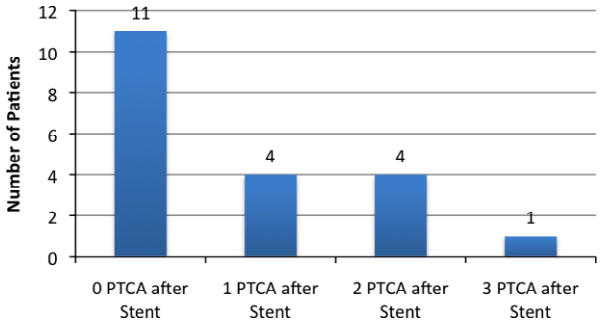


FIG. 2. Number of patients who required angioplasty after stent placement.

during PBA at this site. Uncovered stents after PBA of cephalic arch stenosis is not optimal and there is no conclusive evidence to prove that placement of stent following PBA improves outcomes. The disadvantage of placing an uncovered stent is that its propensity for fracture and the added potential to convert a focal lesion into a stent-length lesion as intimal hyperplasia develops along the length of the stent. There have been no large randomized clinical trials evaluating outcomes with stent grafts at this location.

In a retrospective study of 177 failing fistulas (66% in the forearm and 34% in the upper arm), 39% of brachiocephalic fistulas and 2% of radial artery-cephalic vein fistulas had CAS (2). In this study of 50 angioplasty procedures done on 26 fistulas, brachiocephalic fistulas were 37 times more likely to have CAS than radial artery-cephalic fistulas. Primary patency was 42% at 6 months and 23% at 1 year. The median primary patency was 5 months. Primary assisted patency was 83% at 6 months and 75% at 1 year with a median patency of 3 years. An average of 1.6 procedures was required in 12 months to assist patency. In contrast to primary patency of 50–75% after PBA in stenosis of AV fistulas in MHD patients that does not include cephalic arch, this study reported primary patency of 42% at 6 months at the cephalic arch.

In our study, 102 angioplasty procedures were done on 43 fistulas comprising predominantly of 40 brachiocephalic fistulas. There was one radial artery-cephalic vein fistula, two grafts, and two brachial artery-basilic vein fistulas. An association was found between increased patency and stent placement. Of the 20 patients who had stents placed, the mean number of angioplasties required after stent placement was 0.75. In fact, of the patients who had a stent placed, 11 patients did not show any symptoms of cephalic arch stenosis and therefore did not require any subsequent angioplasties. Of the 25 patients who did not have a stent placed, the mean number of total angioplasties required was 2.76. An association was found between stent placement and a decreased number of angioplasties required.

There has not been a randomized controlled trial of adequate sample size comparing bare metal stents with stent grafts in CAS. Twenty-five patients with recurrent CAS (defined as recurrent CAS within 3 months of successful balloon angioplasty) were randomized to receive angioplasty in addition to placement of either stent graft or bare metal stent (12). In this randomized prospective study with significant limitations which compared 6-month primary patency between stents and stent grafts, there was a reported 39% primary patency with stents and 82% with stent grafts. Surgical treatment of cephalic arch stenosis is considered in the setting of recurrent in situ or in-stent stenosis (10).

The median number of days in our study between stent placement and the subsequent angioplasty was much greater (152 days) than the median number of days between the first two angioplasties of a patient who did not have a stent placed (91.5 days). This suggests stent placement can prolong the patency period after angioplasty.

Previous studies have shown that angioplasty itself can accelerate neointimal hyperplasia leading to stenosis in fistulas and confirming this observation in our study median number of days until another angioplasty was required decreased, starting with a median of 91.5 days after the first, 70.5 days after the second, 85 days after the third, and 56 days after the fourth. No stent grafts were used in our study.

Some limitations of our study are its retrospective nature, type of stent in each of the patients was not uniform, and the degrees of stenosis before angioplasty was not equivalent which may have an impact on time to recurrence of stenosis after angioplasty.

## Conclusions

Angioplasty alone is associated with a faster rate of recurrence of cephalic arch stenosis. The placement of intravascular stent seems to prolong the patency compared to angioplasty alone. Clinical trials with a larger sample size will better elucidate the value and timing of angioplasty versus stent placement in cephalic arch stenosis.

## References

1. Turmel-Rodrigues L, Pengloan J, Baudin S, Testou D, Abaza M, Dahdah G, Mouton A, Blanchard D: Treatment of stenosis and thrombosis in haemodialysis fistulas and grafts by interventional radiology. *Nephrol Dial Transplant* 15(12):2029–2036, 2000
2. Rajan DK, Clark TW, Patel NK, Stavropoulos SW, Simons ME: Prevalence and treatment of cephalic arch stenosis in dysfunctional autogenous hemodialysis fistulas. *J Vasc Interv Radiol* 14(5):567–573, 2003
3. Au FC: The anatomy of the cephalic vein. *Am Surg* 55(10):638–639, 1989
4. Chen JY, Chang KC, Lin KH, Lin YC, Lee JD, Huang SK: Ultrasonographic predictors of unsuccessful cephalic vein approach during pacemaker or defibrillator lead implantation. *Pacing Clin Electrophysiol* 29(7):706–711, 2006
5. Hallock GG: The cephalic vein in microsurgery. *Microsurgery* 14 (8):482–486, 1993
6. Wali MA, Eid RA, Dewan M, Al-Homrany MA: Intimal changes in the cephalic vein of renal failure patients before arterio-venous fistula (AVF) construction. *J Smooth Muscle Res* 39(4):95–105, 2003

7. Paszkowiak JJ, Dardik A: Arterial wall shear stress: observations from the bench to the bedside. *Vasc Endovascular Surg* 37(1):47–57, 2003
8. Harmon JV Jr, Edwards WD: Venous valves in subclavian and internal jugular veins. Frequency, position, and structure in 100 autopsy cases. *Am J Cardiovasc Pathol* 1(1):51–54, 1987
9. Roy-Chaudhury P, Sukhatme VP, Cheung AK: Hemodialysis vascular access dysfunction: a cellular and molecular viewpoint. *J Am Soc Nephrol* 17(4):1112–1127, 2006
10. Kian K, Unger SW, Mishler R, Schon D, Lenz O, Asif A: Role of surgical intervention for cephalic arch stenosis in the "fistula first" era. *Semin Dial* 21(1):93–96, 2008
11. Kian K, Asif A: Cephalic arch stenosis. *Semin Dial* 21(1):78–82, 2008
12. Shemesh D, Goldin I, Zaghal I, Berlowitz D, Raveh D, Olsha O: Angioplasty with stent graft versus bare stent for recurrent cephalic arch stenosis in autogenous arteriovenous access for hemodialysis: a prospective randomized clinical trial. *J Vasc Surg* 48(6):1524–1531, 1531 e1521–1522, 2008