


Lennox-Gastaut syndrome: A consensus approach to differential diagnosis

*Blaise F. D. Bourgeois, †Laurie M. Douglass, and ‡Raman Sankar

Epilepsia, 55(Suppl. 4):4–9, 2014
doi: 10.1111/epi.12567



Dr. Bourgeois is Emeritus Professor of Neurology, Harvard Medical School, and Emeritus Director of the Division of Epilepsy and Clinical Neurophysiology, Boston Children's Hospital.

SUMMARY

Lennox-Gastaut syndrome (LGS) is a severe epileptic encephalopathy that shares many features and characteristics of other treatment-resistant childhood epilepsies. Accurate and early diagnosis is essential to both prognosis and overall patient management. However, accurate diagnosis of LGS can be clinically challenging. This article summarizes key characteristics of LGS and areas of overlap with other childhood epilepsies. Drawing upon input from a committee of established LGS experts convened in June 2012 in Chicago, Illinois, the authors highlight key diagnostic tests for making the differential diagnosis and propose a diagnostic scheme for people with suspected LGS.

KEY WORDS: Epilepsy, Encephalopathy, Seizure, West syndrome, Infantile spasms.

Lennox-Gastaut syndrome (LGS) is a severe epileptic encephalopathy in which the epileptiform abnormalities may contribute to progressive dysfunction.¹ Characterized by polymorphic seizures and neuropsychological decline,² patients with LGS account for 5–10% of children with seizures.² Prognosis for LGS is very poor: 5% of children die, 80–90% continue having seizures into adulthood, and nearly all have cognitive and behavioral problems.² In a population-based cohort of 688 children in Atlanta, Georgia,

the risk of death among children with Lennox-Gastaut syndrome was 14 times greater than that of children, adolescents, and young adults in the general population; most deaths resulted from neurologic causes, often with seizures cited as the precipitating factor.³ This finding suggests that optimal seizure control may contribute to reduced mortality in patients with LGS.³

Accurate and early diagnosis of LGS is essential for effective management and for improving clinical outcomes.⁴ This goal, however, is often elusive for many reasons. Because LGS may arise from multiple etiologies, the clinical presentation varies, demonstrating variable seizure types and electroencephalogram (EEG) features that often change over time, thereby complicating the diagnostic process.⁴ As with many disease processes, LGS has no biologic markers.⁴ But perhaps the most confounding diagnostic factor arises from the medical community itself, which is divided about the specific limits, features, and causes of LGS.^{2,5} Given the polymorphic nature of LGS, it is often confused with other syndromes,

Accepted January 15, 2013.

*Harvard Medical School, Children's Hospital, Boston, Massachusetts, U.S.A.; †Boston Medical Center, Boston University School of Medicine, Boston, Massachusetts, U.S.A.; and ‡David Geffen School of Medicine at UCLA, Los Angeles, California, U.S.A.

Address correspondence to Blaise F. D. Bourgeois, Division of Epilepsy & Clinical Neurophysiology, Harvard Medical School, William G. Lennox Chair in Pediatric Epilepsy, Children's Hospital, F9 300 Longwood Avenue, Boston, MA 02115, U.S.A. E-mail: bfbourgeois@gmail.com

Wiley Periodicals, Inc.

© 2014 International League Against Epilepsy

which delays diagnosis and effective management.⁴ The complex and highly variable presentation of LGS requires a systematic approach toward evaluation and diagnosis.

PRESENTATION AND CLINICAL CHARACTERISTICS

Occurring with a slight male predominance, LGS most commonly first manifests in children between 3 and 5 years of age, but onset can also occur at younger and older ages—even into adulthood.⁴ LGS is sometimes preceded by West syndrome,⁶ potentially delaying diagnosis. In symptomatic cases, LGS most frequently occurs secondary to damage to the brain resulting from prenatal or perinatal insult, infection, malformations, or tumor.⁷ However, approximately one fourth to one third of LGS cases have no clear etiology, with some cases possibly involving genetic factors.⁴

The classic diagnostic criteria for LGS consists of a triad of features: multiple seizure types, abnormal EEG, and cognitive impairment (Fig. 1).⁴ Age at onset, abnormal or normal brain imaging, and causative factors are generally not thought to be important.²

Multiple seizure types

Tonic seizures during sleep is the feature often used as the foundation for diagnosis,⁴ but in fact LGS is characterized by multiple concurrent seizure types: tonic, atypical absence seizures, atonic, and myoclonic jerks.² Nonconvulsive status epilepticus, lasting days to weeks, occurs in half of patients.² Some experts contend that atypical absences must be present for an LGS classification, but others prefer tonic seizures as the defining diagnostic feature.² The first

clinical sign is often the occurrence of sudden tonic or atonic falls, referred to as “drop attacks.”⁷ At least 50% of patients with LGS experience drop attacks.⁸ They typically are preceded by a single generalized myoclonic jerk followed by a tonic contraction of axial muscles or axial atony, or a combination, leading to a sudden fall and injury; patients sometimes wear a helmet with a full face mask to prevent head trauma.⁸ Other seizure types that occur in LGS include focal, generalized tonic-clonic, and unilateral clonic manifestations, often evolving from one type to another over time.⁴

Abnormal EEG

Characteristically, abnormal EEGs show slow spike-wave complexes (originally known as the petit mal variant) at <3 Hz that occur during wakefulness.^{4,9} The complexes typically consist of a spike (duration < 70 msec) or a sharp wave (70–200 msec), followed first by a positive deep “trough,” and then a negative wave (350–400 msec) (Fig. 2).⁹ Not every wave, however, is preceded by a spike. The bursts can wax and wane, with no clear onset and offset.⁸ Although slow spike waves often occur during the seizure, they are sometimes interictal and may not manifest in any clinically observable manner. This allows for diagnostic differentiation from extended 3 Hz spike-wave discharges, which typically are accompanied by notable clinical changes.⁹

In LGS, paroxysmal fast rhythms (10–20 Hz) occur mainly during non-rapid eye movement (REM) sleep (Fig. 3) and their presence is considered by some to be essential to the diagnosis.^{4,10} Paroxysmal fast rhythms are more common in the setting of LGS as compared to secondary bilateral synchrony (79% vs. 15%), and therefore can also be a consideration in the differential diagnosis.⁹ EEG patterns may change over time, manifesting focal epileptiform discharges, diffuse and focal slow waves, or disappearance of these specific abnormalities.⁴

Cognitive impairment

Often accompanied by behavioral problems, cognitive impairment is a function of the epileptic encephalopathy and is an essential diagnostic feature.⁴ Ten percent to 20% of children with LGS are within accepted normal ranges for cognitive function, but have slow mental processing, making it difficult for them to perform day-to-day activities.⁹ The vast majority, however, eventually have cognitive impairment, with decreasing intelligence quotient (IQ) over time.^{4,11} An assessment of the long-term prognosis for patients with LGS followed for a mean of 17 years showed that 69% exhibited some degree of mental retardation at the first visit, whereas 99% exhibited mental retardation at the final follow-up visit.¹²

Four independent risk factors for severe cognitive impairment in patients with LGS have been identified: nonconvulsive status epilepticus (NCSE), a previous diagnosis of West

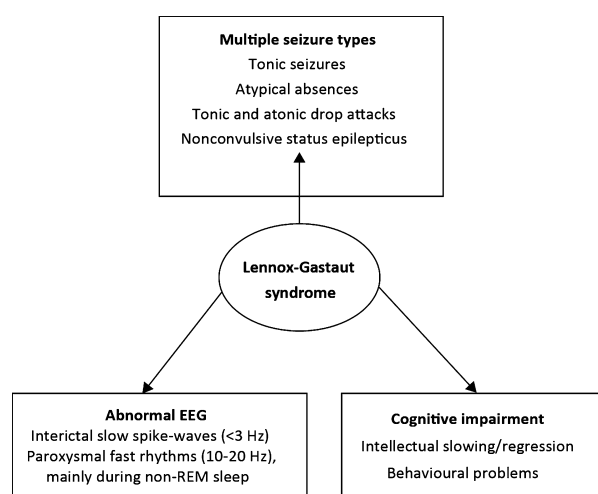


Figure 1.

The classic diagnostic criteria for LGS.⁴ Reprinted with permission from John Libbey Eurotext.

Epilepsia © ILAE

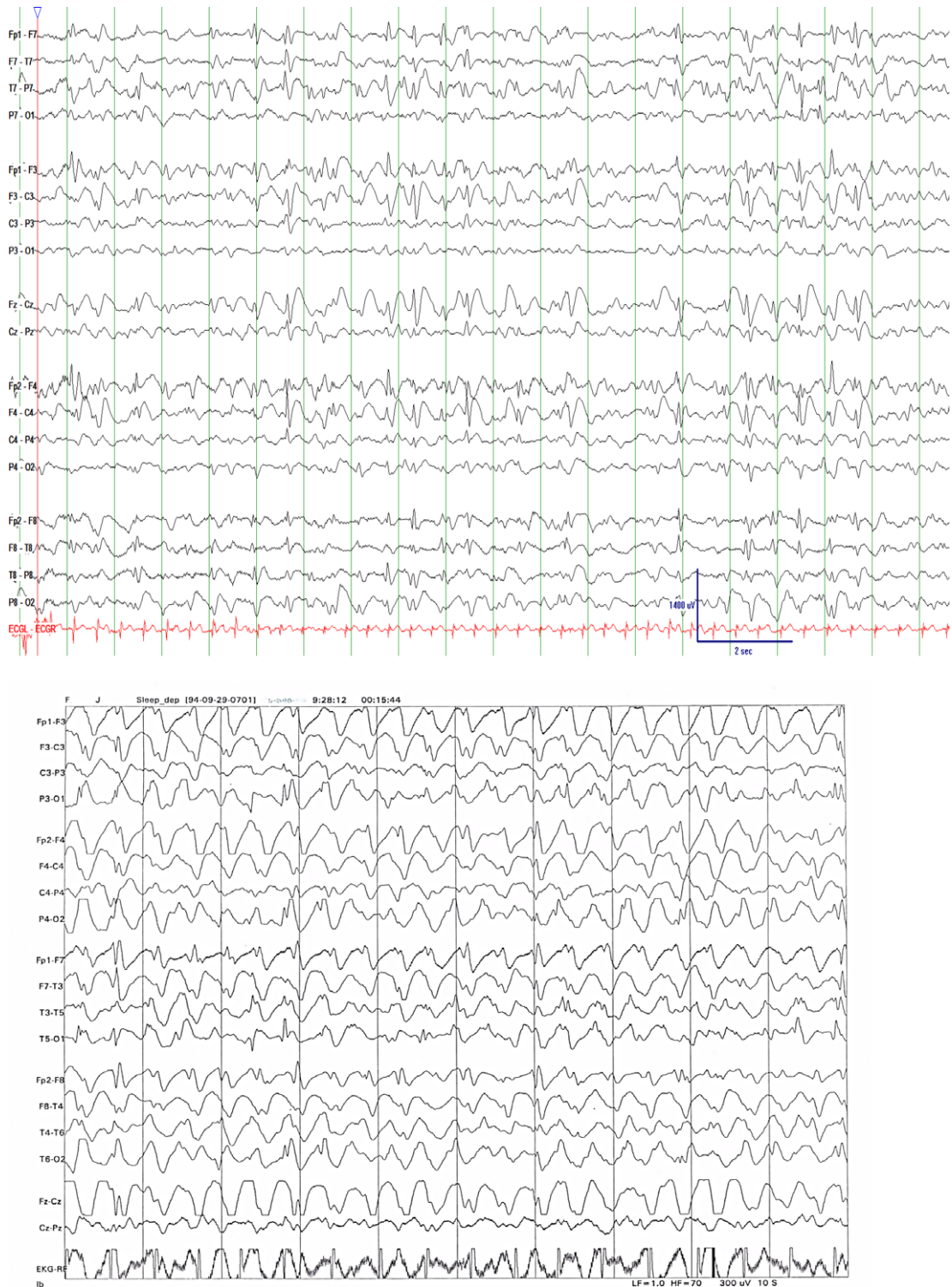


Figure 2.

Slow sharp and spike-wave complexes at 2–2.5 Hz in 2 patients with LGS (segments of 20 and 10 s, respectively). Courtesy of Blaise F. D. Bourgeois.

Epilepsia © ILAE

syndrome, a symptomatic etiology of epilepsy, and an early age at onset of epilepsy. NCSE appears to be the most important risk factor for severe cognitive impairment.¹³ Although

one third of patients experience normal cognitive development prior to seizure onset, most show developmental impairment beforehand.^{2,9}

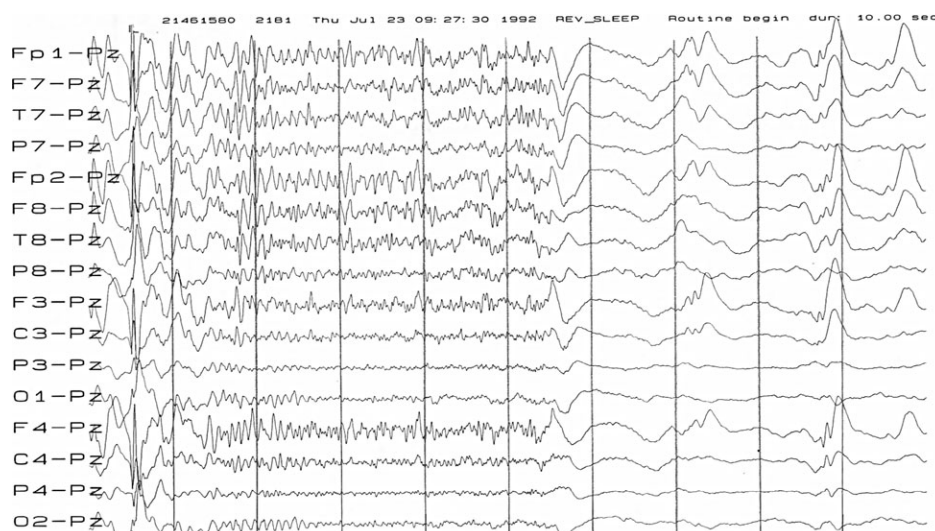


Figure 3. Fast rhythms during sleep, considered by some experts to be key to the differential diagnosis of LGS. Courtesy of Blaise F. D. Bourgeois. *Epilepsia* © ILAE

Behavioral problems, such as hyperactivity, aggression, and autistic traits occur in half of cases. These behaviors are more marked in early onset or symptomatic LGS.⁷

DIFFERENTIAL DIAGNOSIS

LGS can be differentiated from other epilepsy syndromes based on history and EEG characteristics, but achieving an accurate diagnosis can be challenging.⁵ Not all patients with LGS display the characteristic triad of features, particularly at onset.^{4,14} Table 1 highlights typical features and characteristics of various epileptic syndromes to support attempts to achieve a differential diagnosis.^{5,9,15–18}

Despite clear parameters and distinguishing clinical features, significant overlap exists between LGS and other early-onset epileptic encephalopathies. Drop attacks, which are seen frequently in LGS patients, occur in many other syndromes. Epilepsies that share this or other characteristics of LGS include focal epilepsies with secondary bilateral synchrony, myoclonic–astatic epilepsy (Doose syndrome), Dravet syndrome,⁷ West syndrome,¹² and atypical benign

partial epilepsy of childhood.¹⁸ There is a tendency to incorrectly diagnose LGS whenever there are multiple seizure types or drop attacks.¹⁴ One retrospective study reported misdiagnosis in at least 29 of 103 patients who were referred with a diagnosis of LGS.¹⁹ It is important to differentiate LGS from other forms of epilepsies because of differences in prognosis and approaches to treatment.^{4,5}

The diagnosis of LGS versus other severe generalized epilepsies of childhood must be based on a detailed history, and awake and asleep EEGs with polygraphic recording, which are sometimes repeated.⁵ Two thirds or more of patients with LGS have abnormal magnetic resonance imaging (MRI) findings, which is used to detect subtle focal lesions.²

STEPS FOR EVALUATING LGS: A PROPOSED ALGORITHM

In June 2012, a group of LGS experts were convened to discuss approaches to the differential diagnosis of LGS and to the identification of a possible underlying etiology.

Table 1. Features of various epileptic syndromes

Syndrome	Age of onset	EEG	Tonic seizure	Atonic seizure	Intellect impaired	Other seizure types
LGS	1–8 years	<3 Hz sp wave and 10 Hz in sleep	80–90% in sleep	Some	Yes	All
MAE/Doose	1–5 years	4 Hz theta and G PSW	++	++	Rarely	M
Dravet/SIME	<1 year Febrile, other seizures at 2–3 years	Slow with irregular spike wave	Rare	Rare	Yes	M AA GTC Focal
West	Usually <1 year	Hypsarrhythmia	Yes	Yes	Usually impaired	
Pseudo Lennox (ABPE)	2–5 years	Central spikes and GSW	No	Yes	26–56%	M AA Focal

AA, atypical absence; ABPE, atypical benign partial epilepsy; EEG, electroencephalogram; GSW, generalized spike wave; GTC, generalized tonic-clonic; LGS, Lennox-Gastaut syndrome; M, myoclonus; MAE, myoclonic–astatic epilepsy; PSW, polyspike and wave; SIME, severe infantile myoclonic epilepsy.^{5,9,15–18}

Although there were areas of consensus, some advocated tests not used by others. Experts called for, at a minimum, awake and asleep EEGs,⁸ as well as physical examination (in particular neurologic deficits, skin changes, fibromas, heart murmur) and ophthalmologic examination (retinal abnormalities, visual impairment) together with medical and social history and head MRIs. Some of the neurologists also advocated for utilization of video-EEGs with electromyogram (EMG) electrodes, and genetic/chromosomal microarrays, although these were not used universally.

If the underlying etiology was not identified following these investigations, some experts called for further testing, in particular DNA microarray, SLC2A1 (glucose transporter defect), CLN2 (late infantile neuronal ceroid lipofuscinosis), and TSC 1,2 (tuberous sclerosis). Some of these tests are considered when the condition deteriorates. It is observed that different centers have different approaches to doing the tests on a regular basis. Genetics and metabolism consultations were recommended by some experts, as well as ophthalmology (e.g., retinal hamartomas in tuberous sclerosis, visual loss in lipofuscinosis) and cardiology (e.g., rhabdomyomas in tuberous sclerosis).

ADDITIONAL CONFOUNDING FACTORS

Aside from clinical challenges to differential diagnosis,⁵ additional barriers exist. Frequently, parents are unwilling to accept the diagnosis due to the negative prognosis involved. As a group, community child neurologists tend to be less familiar with the diagnostic criteria of LGS and thus more hesitant to make the diagnosis, preferring to call it “mixed seizure disorder.” Lack of access to specialists and lack of insurance coverage pose additional obstacles to diagnosis.

CONCLUSIONS

The diagnosis of LGS is derived from careful evaluation of both clinical and electrographic abnormalities. These include multiple seizure types (tonic seizures, atonic seizures, and atypical absence seizures); EEG with generalized slow spike-wave during the waking state and bursts of generalized paroxysmal fast activity often seen during sleep; as well as cognitive and behavioral impairment. There is significant overlap between LGS and other epilepsy syndromes, making the differential diagnosis particularly challenging. A complete evaluation of the medical history, along with an EEG in waking and sleep states, is critical for accurate diagnosis of the syndrome. A comprehensive physical examination and additional investigations may help to identify a possible underlying etiology. Although making a differential diagnosis can be challenging, it is important for determining prognosis and can impact treatment decisions. Additional approaches to the differential diagnosis proposed in this article may be considered in suspected cases of LGS.

ACKNOWLEDGMENTS

The meeting of the expert committee convened to discuss the differential diagnosis of LGS in June 2012 in Chicago, Illinois. This meeting was supported by a grant from Eisai Inc., which had no direct control of the group's activities. Writing support for this manuscript was provided by Aric J. Fader, PhD, of MedVal Scientific Information Services, LLC, and by Genevieve Belfiglio, RN, MA, agent of MedVal Scientific Information Services, LLC, and was funded by Eisai Inc., which did not have editorial control of the content. This manuscript is an original work and was prepared according to the International Society for Medical Publication Professionals' *Good Publication Practice for Communicating Company-Sponsored Medical Research: The GPP2 Guidelines*.

CONFLICT OF INTEREST

Dr. Bourgeois served as a consultant to Upsher-Smith Laboratories, Inc.; received research support from Lundbeck Inc.; received royalties from the publication of *Pediatric Epilepsy, 3rd Edition* and *The Epilepsy Prescriber's Guide to Antiepileptic Drugs*; and is one of several people holding a patent on technology that allows patient-specific early seizure detection based on EEG recording in patients with epileptic seizures. He is a member of the Data and Safety Monitoring Board for a multicenter drug trial conducted by Pfizer. Dr. Douglass received unrestricted educational grants from Eisai Inc. to conduct continuing medical education programs and to submit manuscripts from the proceedings of these meetings. Dr. Douglass has also received research support from Questcor Pharmaceuticals to study quality care indicators for infantile spasms. Dr. Sankar has received a research grant from Pfizer, and is co-investigator in a grant from BlueBird Bio for a gene therapy treatment trial for adrenoleukodystrophy. He has served as a consultant for Lundbeck, Union Chimique Belge, Supernus, Upsher-Smith, and Acorda Therapeutics and has received speaker's fees from Union Chimique Belge, GlaxoSmithKline, Lundbeck, Supernus, and Cyberonics. Dr. Sankar also has received royalties for book authorship from CRC Press and Demos Publishers. The authors confirm that they have read the Journal's position on issues involved in ethical publication and affirm that this report is consistent with those guidelines.

AUTHORSHIP STATEMENT

Drs. Bourgeois, Douglass, and Sankar all fully qualify for authorship of the manuscript, having met author criteria recently updated and released by the International Committee of Medical Journal Editors. All of the authors were involved in drafting and critically revising the manuscript for important intellectual content, reviewed the final manuscript, and gave approval for submission. Drs. Bourgeois, Douglass, and Sankar are all accountable for all aspects of the work in ensuring that questions related to the accuracy or integrity of any part of the work are appropriately investigated and resolved.

NOTE

Members of the expert committee included John M. Pellock (co-chairman), Richmond, VA; James W. Wheless, (co-chairman) Memphis, TN; Blaise F.D. Bourgeois, Boston, MA; Laurie M. Douglass, Boston, MA; Patricia A. Gibson, Winston-Salem, NC; Tracy A. Glauser, Cincinnati, OH; Eric H.W. Kossoff, Baltimore, MD; Georgia D. Montouris, Boston, MA; Jay Salpekar, Baltimore, MD; Raman Sankar, Los Angeles, CA; W. Donald Shields, Los Angeles, CA; Christina SanInocencio, New York, NY.

REFERENCES

- Engel J Jr. A proposed diagnostic scheme for people with epileptic seizures and with epilepsy: report of the ILAE Task Force on Classification and Terminology. *Epilepsia* 2001;42:796–803.
- Panayiotopoulos C. Epileptic encephalopathies in infancy and early childhood in which the epileptiform abnormalities may contribute to

- progressive dysfunction. In Panayiotopoulos C (Ed) *The epilepsies: seizures, syndromes and management*. Oxfordshire, UK: Bladon Medical Publishing, 2005:137–206.
3. Autry AR, Trevathan E, Van Naarden BK, et al. Increased risk of death among children with Lennox-Gastaut syndrome and infantile spasms. *J Child Neurol* 2010;25:441–447.
 4. Arzimanoglou A, Resnick T. All children who experience epileptic falls do not necessarily have Lennox-Gastaut syndrome ... but many do. *Epileptic Disord* 2011;13(Suppl. 1):S3–S13.
 5. Dulac O, N'Guyen T the Lennox-Gastaut syndrome. *Epilepsia* 1993;34(Suppl. 7):S7–S17.
 6. Riikonen R. Long-term outcome of patients with West syndrome. *Brain Dev* 2001;23:683–687.
 7. van Rijckevorsel K. Treatment of Lennox-Gastaut syndrome: overview and recent findings. *Neuropsychiatr Dis Treat* 2008;4:1001–1019.
 8. Camfield PR. Definition and natural history of Lennox-Gastaut syndrome. *Epilepsia* 2011;52(Suppl. 5):3–9.
 9. Arzimanoglou A, French J, Blume WT, et al. Lennox-Gastaut syndrome: a consensus approach on diagnosis, assessment, management, and trial methodology. *Lancet Neurol* 2009;8:82–93.
 10. Livingston JH. The Lennox-Gastaut syndrome. *Dev Med Child Neurol* 1988;30:536–540.
 11. Glauser TA. Following catastrophic epilepsy patients from childhood to adulthood. *Epilepsia* 2004;45(Suppl. 5):23–26.
 12. Oguni H, Hayashi K, Osawa M. Long-term prognosis of Lennox-Gastaut syndrome. *Epilepsia* 1996;37(Suppl. 3):44–47.
 13. Hoffmann-Riem M, Diener W, Benninger C, et al. Nonconvulsive status epilepticus—a possible cause of mental retardation in patients with Lennox-Gastaut syndrome. *Neuropediatrics* 2000;31:169–174.
 14. Camfield P, Camfield C. Long-term prognosis for symptomatic (secondarily) generalized epilepsies: a population-based study. *Epilepsia* 2007;48:1128–1132.
 15. Zupanc ML. Clinical evaluation and diagnosis of severe epilepsy syndromes of early childhood. *J Child Neurol* 2009;24(8 Suppl.):6S–14S.
 16. Dravet C, Bureau M, Oguni H, et al. Severe myoclonic epilepsy in infancy: Dravet syndrome. *Adv Neurol* 2005;95:71–102.
 17. Kelley SA, Kossoff EH. Doose syndrome (myoclonic-astatic epilepsy): 40 years of progress. *Dev Med Child Neurol* 2010;52:988–993.
 18. Hahn A. Atypical benign partial epilepsy/pseudo-Lennox syndrome. *Epileptic Disord* 2000;2(Suppl. 1):S11–S17.
 19. Beaumanoir A. The Lennox-Gastaut syndrome: a personal study. *Electroencephalogr Clin Neurophysiol* 1982;35(Suppl.):85–99.