

UC Irvine

UC Irvine Previously Published Works

Title

Use of a Novel, Noninvasive Imaging System to Characterize Metabolic Changes in Subcutaneous Adipose Tissue After Cryolipolysis.

Permalink

<https://escholarship.org/uc/item/333565f1>

Journal

Dermatologic Surgery, 46(11)

ISSN

1076-0512

Authors

Juhasz, Margit

Leproux, Anais

Durkin, Amanda

et al.

Publication Date

2020-11-01

DOI

10.1097/dss.0000000000002135

Peer reviewed

Use of a Novel, Noninvasive Imaging System to Characterize Metabolic Changes in Subcutaneous Adipose Tissue After Cryolipolysis

Margit Juhasz, MD*, Anais Leproux, PhD†, Amanda Durkin†, Bruce Tromberg, PhD†, Natasha Atanaskova Mesinkovska, MD, PhD*†

*Department of Dermatology, University of California-Irvine, Irvine, California

†Beckman Laser Institute, University of California-Irvine, Irvine, California

Cryolipolysis (CoolSculpting; Allergan PLC, Madison, NJ) is a popular noninvasive body-contouring technique, with minimal side effects and downtime, approved to target subcutaneous adipose tissue in multiple areas. Each cryolipolysis cycle results in approximately 25% reduction of adipose tissue in the treated area, over a period of 3 months. Despite clinical results, only 73% of patients are satisfied with their treatment. The gradual nature and prolonged time frame to achieve desired results may affect patients' perceptions of treatment effectiveness and negatively impact satisfaction.¹

Currently, there is no reliable, noninvasive, quantitative technique to characterize adipose tissue changes after cryolipolysis. Numerous clinical trials rely on tape measures or cutometers to quantify fat loss after treatment; however, these tools are highly location-dependent and operator-dependent. High-resolution ultrasound and magnetic resonance imaging can be used to characterize changes in adipose tissue; however, they are cumbersome in the outpatient setting and have high associated costs. Given the long period over which cryolipolysis results occur and limitations of current quantitative measurements, it is difficult to monitor treatment response over time.

Diffuse optical spectroscopic imaging (DOSI) is a novel, noninvasive imaging technology that can be used to assess functional and metabolic changes in adipose tissue. The technique uses 2 parallel optical measurement modalities—frequency-domain photo migration with modulated laser sources from 50 to 500 MHz with 4 wavelengths (660, 690, 780, and 830 nm) and broadband near-infrared spectrum (NIRS) using a spectrophotometer providing 650- to 1,000-nm broadband reflectance data. Signals from the 2 modalities are combined to measure NIRS absorption and reduced scattering coefficients, thus “visualizing” metabolic tissue function. The concentrations of water, hemoglobin (oxy-, and deoxy-), and bulk lipid are calculated using known molar extinction coefficients of each component and least-squares method. Oxy- and deoxy-hemoglobin reflect the amount of tissue perfusion and oxygen consumption. Oxygen saturation can be extrapolated using the ratio of oxyhemoglobin to total hemoglobin. A tissue optical index (TOI), defined as deoxyhemoglobin x water/lipid, was also calculated as a measure for tissue metabolism and inflammation.^{2,3} We describe the first case to successfully use DOSI to monitor changes in abdominal adipose tissue after cryolipolysis.

The volunteer for the study is a 40-year-old woman with no significant medical history and no previous invasive or noninvasive body-contouring procedures. The patient was treated with cryolipolysis of the lower abdomen (CoolSculpting CoolAdvantage; 211°C, 35 minutes) followed by 2 minutes of vigorous massage. After treatment, the patient reported numbness and mild bruising at the treated site, both self-resolving over time.

Before cryolipolysis, the patient's abdomen was mapped and measured using DOSI (Figure 1). Diffuse optical spectroscopic imaging measurements were taken in a 2-by 2-cm grid pattern, over an area of 17 by 7 cm, for a total of 28 measurements. Follow-up DOSI occurred

immediately after treatment and days 7, 15, 30, 40, 60, and 75 (63 days). The DOSI data were interpolated into 2-dimensional surface images (i.e., heat maps of the treated area, Figure 1B), which shows the lipid map overlaid over a photograph of the treated region. Ultrasound measurement (HDI-5000 imaging unit; Philips Healthcare, MA) of the adipose layer pre-treatment was 48 mm, which decreased to 38 mm 60 days after treatment.

Discussion

Diffuse optical spectroscopic imaging technology has successfully imaged adipose tissue structure, blood flow, and metabolic activity in healthy and pathologic states. For example, DOSI can be beneficial to predict responses to chemotherapy in breast cancer^{3,4} and is able to characterize subcutaneous adipose tissue metabolic changes associated with calorie restriction and weight loss.²

In this report, we demonstrate that DOSI is a promising modality for monitoring treatment progress after cryolipolysis. DOSI data from each measurement session (pre-treatment, post-treatment, and days 7, 15, 30, 40, 60, and 75) were plotted using grid coordinates as a heat map, with the top-left corner of the grid representing the top-left corner of the treatment area. Pre-treatment optical signals are indicative of healthy adipose tissue with low oxy- and deoxy-hemoglobin concentrations, high lipid content, and oxygen saturation averaging in the 80% to 85% range. Immediately after treatment, there is a marked increase in the deoxyhemoglobin concentration, water content, and TOI, suggesting acute injury and inflammation of adipose tissue. Over the post-treatment recovery period, it is clear that the treated adipose tissue begins to return to normal metabolic activity, yet it does not reach the pre-treatment baseline, even at 75 days, suggesting a fundamental change has occurred in the tissue architecture and functionality (Figure 2).

The DOSI results clearly mirror those obtained by histologic analysis of subcutaneous fat postcryolipolysis, however without invasive biopsy. Histologic analysis 3 days after treatment demonstrates acute inflammation secondary to adipocyte apoptosis, which decreases by day 30. At 2 and 3 months after treatment, histology shows increased thickness of collagenous, fibrous, interlobular septa with selective removal of adipocytes in the treated area.⁵

Diffuse optical spectroscopic imaging technology may be expanded to determine efficacy not only of cryolipolysis treatment response but also for heat, mechanical, ultrasound, and radiofrequency modalities as means for targeting adipose tissue. By early monitoring of tissue response, we hope to better characterize and be able to predict patients at risk of paradoxical adipose hyperplasia. Other yields of DOSI will be to optimize clinical parameters of cryolipolysis, length of postprocedure mechanical manipulation, and use of additional adjuvant techniques to maximize clinical outcomes.

Acknowledgments B. Tromberg acknowledges support from NIH (Laser Microbeam and Medical Program, LAMMP P41-EB015890) and reports intellectual property related to DOSI technology assigned to University of California Regents. Some of these patents have been licensed to private companies, but no authors have a financial interest with these entities.

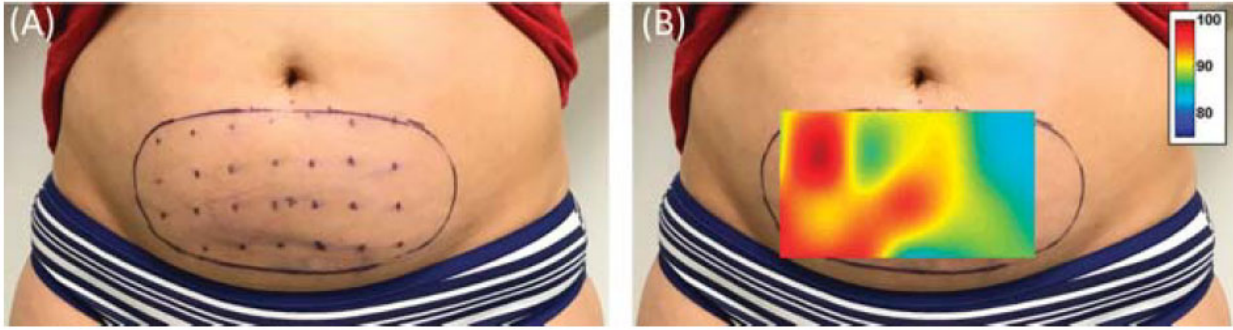


Figure 1. Cryolipolysis treatment of the abdomen. The abdomen of a 40-year-old woman treated using cryolipolysis. (A) DOSI measurements were obtained in a 2- by 2-cm grid pattern. (B) Heat map of pre-treatment lipid DOSI data overlaid over the treated area. DOSI, diffuse optical spectroscopic imaging.

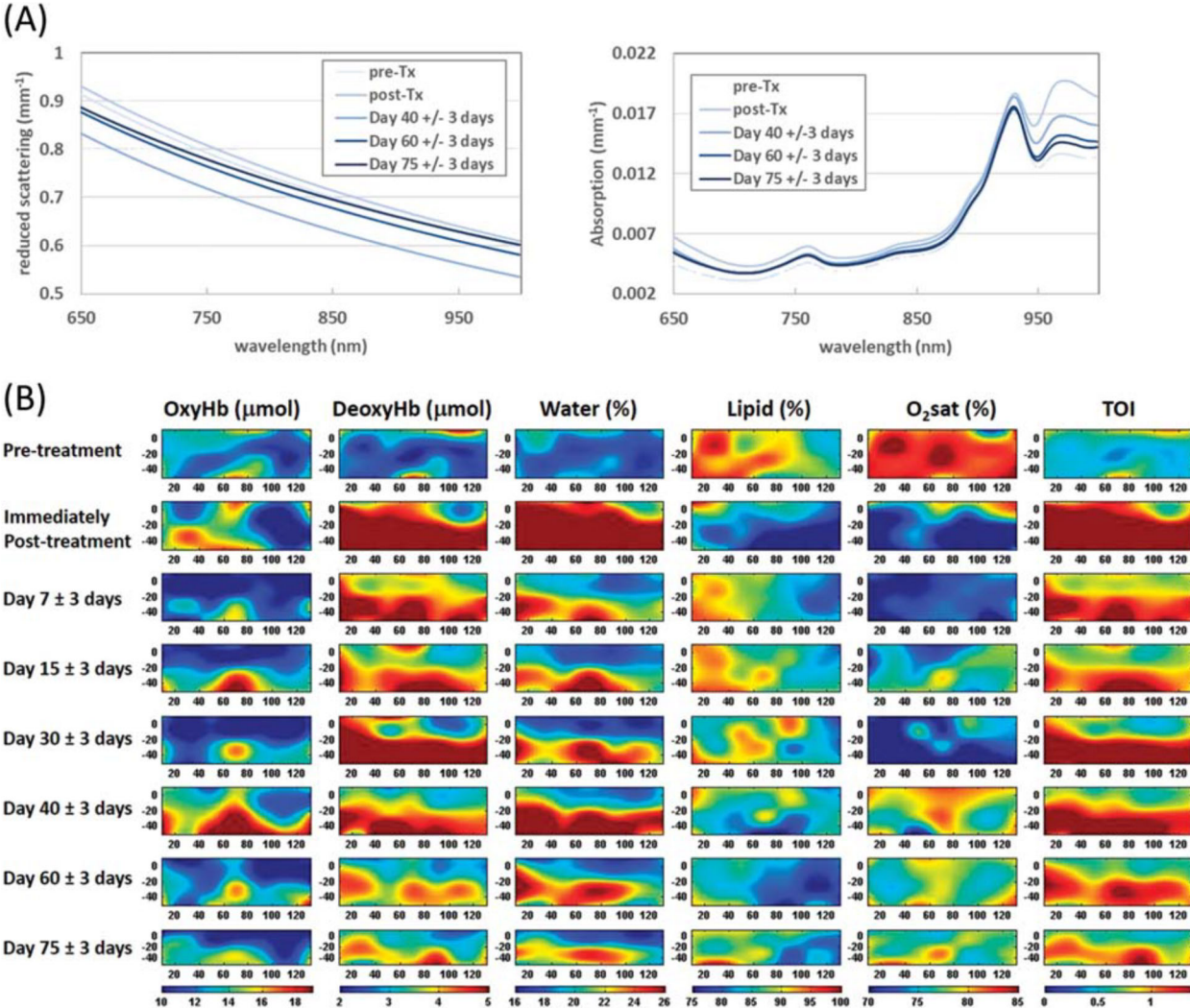


Figure 2. Heat maps, optical scattering, and absorption data obtained using DOSI. (A) Optical reduced scattering and absorption plots corresponding to the treated area, and (B) 3-dimensional heat maps with the top-left corner of each map corresponding to the top-left corner of the treated area. Pre-treatment data are characteristic of healthy adipose tissue with low oxy- and deoxy-hemoglobin concentrations, high lipid content, and 80% to 85% oxygen saturation. Post-treatment data demonstrate acute injury to the treated tissue with marked increase in deoxyhemoglobin and water content, as well as decreased oxygen saturation. Permanent changes to the tissue architecture and metabolic function occur after cryolipolysis as evidenced by the lack of return-to-baseline 75 days after treatment. DOSI, diffuse optical spectroscopic imaging.

References

1. Krueger N, Mai SV, Luebberding S, Sadick NS. Cryolipolysis for noninvasive body contouring: clinical efficacy and patient satisfaction. *Clin Cosmet Investig Dermatol* 2014;7:201–5.
2. Ganesan G, Warren RV, Leproux A, Compton M, et al. Diffuse optical spectroscopic imaging of subcutaneous adipose tissue metabolic changes during weight loss. *Int J Obes (Lond)* 2016;40:1292–300.
3. Tromberg BJ, Zhang Z, Leproux A, O’Sullivan TD, et al. Predicting responses to neoadjuvant chemotherapy in breast cancer: ACRIN 6691 trial of diffuse optical spectroscopic imaging. *Cancer Res* 2016;76:5933–44.
4. Ueda S, Roblyer D, Cerussi A, Durkin A, et al. Baseline tumor oxygen saturation correlates with a pathologic complete response in breast cancer patients undergoing neoadjuvant chemotherapy. *Cancer Res* 2012;72:4318–28.
5. Zelickson B, Egbert BM, Preciado J, Allison J, et al. Cryolipolysis for noninvasive fat cell destruction: initial results from a pig model. *Dermatol Surg* 2009;35:1462–70.

The authors have indicated no significant interest with commercial supporters.