

UCSF

UC San Francisco Previously Published Works

Title

Spinal tuberculosis: a comprehensive review for the modern spine surgeon

Permalink

<https://escholarship.org/uc/item/341641xj>

Journal

The Spine Journal, 19(11)

ISSN

1529-9430

Authors

Khanna, Krishn
Sabharwal, Sanjeev

Publication Date

2019-11-01

DOI

10.1016/j.spinee.2019.05.002

Peer reviewed

Trochanteric Entry for Femoral Lengthening Nails in Children: Is It Safe?

Ahmed I. Hammouda, MD, Julio J. Jauregui, MD, Martin G. Gesheff, BS,
Shawn C. Standard, MD, and John E. Herzenberg, MD, FRCSC

Background: Antegrade intramedullary (IM) nailing for skeletally immature femur fractures can damage the capital femoral epiphysis blood supply, leading to avascular necrosis (AVN) of the femoral head. Reported AVN rates are 2% for piriformis entry and 1.4% for trochanteric entry. None of previous reports described IM lengthening nails for limb lengthening procedures. We have used self-lengthening telescopic nails with a proximal Herzog bend and standard trochanteric entry for femoral lengthening in children. The purpose of this study is to determine whether trochanteric entry IM lengthening nails can be used safely (no AVN or proximal femoral deformity) in the skeletally immature femur.

Methods: A retrospective review was performed between 2004 and 2014 to determine all skeletally immature patients younger than 18 years of age who had a reamed IM lengthening nail inserted through the greater trochanter, with at least 1-year follow-up.

Results: Thirty-one femurs were lengthened in 28 patients (17 males and 11 females). The etiology was congenital femoral deficiency (10), achondroplasia (6), post-traumatic (5), hemihypertrophy (3), Ollier disease (2), and miscellaneous (5). An attending surgeon was present for all procedures. Mean age at time of surgery was 12.9 years (range, 7 to 17 y). Mean follow-up was 3.5 years (range, 1.4 to 9 y). The average amount of lengthening was 5.4 cm (range, 3 to 6.7 cm). Twenty-four nails were 10.7 mm in diameter. Seven nails were 12.5 mm in diameter. Intramedullary skeletal kinetic distractor was used in 18 femurs and PRECICE in 13 femurs. Ten segments (7 intra-

medullary skeletal kinetic distractor; 3 PRECICE) experienced 13 complications. None of the patients developed AVN or proximal femoral deformity.

Conclusions: IM lengthening nails inserted through the greater trochanter may be utilized in skeletally immature patients without increased risk of AVN of the femoral head or proximal femoral deformity. Larger trials would be helpful to confirm our hypothesis. We recommend careful surgical technique with liberal use of the image intensifier to avoid trauma to the femoral head blood supply.

Level of Evidence: Level IV—therapeutic.

Key Words: bone lengthening, intramedullary nail, complication, avascular necrosis, leg length discrepancy, limb lengthening

(*J Pediatr Orthop* 2017;37:258–264)

Antegrade intramedullary (IM) nailing has been established as the gold standard treatment for diaphyseal femoral fractures in the adult population. However, in skeletally immature children the fear of damaging the proximal femoral blood supply and growth plate of the greater trochanter (GT) has aroused debate regarding its use.¹ Using the piriformis fossa as the entry point for fracture IM nails in children has been associated with avascular necrosis (AVN) of the femoral head secondary to blood supply disruption.^{2–4} The primary femoral head blood supply is from the medial femoral circumflex artery. Branches of this artery enter the capsule at the level of superior gemellus muscle and then course proximally along the femoral neck toward the head, which can be easily violated (Fig. 1).⁵ Therefore, attempts to reduce the incidence of AVN of the femoral head have been made by inserting fracture nails through the tip of the GT or slightly lateral to that point to be in a “safe zone” away from the femoral head blood supply.

Over the last decade, lengthening procedures in skeletally immature patients have increased in patients with congenital, developmental, metabolic, or post-traumatic growth arrest.⁶ Multiple techniques and devices have been developed and utilized for these lengthening procedures. However, in selected patients, newer generations of IM lengthening devices provide both surgeons and patients with a more comfortable alternative when compared with external fixators.⁷

We have utilized this technique at our institution for IM lengthening nails in children.⁸ We hypothesize that

From the International Center for Limb Lengthening, Rubin Institute for Advanced Orthopedics, Sinai Hospital of Baltimore, Baltimore, MD.

Study performed at Sinai Hospital, Baltimore, MD.

This study and manuscript were performed without external funding.

S.C.S.: Consultant for as well as royalties and stock options from Ellipse Technologies, Inc. Royalties from Pega Medical. J.E.H.: Research support from Ellipse Technologies, Inc. and consultant for Orthopediatrics. The following companies supported A.I.H.'s, J.J.J.'s, M.G.G.'s, S.C.S.'s, and J.E.H.'s institution's annual course for orthopaedic surgeons: Smith & Nephew; Ellipse Technologies; Stryker; Brainlab; Depuy Synthes; Orthofix; Biomet; KCI; Orthopediatrics; OHK Medical Devices; and The MHE Coalition. The following companies supported A.I.H.'s, J.J.J.'s, M.G.G.'s, S.C.S.'s, and J.E.H.'s institution's nonprofit organization, which provides financial assistance to their patients: Stryker; Orthocare Solutions; and Metro Prosthetics.

Reprints: John E. Herzenberg, MD, FRCSC, Rubin Institute for Advanced Orthopedics, Sinai Hospital of Baltimore, 2401 West Belvedere Avenue, Baltimore, MD 21215. E-mail: jherzenberg@lifebridgehealth.org.

Copyright © 2017 Wolters Kluwer Health, Inc. All rights reserved.

DOI: 10.1097/BPO.0000000000000636

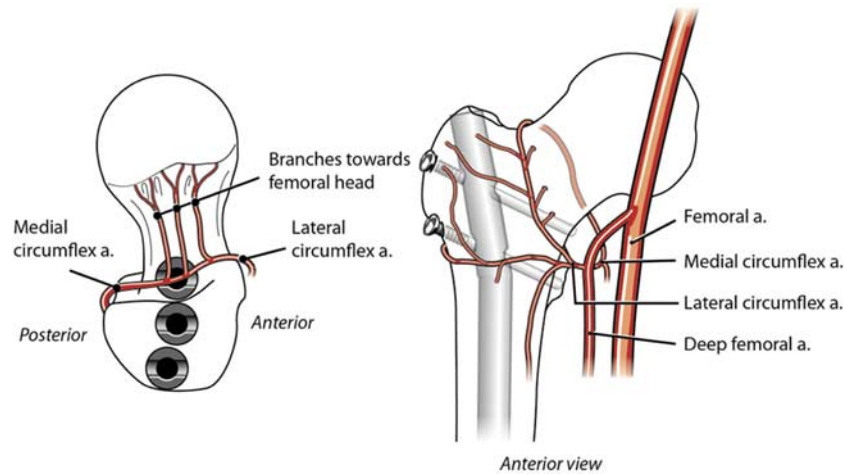


FIGURE 1. Proximal femoral anatomy (superior and anterior views) showing its blood supply relative to femoral nailing. Note the proximity of the piriformis entry point with the proximal femoral vascularity. The greater trochanteric tip or its lateral aspect is anatomically safe relative to this delicate blood supply. Reprinted with permission from Sinai Hospital of Baltimore. Copyright 2015, Rubin Institute for Advanced Orthopedics, Sinai Hospital of Baltimore, Baltimore, MD. All permission requests for this image should be made to the copyright holder.

pediatric patients undergoing femoral lengthening through the GT approach would not develop AVN of the femoral head. Therefore, the purpose of this study is to investigate the safety (in terms of possible femoral head AVN or creation of proximal femoral deformity) of lengthening skeletally immature femurs with 2 types of IM lengthening nails inserted through the lateral aspect of the GT. These 2 nails are the intramedullary skeletal kinetic distractor (ISKD; Orthofix, Lewisville, TX) and the PRECICE (Ellipse Technologies Inc., Irvine, CA).

METHODS

After obtaining institution review board approval, a retrospective review of a prospectively collected database was performed to identify patients who were younger than 18 years of age, underwent IM femoral lengthening using the ISKD or the PRECICE nail, and had at least 1-year follow-up. Radiographs were evaluated on all patients to confirm presence of an open growth plate at the time of surgery.

A total of 98 consecutive femoral segment lengthenings were initially identified. Thirty-one skeletally immature femurs fit the inclusion criteria in 28 patients (17 males and 11 females) and were included in the final analysis. Two of these patients have been previously reported by Shabtai et al.⁸ In this cohort, patients underwent lengthening with the ISKD nail (18 segments) or the PRECICE nail (13 segments) inserted through the lateral aspect of the GT. For the ISKD group, tibial nails were used in an off label manner, because the manufacturer does not produce the ISKD for the femur with a trochanteric entry Herzog bend. This use of a tibial nail for trochanteric femur entry requires that the proximal locking screws are oblique and the distal locking screws are anteroposterior (AP).

The mean age at index surgery was 12.9 years (range, 7 to 17y). Patients had short femurs due to different etiologies (Table 1). Most of the patients underwent several previous complex procedures for joint reconstruction and limb lengthening. Mean follow-up for both groups was 3.5 years (range, 1.4 to 9y). For the ISKD group, the mean follow-up was 4.6 years (range, 1.4 to 9y), whereas for the PRECICE group, it was 1.9 years (range, 1.4 to 3y).

Statistical analyses were performed with the aid of a statistical software, Graph Pad Prism version 5.01 (GraphPad Software Inc., La Jolla, CA), utilizing either a Student *t* test or a Wilcoxon signed-rank test for continuous data. Proportional data were compared with Fisher exact test. A *P* value of <0.05 was considered significant.

TABLE 1. Patient Demographics and Etiology

	ISKD (n = 18 Segments)	PRECICE (n = 13 Segments)	<i>P</i>
Age (y) (range)	14 (11-17)	11.6 (7-16)	0.002
Male/female	11/7	9/4	1.00
Etiology			
CFD/FH	3	7	
Achondroplasia	2	4	
Hemihypertrophy	3	0	
Ollier disease	1	1	
Fibrous dysplasia	1	0	
OI	1	0	
Post-traumatic	4	1	
Developmental	1	0	
Congenital (others)	2	0	

CFD indicates congenital femoral deficiency; FH, fibular hemimelia; ISKD, intramedullary skeletal kinetic distractor; OI, osteogenesis imperfecta.

Operative Technique

A lateral 1-cm incision is then performed at the level of the planned osteotomy site, and the soft tissues are gently spread down to the bone. The periosteum is raised with a small periosteal elevator anteriorly, laterally, and posteriorly. Multiple drill holes are then created at this level using a 4.8-mm drill bit to vent the IM canal. Venting the canal before reaming has the advantage of prophylaxis against increased IM pressure and fat embolism.^{9,10} In addition, bone swarf from the reaming exits through the vent holes and provides natural autograft at the level of the osteotomy, which may improve the quality of the regenerate bone healing.

The image intensifier is used in AP and lateral projections to carefully identify the starting point. This depends on the design of the nail (the diameter and the degree of its proximal bend) and on the patient-specific anatomy. On the basis of that, the entry point can be at the tip of the GT or 2 to 5 mm lateral to it. This ensures entry into a safe zone without the risk of being medial to

the GT (to avoid blood supply) or far lateral (to avoid iatrogenic fracture of the lateral cortex). We start by inserting a 1.8-mm K-wire under biplanar image intensifier control through the skin, down to the bone to determine the best trajectory and to identify the best skin incision site. Next, we open the skin (2 cm) and dissect with a straight hemostat down to the entry point, again checking carefully with the image intensifier. Next, insert a 2.4-mm Steinmann pin (Key Surgical, Minneapolis, MN) under biplanar image intensifier control, and then ream over the Steinmann pin with an 8 mm anterior cruciate ligament reamer to a depth of 4 to 5 cm. A 3 mm beaded guide wire is then inserted into the canal and withdrawn up to the level of intended osteotomy. Great care must be taken to avoid multiple uncontrolled insertion attempts with the wires and Steinmann pins, so as to prevent injury to the blood supply of the capital femoral epiphysis (Fig. 2).

Reaming the IM canal is initiated with an 8 mm flexible reamer and then increased by 0.5 mm increments to reach 12.5 mm for the 10.7 mm nails and 14.5 mm for

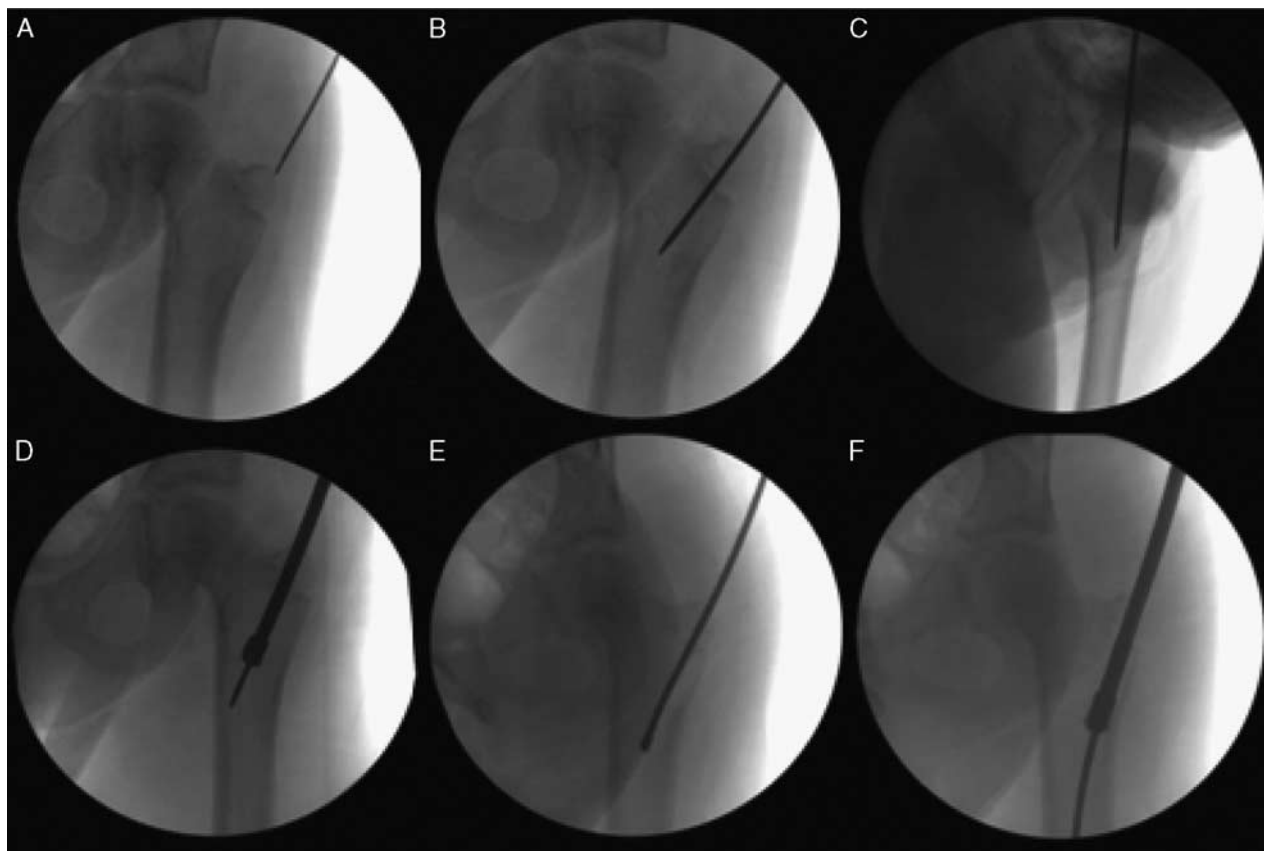


FIGURE 2. A-F, Image demonstrates the technique for identifying the entry point step by step using the C-arm. A, A 1.8-mm K-wire over the tip of the greater trochanter (GT). B and C, A 2.4-mm Steinmann pin advancement from the tip of the GT and through the center of the medulla in anteroposterior and lateral views. D, Opening the canal by using 8 mm anterior cruciate ligament rigid reamer over the Steinmann pin. E, Insertion of 3 mm beaded guide pin through the intramedullary (IM) canal. F, Reaming the canal using flexible IM reamers over the guide pin. Reprinted with permission from Sinai Hospital of Baltimore. Copyright 2015, Rubin Institute for Advanced Orthopedics, Sinai Hospital of Baltimore, Baltimore, MD. All permission requests for this image should be made to the copyright holder.

the 12.5 mm nails. The proper nail is then inserted into the medullary canal down to the level of osteotomy. Occasionally, it is necessary to ream the proximal segment 2.5 mm more than the nail diameter to enable it to pass easily. An osteotome is used to complete the osteotomy, and the nail is advanced across the osteotomy into the distal femur. The nail is then locked proximally and distally. The nails are tested intraoperatively by lengthening 1 to 2 mm before closing the wounds.

Postoperative Care

Patients began distraction on the fifth to sixth day postoperatively, at an approximate rate of 1 mm/d. In the ISKD cohort, distraction was achieved mechanically by cyclically rotating the extended lower limb. In the PRECICE cohort, distraction was performed using rotating magnetic fields generated from the external remote control device placed on the skin at the level of the magnet inside the nail. Radiographs were obtained every 2 weeks after distraction to assess the quality of the regenerate bone and control the distraction rate. All patients received regular active and passive physiotherapy to prevent hip or knee

subluxation, soft tissue contractures, and to maintain normal joint mobility. All patients were allowed partial weight-bearing (approximately 20 kg). When they reached regenerate consolidation in 3 of 4 cortices, they progressed to full weight-bearing.

RESULTS

All of the patients achieved lengthening with a mean of 5.4 cm (range, 3 to 6.7 cm). ISKD group achieved the mean lengthening of 5.2 cm (range, 3.8 to 6.5 cm), whereas the PRECICE group achieved the mean of 5.6 cm (range, 3 to 6.7 cm) (Figs. 3, 4). No significant difference was observed between both groups in the lengthening achieved ($P = 0.35$) (Table 2).

All patients demonstrated normal radiographic appearance of the femoral head throughout the follow-up time period. No radiographic or clinical evidence of femoral head AVN or coxa valga occurred in the study group. A total of 13 complications (42%) occurred in 10 of the total 31 segments lengthened in this study. Seven of 18 ISKD segments (39%) and 3 of 13 PRECICE segments (23%) experienced complications (Table 3). The

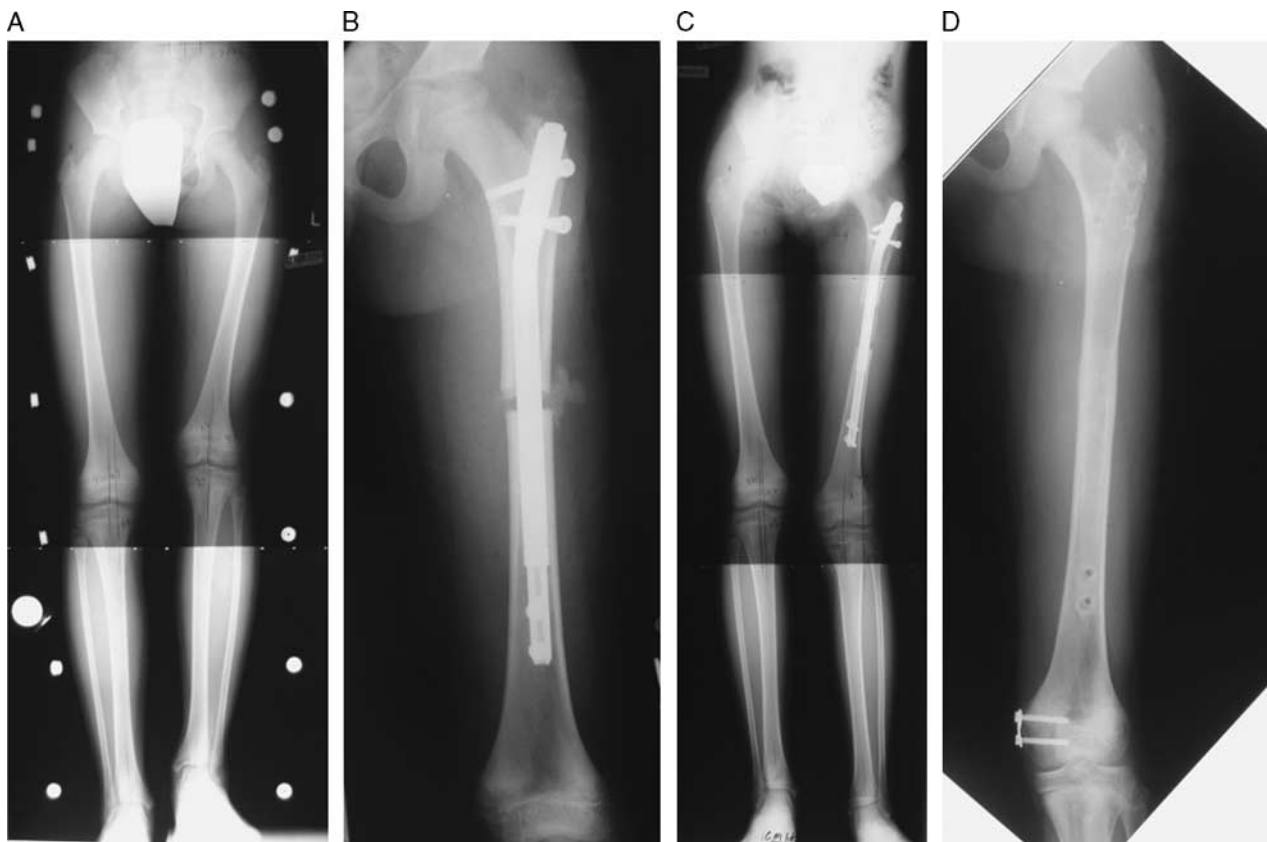


FIGURE 3. A-D, Eleven-year-old boy with left-sided congenital femoral deficiency. A, Preoperative limb length discrepancy of 3.7 cm. B, Immediate postoperative radiograph shows an ISKD inserted in the left femur through the greater trochanter. Notice the natural bone graft at the osteotomy site supplied from the reamed canal after venting. C, Lengthening completed 2 months after surgery. D, Regenerate healing and nail removal 15 months after initial surgery. The length achieved was 4.1 cm. An 8-plate was inserted on the medial distal femur to gradually correct valgus deformity. Reprinted with permission from Sinai Hospital of Baltimore. Copyright 2015, Rubin Institute for Advanced Orthopedics, Sinai Hospital of Baltimore, Baltimore, MD. All permission requests for this image should be made to the copyright holder.

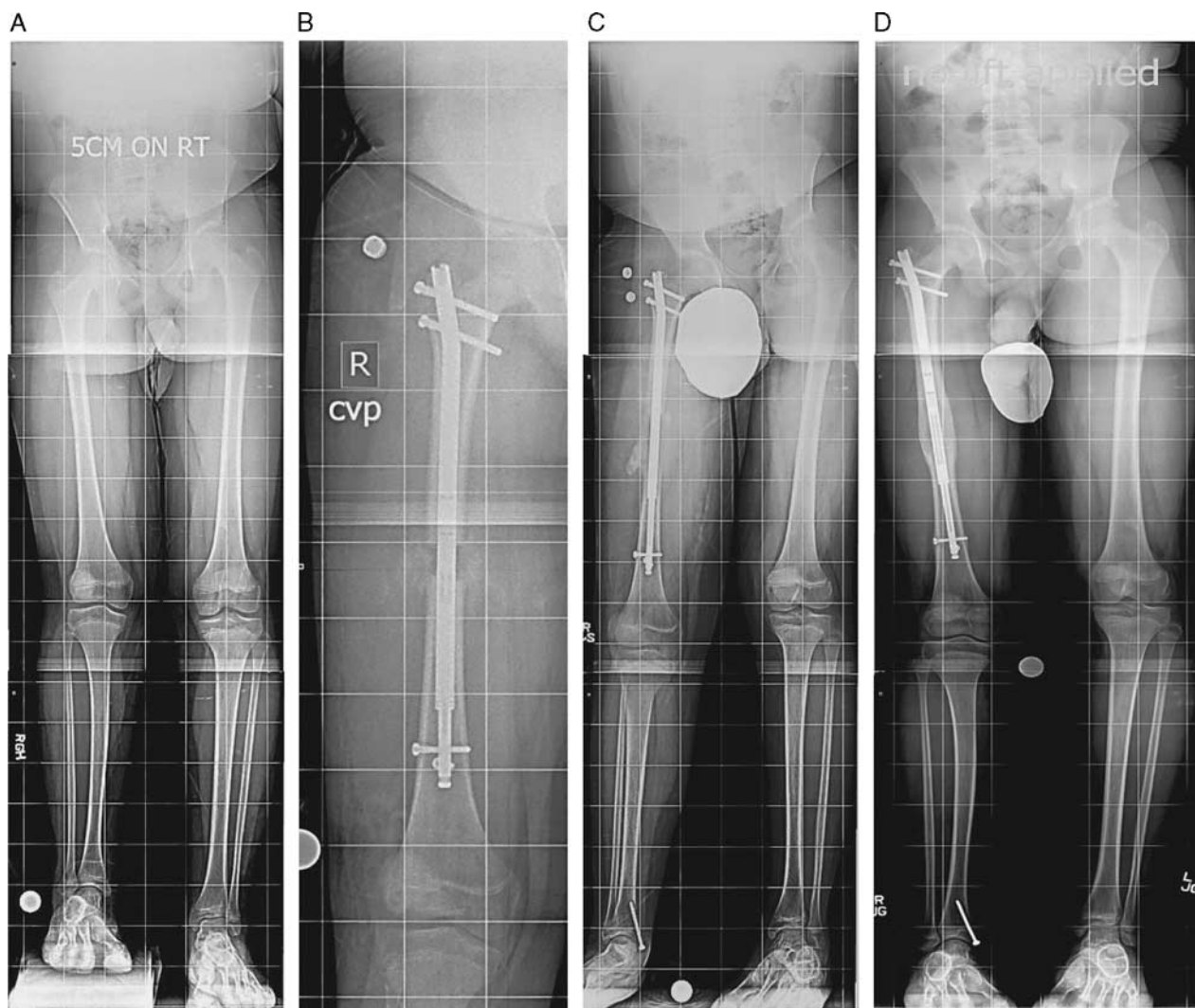


FIGURE 4. A-D, Eleven-year-old boy with right-sided congenital femoral deficiency and fibular hemimelia. A, Preoperative limb length discrepancy of 5.5 cm. B, Early radiograph depicting 1.8 cm lengthening with the PRECICE nail inserted in the right femur through the greater trochanter. Notice the natural bone graft at the osteotomy site supplied from the reamed medullary canal after venting. C, Lengthening completed 2 months after surgery. D, After regenerate healing and complete consolidation. The length achieved was 5.5 cm. Additional lengthening procedure for the right tibia will be performed in the future to achieve equal limb lengths. Reprinted with permission from Sinai Hospital of Baltimore. Copyright 2015, Rubin Institute for Advanced Orthopedics, Sinai Hospital of Baltimore, Baltimore, MD. All permission requests for this image should be made to the copyright holder.

difference between the complication rates in both groups was not significant ($P = 0.45$). Two segments (one in each group) developed more than one complication. One segment in the ISKD group developed a knee flexion contracture and subluxation; this was successfully managed with physiotherapy. The same patient was also treated for regenerate nonunion with bone grafting and nail exchanging 8 months after the index surgery. One segment in the PRECICE group developed hip subluxation and delayed union of the regenerate, which was treated by ligamentum teres reconstruction, regenerate grafting, and nail exchange 6 months after the index surgery. Delayed union occurred in 5 ISKD and 1 PRECICE segments.

Two segments (1 in each group) required re-osteotomy of the regenerate bone due to premature consolidation. However, the PRECICE segment achieved a final length 6 mm shorter than the lengthening goal due to a complete shutdown of the nail mechanism.

DISCUSSION

Skeletally immature patients might present with limb length discrepancy or short stature due to many etiologies including congenital, developmental, post-traumatic, or postinfectious. Many different treatment options have been described to achieve the goal of equal

TABLE 2. Results

	ISKD (n = 18 Segments)	PRECICE (n = 13 Segments)	P
Diameter of the nail (mm)			
10.7 (n)	11	13	—
12.5 (n)	7	0	
Follow-up mean (y) (range)	4.6 (1.4-9)	1.9 (1.4-3)	
Lengthening achieved mean (cm) (range)	5.2 (3.8-6.5)	5.6 (3-6.7)	0.35

ISKD indicates intramedullary skeletal kinetic distractor.

limbs or taller stature. Many patients with congenital or developmental causes of limb length discrepancy may be managed during childhood to successfully correct deformities and achieve satisfactory limb equality. External fixation has been widely used to treat these patients. However, due to their well-known complications, external fixators are being used less frequently in favor of internally lengthening nails whenever feasible.¹¹

There are multiple limitations in our study. The first major limitation is that this study was performed retrospectively in a limited patient population. This study is not adequately powered to definitively prove that AVN is not a risk with this type of procedure. A multicenter trial incorporating a much larger cohort would be required to make these assumptions. Also, all of our cases were performed in a high-volume specialized institution, making the reproducibility of our outcomes potentially difficult at other low-volume hospitals. Nevertheless, if the surgical technique is followed accurately, we believe that other institutions may have similar results. In addition, although our follow-up is relatively short, we feel that a minimum follow-up of 1 year should allow us to detect any case of AVN. Despite these limitations, our cohort of femoral lengthening with IM nails inserted through the lateral aspect of the GT in skeletally immature patients is the largest reported in the current literature.

To date, there is still a debate as to whether using antegrade IM nails to fix adolescent femoral fractures is accompanied by a high risk of interrupting proximal femoral blood supply.^{12,13} MacNeil et al³ systematically evaluated the management of femoral shaft fractures in pediatric patients. In this review, the authors described fewer cases of AVN of the femoral head when inserting

nails through the GT than when using the piriformis fossa as the entry point (1.4% vs. 2% cases of AVN, respectively). They also concluded that no cases of AVN were observed when utilizing the lateral aspect of the GT as the entry site. In a retrospective study, Keeler et al¹⁴ assessed the treatment of 80 pediatric femoral shaft fractures and concluded that no patient developed osteonecrosis of the femoral head because all were treated with IM nails inserted through the lateral aspect of the GT. However, Stans et al¹⁵ had a 7.5% rate of AVN of the femoral head 6 months after IM rod insertion through the GT when managing femoral fractures in adolescent (1 of 13 fractures). Others reported AVN femoral head occurrence when nails were inserted through the piriformis fossa.^{2,4,16,17}

When comparing fracture nailing with intramedullary nail lengthening, the risk of AVN may be theoretically higher in lengthening, as there is additional pressure on the hip and knee joint during the lengthening process. Only 1 article, by Gordon et al⁶ in 2002, described lengthening preadolescent femurs (n = 9) using monolateral external fixator over a humeral IM nail inserted through the GT without cases of AVN of the femoral head. Currently, to the best of our knowledge, no other study has evaluated whether lengthening in skeletally immature femurs with antegrade IM nails is safe to be done without hazardous complications to proximal femoral blood supply or its growth plate.

González-Herranz et al¹⁸ recommended not using IM nailing in children younger than 13 years to avoid proximal growth plate damage. They observed a significant difference in the cervico-diaphyseal angle when patients older than 13 years of age (n = 9) were compared with a group of patients younger than 13 years (n = 25; P < 0.05). An increased cervico-diaphyseal angle between 10 and 25 degrees (when compared with the angle of the normal hip) in 10 of 34 patients (30%) was also reported. In contrast, Green et al¹² concluded that the use of IM nails in children older than 10 years is safe. We did not observe proximal femoral growth abnormalities in our cases despite the fact that we inserted the nails through the lateral aspect of the GT. This might be due to the fact that insertion through the lateral tip of the GT hypothetically avoids disturbance of the proximal femoral growth plate.¹⁹ It allows continued growth of the femoral neck isthmus and avoids valgus deformity or femoral neck narrowing.¹⁵ Growth of the proximal femur is not affected by closure of the GT apophysis since its growth is commonly appositional once the patient reaches 8 years of age.²⁰

The complication rate of the ISKD cohort (39%) was greater than in the PRECICE cohort (23%); however, it did not achieve significance (P = 0.45). Most of the ISKD complications (6 of 8 ISKD complications) were delayed union and nonunion related to the inaccurate mechanical distraction. This is in agreement with published studies confirming high rates of mechanical failure of the ISKD nail.²¹⁻²⁴ Kenaway et al²⁵ reported a high uncontrollable distraction rate in 8 of 35 (23%) patients in their study of femoral lengthening using the

TABLE 3. Complications

	ISKD (n = 18 Segments)	PRECICE (n = 13 Segments)	P
Complication rate (no. segments)	39% (7/18)	23% (3/13)	0.45
Subluxation	1 (knee)	1 (hip)	1.0
Delayed union	5	2	0.67
Nonunion	1	0	1.0
Premature consolidation	1	1	1.0
Rod failure	0	1	0.42

ISKD indicates intramedullary skeletal kinetic distractor.

ISKD nail. Moreover, once the ISKD had been pre-operatively programmed to the desired amount of lengthening, it was impossible to change. Compression is not possible with the ISKD. Mechanical control over the ISKD (through rotating the limb) is much more difficult than the accurate magnetic control of the PRECICE nail (by using the external remote control). Furthermore, the PRECICE nail is fully reversible, making it more versatile in treating delayed healing. In contrast, only 2 of 4 PRECICE complications were delayed union. Complete shutdown of the nail mechanism occurred in another patient who was treated for premature consolidation. Shabtai et al,⁸ in their series of 26 PRECICE nails for 24 patients, reported 4 implant-related complications. Two nails initially failed to function and had to be exchanged, and another 2 nails broke during the consolidation phase.

CONCLUSIONS

We conclude that using IM lengthening nails inserted either through the tip or the lateral aspect of the GT in skeletally immature femurs can be safe. None of the patients in our cohort developed femoral head AVN or proximal valgus deformity. However, extreme care should be taken to avoid injury of the blood supply when attempting to identify the entry point and during the reaming process. This part of the procedure should be performed by or at least very carefully supervised by the attending surgeon.

REFERENCES

1. Beaty JH, Austin SM, Warner WC, et al. Interlocking intramedullary nailing of femoral-shaft fractures in adolescents: preliminary results and complications. *J Pediatr Orthop*. 1994;14:178–183.
2. O'Malley DE, Mazur JM, Cummings RJ. Femoral head avascular necrosis associated with intramedullary nailing in an adolescent. *J Pediatr Orthop*. 1995;15:21–23.
3. MacNeil JA, Francis A, El-Hawary R. A systematic review of rigid, locked, intramedullary nail insertion sites and avascular necrosis of the femoral head in the skeletally immature. *J Pediatr Orthop*. 2011;31:377–380.
4. Buford D Jr, Christensen K, Weatherall P. Intramedullary nailing of femoral fractures in adolescents. *Clin Orthop*. 1998;350:85–89.
5. Gautier E, Ganz K, Krügel N, et al. Anatomy of the medial femoral circumflex artery and its surgical implications. *J Bone Joint Surg Br*. 2000;82:679–683.
6. Gordon JE, Goldfarb CA, Luhmann SJ, et al. Femoral lengthening over a humeral intramedullary nail in preadolescent children. *J Bone Joint Surg Am*. 2002;84-A:930–937.
7. Rozbruch SR, Birch JG, Dahl MT, et al. Motorized intramedullary nail for management of limb-length discrepancy and deformity. *J Am Acad Orthop Surg*. 2014;22:403–409.
8. Shabtai L, Specht SC, Standard SC, et al. Internal lengthening device for congenital femoral deficiency and fibular hemimelia. *Clin Orthop Relat Res*. 2014;472:3860–3868.
9. Dalgorf D, Borkhoff CM, Stephen DJ, et al. Venting during prophylactic nailing for femoral metastases: current orthopedic practice. *Can J Surg*. 2003;46:427–431.
10. Matuszewski PE, Herzenberg JE. Derotational osteotomies utilizing a trochanteric-start intramedullary nail. *J Pediatr Orthop B*. 2015;24:274–275.
11. Silberg ET, Goulet JA, Greenfield ML. Femoral lengthening: conventional Ilizarov technique compared to lengthening over an intramedullary rod. *Orthop Trans*. 1997;21:71.
12. Green N, Letts M, Stanitski CL, et al. Debate: a healthy 12-year-old boy with an isolated mid-diaphyseal femur fracture should be treated with an antegrade, locked, intramedullary rod. *J Pediatr Orthop*. 2002;22:821–826.
13. Angadi DS, Shepherd DE, Vadivelu R, et al. Rigid intramedullary nail fixation of femoral fractures in adolescents: what evidence is available? *J Orthop Traumatol*. 2014;15:147–153.
14. Keeler KA, Dart B, Luhmann SJ, et al. Antegrade intramedullary nailing of pediatric femoral fractures using an interlocking pediatric femoral nail and a lateral trochanteric entry point. *J Pediatr Orthop*. 2009;29:345–351.
15. Stans AA, Morrissy RT, Renwick SE. Femoral shaft fracture treatment in patients age 6 to 16 years. *J Pediatr Orthop*. 1999;19:222–228.
16. Mileski R, Garvin K, Crosby L. Avascular necrosis of the femoral head in an adolescent following intramedullary nailing of the femur. A case report. *J Bone Joint Surg Am*. 1994;76:1706–1708.
17. Mileski RA, Garvin KL, Huurman WW. Avascular necrosis of the femoral head after closed intramedullary shortening in an adolescent. *J Pediatr Orthop*. 1995;15:24–26.
18. González-Herranz P, Burgos-Flores J, Rapariz JM, et al. Intramedullary nailing of the femur in children. Effects on its proximal end. *J Bone Joint Surg Br*. 1995;77:262–266.
19. Gordon JE, Khanna N, Luhmann SJ, et al. Intramedullary nailing of femoral fractures in children through the lateral aspect of the greater trochanter using a modified rigid humeral intramedullary nail: preliminary results of a new technique in 15 children. *J Orthop Trauma*. 2004;18:416–422.
20. Gage JR, Cary JM. The effects of trochanteric epiphysiodesis on growth of the proximal end of the femur following necrosis of the capital femoral epiphysis. *J Bone Joint Surg Am*. 1980;62:785–794.
21. Schiedel FM, Pip S, Wacker S, et al. Intramedullary limb lengthening with the Intramedullary Skeletal Kinetic Distractor in the lower limb. *J Bone Joint Surg Br*. 2011;93:788–792.
22. Simpson AH, Shalaby H, Keenan G. Femoral lengthening with the Intramedullary Skeletal Kinetic Distractor. *J Bone Joint Surg Br*. 2009;91:955–961.
23. Kubiak EN, Strauss E, Grant A, et al. Early complications encountered using a self-lengthening intramedullary nail for the correction of limb length inequality [in Turkish]. *Joint Dis Rel Surg*. 2007;18:52–57.
24. Burghardt RD, Herzenberg JE, Specht SC, et al. Mechanical failure of the Intramedullary Skeletal Kinetic Distractor in limb lengthening. *J Bone Joint Surg Br*. 2011;93:639–643.
25. Kenaway M, Krettek C, Lioudakis E, et al. Insufficient bone regenerate after intramedullary femoral lengthening: risk factors and classification system. *Clin Orthop Relat Res*. 2011;469:264–273.