UC Irvine
UC Irvine Previously Published Works

## Title

Prediction of the early recurrence in spinal giant cell tumor of bone using radiomics of preoperative CT: Long-term outcome of 62 consecutive patients

## Permalink

https://escholarship.org/uc/item/38s187m8

## Authors

Wang, Qizheng
Zhang, Yang
Zhang, Enlong
et al.

## Publication Date

2021-04-01

## DOI

10.1016/j.jbo.2021.100354

Peer reviewed

eScholarship.org Powered by the California Digital Library
University of California

Journal of Bone Oncology 27 (2021) 100354

Contents lists available at ScienceDirect

Journal of Bone Oncology

journal homepage: www.elsevier.com/locate/jbo

# Prediction of the early recurrence in spinal giant cell tumor of bone using radiomics of preoperative CT: Long-term outcome of 62 consecutive patients

Qizheng Wang [a], Yang Zhang [b,c], Enlong Zhang [d], Xiaoying Xing [a], Yongye Chen [a], Min-Ying Su [b,e,*], Ning Lang [a,*]

[a] Department of Radiology, Peking University Third Hospital, 49 North Garden Road, Haidian District, Beijing 100191, China
[b] 164 Irvine Hall, Center for Functional Onco-Imaging, University of California, Irvine, CA 92697-5020, USA
[c] Department of Radiation Oncology, Rutgers-Cancer Institute of New Jersey, Robert Wood Johnson Medical School, New Brunswick, NJ, United States
[d] Department of Radiology, Peking University International Hospital, Life Park Road No.1 Life Science Park of Zhong Guancun, Chang Ping District, Beijing 100191, China
[e] Department of Medical Imaging and Radiological Sciences, Kaohsiung Medical University, Kaohsiung, Taiwan

ARTICLE INFO

*Article history:*
Received 5 November 2020
Revised 26 February 2021
Accepted 28 February 2021
Available online 16 March 2021

*Keywords:*
Radiomics
CT texture analysis
Spine
Giant cell tumor of bone
Prognosis

ABSTRACT

*Objectives:* To determine if radiomics analysis based on preoperative computed tomography (CT) can predict early postoperative recurrence of giant cell tumor of bone (GCTB) in the spine.
*Methods:* In a retrospective review, 62 patients with pathologically confirmed spinal GCTB from March 2008 to February 2018, with a minimum follow-up of 24 months, were identified. The mean follow-up was 73.7 months (range, 28.7–152.1 months). The clinical information including age, gender, lesion location, multi-vertebral involvement, and surgical methods, were obtained. CT images acquired before the operation were retrieved for radiomics analysis. For each case, the tumor regions of interest (ROI) was manually outlined, and a total of 107 radiomics features were extracted. The features were selected via the sequential selection process by using the support vector machine (SVM), then used to construct classification models with Gaussian kernels. The differentiation between recurrence and non-recurrence groups was evaluated by ROC analysis, using 10-fold cross-validation.
*Results:* Of the 62 patients, 17 had recurrence with a recurrence rate of 27.4%. None of the clinical information was significantly different between the two groups. Patients receiving curettage had a higher recurrence rate (6/16 = 37.5%) compared to patients receiving TES (6/26 = 23.1%) or intralesional spondylectomy (5/20 = 25%). The final radiomics model was built using 10 selected features, which achieved an accuracy of 89% with AUC of 0.78.
*Conclusions:* The radiomics model developed based on pre-operative CT can achieve a high accuracy to predict the recurrence of spinal GCTB. Patients who have a high risk of early recurrence should be treated more aggressively to minimize recurrence.
© 2021 The Authors. Published by Elsevier GmbH. This is an open access article under the CC BY-NC-ND license (http://creativecommons.org/licenses/by-nc-nd/4.0/).

## 1. Introduction

The giant cell tumor of bone (GCTB) is generally considered a benign tumor that rarely metastasizes. According to the 5th edition of the 2020 World Health Organization (WHO) classification of soft tissue and bone tumors, GCTB is classified as lesions with intermediate behavior and locoregional aggressiveness, but has potential for distant metastasis [1]. Most bone GCTB occurs in the epiphysis or metaphysis of long bones, while the occurrence in the spine is relatively rare [2,3].

Because spinal GCTB is adjacent to large vessels and neurological structures, performing extensive surgery, such as total en bloc

*Abbreviations:* CT, Computed Tomography; DICOM, Digital Imaging and Communications in Medicine; GCTB, Giant Cell Tumor of Bone; GLCM, Gray Level Co-occurrence Matrix; GLDM, Gray Level Dependence Matrix; GLRLM, Gray Level Run Length Matrix; GLSZM, Gray Level Size Zone Matrix; MRI, Magnetic Resonance Imaging; NGTDM, Neighborhood Gray Tone Difference Matrix; OPG, Osteoprotegerin; PACS, Picture Archiving and Communication System; RANK, Receptor Activator of Nuclear factor Kappa-B; RANKL, Receptor Activator of Nuclear factor Kappa-B Ligand; ROC, Receiver Operating Characteristic; ROI, Regions of Interest; SVM, Support Vector Machine.

* Corresponding author.
*E-mail addresses:* wangqizheng96@163.com (Q. Wang), yangz17@uci.edu (Y. Zhang), enlongzhang@qq.com (E. Zhang), xingxiaoying221@163.com (X. Xing), chenyongye1995@163.com (Y. Chen), msu@uci.edu (M.-Y. Su), langning800129@126.com (N. Lang).

https://doi.org/10.1016/j.jbo.2021.100354
2212-1374/© 2021 The Authors. Published by Elsevier GmbH.
This is an open access article under the CC BY-NC-ND license (http://creativecommons.org/licenses/by-nc-nd/4.0/).

spondylectomy (TES), is challenging and may lead to significant morbidity after surgery [4]. TES involves the removal of entire vertebrae and posterior elements. Although studies have reported favorably low recurrence rates, the procedure carries risks of complications such as neurological deficit, instrumentation failure, postoperative cerebrospinal fluid leakage, etc [5,6]. As the strict en bloc resection is often not feasible for the cervical spine due to the presence of vital structures surrounding the lesion, the less aggressive intralesional spondylectomy and curettage provide alternative options, and they may also achieve a satisfactory prognosis [7].

Some studies have shown that recurrence after surgery cannot be entirely attributed to the residual disease that is not completely resected. The aggressiveness of the tumor based on molecular biomarkers and gene expressions, e.g. Ki-67, P53, RANK/RANKL/OPG, etc., may help predict GCTB patients with higher risk of recurrence [8–11]. If the possibility of recurrence can be predicted before surgery, it will help choose the optimal treatment between performing an aggressive resection of tumorous tissue and maintaining a good quality of life after surgery. Patients with high risk of recurrence should consider more aggressive surgical methods (possibly combined with adjuvant therapy) to achieve a better prognosis. On the other hand, patients with low risk of recurrence do not need extensive surgical resection and should rather focus on a good functional outcome without neurological complications.

In the traditional evaluation of preoperative imaging, features such as cystic change, adjacent soft tissue invasion, and "paint brush borders" sign, are considered poor prognostic indicators related to local recurrence [12–14]. However, because the vast majority of these studies are based on extremity bone tumors, the results are not applicable to spinal GCTB. Given the fact there is much lower occurrence of GCTB in the spine, research is limited with few reports in the literature. There is no information to help clinicians stratify patients appropriately based on their risk of recurrence.

In recent years, radiomics has emerged as a popular image analysis method for performing diagnosis as well as predicting treatment response and prognosis. A large amount of quantitative data can be extracted from medical images to build models and aid in personalized management [15]. It can provide prognostic biomarkers to predict the risk of postoperative recurrence and survival [16]. So far there is no relevant research reported for GCTB. The CT examination is widely used for the management of GCTB to reveal bone changes associated with tumors before the operation. Additional information contained in CT can be extracted by using the radiomics for further analysis.

The purpose of this study is to develop a radiomics model based on imaging features extracted from pre-operative CT of spinal GCTB to predict the chance of recurrence during long-term follow-up.

## 2. Materials and methods

### 2.1. General materials

A retrospective review was performed to identify 62 patients with pathologically confirmed GCTB in the spine from March 2008 to February 2018. The study was approved by the Medical Science Research Ethics Committee of the authors' institution and the requirement of informed consent was waived.

Inclusion criteria were (1) patients who underwent surgery in our hospital with pathologically confirmed GCTB; (2) available CT examination before operation; (3) complete patient medical records. Exclusion criteria were (1) poor image quality, e.g. artifacts from oral metal implants; (2) incomplete follow-up data (including both imaging and comprehensive clinical examination) or with a follow-up time < 24 months; (3) previous surgery or radiotherapy of the lesion, treatment with denosumab (a RANKL inhibitor). Fig. 1 shows the subject identification flowchart.

### 2.2. CT acquisition

All 62 patients received preoperative CT examination before surgery. CT examination was performed on a GE Light speed 64 slice spiral CT (GE Medical System, Chalfont St Giles, UK) or a Siemens Somatom Definition Flash dual-source CT (Siemens, Erlangen, Germany), with tube voltage of 120 kV, tube current of 200–300 mAs. The collimator width was 0.625 and 0.60 mm, respectively; the pitch was 1.0; the slice thickness of reconstruction was 3 mm; the interlayer distance was 3 mm.

### 2.3. Clinical information analysis

The clinical information was obtained from patients' medical records, including: age, gender, location of the lesion, multivertebral involvement, and treatment. The surgery methods were divided into three categories: TES (total en bloc spondylectomy), intralesional spondylectomy (removal of the tumor), and curettage.

### 2.4. Follow-up methods

After confirming the successful treatment based on close evaluation in the first month, all patients were followed according to the clinical guideline: once every 3 months in the first 2 years, once every 6 months in 3–5 years, and then yearly after 5 years. The follow-up procedures included: physical examination and imaging of the operation site (X-ray, CT or MRI). Local recurrence was confirmed by imaging on CT or MRI. If a new lesion such as soft tissue mass with uneven density and invasive growth was found at the tumor resection site, it was considered as GCTB recurrence. For patients showing suspicious lesions or symptoms outside the resection site, CT guided puncture biopsy was performed to confirm the pathological diagnosis. Fig. 2 shows two case examples and the imaging follow-up results.

### 2.5. Regions of Interest (ROI) delineation

The pre-operative CT DICOM (Digital Imaging and Communications in Medicine) images of all identified patients were exported from PACS (Picture Archiving and Communication System). For each case, the range of axial CT slices containing the tumor was first determined. ROI of the tumor was manually delineated by two musculoskeletal radiologists, who had CT interpretation experience of 18 years (N.L.) and 16 years (X.X.), respectively. The boundary of the lesion was determined by combining CT images of different widths and windows.

### 2.6. Radiomics analysis to build prediction model

The radiomics analysis procedures are illustrated in Fig. 3. The procedure starts with generating the 3D tumor mask, extracting radiomics features, selecting important features, and lastly building the classification model to predict the recurrence and non-recurrence cases. For each case, the segmented tumors on all axial CT image were combined to generate a 3D tumor mask, and from which a total of 107 imaging features were extracted using PyRadiomics under Python 3.6 [17]. The detailed methods were described in the Supplementary Materials. The 107 features were obtained using several different algorithms, including First-Order (N = 18); Shape (N = 14); GLCM (N = 24); GLSZM (N = 16); GLRLM (N = 16); GLDM (N = 14); and NGTDM (N = 5), and they were sum-

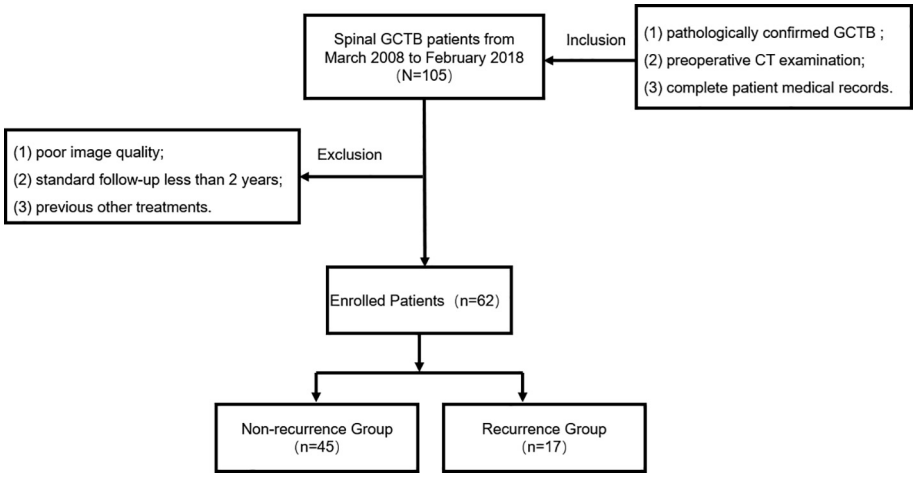


**Fig. 1.** The subject identification flowchart. A total of 62 patients with spinal GCTB in non-recurrence group (N = 45) and recurrence (N = 17) group are identified.

marized in a table. The basic definition and terminology used in each algorithm were explained, and the explicit mathematical equation for each feature was given.

To evaluate the importance of these features in differentiating patients with and without recurrence, a sequential feature selection process was utilized via constructing multiple support vector machine (SVM) classifiers [18]. In this process, we used SVM with Gaussian kernel as the objective function to test the performance of models built with a subset of features. In the beginning, an empty candidate set was presented, and features were sequentially added. 10-fold cross-validation method was applied to test the model performance. In each iteration, the training process was repeated 1,000 times to explore the robustness of each feature. After each iteration, the feature which led to the best performance was added to the candidate set. The selection process stopped after the addition of features did not improve the performance anymore. Here, we used $10^{-6}$ as termination tolerance for the objective function value.

After the features were selected by the SVM, they were used to build the models and test the performance by using 10-fold cross-validation. That is, 90% of cases were used for training to build the model, and the performance was tested using the remaining 10% cases. The output of the model is a recurrence probability for each testing case, which was used to classify as recurrence or non-recurrence using the threshold of 0.5. The process was performed 10 times to complete the 10-fold cross-validation. Each case had only one chance to be included in the testing group. After the analysis was completed, all results were combined to calculate the final prediction performance, and to generate the receiver operating characteristic (ROC) curve.

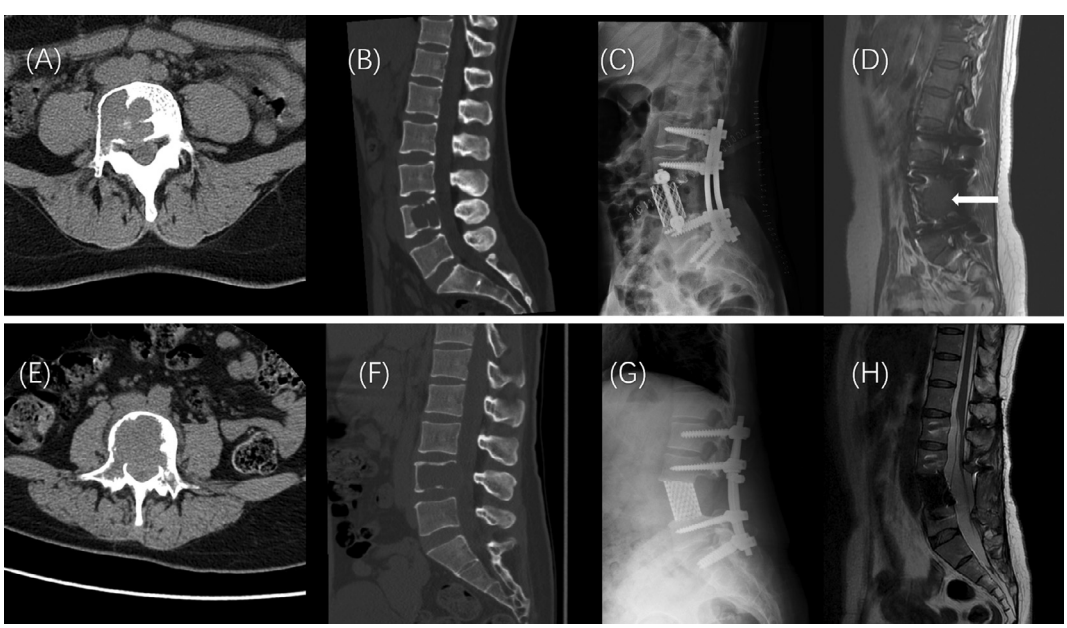


**Fig. 2.** Two case examples. Top panel: A 39-year-old woman, (A-B) axial and sagittal CT images showing the lesion, (C) treated with total *en bloc* spondylectomy, and postoperatively confirmed as GCTB. (D) The sagittal T2-weighted MR image at 13-month follow-up, showing the progression of the residual tumor (arrow), and confirmed by pathology with puncture biopsy. The recurrence probability predicted by the radiomics model is 0.94, a true positive case. Bottom panel: A 34-year-old woman, (E-F) axial and sagittal CT images showing a mass on the L4 vertebra, (G) treated with total *en bloc* spondylectomy, postoperatively confirmed as GCTB. (H) At a 60-month follow-up MRI, there is no sign of recurrence. The patient is continuously being followed and showing no evidence of recurrence. The recurrence probability predicted by the radiomics model is 0.30, a true negative case.

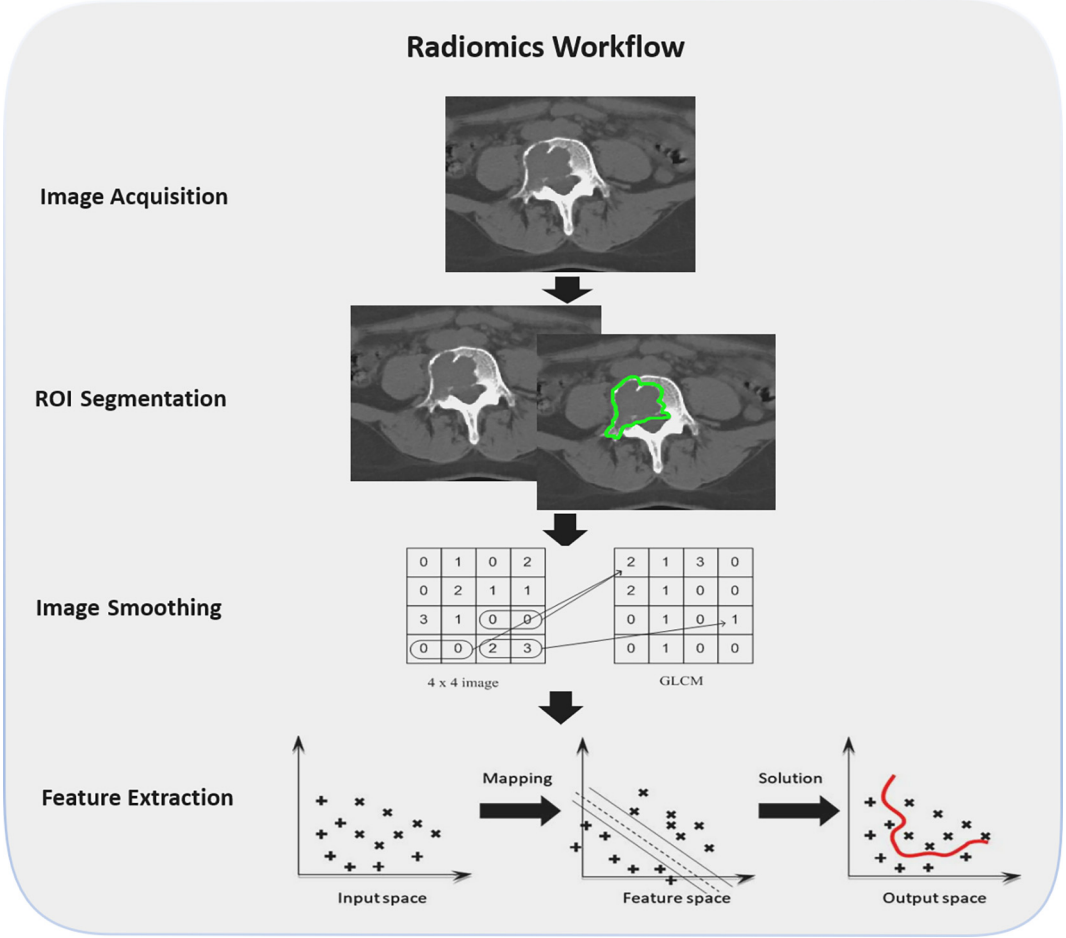


**Fig. 3.** The radiomics analysis procedures to build the classification model. The procedure starts with tumor ROI drawing, followed by radiomics feature extraction using the PyRadiomics software. Lastly, the SVM is applied to select important features and build the final classification model to differentiate the recurrence and non-recurrence cases.

### *2.7. Statistical analysis*

Statistical analyses were performed using Matlab 2019b for Windows. For evaluation of the clinical parameters, chi-square (or Fisher exact test) and Mann-Whitney U tests were applied for categorical and continuous data, respectively. The ROC curve was generated to show the prediction performance. The accuracy, and true positive (TP), true negative (TN), false positive (FP), false negative (FN) were calculated. *P*-value < 0.05 was considered statistically significant.

## 3. Results

### *3.1. Demographics and clinical characteristics*

A total of 62 patients were identified, who were divided into the recurrence group (N = 17) and the non-recurrence group (N = 45) according to follow-up results with a minimum of 2 years. The mean follow-up time was 73.7 months (range, 28.7–152.1 months). The postoperative recurrence rate was 27.4% (17/62). Table 1 shows the demographic and clinical characteristics in these two patient groups, including age, sex, lesion location, multi-vertebral involvement, and treatment methods. None of them shows a statistical difference between the recurrence and non-recurrence groups.

There were three surgical procedures, and patients receiving curettage had a higher recurrence rate (6/16 = 37.5%) compared to patients receiving TES (6/26 = 23.1%) or intralesional spondylectomy (5/20 = 25%). The difference was not statistically significant due to small case number. Although only 5 patients had multi-vertebral involvement, 3 of 5 (60%) had recurrence, suggesting a more aggressive nature when multiple segments were involved.

**Table 1**
Demographic and clinical characteristics of patients (N = 62).

| Characteristics | Non-recurrence (N = 45, 72.6%) | Recurrence (N = 17, 27.4%) |
|---|---|---|
| Age (years) | 31.9 ± 14.0 | 32.7 ± 10.8 |
| Gender | | |
| Male | 22 (75.9%) | 7 (24.1%) |
| Female | 23 (69.7%) | 10 (30.3%) |
| Location | | |
| Cervical spine | 15 (71.4%) | 6 (28.6%) |
| Thoracic spine | 18 (78.3%) | 5 (21.7%) |
| Lumbar spine | 7 (58.3%) | 5 (41.7%) |
| Sacral spine | 5 (83.3%) | 1 (16.7%) |
| Multi-vertebral involvement | | |
| No | 43 (75.4%) | 14 (24.6%) |
| Yes | 2 (40%) | 3 (60%) |
| Treatment | | |
| TES | 20 (76.9%) | 6 (23.1%) |
| Intralesional spondylectomy | 15 (75.0%) | 5 (25.0%) |
| Curettage | 10 (62.5%) | 6 (37.5%) |

### 3.2. Development of radiomics model

A total of 10 features, including 4 first-order histogram parameters (90 Percentile Intensity, Entropy, Kurtosis, Median) and 6 texture features (GLCM Maximal Correlation Coefficient, GLCM Maximum Probability, GLDM Large Dependence High Gray Level Emphasis, GLDM Small Dependence High Gray Level Emphasis, GLRLM Gray Level Non-Uniformity Normalized, and GLSZM Gray Level Non-Uniformity Normalized) were selected by SVM to build the final classification model. The order of the selected feature, their p values, and the accumulated AUC (that is, the AUC achieved by the 1st, 1st + 2nd, 1st + 2nd + 3rd,... etc.) are listed in Table 2. The box plot of the parameter that has the lowest p-value, GLDM Large Dependence High Gray Level Emphasis, is shown in Fig. 4. The box plots of the other 9 features are shown in the Supplementary Materials.

The trained prediction model was evaluated using 10-fold cross-validation. The model will give a recurrence probability for each case, and the combined results are shown in Fig. 5. The generated ROC curves are shown in Fig. 6. The AUC of the final prediction model using all 10 features is 0.78. The overall prediction accuracy is 89%, with 11 TP cases, 44 TN cases, 6 FN cases, and 1 FP cases. When the clinical information in Table 1 was added to the final model, the performance was not improved. If only using the 4 first-order histogram features to build the model, the SVM classification results showed 7 TP cases, 42 TN cases, 10 FN cases, and 3 FP cases. The overall prediction accuracy was 79% and the AUC of the prediction model was 0.73. If only using the 6 texture features to build the model, the SVM classification results showed 4 TP cases, 43 TN cases, 13 FN cases, and 2 FP cases. The overall prediction accuracy was 76% and the AUC of the prediction model was 0.62.

## 4. Discussion

Radiomics is an emerging technology that can be applied to evaluate tumor heterogeneity through the spatial arrangement of imaging voxels with varying signal intensity, which can generate quantitative information to aid in the diagnosis and treatment of tumors [19]. Compared with genetic testing or pathological analysis that requires analysis on tissue samples, radiomics can be analyzed using images, which is non-invasive and easy to perform. CT examination is widely used in clinical diagnosis, treatment planning, and follow-up of GCTB patients. The recurrence of spinal GCTB after surgery is related to the invasiveness of tumor cells, and the biological characteristics of tumor tissues may be revealed in preoperative CT images. However, the conventional imaging analysis using subjective assessment by a radiologist is difficult to capture the tumor heterogeneity. The texture analysis is widely applied to quantify the spatial heterogeneity of tumors. Although the technology-related heterogeneity (e.g. image noise and artifacts) is present on images [20], several studies have shown that the CT texture features have high consistency, and thus CT-based radiomics analysis is feasible [21–23].

From the 10 selected features, there are 4 first-order histogram features and 6 textural features, including 2 GLCM features, 2 GLDM features, 1 GLRLM feature, and 1 GLSZM feature. From the definitions, a GLCM quantifies the incidence of voxels with the same intensities at a predetermined distance along a fixed direction. A GLRLM quantifies consecutive voxels with the same intensity along fixed directions. A GLDM quantifies gray level dependencies in an image, which is defined as the number of connected voxels within a specific distance that is dependent on the center voxel. A GLSZM quantifies gray level zones in an image [17], which is defined as the number of connected voxels that share the same gray level intensity. One drawback of the texture analysis is that the features can only be extracted using sophisticated

**Table 2**
The selected radiomics features by SVM to build the final classification model.

| Feature Name | P-value | AUC |
|---|---|---|
| 90 Percentile Intensity | 0.12 | 0.60 |
| GLCM Maximum Probability | 0.12 | 0.62 |
| Kurtosis | 0.51 | 0.63 |
| GLSZM Gray Level Non-Uniformity Normalized | 0.28 | 0.63 |
| GLDM Large Dependence High Gray Level Emphasis | 0.07 | 0.66 |
| Entropy | 0.16 | 0.68 |
| GLDM Small Dependence High Gray Level Emphasis | 0.31 | 0.71 |
| GLCM Maximal Correlation Coefficient | 0.19 | 0.75 |
| Median | 0.72 | 0.78 |
| GLRLM Gray Level Non-Uniformity Normalized | 0.17 | 0.78 |

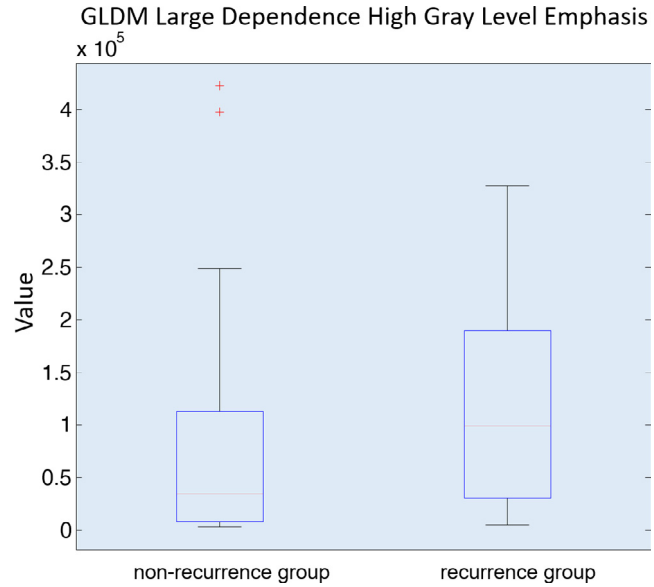


**Fig. 4.** The box plot of the parameter "GLDM Large Dependence High Gray Level Emphasis". The value is lower in the non-recurrence group than in the recurrence group, which has the lowest p-value of 0.07 among all 10 selected features. The box plot of the other 9 features are included in the **Supplementary Materials**.

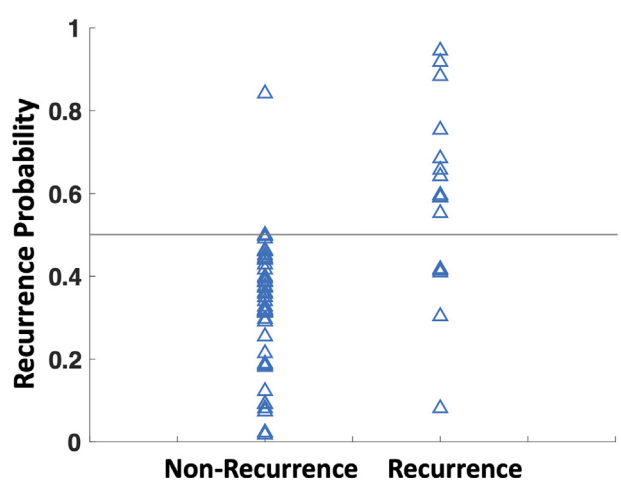


**Fig. 5.** The recurrence probability of all cases predicted by the SVM model. The recurrence probability of each case is predicted by the final radiomics model trained using all 10 selected features. By using the threshold of 0.5 as the cut-off, the overall accuracy is 89%, with 11 true-positive (TP), 44 true-negative (TN), 6 false-negative (FN), and 1 false positive (FP) cases.

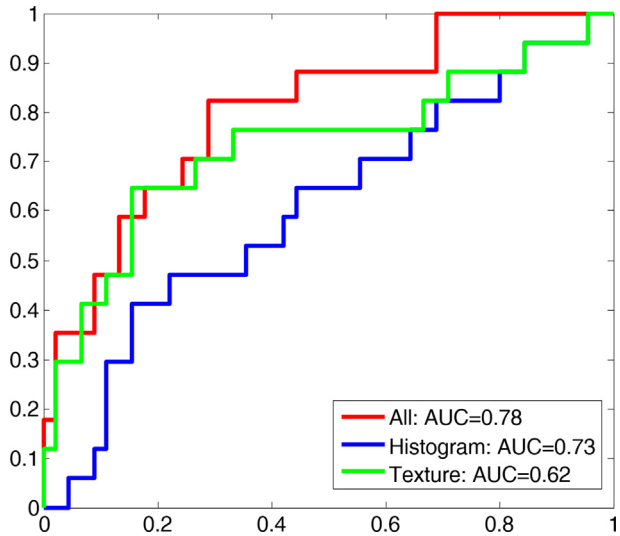


**Fig. 6.** The ROC curves to differentiate recurrence and non-recurrence groups. The ROC curves are generated by using the final model built with all 10 selected radiomics features, as well as the model built with the 4 first-order histogram and 6 texture parameters.

computer algorithms, and not visible by naked eyes. Nonetheless, it is believed that the texture reveals tumor heterogeneity, which is associated with underlying biology, and radiomics analysis provides a feasible method to unlock the buried information.

The classification model used in the present study is SVM, which is a widely used method for dealing with a large number of image-extracted features. SVM is not based on the original feature space but the transformed features via specific kernel methods, which works as a transformation to map input parameters into a different feature space where the transformed data can be divided more easily. This method can transform both the important and unimportant features into a new feature space in which the information of the selected feature can be fully utilized. The Gaussian kernel was used in this study. Each individual feature may provide useful information, even if the corresponding p-value is not lower than 0.05. The combination of all features can provide complementary information in SVM modeling. Meanwhile, the cost function of SVM allows the evaluation of margins between different groups. This can improve the robustness of the model and avoid overfitting during the training process. For a study with a small case number, SVM is the most suitable choice to balance the variance and bias of the input data. Other classification models, such as logistic regression and decision tree, work in the original feature space, and may not reach a high accuracy due to the lack of flexibility.

Spinal GCTB should be managed case-by-case, as each patient presents unique challenges. The treatment goals are tumor removal, spinal stability, and neural tissue decompression. Therefore, the choice of surgical method should be made with consideration of all factors comprehensively. The common methods are total en bloc spondylectomy (TES), intralesional spondylectomy, and curettage. TES may be too damaging and can result in severe complications in some cases because of the proximity of vital structures to the vertebra, especially in complicated cervical spine surgery [6,24]. For these patients, intralesional resection and curettage may be considered, and further, adjuvant therapies can be used to improve outcome. The significance of clinical characteristics in predicting recurrence is still unclear and controversial. For example, some studies reported that GCTB of the proximal tibia were more likely to recur [25], but others not [26]. The majority of research is based on the predictive factors for recurrence of GCTB in the epiphysis or metaphysis of long bones, few for spinal GCTB [27–29]. In our study, we did not find any of the analyzed clinical information (age, sex, location, multi-vertebral involvement) showing a significant difference between the recurrence and non-recurrence groups. When combined with clinical data, the performance of the radiomics model did not improve, suggesting the limited value of clinical information in prognosis prediction.

The value of radiomics in predicting recurrence and prognosis has been demonstrated for some diseases, but mostly for tumors with a high incidence, such as lung cancer [30], liver cancer [31], prostate cancer [32], nasopharyngeal carcinoma [33], ovarian cancer [34], etc. For studies of primary bone tumors, osteosarcoma was the most reported [35–37]. We have not found any radiomics study for predicting postoperative recurrence in GCTB. The radiomics analysis has been applied for the diagnosis of GCTB and other primary spinal tumors, e.g. for differentiation of chordoma and GCTB located in the sacrum [38,39]. It was reported that the radiomics model based on CT and multi-parameter MRI has predictive value in distinguishing them, and thus provides helpful clinical information to aid in diagnosis and treatment planning. For GCTB therapy response prediction, Jisook Yi et al. evaluated the changes in CT images after denosumab treatment and found that changes in tumor size, histogram and textural parameters might be helpful in the assessment of tumor response [40]. However, only 8 patients, including appendicular and spinal GCTB, were included, which could be due to the limited clinical use of denosumab.

The results of our spinal GCTB study indicated that the radiological model has the potential to provide a personalized relapse risk assessment. When patients are predicted to have a high risk of recurrence, more thorough surgery and adjuvant treatments need to be considered. Moreover, patients with a high risk of relapse should receive closer postoperative follow-up after treatment, so the recurrence can be diagnosed early for re-excision and improve the patient's prognosis [41]. On the other hand, for patients predicted to have a low risk of recurrence, follow-up imaging may be spared to reduce radiation risk and unnecessary cost. Furthermore, better risk stratification information can help the surgeon to give patients more reasonable clinical expectations.

There were some limitations in this study. First, the study analyzed a single-center retrospective dataset using patients presenting to our institution, and the sample size was small. Second, the treatment in this patient cohort only included surgery with different procedures, without more advanced adjuvant treatments such as denosumab. This promising drug has not been marketed in some country, and not available to most patients in our cohort. Third, only the pre-operative CT instead of MRI were analyzed in this study. We included spinal GCTB patients in a 10-year period, compared with CT, MRI has undergone substantial changes in the instrumentation upgrade and improved scanning protocol, and thus, CT images were chosen. Lastly, we included all patients who were followed for a minimum of 2 years. Some patients may show later recurrence, and a longer follow-up time is needed to find more recurrence cases.

In conclusion, in this study, we applied radiomics analysis to investigate the relationship between preoperative CT manifestations and postoperative recurrence in patients diagnosed with spinal GCTB. The results showed that the combined histogram and texture features selected by SVM based on preoperative CT images could be applied to predict recurrence with high accuracy. The capability to predict the risk of recurrence can be used to determine the optimal personalized management strategy, including the surgical methods, the need for adjuvant treatment, appropriate prognostic expectations, and the follow-up protocol.

## Funding

This work was supported by the National Natural Science Foundation of China [grant numbers 81971578, 81871326, 81701648], and the Beijing Municipal Natural Science Foundation [grant number Z190020].

**Compliance with ethical standards**

All procedures performed in studies involving human participants were in accordance with the Institutional Review Board (IRB) and ethics committee of Peking University Third Hospital.

**Informed Consent**:

Written informed consent was waived by the Institutional Review Board.

**Ethical Approval**:

Institutional Review Board approval was obtained.

**Study subjects or cohorts overlap**:

Some study subjects or cohorts have not been previously reported.

## Declaration of Competing Interest

The authors declare that they have no known competing financial interests or personal relationships that could have appeared to influence the work reported in this paper.

## Appendix A. Supplementary data

Supplementary data to this article can be found online at https://doi.org/10.1016/j.jbo.2021.100354.

## References

[1] J.H. Choi, J.Y. Ro, The 2020 WHO Classification of Tumors of Bone: An Updated Review, Adv. Anat. Pathol. (2021).
[2] L. Heijden, P.D.S. Dijkstra, M.A.J. Sande, J.R. Kroep, R.A. Nout, C.S.P. Rijswijk, J.V. M.G. Bovée, P.C.W. Hogendoorn, H. Gelderblom, The clinical approach toward giant cell tumor of bone, Oncologist 19 (5) (2014) 550–561.
[3] S. Boriani, S. Bandiera, R. Casadei, L. Boriani, R. Donthineni, A. Gasbarrini, et al. Giant cell tumor of the mobile spine: a review of 49 cases. Spine (Phila Pa 1976). 2012;37(1):E37-45.
[4] D.M. Sciubba, R. De la Garza Ramos, C.R. Goodwin, R. Xu, A. Bydon, T.F. Witham, Z.L. Gokaslan, J.-P. Wolinsky, Total en bloc spondylectomy for locally aggressive and primary malignant tumors of the lumbar spine, Eur. Spine J. 25 (12) (2016) 4080–4087.
[5] C. Errani, S. Tsukamoto, G. Ciani, D.M. Donati, Present day controversies and consensus in curettage for giant cell tumor of bone, J. Clin. Orthop. Trauma. 10 (6) (2019) 1015–1020.
[6] N. Yokogawa, H. Murakami, S. Demura, S. Kato, K. Yoshioka, T. Shimizu, N. Oku, R. Kitagawa, H. Tsuchiya, Total spondylectomy for Enneking stage III giant cell tumor of the mobile spine, Eur. Spine J. 27 (12) (2018) 3084–3091.
[7] D. Li, J. Zhang, Y.i. Li, J. Xia, Y. Yang, M. Ren, Y. Liao, S. Yu, X. Li, Y. Shen, Y.a. Zhang, Z. Yang, Surgery methods and soft tissue extension are the potential risk factors of local recurrence in giant cell tumor of bone, World J. Surg. Oncol. 14 (1) (2016), https://doi.org/10.1186/s12957-016-0871-z.
[8] Z.H. Wan, C.W. Lee, S. Yuan, O.K.S. Lee, Can p63 serve as a biomarker for diagnosing giant cell tumor of bone? A systematic review and meta-analysis, Sao Paulo Med. J. 138 (5) (2020) 393–399.
[9] S. Peters, P. Clézardin, I. Márquez-Rodas, D. Niepel, C. Gedye, The RANK-RANKL axis: an opportunity for drug repurposing in cancer?, Clin. Transl. Oncol. 21 (8) (2019) 977–991.
[10] K. Zhang, M. Zhou, H. Chen, G. Wu, K. Chen, H. Yang, Expression of IMP3 and IGF2 in giant cell tumor of spine is associated with tumor recurrence and angiogenesis, Clin. Transl. Oncol. 17 (7) (2015) 570–575.
[11] T. Okubo, T. Saito, H. Mitomi, T. Takagi, T. Torigoe, Y. Suehara, K. Kaneko, T. Yao, p53 mutations may be involved in malignant transformation of giant cell tumor of bone through interaction with GPX1, Virchows Arch. 463 (1) (2013) 67–77.
[12] Y. He, J. Wang, W. Rui, J. Lin, F. Yuan, L. Du, J.i. Zhang, X. Ding, Retrospective investigation of "paint brush borders" sign in association with local recurrence of giant cell tumor of bone after intralesional curettage, J. Bone Oncol. 10 (2018) 41–48.
[13] He YF, Wang J, Zhang J, Yuan F, Ding XY. A prospective study on predicting local recurrence of giant cell tumour of bone by evaluating preoperative imaging features of the tumour around the knee joint (vol 122, pg 546, 2017). Radiologia Medica. 2017;122(7):556-.
[14] B.D. Elder, E.W. Sankey, C.R. Goodwin, T.A. Kosztowski, S.-F. Lo, A. Bydon, J.-P. Wolinsky, Z.L. Gokaslan, T.F. Witham, D.M. Sciubba, Surgical Outcomes in Patients with High Spinal Instability Neoplasm Score Secondary to Spinal Giant Cell Tumors, Glob Spine J. 6 (1) (2016) 21–28.
[15] P. Lambin, R.T.H. Leijenaar, T.M. Deist, J. Peerlings, E.E.C. de Jong, J. van Timmeren, S. Sanduleanu, R.T.H.M. Larue, A.J.G. Even, A. Jochems, Y. van Wijk, H. Woodruff, J. van Soest, T. Lustberg, E. Roelofs, W. van Elmpt, A. Dekker, F.M. Mottaghy, J.E. Wildberger, S. Walsh, Radiomics: the bridge between medical imaging and personalized medicine, Nat. Rev. Clin. Oncol. 14 (12) (2017) 749–762.
[16] V. Parekh, M.A. Jacobs, Radiomics: a new application from established techniques, Expert Rev Precis Me. 1 (2) (2016) 207–226.
[17] J.J.M. van Griethuysen, A. Fedorov, C. Parmar, A. Hosny, N. Aucoin, V. Narayan, R.G.H. Beets-Tan, J.-C. Fillion-Robin, S. Pieper, H.J.W.L. Aerts, Computational radiomics system to decode the radiographic phenotype, Cancer Res. 77 (21) (2017) e104–e107.
[18] C. Cortes, V. Vapnik, Support-vector networks, Mach. Learn. 20 (3) (1995) 273–297.
[19] P. Lambin, E. Rios-Velazquez, R. Leijenaar, S. Carvalho, R.G.P.M. van Stiphout, P. Granton, C.M.L. Zegers, R. Gillies, R. Boellard, A. Dekker, H.J.W.L. Aerts, Radiomics: Extracting more information from medical images using advanced feature analysis, Eur. J. Cancer 48 (4) (2012) 441–446.
[20] M.G. Lubner, A.D. Smith, K. Sandrasegaran, D.V. Sahani, P.J. Pickhardt, CT Texture Analysis: Definitions, Applications, Biologic Correlates, and Challenges, Radiographics. 37 (5) (2017) 1483–1503.
[21] W. Wei, Z. Liu, Y.u. Rong, B. Zhou, Y. Bai, W. Wei, S. Wang, M. Wang, Y. Guo, J. Tian, A Computed Tomography-Based Radiomic Prognostic Marker of Advanced High-Grade Serous Ovarian Cancer Recurrence: A Multicenter Study, Front. Oncol. 9 (2019), https://doi.org/10.3389/fonc.2019.00255.
[22] W. Tu, G. Sun, L.i. Fan, Y. Wang, Y.i. Xia, Y.u. Guan, Q. Li, D.i. Zhang, S. Liu, Z. Li, Radiomics signature: A potential and incremental predictor for EGFR mutation status in NSCLC patients, comparison with CT morphology, Lung Cancer. 132 (2019) 28–35.
[23] Y. Jiang, W. Wang, C. Chen, X. Zhang, X. Zha, W. Lv, J. Xie, W. Huang, Z. Sun, Y. Hu, J. Yu, T. Li, Z. Zhou, Y. Xu, G. Li, Radiomics Signature on Computed Tomography Imaging: Association With Lymph Node Metastasis in Patients With Gastric Cancer, Front. Oncol. 9 (2019), https://doi.org/10.3389/fonc.2019.0034010.3389/fonc.2019.00340.s001.
[24] P. Luksanapruksa, J.M. Buchowski, W. Singhatanadgige, P.C. Rose, D.B. Bumpass, Management of spinal giant cell tumors, Spine J. 16 (2) (2016) 259–269.
[25] M.A. Siddiqui, C. Seng, M.H. Tan, Risk factors for recurrence of giant cell tumours of bone, J. Orthop. Surg-Hong K. 22 (1) (2014) 108–110.
[26] R.R. Goldenberg, C.J. Campbell, M. Bonfiglio, Giant-cell tumor of bone. An analysis of two hundred and eighteen cases, J. Bone Joint Surg. Am. 52 (4) (1970) 619–664.
[27] J.-L. Lin, Y.-H. Wu, Y.-F. Shi, H. Lin, M. Nisar, Z. Meftah, C. Xu, J.-X. Chen, X.-Y. Wang, Survival and prognosis in malignant giant cell tumor of bone: A population-based analysis from 1984 to 2013, J. Bone Oncol. 19 (2019) 100260, https://doi.org/10.1016/j.jbo.2019.100260.
[28] Q.i. Jia, G. Chen, J. Cao, X. Yang, Z. Zhou, H. Wei, T. Liu, J. Xiao, Clinical features and prognostic factors of pediatric spine giant cell tumors: report of 31 clinical cases in a single center, Spine J. 19 (7) (2019) 1232–1241.
[29] D.D. Cheng, T. Hu, H.Z. Zhang, J. Huang, Q.C. Yang, Factors Affecting the Recurrence of Giant Cell Tumor of Bone After Surgery: A Clinicopathological Study of 80 Cases from a Single Center, Cell. Physiol. Biochem. 36 (5) (2015) 1961–1970.
[30] Y. Huang, Z. Liu, L. He, X. Chen, D. Pan, Z. Ma, C. Liang, J. Tian, C. Liang, Radiomics Signature: A Potential Biomarker for the Prediction of Disease-Free Survival in Early-Stage (I or II) Non-Small Cell Lung Cancer, Radiology 281 (3) (2016) 947–957.
[31] Y. Zhou, L. He, Y. Huang, S. Chen, P. Wu, W. Ye, Z. Liu, C. Liang, CT-based radiomics signature: a potential biomarker for preoperative prediction of early recurrence in hepatocellular carcinoma, Abdom. Radiol. (NY). 42 (6) (2017) 1695–1704.
[32] S.J. Hectors, M. Cherny, K.K. Yadav, A.T. Beksaç, H. Thulasidass, S. Lewis, E. Davicioni, P. Wang, A.K. Tewari, B. Taouli, Radiomics Features Measured with Multiparametric Magnetic Resonance Imaging Predict Prostate Cancer Aggressiveness, J. Urol. 202 (3) (2019) 498–505.
[33] L.-L. Zhang, M.-Y. Huang, Y. Li, J.-H. Liang, T.-S. Gao, B. Deng, J.-J. Yao, L.i. Lin, F.-P. Chen, X.-D. Huang, J. Kou, C.-F. Li, C.-M. Xie, Y. Lu, Y. Sun, Pretreatment MRI radiomics analysis allows for reliable prediction of local recurrence in non-metastatic T4 nasopharyngeal carcinoma, EBioMedicine. 42 (2019) 270–280.
[34] H.e. Zhang, Y. Mao, X. Chen, G. Wu, X. Liu, P. Zhang, Y.u. Bai, P. Lu, W. Yao, Y. Wang, J. Yu, G. Zhang, Magnetic resonance imaging radiomics in categorizing ovarian masses and predicting clinical outcome: a preliminary study, Eur. Radiol. 29 (7) (2019) 3358–3371.
[35] S. Zhao, Y.i. Su, J. Duan, Q. Qiu, X. Ge, A. Wang, Y. Yin, Radiomics signature extracted from diffusion-weighted magnetic resonance imaging predicts outcomes in osteosarcoma. Journal of Bone, Oncology. 19 (2019) 100263, https://doi.org/10.1016/j.jbo.2019.100263.
[36] H. Sheen, W. Kim, B.H. Byun, C.-B. Kong, W.S. Song, W.H. Cho, I. Lim, S.M. Lim, S.-K. Woo, G. Treglia, Metastasis risk prediction model in osteosarcoma using metabolic imaging phenotypes: A multivariable radiomics model, PLoS ONE 14 (11) (2019) e0225242.

[37] Y. Wu, L. Xu, P. Yang, N. Lin, X. Huang, W. Pan, H. Li, P. Lin, B. Li, V. Bunpetch, C. Luo, Y. Jiang, D. Yang, M.i. Huang, T. Niu, Z. Ye, Survival Prediction in High-grade Osteosarcoma Using Radiomics of Diagnostic Computed Tomography, Ebiomedicine. 34 (2018) 27–34.
[38] P. Yin, N. Mao, C. Zhao, J. Wu, C. Sun, L. Chen, N. Hong, Comparison of radiomics machine-learning classifiers and feature selection for differentiation of sacral chordoma and sacral giant cell tumour based on 3D computed tomography features, Eur. Radiol. 29 (4) (2019) 1841–1847.
[39] P. Yin, N. Mao, S. Wang, C. Sun, N. Hong, Clinical-radiomics nomograms for pre-operative differentiation of sacral chordoma and sacral giant cell tumor based on 3D computed tomography and multiparametric magnetic resonance imaging, Br. J. Radiol. 92 (1101) (2019) 20190155, https://doi.org/10.1259/bjr.20190155.
[40] J. Yi, Y.H. Lee, S.K. Kim, S.H. Kim, H.-T. Song, K.-H. Shin, J.-S. Suh, Response evaluation of giant-cell tumor of bone treated by denosumab: Histogram and texture analysis of CT images, J Orthop Sci. 23 (3) (2018) 570–577.
[41] P. Lin, N. Lin, W. Teng, S.-D. Wang, W.-b. Pan, X. Huang, X.-b. Yan, M. Liu, H.-Y. Li, B.-H. Li, L.-L. Sun, Z. Wang, X.-Z. Zhou, Z.-M. Ye, Recurrence of Giant Cell Tumor of the Spine after Resection: A Report of 10 Cases, Orthop Surg. 10 (2) (2018) 107–114.