

UC Irvine

UC Irvine Previously Published Works

Title

Hybrid argon plasma coagulation for Barrett's esophagus.

Permalink

<https://escholarship.org/uc/item/39m4s46w>

Journal

VideoGIE : an official video journal of the American Society for Gastrointestinal Endoscopy, 6(8)

ISSN

2468-4481

Authors

Kolb, Jennifer M
Shah, Sagar
Chahine, Anastasia
et al.

Publication Date

2021-08-01

DOI

10.1016/j.vgie.2021.04.002

Peer reviewed



Hybrid argon plasma coagulation for Barrett's esophagus

Jennifer M. Kolb, MD, MS,¹ Sagar Shah, BS,² Anastasia Chahine, MD,¹ Kenneth Chang, MD,¹
Jason B. Samarasena, MD¹

INTRODUCTION

As the incidence of esophageal adenocarcinoma increases in the United States, detection, diagnosis, and treatment for Barrett's esophagus (BE) is even more critical.¹ BE-related neoplasia is managed by endoscopic eradication therapy, a strategy of endoscopic resection of any nodular or visible lesion and ablation for flat neoplasia.² Ablative modalities include radiofrequency ablation (RFA), argon plasma coagulation (APC), and cryoablation with either spray liquid nitrogen or balloon-based nitrous oxide therapy. The original and still most commonly used method is RFA, which can be performed using a balloon-based circumferential device for long-segment BE or a focal cap device for shorter segments or tongues. APC, a contact-free thermal coagulation technique, uses a jet of ionized argon gas that is ignited to achieve tissue ablation.

The main limitations to current ablative technologies are stricture formation, buried glands below the neosquamous epithelium, the requirement for multiple sessions to achieve remission, the risk of recurrent disease, and technical difficulty in patients with tortuous esophageal anatomy. A new technique called hybrid-APC combines submucosal fluid injection through a high-pressure water jet system to create a protective cushion before ablation, with a goal of safely treating to greater tissue depth compared with standard APC.³ The proposed advantages of hybrid-APC include the ability to ablate a larger area in a single session, the potential to administer therapy deep into the tissue, and a possible decreased rate of stricture formation or adverse events (Video 1, available online at www.giejournal.org).

INDICATIONS AND CONTRAINDICATIONS

Hybrid-APC is indicated for therapy of neoplastic tissue in the GI tract and can be used in the treatment of BE. Contraindications to hybrid-APC are similar to those of any ablative technique and include anticoagulation, coagulopathy, and stricture.

PROCEDURE: TOOLS AND TECHNIQUE

The APC catheter (2.3 mm diameter, 1.9 m in length) is connected to both the electrosurgical unit (Erbe, Tübingen,

Germany) and water jet system (ERBEJET2). The catheter should be primed to ensure there is no air in the line before use. During upper endoscopy, the Barrett's segment is closely examined using high definition white light endoscopy and virtual chromoendoscopy (Fig. 1). The treatment area can be marked using the APC catheter at Pulsed 25 or 30 W. Submucosal injection is performed next using methylene blue mixed with saline. This system facilitates high-pressure injection directly through the catheter without any needle to create a saline solution cushion that will protect the deeper layers and muscularis propria from thermal injury. During injection, we make sure to keep the catheter tip close to the endoscope. If the fluid is not penetrating the mucosa, we roll the catheter toward the wall to achieve a less tangential angle while gaining stabilization from the distal attachment cap.

For normal treatment-naïve tissue, the starting settings for the water jet system is Effect 25 to 30. If the tissue has been previously treated, the pressure can be increased to Effect 35 to 40. The setting can be increased in increments of 5 until the desired lift is accomplished. We typically prefer to lift the entire area and then ablate; however, for long segments, an alternative approach is to lift a portion of the mucosa and then ablate, followed by continued lifting and ablation until the entire segment is treated. With the needleless injection system activated by the foot pedal, either strategy is easy and convenient. During the first pass, one can ablate with extreme precision with pulsed APC at 60 W with an argon flow rate of 0.8 to 1.0 L/min. Circumferential treatment typically works well for shorter segments, whereas for longer segments we burn in longitudinal stripes. The endoscopist controls the dosimetry and can burn to the desired tissue effect. The goal is to achieve a tan brown chamois appearance of the tissue.

After first-pass ablation, we use the distal attachment cap to mechanically clear the tissue surface of the ablation debris. Scraping is always performed before additional ablation. Some of the injection may have dissipated, so we selectively inject again as needed for the second pass. The second ablation is performed at 40 W. The goal during this second pass is to identify "skip areas" that appear pink, indicating the need for additional therapy. Areas where the goal tissue effect has clearly been achieved do not need to be treated a second time. After the procedure, patients are prescribed proton pump inhibitors, sucralfate, and liquid pain

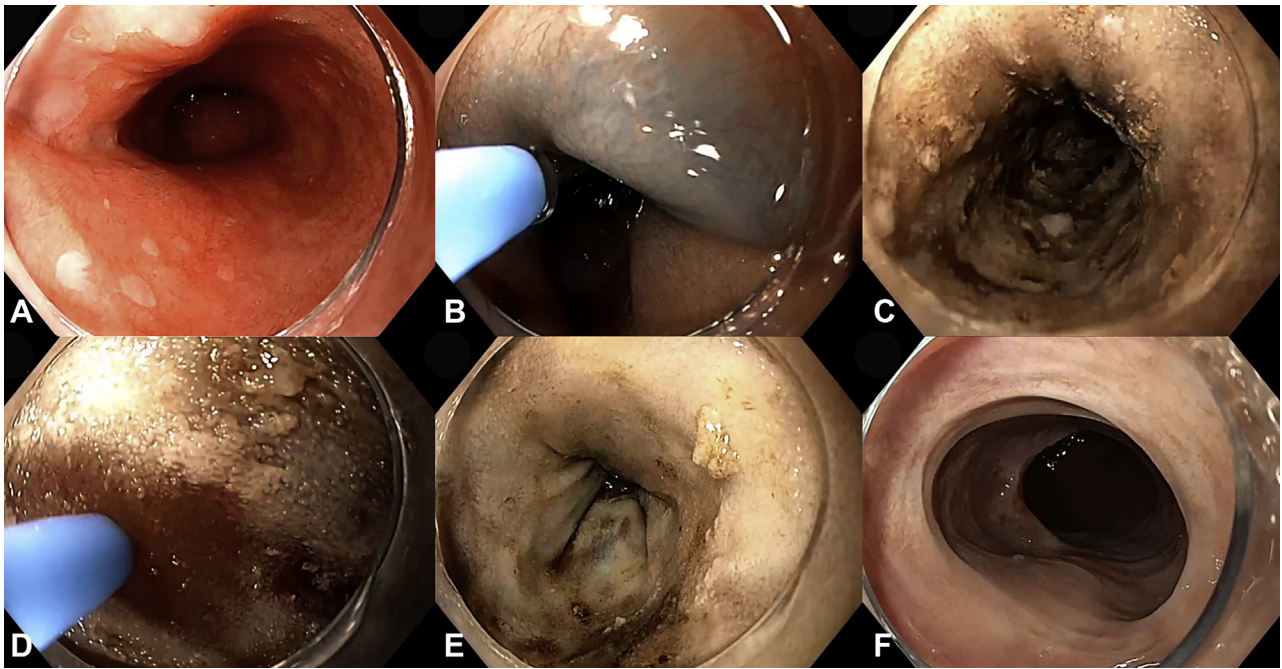


Figure 1. Treatment of Barrett's esophagus with low-grade dysplasia with hybrid-APC **A**, Upper endoscopy demonstrated Barrett's esophagus (C8M8). **B**, Submucosal injection lift is performed using a needleless high-pressure water jet system with methylene blue and saline solution. **C**, After first ablation and scraping the mucosa clean. **D**, Submucosal injection and second-pass ablation are performed for visible pink mucosa needing additional therapy. **E**, After 2 ablations, the tissue has a grey to tan-brown chamois appearance. **F**, Repeat endoscopy 3 months later demonstrated healthy-appearing neosquamous mucosa.

medication as needed. Repeat assessment of the area is performed in 3 months.

OUTCOMES

Initial pilot studies demonstrate hybrid-APC to be safe and effective for BE. Early data from Germany on 50 patients who underwent hybrid-APC after endoscopic resection demonstrate high rates of endoscopic remission (96%) and complete remission of intestinal metaplasia (CRIM, 78%) after a median of 3.5 treatment sessions.⁴ In a more recent U.S. study of 22 patients, the majority of whom had already been treated with other modalities, 86% achieved CRIM.⁵ Hybrid-APC has also been successful in refractory cases where RFA has failed.⁶ A multicenter European study is also underway, and preliminary results of 126 patients at 3 months demonstrate high rates of CRIM (92%).⁷

Minor adverse events include postprocedural pain or discomfort. The reported rates of stricture formation range from 2% to 4.75%, which is relatively similar to those for RFA.^{4,5,7} Although rare, perforations have been described.

CONCLUSION

Hybrid-APC is an emerging alternative therapy for BE-related neoplasia. Preliminary studies suggest it is safe

and effective, although data are limited on long-term outcomes. Factors such as cost, training, and patient selection will need to be considered when deciding which technique to use.

DISCLOSURE

Dr Samarasena has ownership in Docbot; is a consultant for Medtronic, Conmed, Olympus, Neptune Medical, Microtech, Pentax, US Endoscopy, and Motus; is a lecturer for Medtronic, Conmed, Mauna Kea Technologies, and Olympus; and has an educational grant from Cook Medical. Dr Chang is a consultant for Olympus, Endogastric Solutions, Medtronic, Cook Medical, Pentax, and ERBE. All other authors disclosed no financial relationships.

Abbreviations: APC, argon plasma coagulation; BE, Barrett's esophagus; CRIM, complete remission of intestinal metaplasia; RFA, radiofrequency ablation.

REFERENCES

1. Kolb JM, Han S, Scott FI, et al. Early-onset esophageal adenocarcinoma presents with advanced-stage disease but has improved survival compared with older individuals. *Gastroenterology* 2020;159:2238-40.e4.

2. Kolb JM, Wani S. Endoscopic eradication therapy for Barrett's oesophagus: state of the art. *Curr Opin Gastroenterol* 2020;36:351-8.
3. Manner H, Neugebauer A, Scharpf M, et al. The tissue effect of argon-plasma coagulation with prior submucosal injection (Hybrid-APC) versus standard APC: A randomized ex-vivo study. *United European Gastroenterol J* 2014;2:383-90.
4. Manner H, May A, Kouti I, et al. Efficacy and safety of hybrid-APC for the ablation of Barrett's esophagus. *Surg Endosc* 2016;30:1364-70.
5. Shimizu T, Samarasena JB, Fortinsky KJ, et al. Efficacy, tolerance, and safety of hybrid argon plasma coagulation for the treatment of Barrett's esophagus: a single center pilot study [abstract]. *Gastrointest Endosc* 2018;87:AB292.
6. Trindade AJ, Wee D, Wander P, et al. Successful treatment of refractory Barrett's neoplasia with hybrid argon plasma coagulation: a case series. *Endoscopy* 2020;52:812-3.
7. Rösch T, Manner H, May A, et al. Multicenter feasibility study of combined injection and argon plasma coagulation (hybrid-APC) in the ablation

therapy of neoplastic Barrett esophagus [abstract]. *Gastrointest Endosc* 2018;87.

H. H. Chao Comprehensive Digestive Disease Center, University of California, Irvine Medical Center, Department of Medicine, Orange, California (1), University of California, Irvine School of Medicine, Orange, California (2).

If you would like to chat with an author of this article, you may contact Dr Samarasena at jsamaras@hs.uci.edu.

Copyright © 2021 American Society for Gastrointestinal Endoscopy. Published by Elsevier Inc. This is an open access article under the CC BY-NC-ND license (<http://creativecommons.org/licenses/by-nc-nd/4.0/>).

<https://doi.org/10.1016/j.vgje.2021.04.002>

Submit to *VideoGIE*

VideoGIE is now indexed in PubMed Central.

VideoGIE is an Open Access, online-only journal indexed in PubMed Central. Submit video cases of endoscopic procedures used in the study, diagnosis, and treatment of digestive diseases.

VideoGIE publishes the following article types:

- **Case Reports:** Reports of the diagnosis and management of digestive diseases using a single case.
- **Case Series:** Reports of the diagnosis and management of digestive diseases using 3 or more cases.
- **Tools and Techniques:** Educational videos demonstrating the use of a particular endoscopic tool or technique. The goal of this section is to help trainees, endoscopy nurses, and technicians learn how best to use the tools of endoscopy for high-quality care.

All manuscripts must be submitted online at <http://www.editorialmanager.com/vgje>