

UC Irvine

UC Irvine Previously Published Works

Title

Overlapping Spots of Photodynamic Therapy for Treatment of Choroidal Hemangioma in Sturge-Weber Syndrome: A Case Report.

Permalink

<https://escholarship.org/uc/item/39n8s6xm>

Journal

Case Reports in Ophthalmology, 15(1)

ISSN

1663-2699

Authors

Pai, Alex

Han, Michael

Mosaed, Sameh

et al.

Publication Date

2024

DOI

10.1159/000535948

Copyright Information

This work is made available under the terms of a Creative Commons Attribution-NonCommercial License, available at <https://creativecommons.org/licenses/by-nc/4.0/>

Peer reviewed

Case Report

Overlapping Spots of Photodynamic Therapy for Treatment of Choroidal Hemangioma in Sturge-Weber Syndrome: A Case Report

Alex Y. Pai^a Michael M. Han^b Sameh Mosaed^b Mohammad Riazi Esfahani^b

^aSchool of Medicine, University of California – Irvine, Irvine, CA, USA; ^bGavin Herbert Eye Institute, Department of Ophthalmology, University of California – Irvine, Irvine, CA, USA

Keywords

Sturge-Weber syndrome · Choroidal hemangioma · Photodynamic therapy · Case report

Abstract

Introduction: Photodynamic therapy (PDT) has shown substantial benefit in the treatment of choroidal hemangioma (CH) in recent years. This report describes the use of PDT with overlapping spots in a patient with Sturge-Weber syndrome (SWS) and large circumscribed CH. **Case Presentation:** A 9-year-old girl with SWS and a history of glaucoma in her left eye was referred to a retina clinic for possible macular changes. Examination revealed decreased vision in the left eye, pigmentary changes in the macula, and choroidal thickening in the posterior pole. After being lost to follow-up for 2 years, the patient returned with further vision deterioration with best-corrected visual acuity (BCVA) of 20/150 and new subretinal fluid (SRF). Imaging findings were consistent with a diagnosis of CH and SRF. PDT with verteporfin was initiated on the entire area with multiple overlapping spots, resulting in resolution of SRF and improvement in visual acuity and choroidal contour. At 18-month post-treatment, the patient's BCVA was 20/25 with no recurrence of SRF or increased choroidal thickening. Significant pigmentary changes and subretinal hyper-reflective material were observed in the OCT of the treated area. **Conclusion:** Multiple overlapping laser spots of PDT can result in longstanding regression of large circumscribed CH in a patient with SWS with excellent final visual acuity. However, significant subretinal changes may also result following this method of treatment.

© 2024 The Author(s).
Published by S. Karger AG, Basel

Correspondence to:
Michael M. Han, hanmm@hs.uci.edu

Introduction

Sturge-Weber syndrome (SWS), also known as encephalotrigeminal angiomatosis, is a rare neurocutaneous disorder characterized by a constellation of findings including angiomas of the face – the commonly referenced nevus flammeus “port-wine stain” in the trigeminal distribution – leptomeninges, and choroid. Ocular manifestations are common in SWS, with glaucoma presenting in 30–70% of patients and choroidal hemangiomas (CHs) presenting in up to 71% of patients [1].

CH is a benign vascular tumor originating from the choroid, the vascular layer of the eye. It typically presents as an orange-red “tomato ketchup” elevated mass with dilated tortuous vessels within the posterior pole of the eye. In patients with SWS, CH is often unilateral, of the diffuse-type, and occurs ipsilateral to the port-wine stain birthmark. Circumscribed CHs often occur sporadically, most often in the second to fourth decade of life, and may be more difficult to distinguish from malignant tumors given its more ambiguous clinical presentation [1].

Management of symptomatic CH in SWS aims to restore vision if possible. In the past few decades, various treatment modalities including laser photocoagulation, cryotherapy, transpupillary thermotherapy, and radiotherapy have been explored with varying degrees of effectiveness. However, these approaches also come with the risk of causing additional functional damage to the retina [2].

Photodynamic therapy (PDT) is a promising and less-invasive treatment option for CH, particularly for the circumscribed-type. PDT involves the selective targeting of abnormal blood vessels using a photosensitizing agent, followed by light activation to induce vascular occlusion inside the tumor. This technique has also shown favorable outcomes in the treatment of other ocular neovascular conditions, such as choroidal neovascularization in age-related macular degeneration. PDT can be performed as a single spot or multispot treatment, with the latter being reserved for larger tumor sizes. In multispot treatment, the degree of overlap between spots is typically minimized to avoid inducing choroidal atrophy from potential overtreatment [3]. In the following, we present a case report of a patient with SWS and large circumscribed CH with macular involvement who underwent overlapping multispot PDT as a treatment modality, highlighting the clinical presentation, management approach, positive treatment outcome, and possible side effects.

Case Presentation

A 9-year-old female of Caucasian descent with a history of SWS was referred to our retina clinic for possible macular changes in her left eye. Her past ocular history included glaucoma in the left eye which was managed with a Baerveldt drainage implant placed 4 years prior. At the time of the exam, no vision changes or pain were noted. Best-corrected visual acuity (BCVA) was 20/20 in the right eye and 20/50 in the left eye. IOP measured by Tonopen was 16 mm Hg in the right eye and 14 mm Hg in the left eye. Slit lamp examination showed a well-positioned Baerveldt shunt in the left eye with trace pupillary peaking but otherwise no abnormalities. Fundus photographs of the left eye demonstrated fine pigmentary changes in the macula (shown in Fig. 1), and optical coherence tomography (OCT) of the left eye showed significant choroidal thickening (shown in Fig. 1b). Although fluorescein angiography seemed to reveal no pathologic findings (shown in Fig. 1c), indocyanine green angiography showed focal hyperfluorescent pooling in the macula, demonstrating a “wash out” phenomenon (shown in Fig. 1d). These findings were consistent with a diagnosis of CH.

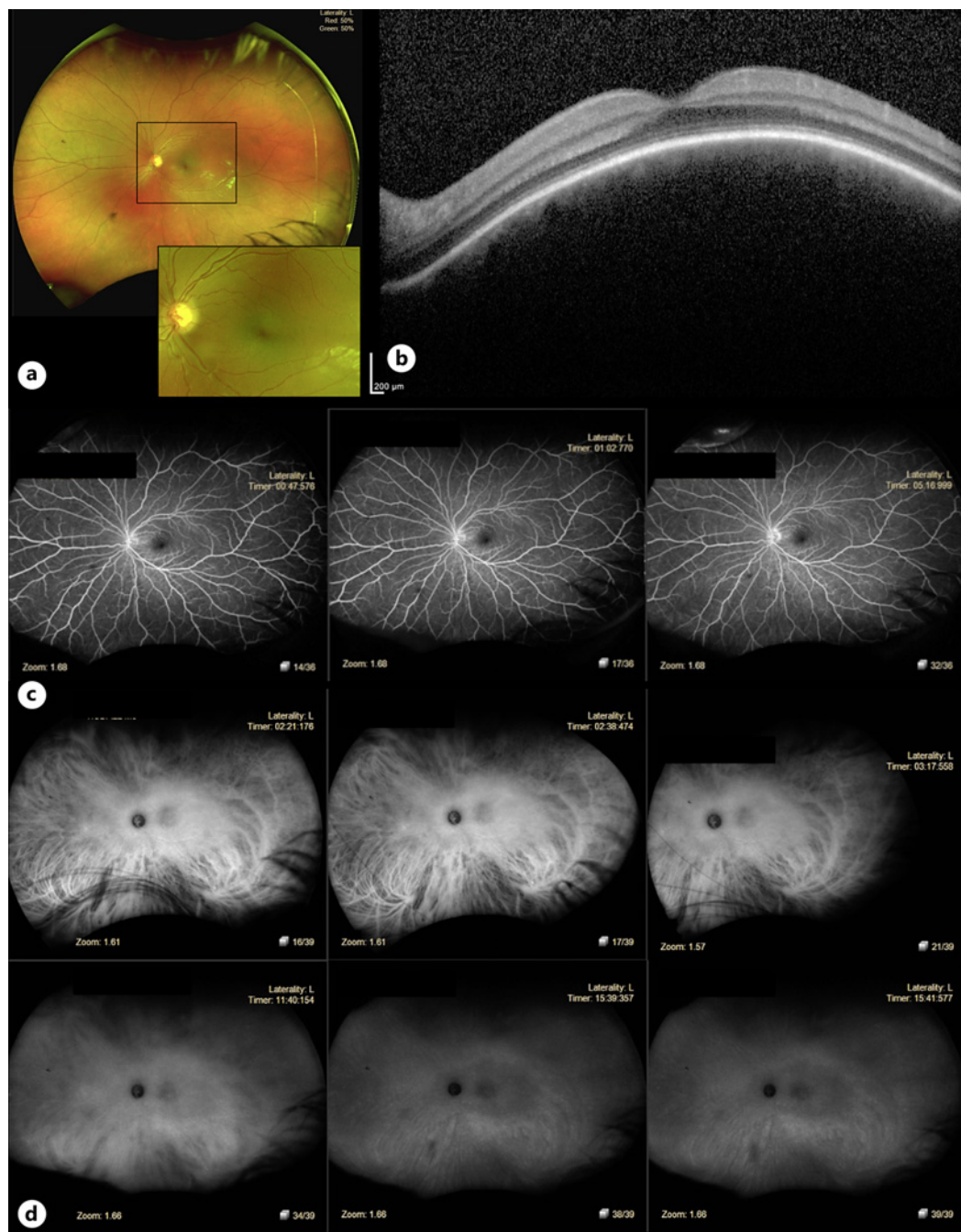


Fig. 1. Initial presentation. **a** Fundus photograph of the left eye with macular pigmentary changes. **b** Optical coherence tomography of the optic nerve head showing diffuse thickening of the pigment epithelium and choroid. **c** Fluorescein angiography of the left eye within normal limits. **d** Late phase indocyanine green angiography of the left eye demonstrating washout effect.

Two years later, the patient returned to the clinic with decreased vision in the left eye with a BCVA of 20/150. Fundus photographs of the left eye showed worsening pigmentary changes in the macula (shown in Fig. 2a) and OCT of the left eye revealed new subretinal fluid (SRF) which had been first noted by the patient's ophthalmologist abroad 5 months prior (shown in Fig. 2b). Fundus autofluorescence demonstrated central hypo-autofluorescence

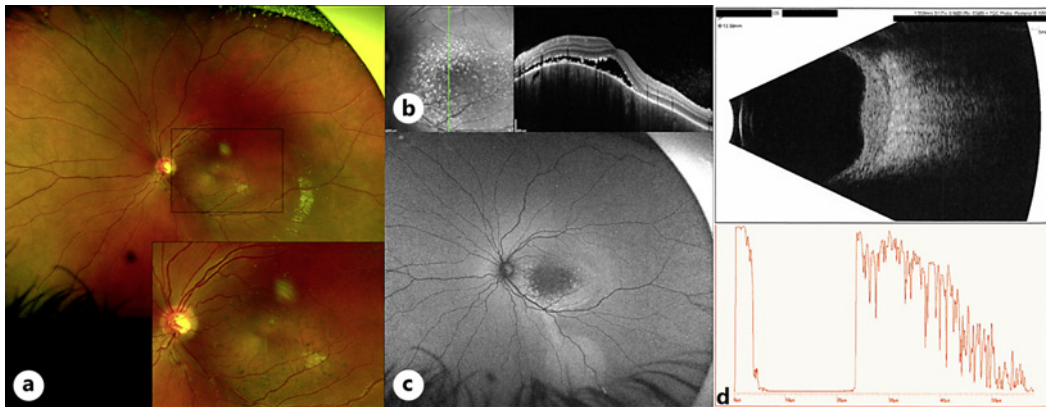


Fig. 2. Two years after initial presentation. **a** Fundus photograph of the left eye showing an elevated posterior pole with pigmentary changes in those areas. **b** Optical coherence tomography of the macula showing SRF, elongation of photoreceptor outer segments and precipitations over retinal pigment epithelium. **c** Fundus autofluorescence of the left eye showing hypo-autofluorescence of the central macula with mild ring of hyper-autofluorescence extending toward the inferior retina. **d** Ultrasound B-scan of left eye showing an echo-dense thickening of the choroid.

with a hyper-autofluorescent ring around the macula that extended to the inferior retina (shown in Fig. 2c). B-scan ultrasonography showed an echo-dense lesion contiguous to the disc approximately 3.5 mm in maximum thickness and 14 mm in diameter with high to medium internal reflectivity (shown in Fig. 2d).

The decision was made to treat with verteporfin PDT. Verteporfin infusion (Visudyne[®], Bausch & Lomb, Canada) was administered intravenously over 10 min at a pre-calculated dosage of 6 mg/cm² followed by a five-minute waiting period before application of 689-nm infrared laser light with fluence 50 J/cm² at intensity of 600 mW/cm² for 83 s. Five consecutive overlapping 5.5 mm spots were applied over the hemangioma using a Wide Field Mainster lens (Ocular Instruments Inc., Bellevue, WA, USA). At 6-week post-procedure, BCVA had improved to 20/40 in the left eye (from 20/150 on the day of the procedure), and on the dilated fundus exam, the macula was flat with no evidence of SRF. At the 1-year follow-up appointment, BCVA had improved to 20/25, and OCT showed a dramatic decrease in choroidal thickness and flattening of elevated posterior pole curvature with no recurrence of SRF (shown in Fig. 3a). However, hypopigmentation was evident in the entire treatment area with subretinal pigment clumps most noticeable in the areas with 3 overlapping exposures of PDT (shown in Fig. 3b).

Discussion

Multiple studies have demonstrated the safety and effectiveness of PDT for treatment of symptomatic circumscribed CH, leading to regression of the lesion, resolution of associated complications such as SRF, and improved visual outcomes. Improvement in BCVA is reported in most cases, including resolution to 20/20 in cases with visual impairment caused by secondary exudative macular detachment without significant retinal pigment epithelium alterations [4]. In the past two decades, PDT has become the gold standard treatment for CH, as prior treatment modalities such as proton beam radiotherapy, external beam radiotherapy, and plaque brachytherapy suffered from significant drawbacks including high cost, unavailability at many institutions, and unavoidable radiation damage to normal ocular tissues,

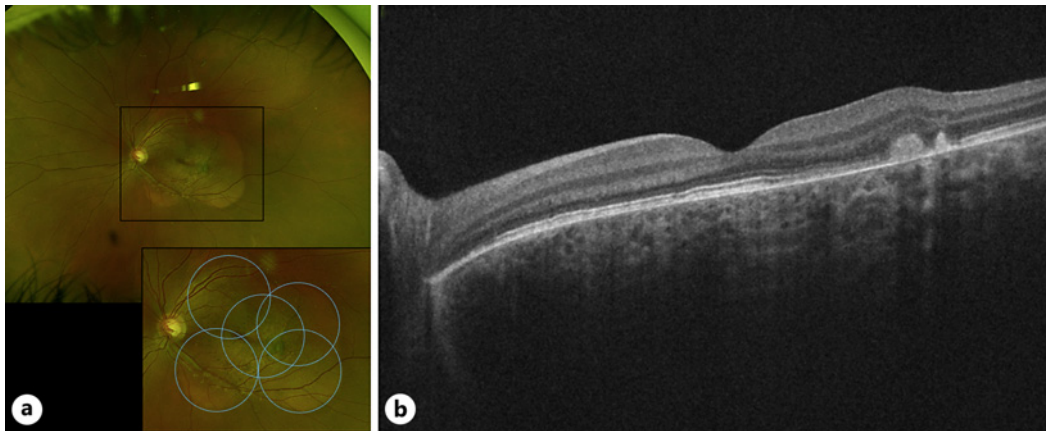


Fig. 3. One-year post-treatment. **a** OCTm of the left eye showing decreased choroidal thickness with subretinal hyper-reflective materials and resorbed SRF. **b** Fundus photograph of left eye showing hypopigmentation in treated areas with hyperpigmentation and subretinal bands in the areas with PDT treatment overlap (demarcated in blue).

with risk for radiation-induced cataract, retinopathy, and/or optic neuropathy [3]. Indeed, a study that compared outcomes in the PDT era (2002–2018) to the pre-PDT era (1967–2001) found that management options in the PDT era allowed for substantially better visual outcomes, with a mean final visual acuity of 20/63 versus 20/400, respectively [5].

The standard protocol involves intravenous verteporfin infusion at a pre-calculated dose of 6 mg/m² over 10 min followed by a 5-min waiting period before application of 689-nm infrared laser light with fluence 50 J/cm² at irradiance of 600 mW/cm² for 83 s with spot diameter up to a maximum of 7.5 mm. PDT has been performed using custom protocols that vary in verteporfin drug dosage (3, 6, or 12 mg/m²) and timing of infusion (bolus infusion over 1 min to reduce washout), duration (83 or 166 s) and intensity (300 or 600 mW/cm²) of laser application, number and size of treatment spots, and in the case of multispot treatment, the degree of overlap between spots [6]. Parameters have typically been adjusted to achieve half-fluence (radiant exposure of 25 J/cm²), which has shown sufficient benefit in treatment of central serious chorioretinopathy, or double-fluence (radiant exposure of 100 J/cm²) in the treatment of thicker lesions that may otherwise require retreatment [7, 8]. There can be multiple ways to achieve the same radiant exposure that leverage different underlying mechanisms. For example, a double-duration PDT can deliver the same 50 J/cm² light dose as standard PDT using 300 mW/cm² irradiance over 166 s, and an investigation by Papastefanou et al. [9] showed a greater improvement in visual acuity using this protocol versus standard PDT based on the hypothesis that blood flow through choroidal hemangiomas is relatively sluggish.

Overlapping multispot treatment may be the preferred method in the treatment of large circumscribed CH. Conventionally, a single spot is preferred if adequate to cover the tumor margin, with some clinicians opting to leave the portion remote from the fovea unexposed if the maximal spot size is close to the size of the tumor [10]. Otherwise, in the case of multispot treatment, overlapping spots have historically been avoided due to the theoretical risk of increased side effects [11]. A 2014 study conducted by Su et al. [3] showed no complications in overlapping treatment at the conventional 50 J/cm² light dose compared to single spot treatment, and more recent studies have suggested the superiority of the double-fluence protocol with 100% tumor regression and SRF resolution after a single treatment session with no need for retreatment, whereas previous cases utilizing the standard

protocol showed retreatment rates of 12–80% of cases [3, 8, 12]. Notably, choroidal ischemia and atrophy have typically been reported in cases requiring three or more sessions of PDT [8]. In our case, the overlap between two consecutive laser spots would represent a “double-fluence” treatment, and our specific strategy to overlap on the central areas of the tumor, which is thicker than the peripheral areas in circumscribed CH, may result in greater efficacy in tumor regression. Prior case reports involving overlapping treatment in CH have demonstrated success without significant evidence of increased fibrosis in areas of overlap, though Robertson [13] reported subtle evidence of subretinal fibrosis in 1 case requiring PDT retreatment and in a second case demonstrating late hyperfluorescence from the accumulation of dye in those areas, similar to our findings reported here in a case associated with SWS. Another case report of overlapping PDT treatment showed retinal pigment epithelium stippling and atrophy in the treated areas [13–15]. It is important to note that some degree of pigmentary changes, including hypopigmentation and residual mottling are also seen after standard, single spot PDT, and our results suggest an additive effect of these pigmentary changes after multispot overlapping PDT treatment, especially in the area with three overlapping exposures [14]. Fortunately, in our case, this did not seem to lead to an adverse visual outcome as it avoided the central visual axis, and our results suggest that areas of double exposure can safely be performed to maximize the effect of PDT in the case of CH.

In this case, our method of PDT treatment led to complete resolution of SRF and an excellent improvement in visual acuity to 20/25 after a single multispot treatment. Currently, at 18 months of follow-up, there has been no recurrence of SRF and serial OCT has been stable. Altogether, despite the lack of conclusive large-scale evidence, the safety profile of PDT as a treatment modality, review of other cases, and our experience suggest that overlapping multispot PDT has a significant role in the treatment of CH associated with SWS. However, the possibility of more subretinal changes following overlapping PDT spots may also be expected. The CARE Checklist has been completed by the authors for this case report, attached as an online supplementary material (for all online suppl. material, see <https://doi.org/10.1159/000535948>).

Statement of Ethics

Written informed consent was obtained from the parent of the patient for publication of the details of their medical case and any accompanying images. This report does not include any identifying patient information. All actions related to this study were performed in accordance with the World Medical Association Declaration of Helsinki. Ethical approval is not required for this study in accordance with local or national guidelines.

Conflict of Interest Statement

The authors have no conflicts of interest to declare.

Funding Sources

This study was not supported by any sponsor or funder. The authors acknowledge support from an unrestricted grant from Research to Prevent Blindness to the Gavin Herbert Eye Institute at the University of California, Irvine.

Author Contributions

A.Y.P., M.M.H., and M.R.E. drafted and edited the manuscript. S.M. and M.R.E. performed the medical treatment, conducted the follow-up of the patient, and critically reviewed the manuscript. All authors were involved in the conception and design of the manuscript as well as the acquisition and interpretation of data. All authors approved the final version of the manuscript and attest to meeting ICMJE criteria for authorship.

Data Availability Statement

All data generated or analyzed during this study are included in this article and its online supplementary material. Further inquiries can be directed to the corresponding author.

References

- 1 Sullivan TJ, Clarke MP, Morin JD. The ocular manifestations of the Sturge-Weber syndrome. *J Pediatr Ophthalmol Strabismus*. 1992;29(6):349–56. <https://doi.org/10.3928/0191-3913-19921101-05>.
- 2 Hassanpour K, Nourinia R, Gerami E, Mahmoudi G, Esfandiari H. Ocular manifestations of the sturge-weber syndrome. *J Ophthalmic Vis Res*. 2021;16(3):415–31. <https://doi.org/10.18502/JOVR.V16I3.9438>.
- 3 Su ZA, Tang XJ, Zhang LX, Su XH. Comparison of outcomes between overlapping-spot and single-spot photodynamic therapy for circumscribed choroidal hemangioma. *Int J Ophthalmol*. 2014;7(1):66–70. <https://doi.org/10.3980/j.issn.2222-3959.2014.01.12>.
- 4 Porrini G, Giovannini A, Amato G, Ioni A, Pantanetti M. Photodynamic therapy of circumscribed choroidal hemangioma. *Ophthalmology*. 2003;110(4):674–80. [https://doi.org/10.1016/S0161-6420\(02\)01968-1](https://doi.org/10.1016/S0161-6420(02)01968-1).
- 5 Shields CL, Dalvin LA, Lim LAS, Chang M, Udyaver S, Mazloumi M, et al. Circumscribed choroidal hemangioma: visual outcome in the pre-photodynamic therapy era versus photodynamic therapy era in 458 cases. *Ophthalmol Retina*. 2020;4(1):100–10. <https://doi.org/10.1016/j.oret.2019.08.004>.
- 6 Kumar A, Shankar S, Singh A, Mishra S, Kumar P, Arora A. Photodynamic therapy in the treatment of circumscribed choroidal hemangioma: current perspectives. *Photodiagnosis Photodyn Ther*. 2022;39:103000. <https://doi.org/10.1016/j.pdpdt.2022.103000>.
- 7 Lim SH, Chang W, Sagong M. Efficacy of half-fluence photodynamic therapy depending on the degree of choroidal hyperpermeability in chronic central serous chorioretinopathy. *Eye*. 2013;27(3):353–62. <https://doi.org/10.1038/eye.2013.13>.
- 8 Blasi MA, Tiberti AC, Scupola A, Balestrazzi A, Colangelo E, Valente P, et al. Photodynamic therapy with verteporfin for symptomatic circumscribed choroidal hemangioma: five-year outcomes. *Ophthalmology*. 2010;117(8):1630–7. <https://doi.org/10.1016/j.ophtha.2009.12.033>.
- 9 Papastefanou VP, Plowman PN, Reich E, Pavlidou E, Restori M, Hungerford JL, et al. Analysis of long-term outcomes of radiotherapy and verteporfin photodynamic therapy for circumscribed choroidal hemangioma. *Ophthalmol Retina*. 2018;2(8):842–57. <https://doi.org/10.1016/j.oret.2017.12.002>.
- 10 Michels S, Michels R, Simader C, Schmidt-Erfurth U. Verteporfin therapy for choroidal hemangioma: a long-term follow-up. *Retina*. 2005;25(6):697–703. <https://doi.org/10.1097/00006982-200509000-00003>.
- 11 Boixadera A, García-Arumí J, Martínez-Castillo V, Encinas JL, Elizalde J, Blanco-Mateos G, et al. Prospective clinical trial evaluating the efficacy of photodynamic therapy for symptomatic circumscribed choroidal hemangioma. *Ophthalmology*. 2009;116(5):822. Arumí, José García [corrected to García-Arumí, José]. *Ophthalmology*. 2009;116(1):100–105.e1. <https://doi.org/10.1016/j.ophtha.2008.08.029>.
- 12 Pellegrini M, Staurengi G, Mambretti M, Preziosa C. Double fluence photodynamic therapy for the treatment OF circumscribed choroidal hemangioma. *Retina*. 2022;42(4):767–74. <https://doi.org/10.1097/IAE.0000000000003373>.
- 13 Robertson DM. Photodynamic therapy for choroidal hemangioma associated with serous retinal detachment. *Arch Ophthalmol*. 2002;120(9):1155–61. <https://doi.org/10.1001/archophth.120.9.1155>.
- 14 Tsipursky MS, Golchet PR, Jampol LM. Photodynamic therapy of choroidal hemangioma in sturge-weber syndrome, with a review of treatments for diffuse and circumscribed choroidal hemangiomas. *Surv Ophthalmol*. 2011;56(1):68–85. <https://doi.org/10.1016/J.SURVOPHTHAL.2010.08.002>.
- 15 Singh AD, Kaiser PK, Sears JE, Gupta M, Rundle PA, Rennie IG. Photodynamic therapy of circumscribed choroidal haemangioma. *Br J Ophthalmol*. 2004;88(11):1414–8. <https://doi.org/10.1136/bjo.2004.044396>.