

UC San Diego

UC San Diego Previously Published Works

Title

Temozolomide and Pazopanib Combined with FOLFOX Regressed a Primary Colorectal Cancer in a Patient-derived Orthotopic Xenograft Mouse Model.

Permalink

<https://escholarship.org/uc/item/39v6v1s2>

Journal

Translational oncology, 13(3)

ISSN

1936-5233

Authors

Zhu, Guangwei
Zhao, Ming
Han, Qinghong
[et al.](#)

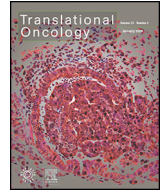Publication Date

2020-03-01

DOI

10.1016/j.tranon.2019.12.011

Peer reviewed



Temozolomide and Pazopanib Combined with FOLFOX Regressed a Primary Colorectal Cancer in a Patient-derived Orthotopic Xenograft Mouse Model

Guangwei Zhu^{a,b,c,d}, Ming Zhao^a, Qinghong Han^a, Yuying Tan^a, Yu Sun^{a,b}, Michael Bouvet^b, Bryan Clary^b, Shree Ram Singh^{e,*}, Jianxin Ye^{c,d,*}, Robert M. Hoffman^{a,b,*}

^a AntiCancer, Inc., San Diego, CA, USA

^b Department of Surgery, University of California, San Diego, CA, USA

^c Department of Gastrointestinal Surgery 2 Section, The First Hospital Affiliated to Fujian Medical University, Fuzhou 350005, China

^d Key Laboratory of Ministry of Education for Gastrointestinal Cancer, Fujian Medical University, Fuzhou 350000, China

^e Basic Research Laboratory, Center for Cancer Research, National Cancer Institute, Frederick, MD, 21702, USA

ARTICLE INFO

Article history:

Received 3 December 2019

Received in revised form 19 December 2019

Accepted 23 December 2019

Available online xxx

ABSTRACT

Purpose: The goal of the present study was to determine the efficacy of temozolomide (TEM) and pazopanib (PAZ) combined with FOLFOX (oxaliplatin, leucovorin and 5-fluorouracil) on a colorectal cancer patient-derived orthotopic xenograft (PDOX) mouse model. **Materials and Methods:** A colorectal cancer tumor from a patient previously established in non-transgenic nude mice was implanted subcutaneously in transgenic green fluorescence protein (GFP)-expressing nude mice in order to label the tumor stromal cells with GFP. Then labeled tumors were orthotopically implanted into the cecum of nude mice. Mice were randomized into four groups: Group 1, untreated control; group 2, TEM + PAZ; group 3, FOLFOX; group 4, TEM + PAZ plus FOLFOX. Tumor width, length, and mouse body weight were measured weekly. The Fluor Vivo imaging System was used to image the GFP-labeled tumor stromal cells in vivo. H&E staining and immunohistochemical staining were used for histological analysis. **Results:** All three treatments inhibited tumor growth as compared to the untreated control group. The combination of TEM + PAZ + FOLFOX regressed tumor growth significantly more effectively than TEM + PAZ or FOLFOX. Only the combination of TEM + PAZ + FOLFOX group caused a decrease in body weight. PAZ suppressed lymph vessels density in the colorectal cancer PDOX mouse model suggesting inhibition of lymphangiogenesis. **Conclusion:** Our results suggest that the combination of TEM + PAZ + FOLFOX has clinical potential for colorectal cancer patient.

Introduction

Surgical resection, radiotherapy and adjuvant chemotherapy are the main treatments for colorectal cancer [1]. Currently, oxaliplatin (OXA) in combination with 5-fluorouracil (5-FU) and leucovorin (LV), termed FOLFOX, showed response rates of more than 50% and increased the survival rate of colorectal cancer [2, 3]. The FOLFOX chemotherapy regimen has become first-line protocol for adjuvant treatment of colorectal cancer [4]. However, colon-cancer patients develop tumor recurrence [5–7]. Therefore, more effective therapy strategies are needed for advanced colorectal cancer.

To accomplish this goal, we have developed the patient-derived orthotopic xenograft (PDOX) nude mouse model for all cancer types [8–17]. To improve efficacy of chemotherapy on colorectal cancer patient,

the colorectal cancer PDOX and cell-line orthotopic nude-mouse models were developed [17–24].

Pazopanib (PAZ) is an orally-available, multi-targeted tyrosine kinase inhibitor of vascular endothelial growth factor receptors (VEGFRs), including VEGFR-1, VEGFR-2 and VEGFR-3, to which it has high affinity [25]. PAZ can inhibit the receptors of platelet-derived growth factor (PDGF), fibroblast growth factor (FGF) receptor and c-kit [26–28]. Bennouna et al. [29] reported that PAZ could be safely given in combination with irinotecan to patients with advanced colorectal cancer. Fu et al. [30] also showed that PAZ could be safe for patients with metastasis colorectal cancer in a Phase I study [30]. Zhang et al. [31] reported that PAZ directly inhibited colon cancer cells in vitro.

Temozolomide (TEM) is an oral alkylating agent with a broad spectrum of antitumor activity [32]. TEM targets methylation and induces apoptosis [32]. TEM has been used in the treatment of patients with glioblastoma [33, 34], metastatic melanoma [35] and pancreatic neuroendocrine tumors [36]. However, the use of TEM is controversial in colorectal cancer [37, 38].

In the present study, we identified a therapeutics strategy with the combination of TEM + PAZ + FOLFOX in a colorectal cancer PDOX nude-mouse model.

* Address all correspondence to: Robert M. Hoffman, AntiCancer, Inc, 7917 Ostrow St, San Diego, CA, 92111, U.S.A. or Jian-Xin Ye, Department of Gastrointestinal Surgery 2 Section, The First Hospital Affiliated to Fujian Medical University, Fuzhou, 350005, China. 20th, Chazhong Road, Fuzhou, Fujian 350005, China. or Shree Ram Singh, Basic Research Laboratory, National Cancer Institute, Frederick, MD, 21702, USA.

E-mail addresses: singhshr@mail.nih.gov, (S.R. Singh), yejianxinfuyi@126.com, (J. Ye), all@anticancer.com. (R.M. Hoffman).

Materials and Methods

Mice

In this study, transgenic green fluorescence protein (GFP)-expressing and non-transgenic athymic nu/nu mice, 4 to 6 weeks old, were used. All mice were obtained from AntiCancer Inc. (San Diego, CA, USA). Mouse housing, feeding, and surgical procedures were performed as previously described [16, 39, 40]. The mice were observed on a daily basis and humanely sacrificed as previously described [40]. All animal experiments were carried out in accordance with AntiCancer Inc. Institutional Animal Care and Use Committee (IACUC)-protocol specifically approved for this study, and in accordance with the principles and procedures outlined in the National Institutes of Health Guidelines for care and Use of Animals under Assurance Number A3873-1 [15] as previously described [40].

Patient-Derived Tumor

The primary colorectal cancer tumor samples were previously obtained in the Division of Surgical Oncology, University of California, San Diego (UCSD) from a patient who did not receive any chemotherapy or radiotherapy before surgery [22, 24]. Informed patient consent and Institutional Review Board (IRB) approval was obtained before surgery. Using the surgical orthotopic implantation (SOI) technique a colorectal cancer PDOX mouse model was established, as previously reported [41].

Establishment of an Imageable Colorectal Cancer PDOX Nude Mouse Model

Colorectal cancer tissues were cut into 5 mm³ fragments and seeded subcutaneously in nude mice. The colorectal cancer tumors grown in nude mice were then harvested, cut into 5 mm³ fragments, and implanted subcutaneously nude mice expressing green fluorescence protein [42, 43]. After two passages in GFP-expressing nude mice, colorectal cancer tumors containing GFP-expressing stromal cells, were harvested and cut into 5 mm³ fragments [44]. After that non-GFP-expressing nude mice were anesthetized with ketamine-mixed drug (20 mg/kg ketamine, 15.2 mg/kg xylazine, and 0.48 mg/kg acepromazine maleate), and an approximately 1 cm skin incision was made at the middle of the abdomen. A 5 mm³ tumor fragment was sutured on the cecum. The incision was closed using 6-0 nylon sutures as previously described [41]. The schematic diagram to establish a colorectal cancer PDOX model is shown in Figure 1A.

Treatment Study Design in the Colorectal Cancer PDOX Nude Mouse Model

Six weeks after orthotopic implantation of colorectal cancer-GFP tumors, the abdomen of the PDOX mice was opened to measure tumor growth. The PDOX mice were randomized into 4 groups (5 mice/per treatment group) by measuring tumor size: Group 1 (G1), control group (no treatment); Group 2 (G2), TEM + PAZ (TEM 25 mg/kg, oral; PAZ 50 mg/kg, oral, daily for 3 weeks); Group 3 (G3), FOLFOX (OXA 6 mg/kg, ip., LV 90 mg/kg, ip.; 5-FU 50 mg/kg, ip.; weekly for 2 weeks); Group 4 (G4), TEM + PAZ + FOLFOX (TEM 25 mg/kg, oral; PAZ 50 mg/kg, oral, daily for 3 weeks; OXA 6 mg/kg, ip., LV 90 mg/kg, ip.; 5-FU 50 mg/kg, ip.; weekly for 2 weeks) (Figure 1B). Tumor length, width and mouse body weight was measured once per week. Tumor volume was calculated with the following formula: Tumor volume (mm³) = length (mm) × width (mm) × width (mm)/2. Data are presented as mean ± standard deviation (SD). Mice were imaged with the FluorVivo imaging system (INDEC Bio Systems, Santa Cruz, CA, USA.) [45].

Hematoxylin and Eosin (H&E) Staining

Before sectioning and staining, fresh tumor samples were fixed in 10% formalin and embedded in paraffin. Tumor tissue sections (4 μm) slices were deparaffinized in xylene and rehydrated in an ethanol series. Hematoxylin and eosin (H&E) staining was performed according to a standard

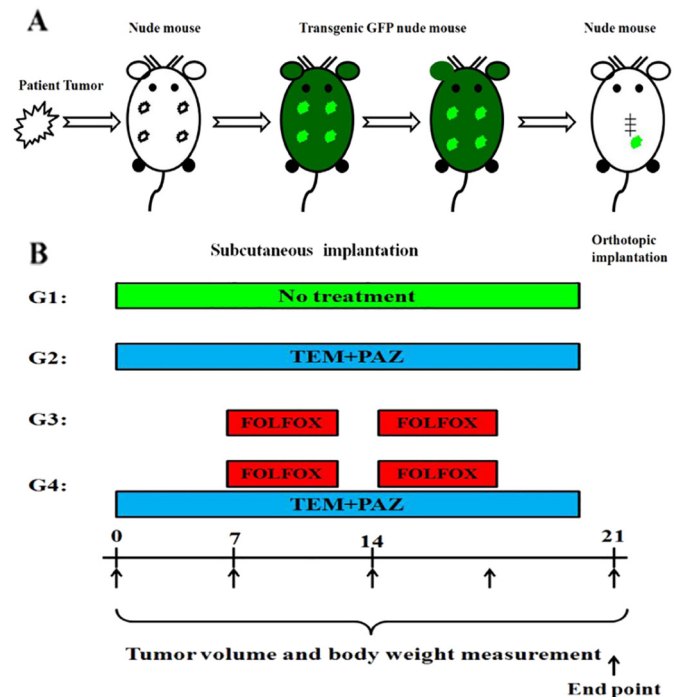


Figure 1. Establishment of an imageable patient-derived orthotopic xenograft (PDOX) model of colon cancer and the drug treatment schema. (A) Schematic illustration of subcutaneous and surgical orthotopic implantation (SOI) to establish an imageable PDOX (iPDOX) model of human colorectal cancer. (B) Treatment regimen and quantitative drug efficacy. Treatment protocol. G1: untreated control; G2: treated with TEM + PAZ (TEM 25 mg/kg, oral; PAZ 50 mg/kg, oral, daily for 3 weeks); G3: treated with FOLFOX (OXA 6 mg/kg, ip., LV 90 mg/kg, ip.; 5-FU 50 mg/kg, ip.; weekly for 2 weeks); G4: treated with TEM + PAZ + FOLFOX (TEM 25 mg/kg, oral; PAZ 50 mg/kg, oral, daily for 3 weeks; OXA 6 mg/kg, ip., LV 90 mg/kg, ip.; 5-FU 50 mg/kg, ip.; weekly for 2 weeks). All treated mice were sacrificed on the endpoint day, and tumors were resected for further histological accession.

protocol. Histological observation and imaging was carried out with a BHS microscope system (Olympus Corporation, Tokyo, Japan) and images were analyzed with INFINITY ANALYZE software (Lumenera Corporation, Ottawa, Canada) [46].

Immunohistochemistry (IHC) and Evaluation

4-μm-thick serial sections were deparaffinized in xylene and rehydrated in ethanol series. Antigen retrieval was performed by heating in sodium citrate (pH 6.0) and then blocked by non-specific antigen. Thereafter, primary rabbit polyclonal anti-mouse LYVE-1 antibody (1:400, Abcam, Cambridge, MA, USA) was incubated with slices overnight in a humidified box at 4 °C, followed by incubation with biotinylated goat anti-polyvalent. Sections were incubated with streptavidin peroxidase for 10 min in DAB for 1–8 min, and in hematoxylin for 2 min. All steps were performed in accordance with the protocol of a rabbit specific HRP/DAB (ABC) detection IHC kit (Abcam, Cambridge, MA, USA) at room temperature. Lymphatic vessels counting was carried out as previously described [47]. Specimens were imaged with a BHS system microscope. Images were analyzed with INFINITY ANALYZE software (Lumenera Corporation, Ottawa, Canada).

Statistical Analysis

All statistical analyses were performed using GraphPad Prism 5 software (GraphPad Software, Inc. La Jolla, CA, USA). The one-way analysis of variance (ANOVA) with Tukey's post hoc test was used when more than two groups were compared. The paired t-test was used for the parametric test to compare the means between two related groups. The data

are expressed as the mean \pm SD. A *P*-value of less than 0.05 or less is considered statistically significant.

Results

Drug Efficacy on the Colorectal Cancer PDOX

At the endpoint of treatment, the tumor volumes were: G1, untreated control, $540 \pm 110.5 \text{ mm}^3$; G2, TEM + PAZ, $293.8 \pm 17.8 \text{ mm}^3$; G3, FOLFOX, $268.6 \pm 46.2 \text{ mm}^3$; G4, TEM + PAZ + FOLFOX, $102.8 \pm 11.1 \text{ mm}^3$. The untreated control group (G1) tumors grew approximately 5 times larger compared to initiation of treatment. In the TEM + PAZ (G2) and FOLFOX groups, at the end point, there was a significant inhibition in tumor growth compared to the control group ($P < 0.001$). The TEM + PAZ + FOLFOX combination group (G4) significantly regressed tumor growth compared to the control group $P < 0.001$ (Figure 2). The TEM + PAZ + FOLFOX group (G4) had a greater inhibition of tumor growth than the TEM + PAZ group (G2) or FOLFOX group (G3) ($P < 0.01$) (Figure 2).

Effect of Treatment on Body Weight

To determine whether the drug treatments had an effect on body weight, we measured the mouse body weight pre-treatment and post-treatment. Final body weight of mice in the untreated control group increased compared to the initial body weight ($P < 0.05$) (Figure 3). Mice treated with TEM + PAZ + FOLFOX also decreased their body weight compared to the initial body weight ($P < 0.05$) (Figure 3). There was no significant difference in body weight among the TEM + PAZ and FOLFOX groups (Figure 3). There were no animal deaths in any group.

Tumor Histology Analysis Colorectal Cancer PDOX

Histologically, the control group tumor mainly comprised viable cancer cells (Figure 4A). In the tumors treated with FOLFOX, the cancer-cell density was lower than the TEM + PAZ group (Figure 4, B and C). In all treated groups (G2, G3 and G4), cancer-cell density was lower than the control (Figure 4, B–D). The strongest reduction in cancer cell density was observed

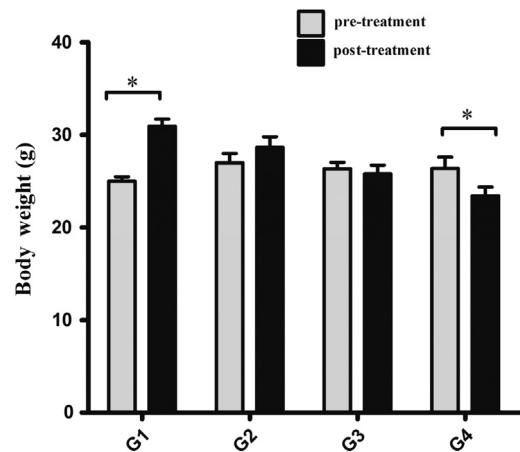


Figure 3. Effect of drugs on mouse body weight. Bar graph shows body weight in each group at pre-treatment and post-treatment. $n = 5$ mice/group. * $P < .05$.

when colorectal cancer PDOX tumors were treated with the combination of TEM + PAZ + FOLFOX (Figure 4D).

PAZ Inhibited the Lymphatic Vessel Density (LVD) and Lymphangiogenesis in the Colorectal Cancer PDOX Mouse Model

The lymphatic vessel density (LVD) and lymphangiogenesis of colorectal cancer PDOX tumors were marked by LYVE-1 antibodies using immunohistochemical staining. Tumors treated with PAZ in G2 and G4 groups had a significantly lower lymphatic vessel density (LVD) compared to groups G1 and G3 ($P < 0.01$) (Figure 5). These results suggest that PAZ could inhibit lymphangiogenesis of colorectal cancer in a PDOX mouse model.

Discussion

Although FOLFOX is first-line treatment for colorectal cancer, there is still recurrence and metastasis of tumors due to resistance to OXA or 5-FU [48]. Several studies showed that TEM [49, 50] and PAZ [30,

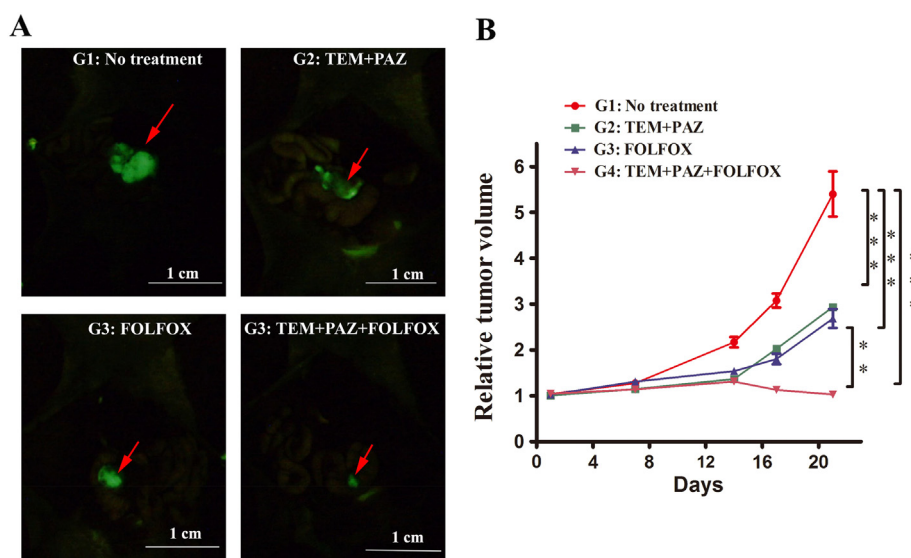


Figure 2. Imaging PDOX tumors treated with each drug, and quantitative efficacy of chemotherapy on the colorectal cancer PDOX model. Images of representative PDOX mouse models from each group at the endpoint. Arrows indicate GFP-expressing tumor stromal cells. (A) G1: untreated control; G2: treated with TEM + PAZ; G3: treated with FOLFOX; G4: treated with TEM + PAZ + FOLFOX. The FluorVivo imaging System was used. (B) Line graphs indicate relative tumor volume (ratio tumor volume at each time point to volume at initiation of treatment) for each drug and control group. $n = 5$ mice/group. ** $P < 0.01$; *** $P < 0.001$.

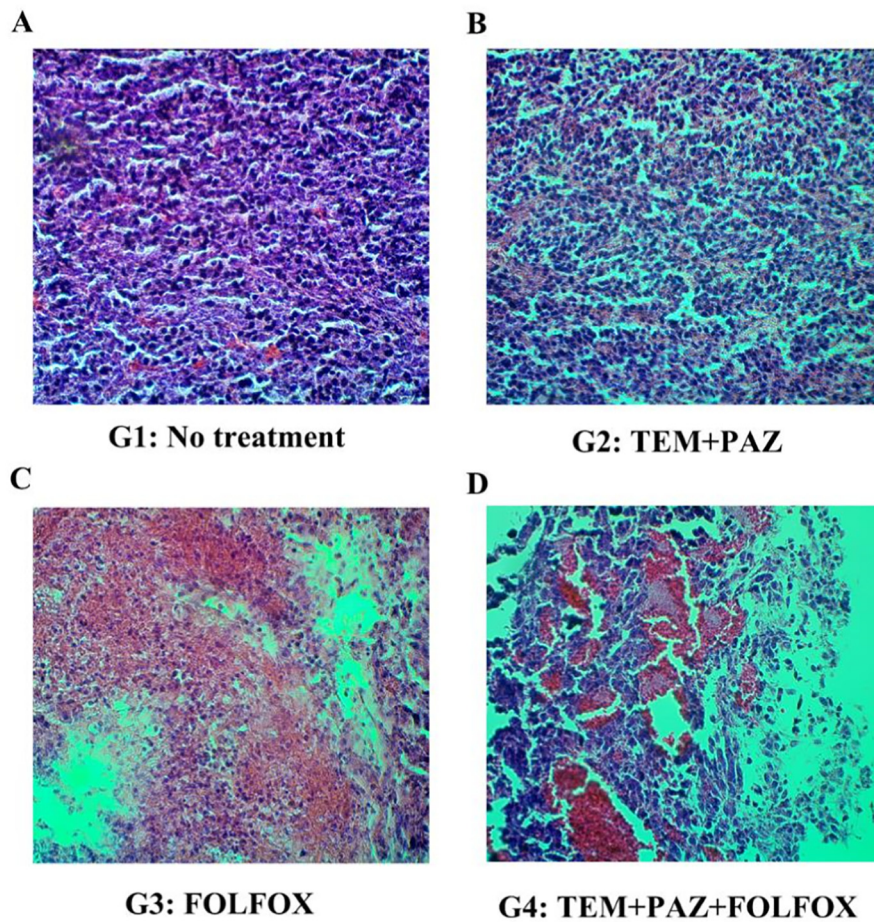


Figure 4. Histology of colorectal cancer PDOX mouse model in treated and untreated tumors. Hematoxylin and eosin (H&E)-stained sections of the (A) Untreated control group. (B) TEM + PAZ-treated group. (C) FOLFOX-treated group, and (D) TEM + PAZ + FOLFOX-treated group. Microscope magnification 200 ×.

31] could effectively inhibit the progression of colorectal cancer. In the present study, we found that TEM and PAZ combined with FOLFOX can regress a colorectal cancer in a PDOX mouse model. This is the first

study which shows that the TEM + PAZ + FOLFOX combination is effective in colorectal cancer using a colorectal cancer PDOX mouse model.

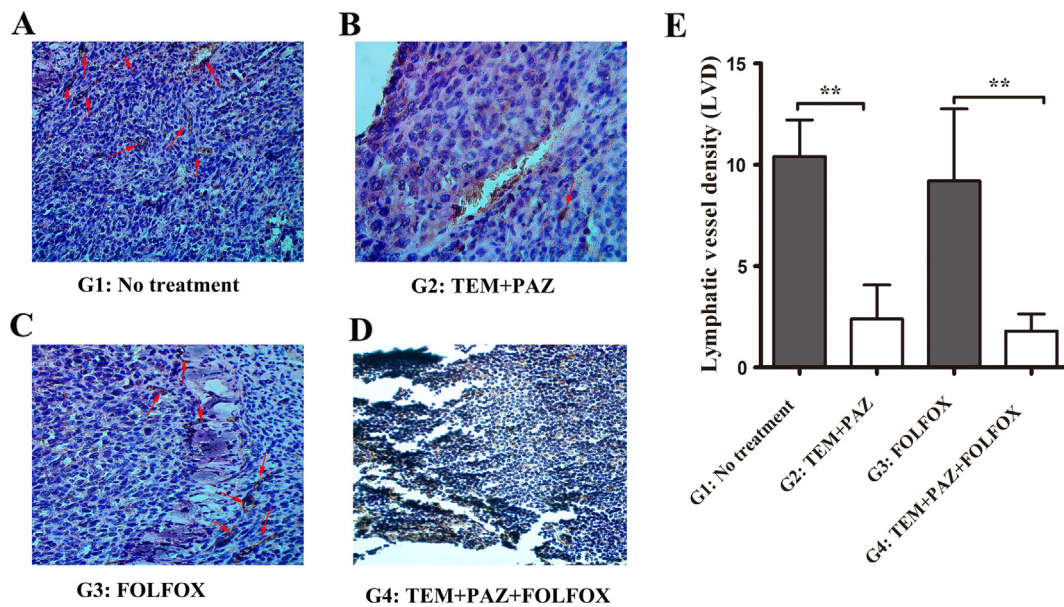


Figure 5. PAZ inhibits lymphangiogenesis of a colorectal cancer PDOX mouse model. (A) Representative lymphatic vessel stained with endothelial hyaluronin receptor 1 (LYVE-1) in the control group. (B) Lymphatic vessels stained in TEM + PAZ group. (C) Lymphatic vessels stained in FOLFOX group. (D) Lymphatic vessels stained in TEM + PAZ + FOLFOX group. (E) Bars with LYVE-1 lymphatic vessel staining density. Arrows indicate lymphatic vessels. Magnification 200 ×. ***P* < 0.01.

TEM is easily absorbed in the digestive tract after oral administration with bioavailability almost 100%. TEM has been approved for glioblastoma [51, 52], sarcoma [53, 54] as well as melanoma [35]. We previously reported that TEM was effective in PDOX mouse models of sarcoma and melanoma [40, 55–65].

We previously also reported that PAZ was effective in PDOX model of sarcomas [46, 61–63]. PAZ has a high affinity with VEGFR-1/2/3, which can inhibit the signaling pathway induced by VEGFRs and regulate corresponding physiological functions [25]. We found that the LYVE-1 staining was reduced in the G2 and G4 groups compared to the G1 and G3 groups, suggesting that PAZ could inhibit the lymphangiogenesis.

Our results suggest that the TEM + PAZ + FOLFOX combination has clinical potential for patient with colorectal cancer and also show the importance of PDOX models for individualized therapy. The detection of the PDOX model was increased by initial growth of the tumor in transgenic nude mice expression a fluorescent protein [42–44].

The reduction in lymphangiogenesis and no death in the treated groups suggest that the combination of TEM + PAZ + FOLFOX is superior. However, we have not tested the survival within the treated groups. However, based on the final tumor volume, high efficacy is very clear in that combination of TEM + PAZ + FOLFOX regressed the tumor. Survival studies will be done in future experiments.

Conclusions

Our results together suggest that TEM + PAZ + FOLFOX combination is a novel effective treatment for colorectal cancer in a PDOX mouse model. We also found that therapy regimen including PAZ could inhibit lymphangiogenesis in the colorectal cancer PDOX mouse model.

Conflicts of interest

GZ, YS and RMH are unpaid affiliates of AntiCancer Inc. MZ, YT and QH are employees of AntiCancer Inc. AntiCancer Inc. uses PDOX models for contract research. The authors declare no conflicts of interest regarding this study.

Acknowledgements

This study was supported by the National Natural Science Foundation of China (No.81702424 and 81872364), The Joint Funds for the Innovation of Science and Technology, Fujian Province (No.2017Y9092), The Fujian Provincial Health Department Young and Middle-aged Talents Training Project (No.2018-ZQN-46), The Project of Science and Technology Research Program in Fujian Province (No. 2016B044), the National Clinical Key Specialty Construction Project (General Surgery) of China. This paper is dedicated to the memory of A.R. Moossa, MD, Sun Lee, MD, Professor Li Jiayi, and Masaki Kitajima, MD.

Author's Contributions

GZ and JY designed the study, and wrote the draft manuscript; GZ, MZ, QH and YS performed the experiments; SRS and RMH revised the manuscript. All authors approved the final manuscript.

References

- [1] K. De Greef, C. Rolfo, A. Russo, T. Chapelle, G. Bronte, F. Passiglia, A. Coelho, K. Papadimitriou, M. Peeters, Multidisciplinary management of patients with liver metastases from colorectal cancer, *World J Gastroenterol* 22 (2016) 7215–7225.
- [2] A.D. Yang, F. Fan, E.R. Camp, G. van Buren, W. Liu, R. Somcio, M.J. Gray, H. Cheng, P. M. Hoff, L.M. Ellis, Chronic oxaliplatin resistance induces epithelial-to-mesenchymal transition in colorectal cancer cell lines, *Clin Cancer Res* 12 (2006) 4147–4153.
- [3] S.R. Alberts, W.L. Horvath, W.C. Sternfeld, R.M. Goldberg, M.R. Mahoney, S.R. Dakhil, R. Levitt, K. Rowland, S. Nair, D.J. Sargent, J.H. Donohue, Oxaliplatin, fluorouracil, and leucovorin for patients with unresectable liver-only metastases from colorectal cancer: a North Central Cancer Treatment Group phase II study, *J Clin Oncol* 23 (2005) 9243–9249.
- [4] Y. Yamada, D. Takahari, H. Matsumoto, H. Baba, M. Nakamura, K. Yoshida, M. Yoshida, S. Swamoto, K. Shimada, Y. Komatsu, Y. Sasaki, T. Satoh, K. Takahashi, H. Mishima, K. Muro, M. Watanabe, Y. Sakata, S. Morita, Y. Shimada, K. Sugihara, Leucovorin, fluorouracil, and oxaliplatin plus bevacizumab versus S-1 and oxaliplatin plus bevacizumab in patients with metastatic colorectal cancer (SOFT): an open-label, non-inferiority, randomised phase 3 trial, *Lancet Oncol* 14 (2013) 1278–1286.
- [5] R.M. Goldberg, D.J. Sargent, R.F. Morton, C.S. Fuchs, R.K. Ramanathan, S.K. Williamson, B.P. Findlay, H.C. Pitot, S.R. Alberts, A randomized controlled trial of fluorouracil plus leucovorin, irinotecan, and oxaliplatin combinations in patients with previously untreated metastatic colorectal cancer, *J Clin Oncol* 22 (2004) 23–30.
- [6] P. Nangia-Makker, Y. Yu, A. Vasudevan, L. Farhana, S.G. Rajendra, E. Levi, A.P. Majumdar, Metformin: a potential therapeutic agent for recurrent colon cancer, *PLoS one* 9 (2014), e84369.
- [7] J. Nautiyal, S.S. Kanwar, Y. Yu, A.P. Majumdar, Combination of dasatinib and curcumin eliminates chemo-resistant colon cancer cells, *J Mol Signl* 6 (2011) 7.
- [8] R.M. Hoffman, Patient-derived orthotopic xenografts: better mimic of metastasis than subcutaneous xenografts, *Nat Rev Cancer* 15 (2015) 451–452.
- [9] Y. Hiroshima, A.A. Maawy, M.H. Katz, J.B. Fleming, M. Bouvet, I. Endo, R.M. Hoffman, Selective efficacy of zoledronic acid on metastasis in a patient-derived orthotopic xenograft (PDOX) nude-mouse model of human pancreatic cancer, *J Surg Oncol* 111 (2015) 311–315.
- [10] Y. Hiroshima, Y. Zhang, N. Zhang, A. Maawy, S. Mii, M. Yamamoto, F. Uehara, S. Miwa, S. Yano, T. Murakami, et al., Establishment of a patient-derived orthotopic Xenograft (PDOX) model of HER-2-positive cervical cancer expressing the clinical metastatic pattern, *PLoS one* 10 (2015), e0117417.
- [11] Y. Hiroshima, Y. Zhang, N. Zhang, F. Uehara, A. Maawy, T. Murakami, S. Mii, M. Yamamoto, S. Miwa, S. Yano, et al., Patient-derived orthotopic xenograft (PDOX) nude mouse model of soft-tissue sarcoma more closely mimics the patient behavior in contrast to the subcutaneous ectopic model, *Anticancer Res* 35 (2015) 697–701.
- [12] Y. Hiroshima, M. Zhao, A. Maawy, Y. Zhang, M.H. Katz, J.B. Fleming, F. Uehara, S. Miwa, S. Yano, M. Momiyama, et al., Efficacy of Salmonella typhimurium A1-R versus chemotherapy on a pancreatic cancer patient-derived orthotopic xenograft (PDOX), *J Cell Biochem* 115 (2014) 1254–1261.
- [13] R.M. Hoffman, Patient-Derived Orthotopic Xenograft (PDOX) Models of Melanoma, *Int J Mol Sci* 18 (2017).
- [14] T. Murakami, T. Murata, K. Kawaguchi, T. Kiyuna, K. Igarashi, H.K. Hwang, Y. Hiroshima, C. Hozumi, S. Komatsu, T. Kikuchi, et al., Cervical cancer patient-derived orthotopic xenograft (PDOX) is sensitive to cisplatin and resistant to Nab-paclitaxel, *Cell cycle* 37 (2017) 61–65.
- [15] K. Kawaguchi, K. Igarashi, T. Murakami, T. Kiyuna, S.D. Nelson, S.M. Dry, Y. Li, T.A. Russell, A.S. Singh, B. Chmielowski, et al., Combination of gemcitabine and docetaxel regresses both gastric leiomyosarcoma proliferation and invasion in an imageable patient-derived orthotopic xenograft (iPDOX) model, *Cell Cycle* 16 (2017) 1063–1069.
- [16] T. Murakami, A.S. Singh, T. Kiyuna, S.M. Dry, Y. Li, A.W. James, K. Igarashi, K. Kawaguchi, J.C. DeLong, Y. Zhang, et al., Effective molecular targeting of CDK4/6 and IGF-1R in a rare FUS-ERG fusion CDKN2A-deletion doxorubicin-resistant Ewing's sarcoma patient-derived orthotopic xenograft (PDOX) nude-mouse model, *Oncotarget* 7 (2016) 47556–47564.
- [17] Y. Hiroshima, A. Maawy, C.A. Metildi, Y. Zhang, F. Uehara, S. Miwa, S. Yano, S. Sato, T. Murakami, M. Momiyama, et al., Successful fluorescence-guided surgery on human colon cancer patient-derived orthotopic xenograft mouse models using a fluorophore-conjugated anti-CEA antibody and a portable imaging system, *J Laparoendosc Adv Surg Tech A* 24 (2014) 241–247.
- [18] A. Bhattacharya, S.G. Turowski, L.D. San Martin, A. Rajput, Y.M. Rustum, R.M. Hoffman, M. Seshadri, Magnetic resonance and fluorescence-protein imaging of the anti-angiogenic and anti-tumor efficacy of selenium in an orthotopic model of human colon cancer, *Anticancer Res* 31 (2011) 387–393.
- [19] Y. Ishihara, K. Matsunaga, H. Iijima, G. Hasegawa, T. Suzuki, A. Sato, T. Kobayashi, M. Yang, R.M. Hoffman, The combination of 5-FU, leucovorin and CPT-11 (FOLFIRI) prolongs survival through inhibition of metastasis in an orthotopic model of colon cancer, *Anticancer Res* 30 (2010) 403–408.
- [20] Y. Ji, K. Hayashi, Y. Amoh, K. Tsuji, K. Yamauchi, N. Yamamoto, H. Tsuchiya, K. Tomita, M. Bouvet, R.M. Hoffman, The camptothecin derivative CPT-11 inhibits angiogenesis in a dual-color imageable orthotopic metastatic nude mouse model of human colon cancer, *Anticancer Res* 27 (2007) 713–718.
- [21] H. Ma, T. Das, S. Pereira, Z. Yang, M. Zhao, P. Mukerji, R.M. Hoffman, Efficacy of dietary antioxidants combined with a chemotherapeutic agent on human colon cancer progression in a fluorescent orthotopic mouse model, *Anticancer Res* 29 (2009) 2421–2426.
- [22] J.H. Park, M. Zhao, H. Oshiro, K. Miyake, T. Higuchi, J. Reynoso, S. Razmjooei, M. Bouvet, B. Clary, Z. Zhang, Peritoneal metastases in a patient-derived orthotopic xenograft (PDOX) model of colon cancer imaged non-invasively via red fluorescent protein labeled stromal cells, *Anticancer Res* 39 (2019) 3463–3467.
- [23] S.N. Yoon, J.H. Park, T.M. Lwin, K. Miyake, S.R. Singh, R.M. Hoffman, M. Bouvet, Tumor-sealing surgical orthotopic implantation of human colon cancer in nude mice induces clinically-relevant metastases without early peritoneal carcinomatosis, *Anticancer Res* 39 (2019) 4065–4071.
- [24] J.H. Park, M. Zhao, Q. Han, Y. Sun, T. Higuchi, N. Sugisawa, J. Yamamoto, S.R. Singh, B. Clary, M. Bouvet, R.M. Hoffman, Efficacy of oral recombinant methioninase combined with oxaliplatin and 5-fluorouracil on primary colon cancer in a patient-derived orthotopic xenograft mouse model, *Biochem Biophys Res Commun* 518 (2019) 306–310.
- [25] FA Schutz, TK Choueiri, CN Sternberg, Pazopanib: clinical development of a potent anti-angiogenic drug, *Crit Rev Oncol Hematol* 77 (2011) 163–171.
- [26] P.A. Harris, A. Boloor, M. Cheung, R. Kumar, R.M. Crosby, R.G. Davis-Ward, A.H. Epperly, K.W. Hinkle, et al., Discovery of 5-[[4-[(2,3-dimethyl-2H-indazol-6-yl)methylamino]-2-pyrimidinyl]amino]-2-methyl-benzene-sulfonamide (Pazopanib), a

- novel and potent vascular endothelial growth factor receptor inhibitor, *J Med Chem* 51 (2008) 4632–4640.
- [27] J. Paesler, I. Gehrke, R.K. Gandhirajan, A. Filipovich, M. Hertweck, F. Erdfelder, S. Uhrmacher, S.J. Poll-Wolbeck, M. Hallek, K.A. Kreuzer, et al., The vascular endothelial growth factor receptor tyrosine kinase inhibitors vatalanib and pazopanib potently induce apoptosis in chronic lymphocytic leukemia cells in vitro and in vivo, *Clin Cancer Res* 16 (2010) 3390–3398.
- [28] P. Schoffski, Pazopanib in the treatment of soft tissue sarcoma, *Expert Rev Anticancer Ther* 12 (2012) 711–723.
- [29] J. Bennouna, M. Deslandres, H. Senellart, C. de Labareyre, R. Ruiz-Soto, C. Wixon, J. Bothy, A.B. Suttle, J.P. Delord, A phase I open-label study of the safety, tolerability, and pharmacokinetics of pazopanib in combination with irinotecan and cetuximab for relapsed or refractory metastatic colorectal cancer, *Invest New Drugs* 33 (2015) 138–147.
- [30] S. Fu, M.M. Hou, A. Naing, F. Janku, K. Hess, R. Zinner, V. Subbiah, D. Hong, J. Wheler, S. Piha-Paul, et al., Phase I study of pazopanib and vorinostat: a therapeutic approach for inhibiting mutant p53-mediated angiogenesis and facilitating mutant p53 degradation, *Ann Oncol* 26 (2015) 1012–1018.
- [31] L. Zhang, H. Wang, W. Li, J. Zhong, R. Yu, X. Huang, H. Wang, Z. Tan, J. Wang, Y. Zhang, Pazopanib, a novel multi-kinase inhibitor, shows potent antitumor activity in colon cancer through PUMA-mediated apoptosis, *Oncotarget* 8 (2017) 3289–3303.
- [32] ES Newlands, MF Stevens, SR Wedge, RT Wheelhouse, C Brock, Temozolomide: a review of its discovery, chemical properties, pre-clinical development and clinical trials, *Cancer Treat Rev* 23 (1997) 35–61.
- [33] U Linz, Commentary on Effects of radiotherapy with concomitant and adjuvant temozolomide versus radiotherapy alone on survival in glioblastoma in a randomised phase III study: 5-year analysis of the EORTC-NCIC trial (*Lancet Oncol.* 2009;10:459-466), *Cancer* 116 (2010) 1844–1846.
- [34] R. Stupp, W.P. Mason, M.J. vanden Bent, M. Weller, B. Fisher, M.J. Taphoorn, K. Belanger, A.A. Brandes, C. Marosi, U. Bogdahn, et al., Radiotherapy plus concomitant and adjuvant temozolomide for glioblastoma, *N Engl J Med* 352 (2005) 987–996.
- [35] M.R. Middleton, J.J. Grob, N. Aaronson, G. Fierlbeck, W. Tilgen, S. Seiter, M. Gore, S. Aamdal, J. Cebon, A. Coates, et al., Randomized phase III study of temozolomide versus dacarbazine in the treatment of patients with advanced metastatic malignant melanoma, *J Clin Oncol* 18 (2000) 158–166.
- [36] J.A. Chan, K. Stuart, C.C. Earle, J.W. Clark, P. Bhargava, R. Miksad, L. Blaszkowsky, P.C. Enzinger, J.A. Meyerhardt, H. Zheng, et al., Prospective study of bevacizumab plus temozolomide in patients with advanced neuroendocrine tumors, *J Clin Oncol* 30 (2012) 2963–2968.
- [37] M.A. Calegari, A. Inno, S. Monterisi, A. Orlandi, D. Santini, M. Basso, A. Cassano, M. Martini, T. Cenci, I. de Pascalis, et al., A phase 2 study of temozolomide in pretreated metastatic colorectal cancer with MGMT promoter methylation, *Br J Cancer* 116 (2017) 1279–1286.
- [38] M.J. Pishvaian, R.S. Slack, W. Jiang, A.R. He, J.J. Hwang, A. Hankin, K. Dorsch-Vogel, D. Kukadiya, L.M. Weiner, J.L. Marshall, J.R. Brody, A phase 2 study of the PARP inhibitor veliparib plus temozolomide in patients with heavily pretreated metastatic colorectal cancer, *Cancer* 124 (2018) 2337–2346.
- [39] K. Miyake, T. Kiyuna, M. Miyake, K. Kawaguchi, Z. Zhang, S. Wangsiricharoen, S. Razmjooei, H. Oshiro, T. Higuchi, Y. Li, et al., Gemcitabine combined with docetaxel precisely regressed a recurrent leiomyosarcoma peritoneal metastasis in a patient-derived orthotopic xenograft (PDOX) model, *Biochem Biophys Res Commun* 509 (2019) 1041–1046.
- [40] K. Igarashi, K. Kawaguchi, T. Kiyuna, K. Miyake, M. Miyake, Y. Li, S.D. Nelson, S.M. Dry, A.S. Singh, I.A. Elliott, Temozolomide regresses a doxorubicin-resistant undifferentiated spindle-cell sarcoma patient-derived orthotopic xenograft (PDOX): precision-oncology nude-mouse model matching the patient with effective therapy, *J Cell Biochem* 119 (2018) 6598–6603.
- [41] XY Fu, JM Besterman, A Monosov, RM Hoffman, Models of human metastatic colon cancer in nude mice orthotopically constructed by using histologically intact patient specimens, *PNAS* 88 (1991) 9345–9349.
- [42] M Yang, J Reynoso, P Jiang, L Li, AR Moossa, RM Hoffman, Transgenic nude mouse with ubiquitous green fluorescent protein expression as a host for human tumors, *Cancer Res* 64 (2004) 8651–8656.
- [43] M Yang, J Reynoso, M Bouvet, RM Hoffman, A transgenic red fluorescent protein-expressing nude mouse for color-coded imaging of the tumor microenvironment, *J Cell Biochem* 106 (2009) 279–284.
- [44] A. Suetsugu, M. Katz, J. Fleming, M. Truty, R. Thomas, H. Moriwaki, M. Bouvet, S. Saji, R.M. Hoffman, Multi-color palette of fluorescent proteins for imaging the tumor microenvironment of orthotopic tumorgraft mouse models of clinical pancreatic cancer specimens, *J Cell Biochem* 113 (2012) 2290–2295.
- [45] H. Oshiro, T. Kiyuna, Y. Tome, K. Miyake, K. Kawaguchi, T. Higuchi, M. Miyake, Z. Zhang, S. Razmjooei, M. Barangi, et al., Detection of metastasis in a patient-derived orthotopic xenograft (PDOX) model of undifferentiated pleomorphic sarcoma with red fluorescent protein, *Anticancer Res* 39 (2019) 81–85.
- [46] K. Igarashi, K. Kawaguchi, T. Murakami, T. Kiyuna, K. Miyake, A.S. Singh, S.D. Nelson, S.M. Dry, Y. Li, N. Yamamoto, et al., High efficacy of pazopanib on an undifferentiated spindle-cell sarcoma resistant to first-line therapy is identified with a patient-derived orthotopic xenograft (PDOX) nude mouse model, *J Cell Biochem* 118 (2017) 2739–2743.
- [47] G. Zhu, Q. Du, X. Chen, X. Wang, N. Tang, F. She, Y. Chen, Receptor-interacting serine/threonineprotein kinase 1 promotes the progress and lymph metastasis of gallbladder cancer, *Oncol Rep* 42 (2019) 2435–2449.
- [48] P. Li, X. Zhang, H. Wang, L. Wang, T. Liu, L. Du, Y. Yang, C. Wang, MALAT1 is associated with poor response to oxaliplatin-based chemotherapy in colorectal cancer patients and promotes chemoresistance through EZH2, *Mol Cancer Ther* 16 (2017) 739–751.
- [49] C.A. Delaney, L.Z. Wang, S. Kyle, A.W. White, A.H. Calvert, N.J. Curtin, B.W. Durkacz, Z. Hostomsky, D.R. Newell, et al., Potentiation of temozolomide and topotecan growth inhibition and cytotoxicity by novel poly(adenosine diphosphoribose) polymerase inhibitors in a panel of human tumor cell lines, *Clin Cancer Res* 6 (2000) 2860–2867.
- [50] J.R. Kouvaris, A. Miliadou, V.E. Kouloulias, D. Kolokouris, M.J. Balafouta, X.N. Papacharalampous, L.J. Vlahos, Phase II study of temozolomide and concomitant whole-brain radiotherapy in patients with brain metastases from solid tumors, *Onkologie* 30 (2007) 361–366.
- [51] Fernandes G, Fernandes BC, Valente V and Dos Santos JL: Recent advances in the discovery of small molecules targeting glioblastoma. *Eur J Med Chem* 164: 8–26, 2019.
- [52] T. Shapira-Furman, R. Serra, N. Gorelick, M. Doglioli, V. Tagliaferri, A. Cecia, M. Peters, A. Kumar, Y. Rottenberg, R. Langer, et al., Biodegradable wafers releasing temozolomide and carmustine for the treatment of brain cancer, *J Control Release* 295 (2019) 93–101.
- [53] S.T. Keir, J.M. Maris, C.P. Reynolds, M.H. Kang, E.A. Kolb, R. Gorlick, R. Lock, H. Carol, C.L. Morton, J. Wu, et al., Initial testing (stage 1) of temozolomide by the pediatric pre-clinical testing program, *Pediatr Blood Cancer* 60 (2013) 783–790.
- [54] M Bupathi, JL Hays, JL Chen, Temozolomide post pazopanib treatment failure in patients with advanced sarcoma: a case series, *PLoS One* 12 (2017), e0188116.
- [55] K. Igarashi, K. Kawaguchi, T. Kiyuna, K. Miyake, M. Miyake, Y. Li, S.D. Nelson, S.M. Dry, A.S. Singh, I.A. Elliott, et al., Temozolomide combined with irinotecan regresses a cisplatin-resistant relapsed osteosarcoma in a patient-derived orthotopic xenograft (PDOX) precision-oncology mouse model, *J Cell Biochem* 9 (2018) 7774–7781.
- [56] K. Igarashi, K. Kawaguchi, T. Kiyuna, T. Murakami, S. Miwa, S.D. Nelson, S.M. Dry, Y. Li, A.S. Singh, H. Kimura, et al., Temozolomide combined with irinotecan caused regression in an adult pleomorphic rhabdomyosarcoma patient-derived orthotopic xenograft (PDOX) nude-mouse model, *Oncotarget* 8 (2017) 75874–75880.
- [57] K. Igarashi, T. Murakami, K. Kawaguchi, T. Kiyuna, K. Miyake, Y. Zhang, S.D. Nelson, S. M. Dry, Y. Li, J. Yanagawa, et al., A patient-derived orthotopic xenograft (PDOX) mouse model of a cisplatin-resistant osteosarcoma lung metastasis that was sensitive to temozolomide and trabectedin: implications for precision oncology, *Oncotarget* 8 (2017) 62111–62119.
- [58] K. Kawaguchi, K. Igarashi, S. Li, Q. Han, Y. Tan, T. Kiyuna, K. Miyake, T. Murakami, B. Chmielowski, S.D. Nelson, et al., Combination treatment with recombinant methioninase enables temozolomide to arrest a BRAF V600E melanoma in a patient-derived orthotopic xenograft (PDOX) mouse model, *Oncotarget* 8 (2017) 85516–85525.
- [59] K. Kawaguchi, K. Igarashi, T. Murakami, B. Chmielowski, T. Kiyuna, M. Zhao, Y. Zhang, A. Singh, M. Unno, S.D. Nelson, et al., Tumor-targeting Salmonella typhimurium A1-R combined with temozolomide regresses malignant melanoma with a BRAF-V600E mutation in a patient-derived orthotopic xenograft (PDOX) model, *Oncotarget* 7 (2016) 85929–85936.
- [60] K. Miyake, T. Murakami, T. Kiyuna, K. Igarashi, K. Kawaguchi, M. Miyake, Y. Li, S. D. Nelson, S.M. Dry, M. Bouvet, et al., The combination of temozolomide-irinotecan regresses a doxorubicin-resistant patient-derived orthotopic xenograft (PDOX) nude-mouse model of recurrent Ewing's sarcoma with a FUS-ERG fusion and CDKN2A deletion: direction for third-line patient therapy, *Oncotarget* 8 (2017) 103129–103136.
- [61] Z. Zhang, K. Hu, T. Kiyuna, K. Miyake, K. Kawaguchi, K. Igarashi, S.D. Nelson, Y. Li, S.R. Singh, R.M. Hoffman, A patient-derived orthotopic xenograft (PDOX) nude-mouse model precisely identifies effective and ineffective therapies for recurrent leiomyosarcoma, *Pharmacol Res* 142 (2019) 169–175.
- [62] K. Igarashi, K. Kawaguchi, T. Kiyuna, K. Miyake, M. Miyake, S.D. Nelson, T.A. Russell, S. M. Dry, Y. Li, N. Yamamoto, et al., Pazopanib regresses a doxorubicin-resistant synovial sarcoma in a patient-derived orthotopic xenograft mouse model, *Tissue Cell* 58 (2019) 107–111.
- [63] T. Kiyuna, T. Murakami, Y. Tome, K. Igarashi, K. Kawaguchi, K. Miyake, M. Miyake, Y. Li, S.D. Nelson, S.M. Dry, et al., Doxorubicin-resistant pleomorphic liposarcoma with PDGFRA gene amplification is targeted and regressed by pazopanib in a patient-derived orthotopic xenograft mouse model, *Tissue Cell* 53 (2018) 30–36.
- [64] T. Kiyuna, Y. Tome, T. Murakami, K. Miyake, K. Igarashi, K. Kawaguchi, H. Oshiro, T. Higuchi, M. Miyake, N. Sugisawa, et al., A combination of irinotecan/cisplatin and irinotecan/temozolomide or tumor-targeting Salmonella typhimurium A1-R arrest doxorubicin- and temozolomide-resistant myxofibrosarcoma in a PDOX mouse model, *Biochem Biophys Res Commun* 505 (2018) 733–739.
- [65] H. Oshiro, Y. Tome, T. Kiyuna, K. Miyake, K. Kawaguchi, T. Higuchi, M. Miyake, Z. Zhang, S. Razmjooei, M. Barangi, et al., Temozolomide targets and arrests a doxorubicin-resistant follicular dendritic-cell sarcoma patient-derived orthotopic xenograft mouse model, *Tissue Cell* 58 (2019) 17–23.