

UC Berkeley

UC Berkeley Previously Published Works

Title

Diagnostic, Prognostic, and Therapeutic Use of Radiopharmaceuticals in the Context of SARS-CoV-2

Permalink

<https://escholarship.org/uc/item/39x045nb>

Journal

ACS Pharmacology & Translational Science, 4(1)

ISSN

2575-9108

Authors

Pallares, Roger M
Abergel, Rebecca J

Publication Date

2021-02-12

DOI

10.1021/acsptsci.0c00186

Peer reviewed

Diagnostic, Prognostic and Therapeutic Use of Radiopharmaceuticals in the Context of SARS-CoV-2

Roger M. Pallares,¹ and Rebecca J. Abergel^{1,2*}

¹Chemical Sciences Division, Lawrence Berkeley National Laboratory, Berkeley, CA 94720, USA

²Department of Nuclear Engineering, University of California, Berkeley, CA 94720, USA

*E-mail: abergel@berkeley.edu

Abstract

The coronavirus disease 2019 (COVID-19) outbreak has devastated the healthcare systems and economies of over 200 countries in just a few months. The etiological agent of COVID-19, SARS-CoV-2, is a highly contagious virus that can be transmitted by asymptomatic and symptomatic carriers alike. While *in vitro* testing techniques have allowed for population-wide screening, prognostic tools are required to assess the disease severity and therapeutic response, contributing to improve the patient clinical outcomes. Moreover, no specific antiviral against COVID-19 exists at the time of publication, severely limiting the treatment against the infection. Hence, there is an urgent clinical need for innovative therapeutic strategies that may contribute to manage COVID-19 outbreak and prevent future pandemics. Herein, we critically examine recent diagnostic, prognostic and therapeutic advancements for COVID-19 in the field of radiopharmaceuticals. First, we summarize the gold standard techniques used to diagnose COVID-19, including *in vitro* assays and imaging techniques, and then discuss how radionuclide-based nuclear imaging provides

complementary information for prognosis and treatment management of infected patients. Second, we introduce new emerging types of radiotherapies that employ radioimmunoconjugates, which have shown selective cytotoxic response in oncological studies, and critically analyze how these compounds could be used as therapeutic agents against SARS-CoV-2. Finally, this perspective further discusses the emerging applications of radionuclides to study the behavior of pulmonary SARS-CoV-2 aerosol particles.

KEYWORDS: Coronavirus, COVID-19, SARS-CoV-2, radionuclide, radiochemistry, positron emission tomography, radiotherapy.

1. Motivations and Background

In December of 2019, a pulmonary disease called coronavirus disease 2019 (COVID-19) first emerged in the city of Wuhan, China, and rapidly spread to the rest of the world.^{1,2} The etiological agent of COVID-19 is SARS-CoV-2, a new type of coronavirus that showed highly efficient transmission between humans.^{1,3} Symptomatic patients diagnosed with COVID-19, often displayed fever, respiratory complications, pneumonia and dyspnea.⁴ However, at early stages of the disease, asymptomatic carriers were also highly contagious,^{5,6} causing a rapid and widespread virus transmission that resulted in several millions of people getting infected with COVID-19 in a few short months. Thus, on March 11, 2020, the World Health Organization officially declared COVID-19 a global pandemic.⁷

Current pandemic management strategies include early diagnosis, treatment, and long-term immunization. Because SARS-CoV-2 could be readily transmitted via asymptomatic carriers, several cost-effective and efficient testing techniques were implemented to recognize and isolate infected patients. The sequencing of the virus genome helped to identify a set of target genes for large-scale and high-fidelity screening, via real-time polymerase chain reaction (RT-PCR) protocols.⁸ Although most common COVID-19 clinical manifestations include fever, cough, fatigue and dyspnea, advanced cases may cause respiratory failure through acute respiratory distress syndrome that can be fatal.^{9,10} Hence, there is the need for sensitive prognostic tools that can assess the disease severity and track the patient evolution after treatment, particularly in severe cases. Regarding strategies to treat COVID-19 infection, available medicines have only served to alleviate patient symptoms, and no specific antiviral is commercially available for COVID-19 treatment at the time of writing this perspective article. Several drug candidates, however, have shown promising therapeutic capabilities *in vitro* and *in vivo*.¹¹⁻¹³ For long-term immunity, major

international efforts have been made to develop a vaccine against COVID-19,¹⁴ despite the irregularity of novel vaccine developments in recent years. For example, while a vaccine for H1N1 influenza was completed relatively rapid because influenza-vaccine technology has been well-established for years, other recent epidemics, such as the SARS and Zika virus outbreaks, were contained before a vaccine was ever fully developed.¹⁴

SARS-CoV-2, along with SARS-CoV and MERS-CoV, belong to the β -coronavirus genus. Coronaviruses are a group of positive-sense, single-stranded ribonucleic acid (ssRNA) viruses with a characteristic spike glycoprotein envelope, which mediates viral entry into the host cell.¹⁵ Spike proteins can be divided in two parts: the S1 subunit, which binds to the host cell receptor (angiotensin-converting enzyme 2 or ACE2, in the case of SARS-CoV-2), and the S2 subunit, which mediates the fusion of the viral and host cell membranes (**Figure 1**).¹⁶ Because spike proteins are a key component of infection, and are exposed on the surface of the virus, novel vaccines have focused on developing neutralizing antibodies for spike proteins. Lastly, based on the identification of viral nucleotides, both SARS-CoV-2 and SARS-CoV were likely zoonotically

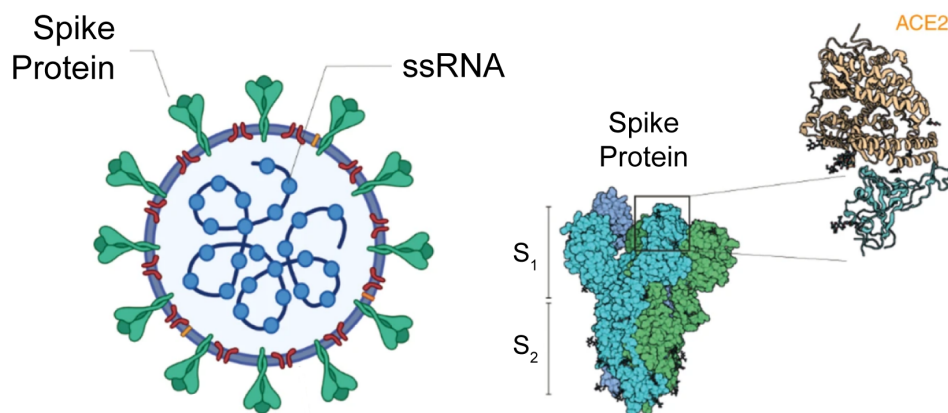


Figure 1. Etiological agent SARS-CoV-2 and spike protein. (c) Schematic illustration of SARS-CoV-2 and spike protein with and S₁ and S₂ subunits highlighted. Adapted with permission from ref 16. Copyright 2020 Springer Nature.

transmitted to humans by bats.¹⁷ The several recorded spillovers of coronaviruses from animals to humans, as well as the detection of multiple coronaviruses in bats may forecast new epidemics in the future.¹⁸ Hence, current efforts to develop novel diagnostic and therapeutic strategies against SARS-CoV-2 will likely yield improved capabilities for the current and future outbreaks.

In this perspective, we summarize the recent advances in the field of radiopharmaceuticals for COVID-19 diagnosis, prognosis and therapy, and offer prospects for emerging opportunities. We initially describe the state of the art in the diagnosis of COVID-19, and analyze how imaging techniques based on radiotracers can provide clinically relevant information for patient prognosis and treatment management. Moreover, using as starting point a recent debate on whether external beam radiotherapy could be used to treat COVID-19 pneumonia, we explore new emerging types of radiotherapies that use immuno-conjugates to obtain selective cytotoxic effects, and how those constructs could be used against SARS-CoV-2. Finally, a new use for radionuclides to model the behavior of COVID-19 aerosol particles is discussed.

2. Diagnosis and Imaging of COVID-19 Patients

Serological assays and RT-PCR are the most common *in vitro* tests to diagnose viral infections, such as COVID-19, in patients.¹⁹⁻²¹ RT-PCR is particularly useful at the early stages of the infection, given that it can detect viral genomes independent of a patient's immunological response.^{8,22} Thus, RT-PCR has become the gold standard technique for COVID-19 diagnosis with newly developed assays providing results in just 45 min.²³ However, a high incidence (between 2% and 29%) of false negative results has raised concerns regarding its diagnostic reliability, particularly in asymptomatic patients.²⁴⁻²⁷

In addition to *in vitro* assays, high-resolution computed tomography (CT) imaging of the chest is a preferred technique for screening, diagnosing, and monitoring patient recovery from COVID-19 induced pneumonia.^{28,29} This imaging technique employs multiple X-ray measurements from different angles to generate specific cross-sectional images of body parts,^{30,31} providing anatomic information of the patient (**Figure 2**). CT can identify COVID-19 related lesions and track disease progression: at early stages, plaques, nodules and ground-glass density lesions can be observed in a patient’s lungs, and as the pneumonia worsens, the amount of damaged tissue increases.³² CT sensitivity for COVID-19 diagnosis is at 97.2 %, which improves the sensitivity values initially reported for RT-PCR (83.3 %).³³ Thus, it has been recommended to isolate patients with positive CT findings, even if they have negative RT-PCR results.

Although chest CT shows high sensitivity for COVID-19 pneumonia diagnosis, imaging modalities that employ radiotracers can also yield accurate diagnostic results, while providing additional information.³⁴ For instance, in January of 2020, before the COVID-19 outbreak was formally recognized, positron-emitting fluorodeoxyglucose (¹⁸F) was administered to four patients with respiratory symptoms and fever in Wuhan, China.³⁵ Fluorodeoxyglucose (¹⁸F) is a glucose analog, where a hydroxyl group has been replaced by a positron-emitting fluorine-18 radionuclide. Hence, the radiotracer is preferentially taken by certain cells and tissues, such as tumor cells in




	Information				Imaging Features	
	Anatomic	Physiologic	Metabolic	Molecular	Emission	Representative radionuclides
CT					X-ray	
PET					Positron	¹⁸ F, ⁶⁸ Ga, ⁶⁴ Cu, ⁸⁹ Zr
SPECT					γ-ray	^{99m} Tc, ¹²³ I

Figure 2. Comparison between different nuclear imaging techniques.

cancer patients,³⁶ and by macrophages and neutrophils in patients suffering from inflammation associated with infection,³⁷ and its location can be determined by positron emission tomography (PET). All four Wuhan patients showed pulmonary lesions, including ground-glass opacities and/or lung consolidations in at least two pulmonary lobes in their scans. Moreover, the lesions had a high fluorodeoxyglucose (¹⁸F) uptake, and indicated evidence of lymph node involvement. In retrospect, a comprehensive review of the clinical data presented and patients' medical histories strongly suggested infection with COVID-19. A characteristic increase in radiotracer uptake by infected pulmonary tissue was later confirmed among patients with COVID-19 positive RT-PCR results (**Figure 3**).^{38,39} The characteristic radiological features and metabolic activities associated with COVID-19 induced pneumonia were also observed in asymptomatic patients undergoing

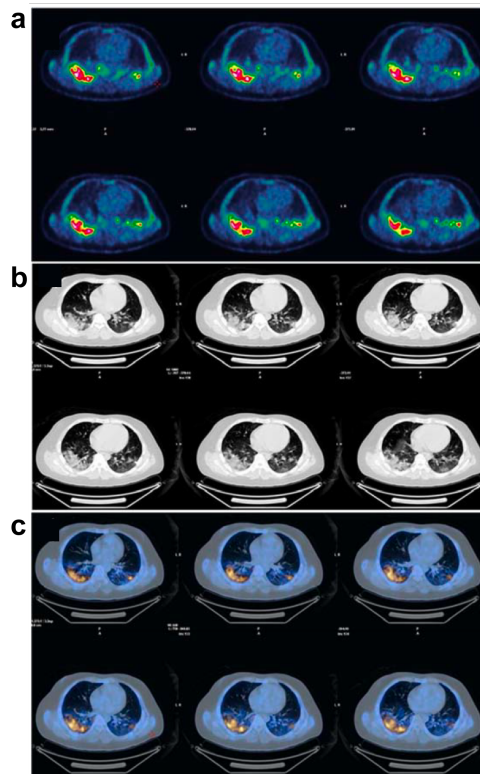


Figure 3. Transaxial images of COVID-19 patient thorax by PET-CT. (a) PET with fluorodeoxyglucose (¹⁸F) radiotracer, (b) low-dose CT, and (c) fused images of COVID-19 patient thorax. The images show high fluorodeoxyglucose (¹⁸F) uptake at the basal lower lobe bilaterally with consolidation and ground glass opacity. Adapted with permission from ref 38. Copyright 2020 Science Publishing Group.

fluorodeoxyglucose (^{18}F) PET-CT procedures.⁴⁰ These results are consistent with previous MERS-CoV cases, in which significant fluorodeoxyglucose (^{18}F) uptake was observed among MERS-CoV patients with pneumonia.⁴¹ Although PET-CT, using fluorodeoxyglucose (^{18}F) radiotracers, is not feasible for population-wide screening, this imaging technique offers a means of identifying the prevalence of COVID-19 among high-risk, asymptomatic patients with underlying conditions.⁴² Because the radiotracer uptake is dependent on non-specific inflammatory response, and can provide vital information on overall immune activation, PET-CT scans have therefore been suggested for COVID-19 prognosis and treatment management.⁴³ To date, all radiotracers used to image SARS-CoV-2 induced pneumonia by PET have been based on fluorine-18. We expect, however, that other commonly used positron-emitting radionuclides, such as carbon-11, nitrogen-13, oxygen-15, gallium-68, copper-64 or zirconium-89,⁴⁴ will also be explored for imaging COVID-19 patients in the near future.

The success of radiotracers for imaging COVID-19 lesions has sparked interest in novel imaging agents that combine radionuclides with targeting vectors. These radiological agents have the potential for enhancing the sensitivity and specificity of the imaging techniques. For instance, macrophages play a key role in the immunological response to SARS-CoV-2 and, when activated, express folate receptor-beta proteins, which can be targeted with folic acid.^{45,46} Hence, ^{18}F -AzaFol, a folic acid-based PET imaging agent that is under clinical trials for metastatic cancer of the ovaries and lungs,⁴⁷ has been proposed as radiotracer for macrophage activity imaging in COVID-19 patients to support clinical decision-making.⁴⁸ This strategy is supported by a previous preclinical study that used ^{18}F -AzaFol to image and monitor macrophage-driven lung diseases.⁴⁹ Other potential candidates to image COVID-19 associated pneumonia could include ^{18}F -labelled FEDAC⁵⁰ and mannose-presenting ^{64}Cu radiotracers,⁵¹ which target receptors over-expressed on

activated macrophages, or radio-labelling blood cells, such as macrophage activated killer cells, with ^{111}In -oxime.⁵²

The radiolabeling of white cells has also been applied to other imaging modalities, such as single-photon emission computed tomography (SPECT), where gamma-emitting radionuclides are used as imaging tracers. $^{99\text{m}}\text{Tc}$ -exametazime-labeled leukocytes, which have been used to detect acute infection sites,⁵³ also revealed pulmonary infections in COVID-19 patients.⁵⁴ Lastly, another strategy to image COVID-19 infections with gamma-emitting radionuclides could be targeting SARS-CoV-2 entry receptor (*i.e.* ACE2) by repurposing already established autoradiography protocols, which radiolabel angiotensin II (an ACE2 substrate) with ^{125}I .⁵⁵ In summary, there is a renewed academic and clinical interest in developing new radiopharmaceuticals and repurposing existing ones for COVID-19 imaging, in order to obtain new pathomechanistic insights and enhanced prognosis capabilities.⁵⁶

Lastly, the radioisotope ^{11}C has been used to improve the understanding about SARS-CoV-2 particle retention and deposition in the respiratory tract after ambient air intake. The authors used a modified version of the lung deposition model developed by the International Committee of Radiological Protection (ICRP),⁵⁷ which calculates region-specific deposition of aerosol particles in the lungs, as well as particle clearance through various pulmonary regions. This model was modified to represent a semi-empirical approach that is based on algebraic equations derived from relevant theoretical and experimental results. The authors remodeled the ICRP lung model to examine SARS-CoV-2, with the conception that the virus has an “environmental half-life” based on its environmental degradation prior to lung deposition. Subsequently, viral degradation was experimentally determined, and replicated in a model with ^{11}C -loaded aerosol particles, since this isotope has a radioactive decay rate similar to the virus environmental degradation rate.⁵⁸ Applying

the IRCP model, the authors observed a high retention of SARS-CoV-2 in the extrathoracic region, with lower viral fraction deposition in the alveolar section. This finding was consistent with previous clinical reports, confirming the validity of the model.

3. Therapeutic Strategies Against COVID-19

In the absence of an antiviral that can effectively treat SARS-CoV-2 infection, Kirkby *et al.* proposed to use low doses (<100 cGy) of radiation to treat COVID-19 induced pneumonia in patients.⁵⁹ A strong reaction followed this article, with several publications supporting the consideration of radiotherapy for applications in COVID-19 treatment based on the anti-inflammatory activity of low dose radiation,⁶⁰⁻⁶⁴ while other groups argued that current scientific evidence does not justify any clinical trial of low dose radiotherapy for COVID-19 pneumonia,⁶⁵⁻⁶⁷ since the clinical data (published between 30's and 70's) was not obtained following well-established protocols that abided by today's clinical standards.⁶⁸

The discussion surrounding utilization of external beam radiation for treatment of COVID-19 pneumonia has increased attention towards other emerging forms of radiotherapy, with more selective cytotoxic effects. For instance, targeted radiotherapy (**Figure 4**) is a clinical strategy in which radionuclides emitting α -particles, β^- particles or Auger electrons, are delivered to tumors.⁶⁹⁻⁷¹ α -particles main advantages are their high linear energy transfer and short penetration depth, which concentrate the cytotoxic effect.⁷² α -emitters, however, present much larger recoil energies during their decay, causing a higher release of daughters from the radiopharmaceutical compound compared to other radionuclides, such as β and Auger electron emitters.⁷³ Because radionuclides are conjugated to targeting vectors, including antibodies and cell surface receptor-binding peptides,⁷⁴ only cancerous cells tend to be exposed to radiation, while surrounding healthy tissue

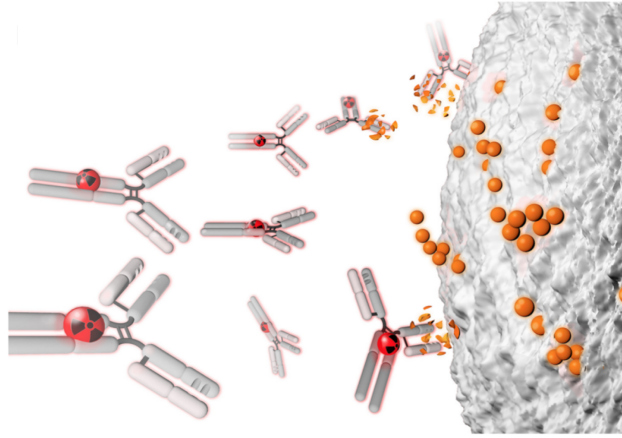


Figure 4. Targeted radiotherapy working principle. The radionuclide-carrying antibody binds to the epitope, while the isotope decay events damage the target. In the case of COVID-19, the radiation is expected to compromise SARS-CoV-2 extracellular virions. Adapted with permission from ref 86. Copyright 2020 Society of Nuclear Medicine and Molecular Imaging.

is primarily unaffected. Examples of promising therapeutic immunoconjugates include ^{225}Ac -HuM195, a lintuzumab conjugate for myeloid leukemia treatment⁷⁵ and ^{227}Th -DOTA-trastuzumab, for HER-2 positive breast and ovarian cancer treatment.⁷⁶ Moreover, several new formulations, wherein α -generators and targeting vectors are functionalized at a high density on nanoparticle surfaces, have shown high therapeutic performances,⁷⁷⁻⁷⁹ and there is increasing interest in developing targeted alpha therapy strategies for the treatment of infectious diseases.⁸⁰ For instance, several radioimmunoconjugates that targeted infected cells (rather than the viruses itself) have been developed to eliminate the virus reservoirs and prevent their propagation.^{81,82} Recently the first antibodies targeting SARS-CoV-2 spike proteins were discovered, providing the missing part in the development of radioimmunoconjugates that directly bind to the virus.^{83,84} Furthermore, several epitopes targeted by these antibodies are highly conserved in other coronaviruses,⁸⁵ making such antibodies ideal candidates for targeting SARS-CoV-2, as well as other related viruses. An early example of immunoconjugate approaches to COVID-19 radiotherapy was developed by Pillarsetty *et al.*, wherein a CR3022 antibody was combined with

a β^- emitting ^{131}I -complex for therapeutic purposes.⁸⁶ The authors, however, did not report *in vitro* or *in vivo* evaluation of the therapeutic performance of the radioimmunoconjugate. It is worth noting that viruses have relatively low radiosensitivity with most D_{10} values (*i.e.* doses necessary to cause a one-log reduction in titer) reported in the kGy range for ^{60}Co gamma photons.⁸⁷ Furthermore, the small size of the SARS-CoV-2 virus (ca. 75 nm)⁸⁸ may represent a challenge for targeted radiotherapy, since the linear energy transfer of ionizing particles, such as alpha particles, is low at sub- μm and a few μm range from the radionuclide.^{89,90} Therefore, it is unclear at the moment whether targeted radiotherapy is a feasible strategy against SARS-CoV-2 infections, and further studies are needed to determine its possible therapeutic value.

4. Summary and Outlook

In the midst of the COVID-19 pandemic, an urgent need for diagnostic and prognostic strategies with improved sensitivity has emerged. Although we believe RT-PCR will remain the gold standard for population-wide screening, CT is currently the most sensitive technique for COVID-19 diagnosis, as well as the most reliable technique for monitoring patient recovery from SARS-CoV-2 induced pneumonia. A combination of CT scans and radiotracer-based imaging tools, such as PET and SPECT, have provided complementary information for the prognosis and treatment management, especially in high-risk patients with underlying conditions. Promising fluorodeoxyglucose (^{18}F) studies have sparked renewed interest in developing new radiotracers and repurposing already existing ones for COVID-19 imaging. With regards to therapeutics, the success of targeted radiotherapy in oncological settings suggests the potential for utilizing radioimmunoconjugates against SARS-CoV-2 infections. A few preclinical studies are currently being published, and more are expected to emerge in the near future.

CONFLICT OF INTEREST

The authors declare no competing financial interest.

AUTHOR INFORMATION

Corresponding Author. *E-mail: abergel@berkeley.edu.

ORCID

Roger M. Pallares: 0000-0001-7423-8706

Rebecca J. Abergel: 0000-0002-3906-8761

ACKNOWLEDGMENTS

This work was supported by the University of California Contractor Supporting Research Program at Lawrence Berkeley National Laboratory under U.S. Department of Energy Contract No. DE-AC02-05CH11231.

References

- (1) Chan, J. F.-W.; Yuan, S.; Kok, K.-H.; To, K. K.-W.; Chu, H.; Yang, J.; Xing, F.; Liu, J.; Yip, C. C.-Y.; Poon, R. W.-S.; Tsoi, H.-W.; Lo, S. K.-F.; Chan, K.-H.; Poon, V. K.-M.; Chan, W.-M.; Ip, J. D.; Cai, J.-P.; Cheng, V. C.-C.; Chen, H.; Hui, C. K.-M.; Yuen, K.-Y. A familial cluster of pneumonia associated with the 2019 novel coronavirus indicating person-to-person transmission: a study of a family cluster. *The Lancet* **2020**, *395* (10223), 514-523.
- (2) Remuzzi, A.; Remuzzi, G. COVID-19 and Italy: what next? *The Lancet* **2020**, *395* (10231), 1225-1228.
- (3) Bar-On, Y. M.; Flamholz, A.; Phillips, R.; Milo, R. SARS-CoV-2 (COVID-19) by the numbers. *eLife* **2020**, *9*, e57309.
- (4) Huang, C.; Wang, Y.; Li, X.; Ren, L.; Zhao, J.; Hu, Y.; Zhang, L.; Fan, G.; Xu, J.; Gu, X.; Cheng, Z.; Yu, T.; Xia, J.; Wei, Y.; Wu, W.; Xie, X.; Yin, W.; Li, H.; Liu, M.; Xiao, Y.; Gao, H.; Guo, L.; Xie, J.; Wang, G.; Jiang, R.; Gao, Z.; Jin, Q.; Wang, J.; Cao, B. Clinical features of patients infected with 2019 novel coronavirus in Wuhan, China. *The Lancet* **2020**, *395* (10223), 497-506.
- (5) Bai, Y.; Yao, L.; Wei, T.; Tian, F.; Jin, D.-Y.; Chen, L.; Wang, M. Presumed Asymptomatic Carrier Transmission of COVID-19. *JAMA* **2020**, *323* (14), 1406-1407.
- (6) Nishiura, H.; Kobayashi, T.; Miyama, T.; Suzuki, A.; Jung, S.-m.; Hayashi, K.; Kinoshita, R.; Yang, Y.; Yuan, B.; Akhmetzhanov, A. R.; Linton, N. M. Estimation of the asymptomatic ratio of novel coronavirus infections (COVID-19). *International Journal of Infectious Diseases* **2020**, *94*, 154-155.
- (7) Spinelli, A.; Pellino, G. COVID-19 pandemic: perspectives on an unfolding crisis. *BJS (British Journal of Surgery)* **2020**, *107* (7), 785-787.
- (8) Park, M.; Won, J.; Choi, B. Y.; Lee, C. J. Optimization of primer sets and detection protocols for SARS-CoV-2 of coronavirus disease 2019 (COVID-19) using PCR and real-time PCR. *Exp. Mol. Med.* **2020**, *52* (6), 963-977.
- (9) Johnson, K. D.; Harris, C.; Cain, J. K.; Hummer, C.; Goyal, H.; Perisetti, A. Pulmonary and Extra-Pulmonary Clinical Manifestations of COVID-19. *Frontiers in Medicine* **2020**, *7*, 526.
- (10) Lang, M.; Som, A.; Carey, D.; Reid, N.; Mendoza, D. P.; Flores, E. J.; Li, M. D.; Shepard, J.-A. O.; Little, B. P. Pulmonary Vascular Manifestations of COVID-19 Pneumonia. *Radiology: Cardiothoracic Imaging* **2020**, *2* (3), e200277.
- (11) Caly, L.; Druce, J. D.; Catton, M. G.; Jans, D. A.; Wagstaff, K. M. The FDA-approved drug ivermectin inhibits the replication of SARS-CoV-2 in vitro. *Antiviral Res.* **2020**, *178*, 104787.
- (12) Sheahan, T. P.; Sims, A. C.; Zhou, S.; Graham, R. L.; Pruijssers, A. J.; Agostini, M. L.; Leist, S. R.; Schäfer, A.; Dinnon, K. H.; Stevens, L. J.; Chappell, J. D.; Lu, X.; Hughes, T. M.; George, A. S.; Hill, C. S.; Montgomery, S. A.; Brown, A. J.; Bluemling, G. R.; Natchus, M. G.; Saindane, M.; Kolykhalov, A. A.; Painter, G.; Harcourt, J.; Tamin, A.; Thornburg, N. J.; Swanstrom, R.; Denison, M. R.; Baric, R. S. An orally bioavailable broad-spectrum antiviral inhibits SARS-CoV-2 in human airway epithelial cell cultures and multiple coronaviruses in mice. *Science Translational Medicine* **2020**, *12* (541), eabb5883.
- (13) Dai, W.; Zhang, B.; Jiang, X.-M.; Su, H.; Li, J.; Zhao, Y.; Xie, X.; Jin, Z.; Peng, J.; Liu, F.; Li, C.; Li, Y.; Bai, F.; Wang, H.; Cheng, X.; Cen, X.; Hu, S.; Yang, X.; Wang, J.; Liu, X.; Xiao, G.; Jiang, H.; Rao, Z.; Zhang, L.-K.; Xu, Y.; Yang, H.; Liu, H. Structure-based design of antiviral drug candidates targeting the SARS-CoV-2 main protease. *Science* **2020**, *368* (6497), 1331.

- (14) Lurie, N.; Saville, M.; Hatchett, R.; Halton, J. Developing Covid-19 Vaccines at Pandemic Speed. *N. Engl. J. Med.* **2020**, *382* (21), 1969-1973.
- (15) Tortorici, M. A.; Veesler, D. Chapter Four - Structural insights into coronavirus entry. In *Advances in Virus Research*; Rey, F. A., Ed.; Academic Press: 2019; pp 93-116.
- (16) Yang, J.; Petitjean, S. J. L.; Koehler, M.; Zhang, Q.; Dumitru, A. C.; Chen, W.; Derclaye, S.; Vincent, S. P.; Soumillon, P.; Alsteens, D. Molecular interaction and inhibition of SARS-CoV-2 binding to the ACE2 receptor. *Nat. Commun* **2020**, *11* (1), 4541.
- (17) Zhou, P.; Yang, X.-L.; Wang, X.-G.; Hu, B.; Zhang, L.; Zhang, W.; Si, H.-R.; Zhu, Y.; Li, B.; Huang, C.-L.; Chen, H.-D.; Chen, J.; Luo, Y.; Guo, H.; Jiang, R.-D.; Liu, M.-Q.; Chen, Y.; Shen, X.-R.; Wang, X.; Zheng, X.-S.; Zhao, K.; Chen, Q.-J.; Deng, F.; Liu, L.-L.; Yan, B.; Zhan, F.-X.; Wang, Y.-Y.; Xiao, G.-F.; Shi, Z.-L. A pneumonia outbreak associated with a new coronavirus of probable bat origin. *Nature* **2020**, *579* (7798), 270-273.
- (18) Walls, A. C.; Park, Y.-J.; Tortorici, M. A.; Wall, A.; McGuire, A. T.; Veesler, D. Structure, Function, and Antigenicity of the SARS-CoV-2 Spike Glycoprotein. *Cell* **2020**, *181* (2), 281-292.e6.
- (19) Kubina, R.; Dziedzic, A. Molecular and Serological Tests for COVID-19. A Comparative Review of SARS-CoV-2 Coronavirus Laboratory and Point-of-Care Diagnostics. *Diagnostics* **2020**, *10*, 434.
- (20) Udugama, B.; Kadhiresan, P.; Kozlowski, H. N.; Malekjahani, A.; Osborne, M.; Li, V. Y. C.; Chen, H.; Mubareka, S.; Gubbay, J. B.; Chan, W. C. W. Diagnosing COVID-19: The Disease and Tools for Detection. *ACS Nano* **2020**, *14* (4), 3822-3835.
- (21) Kilic, T.; Weissleder, R.; Lee, H. Molecular and Immunological Diagnostic Tests of COVID-19: Current Status and Challenges. *iScience* **2020**, *23* (8), 101406.
- (22) Xiao, A. T.; Tong, Y. X.; Zhang, S. Profile of RT-PCR for SARS-CoV-2: A Preliminary Study From 56 COVID-19 Patients. *Clinical Infectious Diseases* **2020**, 10.1093/cid/ciaa460.
- (23) Goldenberger, D.; Leuzinger, K.; Sogaard, K. K.; Gosert, R.; Roloff, T.; Naegele, K.; Cuénod, A.; Mari, A.; Seth-Smith, H.; Rentsch, K.; Hinić, V.; Hirsch, H. H.; Egli, A. Brief validation of the novel GeneXpert Xpress SARS-CoV-2 PCR assay. *J. Virol. Methods* **2020**, *284*, 113925.
- (24) Xiao, A. T.; Tong, Y. X.; Zhang, S. False negative of RT-PCR and prolonged nucleic acid conversion in COVID-19: Rather than recurrence. *Journal of Medical Virology* **2020**, *92* (10), 1755-1756.
- (25) Li, Y.; Yao, L.; Li, J.; Chen, L.; Song, Y.; Cai, Z.; Yang, C. Stability issues of RT-PCR testing of SARS-CoV-2 for hospitalized patients clinically diagnosed with COVID-19. *Journal of Medical Virology* **2020**, *92* (7), 903-908.
- (26) Tahamtan, A.; Ardebili, A. Real-time RT-PCR in COVID-19 detection: issues affecting the results. *Expert Review of Molecular Diagnostics* **2020**, *20* (5), 453-454.
- (27) Woloshin, S.; Patel, N.; Kesselheim, A. S. False Negative Tests for SARS-CoV-2 Infection — Challenges and Implications. *N. Engl. J. Med.* **2020**, *383* (6), e38.
- (28) Kanne, J. P.; Little, B. P.; Chung, J. H.; Elicker, B. M.; Ketani, L. H. Essentials for Radiologists on COVID-19: An Update—Radiology Scientific Expert Panel. *Radiology* **2020**, *296* (2), E113-E114.
- (29) Liu, W.; Zhang, Q.; Chen, J.; Xiang, R.; Song, H.; Shu, S.; Chen, L.; Liang, L.; Zhou, J.; You, L.; Wu, P.; Zhang, B.; Lu, Y.; Xia, L.; Huang, L.; Yang, Y.; Liu, F.; Semple, M. G.; Cowling, B. J.; Lan, K.; Sun, Z.; Yu, H.; Liu, Y. Detection of Covid-19 in Children in Early January 2020 in Wuhan, China. *N. Engl. J. Med.* **2020**, *382* (14), 1370-1371.

- (30) Buzug, T. M. Computed Tomography. In *Springer Handbook of Medical Technology*; Kramme, R.; Hoffmann, K.-P.; Pozos, R. S., Eds.; Springer Berlin Heidelberg: Berlin, Heidelberg, 2011; pp 311-342.
- (31) Kalender, W. A. X-ray computed tomography. *Physics in Medicine and Biology* **2006**, *51* (13), R29-R43.
- (32) Shi, H.; Han, X.; Jiang, N.; Cao, Y.; Alwalid, O.; Gu, J.; Fan, Y.; Zheng, C. Radiological findings from 81 patients with COVID-19 pneumonia in Wuhan, China: a descriptive study. *The Lancet Infectious Diseases* **2020**, *20* (4), 425-434.
- (33) Long, C.; Xu, H.; Shen, Q.; Zhang, X.; Fan, B.; Wang, C.; Zeng, B.; Li, Z.; Li, X.; Li, H. Diagnosis of the Coronavirus disease (COVID-19): rRT-PCR or CT? *European Journal of Radiology* **2020**, *126*, 108961.
- (34) Aljondi, R.; Alghamdi, S. Diagnostic Value of Imaging Modalities for COVID-19: Scoping Review. *J Med Internet Res* **2020**, *22* (8), e19673.
- (35) Qin, C.; Liu, F.; Yen, T.-C.; Lan, X. 18F-FDG PET/CT findings of COVID-19: a series of four highly suspected cases. *European Journal of Nuclear Medicine and Molecular Imaging* **2020**, *47* (5), 1281-1286.
- (36) Schelling, M.; Avril, N.; Nährig, J.; Kuhn, W.; Römer, W.; Sattler, D.; Werner, M.; Dose, J.; Jänicke, F.; Graeff, H.; Schwaiger, M. Positron Emission Tomography Using [18F]Fluorodeoxyglucose for Monitoring Primary Chemotherapy in Breast Cancer. *Journal of Clinical Oncology* **2000**, *18* (8), 1689-1695.
- (37) Love, C.; Tomas, M. B.; Tronco, G. G.; Palestro, C. J. FDG PET of Infection and Inflammation. *RadioGraphics* **2005**, *25* (5), 1357-1368.
- (38) Albano, D.; Camoni, L.; Rinaldi, R.; Bertagna, F.; Giubbini, R. 18F-FDG PET/CT Metabolic Behavior of COVID-19 Pneumonia: A Series of 4 Patients With RT-PCR Confirmation. *Clinical Nuclear Medicine* **2020**, *45* (8).
- (39) Masoomi, M.; Al-Shammeri, A.; Al-Qattan, E.; Ramzy, H.; Elrahman, H. A.; Al-Qattan, A.; Al-Kandari, L.; Al-Shammeri, I. Value of PET/CT and MATLAB in Detection of COVID-19 in an Oncology Patient - Case Report. *American Journal of Internal Medicine* **2020**, *8* (5), 221-225.
- (40) Albano, D.; Bertagna, F.; Bertolia, M.; Bosio, G.; Lucchini, S.; Motta, F.; Panarotto, M. B.; Peli, A.; Camoni, L.; Bengel, F. M.; Giubbini, R. INCIDENTAL FINDINGS SUGGESTIVE OF COVID-19 IN ASYMPTOMATIC PATIENTS UNDERGOING NUCLEAR MEDICINE PROCEDURES IN A HIGH PREVALENCE REGION. *Journal of Nuclear Medicine* **2020**.
- (41) Das, K. M.; Lee, E. Y.; Langer, R. D.; Larsson, S. G. Middle East Respiratory Syndrome Coronavirus: What Does a Radiologist Need to Know? *American Journal of Roentgenology* **2016**, *206* (6), 1193-1201.
- (42) Alberts, I.; Vollnberg, B.; Sachpekidis, C.; Mingels, C.; Weidner, S.; Afshar-Oromieh, A.; Rominger, A. Incidental SARS-CoV-2-related findings in asymptomatic patients in [18F]-FDG-PET/CT—potential insights. *European Journal of Nuclear Medicine and Molecular Imaging* **2020**, *47* (9), 2068-2069.
- (43) Deng, Y.; Lei, L.; Chen, Y.; Zhang, W. The potential added value of FDG PET/CT for COVID-19 pneumonia. *European Journal of Nuclear Medicine and Molecular Imaging* **2020**, *47* (7), 1634-1635.
- (44) Saha, G. B.; MacIntyre, W. J.; Go, R. T. Cyclotrons and positron emission tomography radiopharmaceuticals for clinical imaging. *Seminars in Nuclear Medicine* **1992**, *22* (3), 150-161.
- (45) Tsuneyoshi, Y.; Tanaka, M.; Nagai, T.; Sunahara, N.; Matsuda, T.; Sonoda, T.; Ijiri, K.; Komiya, S.; Matsuyama, T. Functional folate receptor beta-expressing macrophages in

- osteoarthritis synovium and their M1/M2 expression profiles. *Scandinavian Journal of Rheumatology* **2012**, *41* (2), 132-140.
- (46) Paulos, C. M.; Turk, M. J.; Breur, G. J.; Low, P. S. Folate receptor-mediated targeting of therapeutic and imaging agents to activated macrophages in rheumatoid arthritis. *Adv. Drug Delivery Rev.* **2004**, *56* (8), 1205-1217.
- (47) Gnesin, S.; Müller, J.; Burger, I. A.; Meisel, A.; Siano, M.; Früh, M.; Choschzick, M.; Müller, C.; Schibli, R.; Ametamey, S. M.; Kaufmann, P. A.; Treyer, V.; Prior, J. O.; Schaefer, N. Radiation dosimetry of 18F-AzaFol: A first in-human use of a folate receptor PET tracer. *EJNMMI Research* **2020**, *10* (1), 32.
- (48) Müller, C.; Schibli, R.; Maurer, B. Can Nuclear Imaging of Activated Macrophages with Folic Acid-Based Radiotracers Serve as a Prognostic Means to Identify COVID-19 Patients at Risk? *Pharmaceuticals* **2020**, *13*, 238.
- (49) Schniering, J.; Benešová, M.; Brunner, M.; Haller, S.; Cohrs, S.; Frauenfelder, T.; Vrugt, B.; Feghali-Bostwick, C.; Schibli, R.; Distler, O.; Müller, C.; Maurer, B. 18F-AzaFol for Detection of Folate Receptor- β Positive Macrophages in Experimental Interstitial Lung Disease—A Proof-of-Concept Study. *Frontiers in Immunology* **2019**, *10*, 2724.
- (50) Hatori, A.; Yui, J.; Yamasaki, T.; Xie, L.; Kumata, K.; Fujinaga, M.; Yoshida, Y.; Ogawa, M.; Nengaki, N.; Kawamura, K.; Fukumura, T.; Zhang, M.-R. PET Imaging of Lung Inflammation with [18F]FEDAC, a Radioligand for Translocator Protein (18 kDa). *PLoS One* **2012**, *7* (9), e45065.
- (51) Locke, L. W.; Mayo, M. W.; Yoo, A. D.; Williams, M. B.; Berr, S. S. PET imaging of tumor associated macrophages using mannose coated 64Cu liposomes. *Biomaterials* **2012**, *33* (31), 7785-7793.
- (52) Ritchie, D.; Mileshkin, L.; Wall, D.; Bartholeyns, J.; Thompson, M.; Coverdale, J.; Lau, E.; Wong, J.; Eu, P.; Hicks, R. J.; Prince, H. M. In vivo tracking of macrophage activated killer cells to sites of metastatic ovarian carcinoma. *Cancer Immunology, Immunotherapy* **2006**, *56* (2), 155.
- (53) Rozenblum-Beddok, L.; Verillaud, B.; Paycha, F.; Vironneau, P.; Abulizi, M.; Benada, A.; Cross, T.; El-Deeb, G.; Vodovar, N.; Peretti, I.; Herman, P.; Sarda-Mantel, L. 99mTc-HMPAO-leukocyte scintigraphy for diagnosis and therapy monitoring of skull base osteomyelitis. *Laryngoscope Investigative Otolaryngology* **2018**, *3* (3), 218-224.
- (54) Zheng, J.; Liu, Y. 99mTc-Leukocyte Scintigraphy Revealed Viral Pulmonary Infection in a COVID-19 Patient. *Clinical Nuclear Medicine* **2020**, *45* (10).
- (55) Au - Linares, A.; Au - Couling, L. E.; Au - Carrera, E. J.; Au - Speth, R. C. Receptor Autoradiography Protocol for the Localized Visualization of Angiotensin II Receptors. *JoVE* **2016**, doi:10.3791/53866 (112), e53866.
- (56) Juengling, F. D.; Maldonado, A.; Wuest, F.; Schindler, T. H. The Role of Nuclear Medicine for COVID-19: Time to Act Now. *Journal of Nuclear Medicine* **2020**, *61* (6), 781-782.
- (57) Guha, S.; Hariharan, P.; Myers, M. R. Enhancement of ICRP's Lung Deposition Model for Pathogenic Bioaerosols. *Aerosol Sci. Technol.* **2014**, *48* (12), 1226-1235.
- (58) Evangelista, H.; Amaral, C.; Porto, L. C.; Gonçalves, S. J.; Sodré, E. D.; Nogueira, J.; dos Santos, A. M. G.; Cataldo, M. Modeling the initial phase of SARS-CoV-2 deposition in the respiratory tract mimicked by the 11C radionuclide. *medRxiv* **2020**, 10.1101/2020.07.27.20156836, 2020.07.27.20156836.
- (59) Kirkby, C.; Mackenzie, M. Is low dose radiation therapy a potential treatment for COVID-19 pneumonia? *Radiotherapy and Oncology* **2020**, *147*, 221.

- (60) Dhawan, G.; Kapoor, R.; Dhawan, R.; Singh, R.; Monga, B.; Giordano, J.; Calabrese, E. J. Low dose radiation therapy as a potential life saving treatment for COVID-19-induced acute respiratory distress syndrome (ARDS). *Radiotherapy and Oncology* **2020**, *147*, 212-216.
- (61) Bevelacqua, J. J.; Mortazavi, S. A. R.; Mortazavi, S. M. J. Re: Low-dose radiation therapy for COVID-19 pneumonia: is there any supportive evidence? *Int. J. Radiat. Biol.* **2020**, 10.1080/09553002.2020.1797213, 1-2.
- (62) Cosset, J. M.; Deutsch, É.; Bazire, L.; Mazon, J. J.; Chargari, C. Low dose lung radiotherapy for COVID-19-related cytokine storm syndrome: Why not? *Cancer Radiotherapie : Journal de la Societe Francaise de Radiotherapie Oncologique* **2020**, *24* (3), 179-181.
- (63) Roa, D.; Moyses, H.; Leon, S.; Hamrick, B.; Sarria, G. R.; Li, B.; Tajima, T.; Necas, A.; Guzman, C.; Paucar, O.; Gonzales, A.; Chalco, R.; Montoya, M.; Arque, Z.; Gonzales, A.; Hernandez, J. Rationale for using a C-arm fluoroscope to deliver a kilovoltage radiotherapy treatment to COVID-19 patients. *Medical Dosimetry*, 10.1016/j.meddos.2020.07.008.
- (64) Hertzog, R. G.; Bicheru, S. N. Radiotherapy in the fight against pneumonia associated with SARS-CoV-2. *Int. J. Radiat. Biol.* **2020**, 10.1080/09553002.2020.1822560, 1-4.
- (65) Salomaa, S.; Bouffler, S. D.; Atkinson, M. J.; Cardis, E.; Hamada, N. Is there any supportive evidence for low dose radiotherapy for COVID-19 pneumonia? *Int. J. Radiat. Biol.* **2020**, 10.1080/09553002.2020.1786609, 1-8.
- (66) Salomaa, S.; Cardis, E.; Bouffler, S. D.; Atkinson, M. J.; Hamada, N. Low dose radiation therapy for COVID-19 pneumonia: is there any supportive evidence? *Int. J. Radiat. Biol.* **2020**, 10.1080/09553002.2020.1762020, 1-4.
- (67) Kirsch, D. G.; Diehn, M.; Cucinotta, F. A.; Weichselbaum, R. Lack of supporting data make the risks of a clinical trial of radiation therapy as a treatment for COVID-19 pneumonia unacceptable. *Radiotherapy and Oncology* **2020**, *147*, 217-220.
- (68) Kefayat, A.; Ghahremani, F. Low dose radiation therapy for COVID-19 pneumonia: A double-edged sword. *Radiotherapy and Oncology* **2020**, *147*, 224-225.
- (69) Kim, Y.-S.; Brechbiel, M. W. An overview of targeted alpha therapy. *Tumor Biology* **2012**, *33* (3), 573-590.
- (70) Mulford, D. A.; Scheinberg, D. A.; Jurcic, J. G. The Promise of Targeted α -Particle Therapy. *Journal of Nuclear Medicine* **2005**, *46* (1 suppl), 199S-204S.
- (71) Boros, E.; Packard, A. B. Radioactive Transition Metals for Imaging and Therapy. *Chem. Rev. (Washington, DC, U. S.)* **2019**, *119* (2), 870-901.
- (72) Sgouros, G. Alpha-particles for targeted therapy. *Adv. Drug Delivery Rev.* **2008**, *60* (12), 1402-1406.
- (73) De Kruijff, M. R.; Wolterbeek, T. H.; Denkova, G. A. A Critical Review of Alpha Radionuclide Therapy—How to Deal with Recoiling Daughters? *Pharmaceuticals* **2015**, *8* (2).
- (74) Olafsen, T.; Elgqvist, J.; Wu, A. Protein Targeting Constructs in Alpha Therapy. *Current Radiopharmaceuticals* **2011**, *4* (3), 197-213.
- (75) Jurcic, J. G.; Levy, M. Y.; Park, J. H.; Ravandi, F.; Perl, A. E.; Pagel, J. M.; Smith, B. D.; Estey, E. H.; Kantarjian, H.; Cicic, D.; Scheinberg, D. A. Phase I Trial of Targeted Alpha-Particle Therapy with Actinium-225 (225Ac)-Lintuzumab and Low-Dose Cytarabine (LDAC) in Patients Age 60 or Older with Untreated Acute Myeloid Leukemia (AML). *Blood* **2016**, *128* (22), 4050-4050.
- (76) Heyerdahl, H.; Krogh, C.; Borrebæk, J.; Larsen, Å.; Dahle, J. Treatment of HER2-Expressing Breast Cancer and Ovarian Cancer Cells With Alpha Particle-Emitting 227Th-

- Trastuzumab. *International Journal of Radiation Oncology*Biography*Physics* **2011**, 79 (2), 563-570.
- (77) Pallares, R. M.; Agbo, P.; Liu, X.; An, D. D.; Gauny, S. S.; Zeltmann, S. E.; Minor, A. M.; Abergel, R. J. Engineering Mesoporous Silica Nanoparticles for Targeted Alpha Therapy against Breast Cancer. *ACS Appl. Mater. Interfaces* **2020**, 12 (36), 40078-40084.
- (78) Pallares, R. M.; Abergel, R. J. Nanoparticles for targeted cancer radiotherapy. *Nano Research* **2020**, 13 (11), 2887-2897.
- (79) Pallares, R. M.; Abergel, R. J. Transforming lanthanide and actinide chemistry with nanoparticles. *Nanoscale* **2020**, 12 (3), 1339-1348.
- (80) Dadachova, E. Future Vistas in Alpha Therapy of Infectious Diseases. *Journal of Medical Imaging and Radiation Sciences* **2019**, 50 (4), S49-S52.
- (81) Dadachova, E.; Patel, M. C.; Toussi, S.; Apostolidis, C.; Morgenstern, A.; Brechbiel, M. W.; Gorny, M. K.; Zolla-Pazner, S.; Casadevall, A.; Goldstein, H. Targeted Killing of Virally Infected Cells by Radiolabeled Antibodies to Viral Proteins. *PLOS Medicine* **2006**, 3 (11), e427.
- (82) Casadevall, A.; Dadachova, E.; Pirofski, L.-a. Passive antibody therapy for infectious diseases. *Nat. Rev. Microbiol.* **2004**, 2 (9), 695-703.
- (83) Tian, X.; Li, C.; Huang, A.; Xia, S.; Lu, S.; Shi, Z.; Lu, L.; Jiang, S.; Yang, Z.; Wu, Y.; Ying, T. Potent binding of 2019 novel coronavirus spike protein by a SARS coronavirus-specific human monoclonal antibody. *Emerging Microbes & Infections* **2020**, 9 (1), 382-385.
- (84) Wang, C.; Li, W.; Drabek, D.; Okba, N. M. A.; van Haperen, R.; Osterhaus, A. D. M. E.; van Kuppeveld, F. J. M.; Haagmans, B. L.; Grosveld, F.; Bosch, B.-J. A human monoclonal antibody blocking SARS-CoV-2 infection. *Nat. Commun* **2020**, 11 (1), 2251.
- (85) Yuan, M.; Wu, N. C.; Zhu, X.; Lee, C.-C. D.; So, R. T. Y.; Lv, H.; Mok, C. K. P.; Wilson, I. A. A highly conserved cryptic epitope in the receptor binding domains of SARS-CoV-2 and SARS-CoV. *Science* **2020**, 368 (6491), 630.
- (86) Pillarsetty, N.; Carter, L.; Lewis, J. S.; Reiner, T. Oncology-inspired treatment options for COVID-19. *Journal of Nuclear Medicine* **2020**.
- (87) Lowy, R. J. Ionizing radiation inactivation of medically relevant viruses. *Radiation Inactivation of Bioterrorism Agents* **2005**, 365, 175.
- (88) Prasad, S.; Potdar, V.; Cherian, S.; Abraham, P.; Basu, A.; Team, I.-N. N. Transmission electron microscopy imaging of SARS-CoV-2. *Indian Journal of Medical Research* **2020**, 10.4103/ijmr.IJMR_577_20 (2), 241.
- (89) Tracy, B. L.; Stevens, D. L.; Goodhead, D. T.; Hill, M. A. Variation in RBE for Survival of V79-4 Cells as a Function of Alpha-Particle (Helium Ion) Energy. *Radiat. Res.* **2015**, 184 (1), 33-45.
- (90) Song, H.; Senthamizhchelvan, S.; Hobbs, R. F.; Sgouros, G. Alpha Particle Emitter Radiolabeled Antibody for Metastatic Cancer: What Can We Learn from Heavy Ion Beam Radiobiology? *Antibodies* **2012**, 1 (2), 124-148.

For TOC graphics only:



Diagnostic, Prognostic and Therapeutic Use of Radiopharmaceuticals in the Context of SARS-CoV-2

Roger M. Pallares,¹ and Rebecca J. Abergel^{1,2*}

Brief Synopsis: Herein, we critically examine recent advances in the medical use of radiopharmaceuticals in the context of COVID-19.