

# UC Davis

## UC Davis Previously Published Works

### Title

Systematic review of single stage revision for prosthetic joint infection.

### Permalink

<https://escholarship.org/uc/item/3b30k9s4>

### Journal

World journal of orthopedics, 11(12)

### ISSN

2218-5836

### Authors

Lum, Zachary C  
Holland, Christopher Thomas  
Meehan, John P

### Publication Date

2020-12-01

### DOI

10.5312/wjo.v11.i12.559

Peer reviewed

## Systematic review of single stage revision for prosthetic joint infection

Zachary C Lum, Christopher Thomas Holland, John P Meehan

**ORCID number:** Zachary C Lum 0000-0002-5871-8539; Christopher Thomas Holland 0000-0003-0242-1549; John P Meehan 0000-0002-3752-4719.

**Author contributions:** Lum ZC designed and performed the research; Lum ZC and Holland CT analyzed the data; Lum ZC, Meehan JP, and Holland CT wrote and were responsible for revising the paper; Lum ZC and Meehan PJ supervised the manuscript. All authors read and approved the manuscript.

**Conflict-of-interest statement:** Authors declare no conflict of interests for this article.

**Open-Access:** This article is an open-access article that was selected by an in-house editor and fully peer-reviewed by external reviewers. It is distributed in accordance with the Creative Commons Attribution NonCommercial (CC BY-NC 4.0) license, which permits others to distribute, remix, adapt, build upon this work non-commercially, and license their derivative works on different terms, provided the original work is properly cited and the use is non-commercial. See: <http://creativecommons.org/licenses/by-nc/4.0/>

**Manuscript source:** Unsolicited

**Zachary C Lum**, Department of Orthopaedic Surgery, Davis Medical Center, University of California, Sacramento, CA 95817, United States

**Christopher Thomas Holland, John P Meehan**, Department of Orthopaedics, University of California, Davis Medical Center, Sacramento, CA 95817, United States

**Corresponding author:** Christopher Thomas Holland, MD, MSc, Surgeon, Orthopaedics, University of California, Davis Medical Center, 4860 Y Street, Suite 3800, Sacramento, CA 95817, United States. [ctholland@ucdavis.edu](mailto:ctholland@ucdavis.edu)

### Abstract

While advanced technology, increased medical knowledge and improved surgical technique has improved patient outcomes in total joint arthroplasty, prosthetic joint infection still remains one of the leading causes of increased healthcare costs, medical resources and societal burdens in orthopaedic care. Two stage arthroplasty revision remains the gold standard for treatment of prosthetic joint infection. Proponents of single stage revision arthroplasty for infection argue that it results in lower healthcare costs while improving patient reported functional outcomes and with equivalent success rates. Here we review the history of single stage revision arthroplasty, discuss the key principles, highlight the indications and contraindications, and review the reported outcomes with a focus on future developments of single stage revision arthroplasty for hip and knee periprosthetic joint infections.

**Key Words:** Prosthetic joint infection; Single stage; Revision total joint arthroplasty; Total knee arthroplasty; Infection

©The Author(s) 2020. Published by Baishideng Publishing Group Inc. All rights reserved.

**Core Tip:** Single stage revision for periprosthetic joint infection can be a successful operation with careful selection of the patient, infecting organism and precise surgical technique. The 3 key principles of bacterial sensitivities, thorough radical debridement and delivery of local and systemic antibiotics can result in similar infection free survivorship to two stage exchange. Future developments into this technique include its practice in culture negative infections or use of cementless implants. Randomized

manuscript

**Specialty type:** Orthopedics**Country/Territory of origin:** United States**Peer-review report's scientific quality classification**

Grade A (Excellent): 0

Grade B (Very good): B

Grade C (Good): 0

Grade D (Fair): 0

Grade E (Poor): 0

**Received:** August 30, 2020**Peer-review started:** August 30, 2020**First decision:** October 5, 2020**Revised:** October 20, 2020**Accepted:** November 29, 2020**Article in press:** November 29, 2020**Published online:** December 18, 2020**P-Reviewer:** Lass R**S-Editor:** Zhang L**L-Editor:** A**P-Editor:** Li JH

controlled trials may help further our understanding of single stage revision compared with two stage.

**Citation:** Lum ZC, Holland CT, Meehan JP. Systematic review of single stage revision for prosthetic joint infection. *World J Orthop* 2020; 11(12): 559-572

**URL:** <https://www.wjgnet.com/2218-5836/full/v11/i12/559.htm>

**DOI:** <https://dx.doi.org/10.5312/wjo.v11.i12.559>

## INTRODUCTION

In the early 1970s Dr. Hans Wilhelm Buchholz published extensive research into the properties of antibiotics and polymethylmethacrylate with respect to hip and knee replacement surgery. There, he was able to report consistently lower infection rates with addition of gentamycin antibiotics to the bone cement<sup>[1]</sup>. He was one of the first to report successful prophylactic treatment of endoprostheses with antibiotic loaded bone cement as well as surgical treatment by single exchange arthroplasty for infected prostheses<sup>[2]</sup>. Buchholz's experience was unique as treatment of prosthetic joint infections (PJI) were evolving during this time and two-stage exchange arthroplasty was proving to have improved infection control in other parts of the world.

In the modern treatment paradigm, two-stage exchange arthroplasty for PJI is the gold standard treatment. However, more centers around the world are challenging that concept by reporting their successful results of single stage exchange arthroplasty, with techniques and principles similar to the original ones described by Buchholz's center at the ENDO Klinik in Hamburg, Germany<sup>[3-6]</sup>. With a globalization of education and technology, improvements to this process has allowed for a better understanding of single stage exchange arthroplasty. We report the current literature regarding key principles, indications, contraindications, outcomes and future direction of single stage revision arthroplasty for prosthetic hip and knee infections.

## REASONING FOR SINGLE STAGE

Periprosthetic joint infection is one of the most common reasons for early, less than 2 years, and all-cause revisions in total knee arthroplasty and total hip arthroplasty<sup>[7-9]</sup>. With a rising total number of both primary joint procedures and periprosthetic joint infections, understanding surgical management options are important, especially in a value-based healthcare system<sup>[10]</sup>. Single stage revision (SSR) for PJI (SSR PJI) has been reported to have equivalent infection-free success compared to two stage revision, with lower mortality and morbidity, with less hospitalizations, shorter antibiotic treatment duration, and lower overall healthcare costs<sup>[11-15]</sup> (Table 1). The ability to perform one less operation appeals to patients on many levels and naturally will lend itself to lower the risks of an additional operation.

Two stage revision is not without its complications. Gomez *et al*<sup>[16]</sup> reviewed 504 patients undergoing two stage revision for PJI at 56 mo. Only 82% of patients underwent final implantation. In patients with gram negative infection, the re-implantation rate was even lower at 64%. 11% of patients required a spacer exchange from reinfection, and 10.3% of patients died at 2 years. The option for the surgeon to perform single stage revision may help reduce the risk of some devastating outcomes from a second operation.

## KEY PRINCIPLES OF SINGLE STAGE

There are 3 key principles of SSR PJI<sup>[17]</sup>. The first is the organism must be known with sensitivities and bacterial minimally inhibitory concentrations. Single stage revision should not be performed without this information as antibiotic treatment cannot be tailored to combat the infection. Aspiration of the joint is performed with the patient off antibiotics for at least 14 d, using an "as sterile as possible technique" and with a culture incubation period of 14 d. Studies have suggested anesthetics such as

Table 1 Single stage revision outcomes for total knee arthroplasty and total hip arthroplasty

Ref.	Year	PJI	Cases	Reinfection	Follow-up (in year)
Freeman <i>et al</i> <sup>[47]</sup>	1985	Knee	8	0	2
Göksan <i>et al</i> <sup>[48]</sup>	1992	Knee	18	2 (11%)	5
Scott <i>et al</i> <sup>[49]</sup>	1993	Knee	10	3 (30%)	
Silva <i>et al</i> <sup>[50]</sup>	2002	Knee	37	4 (11%)	5
Buechel <i>et al</i> <sup>[51]</sup>	2004	Knee	22	2 (9%)	10
Whiteside <i>et al</i> <sup>[52]</sup>	2011	Knee	18	1 (6%)	5.2
Parkinson <i>et al</i> <sup>[53]</sup>	2011	Knee	22	0	2
Singer <i>et al</i> <sup>[54]</sup>	2012	Knee	63	3 (5%)	3
Klatte <i>et al</i> <sup>[55]</sup>	2014	Knee	4	1 (25%)	2.1
Tibrewal <i>et al</i> <sup>[13]</sup>	2014	Knee	50	1 (2%)	10.5
Haddad <i>et al</i> <sup>[14]</sup>	2015	Knee	28	0	6.5
Labruyère <i>et al</i> <sup>[56]</sup>	2015	Knee	9	0	5
Holland <i>et al</i> <sup>[57]</sup>	2019	Knee	26	1 (4%)	5.3
Siddiqi <i>et al</i> <sup>[58]</sup>	2019	TKA	57	8 (14%)	4.4
Abdelaziz <i>et al</i> <sup>[59]</sup>	2020	TKA	72	8 (11%)	4.2
Ji <i>et al</i> <sup>[60]</sup>	2020	Both	51	5 (10%)	4.4
Carlsson <i>et al</i> <sup>[61]</sup>	1978	Hip	77	17 (22%)	
Hughes <i>et al</i> <sup>[62]</sup>	1979	Hip	13	4 (31%)	
Buchholz <i>et al</i> <sup>[2]</sup>	1981	Hip	640	130 (20%)	4.3
Miley <i>et al</i> <sup>[63]</sup>	1982	Hip	47	6 (13%)	4
Weber <i>et al</i> <sup>[64]</sup>	1986	Hip	8	2 (25%)	6
Wroblewski <i>et al</i> <sup>[4]</sup>	1986	Hip	102	9 (9%)	3.2
Sanzén <i>et al</i> <sup>[65]</sup>	1988	Hip	102	25 (25%)	7
Hope <i>et al</i> <sup>[66]</sup>	1989	Hip	72	9 (13%)	3.75
Raut <i>et al</i> <sup>[67]</sup>	1994	Hip	57	8 (14%)	7.3
Mulcahy <i>et al</i> <sup>[68]</sup>	1996	Hip	15	0	4
Ure <i>et al</i> <sup>[69]</sup>	1998	Hip	22	0	10.5
Callaghan <i>et al</i> <sup>[6]</sup>	1999	Hip	24	2 (8%)	10
Rudelli <i>et al</i> <sup>[70]</sup>	2008	Hip	32	2 (6%)	5
Winkler <i>et al</i> <sup>[71]</sup>	2008	Hip	37	3 (8%)	4.4
Yoo <i>et al</i> <sup>[72]</sup>	2008	Hip	12	1 (8%)	7.2
Oussedik <i>et al</i> <sup>[39]</sup>	2010	Hip	11	0	6.8
De Man <i>et al</i> <sup>[40]</sup>	2011	Hip	22	0	3.8
Klouche <i>et al</i> <sup>[11]</sup>	2012	Hip	38	0	2
Choi <i>et al</i> <sup>[73]</sup>	2013	Hip	17	3 (18%)	5.1
Hansen <i>et al</i> <sup>[26]</sup>	2013	Hip	27	8 (30%)	2.25
Bori <i>et al</i> <sup>[46]</sup>	2014	Hip	24	1 (4%)	3.6
Jenny <i>et al</i> <sup>[74]</sup>	2014	Hip	65	17 (26%)	5
Klatte <i>et al</i> <sup>[55]</sup>	2014	Hip	6	0	2.1
Wolf <i>et al</i> <sup>[27]</sup>	2014	Hip	37	24 (65%)	2
Zeller <i>et al</i> <sup>[5]</sup>	2014	Hip	157	8 (5%)	3.4

Ebied <i>et al</i> <sup>[75]</sup>	2016	Hip	33	1 (3%)	6
Ilchman <i>et al</i> <sup>[76]</sup>	2016	Hip	39	0	6.6
Born <i>et al</i> <sup>[77]</sup>	2016	Hip	28	0	7
Lange <i>et al</i> <sup>[78]</sup>	2017	Hip	56	5 (91%)	4
Whiteside <i>et al</i> <sup>[79]</sup>	2017	Hip	21	1 (95%)	5.2
Zahar <i>et al</i> <sup>[80]</sup>	2018	Hip	85	5 (6%)	10.5
Bori <i>et al</i> <sup>[81]</sup>	2018	Hip	19	1 (5%)	
Wolff <i>et al</i> <sup>[82]</sup>	2019	Hip	26	1 (96%)	15
Ji <i>et al</i> <sup>[24]</sup>	2019	Hip	111	12 (11%)	4.8

Study author listed, year of publication, joint investigated, number of cases, reinfection rate, and follow up reported. PJI: Prosthetic joint infections.

lidocaine and ethyl chloride spray can affect bacterial growth<sup>[18,19]</sup>. Because of this, our institution does not use local anesthetic while aspirating the joint.

The second principle is the debridement. This may be the most important principle of SSR. Mortality after PJI has been worse than the 5 most common cancers, with mortalities reaching up to 5% per year postoperatively<sup>[20,21]</sup>. Treating the debridement similarly to cancer necessitates a radial resection of all infected tissue in order to obtain clean margins and healthy tissue. Aggressive debridement includes anterior and posterior capsule, and even the abductors when addressing PJI in the hip. In knees, the entire synovial membrane is removed *en bloc* so as to not contaminate the joint and to minimize risk of contaminating the entire surgical field. The initial incision excises the previous scar if able, and the debridement removes all peri-incisional tissue towards the joint. This is culminated in removal of the entire block of infected tissue. This style of debridement is in contrast to two-stage revision, where intra-lesional debridement occurs and may leave infected tissue throughout the surgical wound. In certain instances, if there is a sinus tract that can be incorporated in the planned incision then it will be excised as well. Unresectable sinus tracts, and involvement of neurovascular bundles are contraindications for single stage revision. Lastly, while some studies report use of methylene blue injected into the joint prior to resection to ensure adequate resection works for two stage, it has not been studied in single stage as the resection margins need to be greater and the goal of the debridement is not intra-lesional<sup>[22]</sup>.

The third principle is both local and systemic antibiotic delivery tailored to the known pathologic organism. Local antibiotic delivery can be in the form of cement, powder or intra-articular infusion<sup>[23,24]</sup>. The delivery of antibiotics locally is known to achieve much higher tissue concentrations at the site of infection. Naturally, the use of bactericidal antibiotics such as aminoglycosides, cephalosporins, fluoroquinolones, metronidazole, penicillin and vancomycin will provide better treatment than bacteriostatic antibiotics (Table 2)<sup>[17]</sup>. Some authors advocate for Clindamycin as an acceptable bacteriostatic antibiotic<sup>[17]</sup>. Up to 10% of the dry crystalline weight of antibiotics can be added to the cement without significant mechanical loss<sup>[17]</sup>. Addition of slightly more (approximately 1/8<sup>th</sup> bottle per batch) liquid monomer may allow better viscosity characteristics for mixing. While local antibiotics generate high intra-articular concentrations with lower systemic risks, there are case reports of systemic complications such as renal or hepatic failure, and allergic reaction<sup>[25]</sup>. Surgeons must be mindful of dosage in patients with these risk factors. However, local antibiotic use is a key principle. Failure to add local antibiotics has resulted in lower infection free survivorship between 56%-70% compared to intravenous antibiotics only<sup>[26,27]</sup>.

Combination of these three principles in single stage revision for periprosthetic joint infection has resulted in midterm infection free survivorship in the 80%-95% range; similar to two-stage revision arthroplasty<sup>[28]</sup>.

## INDICATIONS

Single stage revision for PJI is a viable treatment option that has gradually increased in acceptance and popularity at certain specialized centers around the world. There has been an increasing body of published literature on this topic with favorable results<sup>[3-6]</sup>.

**Table 2 Bactericidal antibiotics vs bacteriostatic antibiotics**

Bactericidal antibiotics	Bacteriostatic
Aminoglycosides, cephalosporins, fluoroquinolones, metronidazole, penicillin, vancomycin	Chloramphenicol, clindamycin, erythromycin, sulfamethoxazole, tetracycline, trimethoprim

It is important to use local bacteriocidal antibiotics to combat periprosthetic joint infection in single stage revision. The exception is clindamycin where it has been reported to have success in single stage revision for infection.

The first goal is to confirm the presence of PJI in the patient. The International Consensus Meeting (ICM) in Philadelphia 2018 gathered world leaders in orthopaedic surgery in their subspecialized fields and created consensus guidelines based upon available current published literature. The musculoskeletal infection society, part of the ICM, moderately agreed on criteria for diagnosis of PJI based upon patient laboratory tests, cultures and synovial aspiration. Patients are considered positive for PJI if they fulfill one of two major criteria: Two positive cultures of the same organism or a sinus tract with evidence of communication to the joint or prosthesis. Patients are also considered positive if they have 6 or more points, inconclusive if 3-5 points, and negative if less than 3 points on the minor criteria system. Elevated C-reactive protein or D-Dimer (2 points), elevated ESR (1 point), elevated synovial white blood cell or ++ leukocyte esterase test stripe or positive alpha defensin (3 points), elevated synovial polymorphoneutrophils percentage (2 points), single positive culture (2 points), positive histology such as frozen section (3 points), intraoperative purulence (3 points). A definition and threshold of acute and chronic infection is defined in [Table 3](#). Difference from the 2013 criteria is the addition of leukocyte esterase, alpha defensin, and D-Dimer which may improve sensitivity compared to the previous criteria<sup>[29]</sup>.

Although some authors report chronic PJI to be a strict timeframe of more than 4 wk, the key to diagnosis of chronic infection is the establishment of biofilm and the inability to eradicate the bacterial burden without removal of foreign material including the metallic implants, polymethylmethacrylate, and polyethylene bearings. Biofilm is created when groups of the infectious micro-organism(s) aggregate together on a surface embedded in a glycosylated extra-cellular matrix. This matrix prevents penetration of antibiotics, and allows enhanced cell to cell communication for microbe protection and nutrition. Although true biofilm establishment by microbes vary based on organism and conditions, early *in vitro* studies have suggested formation may occur as early as 8 h<sup>[30]</sup>. However, 4 wk is usually the acceptable limit for the ability to debride, lower bacterial burden, and remove sufficient biofilm material, while retaining implants.

Theoretically patients with established biofilm and PJI can be candidates for single stage revision<sup>[31]</sup> ([Figure 1](#)). Although some authors consider virulent organisms a relative contraindication, we further discuss that it may not be a strict contraindication. Patients in the acutely infected period may be better off treated with debridement, antibiotics, irrigation and prosthesis retention<sup>[32]</sup>. This method assumes biofilm has not been established and bacterial burden can be lowered enough for the host's own immune system to clear infection. Surgical options for chronic infection includes single stage revision, two stage revision, chronic suppression, or amputation/disarticulation.

A host's comorbidities play an important role in outcomes in primary and revision total joint arthroplasty. The increase in count and severity of comorbidities can result in higher rates of medical and surgical complications, including infection, reoperation and death. McPherson *et al*<sup>[33]</sup> classified periprosthetic joint infections in hips into infection type, host class, and local extremity grade. Host class correlated with the ability to clear infection, undergo successful reimplantation, and avoid amputation or permanent resection arthroplasty. Host class A has no comorbidities, host class B has 1-2 comorbidities and host class C has 3 or more comorbidities or were essentially immunocompromised with absolute neutrophil count < 1000, CD4 count below 100, intravenous drug abuse, chronic active infection in another site, or dysplasia or neoplasm of immune system. Comorbidities are listed in [Table 4](#). Specific to single stage revision for PJI, one study suggested a host class A had better success of infection clearance compared to host class B or C<sup>[27]</sup>. Although this study did not follow one of the principles of single stage, which is local antibiotic delivery, they were still able to achieve 100% eradication of infection in that subset of patients. European centers more selective in their single stage revision criteria may exclude immunocompromised individuals<sup>[14,31]</sup>. Although there is some variance in patient selection criteria, reports

**Table 3 International Consensus Meeting 2018 Guidelines for prosthetic joint infection for hip and knee arthroplasty**

Major criteria			
Two positive cultures of the same organism / Sinus tract with communication to the joint or prosthesis			
Minor criteria			
Criteria	Acute threshold	Chronic threshold	Score
CRP (mg/L) or D Dimer (ug/L)	100; unknown	10; 860	2
ESR (mm/h)	No role	30	1
Synovial WBC or leukocyte esterase or alpha defensin	10000; ++; 1.0	3000; ++; 1.0	2
Synovial PMN %	90	70	2
Single positive culture			2
Positive histology			3
Positive intraoperative purulence			3

A positive prosthetic joint infection is one of two major criteria, or 6 or more points for minor criteria. 3-5 points for minor criteria is inconclusive and less than 3 points is negative for prosthetic joint infection. WBC: White blood cell; PJI: Prosthetic joint infection; CRP: C-reactive protein; ESR: Erythrocyte sedimentation rate; PMN: Polymorphonuclearleukocyte.

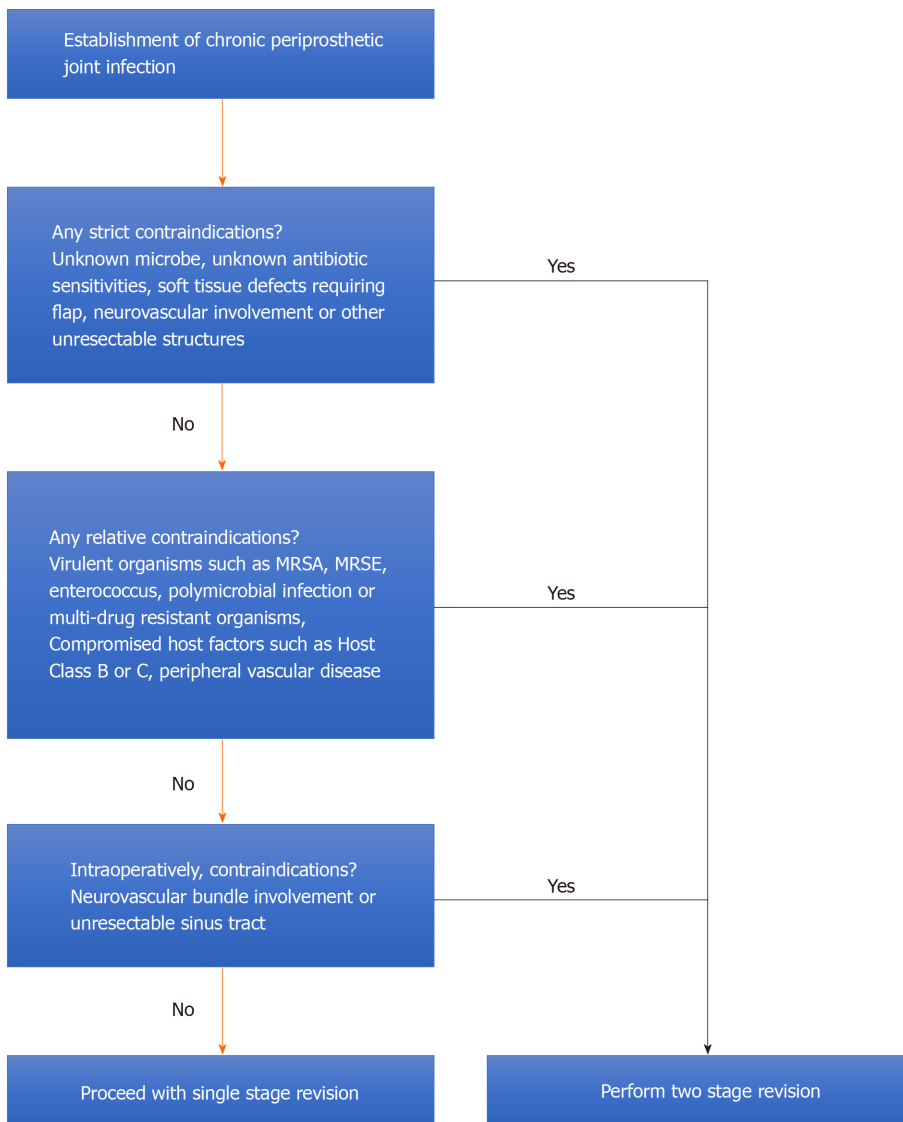
**Table 4 McPherson host class comorbidities**

Systemic host compromising factors		
Age ≥ 80 yr	Alcoholism	Chronic cellulitis or dermatitis
Chronic indwelling catheter	Malnutrition (albumin < 3 g/dL)	Current nicotine use
Diabetes	Hepatic insufficiency	Immunosuppressive drugs
Malignancy (history or active)	Pulmonary insufficiency	Renal failure on dialysis
Systemic inflammatory disease	Systemic immune compromised disease or infection (HIV, AIDS)	

McPherson hip infection classification comprises of infection type, host type and local factors. Host factors are graded A, B or C. A has none of the listed factors, B has 2 or fewer factors, C has 3 or more factors or severe immunocompromise defined by: absolute neutrophil count < 1000/mm<sup>3</sup>, CD<sub>4</sub> T cell count < 100/mm<sup>3</sup>, intravenous drug abuse, or dysplasia or neoplasm of the immune system. HIV: Human immunodeficiency virus; AIDS: Acquired immune deficiency syndrome.

that followed the 3 listed principles had higher infection free success than those that did not<sup>[26,27]</sup>. Further determination of patient selection will be discussed later in this article.

Knowledge of the infecting organism and appropriate antibiotic sensitivities is of critical importance. It is worth repeating, a culture negative infection is a contraindication to single stage revision for PJI. Highly virulent organisms such as methicillin resistant staphylococcus aureus or methicillin resistant staphylococcus epidermidis (MRSA)/(MRSE) or enterococcus, multi-drug resistance, and rare flora may make infection eradication more difficult. Additionally, inability to add local antibiotics to combat the infection due to high drug resistance or inactivation in cement may be a contraindication to single stage revision<sup>[31]</sup>. Other factors that may make single stage revision difficult would be repeat surgeries, repeat infections and enterococcus infection. ENDO Klinik retrospectively reviewed their subsequent failures of single stage revision in hip and knee arthroplasty. For knees, failures correlated to previous failed revision for infection, enterococcus or streptococcus infection. For hips, wound drainage > 1 wk, previous operation and enterococcus infection were risk factors for reoperation or re-infection<sup>[34,35]</sup>. Although these were not contraindications for single stage, surgeons considering performing single stage revision arthroplasty should acknowledge the difficulty eradicating infection in these situations.



**Figure 1** Single stage revision flowchart.

### **ICM 2018 indications**

In July 2018, the International Consensus Meeting on Periprosthetic Joint Infection was held in Philadelphia, PA with over 850 international delegates specializing in the field of orthopaedic surgery. There they developed consensus guidelines on management of various episodes of periprosthetic joint infection based upon current literature. Single stage revision for infection was discussed and 4 consensus agreements were published<sup>[31]</sup>.

The potential advantages of a 1 stage exchange arthroplasty are multiple, including lower surgical morbidity and mortality, earlier functional return, lower healthcare and global economic costs, and increase in health related quality adjusted life years. This statement had an 89% consensus agreement with a moderate level of evidence (LOE).

The indications and contraindications listed below had 93% consensus agreement with a moderate LOE (Table 5): (1) Indications: Non-immunocompromised host, absence of systemic sepsis, minimal bone/soft tissue loss allowing primary wound closure, known pathologic organism with sensitivities preoperatively; and (2) Contraindications: Severe soft tissue defect or unresectable sinus tract, culture negative PJI, unable to perform a radical debridement, unable to deliver local antibiotic treatment, lack of bone stock for fixation of new implant.

There is a role for single stage exchange arthroplasty in the setting of acute cementless total hip arthroplasty (THA) PJI. This statement had an 89% consensus agreement with a moderate LOE.

Putting aside the effect on successful treatment of PJIs, it is logical that a single surgical procedure puts patients at lower risk of both mortality and morbidity



**Table 5 International consensus meeting indications and contra-indications for single stage revision for prosthetic joint infection**

Indications	Contra-indications
Non-immunocompromised host	Severe damage to soft tissues were direct closure not possible or inexcisable complex sinus tract with old scar
Absence of systemic sepsis	Culture negative PJI
Minimal bone/soft tissue loss allowing primary closure	Inability to perform radical debridement
Isolation of pathologic organism preoperatively	Unable to give local antibiotic treatment
Known sensitivities to bactericidal treatment	No proper bone stock available for fixation

PJI: Prosthetic joint infection.

compared to a 2-stage exchange arthroplasty that involves 2 separate operations. 83% of the ICM agreed using moderate LOE.

These 4 agreements suggested single stage revision for PJI may result in similar outcomes with one less operation in the appropriately selected patient with guidance to whom may be good candidates.

## CONTRAINDICATIONS

Although certain centers have attested to performing SSR in a majority of their infection cases, they have a few specific criteria that are absolute contraindications for single stage revision<sup>[17]</sup>. It is worth mentioning, a culture negative infection where bacterial sensitivities are unknown does not allow for properly targeted antibiotic treatment. Inability to obtain adequate primary soft tissue coverage, infection involving the neurovascular bundles, and other unresectable infected areas are also contraindications for single stage revision. Other authors successfully performing single stage revision for PJI have their own indications and contraindications. Haddad *et al*<sup>[14]</sup> reported on 102 patients undergoing treatment for total knee arthroplasty (TKA) PJI. 28 underwent single stage revision while 74 underwent two stage revision. At 6.5 years, no patients in the single stage developed reinfection compared to 5 (9%) of the two stage. In addition to the ICM contraindication criteria, they excluded patients with peripheral vascular disease, polymicrobial infection, and multi-resistant organisms such as MRSA/MRSE. Their retrospective results should not be interpreted as single stage revision is better than two stage, as there is inherent patient selection bias, but that in properly selected individuals it can work as successfully.

## OUTCOMES OF SINGLE STAGE PROSTHETIC JOINT INFECTIONS

Infection free success for properly indicated single stage revision varies from 77%-100% by a variety of studies<sup>[23,24,28]</sup>. Failures of single stage for aseptic loosening on long term follow-up can range from 5%-18%, although this is not dramatically different than aseptic loosening in two stage revisions<sup>[13,34-37]</sup>. Evaluating reoperations from single stage revisions, Citak *et al*<sup>[34]</sup> reported on their reasons for re-revision in single stage TKAs in 91 patients out of 697 patients at the ENDO Klinik. There were 47/697 (6.7%) reinfections and 37/697 (5.3%) revisions for aseptic loosening, three patients underwent revision for patellar mal-tracking, three underwent revision for periprosthetic fracture and one for knee dislocation. Abdelaziz *et al*<sup>[35]</sup> also reported on their reasons for re-revision in single stage THA PJI. Out of 121 reoperations, 53 (40%) were for instability, 40 (33%) reinfection, 16 (13%) aseptic loosening, seven (6%) periprosthetic fracture, three (2%) implant failure, and one each for wound healing disorder and heterotopic ossification. These reasons for revision arthroplasty were similar to those who underwent two stage revisions<sup>[28]</sup>.

Patient reported outcomes after single stage revision have been suggested to be comparable to two stage<sup>[12,14,38]</sup>. Haddad *et al*<sup>[14]</sup> reported their single stage TKA revisions had knee society scores of 88 compared to 76 in their two stage ( $P < 0.02$ ), and better visual analogy scores satisfaction scores of 7.82 compared to 6.18 in the two stage cohort ( $P < 0.01$ ). Comparative studies investigating outcomes after single stage

THA revision had equivalent harris hip scores (HHS) in three studies and better in one<sup>[39-42]</sup>. Oussedik *et al*<sup>[39]</sup> reported on 50 patients undergoing revision for THA PJI with 11 patients undergoing single stage compared with 39 with two stage revision. HHS in the single stage was 87.8 compared with 75.5 in the two stage ( $P < 0.001$ ) as well as change in HHS favoring single stage ( $P = 0.027$ ). Authors recognized the retrospective selection bias of single stage, but suggested for appropriately indicated patients, single stage may provide improved functional outcomes. In additional, Markov model decision tree analyses and quality of life adjusted values after single stage revision has also been calculated to have favorability over two stage revision<sup>[15,43]</sup>. Although healthcare cost savings, outcomes and improved morbidity from one less operation may be appealing for single stage revision, the larger effort of work and lower compensatory reward may be de-incentivizing for the surgeon. Fehring *et al*<sup>[44]</sup> found single stage revision required more time and effort and less compensation compared to primary arthroplasty. They encouraged payors to improve reimbursement to incentivize and align the goals of the healthcare system.

Lastly, failure of a previous single revision is not a contraindication for a repeat single stage revision. Knowledge of the three principles, organism type, antimicrobial sensitivities, and thorough debridement is crucial. However, previous risk factors for single stage revision failure such as poor host class factors, enterococcus infection, virulent organism infection, polymicrobial infection or multiple previous operations may guide the treating surgeon towards two stage revision gold standard.

---

## TECHNICAL PEARLS

---

After obtaining a diagnosis of PJI, with cultures and antibiotic sensitivities, a meticulous debridement occurs. Preoperative intravenous antibiotics are given, tailored to the organism. The operative theatre where the single stage revision is performed is not followed by another primary joint procedure, and a deep extended cleaning of the room is performed after. We typically will use a sterile tourniquet for a total knee unless the planned incision and reconstruction does not give enough operative space. The tourniquet is deflated after removal of implants and re-inflated at the start of the second re-implantation procedure. Hemostasis should be achieved at the deflation. The previous skin incision is utilized with incorporation of a sinus tract if present. Excision of the scar, sinus tract, surgical tract, and all fibrous infected tissue down to the capsule is performed in a single piece leaving normal tissue to remain. Exposure of the capsule and all unhealthy tissue is removed *en bloc*. Removal of the capsule going down to bone is performed in an attempt to minimize surgical field contamination. Meticulous hemostasis is achieved. Removal of implants is performed routinely with marrow reaming to remove any infectious material. Pulsatile lavage with at least 6 liters of normal saline solution is then performed, an optional povidone-iodine solution diluted to 0.3% with irrigation and then the wound is packed with chlorohexidine soaked sponges. Povidone iodine solution is not routinely used at our center as the infection rates are lower with simple saline irrigation. The wound is loosely closed at the skin, all drapes, gowns, gloves, table with all previous instruments are removed. The patient is then re-prepped, re-draped, all new instruments, new table, new gowns and gloves, and new scrubs for the surgical staff is performed for the second stage of the procedure. The second stage includes another irrigation, a change of gloves and suction tips, and proceeding to re-implantation. At this point, the procedure is similar to the second stage of a two-stage revision. Local antibiotics are mixed in cement if cementation is occurring, or topical antibiotics are added down the canals, in the acetabulum and in the joint prior to deep closure. Cementless implants in total hip arthroplasty have been described with success, with all authors adding topical and intravenous antibiotics to their treatment regimen. Antibiotics in calcium sulfate beads are an optional way to deliver the intra-articular concentrations of antibiotics. Dosages of more than 20 cc of beads may cause increased drainage, or other complications such as heterotopic ossification, or hypercalcemia<sup>[45]</sup>. Postoperatively, specific targeted intravenous antibiotics are given for 6 wk with assistance in management by an infectious disease specialist with sub-specialization in periprosthetic joint infections.

## FUTURE DEVELOPMENTS

Single stage revision arthroplasty for infection has been in development since the 1970s, initially pioneered by Buchholz *et al.*<sup>[1,2]</sup>, it has now been furthered by surgeons as technology and surgical techniques continue to improve. One area of progress is in the use of cementless THA implants in single stage revision. The ICM 2018 suggested potential viability of this technique in response to several articles reporting successful infection free survivorship. Bori *et al.*<sup>[46]</sup> reported on single stage THA revision in 24 patients with cementless femoral components, but antibiotic cemented acetabular components in nine patients. Only one patient (95.8%) developed an infection at 44 mo follow-up. Ji *et al.*<sup>[24]</sup> reported on 111 patients with various infecting organisms using both cementless femur and acetabular components with 89.2% infection free survivorship at 58 mo. They applied intra-articular antibiotic infusions in MRSE/MRSA, fungal or culture negative in addition to powdered local antibiotics. An important note is that these patients still received local antibiotic delivery by other methods such as intra-articular infusion or topical powder application, a key principle for this technique.

To date, there is no algorithm for predicting what specific patient factors, organism factors, or surgical factors lead to infection free success in single stage revision for PJI. Although host factors such as McPherson Host Class C, virulent organisms such as fungal, MRSA/MRSE or culture negative, or surgical factors such as inadequate radical debridement may lead to lower infection free survival, it is not known how many factors will lead to failure or success of single stage revision. These are potential future research goals for improvement.

Naturally, single stage revision for PJI has an inherent retrospective selection bias due to less virulent organisms and healthier hosts when comparing to two stage revision. Undergoing a single operation will typically be less costly and have lower morbidity and mortality for the patient. Ultimately, a randomized control trial may be necessary to fully realize who may benefit from this procedure and by how much.

## CONCLUSION

Single stage revision for periprosthetic joint infection can be a successful operation with careful selection of the patient, infecting organism and precise surgical technique<sup>[47-52]</sup>. The 3 key principles of bacterial sensitivities, thorough radical debridement and delivery of local and systemic antibiotics can result in similar infection free survivorship to two stage exchange. Future developments into this technique include its practice in culture negative infections or use of cementless implants. Randomized controlled trials may help further our understanding of single stage revision compared with two stage.

## REFERENCES

- 1 **Buchholz HW**, Elson RA, Heinert K. Antibiotic-loaded acrylic cement: current concepts. *Clin Orthop Relat Res* 1984; 96-108 [PMID: 6386264 DOI: 10.1097/00003086-198411000-00014]
- 2 **Buchholz HW**, Elson RA, Engelbrecht E, Lodenkämper H, Röttger J, Siegel A. Management of deep infection of total hip replacement. *J Bone Joint Surg Br* 1981; 63-B: 342-353 [PMID: 7021561 DOI: 10.1302/0301-620X.63B3.7021561]
- 3 **Zahar A**, Kendoff DO, Klatt TO, Gehrke TA. Can Good Infection Control Be Obtained in One-stage Exchange of the Infected TKA to a Rotating Hinge Design? *Clin Orthop Relat Res* 2016; 474: 81-87 [PMID: 26100256 DOI: 10.1007/s11999-015-4408-5]
- 4 **Wroblewski BM**. One-stage revision of infected cemented total hip arthroplasty. *Clin Orthop Relat Res* 1986; 103-107 [PMID: 3769248 DOI: 10.1097/00003086-198610000-00014]
- 5 **Zeller V**, Lhotellier L, Marmor S, Leclerc P, Krain A, Graff W, Ducroquet F, Biau D, Leonard P, Desplaces N, Mamoudy P. One-stage exchange arthroplasty for chronic periprosthetic hip infection: results of a large prospective cohort study. *J Bone Joint Surg Am* 2014; 96: e1 [PMID: 24382729 DOI: 10.2106/JBJS.L.01451]
- 6 **Callaghan JJ**, Katz RP, Johnston RC. One-stage revision surgery of the infected hip. A minimum 10-year followup study. *Clin Orthop Relat Res* 1999; 139-143 [PMID: 10611868 DOI: 10.1097/00003086-199912000-00014]
- 7 **Sharkey PF**, Lichstein PM, Shen C, Tokarski AT, Parvizi J. Why are total knee arthroplasties failing today--has anything changed after 10 years? *J Arthroplasty* 2014; 29: 1774-1778 [PMID: 25007726 DOI: 10.1016/j.arth.2013.07.024]
- 8 **Delanois RE**, Mistry JB, Gwam CU, Mohamed NS, Choksi US, Mont MA. Current Epidemiology of

- Revision Total Knee Arthroplasty in the United States. *J Arthroplasty* 2017; **32**: 2663-2668 [PMID: 28456561 DOI: 10.1016/j.arth.2017.03.066]
- 9 **Dobzyniak M**, Fehring TK, Odum S. Early failure in total hip arthroplasty. *Clin Orthop Relat Res* 2006; **447**: 76-78 [PMID: 16505710 DOI: 10.1097/01.blo.0000203484.90711.52]
  - 10 **Kurtz SM**, Ong KL, Lau E, Bozic KJ. Impact of the economic downturn on total joint replacement demand in the United States: updated projections to 2021. *J Bone Joint Surg Am* 2014; **96**: 624-630 [PMID: 24740658 DOI: 10.2106/JBJS.M.00285]
  - 11 **Klouché S**, Leonard P, Zeller V, Lhotellier L, Graff W, Leclerc P, Mamoudy P, Sariali E. Infected total hip arthroplasty revision: one- or two-stage procedure? *Orthop Traumatol Surg Res* 2012; **98**: 144-150 [PMID: 22364829 DOI: 10.1016/j.otsr.2011.08.018]
  - 12 **Leonard HA**, Liddle AD, Burke O, Murray DW, Pandit H. Single- or two-stage revision for infected total hip arthroplasty? *Clin Orthop Relat Res* 2014; **472**: 1036-1042 [PMID: 24057192 DOI: 10.1007/s11999-013-3294-y]
  - 13 **Tibrewal S**, Malagelada F, Jeyaseelan L, Posch F, Scott G. Single-stage revision for the infected total knee replacement: results from a single centre. *Bone Joint J* 2014; **96-B**: 759-764 [PMID: 24891575 DOI: 10.1302/0301-620X.96B6.33086]
  - 14 **Haddad FS**, Sukeik M, Alazzawi S. Is single-stage revision according to a strict protocol effective in treatment of chronic knee arthroplasty infections? *Clin Orthop Relat Res* 2015; **473**: 8-14 [PMID: 24923669 DOI: 10.1007/s11999-014-3721-8]
  - 15 **Srivastava K**, Bozic KJ, Silverton C, Nelson AJ, Makhni EC, Davis JJ. Reconsidering Strategies for Managing Chronic Periprosthetic Joint Infection in Total Knee Arthroplasty: Using Decision Analytics to Find the Optimal Strategy between One-Stage and Two-Stage Total Knee Revision. *J Bone Joint Surg Am* 2019; **101**: 14-24 [PMID: 30601412 DOI: 10.2106/JBJS.17.00874]
  - 16 **Gomez MM**, Tan TL, Manrique J, Deirmengian GK, Parvizi J. The Fate of Spacers in the Treatment of Periprosthetic Joint Infection. *J Bone Joint Surg Am* 2015; **97**: 1495-1502 [PMID: 26378265 DOI: 10.2106/JBJS.N.00958]
  - 17 **Gehrke T**, Zahar A, Kendoff D. One-stage exchange: it all began here. *Bone Joint J* 2013; **95-B**: 77-83 [PMID: 24187359 DOI: 10.1302/0301-620X.95B11.32646]
  - 18 **Liu K**, Ye L, Sun W, Hao L, Luo Y, Chen J. Does Use of Lidocaine Affect Culture of Synovial Fluid Obtained to Diagnose Periprosthetic Joint Infection (PJI)? *Med Sci Monit* 2018; **24**: 448-452 [PMID: 29360804 DOI: 10.12659/MSM.908585]
  - 19 **Burney K**, Bowker K, Reynolds R, Bradley M. Topical ethyl chloride fine spray. Does it have any antimicrobial activity? *Clin Radiol* 2006; **61**: 1055-1057 [PMID: 17097428 DOI: 10.1016/j.crad.2006.07.009]
  - 20 **Lum ZC**, Natsuhara KM, Shelton TJ, Giordani M, Pereira GC, Meehan JP. Mortality during Total Knee Periprosthetic Joint Infection. *J Arthroplasty* 2018; **33**: 3783-3788 [PMID: 30224099 DOI: 10.1016/j.arth.2018.08.021]
  - 21 **Natsuhara KM**, Shelton TJ, Meehan JP, Lum ZC. Mortality during Total Hip Periprosthetic Joint Infection. *J Arthroplasty* 2019; **34**: S337-S342 [PMID: 30642705 DOI: 10.1016/j.arth.2018.12.024]
  - 22 **Klare CM**, Fortney TA, Kahng PW, Cox AP, Keeney BJ, Moschetti WE. Prognostic Factors for Success after Irrigation and Debridement with Modular Component Exchange for Infected Total Knee Arthroplasty. *J Arthroplasty* 2018; **33**: 2240-2245 [PMID: 29572037 DOI: 10.1016/j.arth.2018.02.004]
  - 23 **Gehrke T**, Kendoff D. Peri-prosthetic hip infections: in favour of one-stage. *Hip Int* 2012; **22** Suppl 8: S40-S45 [PMID: 22956386 DOI: 10.5301/HIP.2012.9569]
  - 24 **Ji B**, Wahafu T, Li G, Zhang X, Wang Y, Momin M, Cao L. Single-stage treatment of chronically infected total hip arthroplasty with cementless reconstruction: results in 126 patients with broad inclusion criteria. *Bone Joint J* 2019; **101-B**: 396-402 [PMID: 30929477 DOI: 10.1302/0301-620X.101B4.BJJ-2018-1109.R1]
  - 25 **Anagnostakos K**. Therapeutic Use of Antibiotic-loaded Bone Cement in the Treatment of Hip and Knee Joint Infections. *J Bone Jt Infect* 2017; **2**: 29-37 [PMID: 28529862 DOI: 10.7150/jbji.16067]
  - 26 **Hansen E**, Tetreault M, Zmistowski B, Della Valle CJ, Parvizi J, Haddad FS, Hozack WJ. Outcome of one-stage cementless exchange for acute postoperative periprosthetic hip infection. *Clin Orthop Relat Res* 2013; **471**: 3214-3222 [PMID: 23775569 DOI: 10.1007/s11999-013-3079-3]
  - 27 **Wolf M**, Clar H, Friesenbichler J, Schwantzer G, Bernhardt G, Gruber G, Glehr M, Leithner A, Sadoghi P. Prosthetic joint infection following total hip replacement: results of one-stage versus two-stage exchange. *Int Orthop* 2014; **38**: 1363-1368 [PMID: 24638215 DOI: 10.1007/s00264-014-2309-y]
  - 28 **Kunutsor SK**, Whitehouse MR, Lenguerrand E, Blom AW, Beswick AD; INFORM Team. Re-Infection Outcomes Following One- And Two-Stage Surgical Revision of Infected Knee Prosthesis: A Systematic Review and Meta-Analysis. *PLoS One* 2016; **11**: e0151537 [PMID: 26967645 DOI: 10.1371/journal.pone.0151537]
  - 29 **Parvizi J**, Tan TL, Goswami K, Higuera C, Della Valle C, Chen AF, Shohat N. The 2018 Definition of Periprosthetic Hip and Knee Infection: An Evidence-Based and Validated Criteria. *J Arthroplasty* 2018; **33**: 1309-1314. e2 [PMID: 29551303 DOI: 10.1016/j.arth.2018.02.078]
  - 30 **Gutiérrez D**, Hidalgo-Cantabrana C, Rodríguez A, García P, Ruas-Madiedo P. Monitoring in Real Time the Formation and Removal of Biofilms from Clinical Related Pathogens Using an Impedance-Based Technology. *PLoS One* 2016; **11**: e0163966 [PMID: 27695058 DOI: 10.1371/journal.pone.0163966]

- 31 **Bialecki J**, Bucsi L, Fernando N, Foguet P, Guo S, Haddad F, Hansen E, Janvari K, Jones S, Keogh P, McHale S, Molloy R, Mont MA, Morgan-Jones R, Ohlmeier M, Saldaña A, Sodhi N, Toms A, Walker R, Zahar A. Hip and Knee Section, Treatment, One Stage Exchange: Proceedings of International Consensus on Orthopedic Infections. *J Arthroplasty* 2019; **34**: S421-S426 [PMID: 30348563 DOI: 10.1016/j.arth.2018.09.026]
- 32 **Tsang SJ**, Ting J, Simpson AHRW, Gaston P. Outcomes following debridement, antibiotics and implant retention in the management of periprosthetic infections of the hip: a review of cohort studies. *Bone Joint J* 2017; **99-B**: 1458-1466 [PMID: 29092984 DOI: 10.1302/0301-620X.99B11.BJJ-2017-0088.R1]
- 33 **McPherson EJ**, Woodson C, Holtom P, Roidis N, Shufelt C, Patzakis M. Periprosthetic total hip infection: outcomes using a staging system. *Clin Orthop Relat Res* 2002; **8**: 8-15 [PMID: 12360001 DOI: 10.1097/00003086-200210000-00003]
- 34 **Citak M**, Friedenstab J, Abdelaziz H, Suero EM, Zahar A, Salber J, Gehrke T. Risk Factors for Failure After 1-Stage Exchange Total Knee Arthroplasty in the Management of Periprosthetic Joint Infection. *J Bone Joint Surg Am* 2019; **101**: 1061-1069 [PMID: 31220022 DOI: 10.2106/JBJS.18.00947]
- 35 **Abdelaziz H**, Grüber H, Gehrke T, Salber J, Citak M. What are the Factors Associated with Re-revision After One-stage Revision for Periprosthetic Joint Infection of the Hip? *Clin Orthop Relat Res* 2019; **477**: 2258-2263 [PMID: 31135547 DOI: 10.1097/CORR.0000000000000780]
- 36 **Loty B**, Postel M, Evrard J, Matron P, Courpied JP, Kerboull M, Tomeno B. [One stage revision of infected total hip replacements with replacement of bone loss by allografts. Study of 90 cases of which 46 used bone allografts]. *Int Orthop* 1992; **16**: 330-338 [PMID: 1473885 DOI: 10.1007/BF00189615]
- 37 **Svensson K**, Rolfson O, Kärrholm J, Mohaddes M. Similar Risk of Re-Revision in Patients after One- or Two-Stage Surgical Revision of Infected Total Hip Arthroplasty: An Analysis of Revisions in the Swedish Hip Arthroplasty Register 1979-2015. *J Clin Med* 2019; **8** [PMID: 30974876 DOI: 10.3390/jcm8040485]
- 38 **Nagra NS**, Hamilton TW, Ganatra S, Murray DW, Pandit H. One-stage versus two-stage exchange arthroplasty for infected total knee arthroplasty: a systematic review. *Knee Surg Sports Traumatol Arthrosc* 2016; **24**: 3106-3114 [PMID: 26392344 DOI: 10.1007/s00167-015-3780-8]
- 39 **Oussedik SI**, Dodd MB, Haddad FS. Outcomes of revision total hip replacement for infection after grading according to a standard protocol. *J Bone Joint Surg Br* 2010; **92**: 1222-1226 [PMID: 20798438 DOI: 10.1302/0301-620X.92B9.23663]
- 40 **De Man FH**, Sendi P, Zimmerli W, Maurer TB, Ochsner PE, Ilchmann T. Infectiological, functional, and radiographic outcome after revision for prosthetic hip infection according to a strict algorithm. *Acta Orthop* 2011; **82**: 27-34 [PMID: 21189099 DOI: 10.3109/17453674.2010.548025]
- 41 **Klouché S**, Sariali E, Mamoudy P. Total hip arthroplasty revision due to infection: a cost analysis approach. *Orthop Traumatol Surg Res* 2010; **96**: 124-132 [PMID: 20417910 DOI: 10.1016/j.rcot.2010.02.005]
- 42 **Wilson MG**, Dorr LD. Reimplantation of infected total hip arthroplasties in the absence of antibiotic cement. *J Arthroplasty* 1989; **4**: 263-269 [PMID: 2677247 DOI: 10.1016/S0883-5403(89)80023-3]
- 43 **Wolf CF**, Gu NY, Doctor JN, Manner PA, Leopold SS. Comparison of one and two-stage revision of total hip arthroplasty complicated by infection: a Markov expected-utility decision analysis. *J Bone Joint Surg Am* 2011; **93**: 631-639 [PMID: 21471416 DOI: 10.2106/JBJS.I.01256]
- 44 **Fehring KA**, Curtin BM, Springer BD, Fehring TK. One-Stage Periprosthetic Joint Infection Reimbursement-Is It Worth The Effort? *J Arthroplasty* 2019; **34**: 2072-2074 [PMID: 31155461 DOI: 10.1016/j.arth.2019.04.029]
- 45 **Kallala R**, Harris WE, Ibrahim M, Dipane M, McPherson E. Use of Stimulan absorbable calcium sulphate beads in revision lower limb arthroplasty: Safety profile and complication rates. *Bone Joint Res* 2018; **7**: 570-579 [PMID: 30464837 DOI: 10.1302/2046-3758.710.BJR-2017-0319.R1]
- 46 **Bori G**, Muñoz-Mahamad E, Cuñé J, Gallart X, Fuster D, Soriano A. One-stage revision arthroplasty using cementless stem for infected hip arthroplasties. *J Arthroplasty* 2014; **29**: 1076-1081 [PMID: 24332970 DOI: 10.1016/j.arth.2013.11.005]
- 47 **Freeman MA**, Sudlow RA, Casewell MW, Radcliff SS. The management of infected total knee replacements. *J Bone Joint Surg Br* 1985; **67**: 764-768 [PMID: 4055878 DOI: 10.1302/0301-620X.67B5.4055878]
- 48 **Göksan SB**, Freeman MA. One-stage reimplantation for infected total knee arthroplasty. *J Bone Joint Surg Br* 1992; **74**: 78-82 [PMID: 1732271 DOI: 10.1302/0301-620X.74B1.1732271]
- 49 **Scott IR**, Stockley I, Getty CJ. Exchange arthroplasty for infected knee replacements. A new two-stage method. *J Bone Joint Surg Br* 1993; **75**: 28-31 [PMID: 8421028 DOI: 10.1302/0301-620X.75B1.8421028]
- 50 **Silva M**, Tharani R, Schmalzried TP. Results of direct exchange or debridement of the infected total knee arthroplasty. *Clin Orthop Relat Res* 2002; **125**: 125-131 [PMID: 12439250 DOI: 10.1097/00003086-200211000-00022]
- 51 **Buechel FF**. The infected total knee arthroplasty: just when you thought it was over. *J Arthroplasty* 2004; **19**: 51-55 [PMID: 15190550 DOI: 10.1016/j.arth.2004.03.001]
- 52 **Whiteside LA**, Peppers M, Nayfeh TA, Roy ME. Methicillin-resistant *Staphylococcus aureus* in TKA treated with revision and direct intra-articular antibiotic infusion. *Clin Orthop Relat Res* 2011; **469**: 26-33 [PMID: 20390472 DOI: 10.1007/s11999-010-1313-9]

- 53 **Parkinson RW**, Kay PR, Rawal A. A case for one-stage revision in infected total knee arthroplasty? *Knee* 2011; **18**: 1-4 [PMID: 20719522 DOI: 10.1016/j.knee.2010.04.008]
- 54 **Singer J**, Merz A, Frommelt L, Fink B. High rate of infection control with one-stage revision of septic knee prostheses excluding MRSA and MRSE. *Clin Orthop Relat Res* 2012; **470**: 1461-1471 [PMID: 22081299 DOI: 10.1007/s11999-011-2174-6]
- 55 **Klatte TO**, Kendoff D, Kamath AF, Jonen V, Rueger JM, Frommelt L, Gebauer M, Gehrke T. Single-stage revision for fungal peri-prosthetic joint infection: a single-centre experience. *Bone Joint J* 2014; **96-B**: 492-496 [PMID: 24692616 DOI: 10.1302/0301-620X.96B4.32179]
- 56 **Labruière C**, Zeller V, Lhotellier L, Desplaces N, Léonard P, Mamoudy P, Marmor S. Chronic infection of unicompartmental knee arthroplasty: one-stage conversion to total knee arthroplasty. *Orthop Traumatol Surg Res* 2015; **101**: 553-557 [PMID: 26164543 DOI: 10.1016/j.otsr.2015.04.006]
- 57 **Holland G**, Brown G, Goudie S, Brenkel I, Walmsley PJ. Results of Using a "2-in-1" Single-Stage Revision Total Knee Arthroplasty for Infection with Associated Bone Loss: Prospective 2-Year Follow-Up. *J Knee Surg* 2019 [PMID: 31569257 DOI: 10.1055/s-0039-1697963]
- 58 **Siddiqi A**, Nace J, George NE, Buxbaum EJ, Ong AC, Orozco FR, Ponzio DY, Post ZD. Primary Total Knee Arthroplasty Implants as Functional Prosthetic Spacers for Definitive Management of Periprosthetic Joint Infection: A Multicenter Study. *J Arthroplasty* 2019; **34**: 3040-3047 [PMID: 31378510 DOI: 10.1016/j.arth.2019.07.007]
- 59 **Abdelaziz H**, Biewald P, Anastasiadis Z, Haasper C, Gehrke T, Hawi N, Citak M. Midterm Results After Tantalum Cones in 1-Stage Knee Exchange for Periprosthetic Joint Infection: A Single-Center Study. *J Arthroplasty* 2020; **35**: 1084-1089 [PMID: 31813812 DOI: 10.1016/j.arth.2019.11.016]
- 60 **Ji B**, Li G, Zhang X, Wang Y, Mu W, Cao L. Effective treatment of single-stage revision using intra-articular antibiotic infusion for culture-negative prosthetic joint infection. *Bone Joint J* 2020; **102-B**: 336-344 [PMID: 32114816 DOI: 10.1302/0301-620X.102B3.BJJ-2019-0820.R1]
- 61 **Carlsson AS**, Josefsson G, Lindberg L. Revision with gentamicin-impregnated cement for deep infections in total hip arthroplasties. *J Bone Joint Surg Am* 1978; **60**: 1059-1064 [PMID: 721853 DOI: 10.2106/00004623-197860080-00007]
- 62 **Hughes PW**, Salvati EA, Wilson PD Jr, Blumenfeld EL. Treatment of subacute sepsis of the hip by antibiotics and joint replacement. Criteria for diagnosis with evaluation of twenty-six cases. *Clin Orthop Relat Res* 1979; 143-157 [PMID: 477096 DOI: 10.1097/00003086-197906000-00017]
- 63 **Miley GB**, Scheller AD Jr, Turner RH. Medical and surgical treatment of the Septic hip with one-stage revision arthroplasty. *Clin Orthop Relat Res* 1982; 76-82 [PMID: 7127967 DOI: 10.1097/00003086-198210000-00010]
- 64 **Weber FA**, Lautenbach EE. Revision of infected total hip arthroplasty. *Clin Orthop Relat Res* 1986; 108-115 [PMID: 3769249 DOI: 10.1097/00003086-198610000-00015]
- 65 **Sanzén L**, Carlsson AS, Josefsson G, Lindberg LT. Revision operations on infected total hip arthroplasties. Two- to nine-year follow-up study. *Clin Orthop Relat Res* 1988; 165-172 [PMID: 3349672 DOI: 10.1097/00003086-198804000-00022]
- 66 **Hope PG**, Kristinsson KG, Norman P, Elson RA. Deep infection of cemented total hip arthroplasties caused by coagulase-negative staphylococci. *J Bone Joint Surg Br* 1989; **71**: 851-855 [PMID: 2584258 DOI: 10.1302/0301-620X.71B5.2584258]
- 67 **Raut VV**, Siney PD, Wroblewski BM. One-stage revision of infected total hip replacements with discharging sinuses. *J Bone Joint Surg Br* 1994; **76**: 721-724 [PMID: 8083258 DOI: 10.1302/0301-620X.76B5.8083258]
- 68 **Mulcahy DM**, O'Byrne JM, Fenelon GE. One stage surgical management of deep infection of total hip arthroplasty. *Ir J Med Sci* 1996; **165**: 17-19 [PMID: 8867490 DOI: 10.1007/BF02942793]
- 69 **Ure KJ**, Amstutz HC, Nasser S, Schmalzried TP. Direct-exchange arthroplasty for the treatment of infection after total hip replacement. An average ten-year follow-up. *J Bone Joint Surg Am* 1998; **80**: 961-968 [PMID: 9698000 DOI: 10.2106/00004623-199807000-00004]
- 70 **Rudelli S**, Uip D, Honda E, Lima AL. One-stage revision of infected total hip arthroplasty with bone graft. *J Arthroplasty* 2008; **23**: 1165-1177 [PMID: 18534510 DOI: 10.1016/j.arth.2007.08.010]
- 71 **Winkler H**, Stoiber A, Kaudela K, Winter F, Menschik F. One stage uncemented revision of infected total hip replacement using cancellous allograft bone impregnated with antibiotics. *J Bone Joint Surg Br* 2008; **90**: 1580-1584 [PMID: 19043128 DOI: 10.1302/0301-620X.90B12.20742]
- 72 **Yoo JJ**, Kwon YS, Koo KH, Yoon KS, Kim YM, Kim HJ. One-stage cementless revision arthroplasty for infected hip replacements. *Int Orthop* 2009; **33**: 1195-1201 [PMID: 18704412 DOI: 10.1007/s00264-008-0640-x]
- 73 **Choi HR**, Kwon YM, Freiberg AA, Malchau H. Comparison of one-stage revision with antibiotic cement versus two-stage revision results for infected total hip arthroplasty. *J Arthroplasty* 2013; **28**: 66-70 [PMID: 23972299 DOI: 10.1016/j.arth.2013.02.037]
- 74 **Jenny JY**, Lengert R, Diesinger Y, Gaudias J, Boeri C, Kempf JF. Routine one-stage exchange for chronic infection after total hip replacement. *Int Orthop* 2014; **38**: 2477-2481 [PMID: 25078367 DOI: 10.1007/s00264-014-2466-z]
- 75 **Ebied AM**, Elseedy AI, Gamal O. Single-stage revision for periprosthetic hip infection using antibiotic loaded impaction graft. *Hip Int* 2016; **26**: 573-579 [PMID: 27739567 DOI: 10.5301/hipint.5000401]
- 76 **Ilchmann T**, Zimmerli W, Ochsner PE, Kessler B, Zwicky L, Graber P, Clauss M. One-stage revision of infected hip arthroplasty: outcome of 39 consecutive hips. *Int Orthop* 2016; **40**: 913-918 [PMID: 26224611 DOI: 10.1007/s00264-015-2833-4]

- 77 **Born P**, Ilchmann T, Zimmerli W, Zwicky L, Graber P, Ochsner PE, Clauss M. Eradication of infection, survival, and radiological results of uncemented revision stems in infected total hip arthroplasties. *Acta Orthop* 2016; **87**: 637-643 [PMID: 27658856 DOI: 10.1080/17453674.2016.1237423]
- 78 **Lange J**, Troelsen A, Solgaard S, Otte KS, Jensen NK, Søballe K; CORIHA Research Group. Cementless One-Stage Revision in Chronic Periprosthetic Hip Joint Infection. Ninety-One Percent Infection Free Survival in 56 Patients at Minimum 2-Year Follow-Up. *J Arthroplasty* 2018; **33**: 1160-1165. e1 [PMID: 29221839 DOI: 10.1016/j.arth.2017.11.024]
- 79 **Whiteside LA**, Roy ME. One-stage Revision with Catheter Infusion of Intraarticular Antibiotics Successfully Treats Infected THA. *Clin Orthop Relat Res* 2017; **475**: 419-429 [PMID: 27511201 DOI: 10.1007/s11999-016-4977-y]
- 80 **Zahar A**, Klaber I, Gerken AM, Gehrke T, Gebauer M, Lausmann C, Citak M. Ten-Year Results Following One-Stage Septic Hip Exchange in the Management of Periprosthetic Joint Infection. *J Arthroplasty* 2019; **34**: 1221-1226 [PMID: 30857953 DOI: 10.1016/j.arth.2019.02.021]
- 81 **Bori G**, Navarro G, Morata L, Fernández-Valencia JA, Soriano A, Gallart X. Preliminary Results After Changing From Two-Stage to One-Stage Revision Arthroplasty Protocol Using Cementless Arthroplasty for Chronic Infected Hip Replacements. *J Arthroplasty* 2018; **33**: 527-532 [PMID: 28947373 DOI: 10.1016/j.arth.2017.08.033]
- 82 **Wolff M**, Lausmann C, Gehrke T, Zahar A, Ohlmeier M, Citak M. Results at 10-24 years after single-stage revision arthroplasty of infected total hip arthroplasty in patients under 45 years of age. *Hip Int* 2019; 1120700019888877 [PMID: 31766882 DOI: 10.1177/1120700019888877]



Published by **Baishideng Publishing Group Inc**  
7041 Koll Center Parkway, Suite 160, Pleasanton, CA 94566, USA

**Telephone:** +1-925-3991568

**E-mail:** [bpgoffice@wjgnet.com](mailto:bpgoffice@wjgnet.com)

**Help Desk:** <https://www.f6publishing.com/helpdesk>

<https://www.wjgnet.com>

