

# UC San Diego

## UC San Diego Previously Published Works

### Title

Spontaneous Left Atrial Thrombus Formation on the Catheter Delivery System During WATCHMAN Implantation

### Permalink

<https://escholarship.org/uc/item/3c10k59x>

### Journal

JACC Case Reports, 2(3)

### ISSN

2666-0849

### Authors

Patel, Hiren  
Castellanos, Luis R  
Golts, Eugene  
et al.

### Publication Date

2020-03-01

### DOI

10.1016/j.jaccas.2019.10.041

Peer reviewed

## CASE REPORT

INTERMEDIATE

## CLINICAL CASE

# Spontaneous Left Atrial Thrombus Formation on the Catheter Delivery System During WATCHMAN Implantation



Hiren Patel, MD,<sup>a</sup> Luis R. Castellanos, MD, MPH,<sup>b</sup> Eugene Golts, MD,<sup>c</sup> Ryan Reeves, MD,<sup>b</sup> Ehtisham Mahmud, MD,<sup>b</sup> Jonathan C. Hsu, MD, MAS<sup>b</sup>

## ABSTRACT

We present a rare complication of spontaneous thrombus formation on the WATCHMAN delivery system, on both the right- and left-sided systemic circulation. We also describe the multidisciplinary team approach and the use of percutaneous vacuum-assisted aspiration system (AngioVac, AngioDynamics, Latham, New York) for successful thrombus removal. (**Level of Difficulty: Intermediate.**) (J Am Coll Cardiol Case Rep 2020;2:444-8) © 2020 The Authors. Published by Elsevier on behalf of the American College of Cardiology Foundation. This is an open access article under the CC BY-NC-ND license (<http://creativecommons.org/licenses/by-nc-nd/4.0/>).

Atrial fibrillation remains the most commonly diagnosed atrial arrhythmia in the United States, with stroke being a well-known complication of the condition (1). In recent years, transcatheter left atrial appendage (LAA) closure has gained increased interest given its safety and efficacy as reported by multiple prospective studies (2). Currently, the WATCHMAN device (Boston Scientific, Marlborough, Massachusetts) is the only U.S. Food and Drug Administration-approved and commercially available device in the United States. Increasing operator experience has resulted in a procedural success rate as high as 98% with low complication rates (3). Although device-related thrombus has been reported in subsequent WATCHMAN follow-up, no right or left atrial thrombus formation has been reported in the acute setting of implantation. In the following case

## LEARNING OBJECTIVES

- Spontaneous thrombi formation despite adequate anticoagulation may present as an infrequent complication during percutaneous interventions that implanting physicians should be aware of.
- The etiology of intraprocedural thrombus formation is thought to be related to stasis and initiation as well as activation of the coagulation cascade on the catheter surfaces with the catheter acting as a foreign body.
- Spontaneous thrombi formation can be managed successfully with the use of the vacuum-assisted venous aspiration AngioVac system.

From the <sup>a</sup>Division of Cardiovascular Medicine, Advanced Cardiac Imaging Fellowship Program, University of California-San Diego, La Jolla, California; <sup>b</sup>Division of Cardiovascular Medicine, University of California-San Diego, La Jolla, California; and the <sup>c</sup>Division of Cardiothoracic Surgery, University of California-San Diego, La Jolla, California. Dr. Reeves has served on the Speakers Bureau of Abbott Vascular. Dr. Hsu has received honoraria from Medtronic, Boston Scientific, Biotronik, Abbott, Biosense-Webster, Bristol-Myers Squibb, and Janssen Pharmaceuticals; has served as a consultant for Biotronik, Bristol-Myers Squibb, Janssen Pharmaceuticals, Biosense-Webster, Medtronic, Abbott, and Boston Scientific; has received research grants from Pfizer, Biosense Webster, and Biotronik; and has equity in Acutus Medical. All other authors have reported that they have no relationships relevant to the contents of this paper to disclose.

The authors attest they are in compliance with human studies committees and animal welfare regulations of the authors' institutions and Food and Drug Administration guidelines, or patient consent where appropriate. For more information, visit the *JACC: Case Reports* [author instructions page](#).

Manuscript received July 22, 2019; revised manuscript received October 28, 2019, accepted October 31, 2019.

report, we present a rare complication of spontaneous thrombus formation on the delivery system, on both the right- and left-sided systemic circulation, and the use of the AngioVac system for successful thrombus removal.

### HISTORY OF PRESENTATION

A 64-year-old female patient was admitted to our institution for an elective percutaneous LAA occlusion procedure with a WATCHMAN device.

### PAST MEDICAL HISTORY

The patient had a history of paroxysmal atrial fibrillation, transient ischemic attack, hypertension, irritable bowel syndrome, thoracic cavernous malformations, and depression.

### INVESTIGATIONS

The patient was considered for oral anticoagulation given her elevated CHA<sub>2</sub>DS<sub>2</sub>-VASc score of 4 (female sex, hypertension, and transient ischemic attack). However, the presence of her known thoracic cavernous malformations placed her at a high bleeding risk in the long term. She was therefore referred for percutaneous LAA occlusion.

### INITIAL MANAGEMENT: PLACEMENT OF THE WATCHMAN DEVICE

The patient was prepped according to our standard protocol. Venous access was obtained, a heparin

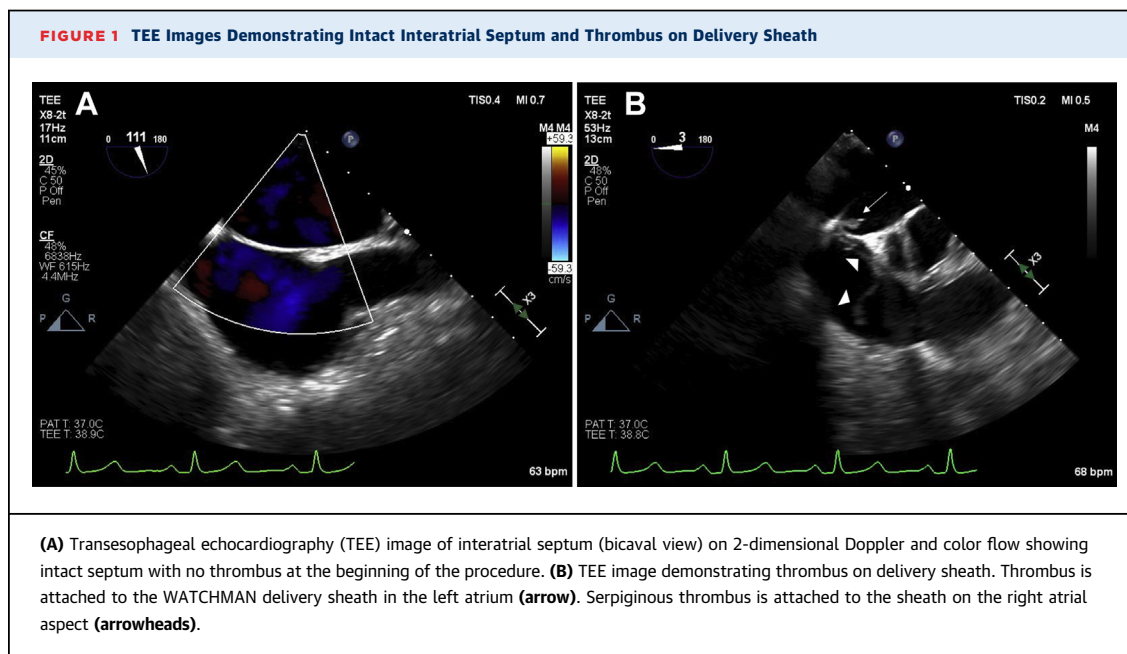
bolus was given, and an activated clotting time (ACT) of >250 s was confirmed prior to transseptal puncture. A standard 8.5-F SL1 sheath (St. Jude Medical, St. Paul, Minnesota) with a radiofrequency-powered NRG transseptal needle (Baylis Medical, Toronto, Ontario, Canada) was used, which was uneventful. A 14-F double-curve WATCHMAN access sheath was introduced to the left atrium without difficulty (the delivery sheath was not placed on continuous saline flush). A 24-mm WATCHMAN device was successfully deployed in the LAA after a single deployment requiring no partial nor full recaptures. The atrial dwell time was 30 min, and the WATCHMAN device was present in the body for 10 min. Prior to device release, post-deployment evaluation with transesophageal echocardiography (TEE) revealed a serpiginous echodensity in the right atrium that appeared to be attached to the transseptal WATCHMAN access sheath (Figures 1A and 1B). Further evaluation demonstrated another smaller mobile echodensity attached to the delivery catheter on the left atrial aspect, consistent with a thrombus (Video 1). Of note, the ACT was >250 s prior to transseptal puncture, was >300 s at the time of transseptal puncture, and was maintained at that level or higher throughout the procedure.

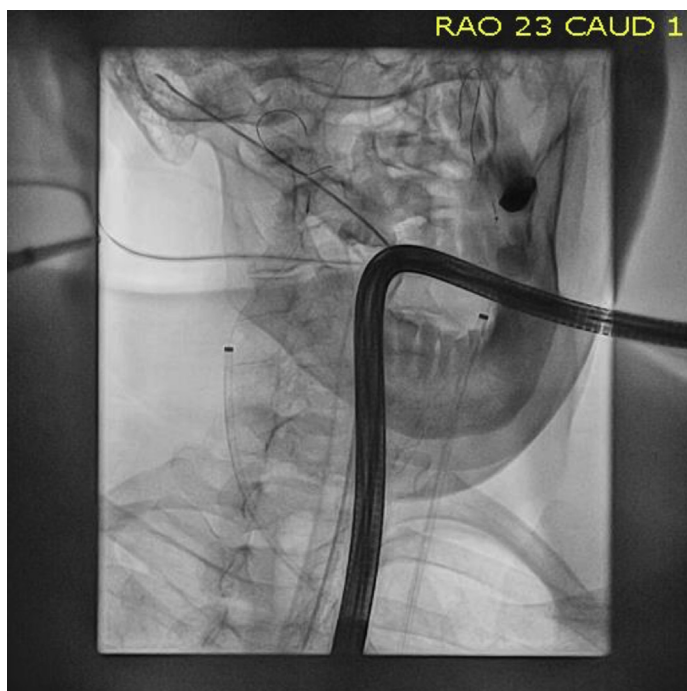
### ABBREVIATIONS AND ACRONYMS

- ACT = activated clotting time
- LAA = left atrial appendage
- TEE = transesophageal echocardiogram

### MANAGEMENT

Given the high risk of embolization, interventions for cerebral protection and thrombus removal were subsequently performed for stroke and pulmonary



**FIGURE 2** Fluoroscopic Image During Carotid Protection Device Placement

Placement of distal embolic protection devices in the right and left internal carotid arteries.

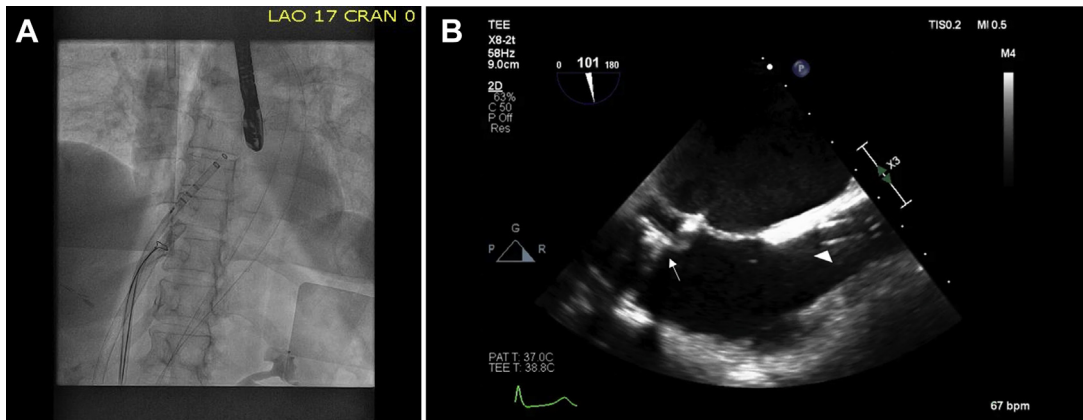
embolism prevention. Femoral arterial access was obtained, and under fluoroscopic guidance, interventional cardiologists successfully deployed bilateral AccUNET (Abbott, Sylmar, California) 6.5-mm distal embolic protection devices in the right and left internal carotid arteries (Figure 2). Anticoagulation was maintained with heparin boluses during these subsequent procedures with ACT measurements >300 s throughout. Venous access was obtained for the AngioVac system (AngioDynamics, Latham, New York). A short 6-F sheath in the right internal jugular vein was upsized to a 17-F sheath, and the cannula was placed in the atrium-superior vena cava junction. The left femoral vein access site was serially dilated over guidewire and a 26-F Gore DrySeal sheath was introduced and advanced into the mid-inferior vena cava. A second common femoral vein access site was obtained, and a 6-F-long sheath was placed for the 25-mm OneSnare device (Merit Medical Systems, Jordan, Utah) that was used to guide the catheter system. The AngioVac system was then connected and flushed. The AngioVac catheter was then placed over the wire and advanced into the inferior vena

cava (Figure 3A). The AngioVac catheter was then advanced into the right atrium, and the system was then fully activated (Figure 3B). Under direct TEE and fluoroscopic guidance, the distal end of the catheter was placed near the transeptal puncture site near the thrombus on the right atrial side (Video 2). Repeat suction attempts successfully aspirated the thrombus, which was captured on TEE images (Video 3). Once the right atrial thrombi were captured, the WATCHMAN was deployed and the delivery system was removed, with cerebral protection in place. The delivery access sheath was removed from the left atrium to the right atrium, and while pulling the system proximally to the right atrial side, the AngioVac system was placed as close as possible to the transeptal puncture site. The AngioVac catheter was then left over the transeptal puncture site until thrombus aspiration was complete from both right and left atria and kept at the transeptal site to allow any mobile thrombus on the left-sided interatrial septum to be captured via right-sided continuous aspiration. Once thrombus aspiration was evident inside the AngioVac filter (Figure 4), the AngioVac system and bilateral carotid filters were removed without complications. However, a temporal relationship between removal of the thrombi on echocardiographic imaging and clinical evidence of aspiration was not appreciated. No debris was noted in the carotid filters. Final TEE assessment revealed no evidence of thrombi (Figure 5). Final cerebral angiography revealed no evidence of carotid artery trauma. Successful decannulation and closure of the access sites was subsequently performed without immediate bleeding complications. The patient was extubated and awoke from anesthesia without any neurologic deficits, or evidence of systemic thromboembolism.

## DISCUSSION

Thrombus formation on catheters is an infrequent complication during percutaneous interventions. Transeptal sheath placement and insertion of catheters can precipitate thrombus formation on the catheter during radiofrequency catheter ablation procedures and can form almost immediately after crossing the septum. Early heparinization substantially decreases this risk (4); however, spontaneous thrombi formation has been described in previously published papers despite adequate anticoagulation (5). In 1 study, left atrial thrombus formation on the transeptal sheath or mapping catheters during radiofrequency atrial fibrillation ablation cases was

**FIGURE 3** Fluoroscopic and TEE Images Demonstrating Placement of the Aspiration Catheter



(A) Fluoroscopic image demonstrating placement of the AngioVac catheter in the inferior vena cava (IVC) advanced into the right atrium. (B) Transesophageal echocardiography (TEE) image demonstrating placement of the AngioVac catheter in the IVC advanced into the right atrium (arrow). Venous cannula placed in the superior vena cava via right internal jugular vein approach (arrowhead).

reported to be 10.3% despite anticoagulation with heparin to ACT >250 s (5).

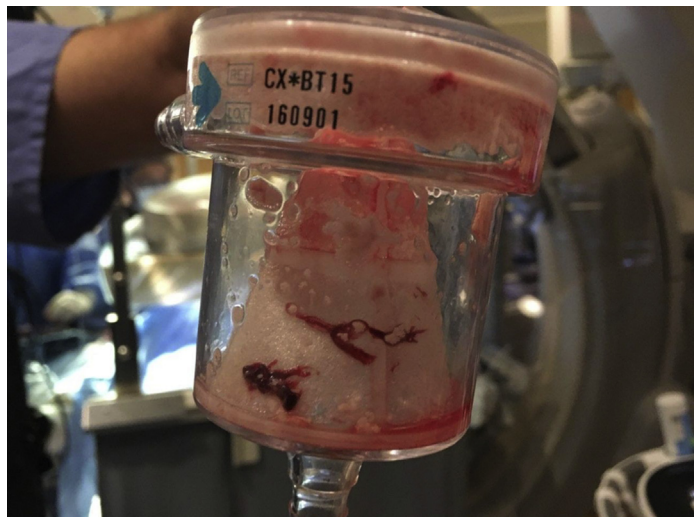The etiology of thrombus formation is unknown; however, it is thought to be related to stasis within the long sheath and initiation as well as activation of the coagulation cascade on the catheter surfaces, with the catheter acting as a foreign body. Given the major concern of development and embolism of intracardiac thrombi during the procedure with the possible risk of stroke, the use of heparin with an ACT of 300 s or greater is endorsed by current Heart Rhythm Society guidelines (Class I, Level of Evidence: B-NR) (6). Management of these thrombi during cardiovascular procedures can be challenging.

To our knowledge, this is the first reported incident of spontaneous thrombus formation in both the left and right atrium on the WATCHMAN delivery catheter system. A multidisciplinary team at a quaternary medical center facilitated a successful outcome by recognizing the complication, providing cerebral protection, and utilizing available systems to allow for thrombus aspiration, which resulted in successful WATCHMAN deployment without any neurological deficits for the patient after the procedure.

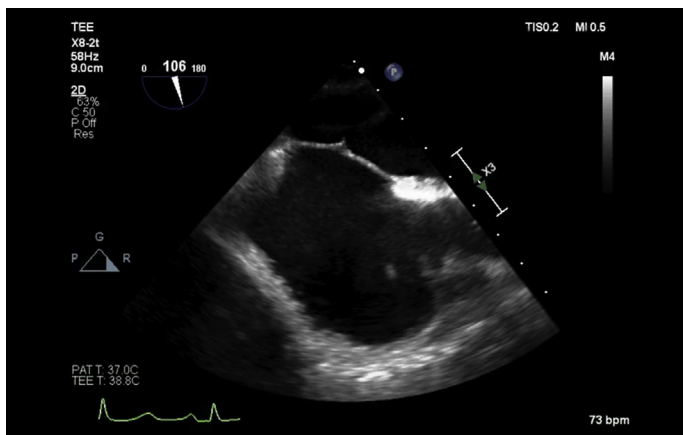
Over recent years, the AngioVac system has emerged as a thrombus aspiration tool, receiving U.S. Food and Drug Administration approval for “venous drainage during extracorporeal bypass for up to 6 h to include removal of fresh, soft thrombi or emboli” (7). The AngioVac system is a vacuum-assisted venous aspiration system that employs a 22-F suction

cannula with a venous return cannula connected to an extracorporeal veno-venous circuit with the goal of removal of large thrombi. The bypass circuit and flow rates are monitored by a perfusionist during the procedure. This device is primarily designed for aspiration of large clot burden while mitigating the bleeding risk associated with fibrinolytics and

**FIGURE 4** Aspiration Cannister With Aspirated Thrombus



Aspirated thrombus captured by the AngioVac filter.

**FIGURE 5 Post-Procedure TEE**

Post-procedure transesophageal echocardiography (TEE) evaluation (bicaval view) with no evidence of residual thrombus, but visible iatrogenic atrial septal defect from transeptal catheterization.

hemolysis associated with rheolytic systems. Previous case reports using this device have demonstrated its efficacy in successfully removing large thrombi in patients with right atrial thrombus (8), acute massive pulmonary embolism (9), and large implantable cardioverter defibrillator/pacing lead vegetations (10), with success rates as high as 73% (11).

## FOLLOW-UP

The patient had an uncomplicated post-procedure course. The patient was evaluated for hypercoagulable disorder with a panel of laboratory testing, which was negative. Her oral anticoagulation was discontinued after a 45-day post procedure TEE demonstrated no evidence of leak or thrombus. Her aspirin and Plavix were continued for another 4.5 months, after which, she remained solely on aspirin. She remained without any neurological issues.

## CONCLUSIONS

Thrombus formation on catheters during cardiovascular percutaneous interventions is uncommon. We report the first use of the AngioVac system for successful thrombus removal during a WATCHMAN procedure. This technique may be considered to assist with thrombus removal for this infrequent complication.

**ADDRESS FOR CORRESPONDENCE:** Dr. Jonathan C. Hsu, Cardiac Electrophysiology Section, Division of Cardiovascular Medicine, Department of Medicine, University of California-San Diego, 9452 Medical Center Drive, 3rd Floor, Room 3E-417, La Jolla, California 92037. E-mail: [Jonathan.Hsu@ucsd.edu](mailto:Jonathan.Hsu@ucsd.edu).

## REFERENCES

- Chugh SS, Havmoeller R, Narayanan K, et al. Worldwide epidemiology of atrial fibrillation: a Global Burden of Disease 2010 Study. *Circulation* 2014;129:837-47.
- Reddy VY, Doshi SK, Sievert H, et al. Percutaneous left atrial appendage closure for stroke prophylaxis in patients with atrial fibrillation: 2.3-year follow-up of the PROTECT AF (Watchman Left Atrial Appendage System for Embolic Protection in Patients with Atrial Fibrillation) trial. *Circulation* 2013;127:720-9.
- Reddy VY, Gibson DN, Kar S, et al. Post-approval U.S. experience with left atrial appendage closure for stroke prevention in atrial fibrillation. *J Am Coll Cardiol* 2017;69:253-61.
- Bruce CJ, Friedman PA, Narayan O, et al. Early heparinization decreases the incidence of left atrial thrombi detected by intracardiac echocardiography during radiofrequency ablation for atrial fibrillation. *J Interv Card Electrophysiol* 2008;22:211-9.
- Ren JF, Marchlinski FE, Callans DJ. Left atrial thrombus associated with ablation for atrial fibrillation: identification with intracardiac echocardiography. *J Am Coll Cardiol* 2004;43:1861-7.
- Calkins H, Hindricks G, Cappato R, et al. 2017 HRS/EHRA/ECAS/APHRS/SOLAECE expert consensus statement on catheter and surgical ablation of atrial fibrillation. *Heart Rhythm* 2017;14:e275-444.
- Food and Drug Administration. (2019, March). Pre-Market Notification- Traditional 50(k) AngioVac Cannula. (510(k) Number: K190594). Available at: [https://www.accessdata.fda.gov/cdrh\\_docs/pdf19/K190594.pdf](https://www.accessdata.fda.gov/cdrh_docs/pdf19/K190594.pdf). Accessed January 2020.
- Dudiy Y, Kronzon I, Cohen HA, Ruiz CE. Vacuum thrombectomy of large right atrial thrombus. *Catheter Cardiovasc Interv* 2012;79:344-7.
- Pasha AK, Elder MD, Khurram D, Snyder BA, Movahed MR. Successful management of acute massive pulmonary embolism using Angiovac suction catheter technique in a hemodynamically unstable patient. *Cardiovasc Revasc Med* 2014;15:240-3.
- Patel N, Azemi T, Zaeem F, et al. Vacuum assisted vegetation extraction for the management of large lead vegetations. *J Card Surg* 2013;28:321-4.
- Salsamendi J, Doshi M, Bhatia S, et al. Single center experience with the AngioVac Aspiration System. *Cardiovasc Intervent Radiol* 2015;38:998-1004.

**KEY WORDS** AngioVac system, atrial fibrillation, thrombus, WATCHMAN device

**APPENDIX** For supplemental videos, please see the online version of this paper.