

UC Merced

Proceedings of the Annual Meeting of the Cognitive Science Society

Title

Making it Right: Can the Right-Hemisphere Compensate for Language Function in Patients with Left-Frontal Brain Tumors?

Permalink

<https://escholarship.org/uc/item/3c39353s>

Journal

Proceedings of the Annual Meeting of the Cognitive Science Society, 38(0)

Authors

Jost, Ethan

Brennan, Nicole P.

Peck, Kyung K.

et al.

Publication Date

2016

Peer reviewed

Making it Right: Can the Right-Hemisphere Compensate for Language Function in Patients with Left-Frontal Brain Tumors?

Ethan Jost (edj37@cornell.edu)

Cornell University, Department of Psychology
Ithaca, NY 13068 USA

Memorial Sloan Kettering Cancer Center, fMRI Lab
New York, NY 10065 USA

Nicole P. Brennan (brennann@mskcc.org), Kyung K. Peck (peckk@mskcc.org), Andrei I. Holodny (holodnya@mskcc.org)

Memorial Sloan Kettering Cancer Center, fMRI Lab
New York, NY 10065 USA

Morten H. Christiansen (christiansen@cornell.edu)

Cornell University, Department of Psychology
Ithaca, NY 13068 USA

Abstract

Both the degree to which the left-hemisphere is specialized for language and the relative ability of the right-hemisphere to subservise language function are underspecified. The present study sought to identify whether the right-frontal fMRI activation seen in a number of case studies in patients with left-sided brain lesions exists as a group-level trend in patients with left-frontal tumors. It also sought to examine the possible compensatory nature of this activation. Thus, a retrospective analysis of 197 brain tumor patients who had undergone pre-surgical fMRI language mapping was conducted. Patients with left-frontal tumors were found to be more likely to show right- or co-dominant fMRI activation during language mapping tasks compared to patients who had tumors elsewhere in the brain. Further, patients with left-frontal tumors who were identified as right- or co-dominant for language were found to possess more intact language function as measured by the Boston Naming Test.

Keywords: language; neuroplasticity

Introduction

Those studying the cognitive neuroscience of language have typically described the brain's left-hemisphere as specialized for language ever since the seminal work of Paul Broca and Carl Wernicke. These studies, along with the century and a half of research they inspired, have focused primarily on uncovering the roles of the left frontal and temporal lobes in the learning and processing of language (Dronkers, Plaisant, Iba-Zizen & Cabanis, 2007). This has led to an emerging characterization of the role that various regions, sub-regions, and pathways within the left-hemisphere's language network play in

language processing (Hagoort, 2014; Friederici & Gierhan, 2013).

However, a lack of research on the role of the right-hemisphere in language has left the debate on specialization open. Even with the focus of research on left-hemisphere language function, some theories posit a complementary role for right-hemisphere processing (e.g., Jung-Beeman, 2005). In addition, there is much evidence that the right-hemisphere, specifically Broca's homologue, is able to take over function from the left-hemisphere following extensive early brain damage (Thal et al., 1991; Vicari et al., 2000; Tivarus, Starling, Newport & Langfitt, 2012). However, the degree to which adults with brain lesions retain this capacity is currently underspecified. Some recent smaller-scale work has suggested that increased right hemispheric activation may be correlated with better language outcomes in patients with left-frontal lesions, and in healthy patients who undergo targeted rTMS (Krieg et al., 2013).

Determining the degree to which the adult brain can reorganize language function, and under what conditions this occurs, promises to yield important insights that not only may inform clinical prognoses, but also lead to a better understanding of the brain's equipotentiality. Examining brain tumor patients may thus provide a fruitful source of data for uncovering the potentially more subtle plasticity that exists in adult populations than acute stroke and brain damage patients, as they may exhibit different compensatory mechanisms and competencies (Fisicaro et al., 2016).

Case studies with brain tumor patients have indicated that damage to traditional language cortex in both the frontal (Holodny, Schulder, Ybasco & Liu, 2002) and temporal (Petrovich, Holodny, Brennan & Gutin, 2004)

lobes can result in contralateral reorganization of the brain's language network, although how this affects patients' cognitive outcomes is not currently known. In addition, the fact that ipsilateral reorganization also occurs in this patient population (Brennan, 2008), creates an ideal setting in which to test for both the relative frequency of contralateral reorganization and its outcomes with respect to language. Does the right-hemisphere demonstrate compensatory activation when there is damage to the left-frontal lobe more often than the occasional case study would suggest? Also, do patient outcomes differ depending on whether the patient exhibits ipsilateral versus contralateral compensation? This set of questions led to the present study, in which a large database of patients with brain tumors of varying grade, size, location, and etiology was queried in order to answer these critical questions. We sought to identify whether or not the compensatory right-frontal activation seen in such case studies exists as a group-level trend among patients suffering from left-frontal tumors, and also to examine the possible compensatory nature of this activation.

Methods

Participants

A database was compiled involving all patients who underwent a pre-surgical fMRI language procedure at Memorial Sloan Kettering Cancer Center over a five-year time period, excluding patients with sub-optimal scans or incomplete patient information (n = 197, 95 female; mean age = 50.52 years, range: 10-83). Patients initially presented with a range of symptoms and tumor etiologies. Table 1 indicates the proportion of patients falling into a number of relevant categories.

Table 1: General patient information.

	Female	High Grade Tumor	Left-frontal tumor	Right-handed	Left-dominant language
Proportion of Patients	0.482	0.538	0.482	0.807	0.873

Data Acquisition

Data were acquired with a 1.5-T or 3.0 T scanner (General Electric, Milwaukee, WI) using an 8 channel head coil. Based on localizer images, a set of 26 T1-weighted (repetition time [TR], 600 ms; echo time [TE], 8 ms; thickness, 4.5-mm) and T2-weighted (TR, 4000 ms; TE, 102 ms; thickness, 4.5-mm) spin-echo axial slices, covering the whole brain, was obtained for the purpose of

coregistration with the functional data. Functional images were acquired with a gradient-echo echo-planar imaging sequence (TR, 4000 ms; TE, 30/40 (for 3T/1.5T) ms; matrix, 128x128; field of view, 240 mm; thickness, 4.5-mm; flip angle, 90°). Head motion was minimized using straps and foam padding.

Task Administration

Patients performed one or more covert block designed fMRI language tasks as part of the pre-surgical language task panel. Tasks consisted of a phonemic fluency task where they were required to generate words that began with a high frequency letter, semantic fluency where they were required to generate words that fit a category, verb generation where they were required to generate verbs to given nouns, or auditory responsive naming where they were required to answer simple questions. All tasks were delivered aurally (Ruff et al., 2008). The radiology team's reports were based on all scans collected for each patient, while reported laterality indices were taken from the task with the highest quality scan, with a preference for the phonemic fluency task.

There were 90 images in total for each patient, consisting of 5 activation images (20 sec) followed by 10 rest images (40 sec) repeated 6 times (6 min total). Subjects were monitored continuously while performing the task. Subject participation was confirmed using real-time imaging software, which provided real-time acquisition, processing, and display of functional results (Brainwave RT, GE Healthcare, Milwaukee, Wisconsin). All language fMRI tasks were visually inspected for lateralization patterns and discrepancies in language lateralization by a board certified neuroradiologist. Clinical reports indicated language lateralization, language localizations in the peri-tumoral region, handedness, and if the Boston Naming Test (BNT) was performed, the patients score.

Results

Plasticity in the brain's language network

In order to determine the possible extent of both ipsilateral and contralateral reorganization following tumor infiltration of the left-frontal lobe, the researchers divided all right-handed patients in the original sample (n = 159, 72 female; mean age = 50.64, range: 10-83) into groups based on tumor location. Patients with tumors impacting the left-frontal lobe (n = 81, 37 female; mean age = 49.65 years, range: 11-75) can be considered the experimental group, while patients with tumors elsewhere in the brain – including other regions within the left-

hemisphere – (n = 78, 35 female; mean age = 52.35, range: 10-83) served as the control¹.

As can be seen in Table 2, patients with tumors localized in the left-frontal lobe were much more likely to be reported as right- or co-dominant for language function by the neuroradiology staff than would be expected given the control group ($\chi^2 = 9.51, p = .002, \phi = .245$).

This finding suggests that the frontal component of the typical left-hemisphere language network is able to shift to the right-hemisphere in patients with tumor impacting putative Broca’s area in the left-frontal lobe. It also demonstrates that this contralateral reorganization happens with some frequency, and is not isolated to a small number of cases. However, it remains unclear whether the plasticity encountered in this patient population has any effect on language function. It is possible that the increased right-hemisphere activation is not compensatory in nature, and may even be deleterious.

Table 2: χ^2 -table exhibiting the difference in report laterality between patients with left-frontal tumors and those with tumor elsewhere in the brain.

	Patients reported as left-dominant	Patients reported as right-or co-dominant	
Patients with left-frontal tumors	67 (72.85)	14 (8.15)	81
Patients with tumors elsewhere in brain	76 (70.15)	2 (7.85)	78
	143	16	159

Patterns of reorganization affect language outcomes

To elucidate the role that potential right-hemisphere reorganization plays in actual language outcomes, patients with left-frontal tumors who completed a BNT during their pre-surgical assessment (n = 28) were evaluated more closely. In order to determine the effect of laterality on language performance, the BNT scores of patients with left-dominant reports (n = 20; M = 48.30; SD = 14.71) were compared to those with right- or co-dominant reports (n = 8; M = 56.38; SD = 2.72)².

¹ There were no significant differences between patient groups in terms of age (t(156) = -1.145, p = .254), sex ($\chi^2 = .01, p = .920$), or tumor grade ($\chi^2 = 2.843, p = .092$).

² Again, no significant differences were found between groups for age (t(156) = -1.145, p = .254), or tumor grade ($\chi^2 = 2.05, p = .152$), although sex and hemisphere of language dominance were not found

As depicted in Figure 1, this analysis found that patients identified as being right- or co-dominant in terms of language function had significantly more intact language abilities than did patients with left-dominant maps exhibiting ipsilateral, and often perilesional activation to language tasks (t(22) = -2.36, p = .028). This independent-samples t-test did not pass Levene’s test for equality of variances (F = 4.82, p = .037), so corrected degrees of freedom were used.

This set of analyses demonstrates that the right-hemisphere is capable of taking over language function in adults who were likely left-dominant prior to tumor development. It also shows that therapeutic techniques which focus on transferring language function to the right-hemisphere in the face of left-hemisphere damage may result in better patient outcomes.

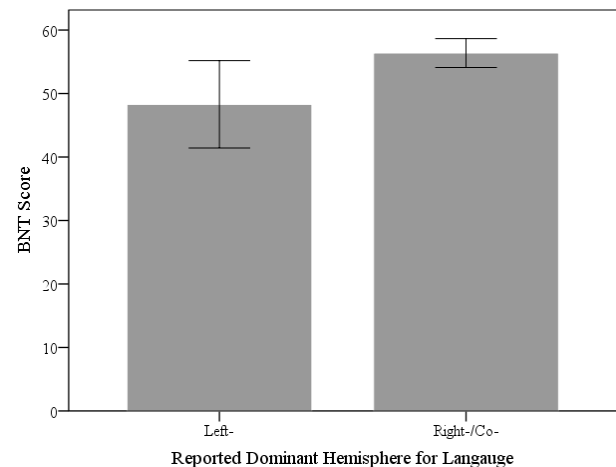


Figure 1: Bar graph displaying the difference in BNT performance between patients with left-dominant reports and those with right- or co-dominant reports. Error bars indicate 95% CIs.

Laterality index verification of report groups

In order to confirm the radiologist report data, a laterality index assessment also was conducted on the patients with BNT data. The patients in both the left-dominant and right-/co-dominant groups were also evaluated using laterality indices (LI), with interior frontal gyrus (IFG), middle frontal gyrus (MFG), frontal lobe, and hemispheric ROIs (see Figures 2-5).

Independent-samples t-tests confirmed that there was a significant difference between the report groups in laterality for each of the ROIs that were assessed, the IFG (t(26) = 4.33, p < .001), MFG (t(26) = 4.08, p < .001), frontal lobe (t(26) = 4.44, p < .001), and hemispheric

to be independent ($\chi^2 = 4.01, p = .045, \phi = .223$), as males were more likely to be right- or co-dominant than expected.

($t(26) = 5.78, p < .001$). See Table 3 for a report of means for each group's LI within each ROI.

This set of analyses corroborates the qualitative findings of the report data, and suggests that patients falling into the left- and right-/co-dominant groups were categorized correctly.

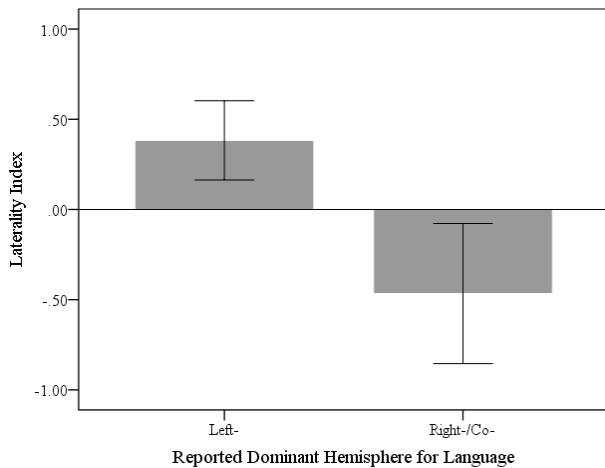


Figure 2: Difference in LI between patients with left-dominant reports and those with right- or co-dominant reports in the IFG ROI. Error bars indicate 95% CIs.

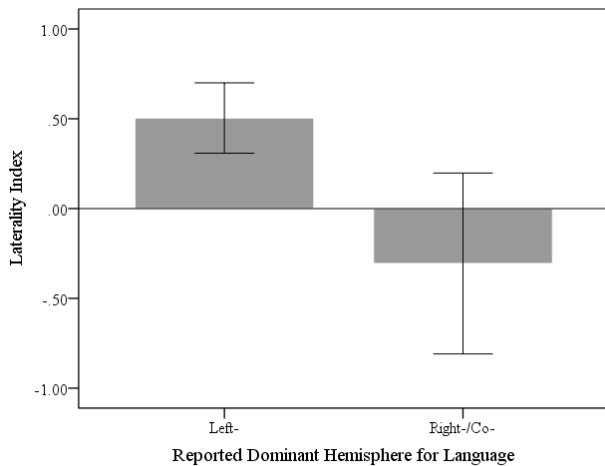


Figure 3: Difference in LI between patients with left-dominant reports and those with right- or co-dominant reports in the MFG ROI. Error bars indicate 95% CIs.

Discussion

This is the first large scale study investigating the complex relationship between reorganization in the brain's language network and behavioral outcomes as a result of brain tumor. While some past research with

Table 3: Group means for each ROI

	IFG	MFG	Frontal	Hemispheric
Left-dominant	0.383	0.504	0.472	0.389
Right-/co-dominant	-0.466	-0.306	-0.387	-0.153

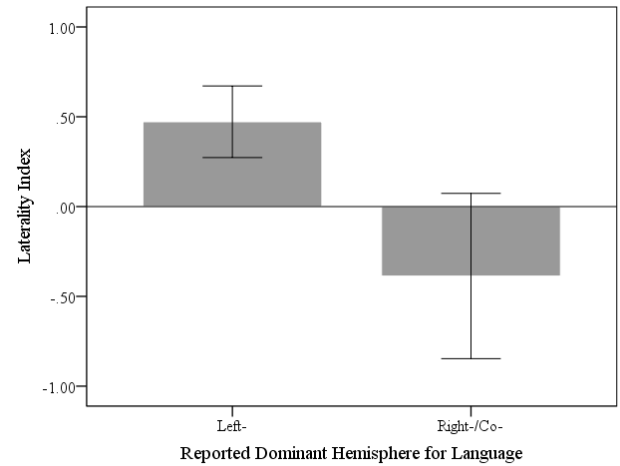


Figure 4: Difference in LI between patients with left-dominant reports and those with right- or co-dominant reports in the frontal lobe ROI. Error bars indicate 95% CIs.

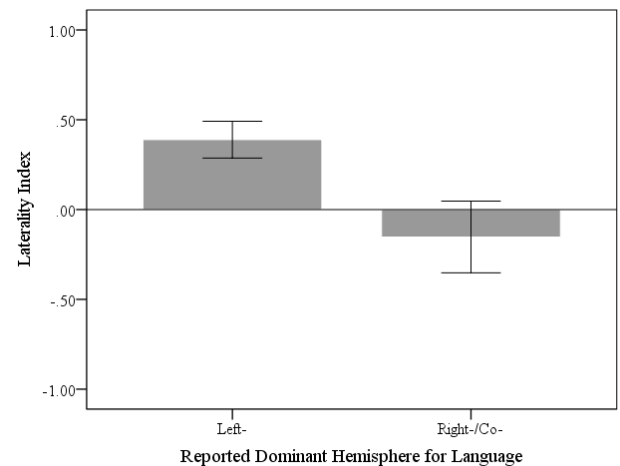


Figure 5: Difference in LI between patients with left-dominant reports and those with right- or co-dominant reports in the hemispheric ROI. Error bars indicate 95% CIs.

stroke patients has incorporated large datasets (Turkeltaub, Messing, Norise & Hamilton, 2011), case studies have made up the majority of past research on atypical language lateralization in adult patient populations.

The findings of the present study point toward a degree of equipotentiality in the adult brain's language network that is somewhat unexpected. The frontal lobe, likely Broca's homologue, in the right-hemisphere seems to be able to take over language function when there is compromise of the left-hemisphere, and may even be a better candidate for reorganization than the ipsilateral cortex. It is also of note that the patients with left-hemisphere damage exhibiting right- or co-dominant activation maps fell within the normal-range of scores on the BNT, demonstrating the right-hemisphere's ability to maintain healthy levels of language performance. Patients with left-dominant maps indicating ipsilateral, and often peri-lesional compensation suffering from left-frontal lesions exhibited a much wider range of outcomes.

Such a pattern of results suggests that while typical development results in an overwhelming majority of adults having left-dominant language networks (Knecht et al., 2000), the right-hemisphere may also possess the requisite capacities for language processing. This falls in line with the work of Bates and colleagues (Bates & Roe, 2001; Thal et al., 1991; Vicari et al., 2000), whose work suggests that early language development can occur in children with severe damage to the left-hemisphere and in children who are lacking their left-hemisphere entirely. It is likely that the left-hemisphere is not uniquely suited or specifically adapted for language learning and processing. Rather, relatively ubiquitous and subtle biases in early development likely lead to the typically left-hemisphere language network. Future work determining the nature of these biases would be a fruitful addition to understanding the developmental intricacies of the brain's language network.

Clinical studies have also indicated that the right-hemisphere may be able to serve what is traditionally the role of the left-hemisphere in language in some circumstances (for a recent review, see FisiCaro et al., 2016). An investigation of a large number of stroke patients suffering from aphasia demonstrates that patients suffering from left-frontal damage recruit the right-hemisphere more often than healthy controls, although the findings of this study did not determine whether the compensatory activation is deleterious or beneficial (Turkeltaub et al., 2011).

Other case-study research has demonstrated an unclear and even conflicting relationship between the role of right-hemispheric activation and language outcomes in patients with aphasia at different points in recovery (Turkeltaub et al., 2012). Unlike this past research, however, the present study demonstrates a clear relationship between right-hemisphere activation during language tasks and positive patient outcomes in a large cohort. Determining whether or not this is true for stroke patients, or patients suffering from brain damage with

other etiologies constitutes an intriguing question for future research.

Studies utilizing therapeutic techniques attempting to transfer language function to healthy right-hemisphere cortex after damage to the left-frontal lobe in two stroke patients have demonstrated that the right-hemisphere may be able to take over such function when the basal ganglia remains intact, and that this compensation leads to positive language outcomes for the patient (Crosson et al., 2005). Other recent research also seems to suggest that a rightward shift in language related function is related to the amount of tumor infiltration suffered by the basal ganglia (Shaw et al., submitted).

It seems likely that basal ganglia activation serves as the causal mechanism by which language function is able to transfer between hemispheres following left-hemisphere damage. Further research examining the trajectories and limitations of this transfer will hopefully not only elucidate mechanisms for contralateral reorganization in clinical populations, but also increase the understanding of how the hemispheres communicate during normal language processing.

The present study is limited in some regards. By utilizing radiologist reports for evaluations of laterality, the analyses are partially based on qualitative measures. A number of patient scans suffered from issues related to drop-out artifacts due to prior surgery and other common issues faced when scanning this patient population, rendering traditional quantitative analyses useless.

However, the limited laterality index findings reported here suggest that the radiologist report data overlaps quite a bit with more quantitative measures, at least at the group level, mitigating such concerns. In addition, the radiology team's reports were able to account for such issues in their analyses. For example, several patients whose scans exhibited multiple artifacts were difficult to categorize using traditional laterality indices due to low voxel counts in the affected hemisphere. By using the qualitative report data based on these scans, but not beholden to the limitations of traditional quantitative analyses, the study was able to include a larger number of patients.

Ideally future research will be able to control for such artifacts and issues in a more well-controlled prospective study, even if that means using a smaller sample. Future prospective research would also benefit from utilizing a broader range of neuropsychological assessments than were able to be accessed in the present study.

Conclusion

The present study is the first to indicate a group level trend in putative right-hemisphere reorganization as a result of damage to traditional left-frontal language cortex. It is also the first to demonstrate positive outcomes for patients as a result of such reorganization in a large sample. Such findings show that the left-hemisphere is

not likely to be uniquely adapted to subserve language function.

Rather, the right-hemisphere seems to be able to take over for left-hemisphere when the latter is damaged, and can maintain a normal-level of language abilities. This study also highlights the potential for therapies attempting to facilitate contralateral shifts in language function in patients suffering from language problems. As the right-hemisphere seems to be just as adept at subserving language function as the left-hemisphere, therapy targeted at shifting language function to healthy right-hemisphere cortex seems like an increasingly attractive option.

Acknowledgements

This research could not have taken place without the support of NIH grant 5T32HD055177. We would also like to thank all of the staff in the Radiology and Neurosurgery Departments at Memorial Sloan Kettering Cancer Center for their help at every stage of this project.

References

- Bates, E., & Roe, K. (2001). Language Development in Children with Unilateral Brain Injury. In C.A. Nelson & M. Luciana (Eds.), *Handbook of developmental cognitive neuroscience*. Cambridge, MA: MIT Press.
- Brennan N.P. (2008). Preparing the patient for the fMRI Study and optimization of paradigm selection and delivery. In A.I. Holodny (Ed.), *Functional neuroimaging: A clinical approach*. New York: Informa Healthcare USA, Inc.
- Crosson, B., Moore, A.B., Gopinath, K., White, K.D., Wierenga, C.E., Gaiefsky, M.E., Fabrizio, K.S., Peck, K.K., Soltysik, D., Milsted, C., & Briggs, R.W. (2005). Role of the right and left hemispheres in recovery of function during treatment of intention in aphasia. *Journal of Cognitive Neuroscience*, 17(3), 392-406.
- Dronkers, N. F., Plaisant, O., Iba-Zizen, M. T., & Cabanis, E. A. (2007). Paul Broca's historic cases: high resolution MR imaging of the brains of Leborgne and Lelong. *Brain*, 130(5), 1432-1441.
- Fiscaro, R., Jost, E., Shaw, K., Brennan, N.P., Peck, K.K., & Holodny, A.H. (in press). Cortical plasticity in the setting of brain tumors. *Topics in Magnetic Resonance Imaging*.
- Friederici, A. D., & Gierhan, S. M. (2013). The language network. *Current Opinion in Neurobiology*, 23(2), 250-254.
- Hagoort, P. (2014). Nodes and networks in the neural architecture for language: Broca's region and beyond. *Current opinion in neurobiology*, 28, 136-141.
- Holodny, A. I., Schulder, M., Ybasco, A., & Liu, W. C. (2002). Translocation of Broca's area to the contralateral hemisphere as the result of the growth of a left inferior frontal glioma. *Journal of computer assisted tomography*, 26(6), 941-943.
- Jung-Beeman, M. (2005). Bilateral brain processes for comprehending natural language. *Trends in cognitive sciences*, 9(11), 512-518.
- Knecht, S., Dräger, B., Deppe, M., Bobe, L., Lohmann, H., Flöel, A., Ringelstein, E.B., & Henningsen, H. (2000). Handedness and hemispheric language dominance in healthy humans. *Brain*, 123(12), 2512-2518.
- Krieg, S. M., Sollmann, N., Hauck, T., Ille, S., Foerschler, A., Meyer, B., & Ringel, F. (2013). Functional language shift to the right hemisphere in patients with language-eloquent brain tumors. *PLoS One*, 8(9), e75403.
- Petrovich N.M., Holodny A.I., Brennan C.W., & Gutin P.H. (2004). Isolated translocation of Wernicke's area to the right hemisphere in a 62-year-man with a temporo-parietal glioma. *American Journal of Neuroradiology* 25, 130–133.
- Ruff, I. M., Brennan, N. P., Peck, K. K., Hou, B. L., Tabar, V., Brennan, C. W., & Holodny, A. I. (2008). Assessment of the language laterality index in patients with brain tumor using functional MR imaging: effects of thresholding, task selection, and prior surgery. *American journal of neuroradiology*, 29(3), 528-535.
- Shaw K., Brennan N.M., Woo K., Zhang Z., Young R., Peck K.K., & Holodny A.I. (submitted). Infiltration of the basal ganglia by brain tumors is associated with the development of co-dominant language function on fMRI.
- Thal, D. J., Marchman, V., Stiles, J., Aram, D., Trauner, D., Nass, R., & Bates, E. (1991). Early lexical development in children with focal brain injury. *Brain and language*, 40(4), 491-527.
- Tivarus, M. E., Starling, S. J., Newport, E. L., & Langfitt, J. T. (2012). Homotopic language reorganization in the right hemisphere after early left hemisphere injury. *Brain and language*, 123(1), 1-10.
- Turkeltaub, P. E., Messing, S., Norise, C., & Hamilton, R. H. (2011). Are networks for residual language function and recovery consistent across aphasic patients? *Neurology*, 76(20), 1726-1734.
- Turkeltaub, P. E., Coslett, H. B., Thomas, A. L., Faseyitan, O., Benson, J., Norise, C., & Hamilton, R. H. (2012). The right hemisphere is not unitary in its role in aphasia recovery. *Cortex*, 48(9), 1179-1186.
- Vicari, S., Albertoni, A., Chilosi, A. M., Cipriani, P., Cioni, G., & Bates, E. (2000). Plasticity and reorganization during language development in children with early brain injury. *Cortex*, 36(1), 31-46.