

UC Davis

UC Davis Previously Published Works

Title

Total knee arthroplasty after Hauser procedure: beware of the patellar tendon!

Permalink

<https://escholarship.org/uc/item/3dn3z3cw>

Journal

Arthroplasty today, 5(1)

ISSN

2352-3441

Authors

Lum, Zachary C
Giordani, Mauro
Meehan, John P


Publication Date

2019-03-01

DOI

10.1016/j.artd.2018.07.004

Peer reviewed



Case report

Total knee arthroplasty after Hauser procedure: beware of the patellar tendon!

Zachary C. Lum, DO^{*}, Mauro Giordani, MD, John P. Meehan, MD

Orthopaedic Surgery Department, University of California: Davis Medical Center, Sacramento, CA, USA

ARTICLE INFO

Article history:

Received 29 March 2018
 Received in revised form
 7 July 2018
 Accepted 9 July 2018
 Available online 27 October 2018

Keywords:

Hauser procedure
 Patellar tendon disruption
 Extensor mechanism disruption
 Lateral parapatellar approach
 Total knee arthroplasty

ABSTRACT

Preoperative planning is a fundamental element in total knee arthroplasty (TKA). A previous surgery that must be recognized and identified preoperatively is the Hauser procedure, a posteromedialization of the tibial tubercle for recurrent patellar instability. Here, we describe 2 case reports in patients with previous Hauser surgeries. The first TKA surgery was complicated from a standard medial peripatellar approach resulting in complete transection of the patellar tendon during standard arthrotomy. The tendon was repaired, and the arthroplasty was aborted. For the second case, correct preoperative identification of the Hauser procedure was performed. The second TKA surgery was performed using a lateral peripatellar arthrotomy with excellent exposure, resulting in a successful operation. Here, we highlight the importance of an accurate history, physical and radiographic examination, and the recommendation of an alternative TKA approach to help avoid the serious intraoperative complication of a patellar tendon laceration.

© 2018 The Authors. Published by Elsevier Inc. on behalf of The American Association of Hip and Knee Surgeons. This is an open access article under the CC BY-NC-ND license (<http://creativecommons.org/licenses/by-nc-nd/4.0/>).

Introduction

The success of accurate and reproducible total knee arthroplasty (TKA) has increased over the decades [1]. This has allowed us to perform knee replacement in complex situations. In the setting of previous knee surgery, such as posttraumatic arthritis, previous anterior cruciate ligament (ACL) reconstruction, failed uni-compartmental knee arthroplasty, or high tibial osteotomy, total knee replacement surgery has become easier to implement but with increased risks [2,3]. Preoperative identification of previous surgery by prior hardware, such as intramedullary nails or screws, may help anticipate intraoperative obstacles, avoid potential complications, and guide treatment.

One such previous surgery that must be recognized and identified preoperatively is the Hauser procedure. Described in 1938, this was a posteromedialization of the tibial tubercle for patellar instability and chondromalacia [4]. Here, we describe 2 case reports highlighting the need for accurate history and physical examination

before TKA surgery and also the use of an alternative TKA approach to avoid an intraoperative complication. The first TKA surgery was aborted due to misidentification of a previous Hauser procedure, and the use of a standard medial peripatellar approach resulted in complete transection of the patellar tendon during standard arthrotomy. The second TKA surgery underwent correct preoperative identification and was performed using a lateral peripatellar arthrotomy. This allowed for excellent exposure and resulted in a successful well-balanced TKA.

Case histories

Case 1

A 67-year-old male presented with a history of progressively worsening right knee pain failing conservative management for arthritis. He described a remote history of a traumatic knee injury at the age of 22 upon sliding in to second base while playing college baseball. He states he immediately underwent an open surgical procedure and cast immobilization. On examination, there was a serpentine anteromedial skin incision from the distal medial thigh extending to a point medial and distal to the nonpalpable tibia tubercle. Preoperative radiographs show a distal and medial to lateral directed tibial screw with normal patella position on lateral and merchant views. Combining the history, physical examination,

No author associated with this paper has disclosed any potential or pertinent conflicts which may be perceived to have impending conflict with this work. For full disclosure statements refer to <https://doi.org/10.1016/j.artd.2018.07.004>.

^{*} Corresponding author. Orthopaedic Surgery Department, 4860 Y Street, Suite 3800, Sacramento, CA 95817, USA. Tel.: +1 916 734 7353.

E-mail address: zacharylum@gmail.com

<https://doi.org/10.1016/j.artd.2018.07.004>

2352-3441/© 2018 The Authors. Published by Elsevier Inc. on behalf of The American Association of Hip and Knee Surgeons. This is an open access article under the CC BY-NC-ND license (<http://creativecommons.org/licenses/by-nc-nd/4.0/>).

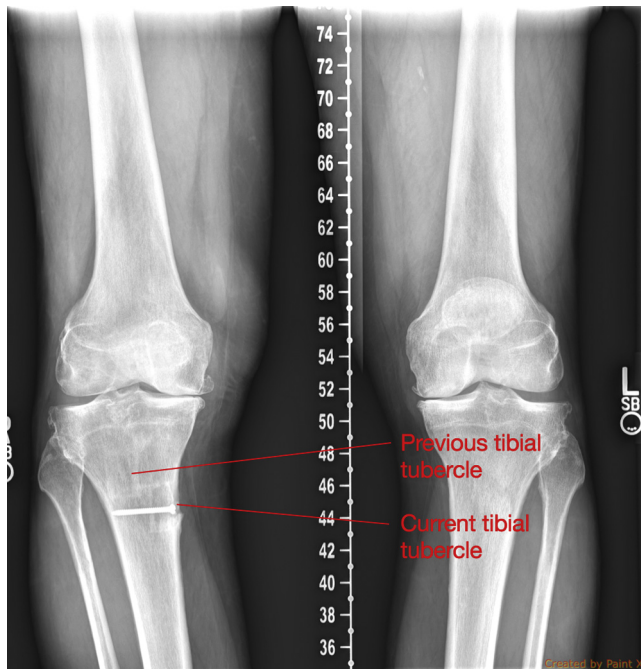


Figure 1. Case 1: 67-year-old male patient with misdiagnosed Hauser procedure. Note the square sclerotic lines consistent with tubercle transfer. See Figure 10 for details on location of tubercle transfer.

and radiographs, the diagnosis was incorrectly interpreted as an MCL injury and repair (Fig. 1).

Intraoperatively after using the superior aspect of his previous serpentine skin incision, a medial peripatellar arthrotomy was performed. As the scalpel passed the inferior pole of the patella, the patella self-everted, indicating release of the patellar tendon tension. Inspection revealed that an atrophic, thin band of tissue, which was identified as the patella tendon coursing from the inferior pole of the patella to the medial tibia, had been transected. The patellar tendon was then repaired primarily and reinforced with multiple suture anchors and additional Krakow suturing. The decision was made to not proceed with TKA to allow for tendon healing. The patient was kept in a hinged knee brace locked in extension for 6 weeks and gradually advanced weekly with progressive flexion over the ensuing 6 weeks. At final follow-up of 2 years, he was able to perform full extension and flexion (0–110 deg), maintain an active straight leg raise against resistance with 5/5 strength, and walk unassisted. Postoperatively, it was determined that the patient underwent a Hauser procedure (posteromedialization of the tibial tubercle) for patellar realignment. In hindsight, the patellar tendon was cut upon utilization of a standard medial peripatellar arthrotomy due to the significant posteromedialization of the new tibial tubercle location. The patellar tendon was perceived to be palpable; however, in the setting of previous surgery and scar tissue, it can be more challenging to identify.

Case 2

A 67-year-old female with a history of bilateral patellar realignment surgeries during adolescence was being prepared for staged bilateral TKA. Radiographs were similar to the previous patient, although the screw fixation was not as medially placed (Figs. 2 and 3). Advanced imaging (computer tomography) was obtained, confirming posteromedialization of the tibial tubercle consistent with a Hauser procedure (Fig. 4). We elected to remove

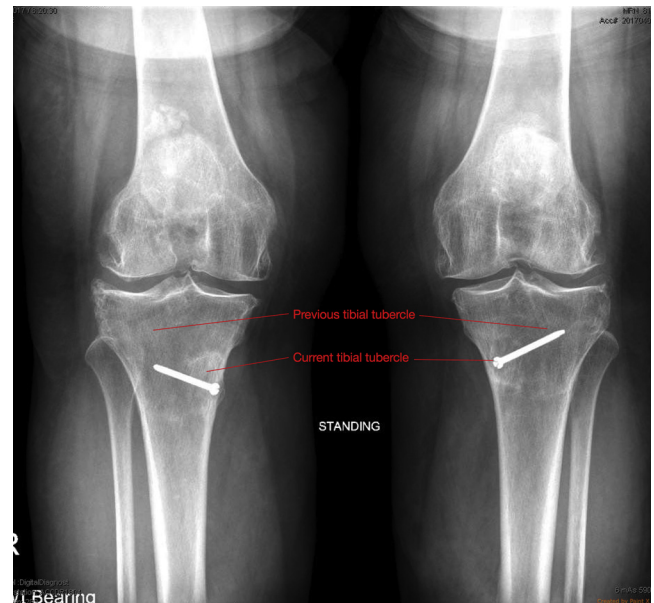


Figure 2. Case 2: Preoperative anterior-posterior radiographs. Note the location and trajectory of the screws.

the screws as a separate procedure to prevent interference with the tibial tray. On the day of the left TKA surgery, a lateral peripatellar arthrotomy was performed, giving excellent exposure to the knee joint (Figs. 5–8). The patella was subluxed medially with removal of osteophytes, and the remaining steps for TKA were performed without any additional modification (Fig. 9). Postoperatively, the patient underwent a routine rehabilitative protocol, including rapid recovery and multimodal pain control, and was discharged in normal fashion. Upon final follow-up, she is satisfied with the procedure and had no complication.

Our second patient with a lateral peripatellar approach TKA is satisfied with her surgical outcome and is set to undergo a contralateral TKA by the same technique. Her preoperative outcome scores of 41 for WOMAC, 90/100 for Knee Society Score (KSS) Objective, 11/100 for Function improved postoperatively to 13 for WOMAC, 97/100 for KSS Objective, 57/100 for function. Upon final follow-up, she is satisfied with the procedure, had no

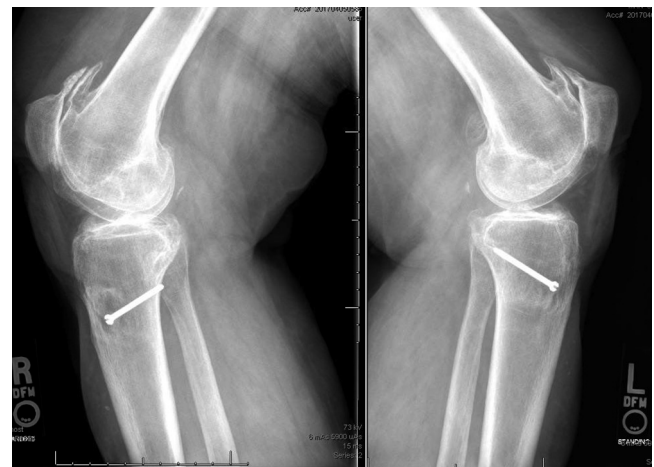

Figure 3. Case 2: Preoperative lateral radiographs noting the medialization of the screw head past the expected point of the tubercle.

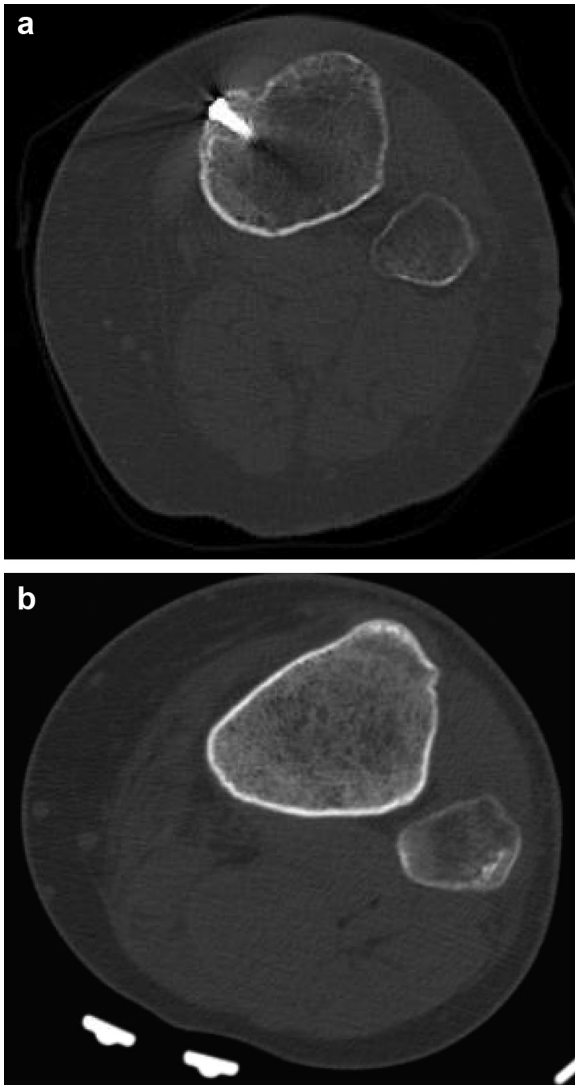


Figure 4. (a and b) Preoperative computer tomography of Hauser procedure (a) and normal tibia (b). Note the location of the new tibial tubercle, far beyond the medial midline of the normal tubercle; a potential problem if performing a standard medial peripatellar arthrotomy.

complication, and is planning to undergo lateral peripatellar TKA on her contralateral limb.

Discussion

Performing TKA in the setting of previous surgery has been associated with increased risks and complications [2,3]. Watters et al. [2] reported on 122 patients who underwent TKA with prior ACL reconstruction. Although their Knee Society outcome scores were no different compared to that of a matched control group, their surgical time was 15 minutes longer (88 vs 73 minutes; $P < .001$), and reoperative rates were 5 times higher ($P = .01$), indicating the complexity of performing TKA in this population. TKA, in the setting of posttraumatic arthritis, also has increased complication risks. Ge et al. [3] reported a significantly higher complication rate (31% vs 3%; $P = .02$) in patients with previous open reduction internal fixation undergoing TKA than that in those who had knee arthroscopy. In addition, they reported higher readmission rates (14.8% vs 2.2%; $P = .042$), reoperation rates (16.7% vs 0%; $P = .39$), and longer operative times (103 vs 85 minutes;



Figure 5. Preoperative anatomical landmarks on the left knee of the patient described in case 2. Note the medialized tibial tubercle on the left side of the photo.

$P = .45$), and more expensive implants are required (1.72 vs 1.07; $P = .026$) in patients with previous knee surgeries such as high tibial osteotomies, ACL reconstructions, and open reduction and internal fixation; however, most of these results approached but did not reach statistical significance.

Similarly, it is not without surprise that previous tibial tubercle osteotomy and advancement can have increased complication rates in the setting of TKA. The Hauser procedure, first described by Dr. Emil Hauser in 1938 described a posteromedialization of the tibial

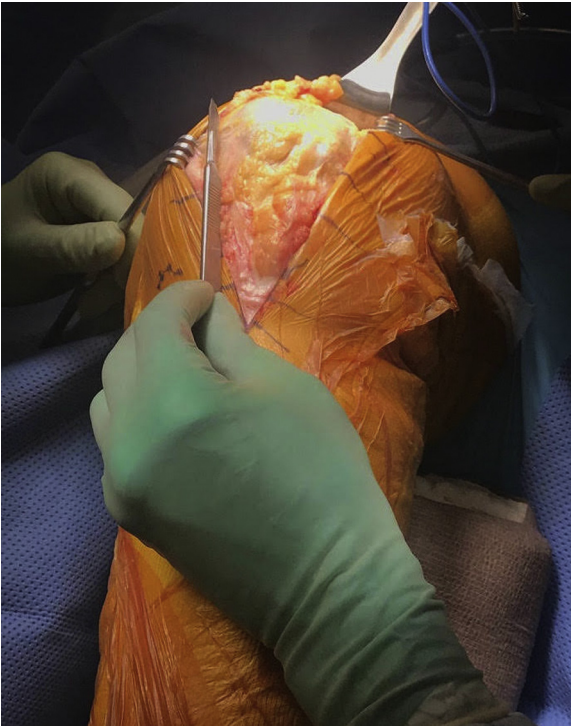

Figure 6. Location of standard medial peripatellar arthrotomy in this left knee. Note the location of the tibial tubercle on the medial side, left of the photo. An arthrotomy here would result in complete patellar tendon transection.

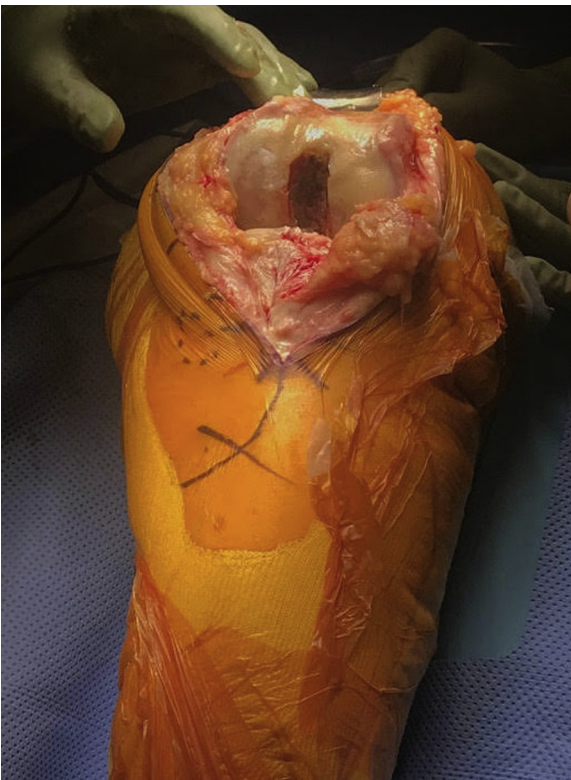

Figure 7. Exposure with lateral peripatellar approach. Subperiosteal dissection laterally to Gerdy's Tubercle, maintaining the iliotibial band insertion. Internal rotation to protect the patellar tendon and obtain exposure. Medial side is to the left.

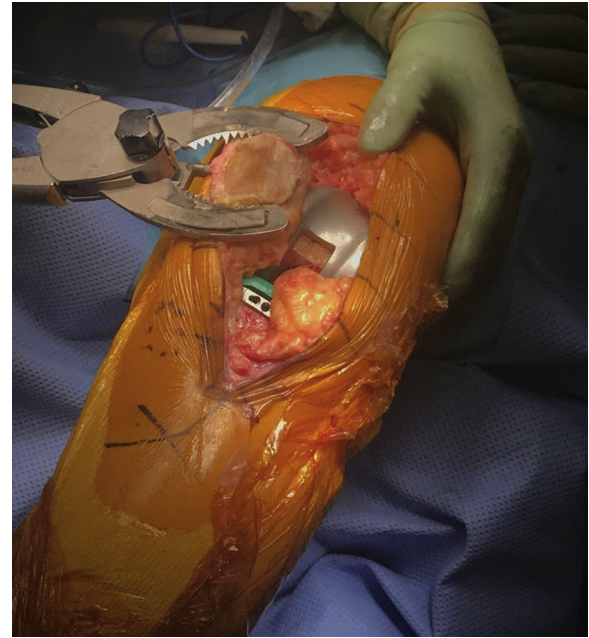

Figure 8. Intraoperatively, femoral and tibial cuts were made, trials performed, patellar preparation being performed. The patella tracked very well and the knee was stable in all aspects of flexion and full extension. Medial is left in the photo.

tubercle for patellar instability (Fig. 10) [4]. Although rarely performed anymore, due to varying amounts of long term arthritic progression, it was one accepted technique to manage patellar dislocation [5,6]. It is important to note the new location of the tubercle insertion and patellar tendon may result in disruption of the tendon with a standard medial peripatellar approach. The tibial tubercle is much more medial and posterior, thus a standard approach crosses the new patellar tendon location. Patellar tendon laceration after a Hauser procedure has only been described once before by Goldstein and Bailie in 1998 [7]. We felt it useful to report our similar experience with this serious complication and highlight the importance of using a lateral peripatellar approach to avoid it in the future.

TKA after tibial tubercle osteotomy and transfer is rarely reported in the literature. There are a few reports on TKA after anteriorization of the tubercle (ie, Maquet technique). Padgett et al. alerts the surgeon to the pitfalls of the surgery: distortion of the proximal tibia risking component malposition, a bulky anterior-posterior proximal tibia which may cause exposure difficulties and improper placement of the cutting guide, and fixation hardware such as screws or cortical bone which may compromise intramedullary alignment devices or fixation devices (ie, keels or punches) [8,9]. Acknowledging and addressing these obstacles, by preoperative evaluation and intraoperative execution can pave the way to a successful surgery.

Iatrogenic patellar tendon disruption has been considered one of the worst complications in TKA. Although rare, outcomes are poor [10]. Acute injuries to the patellar tendon can be repaired primarily, although additional reinforcement with tendon auto/allograft, wires or braided suture have been described [11]. Chronic injuries usually require reconstruction by allograft, synthetic mesh materials or muscle rearrangement flaps [12]. Secure fixation of the repair, graft, or augments is critical to success of the repair. In the setting of previous Hauser procedure, we recommend an alternative TKA approach to help avoid the serious intraoperative complication of a patellar tendon laceration.

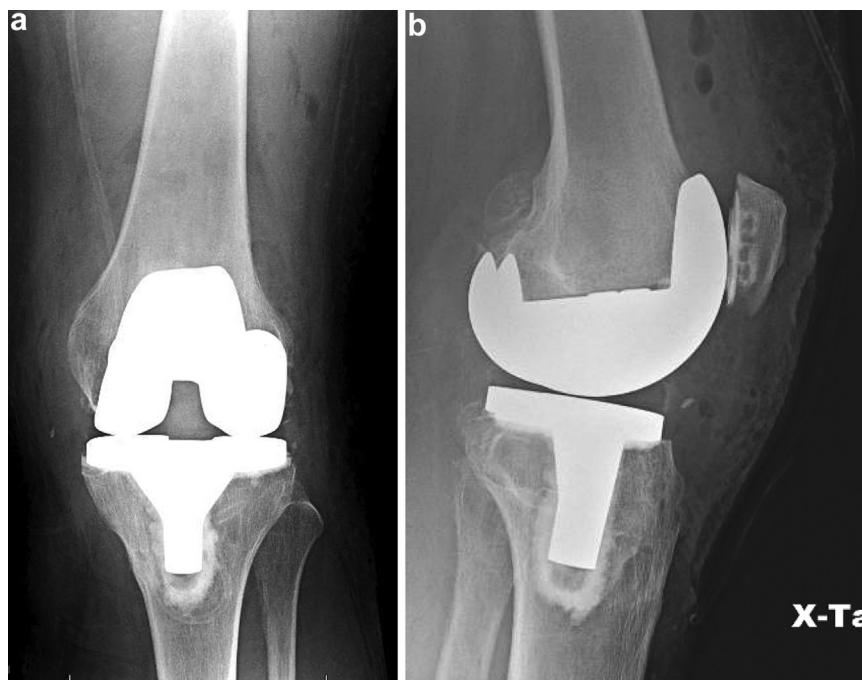


Figure 9. (a) Postoperative AP demonstrates well aligned TKA components. (b) Postoperative lateral radiograph with well fixed and aligned components.

The lateral peripatellar approach was first described by Keblish et al. [13,14], and popularized for the valgus total knee procedure. Reasons for the approach include improved patellar tracking in the fixed valgus deformity knee, ease of balancing and soft tissue release. Difficulties of the lateral peripatellar technique include difficulty with closure of the arthrotomy, unfamiliarity with the operation from the lateral side, limited exposure due to patellar mobility, and technical demand of the surgery. As seen in Figures 7 and 8, lateral peripatellar

approach for the Hauser procedure provided excellent visualization and exposure likely due to the new tibial tubercle location. The new tubercle and patellar tendon is much more medial, thus the patella easily mobilizes medially, and therefore may be difficult to mobilize laterally. This approach may be an additional indication for TKA in patients with a previous Hauser procedure.

Summary

Previous operations to the knee may predispose patients to lower overall TKA outcomes as well as make the surgery more complicated. The Hauser procedure was frequently performed for patella instability prior to the development of less invasive techniques and knee arthroscopy. The transfer of the patella tendon insertion to a new medial and posterior position places the tendon at risk for transection during a medial peripatellar TKA approach. Surgeons should be aware of this risk and be able to identify the preoperative, radiographic and intraoperative characteristics of the Hauser procedure. A lateral peripatellar arthrotomy can help avoid complications and may be the best option for patients with this previous surgery.

References

- [1] Kurtz S, Ong K, Lau E, Mowat F, Halpern M. Projections of primary and revision hip and knee arthroplasty in the United States from 2005 to 2030. *J Bone Joint Surg Am* 2007;89(4):780.
- [2] Watters TS, Zhen Y, Martin JR, Levy DL, Jennings JM, Dennis DA. Total knee arthroplasty after anterior cruciate ligament reconstruction: not just a routine primary arthroplasty. *J Bone Joint Surg Am* 2017;99(3):185.
- [3] Ge DH, Anoushiravani AA, Kester BS, Vigidorchik JM, Schwarzkopf R. Preoperative diagnosis can predict conversion total knee arthroplasty outcomes. *J Arthroplasty* 2018;33(1):124.
- [4] Hauser EDW. Total tendon transplant for slipping patella: a new operation for recurrent dislocation of the patella. *Surg Gynecol Obstet* 1938;66:199.

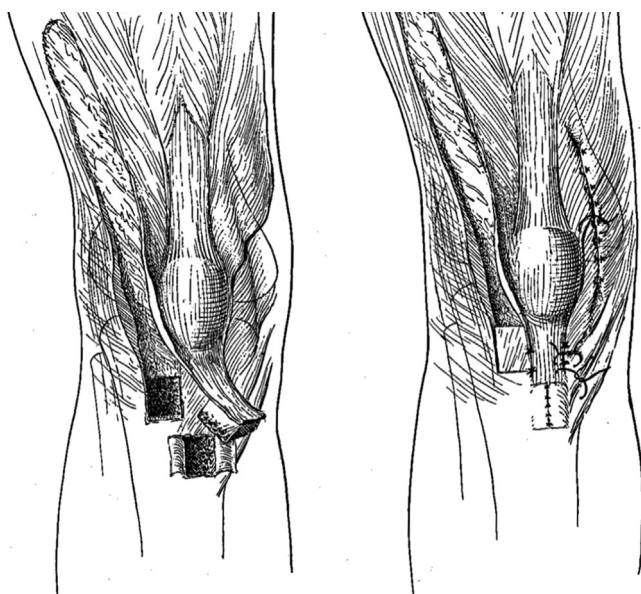


Figure 10. Original Hauser procedure, tibial tubercle transplant medially, combined with lateral release and medial reefing.

- [5] Barbari S, Raugstad TS, Lichtenberg N, Refvem D. The Hauser operation for patellar dislocation. 3-32-year results in 63 knees. *Acta Orthop Scand* 1990;61(1):32.
- [6] Hampson WG, Hill P. Late results of transfer of the tibial tubercle for recurrent dislocation of the patella. *J Bone Joint Surg Br* 1975;57(2):209.
- [7] Goldstein WM, Bailie DS. Total knee arthroplasty after Hauser procedure: case report. *Am J Knee Surg* 1998;11(2):106.
- [8] O'Brien TJ, Padgett DE, Lyons P. Technical considerations in total knee arthroplasty following the Maquet procedure. *Am J Knee Surg* 1993;6(3):108.
- [9] Padgett D. Total knee replacement after Maquet osteotomy. In: Scuderi GR, Tria AJ, editors. *Surgical techniques in total knee arthroplasty*. New York, NY: Springer; 2002.
- [10] Nam D, Abdel MP, Cross MB, et al. The management of extensor mechanism complications in total knee arthroplasty. AAOS exhibit selection. *J Bone Joint Surg Am* 2014;96(6):e47.
- [11] Rosenberg AG. Management of extensor mechanism rupture after TKA. *J Bone Joint Surg Br* 2012;94(11 Suppl A):116.
- [12] Lynch AF, Rorabeck CH, Bourne RB. Extensor mechanism complications following total knee arthroplasty. *J Arthroplasty* 1987;2(2):135.
- [13] Keblish PA. The lateral approach to the valgus knee. Surgical technique and analysis of 53 cases with over two year follow-up evaluation. *Clin Orthop Relat Res* 1991;271:52.
- [14] Keblish PA. The lateral approach for total knee arthroplasty. *J Knee Surg* 2003;16:62.