

Comparison of peribulbar and retrobulbar regional anesthesia with bupivacaine in cats

Yael Shilo-Benjamini, DVM; Peter J. Pascoe, BVSc; David J. Maggs, BVSc;
Bruno H. Pypendop, DrMedVet, DrVetSci; Eric G. Johnson, DVM; Philip H. Kass, DVM, MPVM, PhD;
Erik R. Wisner, DVM

Objective—To compare effectiveness and complications associated with peribulbar and retrobulbar anesthesia with bupivacaine in cats.

Animals—6 healthy adult cats.

Procedures—Cats were sedated with dexmedetomidine and received a peribulbar injection of 0.5% bupivacaine (1.5 mL), iopamidol (0.5 mL), and saline (0.9% NaCl) solution (1 mL) or retrobulbar injection of 0.5% bupivacaine (0.75 mL) and iopamidol (0.25 mL) in a crossover study with ≥ 2 weeks between treatments. The contralateral eye was the control. Injectate distribution was evaluated with CT. After atipamezole administration, periocular and corneal sensations, intraocular pressure (IOP), and ocular reflexes and appearance were evaluated for 24 hours.

Results—All peribulbar and 3 of 6 retrobulbar injections resulted in CT evidence of intracanal injectate. Corneal sensation and periocular skin sensation were absent or significantly reduced relative to that for control eyes for 3 hours after peribulbar injection. Mean \pm SD IOP immediately after injection was significantly higher for eyes with peribulbar injections (33 ± 12 mm Hg) than for control eyes or eyes with retrobulbar injections (both 14 ± 4 mm Hg) but 10 minutes later decreased to 18 ± 3 mm Hg. Exophthalmos, chemosis, and ptosis were evident in most injected eyes, and irritation was evident in 3 of 6 peribulbar-injected and 1 of 6 retrobulbar-injected eyes. All conditions resolved within 14 hours.

Conclusions and Clinical Relevance—Peribulbar injection resulted in intracanal deposition of bupivacaine in a higher percentage of cats than did retrobulbar injection and induced notable anesthesia relative to that for the control eye; however, IOP increased temporarily. (*Am J Vet Res* 2014;75:1029–1039)

Retrobulbar anesthesia or PBA provides excellent analgesia that could reduce the need for perioperative systemic administration of analgesics in humans and dogs.^{1–7} Additionally, these techniques provide excellent extraocular muscle akinesia that can replace the use of neuromuscular blocking agents and avoid the need for positive pressure ventilation, both of which are often required for intraocular surgery.^{1,7–10} As with other regional anesthetic techniques, use of RBA and PBA may reduce the requirements for general anesthetic agents

ABBREVIATIONS

HPD	Horizontal pupil diameter
IOP	Intraocular pressure
PBA	Peribulbar anesthesia
PLR	Pupillary light reflex
RBA	Retrobulbar anesthesia

during surgery and thus reduce the adverse effects of these drugs.^{11–13} Finally, these techniques reduce the incidence of the oculocardiac reflex, which can result in severe bradyarrhythmias and, rarely, asystole.^{3–6,14–17}

In humans, RBA has been considered the criterion-referenced standard for provision of regional anesthesia during many ophthalmic procedures. It is achieved by injecting 2 to 5 mL of an anesthetic agent intracanal (inside the muscle cone created by the extraocular muscles).^{10,18} This technique has also been described in other species.^{1,2,7,13,19–22} However, PBA is considered safer than RBA by some authors and is beginning to replace RBA for cataract surgery in humans.^{9,10,18,23} For PBA, the needle is introduced into the extraconal space (outside the muscle cone), thereby limiting risk of injury to structures within the intracanal space, such as the optic nerve and blood vessels. Injection of a larger volume of anesthetic agent (6 to 12 mL in humans)

Received June 2, 2014.

Accepted August 5, 2014.

From the Departments of Surgical and Radiological Sciences (Shilo-Benjamini, Pascoe, Maggs, Pypendop, Johnson, Wisner) and Population Health and Reproduction (Kass), School of Veterinary Medicine, University of California-Davis, Davis, CA 95616. Dr. Shilo-Benjamini's present address is Anesthesia Department, Veterinary Teaching Hospital, Koret School of Veterinary Medicine, Hebrew University of Jerusalem, Rehovot 7610001, Israel.

Presented in abstract form at the Annual Meeting of the American College of Veterinary Anesthesia and Analgesia, 19th International Veterinary Emergency and Critical Care Symposium, San Diego, September 2013.

The authors thank Georgina Newbold, Rich Larson, Jason Peters, and Jennifer Harrison for technical assistance.

Address correspondence to Dr Shilo-Benjamini (shilo.yael@gmail.com).

causes rostral spread to the eyelids, which provides more complete analgesia as well as akinesia.^{9,10,23} As with other regional anesthetic techniques, ultrasonographic guidance might improve the efficacy and safety of RBA because it permits visual determination of needle placement, minimizes intraneural or intravascular injections, allows visual assessment of local anesthetic distribution during injection, and permits repositioning the needle in cases of maldistribution.^{9,24,25}

Recently, retrobulbar and peribulbar injection techniques were assessed in cat cadavers.²⁶ However, to the authors' knowledge, information regarding the application of these techniques in living cats is limited to a case report²⁷ in which a life-threatening complication following RBA is described. Therefore, the purpose of the study reported here was to evaluate and compare the effectiveness and describe complications of RBA and PBA in cats. Our hypothesis was that both techniques would result in regional anesthesia of the injected eye in comparison to the contralateral noninjected control eye, with minimal complications.

Materials and Methods

Animals—Six adult female domestic shorthair purpose-bred cats were used in the study. Cats were 1 to 2 years old and had a mean \pm SD body weight of 4.6 ± 0.7 kg (range, 3.7 to 5.7 kg). Cats were assessed by use of physical examination, a CBC, and estimation of BUN concentration; no abnormalities were detected. Cats were habituated to handling and experimental procedures for 2 weeks prior to the beginning of the study. The study protocol was approved by the Animal Care and Use Committee of the University of California-Davis.

A complete neuro-ophthalmic examination was performed on each cat. That examination included assessment of (in the following order) direct and consensual PLRs, menace response, dazzle reflex, palpebral reflex (stimulated by lightly applying a finger to the skin at the medial canthus), corneal sensitivity with a Cochet-Bonnet aesthesiometer,^a aqueous tear production with the Schirmer tear test, and IOP with an applanation tonometer^b approximately 60 seconds after administration of 1 drop of 0.5% proparacaine hydrochloride.^c Investigators then performed slit-lamp biomicroscopy (before and after pupil dilation with tropicamide), indirect ophthalmoscopy (after pupil dilation), and ocular examination after topical application of fluorescein stain. All ophthalmic examinations were performed by a board-certified veterinary ophthalmologist (DJM).

Measurement of corneal sensitivity was performed in the central cornea with a standard Cochet-Bonnet monofilament nylon fiber (diameter, 0.12 mm) held perpendicular to the cornea. The aesthesiometer was advanced slowly until the monofilament tip touched the cornea and created a slight bend in the nylon fiber. This was performed 3 to 5 times while observing for reflexive eyelid closure. Initial stimulation involved the use of a 4-cm-long filament, which was decreased by 0.5-cm increments until a reflexive blink was detected. Corneal sensitivity was recorded as the longest filament length that induced a blink reflex on at least 3 of 5 stim-

ulations. Therefore, a decrease in filament length equated to a decrease in corneal sensitivity. Failure to elicit a reflexive blink in response to corneal stimulation with a 0.5-cm-long filament was designated as maximal corneal anesthesia (complete loss of sensation).^{28,29} Corneal sensitivity to stimulation with a 0.5-cm-long filament was defined as notable corneal anesthesia.

Retrobulbar and peribulbar injection techniques—Injections for RBA and PBA were administered to all cats by use of a randomized crossover design with at least a 2-week washout period between injections. The first treatment (right or left eye) was randomly assigned with online software^d; the treated eye was designated for subsequent treatments. The contralateral eye was not injected and served as a nontreated control eye. Food was withheld from cats for 12 hours prior to each injection, but cats were allowed unlimited access to water. Approximately 2 hours prior to injection, a baseline assessment was performed on each cat. This included bilateral assessment of HPD with a Jameson caliper, direct and consensual PLRs, palpebral and dazzle reflexes, menace response, and periorcular skin sensation by means of a pinprick technique.^{30,31} Briefly, the tip of a pen was used to gently apply pressure to the skin surrounding each eye at 4 points (mid-dorsal eyelid, medial canthus, mid-ventral eyelid, and lateral canthus). Care was taken to limit the visual stimulation caused by these actions, and eyelid closure or withdrawal of the head was considered a positive response. Finally, corneal sensitivity and IOP were assessed via the same methods as used prior to study entry.

Approximately 45 minutes before PBA or RBA, cats were sedated with dexmedetomidine hydrochloride^e (approx 45 μ g/kg [range, 36 to 55 μ g/kg]) injected IM. The dexmedetomidine dose used was higher in some cats than the label dose of 40 μ g/kg; however, this higher dose was necessary to induce sufficient sedation to prevent movement of the cats during PBA or RBA injection. Dexmedetomidine was used because its effects are reversible.

Approximately 25 to 30 minutes after cats were sedated with dexmedetomidine, cats were positioned in sternal recumbency with the head elevated on a foam block so that the cervical vertebrae were positioned at an angle of approximately 45° from the table and the eye for injection was elevated approximately 12 to 15 cm above the sternum and table. The hair of both upper eyelids was clipped so that the eye injected would hopefully remain unknown to evaluators. The clipped skin was aseptically prepared with povidone-iodine solution diluted 1:50 in sterile saline (0.9% NaCl) solution. Cats then underwent preinjection CT.^f Imaging parameters included a small field of view, 0.625-mm image collimation, 120 kVp, 200 mA, and image reconstruction with both bone (edge sharpening) and soft tissue (smoothing) algorithms.

For RBA, injection of a mixture containing 0.75 mL of 0.5% bupivacaine^g and 0.25 mL of radiographic contrast agent^h was performed in accordance with guidelines described for cat cadavers.²⁶ Briefly, a 1.5-inch, 22-gauge spinal needleⁱ was bent at the midpoint to achieve an angle of approximately 20°. The needle was

inserted through the superior eyelid at the medial region of the orbit and advanced approximately 30 mm (approx three-fourths of its length) toward the caudal pole of the globe but in close proximity to the orbital wall. Intraconal placement of the needle was performed by use of ultrasonographic guidance with a blended 5- to 8-MHz microconvex transducer.^l The transducer was placed at the dorsal aspect of the orbit (transpalpebral approach). Once the needle tip was believed to be in an intraconal location, the entire volume (1 mL) of contrast agent and local anesthetic was injected.

For PBA, injection of a mixture containing 1.5 mL of 0.5% bupivacaine, 1 mL of saline solution (which was included in the injectate to increase the volume of injection), and 0.5 mL of the same radiographic contrast agent^h was performed in accordance with guidelines described for cat cadavers.²⁶ Briefly, a 5/8-inch, 25-gauge needle^k was inserted through the superior eyelid at the medial region of the orbit and advanced to its full length in close proximity to the wall of the orbit. The entire volume (3 mL) was then injected. Slight pressure was applied to the needle during injection to ensure that it remained in the desired location. Because peribulbar injection relies on distribution of the injectate rather than injection of the anesthetic agent at a precise location, ultrasonographic confirmation was not used for this injection method. For RBA and PBA techniques, injections were performed with the bevel of the needle oriented toward the globe and after ensuring that the needle tip was not located in a blood vessel (no blood was aspirated during application of negative pressure to the syringe plunger). All injections were performed by a board-certified veterinary anesthesiologist (BHP), and ultrasonography was performed by a board-certified veterinary radiologist (EGJ).

Assessment of retrobulbar and peribulbar injection techniques—All cats underwent CT 10 minutes after retrobulbar or peribulbar injections; CT was performed as described for the preinjection imaging. Digital images (DICOM [digital imaging and communication in medicine]) were reviewed on a workstation with commercially available medical imaging software.^l Image data sets were reformatted as necessary to enable regions of interest in dorsal and oblique anatomic planes to be viewed. Another board-certified veterinary radiologist (ERW) who was unaware of the injection technique for each eye assessed distribution of the injected solution and scored the images in accordance with specific guidelines. Scores were assigned for extraconal and intraconal volume of distribution (0 = none, 1 = moderate, and 2 = large) and approximate contact area of injectate around the optic nerve (0°, 90°, 180°, 270°, or 360°), as described elsewhere.²⁶ After completion of CT, sedation was reversed by IM administration of atipamezole^m at 10 times the administered dose of dexmedetomidine.

Both IOP and HPD were measured 15 to 20 minutes after administration of dexmedetomidine but before peribulbar and retrobulbar injections; IOP and HPD were also measured immediately and 10 and 20 minutes after RBA or PBA injections. In sedated cats, IOP was measured without application of a topical anesthetic; otherwise, both IOP and HPD were performed

as described prior to study entry. Neuro-ophthalmic assessment including bilateral evaluation of the HPD, menace response, palpebral and dazzle reflexes, direct and consensual PLRs, skin sensation, and corneal sensitivity (all performed as described for the baseline assessment) was conducted as soon as a cat could walk after reversal of sedation (mean \pm SD, 41 \pm 4 minutes for RBA and 42 \pm 6 minutes for PBA), then every 60 minutes until 12 hours after orbital injection, and then every 120 minutes until all variables returned to baseline values. All assessments were performed while cats were minimally restrained in a sitting or sternal position by the same investigator (YSB), who was not aware of the injection technique for each cat.

An Elizabethan collar was placed when a cat attempted to rub the periocular skin. The collar was removed every 60 minutes to allow the neuro-ophthalmic assessment; cats were observed carefully for further signs of periocular irritation, and the Elizabethan collar was replaced if these were detected.

All reflexes and skin sensitivity were scored as follows: 0 = no response, 1 = partial response, and 2 = normal response. To assess the globe for adverse effects of RBA or PBA, a complete ophthalmic examination (performed in the same manner as before study entry and by the same board-certified veterinary ophthalmologist [DJM], who was unaware of the injection technique for each cat) was performed again approximately 24 hours after injections.

Data analysis—For all analyses, the noninjected eye served as the control eye for comparison. The exact Wilcoxon signed rank test was used to compare scores or values between techniques and between control eyes and injected eyes over time. A linear mixed-effects regression model was used to estimate the effects of treatment, time, and eye on IOP. When a significant interaction was detected, treatment differences at the various times were individually examined, and a Bonferroni adjustment for multiple comparisons was applied. The IOP data were reported as mean \pm SD; all other variables were found to have a nonnormal distribution on the basis of results for the Shapiro-Wilk normality test and were reported as median and range. The correlation between injectate distribution around the optic nerve and body weight or corneal sensitivity at each time point was assessed by means of the Spearman correlation test. For all analyses, statistical softwareⁿ was used, and values of $P < 0.05$ were considered significant.

Results

No ophthalmic or neuro-ophthalmic abnormalities were detected in any cat at study entry. Four cats received RBA in the left eye and 2 in the right eye, whereas 2 cats received PBA in the left eye and 4 in the right eye. The needle tip was difficult to identify ultrasonographically in all cats for the RBA treatment, but after injection, fluid was easily observed ultrasonographically in all cats (**Figure 1**). In 5 of 6 cats, the fluid was believed to be located intraconally. However, CT data revealed that the injectate was intraconal in 3 eyes and extraconal in 3 eyes for the RBA treatment (**Figure 2; Table 1**). As judged by use of CT, injectate was intraconal in

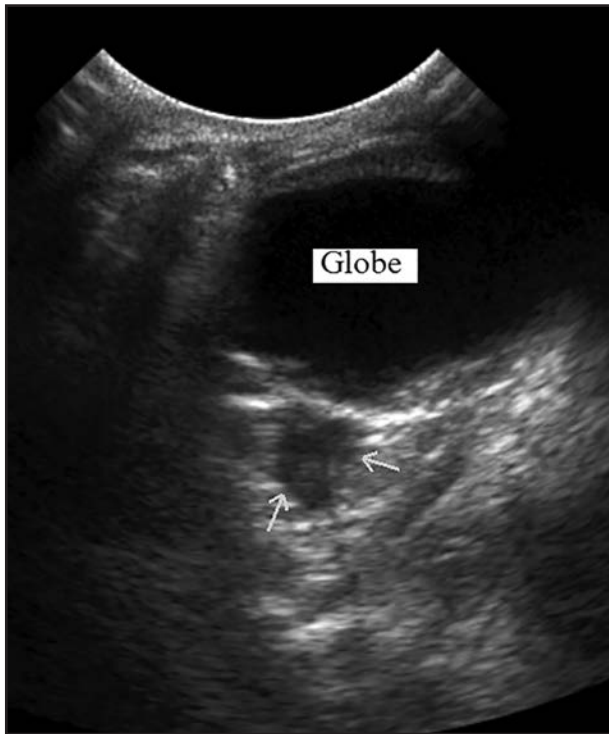

Figure 1—Transpalpebral ultrasonographic image of the left eye of a cat after retrobulbar injection of a mixture of 0.5% bupivacaine (0.75 mL) and iopamidol (0.25 mL). Notice the margins of the injectate (arrows); the injectate was deposited intraconally.

all eyes for the PBA treatment (Figure 3). Injectate was completely distributed around the optic nerve (360°) in 2 of 3 eyes after intraconal RBA and in 3 of 6 eyes after PBA. Data from all injected eyes (including the 3 RBA injections that resulted in extraconal injectate) were included in the analysis. There was no significant difference between treatments with regard to injectate distribution (intraconal, $P = 0.34$; extraconal, $P = 0.25$; and optic nerve circumference, $P = 0.44$) as assessed by use of CT. No intraocular, intravascular, intrathecal, or intraneural injectate was observed on any CT image of any eye for either injection technique.

Results of baseline neuro-ophthalmic assessments were within anticipated limits in all eyes. The number of eyes in which, and the duration for which, neuro-ophthalmic variables were altered after injection were summarized (Table 2). For the first 3 hours after injection, median direct PLR score was significantly ($P = 0.031$ for all time points) lower for eyes for the PBA treatment (score of 0 for the first 2 hours and 0.5 for the third hour) than for control eyes (score of 2 for all time points). Median consensual PLR score (from the untreated to the treated eye) was significantly lower for eyes for the PBA treatment than for control eyes at 40 minutes (score 0 and 2, respectively; $P = 0.031$) and 3 hours (score 0.5 and 2, respectively; $P = 0.031$) after injection.

Median HPD was not significantly different between eyes for the RBA treatment and the PBA treatment ($P = 0.31$ to 1.00) or between control eyes and treated eyes for both treatments ($P = 1.00$), whether measured at baseline or after cats were sedated. However, approximately 20 minutes after administration

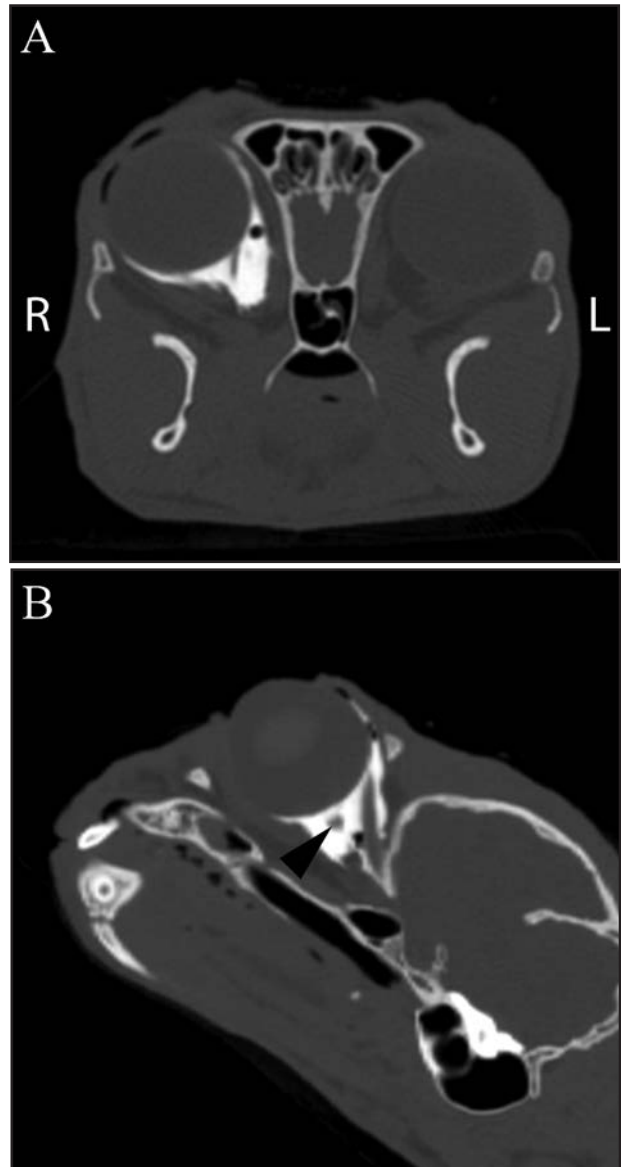


Figure 2—Dorsal plane (A) and reformatted oblique plane (B) CT images of the head of a cat after retrobulbar injection of a mixture of 0.5% bupivacaine (0.75 mL) and iopamidol (0.25 mL) into the right orbit. Notice the optic nerve in long axis (arrowhead) in panel B. L = Left. R = Right.

of sedative for the RBA treatment, the median HPD increased significantly ($P = 0.031$) in both treated and control eyes (from 6 to 8.5 mm). After orbital injection, all eyes for the PBA treatment and 5 of 6 eyes for the RBA treatment had an increase in pupil size, which lasted approximately 10 hours for both treatments (Figure 4). For eyes for the PBA treatment, median HPD was significantly ($P = 0.031$ for all time points) higher in treated than control eyes at 10 minutes (10 and 7.5 mm, respectively), 40 minutes (10.5 and 6 mm, respectively), 1 hour (11 and 7 mm, respectively), 2 hours (10 and 7.5 mm, respectively), 3 hours (10 and 7 mm, respectively), and 5 hours (9 and 6 mm, respectively) after injection.

Periocular sensitivity scores during the first 5 hours after injections were summarized (Table 3). Baseline periocular sensitivity was considered normal (score, 2)

Table 1—Number of eyes with each score for extraconal and intraconal injectate volume and distribution of injectate around the optic nerve as determined by use of CT 10 minutes after retrobulbar injection of 0.75 mL of 0.5% bupivacaine and 0.25 mL of iopamidol or peribulbar injection of 1.5 mL of 0.5% bupivacaine, 1 mL of saline (0.9% NaCl) solution, and 0.5 mL of iopamidol in 6 cats.

Variable	No. of eyes		
	Score	RBA	PBA
Extraconal	0	0	0
	1	3	0
	2	3	6
Intraconal	0	3	0
	1	0	3
	2	3	3
Distribution around optic nerve	0°	3	0
	90°	0	1
	180°	1	2
	270°	0	0
	360°	2	3

Extraconal and intraconal injectate volume was scored as follows: 0 = none, 1 = moderate, and 2 = large.

in all regions in all eyes. Median periocular sensitivity score was significantly ($P = 0.031$ in both regions for all time points) lower for PBA-treated eyes (score, 0) than for control eyes (score, 2) for 3 hours in the dorsal and lateral regions. Median dorsal periocular sensitivity score was also significantly ($P = 0.031$) lower for PBA-treated eyes (score, 0) than for RBA-treated eyes (score, 2) at the 3-hour time point.

Baseline median corneal sensitivity did not differ significantly among eyes for the RBA treatment (2.75 cm; range, 1.5 to 3 cm), control eyes of RBA-treated cats (2.5 cm; range, 1.5 to 3 cm), eyes for the PBA treatment (2.75 cm; range, 1.5 to 3.5 cm), or control eyes of PBA-treated cats (2.75 cm; range, 2 to 3.5 cm). At 40 minutes and 1, 2, and 3 hours after PBA injection, corneal sensitivity in injected eyes (0, 0.25, 0.25, and 0.75 cm, respectively) was significantly ($P = 0.031$ at all time points) lower than corneal sensitivity in control eyes (2.5, 2.75, 3, and 3 cm, respectively; **Figure 5**). After PBA and intraconal RBA injections, median duration of maximal corneal anesthesia (defined as corneal sensitivity of 0) was 3.5 hours (range, 0.67 to 5 hours) and 3 hours (range, 2 to 4 hours), respectively (**Table 4**).

Mean \pm SD baseline and postsedation IOP measurements were not significantly different among injected or control eyes or between treatments (**Figure 6**). Immediately after injection, mean \pm SD IOP in eyes for the PBA treatment (33 ± 12 mm Hg) was significantly higher than that in control eyes (14 ± 4 mm Hg; $P < 0.001$) and RBA-treated eyes (14 ± 4 mm Hg; $P < 0.001$). However, 10 minutes later, mean IOP in PBA-treated eyes had decreased to 18 ± 3 mm Hg, which was still significantly ($P = 0.025$) different from the mean IOP of the control eyes but not the mean IOP of the RBA-treated eyes.

The Spearman correlation coefficient between body weight and distribution around the optic nerve was 0.31 ($P = 0.53$) for the RBA treatment and -0.62 ($P = 0.23$) for the PBA treatment. There were many negative correlations between distribution around the optic nerve and corneal sensitivity (ie, larger distribution correlated with lower sensitivity) for both treatments, but they were significant only for the PBA treatment and

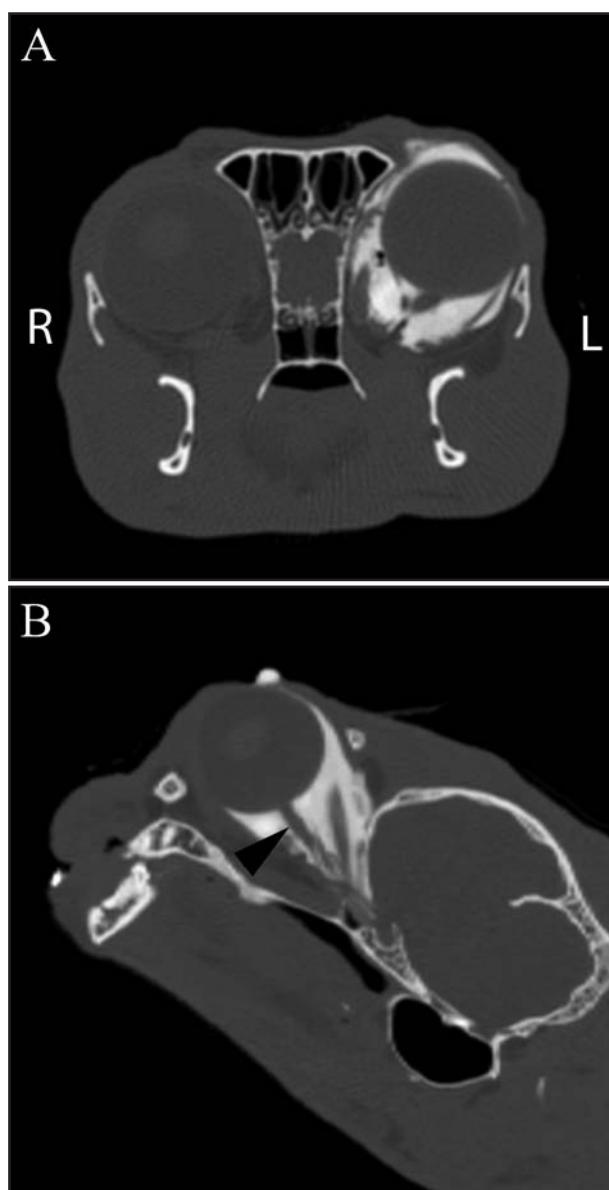


Figure 3—Dorsal plane (A) and reformatted oblique plane (B) CT images of the head of a cat after peribulbar injection of a mixture of 0.5% bupivacaine (1.5 mL), saline (0.9% NaCl) solution (1 mL), and iopamidol (0.5 mL) into the left orbit. Notice the optic nerve in long axis (arrowhead) in panel B. L = Left. R = Right.

only at 2 ($r = -0.95$; $P = 0.033$), 3 ($r = -1$; $P = 0.017$), and 4 ($r = -0.93$; $P = 0.017$) hours after injection.

Blood was not aspirated during application of negative pressure prior to peribulbar or retrobulbar injection, and there was minimal resistance to injection. The popping sensation described as indicating intraconal needle placement in dogs¹ was not felt for any of the retrobulbar injections. Ptosis of the upper eyelid was evident in 5 of 6 RBA-treated eyes 1 to 7 hours after injection and in all PBA-treated eyes 2 to 14 hours after injection. Variable degrees of exophthalmos and chemosis (conjunctival edema) were evident at the first evaluation in 5 of 6 RBA-treated and in all PBA-treated eyes but resolved completely by 8 and 11 hours after injection, respectively. Attempts to rub the periocular skin of the injected eye were observed for 1 of 6 RBA-treated eyes between 1 and 2 hours after in-

Table 2—Number of cats* (range of duration [in hours]) in which a reduced or absent neuro-ophthalmic reflex or response was detected after RBA treatment or PBA treatment in 6 cats.

Neuro-ophthalmic assessment	RBA		PBA
	Intraconal	Extraconal	
Palpebral reflex	0/3 (0)	0/3 (0)	1/6 (3)
Menace response	2/3 (3–4)	0/3 (0)	4/6 (1–5)
Dazzle reflex	3/3 (2–4)†	0/3 (0)	5/6 (1–6)
PLR	3/3 (7–12)	2/3 (1–3)†	6/6 (4–14)
Consensual PLR (untreated to treated eye)	3/3 (7–12)	2/3 (1–3)†	6/6 (4–14)
Consensual PLR (treated to untreated eye)	2/3 (1–2)†	0/3 (0)	2/6 (1–5)

*Results are number of cats affected/number of cats treated. †The reflex was only reduced but never absent in these cats.

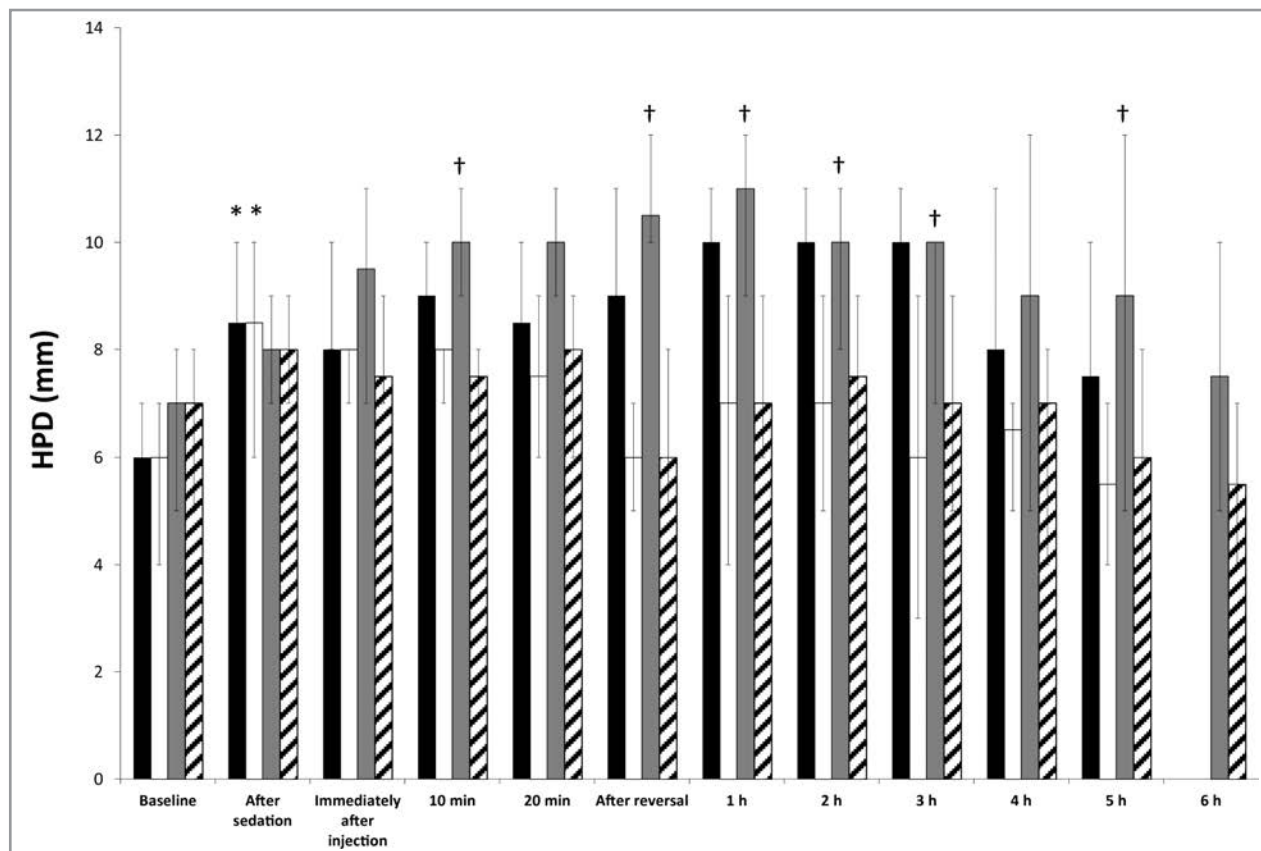


Figure 4—Median (range) HPD at various points before and after retrobulbar injection of 0.75 mL of 0.5% bupivacaine and 0.25 mL of iopamidol (black bars) or peribulbar injection of 1.5 mL of 0.5% bupivacaine, 1 mL of saline solution, and 0.5 mL of iopamidol (gray bars) in the orbit of 6 cats. For both techniques, the contralateral eye served as the noninjected control eye (RBA control eyes, white bars; PBA control eyes, diagonal-striped bars). *Within a treatment, value differs significantly ($P < 0.05$) from the baseline value. †Within a time point, value differs significantly ($P < 0.05$) from the value for the control eyes of the same treatment.

jection and 3 of 6 PBA-treated eyes between 4 and 7 hours after injection.

Ophthalmic examination 24 to 26 hours after injection revealed no differences between injected and control eyes, and the injected eye could not be identified after any of the injections. Approximately 3 weeks after the end of the study, a complete physical examination (including ophthalmic examination) was performed on all cats, and no abnormalities related to vision were detected.

Discussion

In the present study, PBA was more likely than RBA to result in sufficient intraconal injectate and induce regional anesthesia of the cornea and periocular skin.

However, when there was adequate intraconal placement for RBA, decreased sensitivity of the cornea was evident as well. The 3 extraconal RBA injections were included in the data analysis because they represented a clinical situation that would likely go unrecognized without advanced diagnostic imaging. Failure to administer the anesthetic in the correct location with the RBA technique is a clinically relevant disadvantage (ie, PBA with an RBA dose or volume is ineffective). Retrobulbar injections performed without the use of ultrasonographic guidance resulted in successful deposition of injectate (defined as a large volume of distribution intraconally and a contact area $> 270^\circ$ around the optic nerve) in 5 of 7 cat cadavers.²⁶ We hypothesized

Table 3—Median (range) periocular skin sensitivity scores for 4 regions after intraconal RBA treatment in 3 cats, extraconal RBA treatment in 3 cats, or PBA treatment in 6 cats.

Treatment	Baseline	After reversal of sedation	1 hour	2 hours	3 hours	4 hours	5 hours
Dorsal							
Extraconal RBA	2 (2)	2 (1–2)	2 (0–2)	2 (1–2)	2 (2)	2 (2)	2 (2)
Intraconal RBA	2 (2)	0 (0)	0 (0)	1 (0–1)	2 (1–2)	2 (2)	2 (2)
PBA	2 (2)	0 (0)*	0 (0)*	0 (0)*	0 (0–1)*†	0.5 (0–2)	2 (0–2)
Control eyes	2 (2)	2 (2)	2 (2)	2 (2)	2 (2)	2 (2)	2 (2)
Ventral							
Extraconal RBA	2 (2)	1 (0–2)	1 (1–2)	1 (0–2)	2 (2)	2 (2)	2 (2)
Intraconal RBA	2 (2)	2 (1–2)	2 (2)	1 (0–2)	1 (1–2)	2 (1–2)	2 (2)
PBA	2 (2)	0 (0–2)	0.5 (0–2)	0 (0–2)	1 (0–2)	2 (1–2)	2 (2)
Control eyes	2 (2)	2 (2)	2 (2)	2 (2)	2 (2)	2 (2)	2 (2)
Lateral							
Extraconal RBA	2 (2)	1 (0–2)	1 (1–2)	2 (1–2)	2 (2)	2 (2)	2 (2)
Intraconal RBA	2 (2)	1 (0–2)	0 (0–2)	1 (0–1)	1 (1)	2 (1–2)	2 (2)
PBA	2 (2)	0 (0–1)*	0 (0)*	0 (0)*	0 (0)*	1.5 (0–2)	2 (2)
Control eyes	2 (2)	2 (2)	2 (2)	2 (2)	2 (2)	2 (2)	2 (2)
Medial							
Extraconal RBA	2 (2)	2 (2)	2 (2)	2 (2)	2 (2)	2 (2)	2 (2)
Intraconal RBA	2 (2)	2 (1–2)	2 (0–2)	2 (2)	2 (2)	2 (2)	2 (2)
PBA	2 (2)	2 (0–2)	2 (0–2)	2 (0–2)	2 (1–2)	2 (2)	2 (2)
Control eyes	2 (2)	2 (2)	2 (2)	2 (2)	2 (2)	2 (2)	2 (2)

Scores were assigned as follows: 0 = no response, 1 = partial response, and 2 = normal response. Cats were sedated with dexmedetomidine; sedation was subsequently reversed by the administration of atipamezole.
 *Within a region, value differs significantly ($P < 0.05$) from the value for the control eyes. †Within a region, value differs significantly ($P < 0.05$) from the values for both intraconal and extraconal RBA.

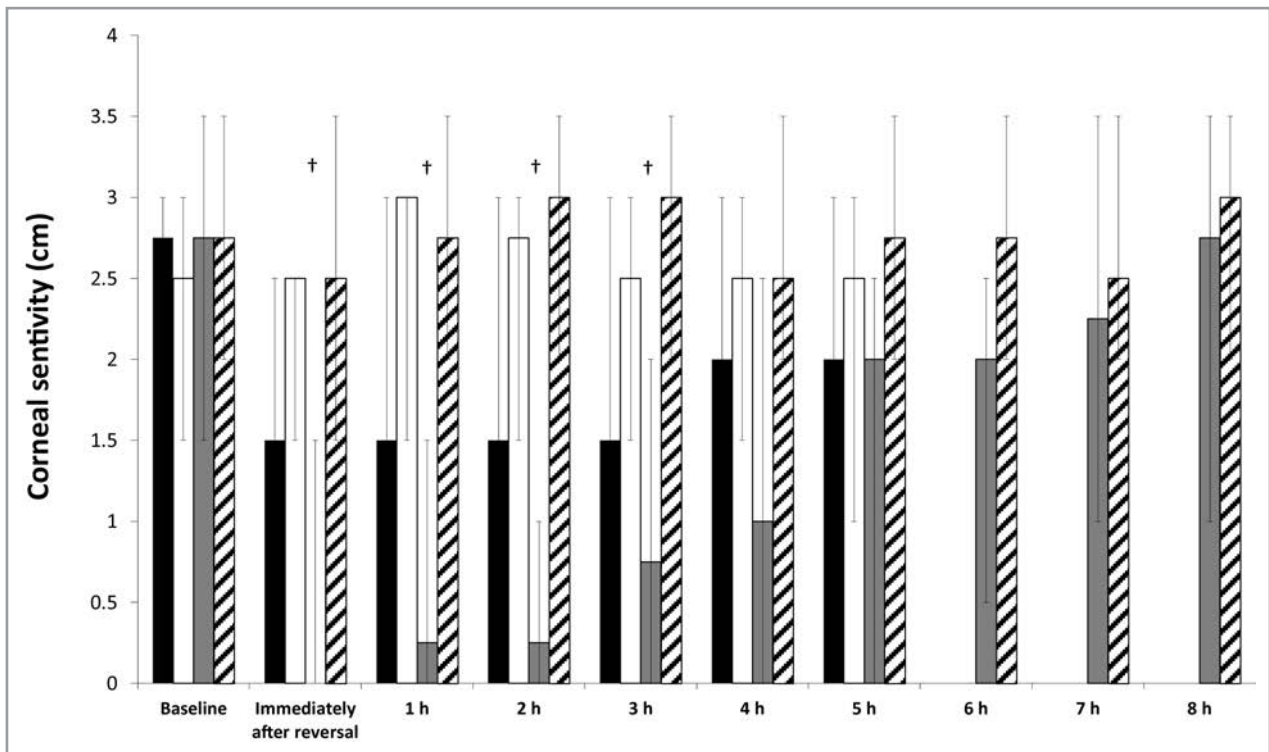


Figure 5—Median (range) corneal sensitivity at various points before and after retrobulbar injection of 0.75 mL of 0.5% bupivacaine and 0.25 mL of iopamidol or peribulbar injection of 1.5 mL of 0.5% bupivacaine, 1 mL of saline solution, and 0.5 mL of iopamidol in the orbit of 6 cats. Corneal sensitivity is reported as the length of the aesthesiometer filament (in centimeters). For both techniques, the contralateral eye served as the noninjected control eye. See Figure 4 for remainder of key.

that ultrasonographic confirmation would increase the accuracy of the RBA technique, but this was not the case. The reasons for failure of half of the RBA injections could have included lack of experience with retrobulbar injections in cats and difficulty identifying the needle tip ultrasonographically because of the cur-

vature of the needle. In human cadavers, ultrasonographic guidance resulted in success in 19 of 20 retrobulbar injections performed with a straight needle.²⁵ Because we routinely use a curved needle¹ in our hospital for RBA in dogs, we did not use a straight needle in the cats of the present study, which might have facilitated

Table 4—Maximal and notable corneal anesthesia* measured by use of an aesthesiometer after intraconal RBA treatment in 3 cats or PBA treatment in 6 cats.

Variable	Intraconal RBA (No. anesthetized/No. treated)	Duration (h)		PBA (No. anesthetized/No. treated)	Duration (h)	
		Median	Range		Median	Range
Maximal corneal anesthesia	2/3	3	2.00–4.00	4/6	3.5	0.67–5.00
Notable corneal anesthesia	2/3	4.5	3.00–6.00	4/6	5	2.00–6.00

Three cats received extraconal RBA injections, but these did not result in a notable decrease in corneal sensitivity.
*Maximal and notable corneal anesthesia is defined as failure to respond to and response to, respectively, an aesthesiometer filament length of 0.5 cm.

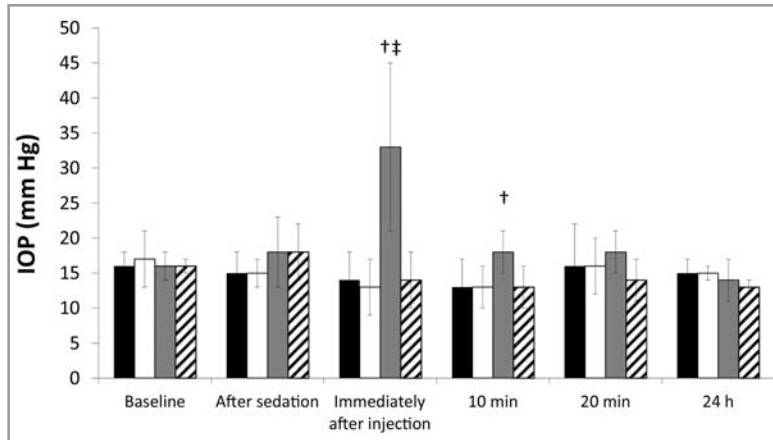


Figure 6—Mean \pm SD IOP at various points before and after retrobulbar injection of 0.75 mL of bupivacaine 0.5% and 0.25 mL of iopamidol or peribulbar injection of 1.5 mL of bupivacaine 0.5%, 1 mL of saline solution, and 0.5 mL of iopamidol in the orbit of 6 cats. For both techniques, the contralateral eye served as the noninjected control eye. †Within a time point, value differs significantly ($P < 0.05$) from the value for the RBA treatment. See Figure 4 for remainder of key.

ultrasonographic imaging and improved accuracy of RBA injections. However, cats have larger eyes relative to their body size than do humans and dogs,^{32,33} which might increase the risk of globe perforation when a long straight needle is used.

The orbit in adult cats is approximately 24 mm wide \times 26 mm high, and the globe is approximately 20 to 21 mm in diameter³²; thus, we standardized the injection volume administered for each orbit, rather than as a function of body weight. We did not find a correlation between body weight and injectate distribution around the optic nerve, but there was a limited distribution for cat body weight. The PBA technique requires a larger volume than that used for RBA because the anesthetic spreads passively into the muscle cone.^{23,34} The volumes for RBA and PBA in the present study were based on results for a study²⁶ in cat cadavers, where 1 and 4 mL resulted in appropriate intraconal distribution. However, although results of that study²⁶ indicated 4 mL was appropriate for PBA, a volume of 3 mL was used in the present study because of 2 concerns: ensuring we did not exceed a bupivacaine dose of 2 mg/kg to avoid systemic toxicosis,^{35–41} and maintaining a bupivacaine concentration $> 0.25\%$ because lower concentrations of the anesthetic may lead to decreased efficacy.^{4,42,43} Given that distribution of the injectate around the optic nerve was only 90° to 180° in 3 of 6 PBA-treated eyes, it is possible that a larger volume (4 mL) was indicated for PBA. Addition of the contrast agent in the present study also may have affected distribution of the bupi-

vacaine, but it was essential for the CT monitoring.

When performing RBA or PBA, the nerves involved include the optic nerve (cranial nerve II), oculomotor nerve (cranial nerve III), trochlear nerve (cranial nerve IV), branches of the trigeminal nerve (cranial nerve V), and abducens nerve (cranial nerve VI).^{8,13,18,44,45} The trochlear, abducens, and oculomotor nerves innervate extraocular muscles, and the oculomotor nerve supplies the iris sphincter muscle. All of these nerves, except the trochlear nerve, pass inside the muscular cone. Therefore, injecting anesthetic inside the cone can be expected to provide anesthesia and akinesia of the globe.^{8,10,33} Ptosis of the eyelid results from paralysis of a branch of the oculomotor nerve, which innervates the levator palpebrae superioris muscle,^{33,44} and was seen in most (5/6 for RBA and 6/6 for PBA) of the injected eyes,

which suggested appropriate technique and adequate administration of anesthetic.

The palpebral reflex involves the trigeminal nerve (periocular skin sensation) and superior branch of the facial nerve (reflex closure of eyelids).⁸ In the present study, the palpebral reflex was not affected (except for 1 PBA-treated eye). In humans, RBA typically is accompanied by a separate injection to block this branch of the facial nerve and prevent patients from blinking.^{8,9} However, for PBA, the larger volume provides rostral spread to the eyelids, which results in a block of the orbicularis muscle of the eyelids and thereby avoids the need for an additional eyelid block.^{8,10} The reason that most of the peribulbar injections in the present study did not eliminate the palpebral reflex could have been the smaller volume used in comparison to orbit size or insufficient rostral drug delivery.

The menace reflex involves the optic and facial nerves.³³ In humans undergoing cataract surgery with regional anesthesia achieved with RBA or PBA, vision is present in approximately 40% of patients.^{46,47} In the present study, the menace reflex was reduced or absent for 2 of 3 intraconal RBA and 4 of 6 PBA injections, which suggested that some cats retained some vision, as has been reported in humans.

The dazzle reflex involves the optic and facial nerves but is a subcortical reflex.³³ In humans undergoing cataract surgery with regional anesthesia achieved with RBA or PBA, $> 80\%$ retained some degree of intraoperative light perception.^{46,47} In the present study, the dazzle reflex

was reduced for 3 of 3 intraconal RBA injections and was reduced or absent for 5 of 6 PBA-treated eyes.

Dilation of the pupil was observed in all injected eyes, presumably because of blockade of the oculomotor nerve.^{8,33,44} Direct and consensual PLRs involve the optic nerve and parasympathetic fibers of the oculomotor nerve.³³ Those reflexes were absent or reduced for up to 14 hours after injection for both treatments. The longer duration of effect for both techniques on pupil dilation and response to light in comparison to the duration of effect for sensation and other reflexes is also described in humans after retrobulbar injection of lidocaine.⁴⁸ This may be a result of the organization of parasympathetic fibers, which are concentrated around the oculomotor nerve and makes them particularly vulnerable to injury³³ or absorption of anesthetics. It may also be related to the increased sensitivity of autonomic fibers to anesthetics, compared with the sensitivity of sensory fibers.^{49,50}

After PBA injections, periocular skin sensation was decreased significantly for 3 hours, and it was also significantly reduced, compared with results for RBA, at 1 time point. Also, when PBA treatment was compared with the 3 intraconal RBA treatments, the PBA treatment resulted in lower scores (decreased sensitivity) for a longer duration. Sensation for the cornea as well as the perilimbal region and dorsomedial quadrant of the peripheral conjunctiva is mediated by the nasociliary nerve (ophthalmic nerve branch) coursing inside the muscle cone. The remainder of the peripheral conjunctiva is innervated by the lacrimal, frontal, and infraorbital nerves (ophthalmic nerve branches) coursing outside the muscle cone.^{9,18,33,44} Hence, extraconal injection of anesthetic would be expected to induce anesthetic and analgesic effects on periocular structures that are superior to anesthetic and analgesic effects after intraconal anesthetic injection.

Baseline corneal sensitivity in the present study was similar to that reported in one study²⁹ but higher than that reported in another study.²⁸ In a different study,⁴⁸ retrobulbar administration of 1 mL of 1% or 2% lidocaine to a person resulted in maximal reduction in corneal sensitivity at 5 minutes, and the duration of maximal effect was 40 minutes with 1% lidocaine (without epinephrine) and 120 minutes with 2% lidocaine in combination with epinephrine. In the present study, the median duration of maximal corneal anesthesia after PBA and intraconal RBA was approximately 3 hours; however, detectable corneal anesthesia lasted longer for both treatments. This suggests that these techniques may provide some degree of ocular analgesia during the postoperative period.

A significant negative correlation between the extent of injectate surrounding the optic nerve and corneal sensitivity for the PBA treatment was detected at 2, 3, and 4 hours after injection. The 3 cats in which the injectate spread 360° around the optic nerve also had reduced corneal sensitivity for a longer duration than did cats in which the injectate spread only 90° to 180° around the optic nerve. This likely was because the nasociliary branch of the ophthalmic nerve, which innervates the cornea, passes in close proximity to the surface of the optic nerve.^{33,44}

Complications of needle-based regional ocular anesthesia may be local (eg, conjunctival edema or hemorrhage, globe perforation, and optic nerve or extraocular muscle damage)⁵¹⁻⁵⁷ or systemic (eg, oculocardiac reflex, local anesthetic toxicosis, intravascular injection, or intrathecal injection, which can induce seizures and cardiorespiratory arrest).^{27,57-60} Theoretically, RBA carries a higher risk of serious complications because of intraconal introduction of the needle. However, this has not been confirmed in humans because of the extremely low rate of complications and the subsequent lack of power of comparative studies.^{10,34} Peribulbar anesthesia is associated with frequent conjunctival edema and hemorrhage because of rostral spread of the anesthetic agent and damage to minor blood vessels. These minor complications usually do not interfere with surgery or surgical outcome and resolve spontaneously within a few hours.^{8,34,58} None of the cats in the present study had notable adverse events after either injection technique, although conjunctival edema was observed in most cats. Recently, anesthesia of the brainstem was suspected in a cat after RBA prior to enucleation of the globe.²⁷ That cat had respiratory arrest 5 minutes after injection, but spontaneous breathing returned within 45 minutes, and recovery was slow with some neurologic deficits.²⁷ That cat was injected with a combination of bupivacaine and lidocaine (1 mL of each) via the lateral bulbar conjunctival fornix, as described for dogs.¹ The technique involved twice the volume and a different needle insertion point than was used in the present study.

The significant increase in IOP in the present study after PBA was reported in cat cadavers (IOP was increased from a mean of 1 to 2 mm Hg [nonmeasurable in 70% of eyes] to a mean of 26 to 29 mm Hg after PBA injections)²⁶ and has been described in humans.^{3,61-63} The authors are not aware of any studies in cats that have examined the extent and duration of increased IOP on vision or funduscopy changes. However, a study⁶⁴ in rats revealed that an increase in IOP to 60 mm Hg for 105 minutes caused no change in electroretinography results at 4 weeks after the insult. The increase in IOP after PBA is usually short-lived, as was seen in the present study, and likely to be clinically irrelevant,³ but it would be undesirable in patients with glaucoma or with a globe at risk of rupture. In a study⁶³ in which investigators examined the effect of RBA and PBA on IOP of humans with or without glaucoma, patients with glaucoma had higher and more persistent increases in IOP than those without glaucoma, and the authors reported that this increase may be sufficient to further compromise optic nerve function. In humans, tear production is decreased after RBA because the lacrimal nerve (small branch of the ophthalmic nerve) is blocked.⁴⁸ Although tear production was not recorded after injections in the present study, it returned to reference limits by 24 hours and did not differ from baseline values. Assuming that cats receiving RBA or PBA are less likely to reflexively blink and produce tears, it will make them more prone to corneal desiccation and potentially ulceration. Thus, it would be advisable to ensure adequate lubrication of the injected eye following the use of these techniques.

Limitations to the present study included the small sample size, limited experience with these techniques in cats, limited experience with ultrasonographic confirmation when a curved needle is used, and concerns regarding extrapolation of these data from healthy young cats to clinical patients with ocular and sometimes systemic disease. Although the same investigator evaluated all cats after the injections, most of the variables assessed may have some subjective interpretation. The injections should be performed in animals that are deeply sedated or under general anesthesia. Because the use of local anesthesia may result in systemic toxicosis, the dose of bupivacaine should not exceed the recommended maximal dose, and no other local anesthetics should be administered concurrently.

In the study reported here, peribulbar injection resulted in bupivacaine intraconally in a higher percentage of cats than did retrobulbar injection and induced notable anesthesia relative to effects in the control eye. Qualitatively, reduced corneal sensitivity was evident after 3 intraconal retrobulbar injections, which suggested that a more refined RBA technique may result in intraconal administration of drug as reliably as for the PBA technique, although it may not induce the same degree and duration of periocular anesthesia. Both techniques had minor temporary adverse effects. However, a significant increase in IOP after PBA will restrict use of this anesthetic technique in cats with glaucoma or at risk of corneal rupture. The use of PBA at the dose and volume and via the approach described in this study will most likely reduce the amount of pain and permit a reduction in the amount of general anesthetic needed in cats undergoing certain ocular or periocular procedures, especially enucleation.

- a. Cochet-Bonnet aesthesiometer, Luneau Ophtalmologie, Chartres Cedex, France.
- b. Tono-Pen Vet, Reichert Technologies, New York, NY.
- c. Falcon Pharmaceuticals, Fort Worth, Tex.
- d. Randomizer.org. Research randomizer. Available at: www.randomizer.org. Accessed Jun 2, 2014.
- e. Dexdomitor, Orion Pharma Ltd, Espoo, Finland.
- f. LightSpeed 16-slice helical CT scanner, General Electric Co, Waukesha, Wis.
- g. Bupivacaine HCl 0.5%, Hospira Inc, Lake Forest, Ill.
- h. Isovue 200, Bracco Dx, Princeton, NJ.
- i. BD spinal needle, BD Medical, Franklin Lakes, NJ.
- j. iE33 ultrasound system, Philips Healthcare, Andover, Mass.
- k. Kendall Monoject, Covidien, Mansfield, Mass.
- l. eFilm 2.1, MERGE Healthcare Inc, Chicago, Ill.
- m. Antisedan, Orion Pharma Ltd, Espoo, Finland.
- n. Intercooled Stata, version 12.1, Stata Corp, College Station, Tex.

References

1. Accola PJ, Bentley E, Smith LJ, et al. Development of a retrobulbar injection technique for ocular surgery and analgesia in dogs. *J Am Vet Med Assoc* 2006;229:220–225.
2. Myrna KE, Bentley E, Smith LJ. Effectiveness of injection of local anesthetic into the retrobulbar space for postoperative analgesia following eye enucleation in dogs. *J Am Vet Med Assoc* 2010;237:174–177.
3. Ghali AM, El Btarny AM. The effect on outcome of peribulbar anaesthesia in conjunction with general anaesthesia for vitreo-retinal surgery. *Anaesthesia* 2010;65:249–253.
4. Shende D, Sadhasivam S, Madan R. Effects of peribulbar bupivacaine as an adjunct to general anaesthesia on peri-operative outcome following retinal detachment surgery. *Anaesthesia* 2000;55:970–975.
5. Deb K, Subramaniam R, Dehnan M, et al. Safety and efficacy of peribulbar block as adjunct to general anaesthesia for paediatric ophthalmic surgery. *Paediatr Anaesth* 2001;11:161–167.
6. Morel J, Pascal J, Charier D, et al. Preoperative peribulbar block in patients undergoing retinal detachment surgery under general anaesthesia: a randomized double-blind study. *Anesth Analg* 2006;102:1082–1087.
7. Hazra S, De D, Roy B, et al. Use of ketamine, xylazine, and diazepam anaesthesia with retrobulbar block for phacoemulsification in dogs. *Vet Ophthalmol* 2008;11:255–259.
8. Malik A, Fletcher EC, Chong V, et al. Local anaesthesia for cataract surgery. *J Cataract Refract Surg* 2010;36:133–152.
9. Nouvellon E, Cuvillon P, Ripart J. Regional anaesthesia and eye surgery. *Anesthesiology* 2010;113:1236–1242.
10. Nouvellon E, Cuvillon P, Ripart J, et al. Anaesthesia for cataract surgery. *Drugs Aging* 2010;27:21–38.
11. McMillan MW, Seymour CJ, Brearley JC. Effect of intratesticular lidocaine on isoflurane requirements in dogs undergoing routine castration. *J Small Anim Pract* 2012;53:393–397.
12. Snyder CJ, Snyder LB. Effect of mepivacaine in an infraorbital nerve block on minimum alveolar concentration of isoflurane in clinically normal anesthetized dogs undergoing a modified form of dental dolorimetry. *J Am Vet Med Assoc* 2013;242:199–204.
13. Skarda RT, Tranquilli WJ. Local and regional anesthetic and analgesic techniques: dogs. In: Tranquilli WJ, Thurmon JC, Grimm KA, eds. *Lumb & Jones' veterinary anaesthesia and analgesia*. 4th ed. Ames, Iowa: Blackwell Publishing, 2007;561–593.
14. Oel C, Gerhards H, Gehlen H. Effect of retrobulbar nerve block on heart rate variability during enucleation in horses under general anaesthesia. *Vet Ophthalmol* 2014;17:170–174.
15. Short CE, Rebhun WC. Complications caused by the oculocardiac reflex during anaesthesia in a foal. *J Am Vet Med Assoc* 1980;176:630–631.
16. Fayon M, Gauthier M, Blanc VF, et al. Intraoperative cardiac arrest due to the oculocardiac reflex and subsequent death in a child with occult Epstein-Barr virus myocarditis. *Anesthesiology* 1995;83:622–624.
17. Gupta N, Kumar R, Kumar S, et al. A prospective randomised double blind study to evaluate the effect of peribulbar block or topical application of local anaesthesia combined with general anaesthesia on intra-operative and postoperative complications during paediatric strabismus surgery. *Anaesthesia* 2007;62:1110–1113.
18. Kumar CM, Dodds C. Ophthalmic regional block. *Ann Acad Med Singapore* 2006;35:158–167.
19. Giuliano EA. Regional anaesthesia as an adjunct for eyelid surgery in dogs. *Top Companion Anim Med* 2008;23:51–56.
20. Raffe MR, Bistner SI, Crimi AJ, et al. Retrobulbar block in combination with general anaesthesia for equine ophthalmic surgery. *Vet Surg* 1986;15:139–141.
21. Ravan N, Azari O, Molaei M. Xylazine-lidocaine combination for retrobulbar block in goats. *Iranian J Vet Surg* 2008;3:67–74.
22. Pearce SG, Kerr CL, Boure LP, et al. Comparison of the retrobulbar and Peterson nerve block techniques via magnetic resonance imaging in bovine cadavers. *J Am Vet Med Assoc* 2003;223:852–855.
23. Ripart J, Lefrant JY, de La Coussaye JE, et al. Peribulbar versus retrobulbar anaesthesia for ophthalmic surgery: an anatomical comparison of extraconal and intraconal injections. *Anesthesiology* 2001;94:56–62.
24. Marhofer P, Greher M, Kapral S. Ultrasound guidance in regional anaesthesia. *Br J Anaesth* 2005;94:7–17.
25. Luyet C, Eichenberger U, Moriggi B, et al. Real-time visualization of ultrasound-guided retrobulbar blockade: an imaging study. *Br J Anaesth* 2008;101:855–859.
26. Shilo-Benjamini Y, Pascoe PJ, Maggs DJ, et al. Retrobulbar and peribulbar regional techniques in cats: a preliminary study in cadavers. *Vet Anaesth Analg* 2013;40:623–631.
27. Oliver JA, Bradbrook CA. Suspected brainstem anaesthesia following retrobulbar block in a cat. *Vet Ophthalmol* 2013;16:225–228.
28. Binder DR, Herring IP. Duration of corneal anaesthesia following topical administration of 0.5% proparacaine hydrochloride solution in clinically normal cats. *Am J Vet Res* 2006;67:1780–1782.

29. Blocker T, Van Der Woerd A. A comparison of corneal sensitivity between brachycephalic and domestic short-haired cats. *Vet Ophthalmol* 2001;4:127–130.
30. Kroin JS, Buvanendran A, Williams DK, et al. Local anesthetic sciatic nerve block and nerve fiber damage in diabetic rats. *Reg Anesth Pain Med* 2010;35:343–350.
31. Nader A, Kendall MC, Deoliveria GS, et al. Ultrasound-guided trigeminal nerve block via the pterygopalatine fossa: an effective treatment for trigeminal neuralgia and atypical facial pain. *Pain Physician* 2013;16:E537–E545.
32. Samuelson D. Ophthalmic anatomy. In: Gelatt K, ed. *Veterinary ophthalmology*. 4th ed. Oxford, England: Wiley-Blackwell, 2007;37–148.
33. Hudson LC, Hamilton WP. Special sensory organs; part 2: eye. In: Hudson LC, Hamilton WP, eds. *Atlas of feline anatomy for veterinarians*. Philadelphia: WB Saunders Co, 1993;240–251.
34. Alhassan MB, Kyari F, Ejere HOD. Peribulbar versus retrobulbar anaesthesia for cataract surgery (review). *Cochrane Database Syst Rev* 2011;CD004083.
35. Lamont L. Local anesthetics. In: Greene S, ed. *Veterinary anesthesia and pain management secrets*. Philadelphia: Hanley & Belfus Inc, 2002;105–108.
36. Lemke K. Pain management II: local and regional anaesthetic techniques. In: Seymour C, Duke-Novakowski T, eds. *BSAVA manual of canine and feline anaesthesia and analgesia*. Dorset, England: British Small Animal Veterinary Association, 2007;104–114.
37. Beckman B. Regional nerve blocks for oral surgery in companion animals. *Compend Contin Educ Vet* 2002;24:439–444.
38. Dugdale A. Local anesthetic techniques for the head: small animals. In: Dugdale A, ed. *Veterinary anaesthesia: principals to practice*. Oxford, England: Wiley-Blackwell, 2010;123–131.
39. Webb A, Pablo L. Local anesthetics. In: Riviere J, Papich MG, eds. *Veterinary pharmacology and therapeutics*. Ames, Iowa: Wiley-Blackwell, 2009;381–400.
40. Robertson SA, Taylor PM. Pain management in cats—past, present and future. Part 2. Treatment of pain—clinical pharmacology. *J Feline Med Surg* 2004;6:321–333.
41. Lemke KA, Dawson SD. Local and regional anesthesia. *Vet Clin North Am Small Anim Pract* 2000;30:839–857.
42. Gupta PK, Hopkins PM. Effect of concentration of local anaesthetic solution on the ED₅₀ of bupivacaine for supraclavicular brachial plexus block. *Br J Anaesth* 2013;111:293–296.
43. Tariq A, Abdulaziz AA. Effect of bupivacaine concentration on the efficacy of ultrasound-guided interscalene brachial plexus block. *Saudi J Anaesth* 2011;5:190–194.
44. Murphy C, Pollock R. The eye. In: Evans H, ed. *Miller's anatomy of the dog*. 3rd ed. Philadelphia: Saunders, 1993;1009–1057.
45. Wong DH. Regional anaesthesia for intraocular surgery. *Can J Anaesth* 1993;40:635–657.
46. Tan CS, Au Eong KG, Kumar CM. Visual experiences during cataract surgery: what anaesthesia providers should know. *Eur J Anaesthesiol* 2005;22:413–419.
47. Riad W, Tan CS, Kumar CM, et al. What can patients see during glaucoma filtration surgery under peribulbar anesthesia? *J Glaucoma* 2006;15:462–465.
48. Boberg-Ans J. Experience in clinical examination of corneal sensitivity; corneal sensitivity and the naso-lacrimal reflex after retrobulbar anaesthesia. *Br J Ophthalmol* 1955;39:705–726.
49. Rosenberg PH, Heinonen E, Jansson SE, et al. Differential nerve block by bupivacaine and 2-chloroprocaine. An experimental study. *Br J Anaesth* 1980;52:1183–1189.
50. Heavner JE, de Jong RH. Lidocaine blocking concentrations for B- and C-nerve fibers. *Anesthesiology* 1974;40:228–233.
51. Krilis M, Zeldovich A, Garrick R, et al. Vision loss and partial third nerve palsy following contralateral peribulbar anesthesia. *J Cataract Refract Surg* 2013;39:132–133.
52. Schrader WF, Schargus M, Schneider E, et al. Risks and sequelae of scleral perforation during peribulbar or retrobulbar anesthesia. *J Cataract Refract Surg* 2010;36:885–889.
53. Kaushik NC. Orbital haemorrhage following retrobulbar injection. *Indian J Ophthalmol* 1988;36:128–130.
54. Gómez-Arnau JI, Yangüela J, González A, et al. Anaesthesia-related diplopia after cataract surgery. *Br J Anaesth* 2003;90:189–193.
55. Sharma A, Gupta A, Bandyopadhyay S, et al. Necrosis of the eyelids and sclera after retrobulbar anesthesia. *J Cataract Refract Surg* 2003;29:842–844.
56. Kumar CM, Dowd TC. Complications of ophthalmic regional blocks: their treatment and prevention. *Ophthalmologica* 2006;220:73–82.
57. Riad W, Akbar F. Ophthalmic regional blockade complication rate: a single center audit of 33,363 ophthalmic operations. *J Clin Anesth* 2012;24:193–195.
58. Kumar CM. Orbital regional anesthesia: complications and their prevention. *Indian J Ophthalmol* 2006;54:77–84.
59. Moorthy SS, Zaffer R, Rodriguez S, et al. Apnea and seizures following retrobulbar local anesthetic injection. *J Clin Anesth* 2003;15:267–270.
60. Chang JL, Gonzalez-Abola E, Larson CE, et al. Brain stem anesthesia following retrobulbar block. *Anesthesiology* 1984;61:789–790.
61. El Said TM, Kabeel MM. Comparison of classic peribulbar anesthesia and new entry point (single percutaneous injection technique) in vitreoretinal surgery. *Saudi J Anaesth* 2010;4:80–85.
62. Bowman R, Liu C, Sarkies N. Intraocular pressure changes after peribulbar injections with and without ocular compression. *Br J Ophthalmol* 1996;80:394–397.
63. O'Donoghue E, Batterbury M, Lavy T. Effect on intraocular pressure of local anaesthesia in eyes undergoing intraocular surgery. *Br J Ophthalmol* 1994;78:605–607.
64. Bui BV, Batcha AH, Fletcher E, et al. Relationship between the magnitude of intraocular pressure during an episode of acute elevation and retinal damage four weeks later in rats. *PLoS ONE* [serial online] 2013;8:e70513. Available at: www.plosone.org/article/info%3Adoi%2F10.1371%2Fjournal.pone.0070513. Accessed Jun 2, 2014.