

UC Davis

UC Davis Previously Published Works

Title

Fragile X syndrome in a girl with variant Turner syndrome and an isodicentric X chromosome

Permalink

<https://escholarship.org/uc/item/3fm4p5z3>

Journal

BMJ Case Reports, 15(7)

ISSN

1757-790X

Authors

Tassanakijpanich, Nattaporn

Wright, Rachel

Tassone, Flora

et al.

Publication Date

2022-07-01

DOI

10.1136/bcr-2021-247901

Peer reviewed

Fragile X syndrome in a girl with variant Turner syndrome and an isodicentric X chromosome

Nattaporn Tassanakijpanich ^{1,2}, Rachel Wright,³ Flora Tassone,^{2,4} Suma P Shankar,^{2,5} Randi Hagerman^{2,5}

¹Pediatrics, Faculty of Medicine, Prince of Songkla University, Hat Yai, Songkhla, Thailand

²UC Davis MIND Institute, UC Davis Health, Sacramento, California, USA

³Biology, Texas A&M University, College Station, Texas, USA

⁴Biochemistry and Molecular Medicine, UC Davis, School of Medicine, Davis, California, USA

⁵Pediatrics, UC Davis, School of Medicine, Sacramento, California, USA

Correspondence to

Dr Randi Hagerman; rjhagerman@ucdavis.edu

Accepted 7 June 2022

SUMMARY

Fragile X (FXS) and Turner (TS) syndromes are X-chromosome-associated disorders. Herein, we report the case of a girl in middle childhood with bicuspid aortic valve in infancy, growth failure, global developmental delay (GDD), visual problems, and coexisting attention-deficit/hyperactivity and anxiety disorders. A high-resolution karyotype in 20 cells revealed 46,X,Idic(X)(p11.21)[19]/45,X[1], suggestive of variant TS. Given her atypical phenotype, subsequent DNA testing was performed. Four *FMR1* cytosine-guanine-guanine repeats (30, 410, 580 and 800) were identified, confirming the additional FXS diagnosis. This case study highlights the importance of additional genetic testing in individuals with atypical variant TS, such as unexplained GDD and distinct facial characteristics. The additional FXS diagnosis prompted new therapeutic development for the patient to advance precision healthcare.

BACKGROUND

Fragile X syndrome (FXS; [MIM: #300624]) is the most common monogenic disorder that causes intellectual disability (ID) and autism spectrum disorder (ASD). Its overall prevalence is estimated at 1 in 7143 males and 1 in 11111 females.¹ In people with ASD, FXS prevalence is approximately 1%–3%.² The fragile X mental retardation 1 (*FMR1*) gene located at Xq27.3 is hypermethylated and silenced when the cytosine-guanine-guanine (CGG) repeat exceeds 200 in the promotor region, leading to deficiency of fragile X mental retardation 1 protein (FMRP). FXS phenotypic hallmarks include an elongated face, prominent ears and macro-orchidism, which begins during puberty in males.³ The majority of patients with FXS have ID, ASD, language deficits, attention-deficit/hyperactivity disorder (ADHD) and anxiety.³ DNA testing for FXS is recommended in all children with global developmental delay (GDD), ID or ASD of unknown causes.⁴

Turner syndrome (TS), caused by a partial or complete loss of an X chromosome, generally occurs at 1 in 2000 females.⁵ Females with TS often present with 45 XO (or mosaicism), isochromosome or ring X chromosome.⁶ Classic TS features include growth failure, congenital heart defects, webbed and short neck, and hypergonadotropic hypogonadism.⁶ TS phenotypes depend on the deleted X chromosome regions, such as isochromosome Xq and isodicentric Xp, which are mostly caused by sporadic exchange between sister chromatids during meiotic phase,⁸ leading

to PAR1 haploinsufficiency, skeletal abnormalities and growth failure.¹⁰ Postnatal karyotype, which detects almost all TS variants,¹⁰ is a reasonable test for females with suspected TS presentation.⁴

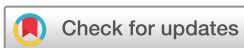FXS and TS are derived from X chromosome abnormalities. *FMR1* full mutation on the X chromosome, particularly in maternal-derived cells, is rarely associated with the loss of X chromosome loss during mitotic phases that causes mosaic TS.¹² To date, only one FXS case with isodicentric Xp in a 19-year-old woman exists.¹³ This patient presented with GDD, ADHD, anxiety, sensory hyper-responsiveness and FXS facial characteristics, and had recurrent otitis media infections and strabismus. Her physical growth and pubertal development were normal except for mesomelic limb shortness, bilateral Madelung deformity, and shortness of radial, ulnar, fourth and fifth metacarpal bones. Her genotype was 46, fra(X)(q27.3), idic(X)(p21.3)[81]/45, fra(X)(q27.3)[5]. Here, we present a second FXS case with isodicentric Xp.

CASE PRESENTATION

A girl in middle childhood was born full-term to a woman in her 20s (G3P2) via caesarean section with 14.5th percentile birth weight (2770 g), 26.8th percentile length (48 cm) and 15.9th percentile head circumference (32.7 cm). Pregnancy was significant for intrauterine growth retardation and abnormal fetal echocardiogram findings. Trivial patent ductus arteriosus and bicuspid aortic valve were confirmed at birth. She had Marcus-Gunn jaw winking phenomenon, hyperopia with astigmatism, high-arched palate with submucous cleft and an umbilical hernia. She was hospitalised for a week with episodes of hypoglycaemia and jaundice, which resolved with glucose infusions and phototherapy.

Her growth failure manifested with swallowing difficulty, requiring nasogastric feeding during the first year of life. Recurrent otitis media and sinus infections were persistent during the first 5 years of life. Thyroid function and hearing test results were normal. Renal ultrasound showed a duplicated right intrarenal collecting system with normal ureter and kidney function.

A review of developmental milestones showed delayed skill acquisition in all domains. The patient was able to sit, crawl, and walk at 10 months, 18 months, and 2 years and 8 months, respectively. She started speaking at 3 years 7 months and began saying three-word phrases at 4 years. Sensory issues were reported, including hyper-responsiveness to



© BMJ Publishing Group Limited 2022. No commercial re-use. See rights and permissions. Published by BMJ.

To cite: Tassanakijpanich N, Wright R, Tassone F, et al. *BMJ Case Rep* 2022;**15**:e247901. doi:10.1136/bcr-2021-247901

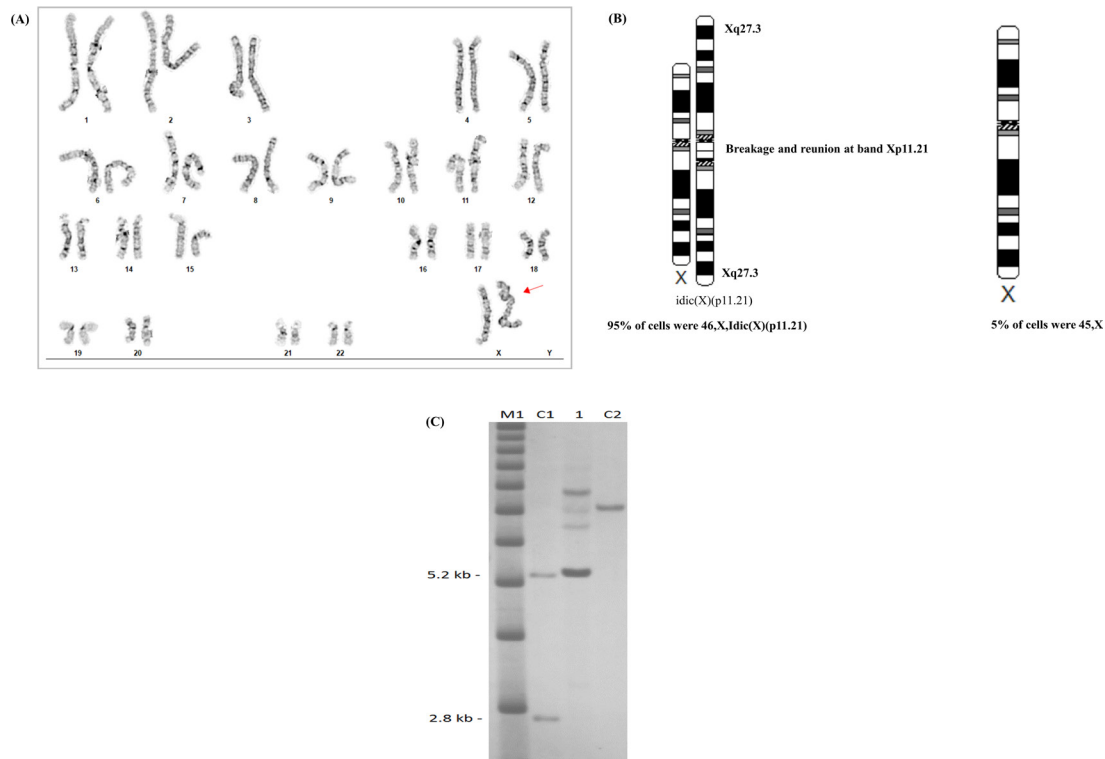


Figure 1 (A) Karyotype showing 46,X,Idic(X)(p11.21) in 95% of cells. (B) Summarised genetic findings.²⁰ (C) Southern blot analysis of genomic DNA isolated from normal control female (C1), from a full-mutation male positive control (C2) and from the proband (1). The proband shows three methylated full-mutation bands of approximately 410, 580, 800 CGG repeats and a normal allele of 30 CGG repeats, sized by PCR, which appears completely methylated, likely due to a skewed X inactivation. The DNA marker, 1 kb ladder, is shown in M1. Normal unmethylated (2.8 kb) and methylated (5.2 kb) bands in a female are shown on the left. CGG, cytosine-guanine-guanine.

lights, loud noises, crowded areas and preference to specific textures.

During physical examination, the patient had good eye contact and reciprocal conversation. However, her speech was delayed with frequent tongue protrusion. She was mildly anxious and hyperactive. She had a 5.8th percentile weight (17.6 kg), 12.9th percentile height (113 cm), 50th percentile head circumference (51 cm), blood pressure of 95/65 mm Hg and pulse rate of 116 beats/min. She had a long face with dolichocephaly, broad forehead, down-slanting palpebral fissures with mild left exotropia, prominent cupping ears, and mild prominent front teeth. Her finger joints were hyperextensible with moderate pronation of both feet and pes planus. No scoliosis was found. Her skin was very soft. Her neurological examination was intact.

A three-generation pedigree was reviewed. Her siblings were typically developing children without a fragile X mutation. Her mother has a premutation allele of 90 CGG repeats on the *FMR1* gene.

INVESTIGATIONS

High-resolution karyotyping (575 GTG-banding, band resolution) revealed 46,X,Idic(X)(p11.21)[19]/45,X[1] (figure 1A,B). This result was confirmed on expanded fluorescence in situ hybridisation using X centromere probes, demonstrating a two-cell-line mosaicism. The first cell line showed three centromeres, consistent with one normal and one isodicentric X chromosome in 95% of the cells (210 of 220), while the remaining cells showed a monosomy X pattern. No evidence of the *SRY* gene was found.

Further, a chromosome microarray revealed a copy number loss of all probes in the Xp22.33p11.22 and a gain of the

Xp11.22q28 (figure 1B). In early childhood, PCR and Southern blot analysis, the gold standard assays for FXS, were conducted since her ID was inconsistent with variant TS alone. Four *FMR1* alleles of 30, 410, 580 and 800 CGG repeats were identified (figure 1C).

Her FMRP expression in lymphocytes was 0.07 ± 0.02 (relative to 1, the normalised CGG repeats in controls). This very low expression is typical for males in the full mutation range.¹⁴ FMRP expression in females varies by the activation ratio (AR). Interestingly, a very skewed AR was observed in this case where the normal allele appears mostly methylated (figure 1C); thus, it was not transcriptionally or translationally active. This could explain the very low levels of *FMR1* mRNA, (0.08 ± 0.03 relative to normal controls) and FMRP.

TREATMENT

The patient attended a kindergarten-level inclusion programme while receiving comprehensive interventions. However, her cognitive performance was not measured due to interfering behavioural issues, including anxiety, hyperactivity and impulsivity. Previous medications, including fluoxetine, dexamethylphenidate hydrochloride, sertraline and guanfacine, showed minimal improvement and were discontinued. She was taking cannabidiol for her anxiety and aripiprazole, and has recently started metformin, a targeted FXS treatment,¹⁵ which shows a positive improvement in her pretend play.

OUTCOME AND FOLLOW-UP

Because of COVID-19 and travel distance to our clinic, in-person follow-up was not possible. Phone follow-up after 1 year revealed

that metformin, gradually increased to 500 mg two times per day, was well tolerated. Her mother initially observed behavioural improvement. While aripiprazole, 2 mg two times per day, has also been well tolerated, fluoxetine, 10 mg a day, increased her aggression and was halved.

DISCUSSION

This is the second case of FXS combined with isodicentric X chromosome causing a variant of TS with atypical features, which could not be explained by either TS or FXS alone. This patient had a bicuspid aortic valve and growth failure, which is uncommon in females with FXS but typical of TS.¹⁶ The patient in our study did not have typical skeletal anomalies in TS, although such anomalies are frequently found in TS with small Xp deletion.¹⁷ She had more severe cognitive deficits than other children with TS; although 10% of individuals with TS have ID, it is mostly found in those with a ring chromosome and a marker chromosome.¹⁰ Her distinct long face, prominent ears and sensory processing problems are more common in FXS.^{3 16} Her cognitive deficits and clinical features could be explained by the combination of variant TS and FXS with low FMRP expression.^{14 18 19}

Recognising that her daughter's problems were more severe than just TS, the patient's mother requested additional genetic testing that led to the diagnosis of FXS. Unfortunately, parents, rather than professional figures, are still too frequently the ones to recognise when a previous diagnosis is inadequate. This diagnosis is important for both the patient and their family members with the premutation because health problems can occur, particularly in older carriers, including those with fragile X-associated tremor ataxia syndrome, fragile X-associated primary ovarian insufficiency and fragile X-associated neuropsychiatric disorders.³ Additionally, FXS diagnosis in our patient offered novel therapeutic options, such as metformin, which downregulates the mammalian target of rapamycin pathway that is upregulated in FXS.¹⁵

This case highlights the importance of a comprehensive evaluation in children with developmental delay. Additional genetic testing should be implemented on presentation of atypical clinical features, unexplained by a single genetic disorder. This is of crucial value to advance precision healthcare with new targeted treatments and identify heritable risk with potential for recurrence risk in the family.

Learning points

- ▶ The rare co-occurrence of fragile X syndrome (FXS) and Turner syndrome should be considered in light of suspected clinical presentation.
- ▶ Accurate diagnosis is necessary for both syndromes, which require specific care.
- ▶ Besides karyotyping and chromosome microarray, DNA testing for FXS is recommended in children with global developmental delay, intellectual disability or autism spectrum disorder of unknown causes.

Acknowledgements We thank the family for their cooperation and contributions to this report, Ma Florita B Yambao-Dela Cruz for editing the first draft of this manuscript, Guadalupe Mendoza for conducting the fragile X DNA testing and Professor Paul Hagerman for providing the molecular result and interpretation.

Contributors NT and RH drafted the manuscript. NT, RH, RW, FT and SS made substantial contributions to the conception of the work, data acquisition, data interpretation, critical revisions and approval of the submitted version of the manuscript.

Funding This study was funded by the Eunice Kennedy Shriver National Institute of Child Health and Human Development (HD036071); the Azrieli Foundation; the National Center for Advancing Translational Sciences and National Institutes of Health (UL1 TR001860); and the MIND Institute Intellectual and Developmental Disabilities Research Center (U54 HD079125).

Competing interests RH is funded by the Azrieli Foundation for a controlled trial of metformin in FXS. FT received funding from the Azrieli Foundation and from Zynerva for studies in FXS. SS holds the Children's Miracle Network endowed chair in paediatrics and receives grant support from it. The other authors declare that they have no competing interests.

Patient consent for publication Parental/guardian consent obtained.

Provenance and peer review Not commissioned; externally peer reviewed.

Case reports provide a valuable learning resource for the scientific community and can indicate areas of interest for future research. They should not be used in isolation to guide treatment choices or public health policy.

ORCID iD

Nattaporn Tassanakijpanich <http://orcid.org/0000-0002-9888-0565>

REFERENCES

- 1 Hunter J, Rivero-Arias O, Angelov A, *et al*. Epidemiology of fragile X syndrome: a systematic review and meta-analysis. *Am J Med Genet A* 2014;164A:1648–58.
- 2 Harris HK, Sideridis GD, Barbaresi WJ, *et al*. Pathogenic yield of genetic testing in autism spectrum disorder. *Pediatrics* 2020;146:e20193211.
- 3 Rajaratnam A, Shergill J, Salcedo-Arellano M, *et al*. Fragile X syndrome and fragile X-associated disorders. *F1000Res* 2017;6:2112.
- 4 Moeschler JB, Shevell M, Committee on Genetics. Comprehensive evaluation of the child with intellectual disability or global developmental delays. *Pediatrics* 2014;134:e903–18.
- 5 Nielsen J, Wohler M. Chromosome abnormalities found among 34,910 newborn children: results from a 13-year incidence study in Aarhus, Denmark. *Hum Genet* 1991;87:81–3.
- 6 Gravholt CH, Viuff MH, Brun S, *et al*. Turner syndrome: mechanisms and management. *Nat Rev Endocrinol* 2019;15:601–14.
- 7 Hong DS, Reiss AL. Cognitive and neurological aspects of sex chromosome aneuploidies. *Lancet Neurol* 2014;13:306–18.
- 8 James RS, Dalton P, Gustashaw K, *et al*. Molecular characterization of isochromosomes of Xq. *Ann Hum Genet* 1997;61:485–90.
- 9 Scott SA, Cohen N, Brandt T, *et al*. Large inverted repeats within Xp11.2 are present at the breakpoints of isodicentric X chromosomes in Turner syndrome. *Hum Mol Genet* 2010;19:3383–93.
- 10 Sybert VP, McCauley E. Turner's syndrome. *N Engl J Med* 2004;351:1227–38.
- 11 Rao E, Weiss B, Fukami M, *et al*. Pseudoautosomal deletions encompassing a novel homeobox gene cause growth failure in idiopathic short stature and Turner syndrome. *Nat Genet* 1997;16:54–63.
- 12 Dobkin C, Radu G, Ding X-H, *et al*. Fragile X prenatal analyses show full mutation females at high risk for mosaic Turner syndrome: fragile X leads to chromosome loss. *Am J Med Genet A* 2009;149A:2152–7.
- 13 Freedenberg DL, Gane LW, Richards CS, *et al*. Fragile X syndrome and an isodicentric X chromosome in a woman with multiple anomalies, developmental delay, and normal pubertal development. *Am J Med Genet* 1999;85:197–201.
- 14 Kim K, Hessler D, Randol JL, *et al*. Association between IQ and FMR1 protein (FMRP) across the spectrum of CGG repeat expansions. *PLoS One* 2019;14:e0226811.
- 15 Dy ABC, Tassone F, Eldeeb M, *et al*. Metformin as targeted treatment in fragile X syndrome. *Clin Genet* 2018;93:216–22.
- 16 Hagerman RJ, Jackson C, Amiri K, *et al*. Girls with fragile X syndrome: physical and neurocognitive status and outcome. *Pediatrics* 1992;89:395–400.
- 17 Ogata T, Muroya K, Matsuo N, *et al*. Turner syndrome and XP deletions: clinical and molecular studies in 47 patients. *J Clin Endocrinol Metab* 2001;86:5498–508.
- 18 Loesch DZ, Huggins RM, Hagerman RJ. Phenotypic variation and FMRP levels in fragile X. *Ment Retard Dev Disabil Res Rev* 2004;10:31–41.
- 19 Loesch DZ, Huggins RM, Bui QM, *et al*. Relationship of deficits of FMR1 gene specific protein with physical phenotype of fragile X males and females in pedigrees: a new perspective. *Am J Med Genet A* 2003;118A:127–34.
- 20 Hiller B, Bradtke J, Balz H, *et al*. CyDAS: a cytogenetic data analysis system. *Bioinformatics* 2005;21:1282–3.

Copyright 2022 BMJ Publishing Group. All rights reserved. For permission to reuse any of this content visit <https://www.bmj.com/company/products-services/rights-and-licensing/permissions/>
BMJ Case Report Fellows may re-use this article for personal use and teaching without any further permission.

Become a Fellow of BMJ Case Reports today and you can:

- ▶ Submit as many cases as you like
- ▶ Enjoy fast sympathetic peer review and rapid publication of accepted articles
- ▶ Access all the published articles
- ▶ Re-use any of the published material for personal use and teaching without further permission

Customer Service

If you have any further queries about your subscription, please contact our customer services team on +44 (0) 207111 1105 or via email at support@bmj.com.

Visit casereports.bmj.com for more articles like this and to become a Fellow