

UC Irvine

UC Irvine Previously Published Works

Title

Preoperative Measurement of Cartilage Defects by MRI Underestimates Lesion Size

Permalink

<https://escholarship.org/uc/item/3gp9n07x>

Journal

Cartilage, 2(4)

ISSN

1947-6035

Authors

Gomoll, Andreas H
Yoshioka, Hiroshi
Watanabe, Atsuya
et al.

Publication Date

2011-10-01

DOI

10.1177/1947603510397534

Copyright Information

This work is made available under the terms of a Creative Commons Attribution License, available at <https://creativecommons.org/licenses/by/4.0/>

Peer reviewed

Preoperative Measurement of Cartilage Defects by MRI Underestimates Lesion Size

Cartilage
2(4) 389–393
© The Author(s) 2011
Reprints and permission:
sagepub.com/journalsPermissions.nav
DOI: 10.1177/1947603510397534
http://cart.sagepub.com


Andreas H. Gomoll¹, Hiroshi Yoshioka², Atsuya Watanabe³,
John C. Dunn¹, and Tom Minas¹

Abstract

Objective: Anecdotal evidence suggests that MRI frequently underestimates the size of cartilage defects when compared with final lesion size after debridement of all degenerated tissue. This has potential implications for the choice of cartilage repair technique since most treatment algorithms are primarily driven by defect size. We conducted an investigation comparing size estimates based on preoperative MRI with final defect size after debridement. Our aim was to provide surgeons with more objective data to assist in predicting true defect size based on MRI scanning. **Design:** Patients were included in this retrospective study if they had undergone preoperative MRI and open cartilage repair within 12 months to minimize potential confounding by defect progression on MRI. Defect sizes measured after debridement were obtained from surgical notes and compared with MRI size estimates by 2 musculoskeletal radiologists. **Results:** Thirty-eight patients were enrolled with a median age of 37 years, median number of 1.7 defects, and a total median defect area of 6 cm² per knee. Preoperative MRI scanning had predicted a median defect area of 3.6 cm². This reflected a difference of 65% ($P < 0.001$) between MRI and final defect area after debridement when 85% of all individual defects were larger than predicted by preoperative MRI. **Conclusions:** Our study compared the size of cartilage defects measured by preoperative MRI with surgical measurements after debridement. On average, the final total defect area per knee was 65% larger than estimated preoperatively by MRI. Individual defects were larger than predicted by 47% to 377%, depending on defect location.

Keywords

magnetic resonance imaging, diagnostics, knee, joint involved, cartilage repair, repair

Introduction

The noninvasive evaluation of cartilage defects is evolving as better MRI scanners and cartilage-specific sequences are being introduced into clinical practice.^{1,2} However, while the zone of full-thickness cartilage loss is easily measured by MRI (**Fig. 1**), most defects are surrounded by an area of degenerated or fissured cartilage that is less easily quantified. Anecdotal evidence suggests that the final defect size after thorough debridement of this surrounding, degenerated cartilage is often substantially larger than predicted by preoperative MRI (**Fig. 2**), leading to underestimation of defect size.³

This underestimation of true defect size has the potential to compromise cartilage repair in a number of ways: first and foremost, treatment algorithms in cartilage repair are primarily driven by defect size since most procedures have upper size recommendations, beyond which outcomes worsen. Microfracture, for example, has been shown to

provide predictable results in femoral condyle lesions of less than 3 to 4 cm²; larger lesions show significantly worse outcomes.^{4,5} Osteochondral autograft transfer has been recommended for lesions of 1 to 4 cm²,^{6,7} since larger lesion size requires harvesting of multiple plugs, increasing the potential for donor site morbidity. Osteochondral allograft transplantation and autologous chondrocyte implantation (ACI), on the other hand, are primarily indicated for lesions larger than 3 to 4 cm² since the increased morbidity and cost of these procedures make them difficult to justify for

¹Brigham and Women's Hospital, Boston, MA, USA

²University of California Irvine, Orange, CA, USA

³Teikyo University Chiba Medical Center, Chiba, Japan

Corresponding Author:

Andreas H. Gomoll, Department of Orthopaedic Surgery, Cartilage Repair Center, Brigham and Women's Hospital, Harvard Medical School, 850 Boylston Street, Suite 112, Chestnut Hill, MA 02467
Email: agomoll@partners.org

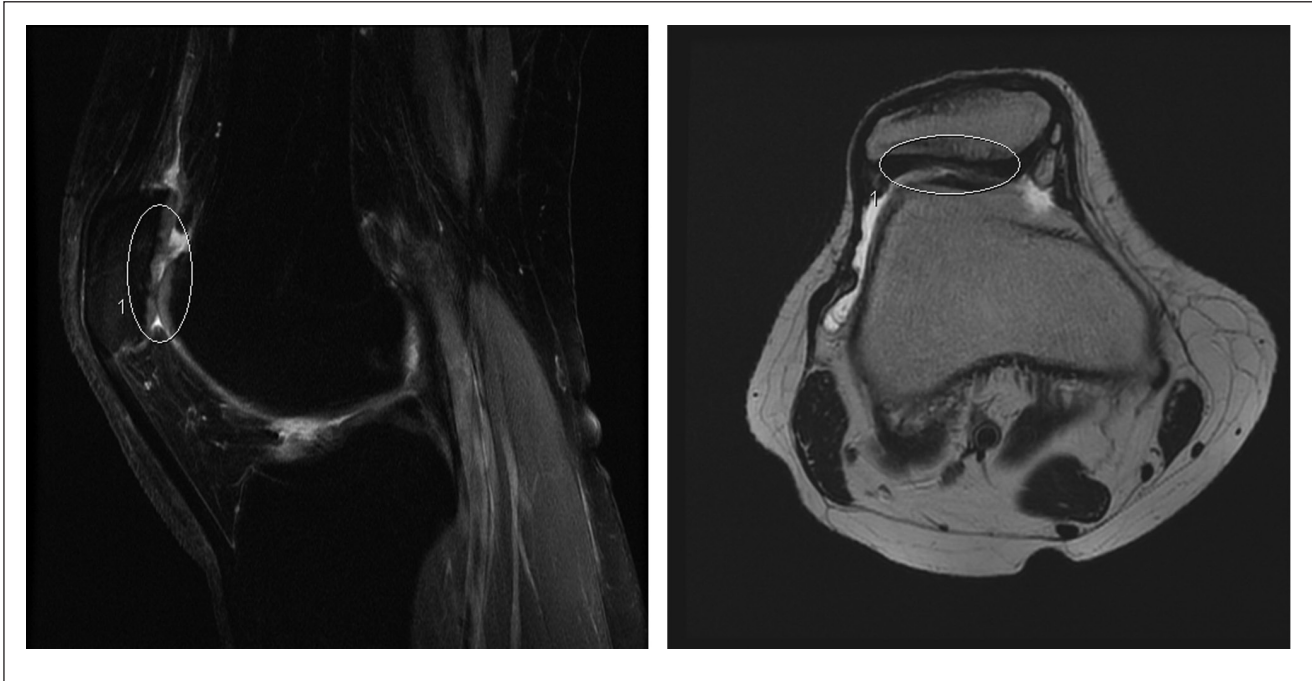


Figure 1. Preoperative MRI scan of patellar defect, measured by radiology as 14 mm × 9 mm (1.3 cm²). Fast spin echo, fat-suppressed proton density sagittal image (left), and fast spin echo axial image (right). The defect areas are outlined.

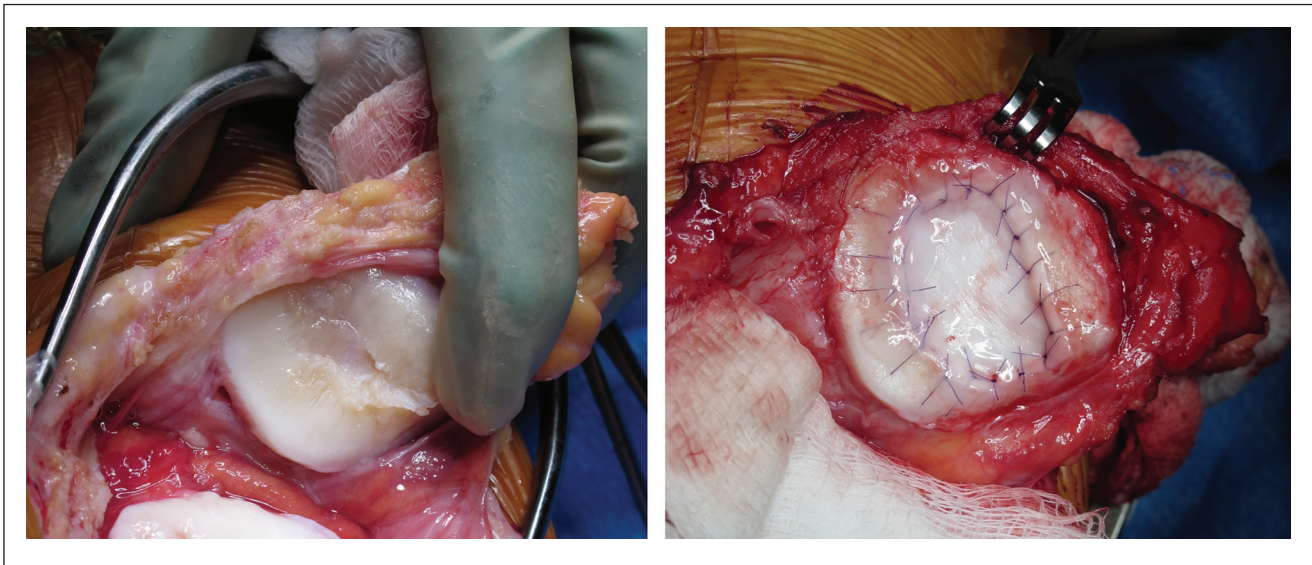


Figure 2. Intraoperative view before (left) and after (right) treatment with ACI, measured as 25 mm × 20 mm (5 cm²).

smaller lesions where less invasive and expensive alternatives exist. Correctly predicting lesion size is therefore crucial to correctly select the most appropriate and efficacious treatment option.

Furthermore, underestimating lesion size has potential implications for several next-generation cartilage repair technologies. Many of these procedures have product-specific size limitations, ranging from 2.5 cm² to 20 cm²,

potentially creating a situation where the defect after debridement exceeds the size of the available implant, leaving the surgeon with inadequate product to fill the defect.

Given the expected increase in the use of next-generation cartilage repair technologies with size limitations and the option of single-stage implantation, it appears desirable to provide surgeons with objective, quantitative information on the correlation between preoperative MRI and final

defect size after thorough debridement. We therefore conducted an investigation comparing size estimates from preoperative MRI with final defect size at the time of cartilage repair, with the hypothesis that MRI would underestimate defect size.

Methods

All data were obtained from our institution's cartilage repair database, which received approval by the Institutional Review Board (IRB) at its inception in 1995. All patients provided written consent to be included in the database and subsequently underwent cartilage repair by the senior author. Patients were considered for inclusion into this retrospective study if they were treated with a cartilage repair procedure that was performed through arthrotomy since open surgery was felt to allow the most accurate debridement and size measurement: arthrotomy enables the surgeon to more thoroughly inspect the defect from multiple angles and continuously evaluate cartilage softness and consistency throughout the debridement process until healthy margins have been established. Autologous chondrocyte implantation (ACI) fulfilled this requirement, while osteochondral autograft or allograft transfer procedures were excluded since the recipient area is not usually debrided but rather removed with a circular punch or reamer; therefore, no information on lesion, opposed to implant, size was available.

Furthermore, we required that patients had undergone their entire diagnostic and surgical treatment at our facility within 12 months to minimize the potential for confounding through interval progression of the defect(s); external imaging was an exclusion criterion to ensure consistent imaging protocols. Specifically, the preoperative intravenous gadolinium-enhanced MRI was performed on a 1.5-T MRI unit (Signa, GE Healthcare, Milwaukee, WI) by using a standard GE transmit-receive knee coil with a consistent protocol utilizing proton density, fast spin echo proton density with fat saturation, and T2-weighted fat-saturated images. Patients were injected with the intravenous (IV) contrast (Magnevist, Bayer Schering Pharma, Germany) and then asked to exercise their knee joint for 20 minutes by walking prior to image acquisition. The in-plane resolution ranged from 0.63×0.83 mm and 0.27×0.55 mm depending on matrix size with a slice thickness of 3.5 to 4 mm. Views were obtained in the sagittal, coronal, and axial planes, as well as in the oblique trochlear plane.

For the purpose of this study, all MRI scans were independently re-reviewed by 2 experienced musculoskeletal radiologists specializing in cartilage imaging (5 and 14 years of experience) who were blinded to the original MRI reports and the defect sizes measured during surgery, as well as to each other's findings. Defect sizes were measured in 2 dimensions (superior to inferior and medial to

lateral). All areas of greater than 50% cartilage thinning were considered defect area. Intraoperatively, defect sizes were consistently measured after thorough debridement of all surrounding degenerated cartilage (more than ICRS grade 1) with a ruler in 2 dimensions (superior to inferior and medial to lateral). All procedures were performed by a single surgeon with 15 years of experience in cartilage repair and over 600 ACI procedures performed.

Statistical Evaluation

Results from the 2 radiologists were compared with the Pearson test to determine the correlation coefficient. Subsequently, each reader's results were averaged for each defect and used as the baseline MRI defect sizes. These were then compared with defect sizes obtained from surgical notes. Significance between groups was evaluated by a paired *t* test with a level of statistical significance set at $P < 0.05$.

Results

A total of 38 patients fulfilled the inclusion criteria. There were 23 men and 15 women with an average age of 37 years (range, 18-55 years) at the time of implantation. There was an average of 1.7 defects per patient and a total of 66 defects: 36 defects of the condyles, 17 of the trochlea, and 13 of the patella. Preoperative MRI scanning demonstrated a median total defect area per knee of 3.6 cm^2 . The Pearson coefficient of correlation assessing interobserver reliability measured 0.77 for lesions in the lateral femoral condyle, 0.83 for lesions in the medial femoral condyle, and 0.98 for lesions in the patella and trochlea. The median interval between preoperative MRI and cartilage repair was 6.5 months (range, 1 week to 12 months). Surgical measurements demonstrated a median total defect area per knee of 6.0 cm^2 after debridement. Overall, median defect area was larger by 65% ($P < 0.001$) between MRI scan and final defect size at implantation. Evaluation of defects by individual location demonstrated differences of median defect sizes between MRI and cartilage repair of 64% and 55% in the medial and lateral femoral condyles, respectively, 47% in the trochlea, and 377% in the patella (**Table 1**). After debridement, 85% of all individual defects were larger than predicted by preoperative MRI. Of the remaining 15%, half were accurately predicted (within 10% of final size), while the other half were overestimated by a median of 41% (range, 16%-100%).

Discussion

Our study compared the size of cartilage defects measured preoperatively by high-resolution MRI with surgical measurements by a single, experienced cartilage surgeon. Even

Table 1. Defect Sizes by Location

	Medial Femoral Condyle	Lateral Femoral Condyle	Trochlea	Patella
Number	24	12	17	13
MRI size	2.7 (1.8, 0.2-7.8)	3.9 (3.3, 0.5-9.3)	2.0 (1.6, 0.5-7.1)	0.6 (1.4, 0.2-4.8)
Surgical size	4.4 (1.7, 2.4-10)	6.0 (2.3, 1.0-9.3)	3.0 (2.1, 0.8-8.8)	3.0 (1.7, 1.0-7.0)
% difference	64%	55%	47%	377%
P value	0.001	0.05	0.002	0.004

Note: Shown as median (standard deviation, range).

when images are interpreted by accomplished musculoskeletal radiologists specializing in cartilage imaging and obtained utilizing high-quality MRI systems with cartilage-specific acquisitions, the majority of defects were underestimated, with the final defect area at implantation being over 60% larger than predicted by preoperative imaging.

Little is known about the predictive accuracy of MRI scanning in regard to cartilage defect size.^{8,9} These studies evaluated artificially created defects in cadaveric knees with 3-dimensional MRI mapping, finding good correlation between actual defect size and MRI size estimates only with full-thickness defects and special sequences. In clinical practice, however, cartilage damage usually extends beyond the area of the full-thickness component of the defect, which is surrounded by a zone of fissured, degenerated, or delaminated cartilage that is debrided during the surgical repair. Even though MRI has made progress in the detection of such non-full-thickness damage, the present study demonstrated the difficulty of accurately predicting the true extent of damage.

Our study demonstrated consistent underestimation of defect sizes in all locations by MRI, with final defect sizes being larger than predicted by 64% and 55% for medial and lateral femoral condyle lesions, respectively. Trochlear lesions were larger by 44%, while patellar defects were larger by a surprising 377%, increasing from 0.6 cm² to 3 cm² on average. The large discrepancy for the latter location can be explained by the commonly encountered clinical scenario of a small area of full-thickness damage seen on MRI, which is surrounded by a very large zone of severely fissured, softened, and delaminated cartilage that is also debrided during surgery, vastly increasing the size of the defect. Overall, the median total defect area was larger by 65% when comparing final defect size with preoperative MRI ($P < 0.001$).

The main limitation of our study lies in the subjective nature of size measurements. While we attempted to minimize these effects through the use of 2 independent radiologists, we were unable to do so for the surgical measurements. Even though intraoperative tools are available to determine certain objective qualities of cartilage, such as stiffness, there is no consensus on threshold levels between "normal" and "abnormal" cartilage. Therefore, the

decision of how much of the non-full-thickness, yet degenerated, surrounding cartilage to debride remains with the surgeon. In this study, all cartilage with changes more severe than ICRS grade 1 was debrided. Obviously, less aggressive debridement of the surrounding degenerated cartilage would have resulted in final defect sizes closer to the MRI estimates. However, there is a consensus among cartilage surgeons that more aggressive treatment of degenerated cartilage appears to decrease the risk of progression of disease, that is, the subsequent development of additional full-thickness damage adjacent to and surrounding a successfully repaired cartilage defect. An additional limitation lies in the potential for defect progression between preoperative imaging and surgical intervention. We attempted to minimize this confounding factor by enrolling only patients with less than 12 months' (average, 6.6 months) delay between MRI and cartilage repair. Several MRI-based studies have investigated progressive cartilage loss over time, reporting estimated losses of cartilage volume between 0.4% and 4.2% per year.¹⁰⁻¹² Based on these studies, a maximum 12 months' delay between MRI and surgery was felt to introduce an acceptably small degree of confounding. Lastly, MRI measurements included all areas with greater than 50% cartilage thinning. However, areas of signal alteration without thinning were excluded since no objective threshold could be defined as to what level of signal abnormality would be considered "defect" versus "normal."

The field of cartilage imaging continues to evolve, bringing about newer, more accurate cartilage-specific sequences every year, including techniques that can provide quantitative information about the biochemical status of the cartilage tissue, such as dGEMRIC (delayed gadolinium-enhanced MRI of cartilage), T1-rho, and T2-mapping.¹ The utilization of these techniques will likely improve the predictive accuracy of preoperative MRI above that presented in this article, where standard techniques were utilized that are most commonly used in current clinical practice. The above-mentioned developing techniques are not widely available at this time outside dedicated centers, but several reports indicate that they might indeed improve the detection of not only full-thickness defects but also better delineate the surrounding zone of damaged cartilage.^{13,14}

Additional studies will be required that correlate these techniques with intraoperative findings.

Our findings have 2 implications for cartilage repair: first, defect size is the primary determining factor for the choice of what cartilage repair technique to use, such as microfracture, osteochondral autograft transfer, ACI, or osteochondral allograft. For example, if preoperative MRI predicts a 4-cm² cartilage defect of the medial femoral condyle, many surgeons would consider treatment with microfracture. If, however, as suggested by our study, this defect in reality measured 6.5 cm² (a 64% size increase, which is an average for this location per our results), surgeons might choose a different technique, such as ACI or osteochondral allograft.

Secondly, certain evolving techniques for cartilage repair are size sensitive. For example, products utilizing minced cartilage allograft or autograft, as well as second- and third-generation membrane-associated ACI techniques, have size limits ranging from 2.5 cm² to 20 cm². Underestimating defect size, particularly a concern for techniques that do not require a staging arthroscopy, can potentially compromise the outcome of surgery if too little product is available to cover the debrided defect area.

In conclusion, orthopedic surgeons should take these findings into consideration when faced with defects that are borderline in size for a specific repair technique or technology. While evolving single-stage technologies are desirable to minimize patient morbidity, reliance on preoperative MRI scans alone can potentially compromise treatment decisions because of the potential for underestimation of defect size. Therefore, a healthy margin of error should be added to defect size estimates obtained from preoperative MRI scans. New MRI sequences are currently being developed that may improve the future accuracy of preoperative scanning.

Acknowledgments and Funding

The investigation was performed at the Department of Orthopedic Surgery, Cartilage Repair Center, Brigham and Women's Hospital, Harvard Medical School, Boston, Massachusetts. The authors received no financial support for the research and/or authorship of this article.

Declaration of Conflicting Interests

AHG and TM have potential conflicts of interest (consulting) with Genzyme BioSurgery, Cambridge, MA.

References

- Potter HG, Chong le R. Magnetic resonance imaging assessment of chondral lesions and repair. *J Bone Joint Surg Am*. 2009;91 Suppl 1:126-31.
- Yoshioka H, Stevens K, Hargreaves BA, Steines D, Genovese M, Dillingham MF, *et al*. Magnetic resonance imaging of articular cartilage of the knee: comparison between fat-suppressed three-dimensional SPGR imaging, fat-suppressed FSE imaging, and fat-suppressed three-dimensional DEFT imaging, and correlation with arthroscopy. *J Magn Reson Imaging*. 2004;20:857-64.
- Azer NM, Winalski CS, Minas T. MR imaging for surgical planning and postoperative assessment in early osteoarthritis. *Radiol Clin North Am*. 2004;42:43-60.
- Knutsen G, Engebretsen L, Ludvigsen TC, Drogset JO, Grontvedt T, Solheim E, *et al*. Autologous chondrocyte implantation compared with microfracture in the knee: a randomized trial. *J Bone Joint Surg Am*. 2004;86-A:455-64.
- Mithoefer K, McAdams T, Williams RJ, Kreuz PC, Mandelbaum BR. Clinical efficacy of the microfracture technique for articular cartilage repair in the knee: an evidence-based systematic analysis. *Am J Sports Med*. 2009;37:2053-63.
- Alford JW, Cole BJ. Cartilage restoration, part 2: techniques, outcomes, and future directions. *Am J Sports Med*. 2005;33:443-60.
- Hangody L, Dobos J, Baló E, Pánics G, Hangody LR, Berkes I. Clinical experiences with autologous osteochondral mosaicplasty in an athletic population: a 17-year prospective multicenter study. *Am J Sports Med*. 2010 Jun; 38(6):1125-33
- McGibbon CA, Trahan CA. Measurement accuracy of focal cartilage defects from MRI and correlation of MRI graded lesions with histology: a preliminary study. *Osteoarthritis Cartilage*. 2003;11:483-93.
- Fischbach F, Bruhn H, Unterhauser F, Rieke J, Wieners G, Felix R, *et al*. Magnetic resonance imaging of hyaline cartilage defects at 1.5T and 3.0T: comparison of medium T2-weighted fast spin echo, T1-weighted two-dimensional and three-dimensional gradient echo pulse sequences. *Acta Radiol*. 2005;46:67-73.
- Brennan SL, Cicuttini FM, Shortreed S, Forbes A, Jones G, Stuckey SL, *et al*. Women lose patella cartilage at a faster rate than men: a 4.5-year cohort study of subjects with knee OA. *Maturitas*. 2010;67:270-4.
- Hanna FS, Teichtahl AJ, Wluka AE, Wang Y, Urquhart DM, English DR, *et al*. Women have increased rates of cartilage loss and progression of cartilage defects at the knee than men: a gender study of adults without clinical knee osteoarthritis. *Menopause*. 2009;16:666-70.
- Ding C, Cicuttini F, Scott F, Boon C, Jones G. Association of prevalent and incident knee cartilage defects with loss of tibial and patellar cartilage: a longitudinal study. *Arthritis Rheum*. 2005;52:3918-27.
- Hannila I, Nieminen MT, Rauvala E, Tervonen O, Ojala R. Patellar cartilage lesions: comparison of magnetic resonance imaging and T2 relaxation-time mapping. *Acta Radiol*. 2007;48: 444-8.
- Lee KY, Dunn TC, Steinbach LS, Ozhinsky E, Ries MD, Majumdar S. Computer-aided quantification of focal cartilage lesions of osteoarthritic knee using MRI. *Magn Reson Imaging*. 2004;22:1105-15.