

Unna boot central gauze technique for chronic venous leg ulcers

Anne L. Gao¹, Justin G. Cole² BS, Zachary T. Woolsey², William V. Stoecker² MD, MS

Affiliations: ¹Department of Life Sciences, University of California Los Angeles, Los Angeles, California. ²S&A Technologies, LLC, Rolla, Missouri

Corresponding Author: William V. Stoecker, M.S., M.D. S&A Technologies, LLC 10101 Stoltz Drive Rolla, MO 65401. Email: wvs@mst.edu

Abstract

Background: Venous leg ulcers generally take many weeks to heal. Novel therapies that shorten healing time and require less complex care are needed. **Purpose:** The purpose of this report is to present a pilot study for a new method that can result in a faster healing time for venous leg ulcers using inexpensive materials. **Methods:** A central-gauze protocol was developed as described here. A three-ply gauze sponge was placed in the center of the ulcer, allowing a peripheral 3-5 mm rim of ulcer to remain exposed. Saline solution was applied to the gauze sponge. A 3-layer Unna boot was applied over the ulcer with short-stretch compression. This novel technique exposed only a peripheral rim of the ulcer to the zinc oxide paste, allowing the central portion of the ulcer to drain through the saline-soaked gauze. The ulcer was photographed at each clinic visit and the wound area was estimated by finding the best-fit ellipse for the ulcer area and computing the area of the ellipse by a standard formula. **Results:** Three patients with small venous leg ulcers treated with the zinc rim technique showed an average healing rate of 46.1% per week (range 27.8% - 50.7%). All ulcers were nearly healed by three weeks. After the ulcer size was reduced sufficiently, patients were discharged with instructions to apply pieces of Unna dressing to the ulcer, under a conventional self-adhesive bandage, maintaining compression, without any saline-gauze in the center. **Conclusions:** The three patients in this pilot study showed rapid healing for venous leg ulcers with the central gauze modification of Unna boot therapy.

Keywords: venous ulcers, zinc dressing, saline dressing, wound care, Unna boot

Introduction

Venous leg ulcers (VLUs) are a result of inadequate blood perfusion and resulting lower oxygen supply to the skin owing to elevated venous pressure and inadequate venous return [1]. The clinical course preceding the ulcer is commonly prolonged, often including a phase of venous stasis, sometimes with stasis dermatitis. Several clinical factors can impede the venous return and increase the risk of developing a VLU. These include obesity, hypertension, age, diabetes mellitus, and smoking, along with any general medical condition that contributes to venous stasis, including renal insufficiency and congestive heart failure [1]. Prevalence of persons developing VLUs in the United States is estimated at 500,000 - 2 million people every year [1]. This number is anticipated to increase with aging of the population and the increase in prevalence of obesity and diabetes mellitus.

VLUs are notoriously slow to heal, with many patients suffering open wounds for months at a time. For VLUs present for six weeks, it is estimated that over 50% of ulcers are not healed after one year [2]. Even after complete healing, there is an estimated 72% overall recurrence rate, with a 21% chance that the ulcer will recur within one year [3]. The combination of slow healing, high recurrence rates and the level of care required to apply treatments of moderate complexity implies that patients often require multiple clinic visits for each ulcer, heavily impacting annual healthcare costs. Venous ulcers account for 0.5-2% of medical expenses in advanced economies [1]. For instance, venous ulcers account for 1.3% - 2.0% of the total annual healthcare budgets of the UK, France, and Germany [4]. The US is estimated to spend \$14.9 billion annually in material costs alone [5, 6]. A large portion of these costs is attributed to long-term treatments, such as the Unna boot

and standard compression therapy, which require frequent dressing changes by someone with training in ulcer care and dressing application. A more effective therapy could allow fewer clinic visits, resulting in a reduction of healthcare costs. An improved method for treating venous ulcers, combining compression with simple, inexpensive surface dressing materials, could prevent progression to a higher level of care.

The Unna boot is a standard mode of treatment for venous ulcers. This wrap contains a paste of zinc oxide, demonstrated to be beneficial in the healing of ulcers. However, the rate of healing with Unna boots is slow, in the range of 4-5% per week [7, 8]. Some studies show that fewer than half of these ulcers heal after a course of six weeks or more of Unna boot therapy [7, 9]. As a result, patients may become noncompliant, further lengthening the duration required for full healing.

We report three cases which showed rapid healing of small VLU's with the use of central saline-soaked gauze for improvement of ulcer drainage.

Methods

Consent and Research Approval

All patients were seen in Dr. Stoecker's dermatology clinic. All patients signed consent forms allowing publication of details and images of their cases. The protocol for this study was approved by the Phelps County Regional Medical Center Institutional Review Board, Rolla Missouri, with FWA number 00009095, expiring August 23, 2016.

Central Gauze Protocol

The first step in this method is to unfold a sheet of 6-ply McKesson Performance Plus Gauze Drain Split Sponge (McKesson Corporation, San Francisco, CA) so that the gauze is three layers thick rather than six. The gauze is then cut to nearly cover the ulcer, leaving a 3-5 mm rim of the ulcer exposed around the gauze piece (**Figure 1**). The gauze piece is soaked with 0.9% saline solution (Select Medical Products, Pinellas Park, FL). If the ulcer has little or no exudate, the width of the ulcer rim surrounding the gauze is approximately 5mm; with increased exudate, this width is approximately 3mm. Ulcers with excessive exudate have a second or third piece of tri-layer gauze (for a total of 6 or 9 individual layers) applied on top of the saline-soaked piece, with the two gauze pieces approximately the same shape and size (**Figure 1**).

After placing the saline-soaked gauze piece inside the wound, a three-layer Unna boot is applied. For ulcers with excessive exudate, a 2 cm thick 3x3 gauze pad is placed over the Unna dressing to accommodate drainage (**Figure 2**). The Unna dressing (Repara, PSS World Medical, Jacksonville, FL) is followed by a single layer of gauze wrap, and finally short stretch elastic bandage (Comprilan, BSN Medical, Hamburg, Germany, **Figure 2**). Using this method, only a rim of zinc oxide comes into direct contact with the wound, different from the full contact with the ulcer that a standard Unna boot provides. The tri-layer configuration of the porous McKesson gauze proved effective in absorbing the drainage in the central ulcer area. The elliptical pore design and basic tri-layer configuration are shown (**Figures 3A, B**).

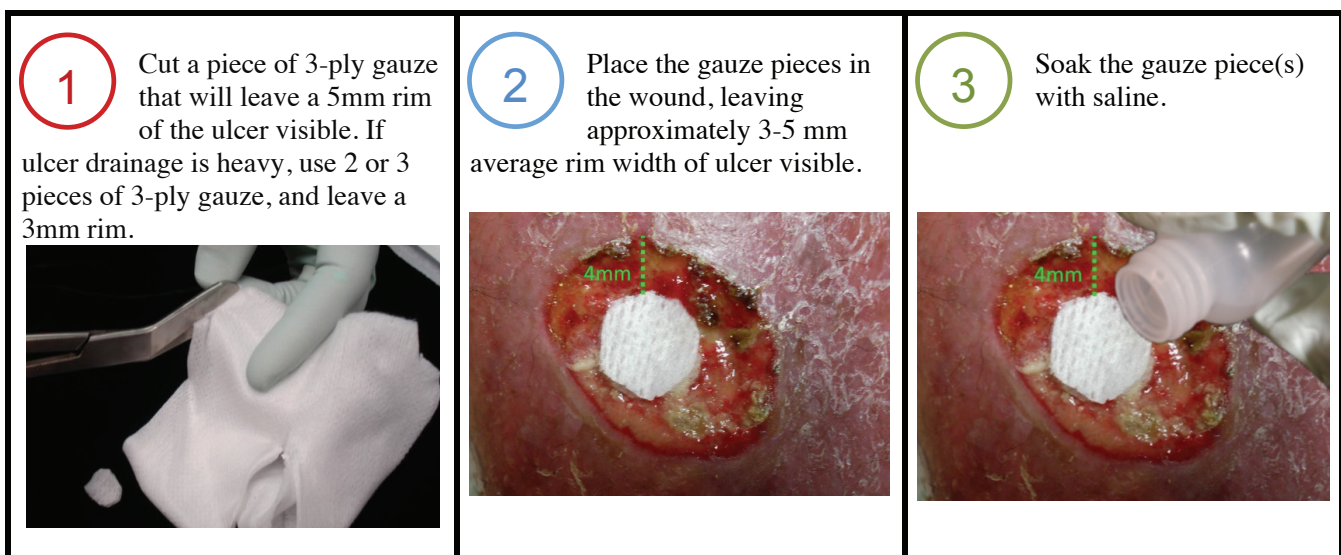


Figure 1. Three-step zinc rim application procedure

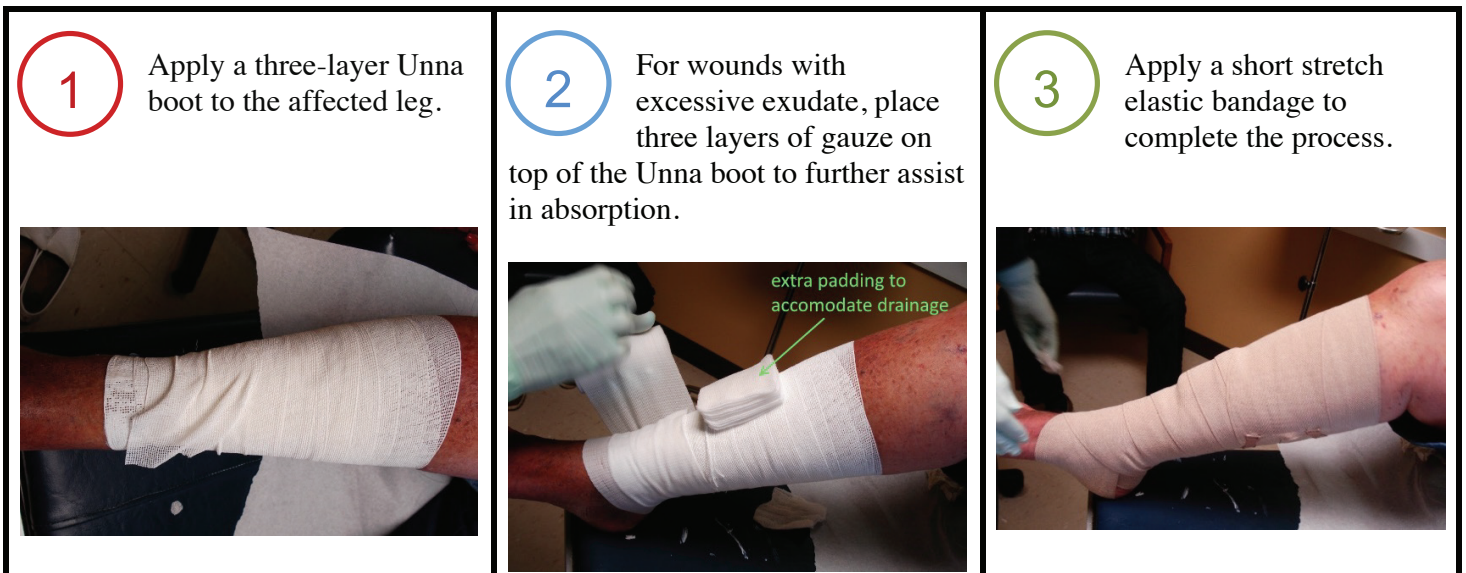


Figure 2. Three-step Unna boot application procedure

Experimental Study Protocol

Undressed ulcers are photographed before and after treatment to record size. A measuring ruler was included in each photograph to accurately determine the area of the ulcer. The area of the best fit ellipse was calculated using a standard formula after determining the major and minor axes of the ellipse. Healing was defined as epithelialization, with or without thin crust, with no ulcer area present. The ulcer area is defined as the area with visible moist dermis and no epidermis. This area of visible moist dermis is photographed at each visit. The patient was discharged from the clinic with compression dressings. For patients with visible ulcer area at the time of discharge, as in Cases 2 and 3, the patient was provided with pieces of Unna dressing cut to cover the ulcer and place under adhesive bandages

(Coverlet Adhesive Bandages, Beiersdorf Inc., Wilton CT).

Results

Three Case Synopses

Case 1

A 79-year-old female developed an ulcer on the lateral right ankle after minor trauma four months previously. There was no prior treatment. She was a daily smoker and had a history of hypertension. She had no history of diabetes. At the initial visit both lower extremities had 2+ pitting edema. The ulcer had an exudative depressed central area of 0.13 cm² (**Figure 4A**). Unna boot therapy with short-stretch dressing was begun, including the saline-soaked




Figure 3. A, Central gauze 10X (Dermlite non-contact photo). B, McKesson gauze 1X

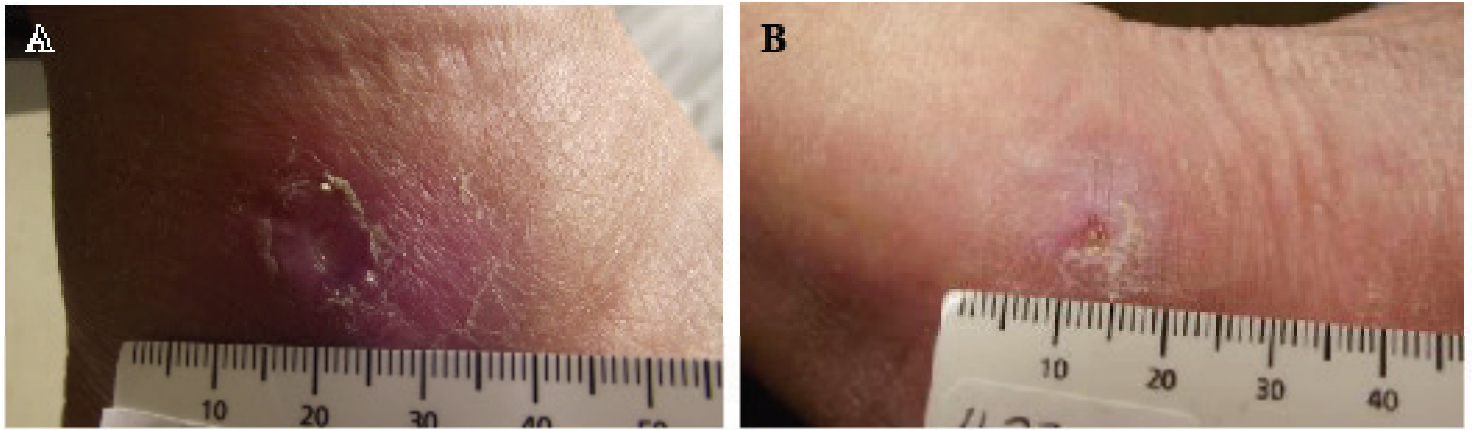


Figure 4. Case 1. A, Initial ulcer visit, day 1, area .13 cm² B, Final ulcer, day 10, area .037 cm²

central gauze per study protocol. She requested to change her own dressing at home; we taught her the Unna dressing technique and her wrapping technique was found to be satisfactory. She changed the saline gauze and Unna boot every two days. After ten days of treatment, the ulcer had decreased in size from 0.13 cm² to 0.037 cm² (**Figure 4B**). The ulcer was sufficiently healed that the Unna boot and gauze dressings were discontinued and the patient was discharged. Compression stockings were advised. The ulcer healed shortly after clinic discharge and was still healed on follow-up visit four months later.

Case 2

An 82-year-old female with hypertension had a painful ulcer on her leg for nine months. She had a normal BMI and no history of diabetes or smoking. A wound care clinic had employed Unna boots and debridement over the nine-month period. During this period the ulcer healed and recurred (**Figure 5A**). Examination showed trace edema and no apparent infection. Three-layer Unna boot therapy with saline-soaked gauze per study protocol was begun with

2-day application cycles. Her husband was taught the Unna technique; his Unna boot wrapping technique was found to be satisfactory. Saline soaks for a duration of 20 minutes were used at the time of dressing changes. After 12 days her ulcer had reduced in size to 0.669 cm² (**Figure 5B**). She was discharged with instructions to continue the 2-day application cycles as was done in the clinic until the ulcer was healed. She continued the zinc gauze for a period of less than two weeks and thereafter used only compression. The healed ulcer showed no sign of recurrence four months later. The wound was healed on examination 5 months later.

Case 3

The 88-year-old female had morbid obesity (BMI 51.34) and a history of hypertension; she had no history of diabetes or smoking. She reported a 3-week history of a non-painful leg ulcer (**Figure 7A**). The affected leg had weeping 3+ edema. Three-layer Unna boot therapy with saline-soaked gauze per protocol was begun. Unna boots were changed twice weekly in the clinic. To accommodate heavy drainage

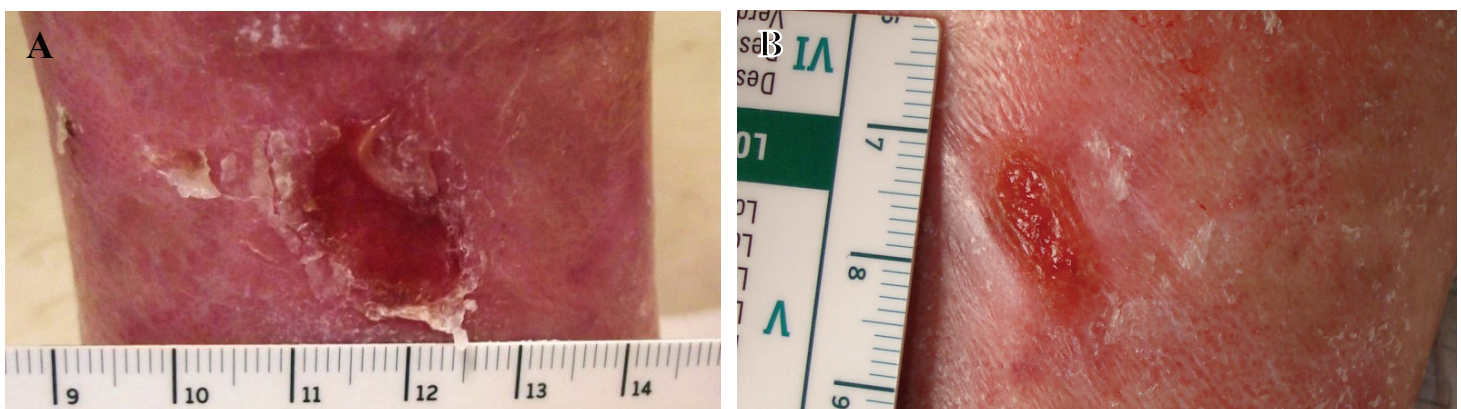


Figure 5. Case 2. A, Initial ulcer visit, day 1, area 1.28 cm². B, Final ulcer visit, day 12, area 0.67 cm².

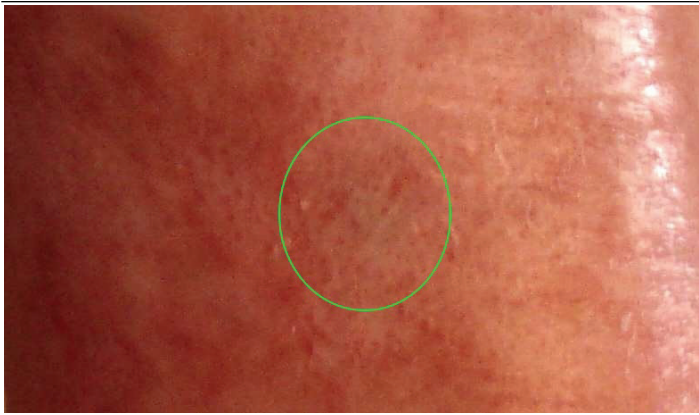


Figure 6. Case 1. Healed wound, four months after final ulcer visit.

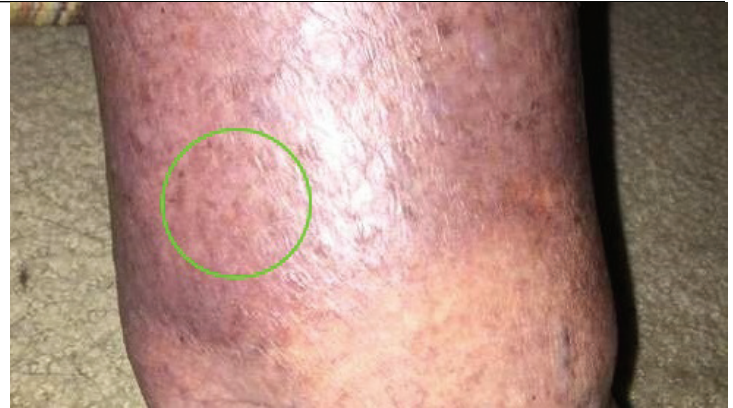

Figure 8. Case 2. Healed wound, four months after final ulcer visit.

from the ulcer, a 2 cm thick 3x3 gauze pad was placed outside the Unna dressing and under the elastic bandage to absorb drainage. She began 300 mg of horse chestnut seed extract oral supplement twice daily for the duration of the study treatment to aid in healing [10]. Within 10 days, the open ulcer area had decreased from 2.08 cm² to 0.30 cm² (**Figures 7B, 8**). The patient was discharged from clinic and instructed to apply Unna dressing squares under adhesive bandages, per protocol. Follow-up examination six months later, when she returned for treatment of a new ulcer, showed no recurrence of the original ulcer.

Patient Satisfaction and Subsequent Courses of Ulcers

All ulcers were sufficiently healed to allow discharge of patients within 12 days; at this time, Unna boots were discontinued. All patients were pleased with their rapid healing. One patient (Case 2) had been previously treated at a wound care clinic for nine months. One patient referred her spouse for therapy

of another ulcer; another patient returned for two subsequent venous leg ulcers. All ulcers remained healed at three-month telephone or clinic visit follow-up.

Ulcer Healing Rates

The ulcer sizes, duration, and wound healing rates are shown in **Table 1**.

Discussion

Representative studies showing leg ulcer healing rates for ulcer treatment methods are listed in **Table 2**. The weekly wound healing rates in these studies range from 3.5% to 20.5%. In only one study were all the ulcers healed at the study conclusion. The average weekly wound healing rate for our three cases treated with the central gauze technique was 46.1%.

The dressing change procedure with the central gauze entails only the application of saline-soaked

Cases	Initial Ulcer Size	Final Ulcer Size	Unna Boot Duration	Wound Healing cm ² /Week
Case 1	0.134 cm ²	0.037 cm ²	10 days	50.7%
Case 2	1.279 cm ²	0.669 cm ²	12 days	27.8%
Case 3	2.078 cm ²	0.304 cm ²	10 days	59.8%
Average	1.164 cm ²	0.337 cm ²	10.7 days	46.1%

Table 1. Initial and final ulcer sizes, ulcer duration, and weekly healing rates of venous ulcers treated with the zinc rim method.

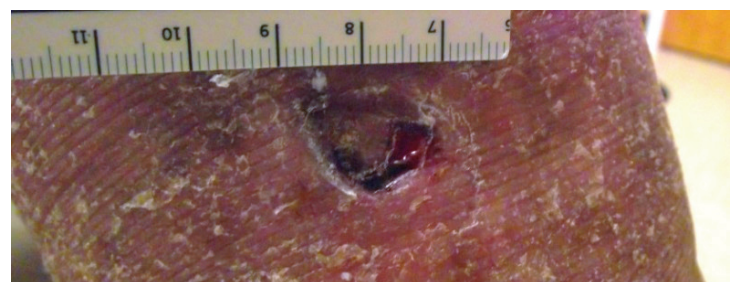
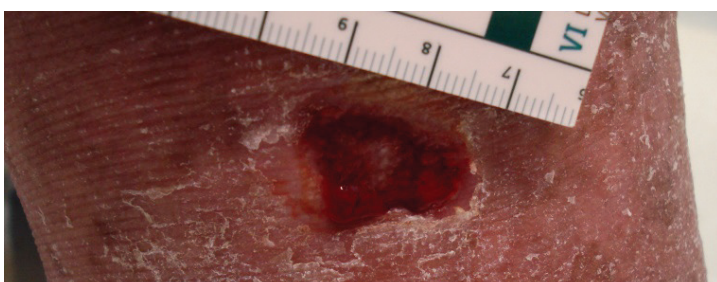


Figure 7. Case 3. A, Initial ulcer visit, day 1, area 2.08 cm². B, Final ulcer visit, day 10, area 0.30 cm²

gauze to the central part of ulcer. Once the ulcer had sufficiently healed, the home dressing change involves only the application of the Unna gauze to the ulcer. Our experience is that most patients need professional help with the Unna boot; therefore they need to be followed in the clinic. In contrast, most patients can manage the home phase of our protocol, which involves applying the Unna gauze under an adhesive dressing and then applying elastic compression.

Moisture Management with the Central Gauze Technique

Moisture in the ulcer environment is favorable; excess drainage that pools under an occlusive dressing is unfavorable. Drainage is maximum at the ulcer center, and minimum at the ulcer periphery, where healing occurs. Therefore a healing ulcer is comprised of two zones- a central drainage zone, often with reticular dermis exposed, and a peripheral healing zone where the shallow ulcer areas are healing rapidly

at the papillary dermis - epidermis junction (Figure 9). An Unna boot is advantageous for rapid healing because the zinc oxide-impregnated gauze is in contact with the ulcer periphery. With the unmodified Unna dressing, the potential healing advantage of zinc oxide is diminished because of excess moisture, sometimes visible on clinic visits where it has leaked out of the Unna boot. The two-zone model shown here can explain how modification of the Unna boot to absorb exudate from the central zone can improve the healing rate. The saline-soaked gauze in the center promotes wicking away of excess drainage. The configuration of the McKesson gauze employed here may allow increased drainage. The dimensions of the elliptical openings are small enough to allow osmotic action and large enough to allow for direct pass-through of excess drainage. For heavy drainage, as we observed in Case 3, a 2cm thick pad of standard 3x3 or 4x4 gauze may be placed outside the Unna wrap.

Author	Treatment Method	Number of Patients	Duration	Average Initial Ulcer Size	Wound Healing Rate per Week	Ulcers Healed
Backhouse et al 1987 [11]	Compression	28	12 weeks	N/A	20.5%	22/28 (78%)
	Hydrocolloid	28	12 weeks	N/A	18%	21/28 (75%)
Cordts et al 1992 [7]	Unna boot	14	12 weeks	6.0 cm ²	5%	6/14 (43%)
	Duoderm	16	12 weeks	9.1 cm ²	7.5%	8/16 (50%)
Luz et al 2013 [8]	Unna boot	32	8 / 12 weeks	15.3 cm ²	3.7 – 4.2%	N/A
	Simple bandage	11	8 / 12 weeks	28.2 cm ²	3.6%	N/A
Limova 2003 [9]	Alginate (Tegagen, Sorbsan)	19	6 weeks	6.9 cm ² – 8.5 cm ²	4.9% - 5.6%	0% - 22%
Samuels et al 2013 [12]	Ultrasound (20kHz for 15 minutes)	5	Varied	4.8 cm ²	12%	5/5 (100%)
	Ultrasound (20kHz for 45 minutes)	5	Varied	N/A	7%	1/5 (20%)
	Ultrasound (100kHz for 15 minutes)	5	Varied	N/A	7%	2/5 (40%)
Hussain 2015 [13]	Nonadherent Ultra dressings	12	Varied	5.47 cm ²	12.2%	7/12 (58%)

Table 2. Healing rates of venous ulcers when various treatments are used

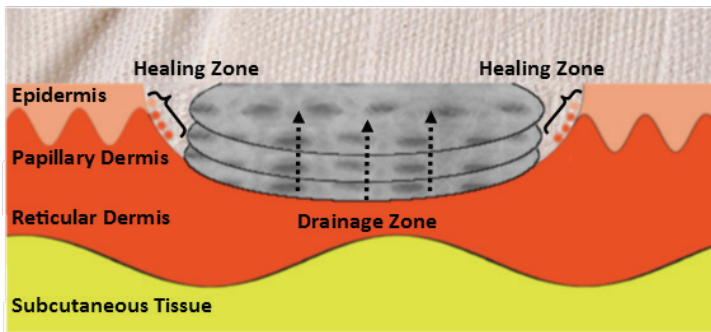


Figure 9. Zone model for healing ulcers: central drainage zone and peripheral healing zone

Accelerated Healing with Zinc Oxide at the Ulcer Rim via Unna Boot

Our technique is targeted to two ulcer zones: a central zone covered with a dressing of gauze and saline and a peripheral healing zone covered with Unna dressing: gauze and zinc oxide. When healing is sufficient and drainage is minimal, only zinc-oxide impregnated gauze is applied. Here we examine the choice of zinc-oxide impregnated gauze used for both the peripheral healing zone and as zinc gauze pieces in the home dressing during the last healing phase.

The importance of topical zinc in wound healing was reviewed by Lansdown et al. [14]. Topical zinc is superior to oral zinc therapy in wound healing [14]. One important mechanism for zinc is through activation of transcription of growth factors, via zinc-finger proteins, transcription factors that bind to DNA [15, 16]. Zinc is present in higher concentrations in the epidermis than the dermis; it plays a central role in mitosis, migration, and maturation. The greater activity of zinc-dependent RNA and DNA polymerases in the mitotically active basal cells [17, 18] favors a bandage design with greater zinc availability at the periphery.

Zinc metallothioneins (MTs), which are complexed with intracellular zinc, help regulate the cellular zinc supply. [19]. Zinc MTs are induced by cytokines such as interleukin-1 [20]. Zinc levels at wound margins are significantly elevated even within 24 hours, following early cytokine upregulation in experimental wounds [21]. Alkaline phosphatase (a zinc metalloenzyme), angiogenesis, matrix metalloproteinases, and integrins including $\alpha 2$, $\alpha 3$, αv , and $\alpha 6$ integrin subunits are all upregulated in wound healing and

are all dependent upon adequate local zinc levels [14, 22-26]. Zinc also has been shown to inhibit bacterial growth [14].

Zinc oxide is the best form of zinc in dressings, supplying the divalent form of zinc needed as a cofactor for zinc metalloenzymes. Zinc oxide has been shown beneficial in double-blind placebo-controlled studies for both venous and arterial leg ulcers [27]. Zinc oxide is so beneficial for wound healing that in one study, it was associated with faster healing than the comparison treatment of platelet-derived growth factor [28]. At present, there may be no better material choice for the healing rim of leg ulcers than zinc-oxide impregnated gauze wrap.

Limitations

Ulcers in the present study were all less than 2 cm², smaller than most ulcers presented in studies from ulcer clinics. The three cases were the first three available after the zinc rim technique was developed. These ulcers were treated before they had progressed in size; no cases of larger ulcers or diabetic ulcers appeared during this time period. The cases presented here may approximate the small ulcers seen in non-specialty clinics. One case had an ulcer that was present for only three weeks; therefore it was not a chronic VLU, which is defined as an ulcer that is present for > 6 weeks [1]. Short-stretch dressing was used for cases 2 and 3 and had not been used previously. For Case 3, horse chestnut extract was used during treatment; this had not been used previously. Despite continuing the horse chestnut extract, the patient in Case 3 developed two more VLUs, which were also treated with the zinc rim protocol; both healed in less than two weeks.

Conclusion

This report presents a novel method of treatment for venous leg ulcers using designated saline-soaked gauze at the center of the ulcer under an Unna boot. The combination of exposing the rim of the ulcer to zinc oxide and allowing the central aspect of the ulcer to drain allowed three patients with small venous leg ulcers to heal rapidly. The specific gauze used for the central ulcer area has an optimal pore size for promoting direct pass-through of excess drainage. The thickness of the central gauze dressing should be increased for ulcers with heavy drainage. Finally,

we note the effectiveness of zinc oxide gauze placed under self-adhesive dressings in the final phase of healing, when Unna dressings are no longer needed. Further studies of this novel dressing technique are warranted. Additional studies are planned to assess the efficacy of this therapy in patients with diabetes.

References

- Zenilman J, Valle MF, Malas MB, Maruthur N, Qazi U, Suh Y, Wilson LM, Haberl EB, Bass EB, Lazarus G. Chronic Venous Ulcers: A Comparative Effectiveness Review of Treatment Modalities. Comparative Effectiveness Review No. 127. (Prepared by Johns Hopkins Evidence-based Practice Center under Contract No. 290-2007-10061-I.) AHRQ Publication No. 13(14)-EHC121-EF. Rockville, MD: Agency for Healthcare Research and Quality. December 2013. Erratum January 2014. www.effectivehealthcare.ahrq.gov/reports/final.cfm.
- Valle MF, Maruthur NM, Wilson LM, et al. Comparative effectiveness of advanced wound dressings for patients with chronic venous leg ulcers: a systematic review. *Wound Repair Regen*. 2014;22(2):193-204. [PMID 24635169]
- Leaper D, Münter C, Meaume S, et al. The use of biatain Ag in hard-to-heal venous leg ulcers: meta-analysis of randomised controlled trials. *PLoS ONE*. 2013;8(7):e67083. [PMID: 23843984]
- Dabiri G, Hammerman S, Falanga V. Low Grade Elastic Compression Regimen for Venous Leg Ulcers-An Effective Compromise for Patients Requiring Daily Dressing Changes. *International Wound Journal*. 2015 Dec; 12(6):655-61. [PMID: 24267477]
- Trent JT, Falabella A, Eaglstein WH, Kirsner RS. Venous ulcers: Pathophysiology and treatment options. *Ostomy Wound Management*. 2005;51(5):38-54. [PMID: 16014984]
- Chatterjee SS. Venous ulcers of the lower limb: Where do we stand? *Indian J Plastic Surg*. 2012;45(2):266-74. [PMID: 23162226]
- Cordts PR, Hanrahan LM, Rodriguez AA, Woodson J, LaMorte WW, Menzoian JO. A prospective, randomized trial of Unna's boot versus Duoderm CGF hydroactive dressing plus compression in the management of venous leg ulcers. *J Vasc Surg*. 1992;15(3):480-6. [PMID: 1538504]
- Luz BS, Araujo CS, Atzingen DA, Mendonça AR, Mesquita Filho M, Medeiros ML. Evaluating the effectiveness of the customized Unna boot when treating patients with venous ulcers. *An Bras Dermatol*. 2013 Jan-Feb;88(1):41-9. [PMID: 23539002]
- Limova M. Evaluation of two calcium alginate dressings in the management of venous ulcers. *Ostomy Wound Manage*. 2003;49(9):26-33. [PMID: 14581707]
- Pittler MH, Ernst E. Horse-chestnut seed extract for chronic venous insufficiency. A criteria-based systematic review. *Arch Dermatol*. 1998;134:1356-60. [PMID: 9828868]
- Backhouse CM, Blair SD, Savage AP, Walton J, McCollum CN. Controlled trial of occlusive dressings in healing chronic venous ulcers. *Br J Surg*. 1987;74(7):626-7. [PMID: 3304523]
- Samuels JA, Weingarten MS, Margolis DJ, Zubkov L, Sunny Y, Bawiec CR, et al. Low-frequency (<100 kHz), low-intensity (<100 mW/cm(2)) ultrasound to treat venous ulcers: a human study and in vitro experiments. *J Acoust Soc Am*. 2013;134:1541-7. [PMID: 23927194]
- Hussain SM. A comparison of the efficacy and cost of different venous leg ulcer dressings: a retrospective cohort study. *Int J Vasc Med*. 2015:187531. [PMID: 25954532]
- Lansdown AB, Mirastschijski U, Stubbs N, Scanlon E, Agren MS. Zinc in wound healing: theoretical, experimental, and clinical aspects. *Wound Repair Regen*. 2007 Jan-Feb;15(1):2-16. [PMID: 17244314]
- Bao B, Prasad AS, Beck FW, Godmere M. Zinc modulates mRNA levels of cytokines. *Am J Physiol Endocrinol Metab* 2003 Nov;285(5):E1095-102. [PMID: 12812920]
- Berg JM, Shi Y. The galvanization of biology: a growing appreciation for the roles of zinc. *Science* 1996 Feb 23;271(5252):1081-5. [PMID: 8599083]
- Ågren MS. Percutaneous absorption of zinc from zinc oxide applied topically to intact skin in man. *Dermatologica* 1990;180(1):36-9. [PMID: 2307275]
- Henzel JH, DeWeese MS, Lichti EL. Zinc concentrations within healing wounds. Significance of postoperative zincuria on availability and requirements during tissue repair. *Arch Surg*. 1970 Apr;100(4):349-57. [PMID: 5417159]
- Lansdown ABG. Metallothioneins: potential therapeutic aids for wound healing in the skin. *Wound Repair Regen* 2002 May-Jun;10(3):130-32. [PMID: 12164164]
- Cousins RJ, Leinart AS. Tissue-specific regulation of zinc metabolism and metallothionein genes by interleukin 1. *FASEB J*. 1988 Oct;2(13):2884-90. [PMID: 2458983]
- Lansdown ABG, Sampson B, Rowe A. Sequential changes in trace metal, metallothionein and calmodulin concentrations in healing skin wounds. *J Anat*. 1999 Oct;195 (Pt 3):375-86. [PMID: 10580852]
- Gerbitz KD Human alkaline phosphatases. II. Metalloenzyme properties of the enzyme from human liver. *Hoppe Seylers Z Physiol Chem*. 1977 Nov;358(11):1491-7. [PMID: 924371]
- Soo C, Shaw WW, Zhang X, Longaker MT, Howard EW, Ting K. Differential expression of matrix metalloproteinases and their tissue-derived inhibitors in cutaneous wound repair. *Plast Reconstr Surg* 2000 Feb;105(2):638-47. Erratum in: *Plast Reconstr Surg*. 2000 Jul;106(1):236-7. [PMID: 10697171]
- Mirastschijski U, Zhou Z, Rollman O, Tryggvason K, Ågren MS. Wound healing in membrane-type-1 matrix metalloproteinase-deficient mice. *J Invest Dermatol* 2004; 123:600-2. [PMID: 15304103]
- Tenaud I, Leroy S, Chebassier N, Dreno B. Zinc, copper and manganese enhanced keratinocyte migration through a functional modulation of keratinocyte integrins. *Exp Dermatol* 2000; 9: 407-16. [PMID: 11099108]
- Pasqualini R, Barbas CF 3rd, Arap W. Vessel maneuvers: zinc fingers promote angiogenesis. *Nat Med*. 2002 Dec;8(12):1353-4. No abstract available. [PMID: 12457173]
- Strömberg HE, Agren MS. Topical zinc oxide treatment improves arterial and venous leg ulcers. *Br J Dermatol* 1984 Oct;111(4):461-8. [PMID: 6386033]
- Mertz PM, Cazzaniga AL, Drosou A, Davis SC. The effect of a zinc/iron solution as compared to a topical growth factor on epithelization of partial thickness wounds. *Wound Healing Society Baltimore, MD. Wound Repair Regen* 2002; 10: A38.