

# UCLA

## UCLA Previously Published Works

### Title

Advances in immune checkpoint inhibitors for bone sarcoma therapy.

### Permalink

<https://escholarship.org/uc/item/3k40w8f4>

### Authors

Thanindratarn, Pichaya

Dean, Dylan C

Nelson, Scott D

et al.

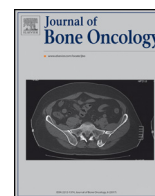### Publication Date

2019-04-01

### DOI

10.1016/j.jbo.2019.100221

Peer reviewed



## Review Article

## Advances in immune checkpoint inhibitors for bone sarcoma therapy

Pichaya Thanindrartarn<sup>a,b</sup>, Dylan C. Dean<sup>a</sup>, Scott D. Nelson<sup>c</sup>, Francis J. Hornicek<sup>a</sup>, Zhenfeng Duan<sup>a,\*</sup>

<sup>a</sup> Department of Orthopedic Surgery, Sarcoma Biology Laboratory, David Geffen School of Medicine, University of California, 615 Charles E. Young Dr. South, Los Angeles, CA 90095, USA

<sup>b</sup> Department of Orthopedic Surgery, Chulabhorn hospital, HRH Princess Chulabhorn College of Medical Science, Bangkok, Thailand

<sup>c</sup> Department of Pathology, University of California, Los Angeles, CA, USA

## ARTICLE INFO

## Keywords:

Immune checkpoint  
Immunotherapy  
Bone sarcoma  
Anti-PD-1/PD-L1  
Anti-CTLA-4

## ABSTRACT

Bone sarcomas are a collection of sporadic malignancies of mesenchymal origin. The most common subtypes include osteosarcoma, Ewing sarcoma, chondrosarcoma, and chordoma. Despite the use of aggressive treatment protocols consisting of extensive surgical resection, chemotherapy, and radiotherapy, outcomes have not significantly improved over the past few decades for osteosarcoma or Ewing sarcoma patients. In addition, chondrosarcoma and chordoma are resistant to both chemotherapy and radiation therapy. There is, therefore, an urgent need to elucidate which novel new therapies may affect bone sarcomas. Emerging checkpoint inhibitors have generated considerable attention for their clinical success in a variety of human cancers, which has led to works assessing their potential in bone sarcoma management. Here, we review the recent advances of anti-PD-1/PD-L1 and anti-CTLA-4 blockade as well as other promising new immune checkpoint targets for their use in bone sarcoma therapy.

## 1. Introduction

Bone sarcomas are a group of sporadic malignancies originating from mesenchymal tissues. In the year 2018 within the United States, approximately 3450 patients are expected to be newly diagnosed with a primary bone sarcoma, representing less than 0.2% of all new cancers [1]. Total deaths are approximated at 1590 total cases per year at a rate of 0.4 deaths per 100,000 people [1,2]. Despite their relative infrequency, bone sarcomas are uniquely challenging with high rates of fatality and overall burden of disease. Primary bone sarcomas affect children, adolescents, as well as older patients, with age-specific incidence varying according to histological subtype [3–8] (Table 1). The most common bone sarcomas include osteosarcoma, Ewing sarcoma, chondrosarcoma, and chordoma [1]. Bone sarcomas have a predilection for pediatric and adolescent populations, as they comprise 6% of all childhood cancers. Overall, osteosarcoma (56%) is much more common than Ewing sarcoma (34%), chondrosarcoma (6%), and chordoma (less than 5%) [1]. In adults, chondrosarcoma is the most common, as it accounts for more than 40% of primary bone sarcomas, followed by osteosarcoma (28%), chordoma (10%), Ewing sarcoma (8%), and undifferentiated pleomorphic sarcoma (4%) (Fig. 1) [1]. These tumors frequently arise from the long bones, especially of the lower extremity,

as well as the pelvis, vertebra, or sacrum for cases of chordoma (Fig. 2). Clinically, the axial lesions tend to be more aggressive compared to appendicular sarcomas.

The standard treatment protocol for osteosarcoma and Ewing sarcoma consists of extensive surgical resection, chemotherapy, and radiation. However, despite these aggressive interventions, patient outcomes have not significantly improved for decades. According to data from the Surveillance, Epidemiology, and End Results (SEER) Program from 2008 to 2014, the five-year overall survival rate for patients with bone sarcoma is 66.9% [2]. Relapse rates also remain high at approximately 35% [9]. Moreover, patients with metastatic disease have an even worse prognosis, with five-year overall survival rates of approximately 10–30% [9,10]. Chemotherapeutic-resistant patients also have poor outcomes, even with detailed regimen modifications [4,10]. While osteosarcoma and Ewing sarcoma can sometimes respond to chemotherapy, chondrosarcoma and chordoma have well-known chemotherapeutic and radiotherapeutic resistance which has contributed to poor patient outcomes. Given these barriers to current treatment regimens, there is an urgent need to identify which novel therapeutics may improve management of bone sarcomas.

In recent years, immune modulating therapies have received considerable attention for their efficacy in cancer treatment. These

\* Corresponding author.

E-mail address: [zduan@mednet.ucla.edu](mailto:zduan@mednet.ucla.edu) (Z. Duan).

**Table 1**  
Overview of clinical characteristics and treatment options in common bone sarcomas.

Disease	Subtype	Incidence	Age	Common location	Chemotherapy	Radiation	Clinical outcome
Osteosarcoma [1–3]	Conventional osteosarcoma (3 subtypes; osteoblastic, chondroblastic, fibroblastic)	75% of all osteosarcoma	2nd–3rd decade of life	Metaphysis of long bone around knee and shoulder joint, axial skeleton	Sensitive	Can be useful	5-year OS 54%
	Telangiectatic osteosarcoma	3–4%	2nd decade of life	Similar to conventional osteosarcoma	Sensitive	Minimal role	Better than conventional osteosarcoma
	Small cell osteosarcoma	1.5%			Sensitive	Radiosensitive	Slightly worse prognosis than conventional osteosarcoma
	Low grade central osteosarcoma	1–2%	3rd decade of life	Intramedullary distal femur, proximal tibia, pelvis	Minimal role	Minimal role	Low grade
	Parosteal osteosarcoma	3.5–4%	> 30 years	Posterior cortex of distal femur	Minimal role	Minimal role	5-years OS 91%
	Periosteal osteosarcoma	1.5–2%	2nd–3rd decade of life	Tibia or femur	Minimal role	Minimal role	Intermediate grade
Ewing's sarcoma [5]	High grade surface osteosarcoma	<1%	10–70 years	Long bone, distal femur	Sensitive	Can be useful	High grade, Same as conventional osteosarcoma
	Secondary osteosarcoma	Pre-existing conditions; paget disease, irradiated bone, bone infarct, chronic osteomyelitis, fibrous dysplasia, etc.	Mostly in 2nd decade	Diaphysis of long bone	Sensitive	Sensitive	5-years OS
		1.5 cases per million children in U.S.A. More common in European population	< 15 years	Lower extremity, pelvis, chest wall, upper extremity, spine, skull			Localized: 70–80% (child 76%, adult 49%) Metastasis: 30% 10-years OS
Chondrosarcoma [6,7]	Conventional chondrosarcoma	85–90% of all chondrosarcoma	> 50 years	Pelvis, proximal femur, proximal humerus and shoulder girdle, distal femur, ribs and sternum	Resistant	Low	
		Mostly low- to intermediate-grade		Higher grade in axial lesion			Grade 1: 83%
	Mesenchymal chondrosarcoma	<2%	10–30 years	65–86% of skeletal lesions (jawbones, ribs, ilium, vertebrae)	Possibly, if high round cells	Possibly radiosensitive	Grade 2: 64% Grade 3: 29% High grade
	Clear cell chondrosarcoma	<2%	40–50 years	Epiphysis of humeral or femoral head	Resistant	Low	10-years OS 28% Low grade
Chordoma [8]	Dedifferentiated chondrosarcoma	10%	> 60 years	Femur and pelvis	Uncertain	Low	10-years OS 89% High grade
		0.08 per 100,000 populations	50–60 years	Sacrum, skull base, mobile vertebrae	Resistant	Low	5-years OS 24% 5-years OS 67.6%
		1–4 % of all bone malignancies 50 % of primary sacral tumors					10-years OS 39.9% 20-years OS 13.1%

Abbreviation: OS – overall survival.

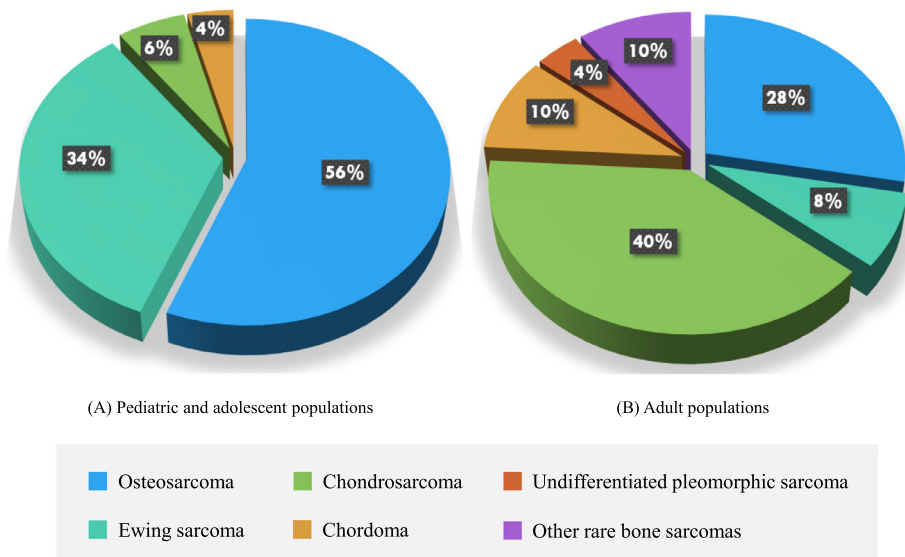


Fig. 1. Histologic subtypes of common bone sarcomas in pediatric and adolescent populations (A), and adults (B) [1,2].

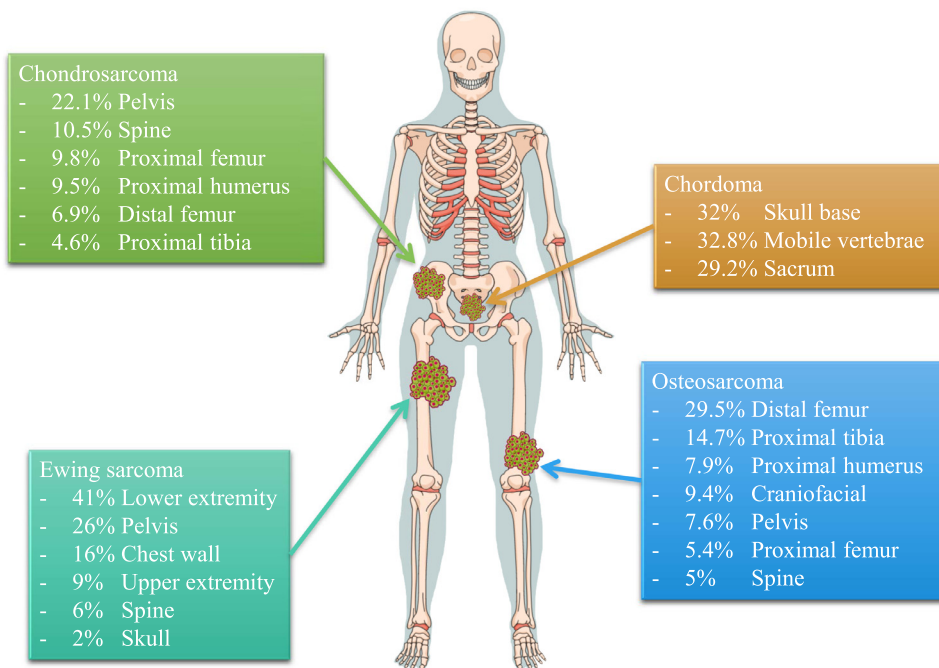


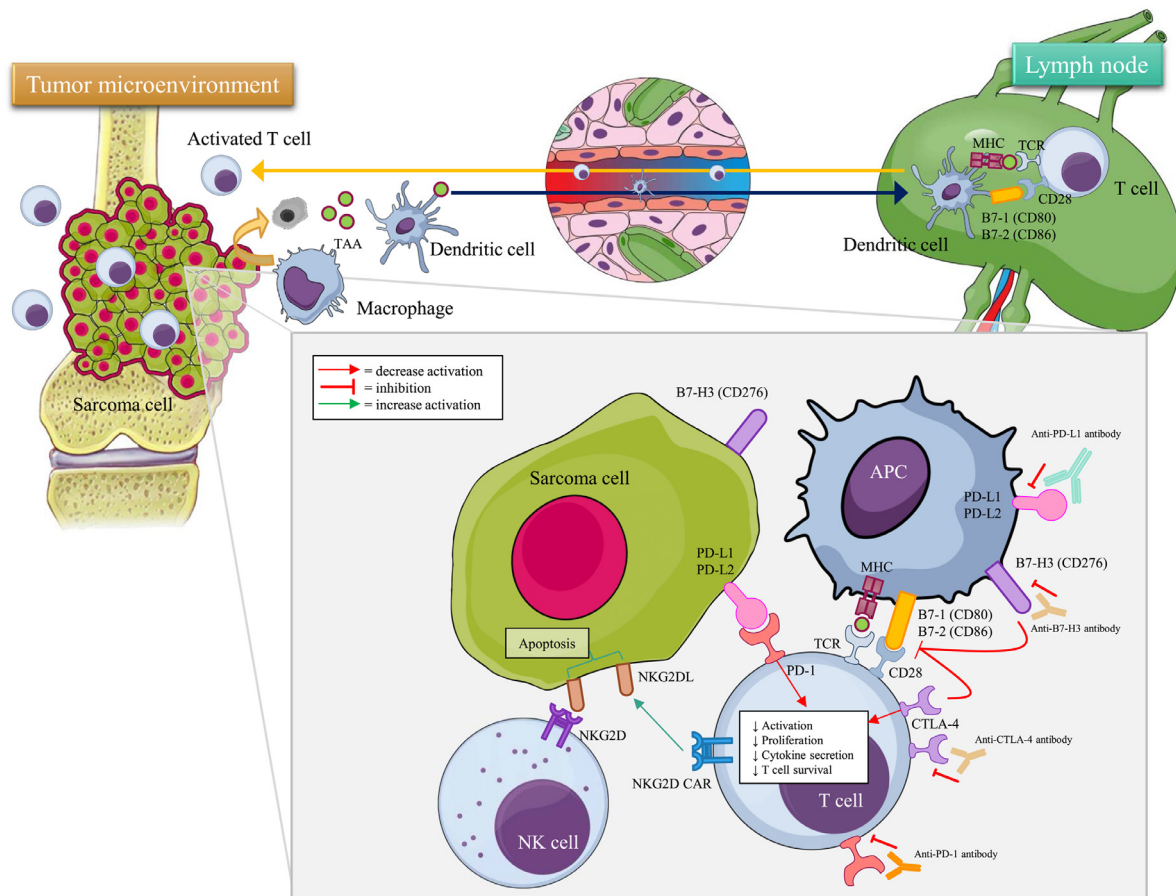
Fig. 2. Anatomical distribution of common bone sarcomas [2-8].

therapies largely function by attenuating the immune inhibitory molecules tumor cells employ to protect themselves from immune cells within the tumor microenvironment. In the normal physiological state, this process is important for regulating peripheral immune tolerance and attenuating a potentially overzealous immune response [11]. However, cancer cells hijack this response. The first generation and best-known checkpoint inhibitors are antibodies targeting programmed cell death receptor-1 (PD-1) and its associated ligand (PD-L1), as well as Cytotoxic T-lymphocyte-associated protein 4 (CTLA-4) antibodies. The anti-tumor immune response has shown impressive clinical results in various tumors, including melanoma, non-small-cell lung cancer, renal cell carcinoma, bladder cancer, and head and neck cancers [12-18]. Of note, the 2018 Nobel Prize for Physiology or Medicine was awarded to Dr. James P. Allison and Dr. Tasuku Honjo, for their respective discoveries of CTLA-4 or PD-1 negative immune regulation as a novel

chemotherapeutic therapy. Their achievements have accelerated investigations into the potential of these therapies in bone sarcomas. Here we review the application of immune checkpoint therapies, including anti-PD-1/PD-L1 and anti-CTLA-4, for the treatment of common bone sarcomas.

## 2. PD-1/PD-L1

PD-1 is a cell-surface protein receptor expressed on activated CD8+ T lymphocytes, B cells, and natural killer (NK) cells. PD-L1 (B7-H1 or CD274) and PD-L2 (B7-DC or CD273) are often expressed on tumor cells and tumor-infiltrating lymphocytes (TILs) within the tumor microenvironment. Mechanistically, PD-1 expression is induced during T cell activation and through the PD-1/PD-L1 pathway controls the induction and maintenance of immune tolerance within the tumor



**Fig. 3.** Overview of immune checkpoints under investigation in bone sarcomas.

Sarcoma cells are initially attacked by macrophages of the innate immune system. Dendritic cells capture tumor-associated antigens at the tumor site and present them to T cells within the lymph node. After activation, the T cells return and kill tumor cells. This anti-tumor immune response is regulated by the immune checkpoint mechanism. The PD-1/PD-L1 axis inhibits T cell activation, while the inhibitory effect of CTLA-4 is caused by competition between CD28 and CTLA-4 binding to B7-1/2 (CD80/86). Similarly, B7-H3 competitively binds CD28 and inhibits T cell activation. On the natural killer (NK) cells, NKG2D/NKG2DL stimulates cytotoxic activity leading to tumor cells apoptosis. Various antibodies which affect these inhibitory and co-stimulatory immune checkpoints may enhance the anti-tumor immune response in bone sarcoma patients. [18,19,63,66].

Abbreviations: Antigen-presenting cell (APC), B7 homolog 3 (B7-H3), cytotoxic T-lymphocyte-associated protein 4 (CTLA-4), major histocompatibility complex (MHC), natural killer cell (NK), natural killer group 2D (NKG2D), natural killer group 2D ligand (NKG2DL), natural killer group 2D chimeric antigen receptor (NKG2D CAR), program cell death receptor-1 (PD-1), program cell death receptor-1/2 ligand (PD-L1/PD-L2), tumor-associated antigen (TAA), T cell receptor (TCR).

microenvironment [19,20]. Engagement of PD-1 and its ligands PD-L1 or PD-L2 inhibits T cell activation, proliferation, and cytotoxic secretion within cancer as well, resulting in an attenuated antitumor immune response (Fig. 3).

Various solid tumors including melanoma, renal cell carcinoma, non-small cell lung cancer, ovarian cancer, colorectal cancer, thymic cancer, and Hodgkin's lymphoma have shown increased PD-L1 expression with associated metastasis and poorer overall outcomes for patients [21,22]. Experimentally, blockage of the PD-1/PD-L1 pathway has produced favorable results in these cancers [12–18]. At present, nivolumab and pembrolizumab are the two FDA approved anti-PD-1 agents for the treatment of advanced melanoma, non-small cell lung cancer, renal cell carcinoma, and Hodgkin's lymphoma [21,22].

In addition to these cancers, higher expression of PD-1 on immune cells and PD-L1 on tumor cells have been reported in various subtypes of bone and soft tissue sarcomas and correlated with poorer prognosis [23–26]. While surgery remains principally important in bone sarcoma treatment, recent advances in cancer immunotherapy have generated considerable interest within the field for their potential to advance current treatment strategies.

### 2.1. PD-1/PD-L1 in osteosarcoma

Osteosarcoma is the most common bone cancer in childhood and second most common for adults (Fig. 1). It often develops at the metaphysis of long bones within the extremities (Fig. 2). In general, adult-onset osteosarcomas primarily occur secondary to predisposing conditions such as Paget's disease of bone, bone irradiation, bone infarction, or other benign bone lesions. For Asian patients, however, there is a much higher incidence of primary osteosarcoma tumors [2]. The five-year overall survival for osteosarcoma is 54% in non-metastatic patients and drops to less than 20% in cases of metastasis [2].

Several studies have examined PD-L1 expression in osteosarcoma cell lines and tumor tissues and is summarized in Table 2 [26–34]. While PD-L1 expression in osteosarcoma cell lines broadly ranges from low to high, the drug-resistant variants trend towards higher expression compared to their parental cell lines [28]. Such findings have led to subsequent biochemical research, including a study utilizing the Clustered Regularly Interspaced Short Palindromic Repeats (CRISPR)/Cas9 system to target the PD-L1 gene in osteosarcoma cell lines [29]. Of clinical interest, PD-L1 has been shown to regulate osteosarcoma cell growth and drug resistance to doxorubicin and paclitaxel [29].

At the human osteosarcoma tissue level, 23.7% of osteosarcomas demonstrate high expression and 50% show intermediate expression

**Table 2**  
Studies of PD-1, PD-L1, and TILs expression in osteosarcoma<sup>a</sup>.

Author	Type of tumor	Samples/cases	Methods	PD-1, PD-L1, and TILs	Clinical correlation
Torabi et al. [26]	Cell lines	HOS cell line	Western blot qRT-PCR	PD-L1 was detected in osteosarcoma cell line (HOS) PD-1 mRNA is higher compared to PD-L1 All tissue samples were positive PD-1 staining.	N/A
Koirala et al. [27]	Tumor tissue microarrays	26 osteosarcoma tissue samples	IHC	The mean PD-1 expression scores significantly in the order: osteosarcoma > chondrosarcoma > benign osteochondroma. 75% of cell lines showed expression of PD-L1 mRNA 40% of cell lines showed detectable of PD-L1 protein by western blot. 67% of tumor specimens showed expression of PD-L1 mRNA.	N/A
	Cell lines	9 cell lines for western blot 21 for qRT-PCR	qRT-PCR, western blot		25% of primary osteosarcoma tumors that express PD-L1 were more likely to contain cells that express PD-1. Expression of PD-L1 was significantly associated with the presence of T cells, dendritic cells, and natural killer cells (91.7 % vs 47.2%), and poorer 5-year-event free survival (25.0 % vs 69.4%)
	Tumor tissues microarrays	2 patients with 107 tissue samples (48, 59)	IHC, flow cytometry		
Shen et al. [28]	Cell lines	18 osteosarcoma cell lines	qRT-PCR, IHC, flow cytometry	30% of patient samples showed detectable of PD-L1 protein by western blot. Osteosarcoma cell lines ranged from low to high PD-L1 expression, with slightly higher expression from drug-resistant variants (KHOSR2 and U-2OSTR) than their parental cell lines (KHOS and U-2OS) 23.7% (9) high PD-L1 expression, 50% (19) intermediate PD-L1 expression, 10.5% (4) low PD-L1 expression, 15.8% (6) negative for PD-L1 expression.	N/A
	Tumor tissues microarrays	38 (30 metastatic lesion; lung 23, other 7)	qRT-PCR, IHC, flow cytometry		No clinicopathologic features correlation. Median OS for low PD-L1 = 89 months, high = 28 months TILs positivity in 28/38 cases, which significant correlation with PD-L1 expression. Mean PD-L1 expression in pulmonary metastatic lesions was significantly higher than non-pulmonary metastases.
Liao et al. [29]	Cell lines	6 cell lines	Western blot, CRISPR/Cas9	PD-L1 expression was significantly correlated with TILs MNNG/HOS and 143B, highly tumorigenic and metastatic, displayed the most abundant expression of PD-L1. Extremely low in normal osteoblast cell lines (HOB-c, NHOST).	PD-L1 was an important factor involved in osteosarcoma cell growth and drug resistance.
	Tumor tissues microarray	97 samples	IHC	PD-L1 staining: 21.6% (21) 3+, 18.6% (18) 2+, 44.3% (43) 1+, 15.5% (15) no stain.	High PD-L1 expression had a trend of poor response to preoperative chemotherapy, metastasis, and lower overall survival rate
Costa Arantes et al. [30]	Oral osteosarcoma tumor tissues	13 patients	IHC	69.2 % (9/13) high expression of HLA-G, HLA-E, and PD-L1, which 8 high grade and 1 low grade oral osteosarcoma.	No relationship between PD-L1 expression and age at surgery, sex, neoadjuvant chemotherapy treatment, metastasis, or survival.
Sundara et al. [31]	Tumor tissues microarrays	85 samples from 25 patients	IHC	27.8% (22/79 evaluated tumors) showed PD-L1 positivity	PD-L1 positivity was significantly higher in metastatic lesions (48%) compared to local relapses and primary tumors (25 and 13%, respectively; <i>p</i> = 0.004). High density of total TILs significantly correlated with PD-L1 expression
Lussier et al. [32]	Tumor tissues	16 patients	IHC	75% had positive expression of PD-L1 within the metastatic tumor.	Significant correlation between PD-L1 staining and CD8+ TILs in metastatic osteosarcoma
Chowdhury et al. [33]	Tumor tissue	115 pediatric tumors; including 15 osteosarcomas	IHC	PD-L1 expression was observed 47% (7/15) of osteosarcoma patients.	PD-L1 expression + high proportion of CD8+ TILs patients showed significantly better overall survival compared to PD-L1 negative patients.
Raj et al. [34]	Tumor tissue microarrays	161 samples of osteosarcoma	IHC	Increased proportion of CD8+ TILs significantly correlated with PD-1 expression, but not PD-L1. 36% of osteosarcomas were positive for PD-L1 expression.	PD-L1 expression was correlated with clinical outcomes, gender, age and treatment response.

Abbreviations: *Clustered Regularly Interspaced Short Palindromic Repeats/Cas9 system (CRISPR/Cas9), Human leukocyte antigens (HLA), Immunohistochemistry (IHC), Not available (N/A), Overall survival (OS), Programmed cell Death receptor-1 (PD-1), Programmed cell Death receptor-1 ligand-1 (PD-L1), Programmed cell Death receptor-1 ligand-2 (PD-L2), quantitative real time polymerase chain reaction (qRT-PCR), Tumor-infiltrating lymphocytes (TILs).*  
<sup>a</sup> The differences of obtained PD-1, PD-L1, and TILs expression among the eligible studies may have resulted from variations in primary antibodies, staining protocols, evaluating methods of expression, and cutoff values for positivity, which make direct cross-study comparisons challenging.

**Table 3**  
Ongoing trials in immune checkpoints recruiting patients with bone sarcoma.

Trial identifier	Phase	Eligible diseases	Treatment	Primary outcome	Safety
NCT01445379	I	Pediatric advanced solid tumors; 8 of 33 patients was osteosarcoma patients	Ipilimumab	No objective tumor regression. 6 of 33 patients had stable disease (melanoma, osteosarcoma, clear cell sarcoma, synovial sarcoma) 2 of these 6 patients had osteosarcomas. Limited efficacy of nivolumab alone.	irAEs; pancreatitis, pneumonitis, colitis, endocrinopathies, transmittitis. Dose limiting toxicities similar to adults but may be evident after a single dose.
NCT02500797 (Alliance A091401)	II	Unresectable bone and soft tissue sarcomas; Metastatic UPS, Advanced liposarcoma	Nivolumab + ipilimumab	Confirmed responses was 2 (5%) of 38 patients in the nivolumab group and 6 (16%) of 38 patients in combined group. No responses were observed in 9 patients with bone sarcoma in both groups. 7 (18%) of 40 soft tissue sarcoma patients had an objective response. 2 (5%) of 40 bone sarcoma patients had an objective response including osteosarcoma and chondrosarcoma.	19% serious adverse events in nivolumab group, 26% in combination group, including anemia, anorexia, dehydration, ↓ platelet count, diarrhea, fatigue, fever, ↑ creatinine, hyponatremia, pain, pleural effusion. No treatment-related deaths
NCT02301039 (SARC028)	II	Bone and soft tissue sarcoma	Pembrolizumab	None of Ewing's sarcoma patients had and objective response. Preliminary: 3 of 50 patients experienced tumor shrinkage. 1 partial response with PD-L1 positive more than 10%. The 6-month non-progression rate was 0%, 0%, 14.3%, and 11.1% in leiomyosarcoma, UPS, others, and GIST Ongoing	Anemia 14%, decreased lymphocyte count 12%, prolonged APTT 10%, decreased platelet count 7% in bone sarcoma group. 11% off all patients had treatment-emergent serious adverse events; 5 irAEs, 2 adrenal insufficiency, 2 pneumonitis and 1 nephritis
NCT02406781	II	Sarcoma; leiomyosarcoma, UPS, Osteosarcoma, GIST, Sarcoma others	MK-3475 + cyclophosphamide	The most frequent adverse events were grade 1 or 2 fatigue, diarrhea, anemia.	
NCT02304458	I/II	Recurrent or refractory solid tumors or sarcomas, including recurrent osteosarcoma, Ewing's sarcoma, chordoma	Nivolumab + ipilimumab	Ongoing	Ongoing
NCT03190174	I/II	UPS, liposarcoma, chondrosarcoma, osteosarcoma, Ewing's sarcoma	Nivolumab + ABL-009 (Nab-rapamycin)	Ongoing	Ongoing
NCT03006848	II	Relapsed, progressed or refractory osteosarcoma	Avelumab (anti-PD-L1)	Ongoing	Ongoing
NCT03359018	II	Advanced relapsed and unresectable osteosarcoma	SHR1020 (anti-PD-1) + apatinib	Ongoing	Ongoing
NCT02636725	II	Soft tissue sarcomas, untreated chordoma, refractory osteosarcoma, chondrosarcoma, Ewing's sarcoma etc.	Pembrolizumab+ axitinib	Ongoing	Ongoing
NCT02982486	I/II	Bone and soft tissue sarcomas, GIST, Ewing's sarcoma, osteosarcoma, chondrosarcoma, desmoplastic round cell tumor	Nivolumab + ipilimumab	Ongoing	Ongoing
NCT02815995	II	Advanced or metastatic tumors; osteosarcoma arm and other sarcomas	Durvalumab + tremelimumab	Ongoing	Ongoing
NCT02982941	I	Osteosarcoma, Ewing's sarcoma, neuroblastoma, Wilms tumor, rhabdomyosarcoma, desmoplastic round cell tumors	Enoblituzumab (MGA-271) anti-B7H3 antibody	Ongoing	Ongoing
NCT03173950	II	CNS tumor; including chordoma	Nivolumab	Ongoing	Ongoing
NCT02989636	I	Recurrent, advanced, or metastatic chordoma	Nivolumab + stereotactic radiosurgery	Ongoing	Ongoing

(continued on next page)

[28]. This is clinically significant, as expression of PD-L1 correlates with TILs, which often mark metastasis and poorer outcomes [28]. Other studies support these findings and are summarized in Table 2 [30–34]. In a recent systematic meta-analysis of 14 studies with 868 total patients, osteosarcoma had 14–75% higher PD-L1 expression in tumor tissues and significantly correlated with metastasis, mortality risk, and poorer overall survival [23]. The differences of obtained PD-L1 expression among the eligible studies may have resulted from variations in primary antibodies, staining protocols, evaluating methods of expression, and cutoff values for positivity, which make direct cross-study comparisons challenging. Other studies have also shown higher PD-L1 expression in metastatic tumor tissues, especially within the lung, compared to primary tumor tissues [32,35].

Preclinical osteosarcoma mouse model work has shown promising results of anti-PD-1 and anti-PD-L1 blockade therapy [36,37]. Specifically, in an anti-PD-1-antibody-treated humanized mouse model of osteosarcoma, there was significantly fewer pulmonary metastasis compared to control [36]. Similar results were seen in a study investigating the effects of a triple antibody therapy consisting of anti-PD-1, anti-PD-L1, and anti-OX40 (Tumor necrosis factor receptor superfamily, member 4 (TNFRSF4), CD134) in mice transplanted with osteosarcoma. The treatment group had significantly longer survival times compared to the control group, with 50% of the treatment group having no lung metastasis on computerized tomographic (CT) imaging or histological follow-up [37]. These mouse model results show anti-PD-1 and anti-PD-L1 blockade therapy to be potentially promising therapies for patients with advanced osteosarcoma.

In a multicenter phase II trial of anti-PD-1 immunotherapy (pembrolizumab) in advanced bone and soft tissue sarcomas (SARC028), 2 of 40 (5%) bone sarcoma patients had an objective response, including in 1 of the 22 osteosarcoma patients [38]. The most frequent grade 3 or worse immune-related adverse events (irAEs) were anemia (14%), decreased lymphocyte count (12%), prolonged activated partial thromboplastin time (10%), and decreased platelet count (7%) [38]. Five patients in the bone sarcoma group had non-fatal treatment-related serious adverse events such as pneumonitis, interstitial nephritis, and bone pain [38]. Interestingly, PD-L1 expression was observed in only 3 of 70 samples in this trial, all of which were from undifferentiated pleomorphic sarcoma patients in the soft tissue sarcoma group [38]. We enumerate the ongoing early phase clinical trials using anti-PD-1 and anti-PD-L1 antibodies for osteosarcomas in Table 3.

## 2.2. PD-1/PD-L1 in Ewing sarcoma

Ewing sarcoma is a malignant bone or soft tissue tumor that mainly occurs in childhood with a peak incidence at 15 years of age [5]. The bone lesions often arise in the diaphysis of the lower extremity, pelvis, upper extremity, and vertebrae (Fig. 2). Although the 5-year survival rate of localized Ewing sarcoma is 70–80% [5], patient outcomes are considerably worse for those with pelvic involvement, large tumors, or incomplete tumor regression after chemotherapy. In addition, those having metastatic involvement upon initial diagnosis have a 5-year survival of less than 30% [5]. Ewing sarcoma is well-known for its translocation of the EWS gene on chromosome 22 with the FLI1 gene on chromosome 11, as it occurs in more than 90% of cases. However, the EWS gene has a number of less recognizable fusion partners as well, including ETV1, ERG, or the EAI1F gene [39]. This genomic instability forms numerous aberrant protein products potentially recognizable by the immune system and is the rationale for strengthening the host immune response through checkpoint blockade.

In a recent study, PD-L1 expression was observed in 39% of Ewing sarcoma tissues and correlated with treatment response and clinical outcome [34]. In a cohort immunohistochemical analysis of 370 Ewing sarcoma tissue samples, PD-L1 was expressed in 19.2% of the samples while PD-1 expression was 25.7% [40]. Of note, metastatic tumors demonstrated significantly higher PD-L1 expression than primary

Table 3 (continued)

Trial identifier	Phase	Eligible diseases	Treatment	Primary outcome	Safety
NCT02517398	I	Advanced or metastatic tumors; 1 chordoma	M7824 (PD-L1 inhibitor)	1 ongoing confirmed complete response (cervical), 1 durable partial response (pancreatic), a 25% reduction in the sum of diameters of target lesions after 2 doses of M7824 (cervical), and 2 cases of prolonged stable disease (pancreatic; carcinoid).	Grade 3 drug-related irAEs occurred in 3 patients (skin infection secondary to grade 2 bullous pemphigoids, lipase increased, and colitis with associated anemia; there were no grade 4–5 irAEs)
NCT02834013 (NCI DART trail)	II	Advanced rare tumors	Nivolumab + ipilimumab	Ongoing	Ongoing
NCT03012620	II	Advanced tumors	Pembrolizumab	Ongoing	Ongoing

Abbreviations: APTT – activated partial thromboplastin time, GIST – gastrointestinal stromal tumor, irAEs – immune-related adverse events, UPS – undifferentiated pleomorphic sarcoma.



**Table 4**  
Studies of PD-1, PD-L1, and TILs expression in Ewing sarcoma<sup>a</sup>.

Author	Type of tumor	Samples/cases	Methods	PD-1, PD-L1, and TILs	Clinical correlation
Torabi et al. [26]	Cell lines	4 cell lines including A673 – Ewing's sarcoma cell line	Western blot	PD-L1 was detected in all of the 4 cell lines.	N/A
Chowdhury et al. [33]	Tumor tissue	115 pediatric tumors; including 14 Ewing's sarcomas	qRT-PCR IHC	PD-1 mRNA is higher compared to PD-L1 PD-L1 expression was observed 57% (8/14) of Ewing's sarcoma patients. Increased proportion of CD8 + TILs significantly correlated with PD-1 expression, but not PD-L1.	PD-L1 expression + high proportion of CD8 + TILs patients showed significantly better OS compared to PD-L1 negative patients.
Raj et al. [34]	Tumor tissue microarrays	33 samples of Ewing's sarcoma	IHC	39% of Ewing's sarcomas were positive for PD-L1 expression.	PD-L1 expression was correlated with clinical outcomes, gender, age and treatment response.
Machado et al. [40]	Tumor tissue microarrays	370 tissue samples	IHC	PD-1 was expressed in 26% PD-L1 was expressed in 19% Of these group, 12% were positive for both PD-1 and PD-L1. TILs were observed in 15.4%	Lack of PD-1 expression correlated with poor progression-free survival and OS. PD-L1 significantly correlated with metastasis. No statistically significant correlations between PD-L1 expression and histologic subtypes, progression-free survival or OS. No correlations between TILs and other parameters, including PD-1 and PD-L1.

Abbreviations: Clustered Regularly Interspaced Short Palindromic Repeats/Cas9 system (CRISPR/Cas9), Human leukocyte antigens (HLA), Immunohistochemistry (IHC), Not available (N/A), Overall survival (OS), Programmed cell Death receptor-1 (PD-1), Programmed cell Death receptor-1 ligand-1 (PD-L1), Programmed cell Death receptor-1 ligand-2 (PD-L2), quantitative real time polymerase chain reaction (qRT-PCR), Tumor-infiltrating lymphocytes (TILs).

<sup>a</sup> The differences of obtained PD-1, PD-L1, and TILs expression among the eligible studies may have resulted from variations in primary antibodies, staining protocols, evaluating methods of expression, and cutoff values for positivity, which make direct cross-study comparisons challenging.

tumors [40]. While TILs were also found in 15.4% of the samples in the same study, there was no significant correlation between TILs and histological subtype, location, PD-1 expression, PD-L1 expression, clinical outcome, or prognosis [40]. More supportive evidence was found in another analysis of PD-L1 expression in patients with soft tissue sarcomas, as 33% of Ewing sarcoma tissue samples expressed PD-L1 and significantly correlated with shorter survival time [41]. We outline these studies and more in Table 4.

Despite robust preclinical data, the clinical application of anti-PD-1 blockade in Ewing sarcoma remains largely unexplored. In a case report, a heavily pre-treated patient with recurrent metastatic Ewing sarcoma of the vertebral bodies experienced complete resolution of pulmonary metastases and vertebral and paravertebral soft tissue lesions following nine cycles of pembrolizumab therapy without serious irAEs [39]. A more recent phase II trial evaluated the efficacy of pembrolizumab for advanced soft tissue and bone sarcomas (SARC028), with 13 Ewing sarcoma patients enrolled in the bone sarcoma group [38]. However, none of these patients had an objective response, including 11 patients (85%) with progressive disease and 2 patients (15%) with stable disease [38]. Because Ewing sarcoma has considerable genomic instability, this may contribute to the variable patient response to anti-PD-1 blockade; nevertheless, this treatment should not be utilized for patients with Ewing sarcoma outside of clinical trials given the poor responses in the SARC028 trial. The variability of clinical response underlines the need for revealing which predictive biomarkers correlate with a strong response to anti-PD-1 therapy. The ongoing clinical trials assessing anti-PD-1 blockade therapy for Ewing sarcoma are summarized in Table 3.

### 2.3. PD-1/PD-L1 in chondrosarcoma

Chondrosarcomas are cartilaginous bone malignancies with increasing incidence up to 75 years of age [6,7]. Conventional chondrosarcomas account for nearly 90% of all chondrosarcomas and are mostly low to intermediate-grade malignancies [6,7]. The prominent sites affected include the metaphysis of the long bones, pelvis, shoulder girdle, ribs, and sternum, with axial lesions often presenting with a higher-grade appearance [6,7]. Except for the mesenchymal subtype, most chondrosarcomas are relatively resistant to chemotherapy and radiation. Clinical outcomes range from a 24% 5-year survival rate for dedifferentiated chondrosarcoma to an 90% 5-year survival for conventional chondrosarcoma [6,7].

Several immunohistochemical studies have focused on PD-1 and PD-L1 in chondrosarcoma and are listed in Table 5 [26,42,43]. Increased expression of PD-1 was observed within chondrosarcoma tissues compared to healthy bone tissue controls and benign osteochondromas [26]. PD-L1 expression has also been studied in various subtypes of chondrosarcomas with significant results. Expression of PD-L1 was observed in 41% of dedifferentiated chondrosarcomas and significantly correlated with TILs and HLA class I expression, but not for overall survival [42]. A more recent study revealed PD-L1 expression in 67.8% and PD-L2 expression in 42.4% of 59 conventional chondrosarcoma tissue samples [43]. Investigators found PD-L1 expression to correlate with younger age (<30 years), larger tumor size (>10 cm), high tumor grade, and recurrence [43]. When evaluated in tandem, combined PD-L1 and PD-L2 expression significantly correlated with earlier recurrence as well [43]. Overall, these findings support the potential of anti-PD-1 blockade therapy for the treatment of chondrosarcoma within clinical trials.

Despite promising preclinical work, clinical studies of immune checkpoint inhibitors in chondrosarcoma remain sparse, as the majority of available data has been drawn from clinical trials focused on diverse sarcoma types. In the SARC028 clinical trial, one of five chondrosarcoma patients treated with pembrolizumab had an objective response [38]. Another study showed a partial response in a 74-year-old patient with dedifferentiated chondrosarcoma after six cycles of

**Table 5**  
Studies of PD-1, PD-L1, and TILs expression in chondrosarcoma<sup>a</sup>.

Author	Type of tumor	Samples/cases	Methods	PD-1, PD-L1, and TILs	Clinical correlation
Torabi et al. [26]	Tumor tissue microarrays	10 chondrosarcoma tissue samples	IHC	9/10 chondrosarcoma tissue samples were positive PD-1 staining. The mean PD-1 expression scores significantly in the order: osteosarcoma > chondrosarcoma > benign osteochondroma.	N/A
Kostine et al. [42]	Tumor tissue microarrays	119 conventional- 19 mesenchymal- 20 clear cell- 22 dedifferentiated chondrosarcoma tissue samples 59 tissue samples	IHC	41% (9/22) of dedifferentiated chondrosarcoma showed PD-L1 expression, which was correlated with high number of TILs and HLA class I expression. None of conventional, mesenchymal, and clear cell chondrosarcoma had PD-L1 expression	Poorer, insignificantly, median OS in PD-L1 positive group. (10 months vs 19 months) compared with PD-L1 negative group
Yang et al. [43]	Tumor tissue	40/59 showed PD-L1 positive 25/59 showed PD-L2 positive	IHC		PD-L1 expression significantly correlated with younger age, larger tumor, higher grade, and recurrence. PD-L2 expression correlated only with younger age. Combined positivity was significantly associated with earlier recurrence.

Abbreviations: Clustered Regularly Interspaced Short Palindromic Repeats/Cas9 system (CRISPR/Cas9), Human leukocyte antigens (HLA), Immunohistochemistry (IHC), Not available (N/A), Overall survival (OS), Programmed cell Death receptor-1 (PD-1), Programmed cell Death receptor-1 ligand-1 (PD-L1), Programmed cell Death receptor-1 ligand-2 (PD-L2), quantitative real time polymerase chain reaction (qRT-PCR), Tumor-infiltrating lymphocytes (TILs).

<sup>a</sup> The differences of obtained PD-1, PD-L1, and TILs expression among the eligible studies may have resulted from variations in primary antibodies, staining protocols, evaluating methods of expression, and cutoff values for positivity, which make direct cross-study comparisons challenging.

nivolumab [44]. Ongoing early phase clinical trials on chondrosarcomas are testing immune checkpoint blockades in combination with the anti-CTLA-4 inhibitor (NCT02982486) and mTOR inhibitor (NCT03190174), as shown in Table 3.

#### 2.4. PD-1/PD-L1 in chordoma

Chordomas are very rare bone malignancies with a high rate of recurrence. Their incidence is 0.08 per 100,000 people and peaks during the sixth decade of life [8]. The chordomas which occur in those less than 40 years of age account for less than 5% of all chordoma cases. The most common sites for chordomas include the sacrum, skull base, and vertebra (Fig. 2). Despite their overall infrequency, chordomas constitute over 50% of all primary neoplasms in the sacrum. Their insidious onset and local invasion of vital nervous system structures complicates clinical management and is a significant contributor to morbidity and mortality. The survival analysis of chordoma from the SEER database reports 67.6%, 39.9%, and 13.1% 5-year, 10-year, and 20-year overall survival rates respectively, with a median survival of 6.29 years [2,8].

Previous investigation has shown PD-L1 to have considerable variation of expression in chordoma cell lines [45]. Interestingly, in this same work, 94.9% of 78 chordoma tissue samples stained positive for PD-L1 [45]. The expression of PD-L1 significantly correlated with elevated TILs and metastasis [45]. In another study focused on spinal chordomas, 68.5% of 54 chordoma tissue samples were positive for both PD-1 and PD-L1 expression, 70.4% of which had positive PD-1 expression in TILs [46]. PD-L1 expression was significantly associated with advanced stage and TILs. Moreover, multivariate analysis revealed PD-L1 expression in TILs as an independent predictor for poor local recurrence-free survival and overall survival [46]. In another work, TILs were observed in six out of ten chordoma tissue samples, three of which had PD-1 expression and four of which had PD-L1 expression in areas of tissue associated macrophages and TILs [47]. These studies, which help elucidate immune checkpoint therapy for chordomas, are summarized in Table 6.

Several ongoing clinical trials are evaluating the utility of anti-PD-1 and anti-PD-L1 agents in chordoma patients, as summarized in Table 3. Of these, one trial is employing the use of nivolumab (NCT03173950). Another phase I trial is investigating the safety and efficacy of nivolumab combined with stereotactic radiosurgery in patients with recurrent, advanced, or metastatic chordoma (NCT02989636). Recruitment is also underway for the DART trial (Dual Anti-CTLA-4 and Anti-PD-1 blockade in Rare Tumors, NCT02834013) which seeks to evaluate the clinical response and toxicities of ipilimumab plus nivolumab combination therapy in chordoma. The results of these trials have expected publication dates in the near future.

### 3. CTLA-4

CTLA-4 (CD152) is a protein receptor expressed on the T lymphocyte surface that plays a crucial role during T cell activation. In normal immunity, T cell activation is initiated when antigen is presented to the T cell receptor (TCR) by MHC class I or II on the antigen presenting cell (APC), which is amplified by a costimulatory signal in the form of CD28 on the T cell binding to B7-1 (CD80) or B7-2 (CD86) on tumor cells or APCs [48]. Following this activation, CTLA-4 is potentially transported from an intracellular compartment to the T cell surface, where it binds to B7-1 and B7-2 with greater affinity than CD28 and subsequently downregulates the immune response, as shown in Fig. 3 [48]. This is a mechanism of peripheral tolerance to mitigate an overactivated immune response in a normal physiological state. CTLA-4 inhibitory signals are quite complex, as they may also inhibit interleukin-2 transcription within the T cells, Src homology domain-containing tyrosine phosphatases (SHP-1, SHP-2, and PP2A), and trans-endocytosis of B7-1 and B7-2 [48]. CTLA-4 is also expressed on regulatory T lymphocytes

**Table 6**  
Studies of PD-1, PD-L1, and TILs expression in chordoma<sup>a</sup>.

Author	Type of tumor	Samples/cases	Methods	PD-1, PD-L1, and TILs	Clinical correlation
Feng et al. [45]	Cell lines	3 cell lines UCH1 UCH2 CH22 9 tissue samples	Western blot IHC	PD-L1 was expressed in these 3 cell lines. PD-L1 protein expressions were induced 16-fold and 4-fold by IFN- $\gamma$ in UCH1 and UCH2, respectively. PD-L1 protein was expressed in these sample. 3/9 samples: high expression 2/9 samples: intermediate expression 4/9 samples: low expression 94.9% positive for PD-L1 expression, which 42.9% of these samples showed high expression. 29.5% prominent TILs	N/A N/A
Zou et al. [46]	Tumor tissues microarrays	78 tissue samples from 56 patients 54 spinal chordoma patients	IHC IHC qRT-PCR	PD-L1 protein expression was significantly associated with elevated TILs, which correlated with metastasis. 68.5% (37/54 samples) showed PD-L1 expression. miR-574-3p (micro RNA) was inversely correlated with PD-L1 expression.	Poorer median OS for high PD-L1 expression group. (81 vs 145 months, $P = 0.0532$ ) Significantly higher median PD-L1 expression score for the metastatic tumors. No correlation with PD-L1 expression and age, gender or tumor location. Positive PD-L1 expression was significantly correlated with advanced stages, and TILs. miR-574-3p could regulate PD-L1 expression in chordoma.
Mathios et al. [47]	Cell lines	3 cell lines UCH1 UCH2 JHC7 10 cases	Flow cytometry qRT-PCR IHC	All cell lines expressed basal levels of PD-L1 and PD-L2 in <5% of total number of cells. Stimulation with IFN- $\gamma$ resulted in significant upregulation of PD-L1 in these cell lines, confirmed by mRNA of PD-L1 and PD-L2 TILs were observed in 6/10 cases. Of these cases, 3/6 showed PD-1 expression by immune cells and 4/6 showed membranous PD-L1 expression.	Decrease miR-574-3p significantly correlated with higher muscle invasion, tumor necrosis, and poorer OS. N/A N/A

Abbreviations: Clustered Regularly Interspaced Short Palindromic Repeats/Cas9 system (CRISPR/Cas9), Human leukocyte antigens (HLA), Immunohistochemistry (IHC), Not available (N/A), Overall survival (OS), Programmed cell Death receptor-1 (PD-1), Programmed cell Death receptor-1 ligand-1 (PD-L1), Programmed cell Death receptor-1 ligand-2 (PD-L2), quantitative real time polymerase chain reaction (qRT-PCR), Tumor-infiltrating lymphocytes (TILs).  
<sup>a</sup> The differences of obtained PD-1, PD-L1, and TILs expression among the eligible studies may have resulted from variations in primary antibodies, staining protocols, evaluating methods of expression, and cutoff values for positivity, which make direct cross-study comparisons challenging.

(Treg) which control effector T lymphocyte function and promote immune tolerance [48]. As expected, blockade of the CTLA-4 receptor increases CD8+ T lymphocyte activation and depletes Treg action. Allison and co-workers demonstrated that combining anti-CTLA-4 antibody with tumor lysate-loaded dendritic cells increased CD8+ TIL, reduced Tregs, inhibited metastasis, and prolonged survival in a mouse model with colon cancer or fibrosarcoma [49]. In another notable work, a human monoclonal IgG1 anti-CTLA-4 antibody (also known as ipilimumab) markedly lengthened median overall survival for metastatic melanoma patients [50,51]. Thus far, anti-CTLA-4 blockade has been successfully used to treat advanced melanoma and carcinomas such as non-small cell lung cancer, renal cell carcinoma, and prostate cancer [52–54]. As a prominent breakthrough treatment, researchers are exploring its potential for other solid tumors, including bone sarcomas.

In a phase I clinical trial of advanced stage pediatric solid tumors, 6 of 33 patients had progression stabilization with ipilimumab, including 2 (25%) of 8 osteosarcoma patients with acceptable irAEs [55]. Interestingly, the overall survival was better in patients with irAEs compared to those without irAEs [55]. Emerging clinical data suggests anti-CTLA-4 antibody therapy may be most useful as part of a combination therapy rather than a stand-alone monotherapy [56].

#### 4. Combination immunotherapy in bone sarcomas

##### 4.1. Combination PD-1 and CTLA-4 blockade therapy

The ultimate goal of checkpoint blockade immunotherapy is to achieve long-term disease control in patients unresponsive to current treatment options. To this end, checkpoint blockade combination therapy is an emerging strategy for improving efficacy with acceptable toxicity. In a double-blind study of combined ipilimumab and nivolumab treatment in 142 patients with untreated advanced melanoma, there was an overall response rate of 61% versus 11% in the ipilimumab-monotherapy group, with 22% compared to 0% having a complete response [56]. These results granted combination ipilimumab/nivolumab therapy FDA approval for advanced melanoma and have since prompted a combination-based approach for various other cancers, including bone sarcoma. In an osteosarcoma mouse model study, a combination therapy of anti-PD-L1 with anti-CTLA-4 antibody completely controlled metastatic osteosarcoma and showed a long-term disease-free survival of 60%. This was markedly better than the 0% long-term disease-free survival seen in the mice receiving anti-PD-L1 blockade monotherapy [57]. In a phase II study of nivolumab with or without ipilimumab for metastatic sarcoma (Alliance A091401), the number of confirmed responses was 2 (5%) of 38 patients in the nivolumab group and 6 (16%) of 38 patients in the combined group [58]. Median progression-free survival and overall survival in the combination group were 4.1 and 14.3 months, respectively, which was much improved over the 1.7 and 10.7 months seen in the monotherapy group. There were, however, no objective responses seen in the nine patients with bone sarcomas in either group [58]. Serious irAEs occurred in 8 (19%) of 42 patients receiving monotherapy and 11 (26%) of the 42 patients receiving combination therapy; there were no treatment-related deaths in either group [58]. In summary, while this clinical trial is ongoing (NCT02500797), combination therapy has already demonstrated improved efficacy and a manageable safety profile compared to current treatment options in preclinical models. In Table 3, we analyze various early phase clinical trials focused on osteosarcoma treatment regimens composed of combination anti-PD-1/PD-L1 and anti-CTLA-4 blockade therapy alone or with other chemotherapeutics.

##### 4.2. Combination immune checkpoint blockade and radiation

Although radiation therapy has classically been considered a measure of pure local control, amounting evidence has shown radiation

alone can improve systemic immune response and regress distant metastasis, a phenomenon known as “the abscopal effect” [59]. This antitumor immune response is largely explained by a strengthened CD4+ and CD8+ T lymphocyte response [60] and a likely contributing factor of enhanced immune checkpoint blockade response. The addition of immune checkpoint inhibition with radiotherapy therefore has the potential to improve clinical outcomes, and is evidenced in patients with bone sarcomas with concurrent micro-metastasis [61].

Previous case series have suggested the synergistic effect of ipilimumab with multiple fraction radiation on out-of-field lesions of metastatic melanoma [62]. Ongoing clinical trials are investigating the combination of immune checkpoint blockade, especially PD-1, PD-L1, and CTLA-4, with radiation in patients with advanced melanoma, non-small cell lung cancer, head and neck cancer, liver cancer, prostate cancer, and lymphoma [63]. To our knowledge, there are no randomized controlled trials showing immune checkpoint blockade therapy combined with radiation to be superior to single treatment alone in treatment-naïve patients. Moreover, the clinical trials recruiting bone sarcoma patients for this treatment regimen is scarce. There is, however, an ongoing phase I trial comparing combination nivolumab with stereotactic radiosurgery to nivolumab alone in the treatment of advanced chordoma (NCT02989636). As this trial is still active, no results have yet been published.

##### 4.3. Combination immune checkpoint blockade and targeted therapy or chemotherapy

Although studies of combination immune checkpoint blockade therapy, chemotherapy, or targeted therapy have expanded for soft tissue sarcomas, including with cyclophosphamide (NCT02406781), trabectedin (NCT03138161), doxorubicin (NCT02888665), gemcitabine (NCT03123276), or dasatinib (NCT01643278), recruitment for study in their bone sarcoma counterparts have been relatively limited. A previous retrospective trial studied the effect of nivolumab with pazopanib, a tyrosine kinase vascular endothelial growth factor inhibitor, in a group of 28 sarcoma patients which included four bone sarcoma patients [44]. There were three partial responses observed, which included a case of dedifferentiated chondrosarcoma, epithelioid sarcoma, and maxillary osteosarcoma, with the last two patients having received concomitant pazopanib [44]. Of note, a clinical benefit was observed in half of the evaluable patients after >4 cycles of nivolumab. The ongoing trials investigating a combination of targeted therapy or chemotherapy with immune checkpoint blockade are shown in Table 3.

#### 5. Other immune checkpoints studied in bone sarcoma

##### 5.1. B7-H3

B7 homolog 3 (B7-H3, CD276) is an inhibitory protein of the B7-CD28 family with vital roles in the inhibition of T cell activation, proliferation, and cytokine production (Fig. 3) [64]. It is expressed in various other immune cells as well, including APCs, NK cells, and B cells. B7-H3 overexpression is present in multiple cancers such as melanoma, non-small-cell lung cancer, osteosarcoma, and rhabdomyosarcoma [64–66]. Notably, it is expressed in 91.8% of osteosarcoma tissues, which is significantly higher than adjacent healthy tissue, osteochondroma, and fibrous dysplasia [65]. Tumor B7-H3 expression inversely correlates with the number of TILs and promotes osteosarcoma cell invasion [65]. It has also been reported that patients with high B7-H3 expression levels have significantly shorter survival and recurrence times compared to those with low expression [65].

As a result of these findings, there has been an expansion of work focused on the efficacy of antibodies against B7-H3. Enoblituzumab (MGA271), a humanized IgG1 monoclonal antagonistic B7-H3 antibody, has been studied in a phase I clinical trial in patients with refractory B7-H3-expressing neoplasms such as melanoma and advanced

solid tumors (NCT01391143). Patients experienced stable disease (>12 weeks) and 2–69% tumor shrinkage with good tolerance and no dose-limiting toxicity. Another ongoing study is investigating enoblituzumab in children with B7-H3-expressing solid tumors such as neuroblastoma, rhabdomyosarcoma, osteosarcoma, Ewing sarcoma, Wilms' tumor, and desmoplastic small round cell tumors (NCT02982941). MGD-009, a humanized dual affinity re-targeting (DART) protein that binds both CD3 on T cells and B7-H3 on its target cell, is another agent in an ongoing phase I clinical trial for patients with mesothelioma, melanoma, non-small cell lung cancer, head and neck squamous cell carcinoma, or soft tissue sarcoma (NCT02628535).

### 5.2. NKG2D/NKG2DL

NK cell activating receptor group 2 member D (NKG2D) and its associated ligand (NKG2DL) have crucial roles in innate immunity. Functionally, NKG2D is a co-stimulatory transmembrane protein receptor belonging to the CD94/NKG2 family and is found in CD8+ T lymphocytes, some  $\gamma\delta$  T cells, and activated macrophages [67]. NKG2DLs are rarely expressed in healthy cells, as they are primarily upregulated in response to infection and malignant transformation [67]. At the cellular level, binding of NKG2D/NKG2DLs triggers NK cell activation via PI3K (phosphatidylinositol-3 kinase) and Grb2-Vav1 (growth factor receptor-bound protein 2, vav guanine nucleotide exchange factor 1) pathways, resulting in the release of cytotoxic granules and eventual tumor cell apoptosis [67]. As a protective mechanism, advanced cancer cells can evade this immunosurveillance by down-regulating or shedding NKG2DLs [67]. In summary, NKG2DL expression, its downstream pathway, and NK cell cytotoxicity are all instrumental in the NKG2D/NKG2DL system and promising areas for novel cancer research.

To this point, one such study revealed moderate to high levels of NKG2DL expression in all 22 osteosarcoma cell lines they investigated [68]. Of these cell lines, every one of the 14 primary osteosarcoma cell lines under investigation was sensitive to the cytotoxicity induced from an NK cell-mediated NKG2D/NKG2DL interaction. However, higher expression of NKG2DLs did not correlate with increased sensitivity [68]. The authors also found that spironolactone, a diuretic drug, could upregulate NKG2DL expression in primary osteosarcoma cell lines and significantly increased the sensitivity of tumor cells to NK cell mediated cytotoxicity from a NKG2D/NKG2DL interaction [68]. Another work showed significantly increased cytolytic activity of NKG2D-CAR+ (chimeric antigen receptor) T-lymphocytes against osteosarcoma cell lines *in vitro* and in murine osteosarcoma while preserving healthy cells [69]. A recent study was conducted on the effectiveness of  $\gamma\delta$  T cell based immunotherapy combined with the DNA demethylating drug decitabine in osteosarcoma [70]. They showed good results, as decitabine increased osteosarcoma cell NKG2D ligand expression which subsequently increased their vulnerability to cytotoxic  $\gamma\delta$  T cells [70].

They investigated Ewing sarcoma in this same study and with flow cytometry showed 14 different Ewing sarcoma cell lines broadly express NKG2DL [71]. The authors also used a lentivirus to fuse a CD3 $\zeta$ /CD28-derived signaling domain to NKG2D to create NKG2D-CAR+ T lymphocytes capable of evoking Ewing sarcoma cell death [71]. These results have prompted researchers to explore additional ways of strengthening the NKG2D/NKG2DL axis in bone sarcomas.

### 5.3. HLA-G

Recently, the non-classical MHC class I molecule HLA-G has been recognized for its important role in regulating immune responses. HLA-G has an inhibitory effect on the NK cell and T cell response and is expressed on mesenchymal stromal cells, T lymphocytes, and various cancers. One recent study showed HLA-G expression in 34.0% of pre-treated Ewing sarcoma biopsies and 33.3% of relapsed tumor biopsies with regards to both the tumor cells and TILs [72]. While HLA-G

expression significantly correlates with increased TILs, no association has been made with other clinical variables [72]. The authors posit that modulation of HLA-G expression within the tumor microenvironment might attenuate resistance to NK cell therapy and therefore enhance the efficacy of immunotherapy for Ewing sarcoma. However, further work is needed to better verify this proposed effect.

## 6. Future direction

Immune checkpoint inhibitors are generating considerable interest for their potential in bone sarcoma treatment, and will likely continue to do so as ongoing clinical trials begin to report on their results. At present, studies have shown highly variable levels of PD-1 and PD-L1 expression in bone sarcomas as well as their inverse correlation with prognosis. However, as of now, PD-1 and PD-L1 expression has not reliably predicted patient response to treatment [73]. As this is an emerging field in sarcoma research, future study is needed to better analyze this phenomenon. As there is a high variability of PD-1 and PD-L1 expression in patients, it may be useful to identify biomarkers for the initiation of blockade therapy. In addition, as the prognostic and predictive value of TILs, MHC, PD-1/PD-L1, and CTLA-4 continues to emerge within the cancer immunotherapy literatures, it is likely that standardized screening biomarkers will be revealed. From this, the best candidates for immune checkpoint therapy may become evident especially as emerging technologies such as liquid biopsy make personalized medicine less invasive in sarcoma therapy [74].

Combination immune checkpoint blockade treatment regimens have demonstrated a superior clinical response compared to single checkpoint blockade therapy. It is therefore essential to find and titrate the appropriate combination of checkpoint blockade drugs which has acceptable irAEs while maintaining maximum efficacy. This is an active area of investigation, especially within the realm of chemotherapy for immunocompromised patients.

We have reviewed the major and emerging checkpoint inhibitors for bone sarcomas herein. There are, however, a number of newer immune checkpoint targets such as LAG-3, TIM3, VISTA, OX40, GITR, 4-1BB, and IDO which have shown promising results in various cancers such as melanoma, breast cancer, non-small cell lung cancer, renal cell carcinoma, and squamous cell carcinoma of head and neck [75]. Few data exist for these newer targets in bone sarcoma, and the efficacy of their inhibition within bone and soft tissue sarcomas is relatively unknown.

## 7. Conclusion

Immune checkpoint blockade therapy has demonstrated remarkable clinical outcomes in malignancies such as metastatic melanoma, renal cell carcinoma, lung cancer, and breast cancer. As an emerging therapeutic approach, these achievements have driven research seeking to reveal their potential for patients with bone sarcomas. Much of the current sarcoma research, from the basic studies to the clinical trials of immune checkpoint blockade, are under ongoing investigation with results expected to be published in the near future. Primary outcomes for these trials include efficacy of treatment in various bone sarcomas as a single agent or as combination therapy and their potential immune-related adverse effects. Continued clinical trial efforts are especially crucial for bone sarcomas, as they are a heterogeneous group of tumors which require detailed study to accurately capture all immune checkpoint targets. Discovery of predictive biomarkers for the efficacy is also an essential next step, as this may allow for personalized medicine within the field of bone sarcomas related immune checkpoint blockade therapy.

## Acknowledgments

This work was supported, in part, by the Department of Orthopaedic Surgery at UCLA. Dr. Duan is supported, in part, through a Grant from

Sarcoma Foundation of America (SFA), 222433, a Grant from National Cancer Institute (NCI)/National Institutes of Health (NIH), UO1, CA151452-01.

### Conflict of interest

The authors declare that there are no conflicts of interest.

### References

- [1] R.L. Siegel, K.D. Miller, A. Jemal, Cancer statistics, 2018, *CA Cancer J. Clin.* 68 (1) (2018) 7–30.
- [2] SEER Cancer Stat Facts: Bone and Joint Cancer. National Cancer Institute. Bethesda, MD, <http://seer.cancer.gov/statfacts/html/bones.html>.
- [3] A.K. Raymond, A.G. Ayala, S. Knuutila, Conventional osteosarcoma. In: World Health Organization Classification of Tumours, Pathology and Genetics of Tumours of Soft Tissue and Bone, in: C.D.M. Fletcher, K.K. Unni, F. Mertens (Eds.), IARC Lyon, vol. 4, 2002, pp. 264–270.
- [4] M.S. Isakoff, S.S. Bielack, P. Meltzer, R. Gorlick, Osteosarcoma: current treatment and a collaborative pathway to success, *J. Clin. Oncol.* 33 (27) (2015) 3029–3035.
- [5] T.G.P. Grunewald, F. Cidre-Aranaz, D. Surdez, E.M. Tomazou, E. de Alava, H. Kovar, P.H. Sorensen, O. Delattre, U. Dirksen, Ewing sarcoma, *Nat. Rev. Dis. Primers* 4 (1) (2018) 5.
- [6] A. Angelini, G. Guerra, A.F. Mavrogenis, E. Pala, P. Picci, P. Ruggieri, Clinical outcome of central conventional chondrosarcoma, *J. Surg. Oncol.* 106 (8) (2012) 929–937.
- [7] A.J. Gelderblom, MD, Chondrosarcoma. Post TW, ed. UpToDate. Waltham, MA: UpToDate Inc. <http://www.uptodate.com/contents/chondrosarcoma> (Accessed on August 17, 2017).
- [8] B.P. Walcott, B.V. Nahed, A. Mohyeldin, J.V. Coumans, K.T. Kahle, M.J. Ferreira, Chordoma: current concepts, management, and future directions, *Lancet Oncol.* 13 (2) (2012) e69–e76.
- [9] D.C. Dean, S. Shen, F.J. Hornicek, Z. Duan, From genomics to metabolomics: emerging metastatic biomarkers in osteosarcoma, *Cancer Metastasis Rev.* (2018).
- [10] P.A. Thompson, M. Chintagumpala, Targeted therapy in bone and soft tissue sarcoma in children and adolescents, *Curr. Oncol. Rep.* 14 (2) (2012) 197–205.
- [11] K.M. Mahoney, P.D. Rennett, G.J. Freeman, Combination cancer immunotherapy and new immunomodulatory targets, *Nat. Rev. Drug Discov.* 14 (8) (2015) 561–584.
- [12] J.D. Wolchok, V. Chiarion-Sileni, R. Gonzalez, P. Rutkowski, J.J. Grob, C.L. Cowey, C.D. Lao, J. Wagstaff, D. Schadendorf, P.F. Ferrucci, M. Smylie, R. Dummer, A. Hill, D. Hogg, J. Haanen, M.S. Carlino, O. Bechter, M. Maio, I. Marquez-Rodas, M. Guidoboni, G. McArthur, C. Lebbe, P.A. Ascierto, G.V. Long, J. Cebon, J. Sosman, M.A. Postow, M.K. Callahan, D. Walker, L. Rollin, R. Bhole, F.S. Hodi, J. Larkin, Overall survival with combined nivolumab and ipilimumab in advanced melanoma, *N. Engl. J. Med.* 377 (14) (2017) 1345–1356.
- [13] C. Robert, J. Schachter, G.V. Long, A. Arance, J.J. Grob, L. Mortier, A. Daud, M.S. Carlino, C. McNeil, M. Lotem, J. Larkin, P. Lorigan, B. Neyns, C.U. Blank, O. Hamid, C. Mateus, R. Shapira-Frommer, M. Kosh, H. Zhou, N. Ibrahim, S. Ebbinghaus, A. Ribas, KEYNOTE-006 investigators, Pembrolizumab versus ipilimumab in advanced melanoma, *N. Engl. J. Med.* 372 (26) (2015) 2521–2532.
- [14] R.S. Herbst, P. Baas, D.W. Kim, E. Felip, J.L. Perez-Gracia, J.Y. Han, J. Molina, J.H. Kim, C.D. Arvis, M.J. Ahn, M. Majem, M.J. Fidler, G. de Castro Jr., M. Garrido, G.M. Lubiniecki, Y. Shentu, E. Im, M. Dilled-Filhart, E.B. Garon, Pembrolizumab versus docetaxel for previously treated, PD-L1-positive, advanced non-small-cell lung cancer (KEYNOTE-010): a randomised controlled trial, *Lancet* 387 (10027) (2016) 1540–1550.
- [15] M. Reck, D. Rodriguez-Abreu, A.G. Robinson, R. Hui, T. Csozsi, A. Fulop, M. Gottfried, N. Peled, A. Tafreshi, S. Cuffe, M. O'Brien, S. Rao, K. Hotta, M.A. Leiby, G.M. Lubiniecki, Y. Shentu, R. Rangwala, J.R. Brahmer, KEYNOTE-024 Investigators, Pembrolizumab versus chemotherapy for PD-L1-positive non-small-cell lung cancer, *N. Engl. J. Med.* 375 (19) (2016) 1823–1833.
- [16] R.J. Motzer, B. Escudier, D.F. McDermott, S. George, H.J. Hammers, S. Srinivas, S.S. Tykodi, J.A. Sosman, G. Procopio, E.R. Plimack, D. Castellano, T.K. Choueiri, H. Gurney, F. Donskov, P. Bono, J. Wagstaff, T.C. Gauler, T. Ueda, Y. Tomita, F.A. Schutz, C. Kollmannsberger, J. Larkin, A. Ravaud, J.S. Simon, L.A. Xu, I.M. Waxman, P. Sharma, I. CheckMate, Nivolumab versus everolimus in advanced renal-cell carcinoma, *N. Engl. J. Med.* 373 (19) (2015) 1803–1813.
- [17] R.J. Motzer, N.M. Tannir, D.F. McDermott, O. Aren Frontera, B. Melichar, T.K. Choueiri, E.R. Plimack, P. Barthelemy, C. Porta, S. George, T. Powles, F. Donskov, V. Neiman, C.K. Kollmannsberger, P. Salman, H. Gurney, R. Hawkins, A. Ravaud, M.O. Grimm, S. Bracarda, C.H. Barrios, Y. Tomita, D. Castellano, B.I. Rini, A.C. Chen, S. Mekan, M.B. McHenry, M. Wind-Rotolo, J. Doan, P. Sharma, H.J. Hammers, B. Escudier, I. CheckMate, Nivolumab plus ipilimumab versus sunitinib in advanced renal-cell carcinoma, *N. Engl. J. Med.* 378 (14) (2018) 1277–1290.
- [18] R.L. Ferris, G. Blumenschein Jr., J. Fayette, J. Guigay, A.D. Colevas, L. Licitra, K. Harrington, S. Kasper, E.E. Vokes, C. Even, F. Worden, N.F. Saba, L.C. Iglesias Docampo, R. Haddad, T. Rordorf, N. Kiyota, M. Tahara, M. Monga, M. Lynch, W.J. Geese, J. Kopit, J.W. Shaw, M.L. Gillison, Nivolumab for recurrent squamous-cell carcinoma of the head and neck, *N. Engl. J. Med.* 375 (19) (2016) 1856–1867.
- [19] M.W. LaFleur, Y. Muroyama, C.G. Drake, A.H. Sharpe, Inhibitors of the PD-1 pathway in tumor therapy, *J. Immunol.* 200 (2) (2018) 375–383.
- [20] S.D. Wang, H.Y. Li, B.H. Li, T. Xie, T. Zhu, L.L. Sun, H.Y. Ren, Z.M. Ye, The role of CTLA-4 and PD-1 in anti-tumor immune response and their potential efficacy against osteosarcoma, *Int. Immunopharmacol.* 38 (2016) 81–89.
- [21] J.R. Brahmer, S.S. Tykodi, L.Q. Chow, W.J. Hwu, S.L. Topalian, P. Hwu, C.G. Drake, L.H. Camacho, J. Kauh, K. Odunsi, H.C. Pitot, O. Hamid, S. Bhatia, R. Martins, K. Eaton, S. Chen, T.M. Salay, S. Alaparthi, J.F. Grosso, A.J. Korman, S.M. Parker, S. Agrawal, S.M. Goldberg, D.M. Pardoll, A. Gupta, J.M. Wigginton, Safety and activity of anti-PD-L1 antibody in patients with advanced cancer, *N. Engl. J. Med.* 366 (26) (2012) 2455–2465.
- [22] S.L. Topalian, F.S. Hodi, J.R. Brahmer, S.N. Gettinger, D.C. Smith, D.F. McDermott, J.D. Powderly, R.D. Carvajal, J.A. Sosman, M.B. Atkins, P.D. Leming, D.R. Spigel, S.J. Antonia, L. Horn, C.G. Drake, D.M. Pardoll, L. Chen, W.H. Sharfman, R.A. Anders, J.M. Taube, T.L. McMiller, H. Xu, A.J. Korman, M. Jure-Kunkel, S. Agrawal, D. McDonald, G.D. Kolli, A. Gupta, J.M. Wigginton, M. Sznol, Safety, activity, and immune correlates of anti-PD-1 antibody in cancer, *N. Engl. J. Med.* 366 (26) (2012) 2443–2454.
- [23] Z. Zhu, Z. Jin, M. Zhang, Y. Tang, G. Yang, X. Yuan, J. Yao, D. Sun, Prognostic value of programmed death-ligand 1 in sarcoma: a meta-analysis, *Oncotarget* 8 (35) (2017) 59570–59580.
- [24] M. Boxberg, K. Steiger, U. Lenze, H. Rechl, R. von Eisenhart-Rothe, K. Wortler, W. Weichert, R. Langer, K. Specht, PD-L1 and PD-1 and characterization of tumor-infiltrating lymphocytes in high grade sarcomas of soft tissue – prognostic implications and rationale for immunotherapy, *Oncoimmunology* 7 (3) (2018) e1389366.
- [25] S. Paydas, E.K. Bagir, M.A. Devעי, G. Gonlusen, Clinical and prognostic significance of PD-1 and PD-L1 expression in sarcomas, *Med. Oncol.* 33 (8) (2016) 93.
- [26] A. Torabi, C.N. Amaya, F.H. Wians Jr, B.A. Bryan, PD-1 and PD-L1 expression in bone and soft tissue sarcomas, *Pathology* 49 (5) (2017) 506–513.
- [27] P. Koirala, M.E. Roth, J. Gill, S. Pipher, J.M. Chinai, D.S. Geller, B.H. Hoang, A. Park, M.A. Fremed, X. Zang, R. Gorlick, Immune infiltration and PD-L1 expression in the tumor microenvironment are prognostic in osteosarcoma, *Sci. Rep.* 6 (2016) 30093.
- [28] J.K. Shen, G.M. Cote, E. Choy, P. Yang, D. Harmon, J. Schwab, G.P. Nielsen, I. Chebib, S. Ferrone, X. Wang, Y. Wang, H. Mankin, F.J. Hornicek, Z. Duan, Programmed cell death ligand 1 expression in osteosarcoma, *Cancer Immunol. Res.* 2 (7) (2014) 690–698.
- [29] Y. Liao, L. Chen, Y. Feng, J. Shen, Y. Gao, G. Cote, E. Choy, D. Harmon, H. Mankin, F. Hornicek, Z. Duan, Targeting programmed cell death ligand 1 by CRISPR/Cas9 in osteosarcoma cells, *Oncotarget* 8 (18) (2017) 30276–30287.
- [30] D.A. Costa Arantes, A.S. Goncalves, B.C. Jham, E.C.B. Duarte, E.C. de Paula, H.M. de Paula, E.F. Mendonca, A.C. Batista, Evaluation of HLA-G, HLA-E, and PD-L1 proteins in oral osteosarcomas, *Oral Surg. Oral Med. Oral Pathol. Oral Radiol.* 123 (6) (2017) e188–e196.
- [31] Y.T. Sundara, M. Kostine, A.H. Cleven, J.V. Bovee, M.W. Schilham, A.M. Cleton-Jansen, Increased PD-L1 and T-cell infiltration in the presence of HLA class I expression in metastatic high-grade osteosarcoma: a rationale for T-cell-based immunotherapy, *Cancer Immunol. Immunother.* 66 (1) (2017) 119–128.
- [32] D.M. Lussier, L. O'Neill, L.M. Nieves, M.S. McAfee, S.A. Holechek, A.W. Collins, P. Dickman, J. Jacobsen, P. Hingorani, J.N. Blattman, Enhanced T-cell immunity to osteosarcoma through antibody blockade of PD-1/PD-L1 interactions, *J. Immunother.* 38 (3) (2015) 96–106.
- [33] F. Chowdhury, S. Dunn, S. Mitchell, T. Mellows, M. Ashton-Key, J.C. Gray, PD-L1 and CD8+PD1+ lymphocytes exist as targets in the pediatric tumor micro-environment for immunomodulatory therapy, *Oncol Immunology* 4 (10) (2015) e1029701.
- [34] S. Raj, M. Bui, R. Gonzales, D. Letson, S.J. Antonia, Impact of PDL1 expression on clinical outcomes in subtypes of sarcoma, *Ann. Oncol.* 25 (2014) 494–510.
- [35] P. Dhupkar, N. Gordon, J. Stewart, E.S. Kleinerman, Anti-PD-1 therapy redirects macrophages from an M2 to an M1 phenotype inducing regression of OS lung metastases, *Cancer Med.* 7 (6) (2018) 2654–2664.
- [36] B. Zheng, T. Ren, Y. Huang, K. Sun, S. Wang, X. Bao, K. Liu, W. Guo, PD-1 axis expression in musculoskeletal tumors and antitumor effect of nivolumab in osteosarcoma model of humanized mouse, *J. Hematol. Oncol.* 11 (1) (2018) 16.
- [37] T. Shimizu, Y. Fuchimoto, K. Fukuda, H. Okita, Y. Kitagawa, T. Kuroda, The effect of immune checkpoint inhibitors on lung metastases of osteosarcoma, *J. Pediatr. Surg.* 52 (12) (2017) 2047–2050.
- [38] H.A. Tawbi, M. Burgess, V. Bolejack, B.A. Van Tine, S.M. Schuetz, J. Hu, S. D'Angelo, S. Attia, R.F. Riedel, D.A. Priebe, S. Movva, L.E. Davis, S.H. Okuno, D.R. Reed, J. Crowley, L.H. Butterfield, R. Salazar, J. Rodriguez-Canales, A.J. Lazar, Wistuba II, L.H. Baker, R.G. Maki, D. Reinke, S. Patel, Pembrolizumab in advanced soft-tissue sarcoma and bone sarcoma (SARC028): a multicentre, two-cohort, single-arm, open-label, phase 2 trial, *Lancet Oncol.* 18 (11) (2017) 1493–1501.
- [39] G.J. McCaughan, M.J. Fulham, A. Mahar, J. Soper, A.M. Hong, P.D. Stalley, M.H. Tattersall, V.A. Bhadri, Programmed cell death-1 blockade in recurrent disseminated Ewing sarcoma, *J. Hematol. Oncol.* 9 (1) (2016) 48.
- [40] I. Machado, J.A. Lopez-Guerrero, K. Scotlandi, P. Picci, A. Lombart-Bosch, Immunohistochemical analysis and prognostic significance of PD-L1, PD-1, and CD8+ tumor-infiltrating lymphocytes in Ewing's sarcoma family of tumors (ESFT), *Virchows Arch.* 472 (5) (2018) 815–824.
- [41] C. Kim, E.K. Kim, H. Jung, H.J. Chon, J.W. Han, K.H. Shin, H. Hu, K.S. Kim, Y.D. Choi, S. Kim, Y.H. Lee, J.S. Suh, J.B. Ahn, H.C. Chung, S.H. Noh, S.Y. Rha, S.H. Kim, H.S. Kim, Prognostic implications of PD-L1 expression in patients with soft tissue sarcoma, *BMC Cancer* 16 (2016) 434.
- [42] M. Kostine, A.H. Cleven, N.F. de Miranda, A. Italiano, A.M. Cleton-Jansen, J.V. Bovee, Analysis of PD-L1, T-cell infiltrate and HLA expression in chondrosarcoma indicates potential for response to immunotherapy specifically in the

- dedifferentiated subtype, *Mod. Pathol.* 29 (9) (2016) 1028–1037.
- [43] X. Yang, G. Zhu, Z. Yang, K. Zeng, F. Liu, J. Sun, Expression of PD-L1/PD-L2 is associated with high proliferation index of Ki-67 but not with TP53 overexpression in chondrosarcoma, *Int. J. Biol. Markers* 33 (4) (2018) 507–513.
- [44] L. Paoluzzi, A. Cacavio, M. Ghesani, A. Karambelkar, A. Rapkiewicz, J. Weber, G. Rosen, Response to anti-PD1 therapy with nivolumab in metastatic sarcomas, *Clin. Sarcoma Res.* 6 (2016) 24.
- [45] Y. Feng, J. Shen, Y. Gao, Y. Liao, G. Cote, E. Choy, I. Chebib, H. Mankin, F. Hornicek, Z. Duan, Expression of programmed cell death ligand 1 (PD-L1) and prevalence of tumor-infiltrating lymphocytes (TILs) in chordoma, *Oncotarget* 6 (13) (2015) 11139–11149.
- [46] M.X. Zou, A.B. Peng, G.H. Lv, X.B. Wang, J. Li, X.L. She, Y. Jiang, Expression of programmed death-1 ligand (PD-L1) in tumor-infiltrating lymphocytes is associated with favorable spinal chordoma prognosis, *Am. J. Transl. Res.* 8 (7) (2016) 3274–3287.
- [47] D. Mathios, J. Ruzevick, C.M. Jackson, H. Xu, S.R. Shah, J.M. Taube, P.C. Burger, E.F. McCarthy, A. Quinones-Hinojosa, D.M. Pardoll, M. Lim, PD-1, PD-L1, PD-L2 expression in the chordoma microenvironment, *J. Neurooncol.* 121 (2) (2015) 251–259.
- [48] E. Buchbinder, F.S. Hodi, Cytotoxic T lymphocyte antigen-4 and immune checkpoint blockade, *J. Clin. Invest.* 125 (9) (2015) 3377–3383.
- [49] D.R. Leach, M.F. Krummel, J.P. Allison, Enhancement of antitumor immunity by CTLA-4 blockade, *Science* 271 (5256) (1996) 1734–1736.
- [50] F.S. Hodi, S.J. O'Day, D.F. McDermott, R.W. Weber, J.A. Sosman, J.B. Haanen, R. Gonzalez, C. Robert, D. Schadendorf, J.C. Hassel, W. Akerley, A.J. van den Eertwegh, J. Lutzky, P. Lorigan, J.M. Vaubel, G.P. Linette, D. Hogg, C.H. Ottensmeier, C. Lebbe, C. Peschel, I. Quidt, J.I. Clark, J.D. Wolchok, J.S. Weber, J. Tian, M.J. Yellin, G.M. Nichol, A. Hoos, W.J. Urba, Improved survival with ipilimumab in patients with metastatic melanoma, *N. Engl. J. Med.* 363 (8) (2010) 711–723.
- [51] D. Schadendorf, F.S. Hodi, C. Robert, J.S. Weber, K. Margolin, O. Hamid, D. Patt, T.T. Chen, D.M. Berman, J.D. Wolchok, Pooled analysis of long-term survival data from phase II and phase III trials of ipilimumab in unresectable or metastatic melanoma, *J. Clin. Oncol.* 33 (17) (2015) 1889–1894.
- [52] T.J. Lynch, I. Bondarenko, A. Luft, P. Serwatowski, F. Barlesi, R. Chacko, M. Sebastian, J. Neal, H. Lu, J.M. Cuillerot, M. Reck, Ipilimumab in combination with paclitaxel and carboplatin as first-line treatment in stage IIIB/IV non-small-cell lung cancer: results from a randomized, double-blind, multicenter phase II study, *J. Clin. Oncol.* 30 (17) (2012) 2046–2054.
- [53] E.D. Kwon, C.G. Drake, H.I. Scher, K. Fizazi, A. Bossi, A.J. van den Eertwegh, M. Krainer, N. Houede, R. Santos, H. Mohammedi, S. Ng, M. Maio, F.A. Franke, S. Sundar, N. Agarwal, A.M. Bergman, T.E. Ciuleanu, E. Korbenfeld, L. Sengelov, S. Hansen, C. Logothetis, T.M. Beer, M.B. McHenry, P. Gagnier, D. Liu, W.R. Gerritsen, C.A. Investigators, Ipilimumab versus placebo after radiotherapy in patients with metastatic castration-resistant prostate cancer that had progressed after docetaxel chemotherapy (CA184-043): a multicentre, randomised, double-blind, phase 3 trial, *Lancet Oncol.* 15 (7) (2014) 700–712.
- [54] J.C. Yang, M. Hughes, U. Kammula, R. Royal, R.M. Sherry, S.L. Topalian, K.B. Suri, C. Levy, T. Allen, S. Mavroukakis, I. Lowy, D.E. White, S.A. Rosenberg, Ipilimumab (anti-CTLA4 antibody) causes regression of metastatic renal cell cancer associated with enteritis and hypophysitis, *J. Immunother.* 30 (8) (2007) 825–830.
- [55] M.S. Merchant, M. Wright, K. Baird, L.H. Waxler, C. Rodriguez-Galindo, D. Bernstein, C. Delbrook, M. Lodish, R. Bishop, J.D. Wolchok, H. Streicher, C.L. Mackall, Phase I clinical trial of ipilimumab in pediatric patients with advanced solid tumors, *Clin. Cancer Res.* 22 (6) (2016) 1364–1370.
- [56] M.A. Postow, J. Chesney, A.C. Pavlick, C. Robert, K. Grossmann, D. McDermott, G.P. Linette, N. Meyer, J.K. Giguere, S.S. Agarwala, M. Shaheen, M.S. Ernstoff, D. Minor, A.K. Salama, M. Taylor, P.A. Ott, L.M. Rollin, C. Horak, P. Gagnier, J.D. Wolchok, F.S. Hodi, Nivolumab and ipilimumab versus ipilimumab in untreated melanoma, *N. Engl. J. Med.* 372 (21) (2015) 2006–2017.
- [57] D.M. Lussier, J.L. Johnson, P. Hingorani, J.N. Blattman, Combination immunotherapy with alpha-CTLA-4 and alpha-PD-L1 antibody blockade prevents immune escape and leads to complete control of metastatic osteosarcoma, *J. Immunother. Cancer* 3 (2015) 21.
- [58] S.P. D'Angelo, M.R. Mahoney, B.A. Van Tine, J. Atkins, M.M. Milhem, B.N. Jahagirdar, C.R. Antonescu, E. Horvath, W.D. Tap, G.K. Schwartz, H. Streicher, Nivolumab with or without ipilimumab treatment for metastatic sarcoma (Alliance A091401): two open-label, non-comparative, randomised, phase 2 trials, *Lancet Oncol.* 19 (3) (2018) 416–426.
- [59] S. Siva, M.P. MacManus, R.F. Martin, O.A. Martin, Abscopal effects of radiation therapy: a clinical review for the radiobiologist, *Cancer Lett.* 356 (1) (2015) 82–90.
- [60] Y. Lee, S.L. Auh, Y. Wang, B. Burnette, Y. Wang, Y. Meng, M. Beckett, R. Sharma, R. Chin, T. Tu, R.R. Weichselbaum, Y.X. Fu, Therapeutic effects of ablative radiation on local tumor require CD8+ T cells: changing strategies for cancer treatment, *Blood* 114 (3) (2009) 589–595.
- [61] C. Twyman-Saint Victor, A.J. Rech, A. Maity, R. Rengan, K.E. Pauken, E. Stelekati, J.L. Benci, B. Xu, H. Dada, P.M. Odorizzi, R.S. Herati, K.D. Mansfield, D. Patsch, R.K. Amaravadi, L.M. Schuchter, H. Ishwaran, R. Mick, D.A. Pryma, X. Xu, M.D. Feldman, T.C. Gangadhar, S.M. Hahn, E.J. Wherry, R.H. Vonderheide, A.J. Minn, Radiation and dual checkpoint blockade activate non-redundant immune mechanisms in cancer, *Nature* 520 (7547) (2015) 373–377.
- [62] R.A. Chandra, T.J. Wilhite, T.A. Balboni, B.M. Alexander, A. Spektor, P.A. Ott, A.K. Ng, F.S. Hodi, J.D. Schoenfeld, A systematic evaluation of abscopal responses following radiotherapy in patients with metastatic melanoma treated with ipilimumab, *Oncotimmunology* 4 (11) (2015) e1046028.
- [63] J. Kang, S. Demaria, S. Formenti, Current clinical trials testing the combination of immunotherapy with radiotherapy, *J. Immunother. Cancer* 4 (2016) 51.
- [64] E. Picarda, K.C. Ohaegbulam, X. Zang, Molecular Pathways: Targeting B7-H3 (CD276) for Human Cancer Immunotherapy, *Clin. Cancer Res.* 22 (14) (2016) 3425–3431.
- [65] L. Wang, Q. Zhang, W. Chen, B. Shan, Y. Ding, G. Zhang, N. Cao, L. Liu, Y. Zhang, B7-H3 is overexpressed in patients suffering osteosarcoma and associated with tumor aggressiveness and metastasis, *PLoS One* 8 (8) (2013) e70689.
- [66] A. Gregorio, M.V. Corrias, R. Castriconi, A. Dondero, M. Mosconi, C. Gambini, A. Moretta, L. Moretta, C. Bottino, Small round blue cell tumours: diagnostic and prognostic usefulness of the expression of B7-H3 surface molecule, *Histopathology* 53 (1) (2008) 73–80.
- [67] H. Ding, X. Yang, Y. Wei, Fusion proteins of NKG2D/NKG2DL in cancer immunotherapy, *Int. J. Mol. Sci.* 19 (1) (2018).
- [68] L. Fernandez, J. Valentin, M. Zalacain, W. Leung, A. Patino-Garcia, A. Perez-Martinez, Activated and expanded natural killer cells target osteosarcoma tumor initiating cells in an NKG2D-NKG2DL dependent manner, *Cancer Lett.* 368 (1) (2015) 54–63.
- [69] L. Fernandez, J.Y. Metais, A. Escudero, M. Vela, J. Valentin, I. Vallcorba, A. Leivas, J. Torres, A. Valeri, A. Patino-Garcia, J. Martinez, W. Leung, A. Perez-Martinez, Memory T cells expressing an NKG2D-CAR efficiently target osteosarcoma cells, *Clin. Cancer Res.* 23 (19) (2017) 5824–5835.
- [70] Z. Wang, Z. Wang, S. Li, B. Li, L. Sun, H. Li, P. Lin, S. Wang, W. Teng, X. Zhou, Z. Ye, Decitabine enhances Vgamma9Vdelta2 T cell-mediated cytotoxic effects on osteosarcoma cells via the NKG2DL-NKG2D axis, *Front. Immunol.* 9 (2018) 1239.
- [71] M. Lehner, G. Gotz, J. Proff, N. Schaft, J. Dorrie, F. Full, A. Ensser, Y.A. Muller, A. Cerwenka, H. Abken, O. Parolini, P.F. Ambros, H. Kovar, W. Holter, Redirecting T cells to Ewing's sarcoma family of tumors by a chimeric NKG2D receptor expressed by lentiviral transduction or mRNA transfection, *PLoS One* 7 (2) (2012) e31210.
- [72] C. Spurny, S. Kailayangiri, B. Altwater, S. Jamitzky, W. Hartmann, E. Wardelmann, A. Ranft, U. Dirksen, S. Amler, J. Hards, M. Fluegge, J. Meltzer, N. Farwick, L. Greune, C. Rossig, T cell infiltration into Ewing sarcomas is associated with local expression of immune-inhibitory HLA-G, *Oncotarget* 9 (5) (2018) 6536–6549.
- [73] G. Lizee, W.W. Overwijk, L. Radvanyi, J. Gao, P. Sharma, P. Hwu, Harnessing the power of the immune system to target cancer, *Annu. Rev. Med.* 64 (2013) 71–90.
- [74] X. Li, N.A. Seebacher, F.J. Hornicek, T. Xiao, Z. Duan, Application of liquid biopsy in bone and soft tissue sarcomas: present and future, *Cancer Lett.* 439 (2018) 66–77.
- [75] J.A. Marin-Acevedo, B. Dholaria, A.E. Soyano, K.L. Knutson, S. Chumsri, Y. Lou, Next generation of immune checkpoint therapy in cancer: new developments and challenges, *J. Hematol. Oncol.* 11 (1) (2018) 39.