


Contents lists available at [ScienceDirect](https://www.sciencedirect.com)

## International Journal of Pediatric Otorhinolaryngology

journal homepage: [www.elsevier.com/locate/ijporl](http://www.elsevier.com/locate/ijporl)

## Long-range optical coherence tomography of pediatric airway during drug induced sleep endoscopy: A preliminary report

Khodayar Goshtasbi<sup>a,b</sup>, Erica Su<sup>b</sup>, Joseph C. Jing<sup>b</sup>, Theodore V. Nguyen<sup>b</sup>, Ellen M. Hong<sup>b</sup>, Katelyn D. Dilley<sup>b</sup>, Gurpreet S. Ahuja<sup>c</sup>, Zhongping Chen<sup>b,d</sup>, Brian J.F. Wong<sup>a,b,d,\*</sup>

<sup>a</sup> Department of Otolaryngology-Head and Neck Surgery, University of California Irvine, Irvine, CA, USA

<sup>b</sup> Beckman Laser Institute, University of California Irvine, Irvine, CA, USA

<sup>c</sup> Division of Pediatric Otolaryngology, Children's Hospital of Orange County, Orange, CA, USA

<sup>d</sup> School of Biomedical Engineering, University of California Irvine, Irvine, CA, USA

### ABSTRACT

**Objective:** Drug induced sleep endoscopy (DISE) is often performed for pediatric obstructive sleep apnea (OSA) when initial diagnostic studies do not provide adequate information for therapy. However, DISE scoring is subjective and with limitations. This proof-of-concept study demonstrates the use of a novel long-range optical coherence tomography (LR-OCT) system during DISE of two pediatric patients.

**Methods:** LR-OCT was used to visualize the airway of pediatric patients during DISE. At the conclusion of DISE, the OCT probe was guided in the airway under endoscopic visual guidance, and cross-sectional images were acquired at the four VOTE locations. Data processing involved image resizing and alignment, followed by rendering of three-dimensional (3D) volumetric models of the airways.

**Results:** Two patients were included in this study. Patient one had 18.4%, 20.9%, 72.3%, and 97.3% maximal obstruction at velum, oropharynx, tongue base, and epiglottis, while patient two had 40.2%, 41.4%, 8.0%, and 17.5% maximal obstruction at these regions, respectively. Three-dimensional reconstructions of patients' airways were also constructed from the OCT images.

**Conclusion:** This proof-of-concept study demonstrates the successful evaluation of pediatric airway during DISE using LR-OCT, which accurately identified sites and degrees of obstruction with respective 3D airway reconstruction.

### 1. Introduction

Pediatric obstructive sleep apnea (OSA) is associated with decreased neurocognitive, pulmonary, cardiovascular, and quality of life measures as well as increased healthcare costs [1–5]. Polysomnography remains the gold standard diagnostic tool for pediatric OSA [6], but it provides no information on the site of obstruction. For patients who fail tonsillectomy and adenoidectomy, drug induced sleep endoscopy (DISE) is used to aid in identifying restriction points [7–9]. During DISE, airway collapse is rated at the velum, oropharynx, tongue base, and epiglottis (VOTE system) [10]. However, VOTE can be subjective with reports of interobserver disagreement for the location and degree of airway obstruction [11,12]. As such, there is a need for the development of other diagnostic tools that provide objective information regarding the site and degree of airway obstruction. Optical coherence tomography (OCT) is a mesoscopic imaging modality that provides high-resolution cross-sectional images of biologic systems [13,14]. Long-range Optical Coherence Tomography (OCT) represents an advanced variant of OCT

technology tailored for imaging the intricate anatomical features within hollow viscera. Similar to optical rangefinders, it employs light-based methodology. However, it uniquely incorporates a coherence gate to ascertain the temporal behavior of photons, enabling precise determination of structural characteristics by time-of-flight analysis. Our group has shown the efficacy of long-range OCT (LR-OCT) for imaging the pediatric and adult airways [15–21], but it has yet to be evaluated for use during DISE. The aim of this proof-of-concept study is to perform LR-OCT during pediatric DISE and evaluate its utility for the determination of location and degree of airway collapse during induced sleep.

### 2. Methods

This study was performed following institutional review board approval at the University of California, Irvine. Two patients who were undergoing DISE as part of their routine clinical decision-making were enrolled in the study. The first patient was a 7-year-old male who had persistent sleep disordered breathing after adenotonsillectomy. The

\* Corresponding author. Department of Otolaryngology – Head and Neck Surgery, University of California, Irvine Medical Center, 101 The City Dr South, Orange, CA, 92868, USA.

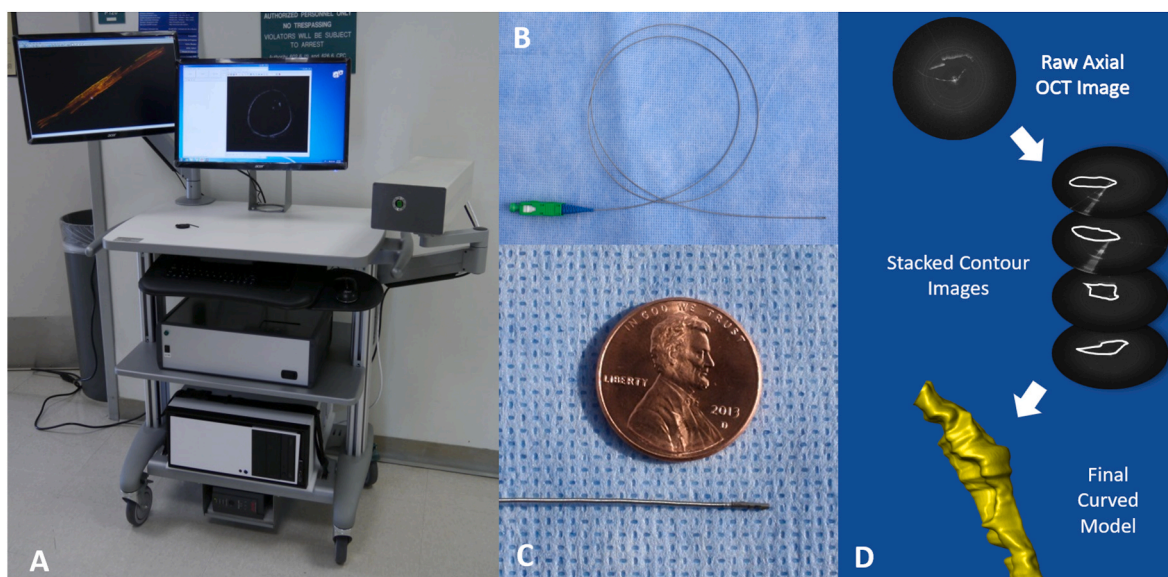
E-mail address: [bjwong@uci.edu](mailto:bjwong@uci.edu) (B.J.F. Wong).

<https://doi.org/10.1016/j.ijporl.2024.111900>

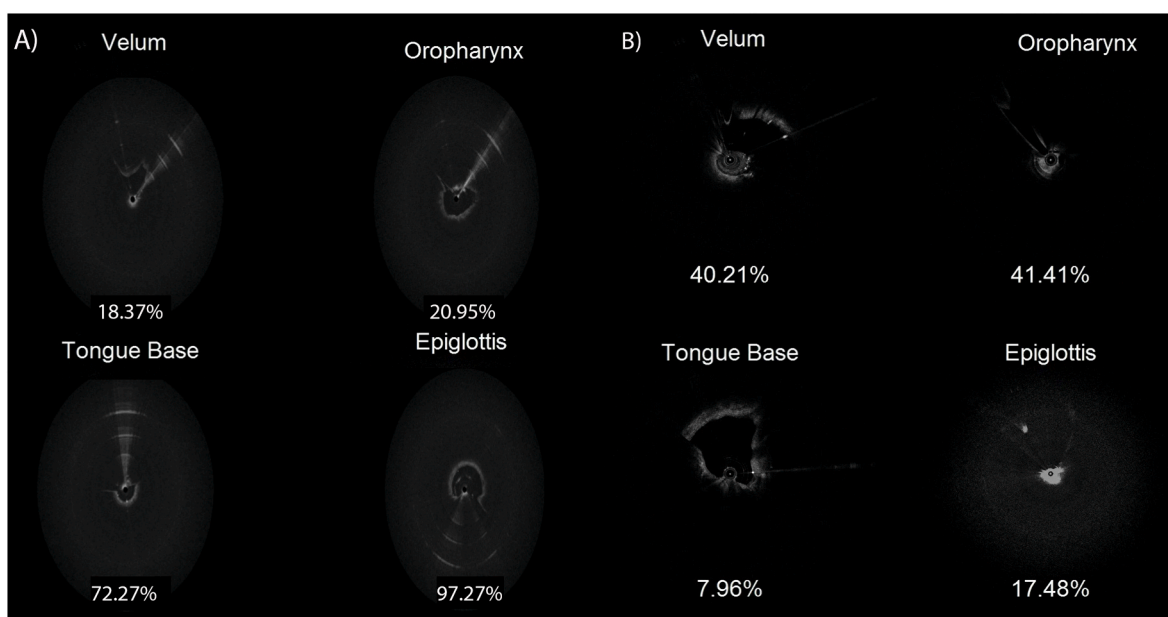
Received 8 January 2024; Received in revised form 17 February 2024; Accepted 21 February 2024

Available online 22 February 2024

0165-5876/© 2024 Elsevier B.V. All rights reserved.



**Fig. 1.** Long-range OCT setup: (A) Hardware including an OCT arm on the right and (B–C) fiber-based rotatory probe. (D) Depicts processing and segmenting the raw images for creating three-dimensional volumetric airway models.



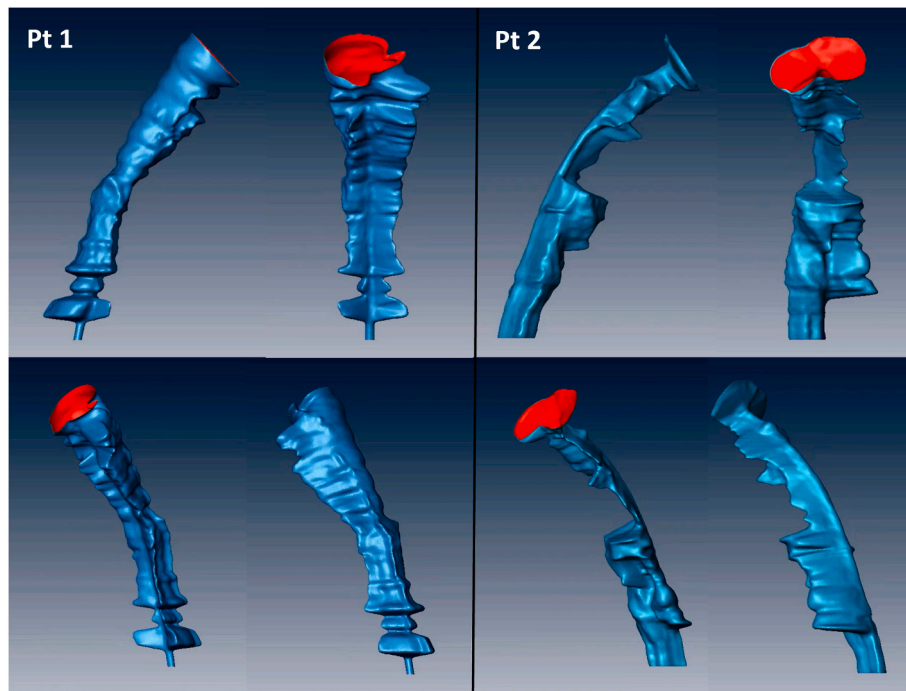
**Fig. 2.** OCT images of patient one (A) and patient two (B) at the VOTE locations. Patient one had maximal obstruction at epiglottis followed by tongue-base. Patient two had maximal obstruction at oropharynx and velum.

second patient was a 12-year-old male with severe autism who could not tolerate sleep study or physical exam. LR-OCT was used to visualize the airway of pediatric patients during DISE. The procedures were reimbursed like the usual DISE procedures, and the addition of OCT was not coded as it was only done for research purposes. The LR-OCT system utilized a 1310 nm swept light source with 50 kHz repetition rate, 100 nm bandwidth, 11 μm axial resolution, and 150 MHz frequency shift in the reference arm of the acousto-optic modulator (Fig. 1A). The sampling OCT probe was rotatory and fiber-based in a transparent sheath with a 0.7 mm outer diameter and 25 Hz rotation (Fig. 1 B–C). At the conclusion of DISE, the OCT probe was guided in the airway under endoscopic visual guidance. The probe was advanced from the nare to the pyriform sinus; as the probe was steadily pulled back at a rate of 1 cm/s, cross-sectional images were acquired at the four VOTE locations. Continuous spiral scanning of the upper airway resulted in 300–500

individual images of the airway. As detailed in previous studies [15–20, 22], data processing involved image resizing and alignment, followed by rendering of three-dimensional (3D) volumetric models of the airways (Fig. 1D).

### 3. Results

LR-OCT was intraoperatively obtained during DISE for two pediatric patients with a history of sleep disordered breathing. **Supplemental Video 1** demonstrates a side-by-side comparison of OCT with endoscopy in the first patient. In accordance with the VOTE system, OCT videos of the velum, oropharynx, base of tongue, and epiglottis of the patients one and two are demonstrated in **Supplemental Videos 2–3, respectively**. OCT images of the two patients with the respective calculated maximum obstruction as a function of cross-sectional diameter is demonstrated in



**Fig. 3.** Three-dimensional volumetric reconstructions of the patients' airways created from the cross-sectional long-range OCT images. The major obstruction sites in Fig. 2 are correlated in the three-dimensional figures.

**Fig. 2.** For patient one, the cross-sectional obstructions at the velum, oropharynx, tongue base, and epiglottis were 18.4%, 20.9%, 72.3%, and 97.3%, respectively. For patient two, the calculated cross-sectional obstructions were 40.2%, 41.4%, 8.0%, and 17.5%, respectively. **Fig. 3** demonstrates a 3D reconstruction of the patients' airways from different angles, which is also portrayed as a video in **Supplemental Video 4**.

Supplementary data related to this article can be found online at <https://doi.org/10.1016/j.ijporl.2024.111900>

#### 4. Discussion

This is the first study to evaluate the utility of LR-OCT for evaluation of pediatric OSA during DISE, in which we demonstrated quantitative assessment of the degree of airway collapse at the VOTE regions. Moreover, the LR-OCT cross-sectional images allowed for 3D reconstruction of the airway, which can further assist pediatric and sleep surgeons by depicting airway collapse during sleep and guiding surgical planning for future interventions. After the DISE-OCT procedure the first patient underwent conservative management with 6-month sleep study, whereas the second patient underwent adenotonsillectomy. The OCT results provided numeric and objective values for targeted points of airway obstructions that were then discussed with the families and incorporated in the counselling of possible interventions in the future.

If future large population studies continue to validate the utility and efficacy of this diagnostic method for OSA patients, LR-OCT can potentially supplement or even substitute DISE, particularly if in the future devices can be designed for use in native sleep. In principle LR-OCT catheters can have the form factor or pH monitoring probes, albeit a bit more rigid. While, DISE is subjective and susceptible to interobserver disagreement [11,12]. LR-OCT is quantitative as airway geometry is precisely measured. 3D airway reconstruction and computational analysis of cross-sectional airway collapse can be performed as well. Our future work will be to increase imaging speed with the incorporation of faster laser sources, to facilitate dynamic imaging and capture of airway motion in 3D in all locations and in all time points of the respiratory cycle. Two current limitations of the project were the setup cost and time of data analysis, both of which can limit the

generalizability and broad implementation of this technology in clinical settings. Our setup had an estimated cost of ~\$75,000 most of which was attributed to the laser and data acquisition card. Additionally, there was the cost of MATLAB subscription for running the program and analyzing the data, and creating disposable fiber probes with an approximate material cost of ~\$100 per probe. Lastly, although the OCT portion only added an extra 3–5 min to the DISE procedure, the data processing and analysis took approximately 3–5 h per subject. Our future works will attempt to make improvements on the cost and data-processing time requirement to make this technology more generalizable in the future.

#### 5. Conclusion

This proof-of-concept study demonstrates the successful evaluation of pediatric airway during DISE using LR-OCT, which accurately identified sites and degrees of obstruction with respective 3D airway reconstruction. Future large population studies are warranted to compare the efficacy and targeted surgical outcomes of this method to that of DISE.

#### Funding

This work was supported by NIH Grants R01EB030024, R01HL125084, and R01HL127271, the Flight Attendant Medical Research Institute Grant 32456, and grants from the University of California, Irvine (UCI) Department of Pediatrics and Institute for Clinical & Translational Science (ICTS) and UCI ICTS Neonatal Pilot Research Children's Hospital of Orange County (CHOC).

#### Credit authorship contribution statement

**Khodayar Goshtasbi:** Writing – review & editing, Writing – original draft, Visualization, Methodology, Formal analysis. **Erica Su:** Writing – review & editing, Writing – original draft, Formal analysis, Data curation, Conceptualization. **Joseph C. Jing:** Writing – review & editing, Formal analysis, Data curation. **Theodore V. Nguyen:** Writing –

original draft, Formal analysis. **Ellen M. Hong:** Writing – review & editing, Formal analysis, Data curation. **Katelyn D. Dilley:** Writing – original draft, Formal analysis. **Gurpreet S. Ahuja:** Writing – original draft, Supervision, Data curation. **Zhongping Chen:** Writing – original draft, Supervision, Data curation. **Brian J.-F Wong:** Writing – review & editing, Supervision, Formal analysis, Conceptualization.

#### Declaration of competing interest

None.

#### References

- [1] Ariel Tarasiuk, Haim Reuveni, The economic impact of obstructive sleep apnea, *Curr. Opin. Pulm. Med.* 19 (6) (2013) 639–644.
- [2] A.M. Li, C.T. Au, R.Y. Sung, C. Ho, P.C. Ng, T.F. Fok, Y.K. Wing, Ambulatory blood pressure in children with obstructive sleep apnoea: a community based study, *Thorax* 63 (9) (2008 Sep 1) 803–809.
- [3] R.B. Mitchell, Sleep-disordered breathing in children: are we underestimating the problem? *Eur. Respir. J.* 25 (2) (2005 Feb 1) 216–217.
- [4] Z. Ehsan, S.L. Ishman, Pediatric obstructive sleep apnea, *Otolaryngol. Clin.* 49 (6) (2016 Dec) 1449–1464.
- [5] K.D. Tran, C.D. Nguyen, J. Weedon, N.A. Goldstein, Child behavior and quality of life in pediatric obstructive sleep apnea, *Arch. Otolaryngol. Head Neck Surg.* 131 (1) (2005 Jan 1) 52–57.
- [6] N.A. Goldstein, N. Sculerati, J.A. Walsleben, N. Bhatia, D.M. Friedman, D. M. Rapoport, Clinical diagnosis of pediatric obstructive sleep apnea validated by polysomnography, *Otolaryngology-Head Neck Surg. (Tokyo)* 111 (5) (1994 Nov) 611–617.
- [7] D.J. Lam, E.M. Weaver, C.J. Macarthur, H.A. Milczuk, E. O'Neill, T.L. Smith, T. Nguyen, S.A. Shea, Assessment of pediatric obstructive sleep apnea using a drug-induced sleep endoscopy rating scale, *Laryngoscope* 126 (6) (2016 Jun) 1492–1498.
- [8] D. Raposo, M. Menezes, J. Rito, M. Trindade-Soares, C. Adónis, H.C. Loureiro, F. Freire, Drug-induced sleep endoscopy in pediatric obstructive sleep apnea, *Otolaryngology-Head Neck Surg. (Tokyo)* 164 (2) (2021 Feb) 414–421.
- [9] F. Galluzzi, L. Pignataro, R.M. Gaini, W. Garavello, Drug induced sleep endoscopy in the decision-making process of children with obstructive sleep apnea, *Sleep Med.* 16 (3) (2015 Mar 1) 331–335.
- [10] E.J. Kezirian, W. Hohenhorst, N. de Vries, Drug-induced Sleep Endoscopy: the VOTE Classification, vol. 268, *European Archives of Oto-Rhino-Laryngology*, 2011 Aug, pp. 1233–1236.
- [11] S. Bartier, M. Blumen, F. Chabolle, Is image interpretation in drug-induced sleep endoscopy that reliable? *Sleep Breath.* 24 (2020) 677–685.
- [12] E.J. Kezirian, D.P. White, A. Malhotra, W. Ma, C.E. McCulloch, A.N. Goldberg, Interrater reliability of drug-induced sleep endoscopy, *Arch. Otolaryngol. Head Neck Surg.* 136 (4) (2010 Apr) 393–397.
- [13] D. Huang, E.A. Swanson, C.P. Lin, J.S. Schuman, W.G. Stinson, W. Chang, M. R. Hee, T. Flotte, K. Gregory, C.A. Puliafito, J.G. Fujimoto, Optical coherence tomography, *Science* 254 (5035) (1991 Nov 22) 1178–1181.
- [14] A.G. Podoleanu, Optical coherence tomography, *J. Microsc.* 247 (3) (2012 Sep) 209–219.
- [15] J. Jing, J. Zhang, A.C. Loy, B.J. Wong, Z. Chen, High-speed upper-airway imaging using full-range optical coherence tomography, *J. Biomed. Opt.* 17 (11) (2012 Nov) 110507.
- [16] F.B. Lazarow, G.S. Ahuja, A. Chin Loy, E. Su, T.D. Nguyen, G.K. Sharma, A. Wang, J. Jing, Z. Chen, B.J. Wong, Intraoperative long range optical coherence tomography as a novel method of imaging the pediatric upper airway before and after adenotonsillectomy, *Int. J. Pediatr. Otorhinolaryngol.* 79 (1) (2015 Jan) 63–70.
- [17] V. Volgger, G.K. Sharma, J.C. Jing, Y.S. Peaks, A.C. Loy, F. Lazarow, A. Wang, Y. Qu, E. Su, Z. Chen, G.S. Ahuja, B.J. Wong, Long-range Fourier domain optical coherence tomography of the pediatric subglottis, *Int. J. Pediatr. Otorhinolaryngol.* 79 (2) (2015 Feb) 119–126.
- [18] G.K. Sharma, A. Chin Loy, E. Su, J. Jing, Z. Chen, B.J. Wong, S. Verma, Quantitative evaluation of adult subglottic stenosis using intraoperative long-range optical coherence tomography, *Ann. Otol. Rhinol. Laryngol.* 125 (10) (2016 Oct) 815–822.
- [19] J.C. Jing, L. Chou, E. Su, B.J.F. Wong, Z. Chen, Anatomically correct visualization of the human upper airway using a high-speed long range optical coherence tomography system with an integrated positioning sensor, *Sci. Rep.* 6 (2016 Dec 19) 39443.
- [20] K.M. Kozlowski, G.K. Sharma, J.J. Chen, L. Qi, K. Osann, J.C. Jing, G.S. Ahuja, A. E. Heidari, P.S. Chung, S. Kim, Z. Chen, B.J. Wong, Dynamic programming and automated segmentation of optical coherence tomography images of the neonatal subglottis: enabling efficient diagnostics to manage subglottic stenosis, *J. Biomed. Opt.* 24 (9) (2019 Sep) 1–8.
- [21] G.K. Sharma, G.S. Ahuja, M. Wiedmann, K.E. Osann, E. Su, A.E. Heidari, J.C. Jing, Y. Qu, F. Lazarow, A. Wang, L. Chou, C.C. Uy, V. Dhar, J.P. Cleary, N. Pham, K. Huoh, Z. Chen, B.J. Wong, Long-range optical coherence tomography of the neonatal upper airway for early diagnosis of intubation-related subglottic injury, *Am. J. Respir. Crit. Care Med.* 192 (12) (2015 Dec 15) 1504–1513.
- [22] G.K. Sharma, L.Y. Chen, L. Chou, C. Badger, E. Hong, S. Rangarajan, T.H. Chang, W.B. Armstrong, S.P. Verma, Z. Chen, R. Ramalingam, B.J. Wong, Surface kinematic and depth-resolved analysis of human vocal folds in vivo during phonation using optical coherence tomography, *J. Biomed. Opt.* 26 (8) (2021 Aug) 086005.