

UC San Diego

Independent Study Projects

Title

Emergency Medicine : A Pragmatic Orthopaedic Approach.

Permalink

<https://escholarship.org/uc/item/3kb3h1qr>

Author

Kohanchi, David

Publication Date

2014

EMERGENCY MEDICINE: A PRAGMATIC ORTHOPAEDIC APPROACH



**DAVID KOHANCHI, MD
INDEPENDENT STUDY PROJECT
UCSD SCHOOL OF MEDICINE
CLASS OF 2014**

EMERGENCY MEDICINE: A PRAGMATIC ORTHOPAEDIC APPROACH

FIRST EDITION

Independent Study Project (ISP)
University of California, San Diego
School of Medicine
Class of 2014

Committee Members

Vaishal M. Tolia, MD, MPH
Assistant Clinical Professor
Department of Emergency Medicine
University of California, San Diego School of Medicine

Alexandra Schwartz, MD
Clinical Professor
Chief, Orthopaedic Trauma
Residency Program Director
Department of Orthopaedic Surgery
University of California, San Diego School of Medicine

Gary M. Vilke, MD
Professor of Clinical Medicine
Department of Emergency Medicine
University of California, San Diego School of Medicine

Editors

Daniel Kohanchi, BS
University of California, Irvine

Siamak Yasmeh, MD
PGY3 Resident
Department of Orthopaedic Surgery
Keck School of Medicine of USC

Jonathan Falakassa, MD
PGY5 Resident
Department of Orthopaedic Surgery
University of Miami Miller School of Medicine

Table of Contents

CHAPTER 1- ARM INJURY	2-20
ANATOMY	2 - 6
COMMON SPLINTING TECHNIQUES	7 - 9
PROXIMAL HUMERUS FRACTURES	9 - 10
HUMERAL SHAFT FRACTURES	10-11
DISTAL HUMERUS FRACTURES	11-12
OLECRANON FRACTURES	12-13
ELBOW DISLOCATIONS	13-14
ROTATOR CUFF TEAR	14-15
BICEPS TENDON RUPTURE	15-17
BICEPS TENDONITIS	17-18
LATERAL/MEDIAL EPICONDYLITIS	18-19
CHAPTER 2- FOREARM INJURY	21-39
ANATOMY	21-22
COMMON SPLINTING TECHNIQUES	23-26
RADIAL HEAD FRACTURES	26-28
PROXIMAL ULNA FRACTURE AND RADIAL HEAD DISLOCATION (MONTEGGIA FX)	28-29
RADIAL/ULNAR SHAFT FRACTURES	29-30
DISTAL RADIUS FRACTURES	30-34
CARPAL TUNNEL SYNDROME	34-35
DE QUERVAIN'S SYNDROME	35-37
INTERSECTION SYNDROME	37-38
CHAPTER 3- WRIST INJURY	40-59
ANATOMY	40-42
COMMON SPLINTING TECHNIQUES	42-46
SCAPHOID FRACTURES	47-50
LUNATE FRACTURES	50-51
CAPITATE FRACTURES	51-52
TRIQUETRUM FRACTURES	52-54
PISIFORM FRACTURES	54-55
TRAPEZIUM FRACTURES	55-56
TRAPEZOID FRACTURES	56-57
HAMATE/HOOK OF HAMATE FRACTURES	57-58
CHAPTER 4- THIGH INJURY	60-92
ANATOMY	60-65
COMMON SPLINTING TECHNIQUES	65-66
HIP DISLOCATIONS	66-72
FEMORAL HEAD FRACTURES	72-76
FEMORAL NECK FRACTURES	76-79
INTERTROCHANTERIC FRACTURES	79-82

SUBTROCHANTERIC FRACTURES	82-84
FEMORAL SHAFT FRACTURES	85-87
DISTAL FEMUR FRACTURES	87-90

CHAPTER 5- LOWER LEG INJURY **93-114**

ANATOMY	93-98
COMMON SPLINTING TECHNIQUES	98-100
TIBIAL SHAFT FRACTURES	100-103
ISOLATED FIBULAR SHAFT FRACTURES	103-104
PROXIMAL TIBIOFIBULAR JOINT DISLOCATION/FIBULAR HEAD DISLOCATION	104-106
PILON FRACTURES	106-108
ANKLE FRACTURES	108-113

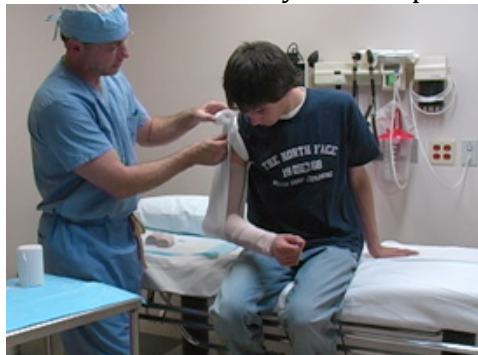Arm Injury

Common Splinting Techniques^{6,9,12}

- **Supplies:**
 - Warm water
 - Stockinette
 - Soft cotton bandage/undersplint material (i.e. 4-6 inch webril)
 - Plaster bandages (4-6 inch)
 - Elastic bandages (i.e. Ace)
 - Adhesive tape
- **Arm Sling**
 - Indications:
 - Clavicle fxs
 - Minimally displaced proximal humerus fxs
 - AC separations
 - Supporting splints of the upper extremity

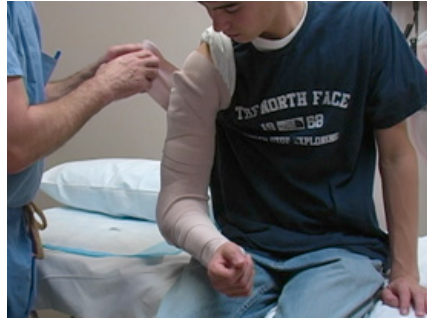

- **Coaptation**
 - Indications:
 - Humeral shaft fxs
 - Application:
 - Step 1: Seated position, arm in neutral abduction with 90 deg elbow flexion
 - Step 2: Measure length of splint by unrolling webril, **from midclavicle, around the elbow joint, to 3 to 5 cm distal to the axillary crease**
 - Lay this webril on the bed (i.e. anywhere that is convenient), roll out an additional 3 layers on top of it to form cast padding



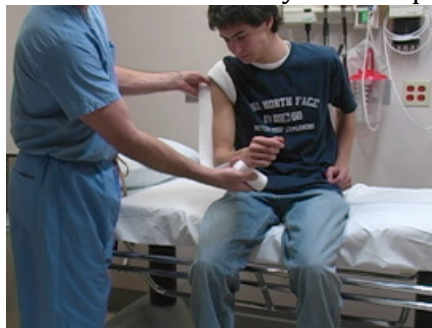- Step 3: Roll out 10-15 layers of plaster bandages over the webril
- Step 4: Soak the plaster in slightly warm to room temperature water (the cooler the faster it hardens)

- Gentle squeeze on the plaster in a laminating fashion, top to bottom motion
- Step 5: Place plaster over cast padding, roll over excess webril (which should be slightly longer) over the plaster
- Step 6: Apply splint to arm, **beginning in the axilla, wrapping it around the elbow, and then up the lateral aspect of the arm**
- Step 7: Roll 4-6 inch elastic bandage (of whatever form is used by your institution) over the splint, in a distal to proximal direction
- Step 8: Stabilize forearm with shoulder sling



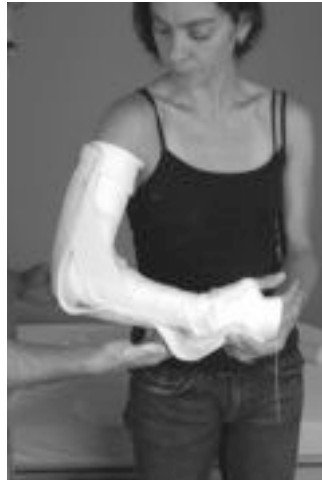- **Long arm (posterior)**

- Indications:
 - Fractures near the elbow
 - Elbow dislocations
- Application:
 - Step 1: Arm in neutral abduction, 90 deg elbow flexion
 - Step 2: Apply the stockinette
 - From **distal palmar crease to 5 cm below the axillary fold**
 - Step 3: Measure length of splint by unrolling webril, posteriorly from the inferior border of the deltoid muscle along the triceps proximally, along the ulnar border distally, to the head of the fifth metacarpal
 - Lay this webril on the bed (i.e. anywhere that is convenient), roll out an additional 3 layers on top of it to form cast padding



- Step 4: Roll out 10-12 layers of plaster bandages over the webril
- Step 5: Soak the plaster in slightly warm to room temperature water (the cooler the faster it hardens)
 - Gentle squeeze on the plaster in a laminating fashion, top to bottom motion
- Step 6: Place plaster over cast padding, roll over excess webril (which should be slightly longer) over the plaster

- Step 7: Apply splint to the posterior aspect of the arm, from the deltoid to the hand.
 - Important Recommendation from Orthopaedics Hand
 - The splint should not go beyond the distal palmar crease (volar side of MCP joints), because it causes stiffness at the joints
 - Related to the fact that the dorsal surface of the metacarpal is longer than the volar surface, pulling the collateral ligaments of the MCP on inappropriate tension versus relaxation
- Step 8: Roll 3 inch elastic bandage (of whatever form is used by your institution) over the splint, in a distal to proximal direction
- Step 9: Continue to mold the splint until hardened (tapping on it with two fingers gives an indication), maintain a neutral to 30 deg wrist extension



- **Differential Diagnosis**
 - **Proximal humerus fracture**^{2,5,6,11}
 - Imaging: AP, Grashey (true AP), axillary views (look up in articles)
 - Classification:
 - Neers
 - Separated into four parts
 - Greater tuberosity
 - Lesser tuberosity
 - Proximal humeral shaft/"surgical neck"
 - Articulating surface of humeral head
 - A part is defined as displaced if >1cm of fracture displacement or >45 degrees of angulation
 - Symptoms:
 - Pain in proximal arm
 - Limited shoulder ROM
 - Associated injuries/complications:
 - Axillary nerve stretch/transection
 - Axillary artery injury

- Epidemiology:
 - Most common humerus fracture (45%)
 - Major blood supply is from anterior and posterior humeral circumflex arteries
- ED Management:
 - Minimally displaced/non displaced:
 - Sling/early Codman exercises
 - Follow up with orthopaedic surgeon
 - Multiple part/comminuted fractures, significant displacement, neurologic compromise warrant Orthopaedic consultation
- Ortho research:
 - *Interventions for treating proximal humeral fractures in adults* (2010) ⁵
 - Goals:
 - Cochrane review of the surgical management of proximal humerus fractures
 - Salient Facts:
 - Insufficient evidence to dictate management
 - PT with without immobilization might be sufficient for undisplaced fractures
 - Unclear whether surgery will produce consistently better long-term outcomes.
 - Insufficient evidence to establish the best method of surgical treatment (i.e. plate versus nail fixation, or hemiarthroplasty versus tension wire fixation)
- **Humeral shaft fractures**^{2,6,12}
 - Imaging: AP/lateral humerus
 - With almost all long bone fractures image joint above and below, therefore shoulder series and elbow series warranted.
 - Classification:
 - No official classification scheme
 - Instead describe based on location, level of displacement
 - Symptoms:
 - Pain, swelling, and/or obvious deformity
 - Shortening of affected arm
 - Associated injuries/complications:
 - Radial nerve transection/stretch
 - Epidemiology:
 - 60% middle third, 30% proximal third, 10% distal third
 - Bimodal distribution, 3rd decade in men, 7th decade in women
 - ED Management:¹²
 - Coaptation splint
 - Acceptable reduction parameters in ED:
 - 3 cm shortening
 - 30 deg varus angulation
 - 20 deg anterior angulation
 - 15 deg malrotation
 - Follow up with orthopaedic surgeon for all humerus fractures

- Orthopaedic ED consultation warranted for radial nerve palsies, open fx, difficult reductions, multiple trauma, comminuted, bilateral fxs.
- Ortho Research:
 - *Humeral Shaft Fractures: Measuring recovery after operative versus non-operative treatment (HUMMER): a multicenter comparative observational study*⁷
 - Goals:
 - Reiterates concept that according to recent Cochrane meta-analysis, there is insufficient evidence to decide of operative versus non-operative management
 - Evaluate functional recovery after operative versus non-operative treatment in adult patients with humeral shaft fractures.
 - Salient Points:
 - Ongoing study
- **Distal Humerus Fractures**^{2,6,8,9,13}
 - Imaging:
 - AP/lateral elbow
 - Potential traction views
 - CT scan if operative candidate for planning
 - Classification:
 - Descriptive:⁵
 - Supracondylar
 - Transcondylar
 - Intercondylar
 - Condylar
 - Capitellum
 - Trochlea
 - Lateral epicondylar
 - Medial epicondylar
 - Supracondylar process

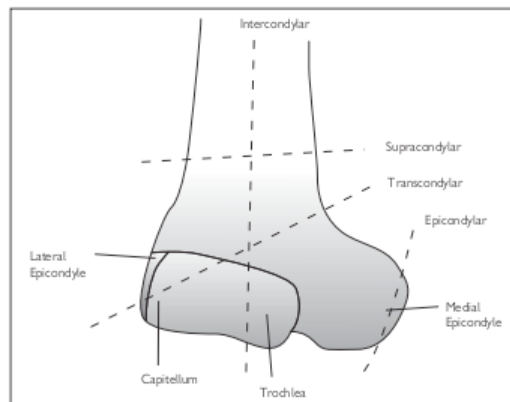


Figure 3.11 The types of distal humerus fractures, including supracondylar, transcondylar, intercondylar, condylar, capitellum, trochlear, and epicondylar.

- AO/OTA:

- Type A: Extraarticular (supracondylar)
- Type B: Intraarticular - single column
- Type C: Intraarticular- both columns fractured
- Symptoms:
 - Loss of elbow ROM
 - TTP over distal arm/elbow region
 - Deformity
- Associated injuries/complications:
 - Compartment syndrome/volkmann ischemic contracture
- Epidemiology:
 - Bimodal age distribution – males between 12 to 19, females >80
 - Intercondylar fractures are most common
- ED Management:
 - Anatomic reduction with posterior long arm splint
 - Admit pts with significant swelling for serial compartment checks
 - Open fxs, unstable fxs, comminuted/displaced fxs all warrant orthopaedic consultation
 - All distal humerus fractures require outpatient Orthopaedic follow-up
- Ortho Research:
 - *Surgical Interventions for treating distal humeral fractures in adults (2012)*:¹²
 - Goals:
 - To assess the effects of surgical interventions for distal humeral fractures in adults.
 - Within the context of lack of consensus on the best management, including conservative treatment, appropriate surgical approach, fixation strategies, and the role of total elbow arthroplasty.
 - Salient Points:
 - Either no or insufficient evidence from randomized controlled trials to determine whether surgery is the most appropriate management.
- **Olecranon Fracture**^{2,3,6,8,12}
 - Imaging:
 - AP/lateral/true lateral elbow
 - Classification:
 - Mayo Classification
 - Type I fx: stable, non-displaced
 - Type II: unstable, displaced fx. Joint stable
 - A: Noncomminuted
 - B: Comminuted
 - Type III: unstable, displaced fx. Unstable joint
 - A: Noncomminuted
 - B: Comminuted
 - Schatzker (based on fracture pattern)
 - Transverse
 - Transverse impacted

- Oblique
- Comminuted
- Oblique distal
- Fx/dislocation
- Symptoms:
 - Pain and tenderness to palpation over the olecranon area
 - Inability to extend elbow against force
- Associated injuries/complications:
 - Ulnar stretch/transection
 - Triceps weakness
- ED Management:
 - Long arm posterior splint
 - Neurovascular compromise, fx-dislocation, open fxs all warrant orthopaedic consultation. Type II and II are generally also seen for immediate operative planning by orthopedic surgeon.
 - All olecranon fxs require outpatient orthopaedic follow up
- Ortho Research:
 - *Management and Treatment of Elbow and Forearm Injuries (2010)*³
 - Salient Points:
 - Nondisplaced injuries can typically be managed conservatively as outpatients with RICE and long arm posterior splint 3-4 weeks.
 - Displaced fxs or fxs with dislocation generally require ORIF.
- **Elbow dislocations**^{2,3,6,11,12}
 - Imaging:
 - Standard elbow AP/lateral
 - Possible CT scan to identify displaced fragments and operative planning
 - Classification:³
 - According to direction of ulna relative to the distal humerus.
 - Anterior
 - Posterior
 - Further subdivided by the relationship between humerus and the olecranon.
 - Posterior
 - Posterolateral
 - Posteromedial
 - Pure lateral dislocations
 - Divergent
 - Dislocation of elbow and dissociation of the radius and ulna, secondary to ruptured annular ligament and the interosseus membrane (IOM).
 - Symptoms:
 - Elbow flexed to 45 deg with pain
 - Decreased ROM
 - Forearm shortening

- Associated injuries/complications:
 - Brachial artery
 - Median nerve, especially anterior interosseus nerve (AIN) branch
 - Fractures to the radial head, medial epicondyle, lateral epicondyle, and coronoid process
- Epidemiology:
 - 2x men vs. women
- ED Management:
 - Reduction maneuvers:¹²
 - Traction method (2 people):
 - Operator 1 flexes elbow to 90 deg and supinates forearm while applying posterior pressure to the humerus.
 - Operator 2 applies downward pressure on the proximal forearm.
 - Mayo technique (1 person):
 - Pt supine, arm held overhead
 - Valgus force applied at elbow joint with forearm supination.
 - When you hear a “click” and the elbow joint unlocks, apply an axial force to reduce the elbow.
 - Parvin method (1 person)
 - Pt prone, forearm-hanging perpendicular to table.
 - Apply ten pounds downward pressure to wrist.
 - Meyn and Quigley method (1 person):
 - Pt prone, forearm hanging over stretcher/bed
 - Gentle downward traction to the wrist with one hand, while the other hand guides reduction of the olecranon
 - Open dislocations, complex dislocations, neurovascular compromise all warrant orthopaedic consultation
- **Rotator Cuff tear** ^{2,6,8,9}
 - Important considerations:
 - Hx of Trauma versus Repetitive strain
 - Rotator cuff tendonitis versus tear
 - Acute versus chronic
 - Imaging:
 - Standard shoulder series—AP, Grashey (true AP), axillary views
 - MRI should typically be ordered by treating orthopaedic surgeon. Not to be done on an acute basis.
 - Variations:
 - Supraspinatus
 - Infraspinatus
 - Teres minor
 - Subscapularis
 - Symptoms:
 - Variable

- Difficulty abducting versus internal rotation versus external rotation
- Physical Exam:
 - Assess ROM to r/o adhesive capsulitis and osteoarthritic pain
 - Resisted shoulder extension, external rotation, and internal rotation
 - Provocative tests for cuff tear:
 - Gerber's test – lift off
 - Empty can test- arm abducted 60 deg, forward flexed 30 deg, thumb down, resistance to additional flexion
 - R/o other shoulder pathology with full shoulder physical exam:

Shoulder
1. Observation, palpation
2. Range of motion (flexion/extension, abduction/adduction, internal/external rotation), with palpation
3. "Empty can test" (arm abducted 60 degrees, forward flexed ~ 30 degrees, thumb down, resistance to additional flexion)
4. Resisted external rotation
5. Resisted internal rotation and lift off from back (Gerber's test)
6. Sub-acromial palpation
7. Hawkin's test for impingement (elbow 90 degrees, arm forward flexed 90 degrees, examiner internally rotates)
8. Neer's test for impingement (thumb down, elbow straight, examiner raises arm thru forward flexion)
9. Long head biceps palpation
10. Yergason's test for bicipital tendonitis (elbow 90 degrees, arm adducted, patient attempts supination while examiner resists)
Test for A-C joint pathology: A-C joint tenderness on palpation, Cross arm test (reach across towards opposite shoulder)

- Epidemiology:
 - Acute injuries more common in <40 yo pts 2/2 to trauma. Associated dislocations and greater tuberosity fractures are relatively common in that setting.
 - Chronic injuries more common in >60 yo pts.
- ED Management:
 - Shoulder sling, early shoulder ROM to prevent joint stiffness
 - Conservative management initially
 - All patients should have outpatient orthopaedic follow up
 - Acute tears require timely surgical repair
 - Chronic tears treatment is variable, depending on age, health status, and activity demands
- **Biceps Tendon Rupture**^{1,2,4,6,8}
 - Imaging:
 - Standard shoulder series- AP, Grashey, axillary views
 - Standard elbow series- AP/lateral

- Variations:
 - Proximal biceps tendon rupture
 - Symptoms: classically have a proximal arm bulge, “popeye”
 - Distal biceps tendon rupture
 - Symptoms: elbow swelling
 - Biceps “squeeze” and “hook” tests help in diagnosis
 - Double Click Video (Squeeze Test)



- Double Click Video (Hook Test)



- Imaging:¹
 - Plays a limited role
 - Plain shoulder series and elbow series may be used to exclude other diagnoses
 - “Plain x rays may show enlargement or irregularity of the biceps tuberosity in those pts with tendon ruptures”
 - Ultrasound may be useful with the appropriate (operator dependent)
 - MRI can quantify proximal retraction of the tendon, aiding in operative decision making
- Epidemiology:
 - Tend to occur in the dominant extremity in middle-aged men.
- Ortho Research:
 - *Treatment of chronic biceps tendon ruptures (2013)*¹
 - Goals:

- Discuss operative versus nonoperative treatments
 - Salient Points:
 - Distal ruptures account for only 3% of biceps ruptures
 - Repair of tendon to the radial tuberosity is now widely accepted, with the purpose of preventing loss of flexion and supination of elbow.
 - Unclear which patients will tolerate nonoperative management, though the more subacute/chronic the less likelihood of operative repair.
 - Both direct repair to the tuberosity +/- tendon graft are viable options.
 - Overall Symptoms:
 - Supination/flexion weakness
 - Pain with resisted flexion
 - ED Management:
 - Shoulder sling for comfort, early elbow/shoulder ROM to avoid stiffness
 - All pts should have orthopaedic follow up
 - **Biceps tendinitis**^{2,4,6,8}
 - Imaging:
 - Standard shoulder trauma series (AP, Grashey, and axillary views)
 - MRI typically unnecessary...clinical diagnosis
 - Symptoms:
 - TTP in bicipital groove
 - Resisted supination/flexion cause pain
 - ED Management:
 - Shoulder sling for comfort, early elbow, shoulder ROM to avoid stiffness
 - Rest, ice, anti-inflammatories typically improve symptoms
 - Ortho Research:
 - *Tenotomy versus Tenodesis in the treatment of the long head of biceps brachii tendon lesions. 1471 (current ongoing study)*⁴
 - Goals:
 - No current consensus on the most effective surgical procedure.
 - Assess advantages/disadvantages of tenotomy versus tenodesis in the treatment of long head of biceps tendon lesions
 - Salient Points:
 - Biceps tenotomy- released from its insertion on the superior glenoid labrum using arthroscopic electrocautery

- Biceps tenodesis- released, pinned/screwed in place.
- Ongoing study- first RCT of its kind
- **Lateral Epicondylitis (“Tennis Elbow”)**^{2,3,6,10,11}
 - Repetitive use of forearm extensors
 - Imaging:
 - In most cases, imaging is not required for diagnosis.
 - Oftentimes, elbow AP/lateral are utilized to delineate the differential diagnosis
 - MRI is the gold standard, rarely necessary however
 - Symptoms:
 - Chronic pain at lateral elbow (“over lateral epicondyle”)
 - Pain with wrist/hand extension
 - Epidemiology:
 - Women (1.1 – 4%) > Men (1 – 1.3%)
 - Approximately ½ of pts seek treatment
 - ED Management:
 - Clinical diagnosis
 - Conservative management initially with rest, ice, anti-inflammatories are the initial treatment
 - Forearm counterforce strap
 - Outpatient orthopaedic follow up
 - Ortho research:
 - *Lateral and medial epicondylitis: Role of occupational factors (2011)*¹⁰
 - Salient Points:
 - Over 80% of pts report improvement within one year with a “wait and see policy.”
 - Workload modification is often considered for manual laborers.
 - Topical NSAID therapy provides short term benefit (3-4 weeks)
 - Oral NSAIDs do not provide more long-term benefits.
 - Local corticosteroid injections have beneficial short-term (less than 6 weeks) effects. Three injections maximally a year 2/2 to minimizing soft tissue.
 - Orthotic devices that prevent wrist extension are often used, “no clear evidence base.”
 - Surgical treatment has shown fair to good results; efficacy has not been evaluated with RCTs as of yet.
- **Medial Epicondylitis (“Golfer’s elbow”)**^{2,3,6,10,11}
 - Repetitive use of forearm flexors
 - Imaging:
 - In most cases, imaging is not required for diagnosis.
 - Oftentimes, elbow AP/lateral are utilized to delineate the differential diagnosis

- MRI is the gold standard, rarely necessary however
- Symptoms:
 - Chronic pain at medial elbow (“over medial epicondyle”)
- Epidemiology:
 - Women (1.1 – 4 %) > Men (1 -1.3%)
 - Most common in individuals aged 40 - 60 yo
 - Approximately ½ of pts seek treatment
- ED Management:
 - Clinical diagnosis
 - Conservative management with rest, ice, anti-inflammatories are the initial treatment
 - Forearm counterforce strap (if available), no proven benefit
 - Outpatient orthopaedic follow up
- Ortho research:
 - *Lateral and medial epicondylitis: Role of occupational factors (2011)*¹⁰
 - Over 80% of pts report improvement within one year with a “wait and see policy.”
 - Workload modification is often considered for manual laborers.
 - Topical NSAID therapy provides short term benefit (3-4 weeks)
 - Oral NSAIDs do not provide more long-term benefits.
 - Local corticosteroid injections have beneficial short term (less than 6 weeks) effects. Three injections maximally a year 2/2 to minimizing soft tissue.
 - Orthotic devices that prevent wrist extension are often used, “no clear evidence base.”
 - Surgical treatment has shown fair to good results; efficacy has not been evaluated with RCTS as of yet.

References

1. Dillon, Mark T., and Jeffrey C. King. "Treatment of Chronic Biceps Tendon Ruptures." *Hand* 8.4 (2013): 401-09. Print.
2. Egol, Kenneth A., Kenneth J. Koval, Joseph D. Zuckerman, and Kenneth J. Koval. *Handbook of Fractures*. Philadelphia: Wolters Kluwer/Lippincott Williams & Wilkins Health, 2010. Print.
3. Falcon-Chevere, Jorge L., Dana Mathew, Jose G. Cabanas, and Eduardo Labat. "Management and Treatment of Elbow and Forearm Injuries." *Emergency Medicine Clinics of North America* 28.4 (2010): 765-87. Print.
4. Galasso, Olimpio, Giorgio Gasparini, Massimo De Benedetto, Filippo Familiar, and Roberto Castricini. "Tenotomy versus Tenodesis in the Treatment of the Long Head of Biceps Brachii Tendon Lesions." *BMC Musculoskeletal Disorders* 13.1 (2012): 205. Print.
5. Handoll, HH G., B. J. Ollivere, and K. E. Rollins. "Interventions for Treating Proximal Humeral Fractures in Adults (Review)." *The Cochrane Collaboration* 12 (2012): n. pag. Web.
6. Humbyrd, Casey Jo. *Orthopaedic Emergencies*. Oxford: Oxford UP, 2012. Print.

7. Mahabier, Kiran C., Esther MM Van Lieshout, Hugo W. Bolhuis, Maarten WGA Bronnkorst, Milko MM Bruijninx, and J. C. Goslings. "Humeral Shaft Fractures: Measuring Recovery after Operative versus Non-operative Treatment (HUMMER): A Multicenter Comparative Observational Study." *BMC Musculoskeletal Disorders* 15.39 (2014): n. pag. Web.
8. Miller, Mark D., Stephen R. Thompson, and Jennifer Hart. *Review of Orthopedics*. Philadelphia, PA: Elsevier/Saunders, 2012. Web.
9. "Procedures Consult." *Procedures Consult*. Web. 28 Apr. 2014.
10. Shiri, Rahman, and Eira Viikari-Juntura. "Lateral and Medial Epicondylitis: Role of Occupational Factors." *Best Practice & Research Clinical Rheumatology* 25.1 (2011): 43-57. Print.
11. Thompson, Jon C., and Frank H. Netter. *Netter's Concise Orthopaedic Anatomy*. Philadelphia, PA: Saunders Elsevier, 2010. Print.
12. Thompson, Stephen R., and Dan A. Zlotolow. *Handbook of Splinting and Casting*. Philadelphia, PA: Elsevier/Mosby, 2012. Print.
13. Y, Wang, Zhuo Q, and Yang W. "Surgical Interventions for Treating Distal Humerus Fractures in Adults (Review)." *The Cochrane Collaboration* 1 (2013): n. pag. Web.

Forearm Injury

Common Splinting Techniques^{13,18}

- **Supplies**

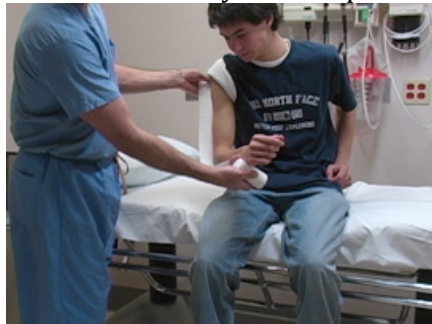- Warm water
- Stockinette
- Soft cotton bandage/undersplint material (i.e. Webril)
- Plaster bandages (3 or 4 inch)
- Elastic bandages (i.e. ACE)
- Adhesive tape



-

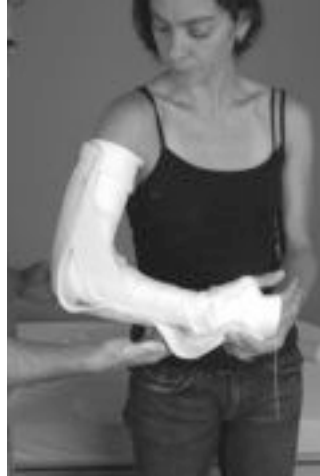Long arm

- **Indications:**
 - Adult distal radius fx
 - Adult forearm fractures
 - Elbow joint dislocation
 - Olecranon fracture
 - Elbow or distal humerus following ORIF
- **Application:**
 - Step 1: Arm in neutral abduction, 90 deg elbow flexion
 - Step 2: Apply the stockinette
 - From **distal palmar crease to 5 cm below the axillary fold**
 - Step 3: Measure length of splint by unrolling webril, posteriorly from the inferior border of the deltoid muscle along the triceps proximally, along the ulnar border distally, to the head of the fifth metacarpal
 - Lay this webril on the bed (i.e. anywhere that is convenient), roll out an additional 3 layers on top of it to form cast padding



- Step 4: Roll out 10-12 layers of plaster bandages over the webril
- Step 5: Soak the plaster in slightly warm to room temperature water (the cooler the faster it hardens)

- Gentle squeeze on the plaster in a laminating fashion, top to bottom motion
- Step 6: Place plaster over cast padding, roll over excess webril (which should be slightly longer) over the plaster
- Step 7: Apply splint to the posterior aspect of the arm, from the deltoid to the hand.
 - Important Recommendation from Orthopaedics Hand
 - The splint should not go beyond the distal palmar crease (volar side of MCP joints), because it causes stiffness at the joints
 - Related to the fact that the dorsal surface of the metacarpal is longer than the volar surface, pulling the collateral ligaments of the MCP on inappropriate tension versus relaxation
- Step 8: Roll 3 inch elastic bandage (of whatever form is used by your institution) over the splint, in a distal to proximal direction
- Step 9: Continue to mold the splint until hardened (tapping on it with two fingers gives an indication), maintain a neutral to 30 deg wrist extension



- - **Short arm**
 - Indications:
 - Distal radius fx (non acute)
 - Non scaphoid carpal fxs
 - Distal ulna fx
 - Application:
 - Step 1: Arm in neutral abduction, 90 deg elbow flexion
 - Step 2: Apply the stockinette
 - From **distal palmar crease to 5 cm distal to the elbow**
 - Step 3: Measure length of splint by unrolling webril along the course, from the distal palmar crease to 5-10 cm distal to the elbow
 - Lay this webril on the bed (i.e. anywhere that is convenient), roll out an additional 3 layers on top of it to form cast padding
 - Step 4: Roll out 8-10 layers of plaster bandages over the webril
 - Step 5: Soak the plaster in slightly warm to room temperature water (the cooler the faster it hardens)
 - Gentle squeeze on the plaster in a laminating fashion, top to bottom motion

- Step 6: Place plaster over cast padding, roll over excess webril (which should be slightly longer) over the plaster
- Step 7: Apply splint along volar surface of the forearm and wrist, mold using the palms of your hands
 - Important Recommendation from Orthopaedics Hand
 - The splint should not go beyond the distal palmar crease (volar side of MCP joints), because it causes stiffness at the joints
 - Related to the fact that the dorsal surface of the metacarpal is longer than the volar surface, pulling the collateral ligaments of the MCP on inappropriate tension versus relaxation
- Step 8: Roll 3 inch elastic bandage (of whatever form is used by your institution) over the splint, in a distal to proximal direction
- Step 9: Continue to mold the splint until hardened (tapping on it with two fingers gives an indication), maintain a neutral to 30 deg wrist extension

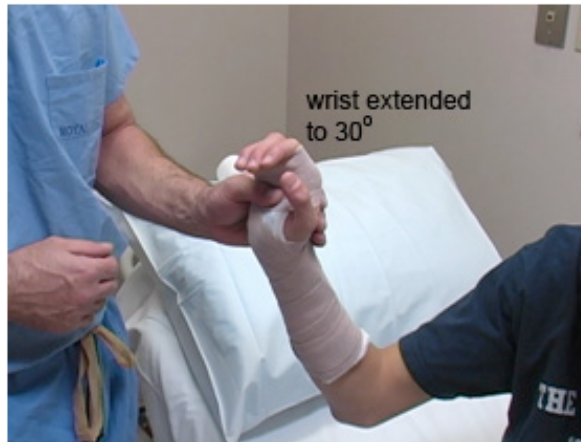
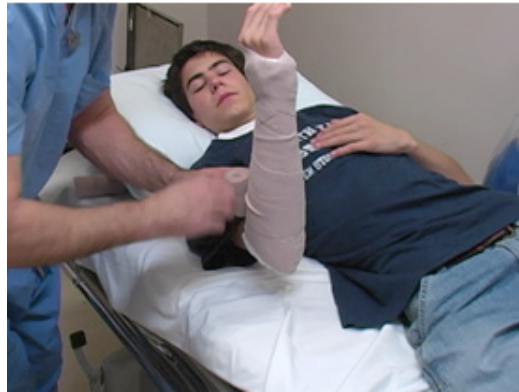
Figure 6 : The "position of function"

- **Sugar tong**
 - Indications:
 - Temporary immobilization of distal radius fractures, typically with suspected DRUJ instability
 - i.e Colles' or Smith's fractures
 - i.e. Radial styloid (chauffeur's) fractures
 - i.e. Comminuted intraarticular fracture
 - Application:
 - Step 1: Seated position, elbow in 90 deg abduction and 90 deg elbow flexion
 - Step 2: Apply the stockinette
 - From **distal palmar crease to midshaft humerus**
 - Step 3: Measure length of splint by unrolling webril along the course, from dorsal metacarpal heads, proximally along the dorsal aspect of the forearm, around the elbow, distally along the volar forearm, up to the distal palmar crease
 - Lay this webril on the bed (i.e. anywhere that is convenient), roll out an additional 3 layers on top of it to form cast padding
 - Step 4: Roll out 8-10 layers of plaster bandages over the webril

- Step 5: Soak the plaster in slightly warm to room temperature water (the cooler the faster it hardens)
 - Gentle squeeze on the plaster in a laminating fashion, top to bottom motion
- Step 6: Place plaster over cast padding, roll over excess webril (which should be slightly longer) over the plaster
- Step 7: Apply splint to the arm, similar to measuring instructions
 - Important Recommendation from Orthopaedics Hand
 - The splint should not go beyond the distal palmar crease (volar side of MCP joints), because it causes stiffness at the joints
 - Related to the fact that the dorsal surface of the metacarpal is longer than the volar surface, pulling the collateral ligaments of the MCP on inappropriate tension versus relaxation
- Step 8: Roll 3-4 inch elastic bandage (of whatever form is used by your institution) over the splint, in a distal to proximal direction
- Step 9: Continue to mold the splint until hardened (tapping on it with two fingers gives an indication), maintain a neutral to 30 degree wrist extension



- **Differential Diagnosis**

- **Radial head fractures in adults**^{1,2,4,7,8,15,19}

- **Imaging:**

- AP, lateral, and oblique views (Greenspan views) of elbow
- Wrist and forearm x-rays
- CT scan is “not routinely performed unless there is an associated complex periarticular injury involving the distal part of the humerus or the proximal part of the ulna”¹⁹
- MRI screens for associated osseous and ligament injury, “but the additional information has not been proved to change patient treatment and routine use is not necessary”¹⁹

- **Classification:**

- **Mason:**

- Based on displacement, comminution, and dislocation
- Type I: minimally displaced/nondisplaced
- Type II: partial articular fractures with displacement (>2 mm)
- Type III comminuted fractures involving the entire radial head

- Johnston's Modification- Type IV: Radial head fx with elbow dislocation
- Simple vs. Complex
 - Simple
 - Isolated
 - Complex
 - Associated with osseous or soft-tissue injury
- Symptoms:
 - Pain and limited ROM at elbow
 - Tenderness in the "medial and lateral epicondylar regions may signify the presence of an accompanying ligamentous injury, whereas pain in the wrist or forearm should raise suspicion of an Essex-Loprestic lesion (radial head fx plus dislocation of distal radioulnar joint)" ¹⁹
- Associated Injuries/Complications:
 - Disruption of primary/secondary stabilizers of the elbow
 - Primary stabilizers
 - MCL complex
 - Anterior, posterior, transverse bundles
 - LCL complex
 - Lateral ulnar collateral ligament, radial collateral ligament, annular ligament, accessory collateral ligament
 - Ulnohumeral joint
 - Secondary stabilizers
 - Radiocapitellar joint
 - Joint capsule
 - Flexor/extensor tendon attachments
 - Coronoid process fx
 - Elbow dislocation
 - "Terrible triad of the elbow" ⁸
 - Radial head/neck fx, coronoid fx, and elbow dislocation
- Epidemiology:²
 - 1/3 of pts have associated injuries such as fracture or ligamentous damage of the shoulder, humerus, forearm, wrist, or hand
 - 1.7% to 5.4% of all fractures
- ED Management:
 - Non-displaced/minimally displaced
 - Sling/early ROM 24 to 48 hours after injury
 - Assess for injuries to the capitellum, trochlea, medial epicondyle, and coronoid¹⁵
 - Fractures with neurovascular compromise, fracture dislocation, open fxs, or concomitant injuries warrant orthopaedic consultation
 - All fractures require orthopaedic outpatient follow up
- Ortho Research:
 - *Current Concepts Review Fractures of the Radial Head and Neck (2013)*¹⁵

TABLE I Radial Head-Neck Fracture Characteristics Impacting Treatment

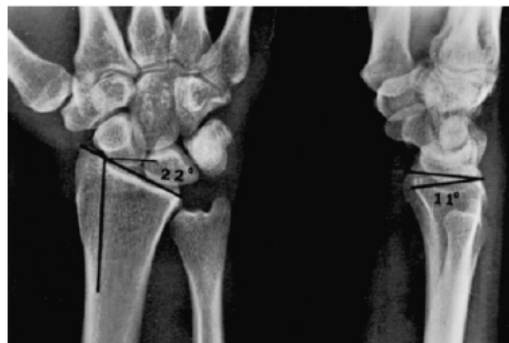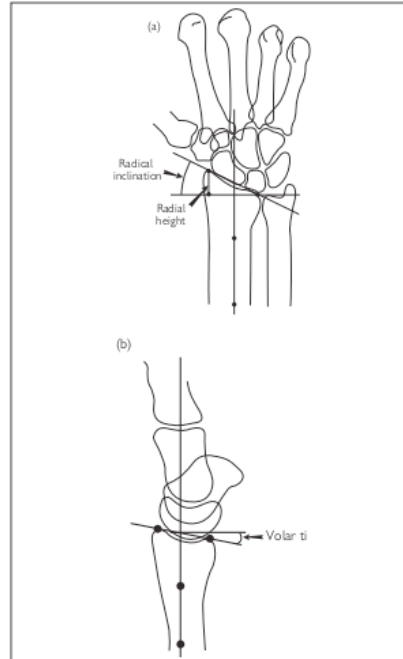
1. Partial articular versus complete articular
2. Fragment number
3. Fragment size (percentage of articular disc)
4. Fragment comminution
5. Fragment stability
6. Displacement and corresponding block to motion
7. Osteopenia
8. Articular impaction
9. Radiocapitellar malalignment
10. Radial neck and metaphyseal comminution and/or bone loss

- Salient Facts:
 - 1) Attempt ORIF of displaced radial head fractures when anatomic reduction, restoration of articular congruity, and initiation of early motion can be achieved. If these goals are not obtainable, ORIF may lead to early fixation failure, nonunion, and loss of elbow/forearm motion.
 - 2) Radial head replacement is preferred for displaced radial head fxs with “more than three fragments, unstable articular fractures in which stable fixation cannot be achieved, and fxs occurring in association with complex elbow injury patterns if stable fixation cannot be ensured.”
- *Current Concepts Radial Head Fractures*¹⁹
 - Salient Facts:
 - 1) Undisplaced or minimally displaced fxs with no rotational block to motion can be treated nonoperatively with excellent results.
 - 2) The minimal amount of displacement in a partial articular radial head fracture required for ORIF to provide a superior outcome to non-operative management is still unknown.
 - 3) Data suggests that patients with comminuted radial head fractures do well with radial head replacement.
- **Proximal ulna fracture and radial head dislocation (Monteggia fx)**^{1,2,4,5,7,8,10}
 - Imaging:
 - AP/lateral elbow, forearm, wrist
 - Possible CT scan for operative planning
 - Classification:⁸
 - Bado Classification:
 - Based on mechanism, direction of the dislocation, and the location/angulation of the fx

Type	Mechanism	Dislocation	Fracture
I	Forced pronation	Radial head anterior	Proximal 1/3 ulna fracture; apex anterior
II	Axial loading	Radial head posterior	Proximal 1/3 ulna fracture; apex posterior
III	Forced abduction	Radial head lateral	Proximal ulna metaphyseal fracture
IV	Forced pronation	Radial head anterior	Proximal 1/3 of the radius and ulna at the same level

- Symptoms:
 - Pain and swelling proximal forearm/elbow
 - Pain with elbow ROM, supination, and pronation
- Associated Injuries/Complications:
 - Radial head fxs
 - Radial head instability
 - Interposed annular ligament
 - Radial nerve/median nerve stretch injury
- Epidemiology: (cite orthobullets)
 - Rare in adults
 - More common in children (peak 4 – 10 yo)
- ED Management:
 - Long arm splint
 - All adult Monteggia fractures require ORIF of the ulna fx and closed versus open reduction of the radial head
 - Orthopaedic consultation is necessary
- Ortho Research:
 - *Monteggia Fractures in Adults: Long Term Results and Prognostic Factors (2007)*¹⁰
 - Salient Facts:
 - 1) Negative prognostic factors include Bado type II, Jupiter type IIa, radial head fracture, coronoid fracture, and complications requiring further surgery.
 - 2) Bado type I injury showed excellent or good functional results in most cases.
 - 3) Bado type II injury showed significantly poorer outcomes, the worst group being those with radial head or coronoid process fractures.
- **Shaft fractures of radius and/or ulna in adults**^{1,2,4,5,7,8,14}
 - Imaging:
 - AP/lateral forearm
 - AP/lateral/oblique wrist
 - AP/lateral elbow
 - Possible CT for operative planning, non emergent
 - Classification:
 - Descriptive
 - Variations:
 - Distal-third radius fx with distal radioulnar joint instability
 - “Galeazzi” aka “fracture of necessity”
 - Isolated ulnar shaft fractures
 - “Nightstick fractures”
 - Distal ulna fx with associated distal radioulnar joint instability

- “Reverse Galeazzi”
- Symptoms:
 - Pain, swelling, ecchymosis over forearm
 - Gross deformity
- Associated Injuries/Complications:
 - Radial artery/ulnar artery damage
 - Median, radial, or ulnar nerve stretch
 - Compartment syndrome/Volkmann ischemia
- Epidemiology:
 - More common in men than in women, 2/2 to higher incidence of motor vehicle collisions
- ED Management:
 - Sugar tong splint
 - If proximal 1/3 of radius or ulna involved, add posterior slab
 - Virtually all of these injuries require Orthopaedic consultation
- Ortho Research:
 - *Isolated Radial Shaft Fractures are More Common Than Galeazzi Fractures (2006)*¹⁴
 - Goals: Retrospective review of isolated fractures of the radial shaft to determine how often these fractures occur without DRUJ injury/instability
 - Salient Points:
 - Rettig and Raskin used fracture location as an index, with fractures 7.5 cm from the lunate facet being stable (previous dogma)
 - Although it's important to identify DRUJ instability, fractures without identifiable radioulnar disruption can be treated without specific treatment of the DRUJ and with immediate immobilization.
- **Distal Radius Fractures**^{1,2,4,5,7,8,11,12,16,18}
 - Imaging:
 - PA, lateral (inclined 20 deg), 45 deg pronated oblique wrist¹⁹
 - AP/lateral elbow
 - CT scan to delineate intraarticular involvement and operative planning-ordered by orthopaedic surgeon
 - Normal radiographic relationships:
 - Radial inclination (avg 22 deg)
 - Radial height (avg 13 mm)
 - Volar tilt (avg 11 deg)

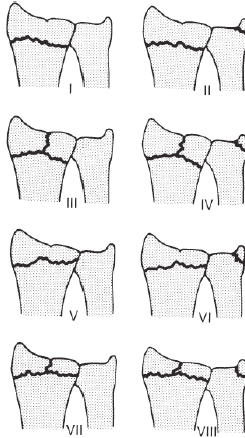


Copyright 2005 Elsevier Science
Add to lightbox

Figure 16-7 The anteroposterior radiograph on the left illustrates normal radial inclination of approximately 22 degrees. The lateral radiograph on the right illustrates normal volar tilt of the distal articular surface of approximately 11 degrees.

- Classification:
 - Fernandez: based on mechanism of injury
 - Type I: bending fx of metaphysis
 - Type II: shearing fx of joint surface
 - Type III: compression fx of the joint surface
 - Type IV: avulsion fx or radiocarpal fx-dislocation
 - Type V: combined fracture pattern (I, II, III, or IV in combinations)
 - Frykman (for colles fractures): based on pattern of intra-articular involvement

Frykman classification of distal radius fractures		
Distal Ulna Fracture:	No	Yes
Extraarticular	I	II
Intraarticular into RC Joint	III	IV
Intraarticular into RU Joint	V	VI
Intraarticular into RC + RU Joints	VII	VIII



• Melone (for intraarticular fractures):

Melone Classification of Intraarticular distal radius fractures	
I	Minimally displaced / Stable
II	Comminuted / Stable
	Displaced Medial Complex Dorsal: die-punch, Barton Palmar: Smith 2
III	Displaced Medial Complex as a unit, Displaced radial shaft fragments
IV	Wide separation or rotation of medial fragments Extensive soft tissue and periarticular damage

▪ Variations:

- Colles fx- dorsally displaced
- Smith fx- volarly displaced
- Barton's fx- fracture/dislocation of radiocarpal joint with intraarticular fx involving the volar or dorsal lip
 - Volar barton vs. dorsal barton fx

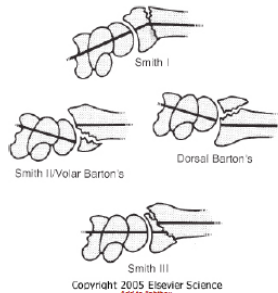
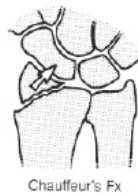

Figure 16-9 Thomas' classification of Smith's fractures. Type I Smith fracture: extra-articular fracture with palmar angulation and displacement of the distal fragment. Type II Smith fracture: intra-articular fracture with volar and proximal displacement of the distal fragment along with the carpus. Type III Smith fracture: extra-articular fracture with volar displacement of the distal fragment and carpus. (In type III the fracture line is more oblique than in a type I fracture.) A Smith type II fracture is essentially a volar Barton fracture. A dorsal Barton fracture, illustrated for comparison, shows the dorsal and proximal displacement of the carpus and distal fragment on the radial shaft.

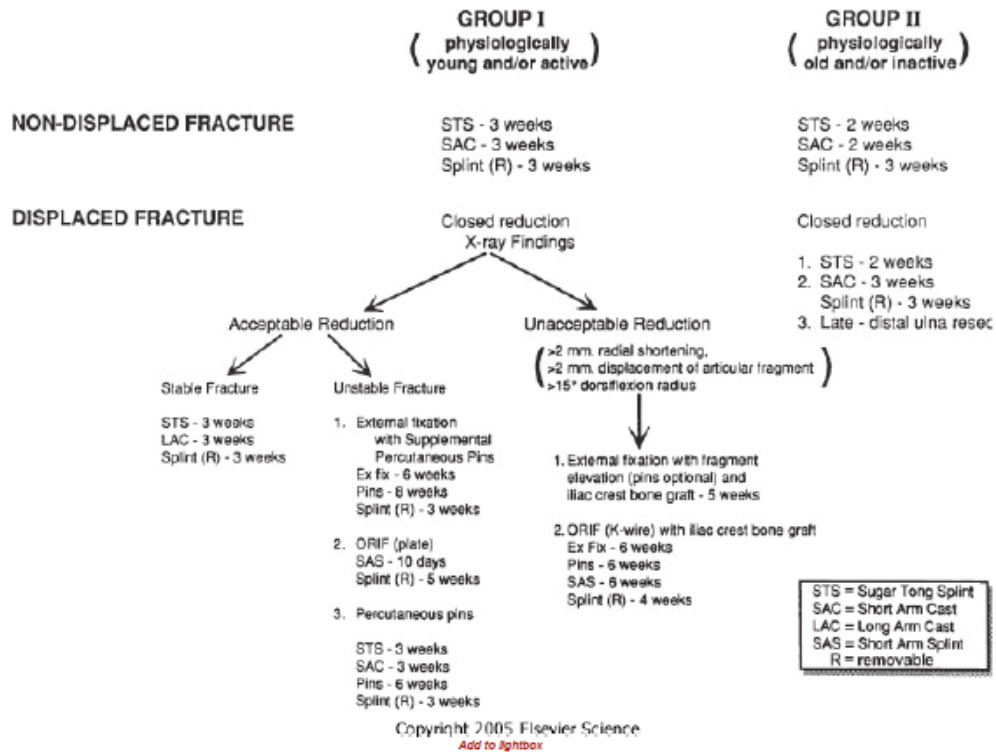
- Chauffer's fx- radial styloid fx



▪ Symptoms:

- Variable wrist deformity
- Pain, swelling, and bruising about the wrist

- Possible median nerve deficits
- Associated injuries/Complications:
 - DRUJ instability
 - The primary stabilizer of the DRUJ is the triangular fibrocartilage complex (TFCC). Additional stabilizers include the ulnocarpal ligaments, extensor carpi ulnaris subsheath, and interosseous membrane (cite JBJS article).
 - Radiographic findings that increase suspicion
 - Ulnar styloid base fracture (most common cause)
 - Widening of the DRUJ interval on PA radiographs
 - Dislocation of DRUJ on lateral radiographs
 - Median nerve compression
 - Relatively common “as a result of concussive insult at the time of trauma or extrinsic nerve compression” (cite JBJS article)
- Epidemiology:
 - Among the most common fractures of the upper extremity (handbook)
 - >650000 annually in US
 - Risk factors for fractures of the distal radius in the elderly include decreased bone density, female sex, white race, family hx, and early menopause
- ED Management:
 - Reduction Maneuver¹⁸
 - Dorsally displaced fractures (most common)
 - With your dominant hand grasp the person’s hand, as if arm wrestling
 - With the non-dominant hand, grab the proximal radius with your thumb on the fracture site dorsally and your fingers curled around the radius proximal to the fracture site
 - Recreate the mechanism of injury by hyperextending the wrist
 - Followed by immediate wrist flexion
 - Shift thumb slightly distally so it is over the distal fragment
 - Using the left thumb volarly and use your fingers to pull dorsally.
 - Acceptable reduction:
 - <5 deg loss of radial inclination
 - <5 mm radial shortening
 - Neutral volar/dorsal tilt
 - < 2mm articular step off
 - Place in well molded sugar tong splint
 - Orthopaedic consultation warranted for open fxs, fxs with neurovascular compromise, comminuted fxs, irreducible fxs, or those associated with other injuries.
 - All pts require follow up Orthopaedic appointment
 - “Need for surgery is determined by fracture stability as well as the quality of reduction.”
 - *Green’s Operative Hand Surgery (7th edition)* Treatment Algorithm



- Ortho Research:
 - *Distal Radius Fractures: Current Concepts (2012)*¹⁶
 - Goals: Review 5-year literature to guide management of distal radius fractures.
 - Salient Points:
 - Recent Cochrane review showed **insufficient evidence to support any one method of surgical fixation**, therefore no treatment could be recommended over the others.
 - Incidence of operative fixation has steadily increased since 1998
 - Various interventions
 - Closed reduction, pinning- only for stable fxs
 - External fixation
 - Individual fragment fixation
 - Dorsal plates
 - Volar fixed-angle plates
 - Intramedullary based devices (i.e. subchondral screws)
 - Bridge plating
 - **Carpal Tunnel Syndrome**^{2,7,8,12}
 - Basic Anatomy
 - 9 tendons, 1 nerve
 - Flexor digitorum superficialis (4), Flexor digitorum profundus (4), and FPL (1)
 - Median nerve

- Imaging:
 - None required in the emergent setting (unless 2/2 to traumatic event)
 - MRI/US may provide insight into possible focal causes of CTS such as localized space occupying lesions, RA, tenosynovitis, or synovitis of the wrist (carpal tunnel article)
- Symptoms:
 - CTS is caused by compression of the median nerve within the carpal tunnel.
 - Paresthesias/numbness in the distribution of the median nerve distal to the carpal tunnel.
 - **Hint:** although the patient's proximal palm is within the median nerve distribution, it is supplied by the palmar cutaneous branch. A nerve notorious for not traveling within the carpal tunnel.
 - Loss of grip strength is a later symptom
- Physical Exam Findings:
 - Tinel test
 - Tapping over the carpal tunnel
 - Positive if recreates "electric-like sensation" in median nerve distribution
 - Phalen test
 - Flexing at wrist for at least 60 seconds
 - Positive if recreates "electric-like sensation" in median nerve distribution
 - Reverse Phalen test
 - Variable mono-filament test (highly sensitive and specific)
 - Carpal tunnel compression test (30 seconds)
- Epidemiology:
 - 0.6% in men, 5.8% in women
 - Insufficient evidence to identify a single "best" examination based clinical test
 - Usually idiopathic in nature
 - May be associated with multiple metabolic disorders, including diabetes, thyroid disease, alcoholism, and pregnancy.
- ED Management:
 - Acute setting: Requires emergent orthopaedic hand consultation
 - Typically requires surgical release to prevent permanent injury to the median nerve
 - Subacute/chronic (most common):
 - Conservative management: rest, anti inflammatories, and ice
 - Splint wrist in neutral position at night (cite Green Hand)
- Ortho Research:
 - *Clinical Diagnosis of Carpal Tunnel Syndrome: Old tests- new concepts (2008)*¹²
 - Salient Points:
 - Tinel's, Phalen's, Reverse Phalen's, and carpal tunnel compression tests are more sensitive, as well as being specific tests for the diagnosis of tenosynovitis of the flexor muscles of the hand, rather than being specific tests for carpal tunnel syndrome and can be used as an indicator for medical management of the condition.

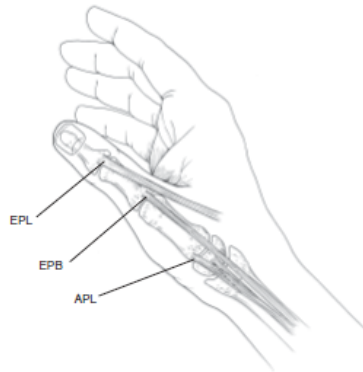
- *Green's Hand Operative Surgery (7th edition)- Compression Neuropathies*⁷
 - Non-operative treatment
 - Wrist splinting, neutral position only at night
 - Oral anti-inflammatories and corticosteroid injections have been utilized with “varying reported success.”
 - Recent evidence suggests that nerve gliding and stretching exercises show symptomatic relief and avoidance of surgery in many patients.
 - Operative treatment
 - Recommended when conservative management has failed
 - The surgeon should choose a method that offers the best visualization of the median nerve to avoid injury.
 - A number of endoscopic systems have been described, but the risk of complications, including iatrogenic nerve injury, poor visualization, inability to identify anatomic variations, incomplete release, and apparent beneficial cost savings is still debated.

- **De Quervain's syndrome**^{2,6,7,17}

- Basic Anatomy:

- Extensor Compartments of the hand

- 1: Abductor pollicis longus (APL), Extensor pollicis brevis (EPB)

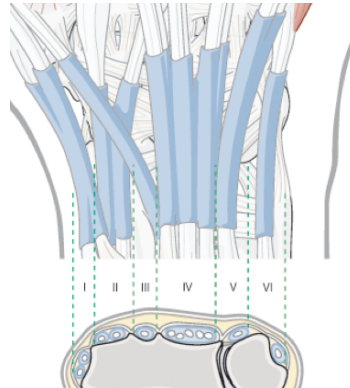


Anatomy of the first dorsal compartment demonstrating the insertion of the abductor pollicis longus (APL), extensor pollicis brevis (EPB), and extensor pollicis longus (EPL) tendons.

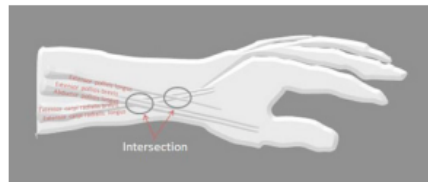
- 2: Extensor carpi radialis longus (ECRL), Extensor carpi radialis brevis (ECRB)
- 3: Extensor pollicis longus (EPL)
- 4: Extensor digitorum communis (EDC), extensor indicis proprius (EIP)
- 5: Extensor digiti minimi
- 6: Extensor carpi ulnaris
- De Quervain's syndrome is tenosynovitis of the first extensor compartment (EPB, APL).
- Imaging:
 - Clinical diagnosis

- No imaging studies required
- MRI/US/bone scans have demonstrated findings that may support the diagnosis
- Symptoms:
 - Pain and swelling over the radial aspect of the wrist and dorsal thumb.
- Physical Exam:
 - Tenderness in the 1st dorsal/extensor compartment
 - + Finkelstein test/Eichhoff maneuver
 - Grip thumb within a closed fist
 - Ulnar deviation of the fist
 - Positive test if this particular motion elicits the patient's pain
- Epidemiology:⁶
 - Case series suggest that affects 6x Women > Men
 - Occupations requiring repetitive typing, lifting, and manipulation have been considered risk factors.
 - Pregnant and lactating women have a higher prevalence of the disease
- ED Management:
 - Conservative management- rest, anti-inflammatories, and ice
 - Thumb spica splint may be applied to allow for rest
 - Outpatient follow up with orthopaedic hand surgeon if symptoms do not resolve
 - Alternative therapies include corticosteroid injections into the extensor sheath and/or surgical release.
- Ortho Research:
 - *The Wrist Hyperflexion and abduction of the Thumb (WHAT) test: a More Specific and Sensitive test to diagnose de Quervain's tenosynovitis than the Eichhoff's test (2013)*⁶
 - Salient Points:
 - Diagnosis is made clinically and is most closely correlated with a positive Finkelstein test or Eichhoff maneuver
 - Radiographs may be used to rule out other wrist pathologies, but are generally not routinely required
 - Nonsurgical management is the mainstay of treatment, consisting primarily of rest, thumb spica splinting, and corticosteroid injection
 - When non-surgical management fails, open surgical release of the first dorsal compartment may be performed.
- **Intersection Syndrome**^{2,3,7,8,17}
 - Tenosynovitis of the second extensor compartment (ECRL/ECRB)
 - Imaging:
 - Clinical diagnosis
 - No imaging required
 - MRI/US have been shown to help in excluding other diagnoses

- Symptoms:
 - Pain/swelling in the area overlaying the second dorsal compartment.



- Epidemiology:
 - There are few prevalence studies, some suggesting between 0.20 to 0.37% of the population
- ED Management:
 - Limit wrist overuse
 - Conservative management with rest, anti-inflammatories, and ice
 - Wrist volar splint, 20 deg flexion (less tension on tendons)
 - Follow up with orthopaedic hand surgeon if symptoms persist
 - Alternative therapies include corticosteroid injection
 - Surgical release
- Ortho Research:
 - Extremely limited
 - *Intersection syndrome: ultrasound imaging (2013)*³
 - Goals: evaluate use of ultrasound for the diagnosis of intersection syndrome
 - Salient Points:



- Most common site of inflammation was 4-8 cm proximal to Lister's tubercle, where the tendons of first extensor compartment intersect the second compartment.
- Ultrasound is a useful means of detecting intersection syndrome, anatomic landmarks, and excludes other pathology (i.e. de Quervain's).

References

1. Black, W. S., and Jonathan A. Becker. "Common Forearm Fractures in Adults." *American Family Physician* 80.10 (2009): n. pag. Web.

2. Egol, Kenneth A., Kenneth J. Koval, Joseph D. Zuckerman, and Kenneth J. Koval. *Handbook of Fractures*. Philadelphia: Wolters Kluwer/Lippincott Williams & Wilkins Health, 2010. Print.
3. Draghi, Ferdinando, and Chandra Bortolotto. "Intersection Syndrome: Ultrasound Imaging." *Skeletal Radiology* 43.3 (2014): 283-87. Print.
4. Falcon-Chevere, Jorge L., Dana Mathew, Jose G. Cabanas, and Eduardo Labat. "Management and Treatment of Elbow and Forearm Injuries." *Emergency Medicine Clinics of North America* 28.4 (2010): 765-87. Print.
5. Goldberg, Howard, Jeremy W. Young, Bruce Reiner, Charles Resnik, and Thomas Gillespie. "Double Injuries of the Forearm: A Common Occurrence." *Radiology* 185.1 (2007): 223-27. Web.
6. Goubau, J. F., A. V. Tongel, P. V. Hoonacker, and D. Kerckhove. "The Wrist Hyperflexion and Abduction of the Thumb (WHAT) Test: A More Specific and Sensitive Test to Diagnose De Quervain Tenosynovitis than the Eichoff Test." *Journal of Hand Surgery (European Volume)* 286th ser. 2014.39 (2013): n. pag. Web.
7. Green, David P., and Scott W. Wolfe. *Green's Operative Hand Surgery*. New York: Churchill Livingstone, 2011. Print.
8. Humbyrd, Casey Jo. *Orthopaedic Emergencies*. Oxford: Oxford UP, 2012. Print.
9. Ilyas, Asif M., Michael A. Ast, Alyssa A. Schaffer, and Joseph Thoder. "De Quervain Tenosynovitis of the Wrist." *Journal of the American Academy of Orthopaedic Surgeons* 15.12 (2007): 757-64. Web.
10. Konrad, G. G., K. Kundel, P. C. Kreuz, M. Oberst, and N. P. Sudkamp. "Monteggia Fractures in Adults: LONG-TERM RESULTS AND PROGNOSTIC FACTORS." *Journal of Bone and Joint Surgery - British Volume* 89-B.3 (2007): 354-60. Print.
11. Kural, Cemal, Ibrahim Sungur, Ibrahim Kaya, Akin Ugras, Ahmet Erturk, and Ercan Cetinus. "Evaluation of the Reliability of Classification Systems Used for Distal Radius Fractures." *Orthopedics* 33.11 (2010): n. pag. Web.
12. Miedany, Yasser E., Samia Ashour, Sally Youssef, Annie Mehanna, and Fatma Meky. "Clinical Diagnosis of Carpal Tunnel Syndrome: Old Tests-new Concepts." *Joint Bone Spine* 75 (2008): 451-57. Web.
13. Miller, Mark D., Stephen R. Thompson, and Jennifer Hart. *Review of Orthopaedics*. Philadelphia, PA: Elsevier/Saunders, 2012. Web.
14. "Procedures Consult." *Procedures Consult*. N.p., n.d. Web. 28 Apr. 2014.
15. Ring, David, Richard Rim, Creg Carpenter, and Jesse B. Jupiter. "Isolated Radial Shaft Fractures Are More Common Than Galeazzi Fractures." *The Journal of Hand Surgery* 31.1 (2006): 17-21. Print.
16. Ruchelsman, David E., Dimitrios Christoforou, and Jesse Jupiter. "Current Concepts Review Fractures of the Radial Head and Neck." *The Journal of Bone and Joint Surgery* 95 (2013): 469-78. Web.
17. Schnependahl, Johannes, Joachim Windolf, and Robert A. Kaufmann. "Distal Radius Fractures: Current Concepts." *The Journal of Hand Surgery* 37.8 (2012): 1718-725. Print.

18. Thompson, Jon C., and Frank H. Netter. *Netter's Concise Orthopaedic Anatomy*. Philadelphia, PA: Saunders Elsevier, 2010. Print.
19. Thompson, Stephen R., and Dan A. Zlotolow. *Handbook of Splinting and Casting*. Philadelphia, PA: Elsevier/Mosby, 2012. Print.
20. Yoon, Albert, George S. Athwal, Kenneth J. Faber, and Graham J. King. "Current Concepts Radial Head Fractures." *Journal of Hand Surgery A* 37 (2012): 2626-634. Web.

Wrist Injury

Common Splinting Techniques^{10,15}

- **Supplies:**

- Warm water
- Soft cotton bandage/undersplint material (i.e. webril padding)
- Plaster bandages (3 inch)
- Elastic bandages (i.e. Ace)
- Adhesive tape



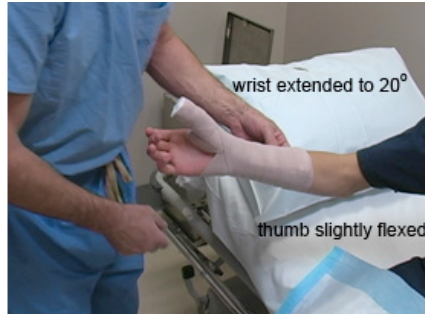- **Thumb spica**

- **Indications:**

- Scaphoid fractures
- Thumb metacarpal fractures
- Thumb carpometacarpal dislocations
- Add to radial gutter for radial sided carpal injuries (i.e. trapezium, trapezoid)

- **Application:**

- Step 1: Seated position, arm rested on a table with elbow bent to 90 deg
- Step 2: Measure length of splint by unrolling webril, **along radial aspect of the forearm, from the tip of the thumb to the proximal third of the radius.**
 - Lay this webril on the bed (i.e. anywhere that is convenient), roll out an additional 3 layers on top of it to form cast padding
- Step 3: Roll out 6-8 layers of plaster bandages over the webril
- Step 4: Soak the plaster in slightly warm to room temperature water (the cooler the faster it hardens)
 - Gently squeeze on the plaster in a laminating fashion, top to bottom motion
- Step 5: Place plaster over cast padding, roll over excess webril (which should be slightly longer) over the plaster
- Step 6: Apply splint along thumb and radial aspect of the forearm.
- Step 8: Roll 2-3 inch elastic bandage (of whatever form is used by your institution) over the splint, in a distal to proximal direction
- Step 9: Continue to mold the splint until hardened, **maintaining wrist at 20 deg extension, thumb slightly flexed at both the MCP and IP.**



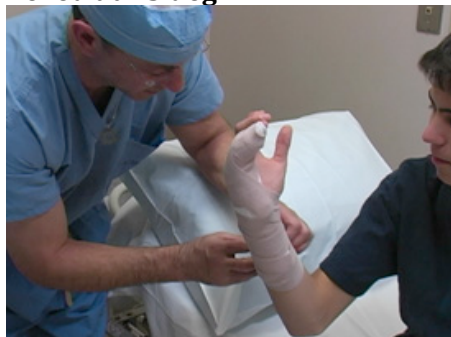- **Ulnar gutter**

- Indications:

- Ulnar sided carpal injuries (i.e. pisiform, triquetrum, and hamate fractures)
 - Ring and little finger metacarpal and proximal phalangeal fractures
 - Little finger metacarpal neck fracture (aka Boxer's fracture)

- Application:

- Step 1: Seated position, arm rested on a table with elbow bent to 90 deg
 - Step 2: Measure length of splint by unrolling webril, **from the tip of the little finger to a point 5-10 cm from the elbow (before it), along the ulnar portion of the forearm.**
 - Lay this webril on the bed (i.e. anywhere that is convenient), roll out an additional 3 layers on top of it to form cast padding
 - Step 3: Roll out 6-8 layers of plaster bandages over the webril
 - Step 4: Soak the plaster in slightly warm to room temperature water (the cooler the faster it hardens)
 - Gently squeeze on the plaster in a laminating fashion, top to bottom motion
 - Step 5: Place plaster over cast padding, roll over excess webril (which should be slightly longer) over the plaster
 - Step 6: Apply splint along the ulnar side of the forearm. **It should extend to the tip of the little finger and wrap along the ring and little finger.**
 - Step 8: Roll 2-3 inch elastic bandage (of whatever form is used by your institution) over the splint, in a distal to proximal direction
 - Step 9: Continue to mold the splint until hardened, **maintaining wrist at 20 deg extension, and the MCP, PIP, and DIP of the little and ring finger flexed at 45 deg.**

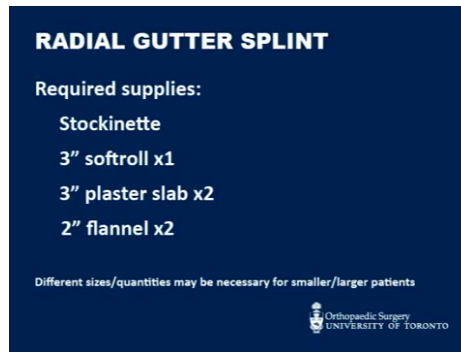


- **Radial gutter**

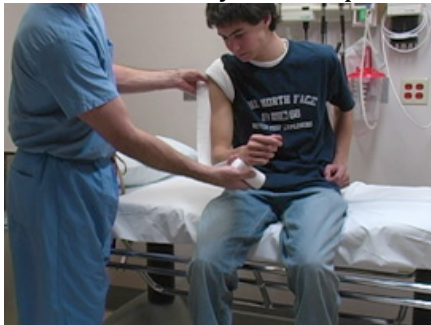- Indications:

- Added to thumb spica for radial sided carpal fractures (i.e. trapezium, trapezoid)
 - Index and long finger metacarpal and proximal phalangeal fractures

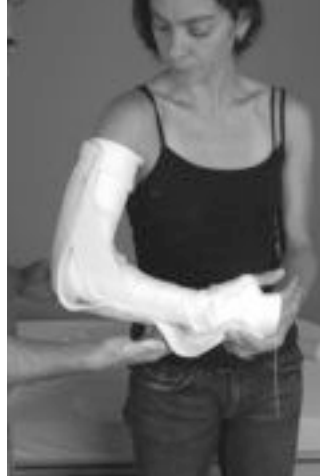- Application:
 - Double click video



- **Long arm**
 - Indications:
 - Adult distal radius fx
 - Adult forearm fractures
 - Application:
 - Step 1: Arm in neutral abduction, 90 deg elbow flexion
 - Step 2: Apply the stockinette
 - From **distal palmar crease to 5 cm below the axillary fold**
 - Step 3: Measure length of splint by unrolling webril, **posteriorly from the inferior border of the deltoid muscle along the triceps proximally, along the ulnar border distally, to the head of the fifth metacarpal.**
 - Lay this webril on the bed (i.e. anywhere that is convenient), roll out an additional 3 layers on top of it to form cast padding
 - Step 4: Roll out 10-12 layers of plaster bandages over the webril
 - Step 5: Soak the plaster in slightly warm to room temperature water (the cooler the faster it hardens)
 - Gentle squeeze on the plaster in a laminating fashion, top to bottom motion
 - Step 6: Place plaster over cast padding, roll over excess webril (which should be slightly longer) over the plaster
 - Step 7: Apply splint to the posterior aspect of the arm, from the deltoid to the hand.
 - Important Recommendation from Orthopaedics Hand
 - The splint should not go beyond the distal palmar crease (volar side of MCP joints), because it causes stiffness at the joints



- Related to the fact that the dorsal surface of the metacarpal is longer than the volar surface, pulling the collateral ligaments of the MCP on inappropriate tension versus relaxation
- Step 8: Roll 3 inch elastic bandage (of whatever form is used by your institution) over the splint, in a distal to proximal direction
- Step 9: Continue to mold the splint until hardened (tapping on it with two fingers gives an indication), maintain a neutral to 30 deg wrist extension



- **Short arm**
 - Indications:
 - Distal radius fx (non acute)
 - Non scaphoid carpal fxs
 - Distal ulna fx
 - Application:
 - Step 1: Arm in neutral abduction, 90 deg elbow flexion
 - Step 2: Apply the stockinette
 - From **distal palmar crease to 5 cm distal to the elbow**
 - Step 3: Measure length of splint by unrolling webril along the course, **from the distal palmar crease to 5-10 cm distal to the elbow**
 - Lay this webril on the bed (i.e. anywhere that is convenient), roll out an additional 3 layers on top of it to form cast padding
 - Step 4: Roll out 8-10 layers of plaster bandages over the webril
 - Step 5: Soak the plaster in slightly warm to room temperature water (the cooler the faster it hardens)
 - Gentle squeeze on the plaster in a laminating fashion, top to bottom motion
 - Step 6: Place plaster over cast padding, roll over excess webril (which should be slightly longer) over the plaster
 - Step 7: Apply splint along volar surface of the forearm and wrist, mold using the palms of your hands
 - Important Recommendation from Orthopaedics Hand
 - The splint should not go beyond the distal palmar crease (volar side of MCP joints), because it causes stiffness at the joints
 - Related to the fact that the dorsal surface of the metacarpal is longer than the volar surface, pulling

the collateral ligaments of the MCP on inappropriate tension versus relaxation

- Step 8: Roll 3 inch elastic bandage (of whatever form is used by your institution) over the splint, in a distal to proximal direction
- Step 9: Continue to mold the splint until hardened (tapping on it with two fingers gives an indication), **maintain a neutral to 30 deg wrist extension**

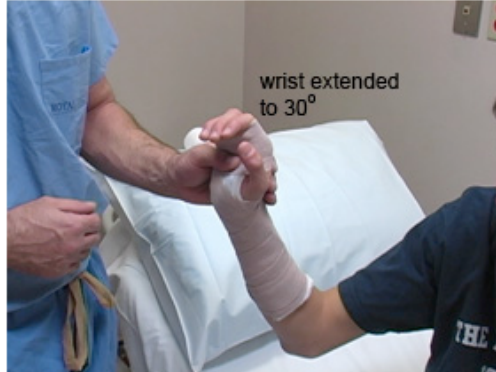
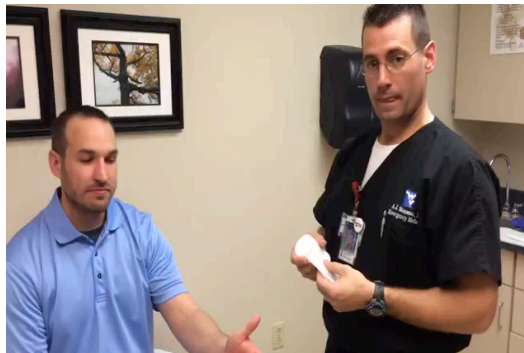
Figure 6 : The "position of function"

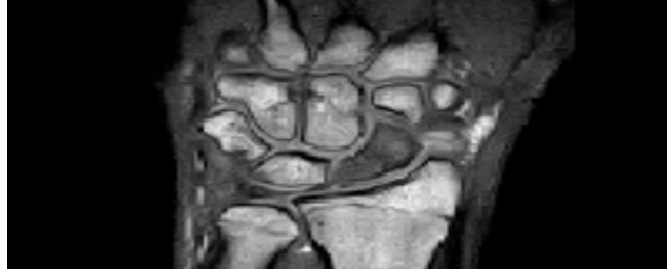- **Volar Splint aka "cockup"**
 - Indications:
 - Carpal tunnel
 - Central carpal fracture/fracture-dislocations
 - Application:
 - Double click video



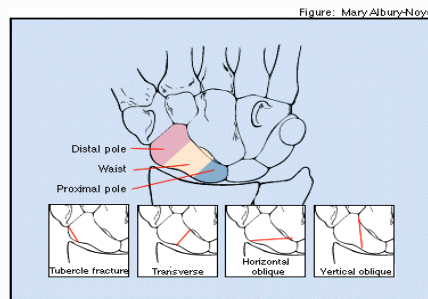
Differential Diagnosis

- **Scaphoid fracture**^{2,4,14,16}
 - Imaging:
 - Scaphoid series²
 - PA in ulnar deviation (navicular view)
 - PA of the scaphoid
 - Semi-pronated oblique in ulnar deviation- detects fractures of tubercle
 - True lateral of the wrist- detects instability patterns
 - AP with grip- r/o ligamentous injury
 - Classic Teaching:
 - Negative imaging, high clinical suspicion = repeat radiographs at 2-3 weeks
 - New recommendations by *Green's Operative Hand Surgery (6th edition)*:¹⁶

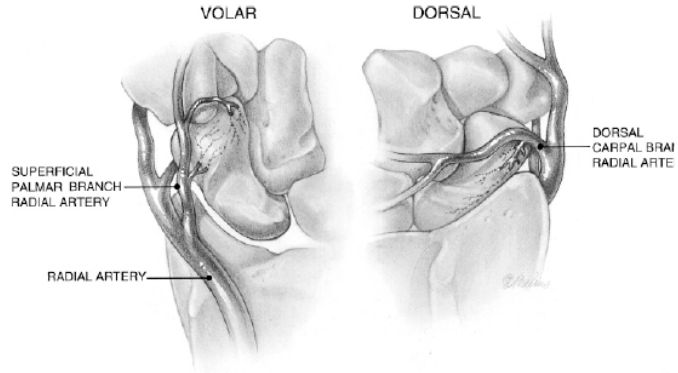
- **Perform MRI for clinically suspected cases with normal radiographs or bone scan at 48-72 hours from injury.**
 - Dorsay has shown that immediate MRI of suspected scaphoid fractures provides a cost benefit when compared with splinting and repeat radiographs.



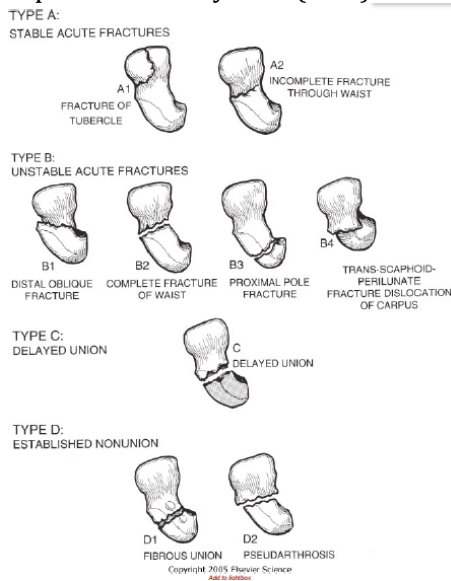
- Scintigraphy/CT/MRI utilized for occult scaphoid fractures.
 - Gaebler and colleagues performed a prospective blinded study of 32 patients in whom a scaphoid fracture was suspected. MRI was performed at an average of 2.8 days after trauma, with a sensitivity and specificity of 100%.
- Basic Anatomy¹⁶
 - 5 articulating surfaces, almost entirely covered by cartilage
 - In contact with radius, lunate, capitate, trapezium, and trapezoid
 - Serves as a mechanical link between the proximal and distal carpal rows.
 - Divided into a proximal pole, distal pole, tubercle, and waist (4 parts)



- Ligamentous attachments
 - Scapholunate interosseous ligament inserts into the proximal, dorsal, and palmar edges of the proximal pole.
 - Radioscaphocapitate ligament attaches to the lateral palmar surface of the scaphoid waist and the proximal surface of the distal pole.
 - Scaphotrapezium ligament attaches to lateral surface of the distal pole.
 - Scaphocapitate ligament attaches to the palmar and lateral nonarticulating surface of the distal pole.
- Blood supply
 - 2 arterial groups supplying the scaphoid (postulated by Gelberman and Menon)
 - Superficial palmar branch of the radial artery
 - Dorsal carpal branch of the radial artery



- *Proximal pole is an intra-articular structure covered in hyaline cartilage, making it entirely dependent on an intraosseous blood supply^{5,16}*
 - *Therefore, fractures of the scaphoid waist or proximal third depend on fracture union for revascularization.*
- Classification^{5,16}
 - Based on fx pattern- Russe
 - Horizontal oblique
 - Transverse
 - Vertical oblique
 - Based on displacement
 - Stable- nondisplaced, no step off
 - Unstable- displaced, > 1 mm step off, scapholunate angulation > 60 deg, radiolunage angulation > 15 deg.
 - Based on location
 - Tuberosity, distal pole, waist, horizontal oblique, vertical oblique, transverse, proximal pole
 - Herbert alphanumeric system (new) _____



- Symptoms:
 - Tenderness to palpation over the scaphoid tubercle and anatomical snuff-box (sensitivity 100%)
- Physical Exam:

- Scaphoid shift test- pain with dorsal-volar shifting of the scaphoid
- Associated injuries:
 - Proximal fractures
 - Poor blood supply = high risk of AVN and nonunion
 - Distal fractures
 - Excellent blood supply= lowest risk of AVN and nonunion
 - Middle third/scaphoid waist fractures
 - Intermediate blood supply = relative AVN risk
 - Carpal dislocations and ligamentous injuries
- Epidemiology:
 - The most common mechanism is a fall onto the outstretched hand, forces dorsiflexion and ulnar deviation
 - Non union occurs in 5-10% of undisplaced scaphoid fractures¹
- ED Management^{5,6}
 - Isolated distal-third fractures- radial gutter thumb spica splint
 - Isolated middle- and proximal third fractures- sugar tong-thumb-spica splint
 - Scaphoid fractures with distal radius/ulnar fractures- sugar tong-thumb spica splint
 - Any fx that could potentially require surgery (i.e. displaced, middle/distal third/waist), non-union, open fxs, fxs with associated injuries, fxs with neurovascular compromise all warrant orthopaedic hand consultation.
 - All documented scaphoid fractures require orthopaedic follow up
- Ortho research:
 - *Current methods of diagnosis and treatment of scaphoid fractures (2011)*¹⁹

Table 1

Sensitivity and specificity for bone scans, MR examination and CT scans

	Sensitivity (%)	Specificity (%)
Bone scan [19]	100 (83-100)	90 (81-96)
MR examination [19]	80 (56-94)	100 (96-100)
CT [48]	93 (83-98)	99 (96-100)

- Xray:
 - Initial radiographs detect at most 70% of all scaphoid fractures. No consensus regarding the best ones to use. AP/lateral and “at least two additional views are advocated.”
- CT
 - Difficult to ascertain if it is a useful diagnostic tool for scaphoid fractures because of insufficient inclusion of patients in research to date.
- Bone scintigraphy
 - Can rule out scaphoid fractures with “high level of confidence” (cite green). Sensitivity close to 100%, though approximately 25% false positives.
- MRI
 - Early MRI within 1 day has a limited sensitivity of 80%.
 - *Green’s Operative Hand Surgery (6th edition)* recommends new data suggests diagnostic MRI at 48-72 hours)
- Sonogram

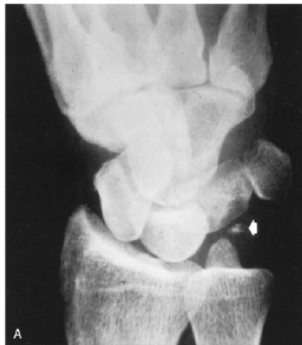- Routine use not indicated.
 - Cast immobilization
 - Occult/stable fractures
 - No study proving the best immobilization, but slight dorsal extension has a positive effect on grip strength and wrist ROM.
 - Generally, cast for 6 weeks should be sufficient for most non-displaced, stable fractures.
 - Operative management
 - Indicated for unstable fractures
 - Distal and middle fractures best approached from the volar side, good exposure/conserves blood supply.
 - Displaced proximal pole fx's require dorsal approach.
- **Lunate fracture** ^{5,6,9,13,14,16}
 - **“Fractures of the lunate, as distinguished from Kienbock disease, are rare”** ¹⁶
 - Imaging:
 - PA/lateral wrist
 - Often inconclusive
 - CT scan most easily demonstrates the fracture
 - MRI used for diagnosing associated Kienbock disease
 - Basic Anatomy:
 - Vascular supply from proximal carpal arcade dorsally and volarly
 - “Internal anastomoses are present, so both dorsal and palmar flow must be occluded for the lunate to lose circulation; fractures that split the bone into dorsal and palmar halves or dislocations leave a capsular hinge intact should not be expected to result in AVN”¹⁶
 - Classification:
 - 5 groups
 - Frontal fractures of the palmar pole
 - Osteochondral fractures of the proximal articular surface without substantial damage to the nutrient vessels
 - Frontal fractures of the dorsal pole
 - Transverse fractures of the body
 - Transarticular frontal fractures of the body of the lunate
 - Symptoms:
 - Tenderness to palpation over the dorsal wrist overlying the distal radius and lunate
 - Painful ROM
 - Associated injuries:
 - Avascular necrosis
 - Perilunate dislocation
 - Epidemiology:
 - 4th most fractured carpal bone
 - Teisen and Hjarbaek divided these injuries into five groups¹⁶
 - Based on a review of 17 cases collected over 31 years
 - Group 1: volar pole (most common)
 - Group 2: small marginal chip
 - Group 3: dorsal pole

- Group 4: Sagittal
 - Group 5: Transverse
 - ED Management:
 - Non displaced fractures
 - Short arm splint usually sufficient
 - Limited avulsion fractures require at least 4 weeks immobilization²
 - Displaced fractures
 - Should be treated surgically, therefore requires Orthopaedic consultation.
 - All fractures need Orthopaedic follow up appointment
- **Capitate Fracture**^{4,6,9,14,16}
 - Imaging:
 - Standard scaphoid views
 - PA in ulnar deviation (navicular view)
 - PA of the scaphoid
 - Semi-pronated oblique in ulnar deviation- detects fractures of tubercle
 - True lateral of the wrist- detects instability patterns
 - AP with grip- r/o ligamentous injury
 - CT scan may be required
 - Basic Anatomy:
 - Largest carpal bone
 - 1st carpal bone to ossify
 - Retrograde blood supply
 - Classification:
 - No official scheme
 - Symptoms:
 - Tenderness and painful dorsiflexion at the distal rim of the radius
 - Associated injuries:
 - Perilunate dislocations- urgent consultation
 - Scaphoid fractures
 - Carpometacarpal fractures and dislocations
 - Midcarpal arthritis
 - Avascular necrosis
 - Epidemiology:
 - Isolated injury to the capitate is uncommon, owing to its relatively protected position
 - 50% of fractures will be associated with concomitant ligamentous and bony injuries
 - ED Management:
 - Capitate fractures require emergent reduction to minimize the risk of osteonecrosis
 - If closed reduction unattainable, Orthopaedic consultation is warranted
 - Splinting⁶
 - Radial gutter thumb spica
 - Radial sided carpal injuries (i.e. trapezium, trapezoid)
 - Ulnar gutter

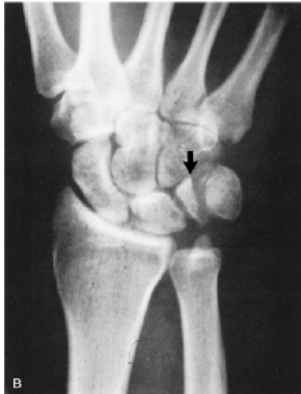- Ulnar sided carpal injuries (i.e. pisiform, triquetrum, and hamate fractures)
- Volar slab
 - Central carpal injuries (i.e. lunate, capitate)
- Displaced fractures, complicated injury patterns, associated injuries/dislocations, neurovascular compromise all require Orthopaedic consultation.
- All fractures need Orthopaedic hand follow up appointment

- **Triquetrum fracture**^{5,6,8,12,16}

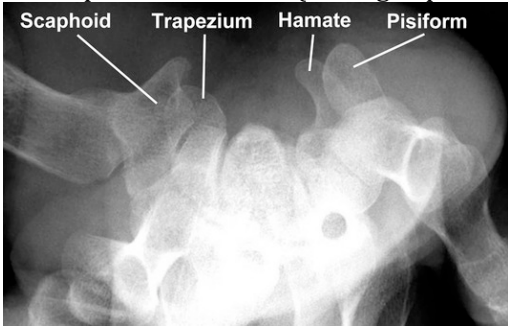
- Imaging:
 - PA/lateral/oblique wrist
 - MRI/CT scan/bone scan to be utilized with negative radiographs, but high clinical suspicion
- Basic Anatomy:
 - Lies deep to the pisiform and ulnar styloid.
 - Articulates with TFCC
- Classification:¹⁶
 - Based on location
 - 1) Dorsal cortical fractures- impaction is the most common mechanism



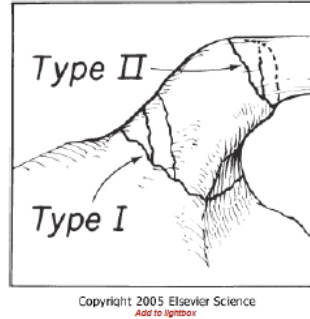
- 2) Body fractures- usually non-displaced



- 3) Avulsion fracture off the volar aspect
- Symptoms:
 - Tenderness to palpation on the dorsoulnar aspect of the wrist
 - Painful ROM
- Associated injuries:
 - Commonly associated with other carpal injuries
 - Perilunate fracture-dislocations
 - Avascular necrosis is rare

- Epidemiology:
 - Second or third most common carpal bone fracture
 - High affiliation with skaters
- ED Management:
 - Splinting⁶
 - Radial gutter thumb spica
 - Radial sided carpal injuries (i.e. trapezium, trapezoid)
 - Ulnar gutter
 - Ulnar sided carpal injuries (i.e. pisiform, triquetrum, and hamate fractures)
 - Volar slab
 - Central carpal injuries (i.e. lunate, capitate)
 - Displaced fxs, fxs with associated injuries, open fractures, or neurovascular compromise all warrant orthopaedic consultation.
 - All fractures need Orthopaedic hand follow up appointment
- Ortho Research:
 - *Isolated displaced non-union of a triquetral body fracture: a case report (2012)*¹²
 - Case report of 29-year-old man with isolated displaced triquetral body fracture missed on initial plain radiographs, with subsequent non-union and operative fixation.
 - Recommend evaluation of ulnar sided wrist pain s/p history of fall with CT or MRI
- **Pisiform Fractures**^{5,6,9,16}
 - Imaging:
 - PA/lateral/oblique wrist
 - Lateral view of wrist with forearm supination of 20 to 45 deg
 - Or Carpal tunnel views (20 deg supination oblique view)
 - 
 - MRI/CT scan/bone scan to be utilized with negative radiographs, but high clinical suspicion
- Basic Anatomy:
 - Large sesamoid bone
 - Imbedded in flexor carpi ulnaris (FCU) tendon
 - Anterolateral to triquetrum
 - Last carpal bone to ossify at around 8 to 12 years of age
- Classification:
 - Based on pattern
 - Transverse avulsion
 - Parasagittal
 - Comminuted

- Symptoms:
 - Tenderness on the volar aspect of the ulnar wrist
 - Painful passive extension of the wrist
- Associated Injuries:
 - Ulnar neuropathy 2/2 to pisiform's close proximity to Guyon's canal
 - Non union
 - Post traumatic pisotriquetral arthritis
- Epidemiology:¹⁶
 - Represents 1% of carpal fractures (rare)
 - Most common MOI is a direct blow to the hypothenar eminence.
- ED Management:
 - Splinting⁶
 - Radial gutter thumb spica
 - Radial sided carpal injuries (i.e. trapezium, trapezoid)
 - Ulnar gutter
 - Ulnar sided carpal injuries (i.e. pisiform, triquetrum, and hamate fractures)
 - Volar slab
 - Central carpal injuries (i.e. lunate, capitate)
 - Displaced fxs, fxs with associated injuries, open fractures, or neurovascular compromise all warrant orthopaedic consultation.
 - All fractures need Orthopaedic hand follow up appointment
- Ortho Research:
 - *Green's Operative Hand Surgery (7th edition)*¹⁶
 - Cast treatment of acute pisiform fractures is now recommended, though there is no evidence that it alters the natural history of the injury.
 - If nonunion or posttraumatic pisotriquetral arthritis occurs, pisiform excision is usually the procedure of choice. Complications are extremely rare.
- **Trapezium**^{5,6,7,8,9,11,17}
 - Imaging:
 - PA/lateral/oblique wrist
 - Lateral or PA with wrist pronated
 - MRI/CT scan/bone scan to be utilized with negative radiographs, but high clinical suspicion
 - Basic Anatomy:
 - Saddle shaped
 - Has a groove for flexor carpi radialis (FCR) tendon
 - Classification/variations:¹⁶
 - 3 main types
 - Body fractures (typically vertical)
 - Marginal trapeziometacarpal fractures
 - Trapezial ridge fractures (most common)
 - Type I
 - Occur at the base, typically heal with immobilization
 - Type II
 - Occur at the tip, less likely to heal with immobilization. Treated with surgical excision⁴



- Symptoms:
 - Tenderness to palpation over radial wrist
 - Painful ROM
- Associated Injuries:
 - Carpometacarpal dislocations
 - First metacarpal fractures
 - Median nerve compression (rare)
 - About 60% report unsatisfactory outcomes secondary to degenerative changes
- Epidemiology:
 - 3% of carpal fractures
 - High affiliation with cyclists
- ED Management:
 - Splinting⁶
 - Radial gutter thumb spica
 - Radial sided carpal injuries (i.e. trapezium, trapezoid)
 - Ulnar gutter
 - Ulnar sided carpal injuries (i.e. pisiform, triquetrum, and hamate fractures)
 - Volar slab
 - Central carpal injuries (i.e. lunate, capitate)
 - Displaced fxs, fxs with associated injuries, open fractures, or neurovascular compromise all warrant orthopaedic consultation.
 - All fractures need Orthopaedic hand follow up appointment
- Ortho Research:
 - *Trapezium fracture- a common technique to fix a rare injury: a case report (2009)*¹⁷
 - Goal:
 - Report a case of a 27-year-old RHD male with closed vertical trapezium fracture and 1st CMC dislocation, treated with closed reduction and percutaneous K-wire fixation.
- Trapezoid fracture^{5,6,7,9,14,16}
 - Imaging:
 - PA/lateral/oblique wrist (usually sufficient)
 - If negative radiographs, but clinical suspicion high.
 - Robert View = True AP
 - MRI/CT scan/bone scan to be utilized with negative radiographs, but high clinical suspicion
 - Basic Anatomy:
 - Second smallest carpal bone

- Surrounded on three sides by other carpal bones- capitate, trapezium, and scaphoid
- Articulates with second metacarpal
- Classification:
 - Descriptive
- Symptoms:
 - Pain at the base of the second metacarpal.
 - Possible pain in the snuffbox.
 - 2nd carpometacarpal joint pain with ROM
- Associated injuries:
 - Dorsal dislocation of the trapezoid or is articulating metacarpal
 - Palmar dislocation of the trapezoid (less common)
 - Post traumatic osteoarthritis at the 2nd carpometacarpal articulation
- Epidemiology
 - Rare
 - Well protected by ligaments and its inherent shape
- ED Management:
 - Fractures with displacement should be immediately reduced.
 - Splinting
 - Radial gutter thumb spica
 - Radial sided carpal injuries (i.e. trapezium, trapezoid)
 - Ulnar gutter
 - Ulnar sided carpal injuries (i.e. pisiform, triquetrum, and hamate fractures)
 - Volar slab
 - Central carpal injuries (i.e. lunate, capitate)
 - Displaced fxs, fxs with associated injuries, open fractures, or neurovascular compromise all warrant orthopaedic consultation.
 - All fractures need Orthopaedic hand follow up appointment
- Ortho research:
 - Green's Operative Hand Surgery (7th Edition)¹⁶:
 - Non displaced Isolated fractures of the trapezoid
 - May be treated nonoperatively
 - Displaced fractures
 - Small fracture fragment- closed reduction, cast protection
 - Larger fracture fragment- open reduction, bone grafting, and carpometacarpal arthrodesis.
 - Trapezoid excision not advised
- **Hamate Fracture/Hook of the Hamate Fracture**^{5,6,8,9}
 - Imaging:
 - PA/lateral/oblique wrist
 - "Detection of fractures of the body of the hamate requires careful radiographic examination, often including several oblique projections until the plane of the fracture can be clearly seen."
 - Carpal Tunnel View (20 deg supination oblique) may be helpful
 - MRI/CT scan/bone scan to be utilized with negative radiographs, but high clinical suspicion
 - Basic Anatomy:
 - Volar oriented hook that is distal and radial to pisiform.

- Hook of hamate is in close proximity to ulnar artery (lateral border of Guyon canal), putting it at risk with injury.
- Classification/Variations:
 - Descriptive
 - Body
 - Distal articular surface
 - Hamulus
 - Hook of hamate
- Symptoms:
 - Pain and tenderness over the hamate
- Associated injuries:^{5,6,16}
 - 4th and 5th metacarpal fractures/fracture-dislocations
 - Hamate dislocation
 - Ulnar neuropathy
 - Median neuropathy
 - Injury to the ulnar artery
 - Compartment syndrome
 - Ruptures of the flexor tendons to the small finger (chronic)
 - Non-union
- Epidemiology:
 - Hook of hamate fractures are a frequent athletic injury that occurs when the palm is struck by an object (i.e. baseball bat, golf club, hockey stick)
- ED Management:
 - Splinting
 - Radial gutter thumb spica
 - Radial sided carpal injuries (i.e. trapezium, trapezoid)
 - Ulnar gutter
 - Ulnar sided carpal injuries (i.e. pisiform, triquetrum, and hamate fractures)
 - Volar slab
 - Central carpal injuries (i.e. lunate, capitate)
 - Displaced fxs, fxs with associated injuries, open fractures, or neurovascular compromise all warrant orthopaedic consultation.
 - All fractures need Orthopaedic hand follow up appointment
- Ortho research:
 - *Green's Operative Hand Surgery (7th edition)*¹⁶
 - Isolated body fractures are stable, become asymptomatic after immobilization for 4-6 weeks (only if fracture line remains extraarticular).
 - If fracture fragments are unstable/displaced, or there is carpometacarpal instability, ORIF is preferred.

References

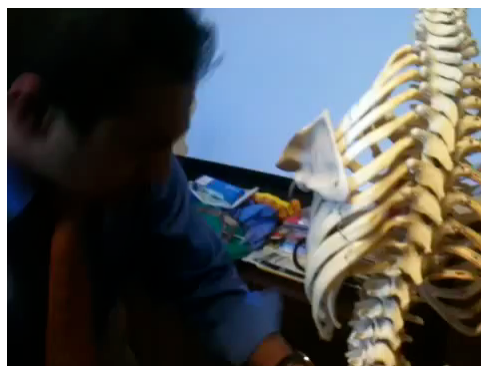1. Alshryda, S., A. Shah, S. Odak, J. Al-Shryda, B. Ilango, and S.r. Murali. "Acute Fractures of the Scaphoid Bone: Systematic Review and Meta-analysis." *The Surgeon* 10.4 (2012): 218-29. Print.
2. Day, Thomas, MD. "Wrist Fractures, Injuries, and Disorders." Grand Rounds. USC Health Sciences, Los Angeles. 2014. Lecture.

3. Dillon, Mark T., and Jeffrey C. King. "Treatment of Chronic Biceps Tendon Ruptures." *Hand* 8.4 (2013): 401-09. Print.
4. Draghi, Ferdinando, and Chandra Bortolotto. "Intersection Syndrome: Ultrasound Imaging." *Skeletal Radiology* 43.3 (2014): 283-87. Print.
5. Egol, Kenneth A., Kenneth J. Koval, Joseph D. Zuckerman, and Kenneth J. Koval. *Handbook of Fractures*. Philadelphia: Wolters Kluwer/Lippincott Williams & Wilkins Health, 2010. Print.
6. Humbyrd, Casey Jo. *Orthopaedic Emergencies*. Oxford: Oxford UP, 2012. Print
7. Miller, Mark D., Stephen R. Thompson, and Jennifer Hart. *Review of Orthopaedics*. Philadelphia, PA: Elsevier/Saunders, 2012. Web.
8. "Orthopaedics References and Discussions for Physicians." - *Wheeless' Textbook of Orthopaedics*. Duke Orthopaedics, n.d. Web. 28 Apr. 2014.
9. Potini, Vishnu C., Walter Bratchenko, Glen Jacob, Linda Chen, and Virak Tan. "Repeat Emergency Room Visits for Hand And Wrist Injuries." *The Journal of Hand Surgery* 39.4 (2014): 752-56. Print.
10. "Procedures Consult." *Procedures Consult*. N.p., n.d. Web. 28 Apr. 2014.
11. Ramoutar, Darryl Nilesh, Constantine Katevu, Andrew Gordon Titchener, and Arpit Patel. "Trapezium Fracture - a Common Technique to Fix a Rare Injury: A Case Report." *Cases Journal* 2.1 (2009): 8304. Print.
12. Rashid, Mamun Al Rashid Al, Sonia Rasoli, and Wasim S Khan S Khan. "Non-union of Isolated Displaced Triquetral Body Fracture- A Case Report." *Ortopedia Traumatologia Rehabilitacja* 14.1 (2012): 71-74. Print.
13. Stanbury, Spencer J., and John C. Elfar. "Perilunate Dislocation and Perilunate Fracture-dislocation." *Journal of the American Academy of Orthopaedic Surgeons* 19.9 (2011): 554-62. Web.
14. Thompson, Jon C., and Frank H. Netter. *Netter's Concise Orthopaedic Anatomy*. Philadelphia, PA: Saunders Elsevier, 2010. Print.
15. Thompson, Stephen R., and Dan A. Zlotolow. *Handbook of Splinting and Casting*. Philadelphia, PA: Elsevier/Mosby, 2012. Print.
16. Wolfe, Scott W., Robert N. Hotchkiss, William C. Pederson, and Scott H. Kozin. *Green's Operative Hand Surgery, 7th Edition*. Vol. 1-2. N.p.: Churchill Livingstone, 2011. Print.
17. Ramoutar, Darryl Nilesh, Constantine Katevu, Andrew Gordon Titchener, and Arpit Patel. "Trapezium Fracture - a Common Technique to Fix a Rare Injury: A Case Report." *Cases Journal* 2.1 (2009): 8304. Print.
18. Rashid, Mamun Al Rashid Al, Sonia Rasoli, and Wasim S Khan S Khan. "Non-union of Isolated Displaced Triquetral Body Fracture- A Case Report." *Ortopedia Traumatologia Rehabilitacja* 14.1 (2012): 71-74. Print.
19. Rhemrev, Steven J., Daan Ootes, Frank Jp Beeres, Sven Ag Meylaerts, and Inger B. Schipper. "Current Methods of Diagnosis and Treatment of Scaphoid Fractures." *International Journal of Emergency Medicine* 4.1 (2011): 4. Print

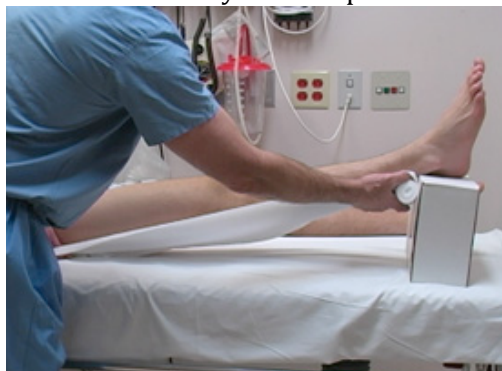Thigh Injury

Common Splinting/Traction Techniques^{7,10,16,21}

- Femoral Skeletal Traction²¹
 - Indications:
 - Acetabular fractures
 - Proximal femur fractures
 - Application:
 - Step 1: Traction pin placed medial to lateral
 - Helps avoid injury to femoral artery
 - Step 2: Ensure pin placed perpendicular to the axis of the limb + in a straight horizontal plane
 - Step 3: Add weights to traction construct, gently
 - **Click Video**

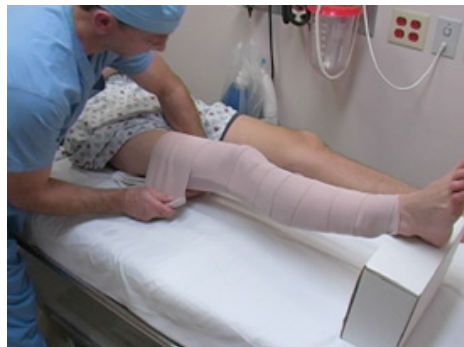

- Long Leg Splint:
 - Indications:
 - Tibia fx
 - Fibula fx
 - **Distal femur fx**
 - Knee dislocations
 - Application:
 - Step 1: Patient supine, knee flexed to 20 deg, ankle in neutral
 - Step 2: Apply the stockinette
 - Step 3: Measure length of splint by unrolling webril, **from proximal thigh, past knee, to a level 5 cm proximal to the malleoli**
 - Lay this webril on the bed (i.e. anywhere that is convenient), roll out an additional 3 layers on top of it to form cast padding



- Step 4: Roll out 12-15 layers of plaster bandages over the webril

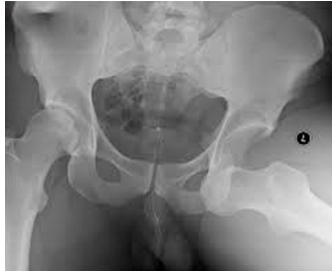- Step 5: Soak the plaster in slightly warm to room temperature water (the cooler the faster it hardens)
 - Gentle squeeze on the plaster in a laminating fashion, top to bottom motion
- Step 6: Place plaster over cast padding, roll over excess webril (which should be slightly longer) over the plaster
- Step 7: Apply splint to the posterior surface of the leg.
 - Hint: the splint can be extended to the metatarsal heads if one desires to mobilize the ankle joint as well
- Step 8: Roll 6 inch elastic bandage (of whatever form is used by your institution) over the splint, in a distal to proximal direction
- Step 9: Continue to mold the splint until hardened (tapping on it with two fingers gives an indication), **knee flexed 10-20 deg, ankle flexed to 90 deg (neutral position)**



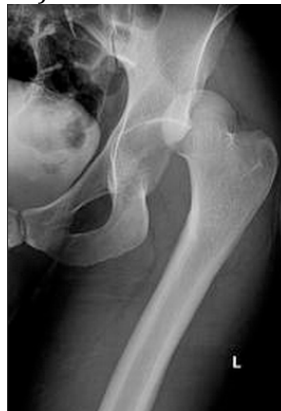Differential Diagnosis

- **Hip Dislocations**^{3,6,7,10,20,22}
 - Imaging:
 - AP pelvis
 - AP/Cross-table lateral hip
 - Judet views (45 degree oblique views)
 - CT scan of the pelvis using 3 mm cuts should be obtained followed closed reduction to demonstrate concentric reduction³
 - MRI can help delineate pathoanatomy and complications
 - Not recommended for 1st simple dislocation
 - Controversial
 - Classification
 - Thompson and Epstein²²
 - Type I: Pure dislocation with at most a small posterior wall fragment
 - Type II: Dislocation with large posterior wall fragment
 - Type III: Dislocation with comminuted posterior wall
 - Type IV: Dislocation with acetabular rim and floor fracture
 - Type V: Dislocation with femoral head fracture
 - Variations:
 - Anterior dislocations (10-15%)
 - Superior subdivision
 - Caused by forced abduction, external rotation, and **hip extension**.
 - Inferior subdivision (90%)

- Caused by forced abduction, external rotation, and **hip flexion**.

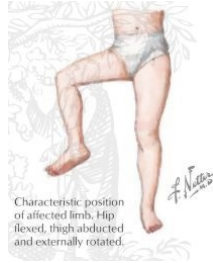


- Posterior dislocations (>85%)
 - Caused by trauma to the flexed knee (i.e. car accident, knee flies into dashboard)

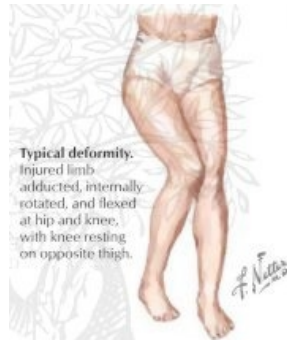


- Symptoms:

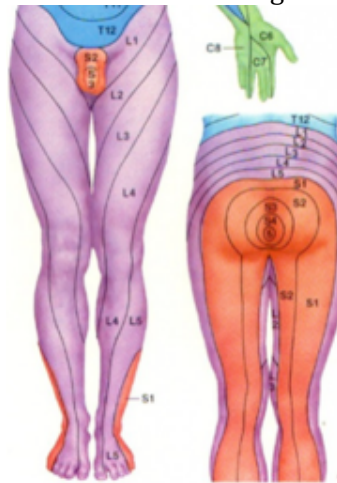
- Anterior variant
 - Knee flexed, **hip extended, externally rotated and abducted**
 - TTP over groin/lateral hip
 - Pain in groin



- Posterior variant
 - Knee flexed, **hip flexed, internally rotated and adducted** (show a picture of that)
 - TTP over groin/lateral hip
 - Pain in groin



- Physical Exam:
 - Assess Neurovascular function as thorough as possible
 - Palpate dorsalis pedis/posterior tibialis pulses
 - Assess sensation to light touch (SILT) in all sensory dermatomes



- Assess muscle strength throughout the leg-
 - Including hip flexors/extensors, knee flexors/extensors, foot dorsiflexors/plantarflexors, and inversion/eversion.
 - ROM of hip
- Associated injuries/complications:
 - Osteonecrosis of the femoral head
 - Increased risk with > time to reduction
 - AVN doubles from 10 to 20% if not reduced within 6 hours
 - Posttraumatic arthritis
 - Recurrent dislocation
 - <2%, much higher for shoulder dislocations
 - Neurovascular injury
 - Posterior dislocations
 - Sciatic nerve injury anticipated in 8 to 19% of patients¹⁶
 - Anterior dislocations
 - Femoral nerve injury
 - Femoral artery/vein injury
 - Femoral head fractures
 - 10% of posterior dislocations
 - 25-75% of anterior dislocations
 - Heterotopic Ossification

- In lieu of this, some physicians prescribe NSAIDs for 6 weeks after severe muscle damage/hematoma in the limb
- Epidemiology: ^{3,7}
 - **>30-50% sustain concomitant fractures at the time of dislocation**
 - Anterior dislocations account for 10-15%, while posterior dislocations account for 85-90%
 - Femoral head osteonecrosis occurs between 2-17% of patients
 - Many authors report that 70-100% of posterior hip dislocations result from MVC
 - 95% incidence of injury to other areas of the body in patients with hip dislocation
 - 70% acetabular fractures
 - 23% other lower extremity fractures
 - 21% upper extremity fractures
 - 24% closed head injuries
 - 21% thoracic injuries
 - 15% abdominal injuries
 - 2/3 of patients sustain a serious non-orthopaedic injury
- ED Management:
 - Considered a true orthopaedic emergency
 - General surgery/trauma evaluation warranted in all hip dislocation patients
 - Closed Reduction (<6hours is important) ¹⁶
 - Posterior dislocation
 - Allis Maneuver (2 people)
 - Most commonly used
 - Step 1: Supine position
 - Step 2: One person presses down on the patient's pelvis (typically ASIS), providing counter-traction
 - Step 3: Another person grasps the ipsilateral knee, ensuring the leg remains adducted
 - Step 4: Apply axial traction to the femur, while flexing the hip to 90 degrees
 - Step 5: While maintaining traction, rotate the hip internally and externally until reduction is achieved

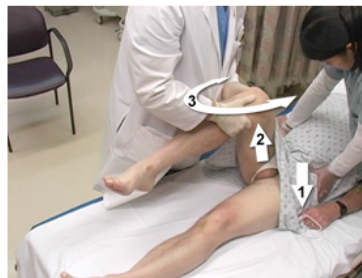

Figure 9 : With the leg held in adduction, 1: Downward pressure on pelvis, 2: Axial traction to the femur, and 3: Internal and external rotation of the hip.

- Whistler Maneuver (2 people)
 - Step 1: Supine with both knees flexed to 130 degrees
 - Step 2: One person presses down on the patient's pelvis (typically ASIS), providing counter-traction

- Step 3: Another person places their elbow under the ipsilateral knee and grasps the contralateral knee
- Step 4: With the other hand immobilize the ipsilateral ankle
- Step 5: Elevate the ipsilateral knee, using your elbow/shoulder as the fulcrum

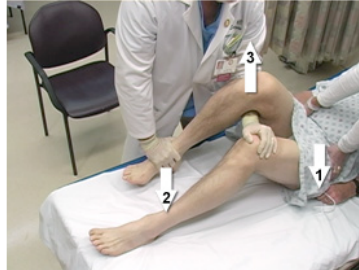

Figure 11 : With your elbow under the ipsilateral knee, 1: Downward pressure on the pelvis, 2: Ankle immobilized on the stretcher, and 3: Upward elevation of the knee.

- Stimson Maneuver – not recommended, but discussed in the literature
- Anterior dislocation
 - Modified Allis Maneuver
 - Step 1: Supine position
 - Step 2: One person presses down on the patient's pelvis (typically ASIS), providing counter-traction
 - Step 3: Another person grasps the ipsilateral knee with both hands
 - Step 4: Hold the leg in abduction, knee slightly flexed
 - Step 5: Apply longitudinal traction to the femur, adducting and internally rotating until reduction is achieved

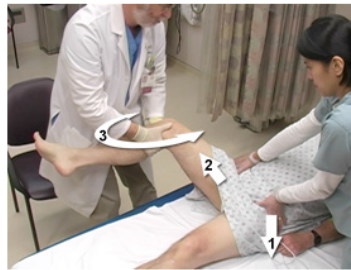

Figure 12 : With the leg held in abduction, exert 1: downward pressure on pelvis, 2: axial traction to the femur, and 3: internal and external rotation of the hip.

- Caveat: Time restrictions (<6 hours) do not apply to dislocated hip arthroplasty, because there is no risk of osteonecrosis
- Post reduction CT scan should “be obtained followed closed reduction to demonstrate concentric reduction”³
- Simple first time hip dislocations (particularly total hip arthroplasty), without significant associated injuries or neurovascular deficits, can be discharged
- Abduction bracing warranted

- Failed reductions, concomitant injuries, recurrent dislocations, and prolonged dislocation require emergent orthopaedic consultation
- All hip dislocations require follow up orthopaedic appointment
- Ortho Research:
 - *Complications after posterior dislocation of the hip (2006)*⁶
 - Salient Points:
 - Right hip most commonly involved
 - Time IV injuries most common
 - **Avascular necrosis occurred in 6/10 type IV fractures, 50% of type III and IV, 1/13 of type I and II patients.**
 - About 25% of patients develop post-traumatic osteoarthritis
 - About 11.4% of patients present with sciatic nerve injury, half recovered completely in < 3 month, the other half partially recovered partially at two year follow up.
 - *Hip Dislocations- Epidemiology, treatment, and outcomes (2010)*³
 - Review of current mechanisms of injury, epidemiology, associated injuries, evaluation, treatment, and functional outcomes
 - Interesting Points:
 - Classic dashboard injury hypothesis may be incorrect
 - Monma and Sugita found that brake pedal deceleration to be the contributing cause
 - Epidemiology/imaging recommendations listed above
 - Factors that affect prognosis include extent of concomitant injuries, time to reduction, direction of dislocation, and overall condition of the patient.
 - Anterior dislocations do better than posterior ones
 - Patients with multiple injuries do significantly worse

○ **Suggested Treatment**

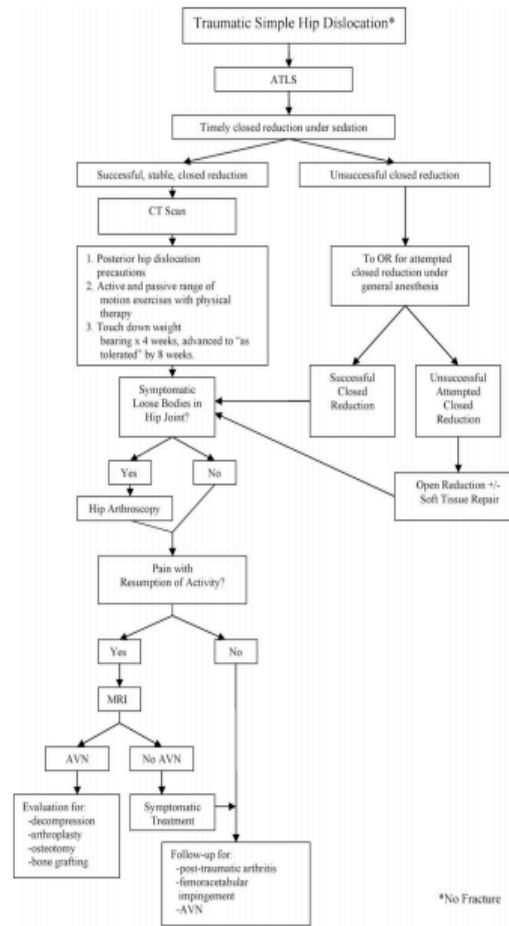
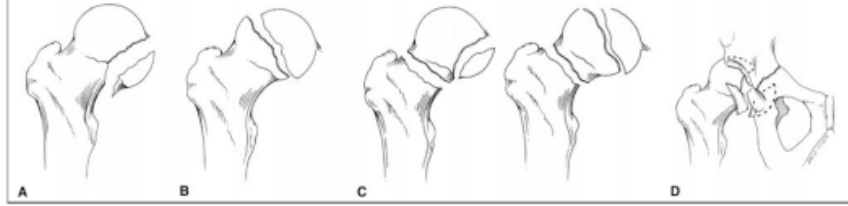


Fig. 3. Flow chart for the treatment of simple hip dislocations.

Algorithm:

- **Femoral Head Fractures**^{3,5,7,8,10,16,19}
 - Almost always occur with femoral head dislocations-almost always present.
 - Imaging:
 - AP pelvis
 - AP/lateral hip
 - Inlet/Outlet views
 - Judet view (45 degree obliques)
 - CT scan of the pelvis using 3 mm cuts should be obtained followed closed reduction to demonstrate concentric reduction³
 - MRI can help delineate pathoanatomy and complications
 - Not recommended for 1st simple dislocation
 - Controversial
 - Classification:⁵
 - Pipkin (most common)
 - Type I: Hip dislocation with fracture of the femoral head inferior to the fovea capitis femoris
 - Type II: Hip dislocation with fracture of the femoral head superior to the fovea capitis femoris
 - Type III: Type I or II injury associated with fracture of the femoral neck

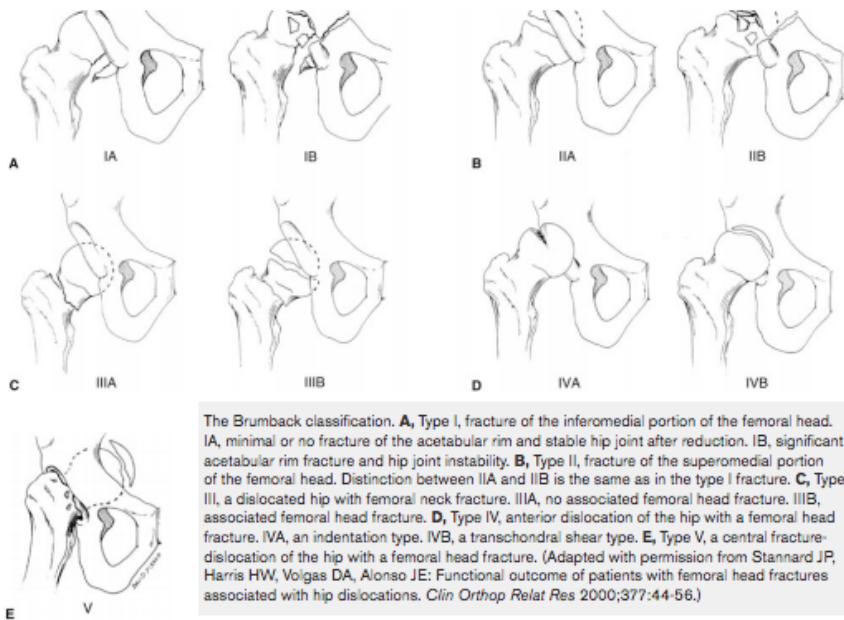
- Type IV: Type I or II injury associated with fracture of the acetabular rim



The Pipkin classification. **A**, Type I, femoral head fracture inferior to the fovea centralis. **B**, Type II, fracture extended superior to the fovea centralis. **C**, Type III, any femoral head fracture with an associated femoral neck fracture. **D**, Type IV, any femoral head fracture with an associated acetabular fracture. (Adapted with permission from Stannard JP, Harris HW, Volgas DA, Alonso JE: Functional outcome of patients with femoral head fractures associated with hip dislocations. *Clin Orthop Relat Res* 2000; 377:44-56.)

- Brumback

- Type I: Fracture of the inferomedial portion of the femoral head
 - IA: Minimal or no fracture of the acetabular rim
 - IB: Significant acetabular rim fracture and hip joint instability
- Type II: Fracture of the superomedial portion of the femoral head
 - IIA: Minimal or no fracture of the acetabular rim
 - IIB: Significant acetabular rim fracture and hip joint instability
- Type III: Dislocated hip with femoral neck fracture
 - IIIA: No associated femoral head fracture
 - IIIB: Associated femoral head fracture
- Type IV: Anterior dislocation of the hip with a femoral head fracture
 - IVA: Indentation type
 - IVB: Transchondral shear type
- Type V: Central fracture-dislocation of the hip with a femoral head fracture



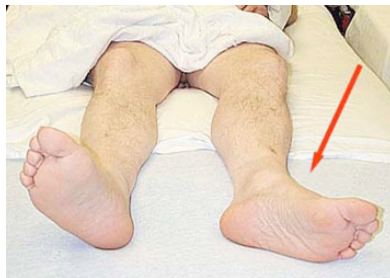The Brumback classification. **A**, Type I, fracture of the inferomedial portion of the femoral head. IA, minimal or no fracture of the acetabular rim and stable hip joint after reduction. IB, significant acetabular rim fracture and hip joint instability. **B**, Type II, fracture of the superomedial portion of the femoral head. Distinction between IIA and IIB is the same as in the type I fracture. **C**, Type III, a dislocated hip with femoral neck fracture. IIIA, no associated femoral head fracture. IIIB, associated femoral head fracture. **D**, Type IV, anterior dislocation of the hip with a femoral head fracture. IVA, an indentation type. IVB, a transchondral shear type. **E**, Type V, a central fracture-dislocation of the hip with a femoral head fracture. (Adapted with permission from Stannard JP, Harris HW, Volgas DA, Alonso JE: Functional outcome of patients with femoral head fractures associated with hip dislocations. *Clin Orthop Relat Res* 2000;377:44-56.)

- Symptoms:
 - Most often involved in high-energy trauma

- Trauma evaluation warranted
- Almost all present with posterior hip dislocations
 - Knee flexed, **hip flexed, internally rotated and adducted**
 - TTP over groin/lateral hip
 - Pain in groin
- If the patient has a concomitant femoral neck fracture, the presentation can be significantly different
- Physical Exam:
 - Assess Neurovascular function as thorough as possible
 - Palpate dorsalis pedis/posterior tibialis pulses
 - Assess sensation to light touch (SILT) in all sensory dermatomes
 - Assess muscle strength throughout the leg-
 - Including hip flexors/extensors, knee flexors/extensors, foot dorsiflexors/plantarflexors, and inversion/eversion.
 - ROM of hip
- Associated injuries/complications:
 - Osteonecrosis of the femoral head
 - Pipkin type I and II have same prognosis as simple dislocations (listed above 1 to 10% if reduced <6hours)
 - **Pipkin type III have very poor prognosis (50% rate of osteonecrosis).**
 - 10% anterior dislocations develop osteonecrosis
 - Posttraumatic arthritis
 - Recurrent hip dislocation
 - Neurovascular injury
 - Posterior dislocations
 - Sciatic nerve injury anticipated in 8 to 19% of patients¹⁶
 - Anterior dislocations
 - Femoral nerve injury
 - Femoral artery/vein injury
 - Heterotopic Ossification
- Epidemiology:^{5,7}
 - 5-15% of posterior hip dislocations are associated with femoral head fracture
 - Almost all femoral head fractures are associated with hip dislocations (90% posterior, 10% anterior)
 - Impaction fractures are more commonly seen with anterior hip dislocations (25-75%)
 - Injury pattern first described by Birkett in 1869
- ED Management:
 - Isolated femoral head fractures are extremely rare
 - Closed Reduction (<6hours is important)
 - Posterior dislocation
 - Allis Maneuver or Whistler Maneuver
 - Detailed description provided in hip dislocation section
 - Anterior dislocation
 - Modified Allis Maneuver
 - Obtain post reduction CT scan
 - Irreducible fracture-dislocations warrant emergent open reduction internal fixation

- **All femoral head fractures with/without hip dislocations require emergent orthopaedic consultation.**
- Ortho Research:
 - *Femoral head fractures (2014)*⁵
 - Goals:
 - 1) Review current literature on the treatment options for femoral head fractures.
 - 2) Present operative techniques that have improved exposure, while minimizing associated risks such as avascular necrosis, heterotopic ossification, and neurovascular compromise
 - Salient Points:
 - No firm conclusions regarding optimal treatment
 - Definite treatment for acute femoral head fractures are to achieve anatomic reduction, restore stability, and remove fragments when appropriate
 - **Irreducible fracture-dislocation of the hip or a femoral head fracture with associated femoral neck fracture are indications for emergent open reduction.**
 - Nonoperative versus Operative Management
 - Nonoperative
 - Only if anatomic reduction is achieved, with hip joint stability
 - Fractures should be inferior to fovea and non-problematic
 - Butler showed that even fractures superior to the fovea can have excellent outcomes if successfully reduced.
 - Remains controversial given lack of data
 - Operative
 - Indications:
 - Nonanatomic reduction
 - Unstable hip joint
 - Presence of intra articular fragments (that are preventing reduction)
 - Controversy regarding preferred approach- anterior (Smith-Petersen) and posterior (Kocher-Langenbeck) are most common
 - *Acetabular Fractures and Femoral Head & Neck Fractures Lecture Series (Dr. Samimi, 2008)*¹⁹
 - Salient Points:
 - Indications for ORIF femoral head fractures:
 - Inadequate fx reduction
 - > 1 mm stepoff
 - Loose bodies in joint space
 - Associated neck or acetabular fx
 - Polytrauma patients
 - **Femoral Neck Fractures (intracapsular)**^{7,8,10,15,19}
 - Imaging:

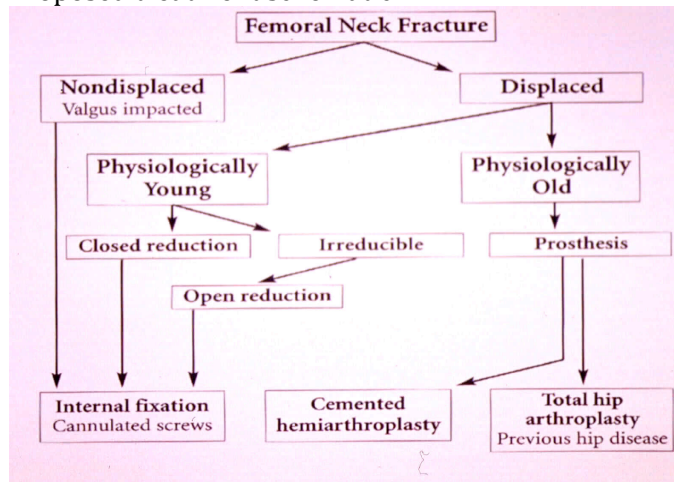
- AP pelvis
- AP/cross table lateral hip
- MRI is the study of choice for nondisplaced or occult fractures not apparent on plain radiographs^{7,19}
- CT scan rarely used, though trauma abdominal CT can be used to visualize/identify femoral neck fractures
- Classification:
 - Poor reliability of classification schemes
 - **Fractures most commonly identified as nondisplaced, displaced, or impacted.**
 - Anatomic
 - Subcapital (most common)
 - Transcervical
 - Basicervical
 - **Caveat:** This fracture is most often extracapsular, making it a lot less likely to have complicated avascular necrosis. Operative management is less urgent and more akin to intertrochanteric fractures
 - Based on angle of fracture from the horizontal plane
 - Type I: >30 degrees
 - Type II: 30-70 degrees
 - Type III: >70 degrees
 - Garden
 - Based on degree of valgus displacement
 - Type I: Incomplete/valgus impacted
 - Type II: Complete fx, non displaced
 - Type III: Complete fx, partial displacement (<50%)
 - Type IV: Completely displaced fx
- Symptoms:
 - Groin pain
 - Pain with ambulation
 - Displaced fractures often present **abducted, externally rotated, and shortened.**



- Physical Exam:
 - Assess Neurovascular function as thorough as possible
 - ROM of hip
- Associated injuries/complications:
 - Nonunion
 - Osteonecrosis
 - 10% of nondisplaced fractures
 - 30% of displaced fractures
 - Dislocation

- 1-2%
- Epidemiology:
 - Accounts for 50% of hip fractures
 - Annual worldwide incidence of 1.7 million¹⁵
 - Bimodal distribution
 - 20s incidence secondary to high energy trauma
 - Elderly patients (avg age 72) secondary to low energy falls
 - Women account for 80%
 - One year mortality rates range from 14 to 36%¹⁵
 - Mortality in the first month is estimated at 10%
 - Risk factors
 - 1) Female sex
 - 2) White race
 - 3) Increasing age
 - 4) Poor health
 - 5) Tobacco/alcohol use
 - 6) Previous fracture and repeated falls
 - 7) Low estrogen level
- ED Management:
 - Primary stabilization with bedrest and limited hip motion
 - All hip fractures warrant urgent orthopaedic consultation
 - Most will require operative reduction internal fixation
 - >72 hours to operative fixation significantly increases first month mortality rates
 - All patients need to be admitted to the hospital
 - Service depends on medical comorbidities, often significant given the patient population at risk
- Ortho Research:
 - *Surgical Management of Hip Fractures: An Evidence-based Review of the Literature. I: Femoral Neck Fractures (2008)*¹⁵
 - Goals:
 - Evidence based review of current literature on the surgical management of femoral neck fractures
 - Salient Points:
 - Treatment options include nonsurgical management, percutaneous fixation, closed reduction and internal fixation, open reduction and internal fixation, and arthroplasty (i.e. hemi versus total hip arthroplasty)
 - Non-displaced femoral neck fractures
 - No level I or II studies comparing surgical versus nonsurgical management
 - Elderly patients with medical conditions that put them at risk for anesthesia/surgery are often treated non-surgically
 - Surgical fixation for other patients allows early mobilization, and ensures stability
 - Displaced femoral neck fractures
 - High risk for osteonecrosis and non-union

- Options include closed reduction and internal fixation, open reduction internal fixation, hemiarthroplasty, and total hip arthroplasty
 - Internal fixation- minimal differences between implants, choice should be based on comfort/familiarity
 - ORIF vs hemi- higher revision rates for fractures treated with internal fixation. Hemi seems to have better outcomes overall. No official recommendations made given lack of considerations of crucial epidemiological factors such as age.
 - ORIF vs THA- THA leads to better outcomes measured by hip function scores and decreased rates of revision.
- *Acetabular Fractures and Femoral Head/Neck Fractures (Core Curriculum Lecture Series, Dr. Babak Samimi, 2008)*¹⁹
 - Proposed treatment schematic



- *Handbook of Fractures*⁷
 - Salient points:
 - Impacted/nondisplaced fractures
 - Approximately up to 40% will displaced without internal fixation
 - Less than 5% develop osteonecrosis
 - Displaced fractures
 - Young patients/normal bone- ORIF with fixed-angle implant
 - Elderly (controversial)
 - High demands/good bone
 - THA
 - ORIF may be considered, though reoperation rates expected to be higher
 - Low demands/poor bone
 - Hemiarthroplasty
 - Severely ill, demented

- Consider non-operative treatment
 - Operative treatment principles
 - **Multiple screw fixation (most common)- three parallel screws typical number**
 - Sliding-screw sideplate device- much less commonly used for these injuries
 - Prosthetic replacement
 - Pros: faster weight bearing, no risk for nonunion, osteonecrosis
 - Cons: more extensive, greater blood loss
 - **Intertrochanteric Fractures (extracapsular)**^{1,2,7,10,12,13}
 - Imaging:
 - AP pelvis
 - AP/cross table lateral hip
 - MRI is the study of choice for nondisplaced or occult fractures not apparent on plain radiographs
 - CT scan rarely used, though trauma abdominal CT can be used to visualize/identify intertrochanteric fractures
 - Classification:¹
 - Evans
 - Based on prereduction and postreduction stability
 - Stable fracture patterns have minimal or no comminution of the posteromedial cortex, therefore easier to maintain stability
 - Unstable fracture patterns typically have more posteromedial cortex comminution
 - Reverse obliquity pattern is inherently unstable
- The diagrams illustrate five types of intertrochanteric fractures. The top row shows two 'Stable' fractures: one with a simple comminution of the posteromedial cortex and one with a reverse obliquity fracture. The bottom row shows three 'Unstable' fractures: one with a comminuted posteromedial cortex, one with a reverse obliquity fracture, and one with a comminuted reverse obliquity fracture.
- Recap:
 - 3 inherently unstable fracture patterns
 - 1) Posteromedial cortex disruption
 - 2) Reverse obliquity
 - 3) Comminution
- Symptoms:
 - Groin/hip pain
 - Pain with ambulation

- Displaced fractures often present **abducted, externally rotated, and shortened** (same as femoral neck fractures)
- Physical Exam:
 - Assess Neurovascular function as thorough as possible
 - ROM of hip
- Associated injuries/complications:
 - Loss of fixation
 - Non-union
 - Malrotation deformity
 - Osteonecrosis of femoral head (very rare, given extracapsular nature of injury)
 - Femoral artery laceration (more common with associated lesser trochanteric fracture)
- Epidemiology:
 - 50% of all proximal femur fractures
 - Average age 66 to 76
 - 2:1 to 8:1 ratio of women to men
- ED Management:
 - Bedrest, limited motion
 - All intertrochanteric fractures warrant orthopaedic consultation
 - Operative reduction internal fixation is indicated for almost all of these fracture patterns
- Ortho Research:
 - *A meta-analysis of percutaneous compression plate versus sliding hip screw for the management of intertrochanteric fractures of the hip (2012)*¹²
 - Salient Points:
 - Sliding hip screw is the standard device used to treat intertrochanteric fractures
 - Proposed minimally invasive percutaneous compression plate (PCCP) with theorized reduced surgical time, perioperative bleeding, postoperative pain, and increased early recovery.
 - PCCP and SHS have no obvious statistical difference in hospital stay, mortality rate, reoperation rate, and implant related complications. PCCP does reduce the duration of surgical time, blood loss, transfusion requirements, and systemic complications (level 3 evidence)
 - *Gamma nails revisited: gamma nails versus compression hip screws in the management of intertrochanteric fractures of the hip: a meta-analysis (2009)*²
 - Goals:
 - Meta-analysis of the effects of gamma nails on risks of femoral shaft fractures after extracapsular hip fracture treatment in adults
 - Salient Points:
 - Femoral shaft fractures presented in 0-17% of patients treated with gamma nails, compared to 0-3% of patients treated with compression hip screws (studies from 1988-1996)

- **More recent studies (1997-2005) did not show increased risk of femoral shaft fractures with gamma nails compared to compression hip screws.**
- Author concludes that newer gamma nails have better designs and curvature, indicating that previous concerns for increased femoral shaft fractures have since been resolved.
- *Classification and Surgical Approaches to Hip Fractures for Nonsurgeons (2014)*¹³
 - Goals:
 - Provide interdisciplinary knowledge that allows nonsurgeons to develop communication with surgeons, leading to improved outcomes for elderly patients.
 - Salient Points:
 - 3 major hip fracture types
 - Femoral neck
 - Intertrochanteric
 - Subtrochanteric

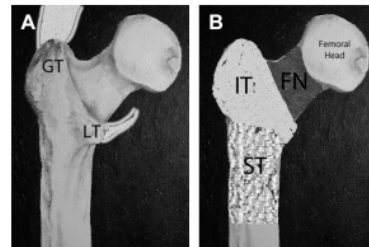


Fig. 1. Hip anatomy and fracture types. (A) The hip joint is pictured with the insertions of the gluteus medius and psoas muscles. GT, greater trochanter; LT, lesser trochanter. (B) Regions are shown identifying the areas in which femoral neck (FN), intertrochanteric (IT), and subtrochanteric (ST) fractures occur.

- Different constructs for intertrochanteric fractures

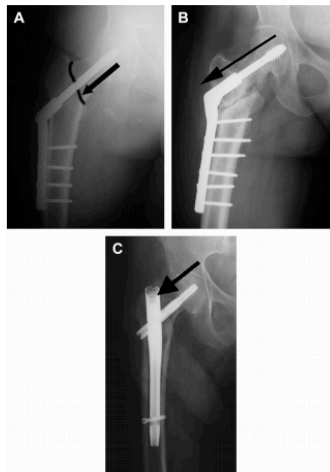


Fig. 6. Anteroposterior radiographs showing treatment options and biomechanics for intertrochanteric fractures. (A) SHS in a stable fracture. The arrow shows the vector of force during standing. With the lateral cortex intact, the fracture can stably impact as the screw slides within the barrel of the plate. (B) SHS in an unstable fracture. In this reverse oblique pattern, the plate cannot resist the sliding force in the direction of the arrow, and the device fails before fracture healing. (C) IMHS in an unstable fracture. The fracture impacts along the path indicated by the arrow, and the nail itself acts as a limitation to the sliding of the screw.

A = Sliding Hip Screw (SHS) in a stable fracture

B = Sliding Hip Screw (SHS) in an unstable fracture. Reverse obliquity makes it difficult for the fracture pattern to be stabilized and it fails.

C = Intramedullary hip screw in an unstable fracture. Successfully achieves fracture stability and healing.

- IMHS also called Cephalomedullary nail

- **Subtrochanteric Fractures (extracapsular)**^{7,8,10,11,13}
 - Subtrochanteric region is defined as below the lesser trochanter to 5 cm distal to the femur.
 - Imaging:

- AP pelvis
- AP/cross lateral hip
- AP/lateral knee
- CT is optional, used for operative planning and fracture delineation
- Classification:¹¹
 - Russell-Taylor
 - Based on mechanical stability and fracture extension
 - Two points:
 - Extension into the piriformis fossa (types I and II)
 - Comminution of the lesser trochanter (types A and B)
 - Type IA: Fracture does not extend into the piriformis fossa and there is no comminution of the lesser trochanter
 - Type IB: Fracture does not extend into the piriformis fossa, but there is comminution of the lesser trochanter
 - Type IIA: Fracture extends into the piriformis fossa, but there is no comminution of the lesser trochanter
 - Type IIB: Fracture extends into the piriformis fossa and there is comminution of the lesser trochanter
 - Fielding
 - Based on location of fracture line relative to lesser trochanter
 - Type I: At the level of the lesser trochanter
 - Type II: <2.5 cm below the lesser trochanter
 - Type III: 2.5 to 5 cm below the lesser trochanter
 - AO
 - Proximal segment of the femur = 31
 - Trochanteric area = 31A
 - Reverse obliquity intertrochanteric fracture = 31-A3.1
 - Transverse subtrochanteric fracture = 31-A3.2
 - Multifragmentary subtrochanteric fracture = 31-A3.3

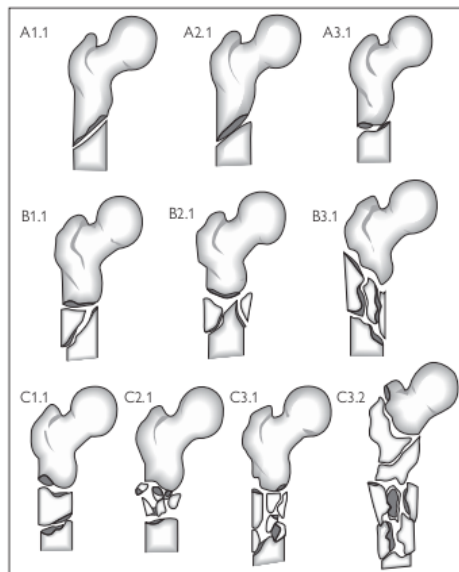


Figure 4.9 AO classification of subtrochanteric femur fractures.

- Symptoms:
 - Groin/hip pain
 - Inability to ambulate

- Tenderness to palpation and swelling of proximal thigh
- Proximal femur portion typically flexed and externally rotated because of the “deforming force by the unopposed pull of the iliopsoas”⁷
- Physical Exam:
 - Assess Neurovascular function as thorough as possible
 - ROM of hip
- Associated injuries/complications:
 - Loss of fixation
 - Nonunion
 - Malunion
 - Osteonecrosis of the femoral head almost non-existent
- Epidemiology:
 - Account for 10% of all hip fractures¹³
 - Younger patients characterized as trauma pts who sustain injuries 2/2 to high energy mechanisms¹¹
 - Older patients are often osteoporotic, with diminished calcar strength over time.
 - New subset of fractures that are appearing 2/2 to iatrogenic inability to remodel bone from prolonged used of bisphosphonates
- ED Management:
 - Bedrest, limited motion
 - All patients require hospital admission
 - All subtrochanteric fractures warrant orthopaedic consultation
 - Open Reduction Internal Fixation will be indicated in almost all cases of subtrochanteric fractures
- Ortho Research:
 - *Subtrochanteric Femoral Fractures (2007)*¹¹
 - Salient Points:
 - Calcar is a vertical sheet of bone in the medial femur that projects from the posteromedial side of the femur just inferior to the lesser trochanter and extends proximally to the posteriorinferior femoral neck
 - Two major treatment options:
 - 1) Plate-and screw devices
 - 2) Intramedullary nails
 - Either centromedullary (interlocked femoral nails) or cephalomedullary (reconstruction and trochanteric femoral nails)
 - Cephalomedullary nails have screws that engage the bone in the femoral head
 - Concludes that **reconstruction nails (uses screws that engage bone in the femoral head) and trochanteric femoral nails (placed started proximally in the greater trochanter) are the most commonly used implants**, but many surgeons experienced in 95-degree plate devices can achieve great results as well.
 - *Classification and Surgical Approaches to Hip Fractures for Nonsurgeons (2014)*¹³
 - Salient Points:

- Fractures are difficult to treat, because psoas pulls on the lesser trochanter, which flexes the proximal portion of the broken bone.
 - **They are most often treated with IMHS (aka cephalomedullary nails).**
 - Typical fractures result from falls and high-energy mechanisms.
 - Atypical fractures result from the prolonged use of bisphosphonates.
- **Femoral Shaft Fractures**^{7,8,10,13,17,18}
 - Imaging:
 - AP pelvis
 - AP/cross lateral hip
 - AP/lateral femur
 - AP/lateral knee
 - Be sure to evaluate more proximal segments of the femur for intertrochanteric fractures, femoral neck fractures, and femoral head fractures.
 - CT scan rarely used, though trauma abdominal CT can be used to visualize/identify femoral neck fractures
 - Classification:
 - Descriptive:
 - Open vs closed
 - Displaced vs partially displaced versus nondisplaced
 - Proximal, middle, or distal third
 - Isthmal, infraisthmal, or supracondylar
 - Spiral, oblique, or transverse
 - Comminuted, segmental, or butterfly fragments
 - Angulation or rotation
 - Shortening or translation
 - Winqvist and Hansen
 - Series of 520 femoral shaft fractures treated by intramedullary nails between 1968-1979.

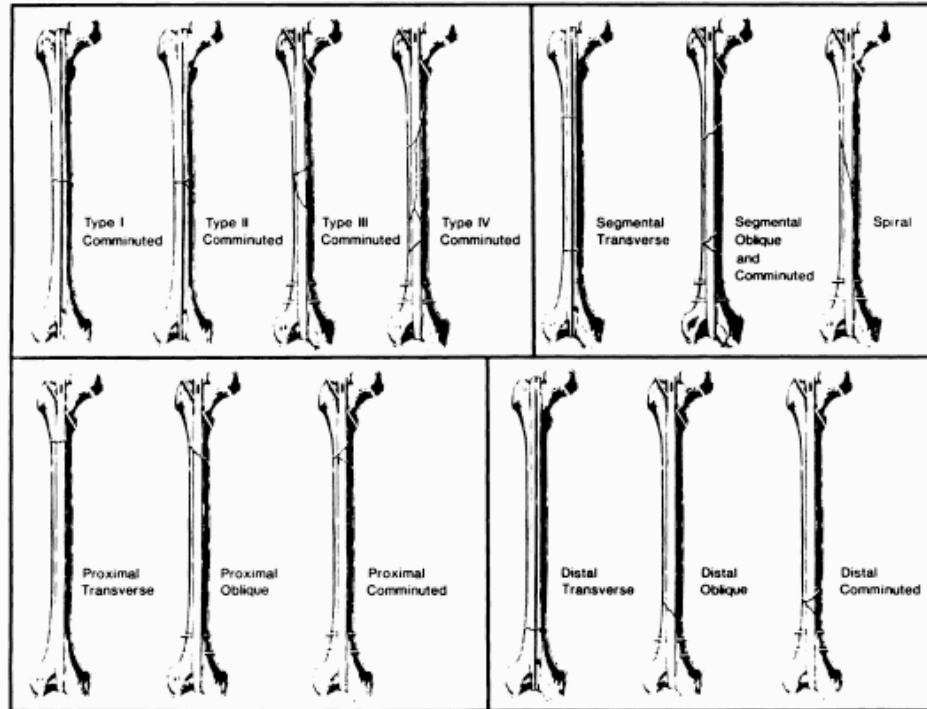


FIG. 1

The types of comminuted fractures are illustrated. Our recommended treatment method (standard intramedullary nail or interlocking nail) for femoral fractures of various patterns is also indicated.

- OTA Classification
 - 32A- simple
 - A1 spiral, A2 Oblique, angle >30 deg, A3 Transverse, angle <30 deg
 - 32B- wedge
 - B1 spiral wedge, B2 bending wedge, B3 fragmented wedge
 - 32C- complex
 - C1 spiral, C2 segmental, C3 irregular
- Symptoms:
 - Thigh pain
 - Deformity and shortening of the femur
 - These fractures can present with significant blood loss (up to 1 liter can accumulate in the thigh)¹⁰
 - Proximal fragment is most often posterior and abducted
- Physical Exam:
 - Assess Neurovascular function as thorough as possible
 - ROM of hip
- Associated injuries/complications:
 - 5-15% present with significant associated injuries, including multisystem trauma, spine, pelvis, and ipsilateral lower extremity injuries
 - Ligamentous/meniscal damage is seen in the ipsilateral knee of 50% of patients
- Epidemiology:
 - Most common in young men 2/2 to high energy trauma and elderly women 2/2 to ground level falls
 - Males 15-24 years of age
 - Females > 75 years of age
- ED Management:

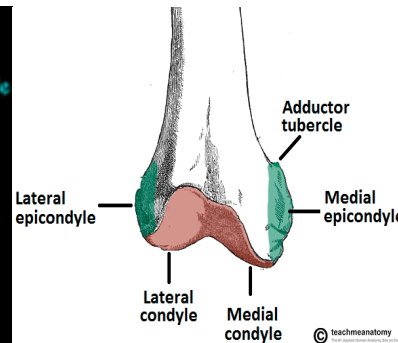
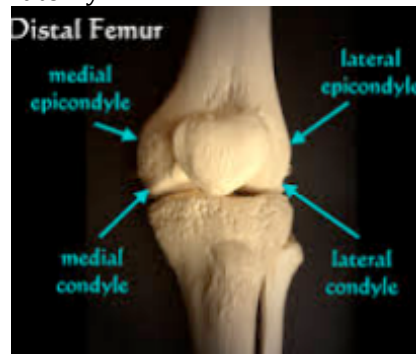- Bedrest, limited motion
- Traction required for most skeletally mature adults
 - This is most often done by orthopaedic residents and attendings
- All femur fractures require orthopaedic consultation
- Ortho Research:
 - *Femoral Shaft Fractures in Adults: Epidemiology, Fracture Patterns, Nonunions, and Fatigue Fractures (2005)*¹⁸
 - Salient Points:
 - Circumference of the femur is triangular in nature
 - Anterior
 - Lateral
 - Medial
 - Thickest portion is the posterior aspect
 - Concomitant injuries associated with shaft fractures
 - “General associated injuries” in 45% of patients
 - Craniocerebral injuries 2.7 – 10.9%
 - Facial fractures 12.1 %
 - Humeroscapular injuries 20%
 - Thoracic injuries 6.7%
 - Vertebral fractures 1.2%
 - Upper arm/elbow injuries 5.8%
 - Forearm/hand injuries 9.7%
 - Contralateral femoral shaft fractures 1.8%
 - Contralateral lower leg fractures 1.4%
 - Ankle/foot injuries 2.4%
 - *Orthobullets*
 - Nonoperative
 - Long leg cast
 - Only nondisplaced with comorbidities
 - Operative
 - Antegrade IM nail (reamed)
 - Gold standard
 - Retrograde IM nail (reamed)
 - External fixation → IM nails (2-3 weeks)
 - Plate fixation
 - <http://www.msdlatinamerica.com/ebooks/RockwoodWilkinsFracturesinChildren/sid644046.html>¹⁷

Age	Treatment
Birth to 24 mo	Pavlik harness (newborn to 6 mo) Immediate spica cast Traction → spica cast
24 mo to 5 yr	Immediate spica cast Traction → spica cast External fixation (rare) Flexible intramedullary rod (rare)
6–11 yr	Traction → spica cast Flexible intramedullary rod Compression plate External fixation
12 yr to maturity	Flexible intramedullary rod Compression plate Locked intramedullary rod External fixation

Treatment choices are influenced by polytrauma (vs. an isolated femoral shaft fracture) or open fractures with soft tissue trauma.

• **Distal Femur Fractures**^{4,7,9,10,13,14,20}

○ Basic Anatomy:



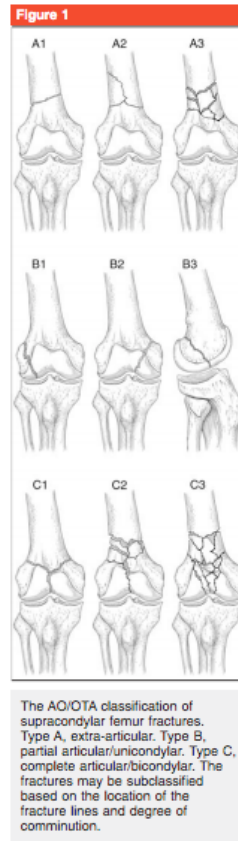
○ Imaging:

- AP/lateral/45 degree oblique views distal femur
- AP/lateral hip
- AP/lateral knee
- CT knee if suspected intra-articular extension

○ Classification:^{4,9}

- Broadly classified
 - Extra-articular
 - Intra-articular unicondylar
 - Intra-articular bicondylar
- AO/OTA Classification (most common)⁴
 - Type 33A- extraarticular fracture
 - A1: simple
 - A2: metaphyseal wedge and/or fragmented wedge
 - A3: metaphyseal complex
 - Type 33B: partial articular fracture
 - B1: lateral condyle, sagittal
 - B2: medial condyle, sagittal
 - B3: frontal

- Type 33C: complete articular fracture
 - C1: articular simple, metaphyseal simple
 - C2: articular simple, metaphyseal multifragmentary
 - C3: articular multifragmentary



- Symptoms:
 - Knee/distal thigh pain
 - Deformity about the knee (often apex posterior)
- Physical Exam:
 - Assess Neurovascular function as thorough as possible
 - Assess ipsilateral hip, entire femur, knee, and tibia
- Associated injuries/complications:
 - 5-15% of cases including multisystem trauma, spine, pelvis, and ipsilateral lower extremity injuries
 - Injury to knee ligaments and menisci
 - Injury to ipsilateral tibia (relatively common)
 - Malunion/nonunion
 - Post traumatic osteoarthritis
 - Significant loss of knee motion
- Epidemiology:⁹
 - < 1% of all fractures, 3-6% of femoral fractures
 - Bimodal peaks at 25 and 65 years of age
 - Elderly osteoporotic patients with “simple” falls
 - Young patients with high energy mechanisms (i.e. MVC)
 - 10/100000 population per year
- ED Management:

- Primary stabilization with bedrest and limited motion
- Depending on fracture pattern, skeletal traction through the tibia may help regain length and temporize pain
 - Most often done by orthopaedic residents and attendings
- All distal femur fractures require urgent orthopaedic consultation
- Ortho Research:
 - www.aofoundation.org
 - Meta-analysis distal femur fractures
 - Salient Points:
 - Non-operative versus non-operative
 - Splint versus cast bracing
 - Delayed union > in splint (6.7% versus 0%)
 - No difference in malunion
 - Non-operative versus operative
 - ORIF versus cast bracing/splint
 - High frequency unions in both groups
 - ORIF had increased ROM (100 deg versus 95 deg)
 - Open versus closed reduction
 - ORIF most often preferred, with 2x better results and reduced malunion (3% versus 37%)
 - Operative versus operative
 - Nails versus plates
 - No statistical difference in union
 - Plates have more complications (not statistically significant however)
 - Percutaneous versus ORIF
 - Union frequency similar in both groups
 - ORIF supracondylar IM nails required subsequent bone grafts much more frequently (40% versus 8%)
 - *Distal Femoral Fractures: Current Concepts (2010)*⁹
 - Salient Points:
 - Coronal plane alignment shown to be most difficult factor/issue to control, most crucial to successful outcomes
 - Posttraumatic arthritis reported in fractures with >15 degrees valgus or any degree of varus
 - Priorities in management include restoration of articular surface, in addition to femur length, appropriate rotation and alignment.
 - Locked plating and IM nailing are the most common surgical treatment options (complete discussion provided in the article)

References

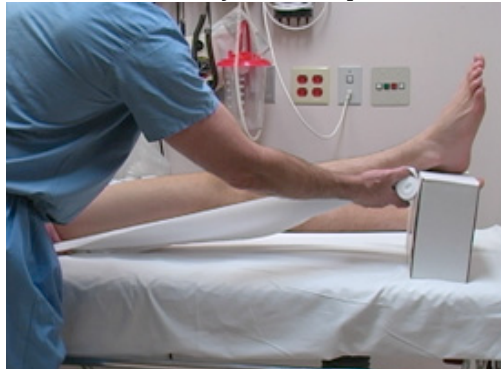1. Andersen, E., L.g. Jørgensen, and L.t. Hededam. "Evans' Classification of Trochanteric Fractures: An Assessment of the Interobserver and Intraobserver Reliability." *Injury* 21.6 (1990): 377-78. Print.
2. Bhandari, Mohit, Emil Schemitsch, Anders Jönsson, Michael Zlowodzki, and George J. Haidukewych. "Gamma Nails Revisited: Gamma Nails Versus Compression Hip Screws in the Management of Intertrochanteric Fractures of the Hip: A Meta-Analysis." *Journal of Orthopaedic Trauma* 23.6 (2009): 460-64. Print.
3. Clegg, Travis E., Craig S. Roberts, Joseph W. Greene, and Brad A. Prather. "Hip Dislocations- Epidemiology, Treatment, and Outcomes." *Injury* 41.4 (2010): 329-34. Print.
4. "Distal Femur - AO Surgery Reference." *Distal Femur - AO Surgery Reference*. AO Foundation, n.d. Web. 14 May 2014.
5. Droll, Kurt P., MD, Henry Broekhuysse, MD, and Peter O'Brien, MD, FRCSC. "Fracture of the Femoral Head." *Journal of the American Academy of Orthopaedic Surgeons* 15.12 (2007): 716-27. Web.
6. Dwyer, A. J., B. John, S. A. Singh, and M. K. Mam. "Complications after Posterior Dislocation of the Hip." *International Orthopaedics* 30.4 (2006): 224-27. Print.
7. Egol, Kenneth A., Kenneth J. Koval, Joseph D. Zuckerman, and Kenneth J. Koval. *Handbook of Fractures*. Philadelphia: Wolters Kluwer/Lippincott Williams & Wilkins Health, 2010. Print.
8. Grose, A. W., M. J. Gardner, P. S. Sussmann, D. L. Helfet, and D. G. Lorch. "The Surgical Anatomy of the Blood Supply to the Femoral Head: DESCRIPTION OF THE ANASTOMOSIS BETWEEN THE MEDIAL FEMORAL CIRCUMFLEX AND INFERIOR GLUTEAL ARTERIES AT THE HIP." *Journal of Bone and Joint Surgery - British Volume* 90-B.10 (2008): 1298-303. Print.
9. Gwathmey, F. W., MD, Sean M. Jones-Quaidoo, MD, David Kahler, MD, Shepard Hurwitz, MD, and Quanjun Cui, MD. "Distal Femoral Fractures: Current Concepts." *Journal of the American Academy of Orthopaedic Surgeons* 18.10 (2010): 597-607. Web.
10. Humbyrd, Casey Jo. *Orthopaedic Emergencies*. Oxford: Oxford UP, 2012. Print.
11. Lundy, DW, MD. "Subtrochanteric Femoral Fractures." *Journal of the American Academy of Orthopaedic Surgeons* 15.11 (2007): 663-71. Web.
12. Ma, J., D. Xing, X. Ma, W. Xu, J. Wang, Y. Chen, and D. Song. "The Percutaneous Compression Plate versus the Dynamic Hip Screw for Treatment of Intertrochanteric Hip Fractures: A Systematic Review and Meta-analysis of Comparative Studies." *Orthopaedics & Traumatology: Surgery & Research* 98.7 (2012): 773-83. Print.
13. Mears, Simon C. "Classification and Surgical Approaches to Hip Fractures for Nonsurgeons." *Clinical Geriatric Medicine* 30 (2014): 229-41. Web.
14. Miller, Mark D., and Jennifer A. Hart. *Review of Orthopaedics*. Philadelphia, PA: Saunders / Elsevier, 2008. Print.
15. Miyamoto, Ryan G., MD, Kevin M. Kaplan, MD, Brett R. Levine, MD, Kenneth A. Ego, MD, and Joseph D. Zuckerman, MD. "Surgical Management of Hip Fractures: An Evidence-based Review of the Literature. I: Femoral Neck Fractures." *Journal of the American Academy of Orthopaedic Surgeons* 16.10 (2008): 596-607. Print.

16. "Procedures Consult." *Procedures Consult Video*. N.p., n.d. Web. 14 May 2014.
17. "Rockwood & Wilkins? Fractures in Children 6th Edition." *Femoral Shaft Fractures*. Lippincott Williams & Wilkins, 2006. Web. 14 May 2014.
18. Salminen, Sari. *Femoral Shaft Fractures in Adults: Epidemiology, Fracture Patterns, Nonunions, and Fatigue Fractures*. Diss. U of Helsinki, 2005. N.p.: Helsinki U Printing House, n.d. Print.
19. Samimi, Babak, MD. "Acetabular Fractures and Femoral Head/Neck Injuries." Core Curriculum Lectures. Los Angeles. Oct.-Nov. 2008. Lecture.
20. Thompson, Jon C., and Frank H. Netter. *Netter's Concise Orthopaedic Anatomy*. Philadelphia, PA: Saunders Elsevier, 2010. Print.
21. Thompson, Stephen R., and Dan A. Zlotolow. *Handbook of Splinting and Casting*. Philadelphia, PA: Elsevier/Mosby, 2012. Print.
22. Thompson, Vernon P., MD, and Herman C. Epstein, MD. "Traumatic Dislocations of the Hip- A Survey of Two Hundred and Four Cases Covering a Period of Twenty-one Years." *The Journal of Bone and Joint Surgery* 33A.3 (1951): 746-92. Web.

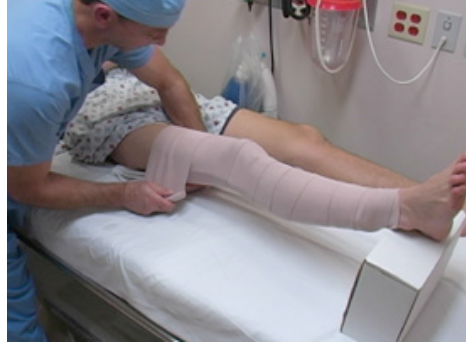Lower Leg Injury

Common Splinting Techniques^{7,16,21}

- Supplies:
 - Warm water
 - Stockinette
 - Soft cotton bandage/undersplint material (6 inch, i.e webril)
 - Plaster bandages (6 inch)
 - Elastic bandages (i.e. Ace)
 - Adhesive tape
- Long Leg Splint:
 - Indications:
 - Tibia fx
 - Fibula fx
 - Distal femur fx
 - Knee dislocations
 - Application:
 - Step 1: Patient supine, knee flexed to 20 deg, ankle in neutral
 - Step 2: Apply the stockinette
 - Step 3: Measure length of splint by unrolling webril, **from proximal thigh, past knee, to a level 5 cm proximal to the malleoli**
 - Lay this webril on the bed (i.e. anywhere that is convenient), roll out an additional 3 layers on top of it to form cast padding



- Step 4: Roll out 12-15 layers of plaster bandages over the webril
- Step 5: Soak the plaster in slightly warm to room temperature water (the cooler the faster it hardens)
 - Gentle squeeze on the plaster in a laminating fashion, top to bottom motion
- Step 6: Place plaster over cast padding, roll over excess webril (which should be slightly longer) over the plaster
- Step 7: Apply splint to the posterior surface of the leg.
 - Hint: the splint can be extended to the metatarsal heads if one desires to mobilize the ankle joint as well
- Step 8: Roll 6 inch elastic bandage (of whatever form is used by your institution) over the splint, in a distal to proximal direction
- Step 9: Continue to mold the splint until hardened (tapping on it with two fingers gives an indication), **knee flexed 10-20 deg, ankle flexed to 90 deg (neutral position)**



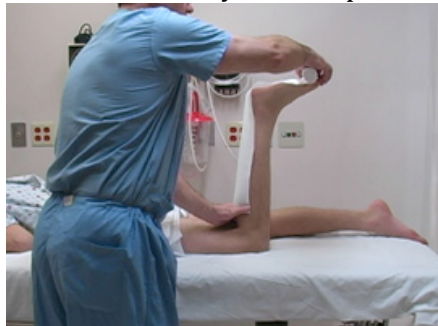- Short Leg Splint

- Indications:

- Distal tibia fx
 - Talus fx
 - Calcaneous fx
 - Cuboid fx
 - Navicular fx
 - Cuneiform fx
 - Metatarsal bone fx
 - Ankle dislocations

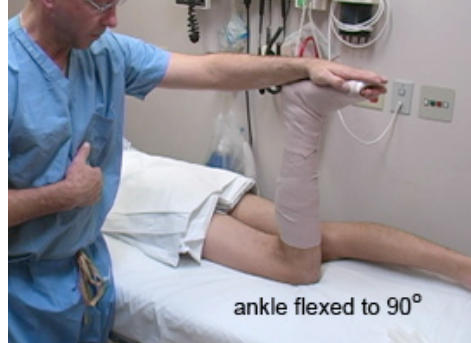- Application:

- Step 1: Patient prone, knee flexed at 90 deg
 - Relaxes gastrocnemius, easier for foot to remain neutral
 - Step 2: Apply the stockinette
 - Step 3: Measure length of splint by unrolling webril, **from proximal posterior leg, down around the ankle, and then to the level of the metatarsal heads**
 - Lay this webril on the bed (i.e. anywhere that is convenient), roll out an additional 3 layers on top of it to form cast padding



- Step 4: Roll out 12-15 layers of plaster bandages over the webril
 - Step 5: Soak the plaster in slightly warm to room temperature water (the cooler the faster it hardens)
 - Gentle squeeze on the plaster in a laminating fashion, top to bottom motion
 - Step 6: Place plaster over cast padding, roll over excess webril (which should be slightly longer) over the plaster
 - Step 7: Apply splint to the posterior surface of the leg.
 - Step 8: Roll 4-6 inch elastic bandage (of whatever form is used by your institution) over the splint, in a distal to proximal direction

- Step 9: Continue to mold the splint until hardened (tapping on it with two fingers gives an indication), **ankle flexed to 90 deg (neutral position)**



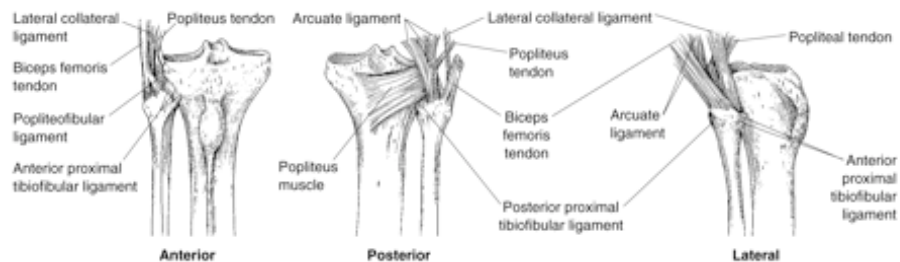
Differential Diagnosis

- **Tibial Shaft Fractures**^{1,4,5,7,9,10,12,15}
 - Imaging:
 - AP/lateral tibia/fibula
 - AP/lateral knee
 - AP/lateral/oblique ankle
 - CT scan if suspected articular involvement
 - Classification:
 - Most often described anatomically:
 - i.e. proximal, middle, distal third
 - i.e. nondisplaced, minimally displaced, displaced, non angulated, angulated
 - i.e. transverse, oblique, spiral, butterfly, comminuted, etc
 - i.e. open vs closed
 - **Open Fracture Classification**¹⁰
 - Based on 1) wound size, 2) level of contamination, 3) osseous injury
 - Type I: Less than 1 cm long and clean
 - Type II: Greater than 1 cm long without extensive soft tissue damage, flaps, or avulsions
 - Type III: Either open segmental fracture, open fx with extensive soft tissue damage, or traumatic amputation
 - IIIA: Adequate soft tissue coverage, minimal periosteal stripping
 - IIIB: Requires soft tissue flap closure, moderate periosteal stripping
 - IIIC: Vascular injury that requires repair
 - Symptoms:
 - Swelling, tenderness at fracture site
 - Possible deformity and angulation
 - Physical Exam:
 - Complete neurovascular exam to r/o compartment syndrome
 - Associated Injuries/Complications:
 - Compartment Syndrome
 - Malunion/Nonunion
 - Infection with open fractures
 - Knee pain (related to IM nail)

- Fat embolism (risk with all long bone fractures)
- Neurovascular injury
 - Anterior tibial artery (most common)
 - Common peroneal nerve
- Epidemiology:
 - Fractures of the tibia/fibula are the most common long bone fractures
 - Highest incidence of diaphyseal fractures seen in males 15-19.
 - Highest incidence of diaphyseal fractures seen in females 90-99
 - Highest rate of nonunion for all long bones
 - “Some authors have defined tibia nonunion as a fracture that has not united without additional surgical or nonsurgical intervention within 6-9 months” ¹
- ED Management:
 - Reduction/Alignment parameters⁹
 - < 5 degrees of varus/valgus angulation
 - < 10 degrees of anterior/posterior angulation
 - < 10 degrees rotational deformity
 - <1 cm shortening
 - > 50% cortical contact
 - Long leg splint
 - All adult tibial shaft fractures require emergent Orthopaedic consultation
- Ortho Research:
 - *Management and outcome of diaphyseal aseptic non-unions of the lower limb (2011)* ¹⁵
 - Goal: compare the healing rates of lower limb bone non-unions treated with various modalities, to determine the best available treatment
 - Salient points:
 - Modalities include exchange nailing, nail dynamization, augmentation plating, augmentation bone graft.
 - Autograft considered gold standard- osteogenic, osteoinductive, and osteoconductive
 - BMP- 7 approved for use as an alternative to autologous bone graft in tibial non-unions
 - ABG has a higher success rate compared to BMP-7 (95% vs 87%), though BMP-7 often used for longer-term failure.
 - *Autograft versus BMPs for the treatment of non-unions: What is the evidence? (2013)* ⁴
 - Goal: Compare autograft to BMPs and autograft + BMPs in the treatment of tibial non-unions
 - Salient points:
 - Friedlaender et al- autograft versus BMP-7 = no difference in clinical and radiographic healing at 9 months
 - Autograft remains gold standard, but complications include additional surgical intervention and morbidity

- associated with harvest (i.e. donor site pain, local infection, paresthesia, limited bone available)
- Various studies have shown that BMP-7 + autograft work synergistically with success rates higher than BMP- 7 or autograft alone
- *Systematic review and metaanalysis of the additional benefit of local prophylactic antibiotic therapy for infection rates in open tibia fractures treated with intramedullary nail (2014)* ⁵
 - Goal: compare rate of deep wound infections in patients with open tibia fractures, treated with intramedullary nails, receiving additional locally-delivered antibiotics to those receiving standard of care.
 - Salient points:
 - Rates of infection lower for all Gustilo-anderson grades when local antibiotics used as an adjunctive therapy.
 - GIII fractures with systemic antibiotics alone rate of infection = 14.4%, added local antibiotics decreased rate to 2.4%
- **Isolated Fibular Shaft Fractures**^{2,3,7,9,12}
 - Fibular shaft above ankle joint/ligaments and below proximal tib-fib syndesmosis is a non-weight bearing segment.
 - Imaging:
 - AP/lateral tibia/fibula
 - AP/lateral knee
 - AP/lateral/Oblique ankle
 - CT scan if suspected articular involvement
 - Classification:
 - Descriptive
 - Transverse, oblique, spiral
 - Displaced, non-displaced
 - Comment on angulation, rotation, and shortening
 - Segmental, comminuted
 - Open versus closed
 - Symptoms:
 - Most often caused by direct injury to the lateral aspect of the leg.
 - Pain, swelling, ecchymoses at the fracture site
 - r/o neurovascular compromise
 - r/o tenderness at the fibular head and ankle
 - Associated injuries/complications:
 - Tibial fracture
 - Common peroneal neuropathy
 - Compartment syndrome (rare in isolated fibula fractures)
 - Epidemiology:
 - Isolated fibular fxs comprise the majority of ankle fractures in elderly women (1-2 out of 1000 white women) **uptodate**
 - Higher incidence in contact sports, including American football, soccer, and rugby.
 - Snowboarders >> skiers have a particular higher incidence
 - Fibula is fractured in 75-85% of tibia fractures.
 - ED Management:

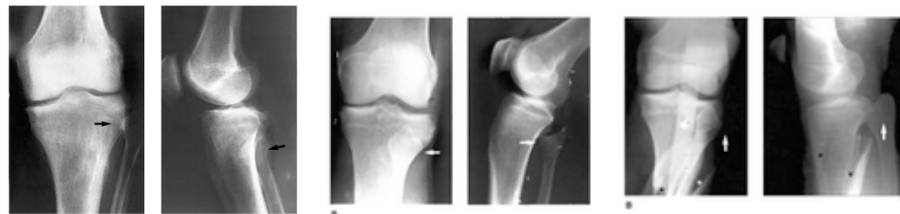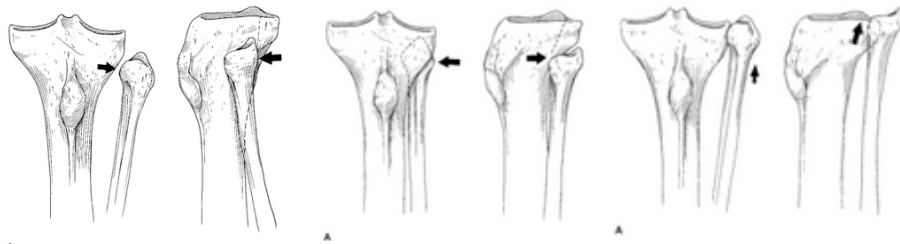
- **True isolated fibula fractures without associated injuries, do not require reduction or stabilization.**
- Complete neurovascular examination
 - Check for common peroneal dysfunction
- RICE, conservative management with crutches/CAM boot to reduce pain
- Orthopaedic consultation for open fractures or neurovascular compromise.
- All other fibula fractures should have orthopaedic outpatient follow up
- Ortho Research:
 - *Nonunion of fibula: a systematic review (2012)*³
 - Goal: analyze the available evidence regarding nonunions of the fibula
 - Salient Points:
 - Incidence
 - Very little evidence for the incidence of isolated fibular nonunion
 - 119 fibular nonunions reported, 57.9% associated with rotational ankle fractures, 41.2% associated with tibial shaft fractures.
 - Etiology/risk factors
 - Inadequate blood supply/instability at the fracture site
- **Proximal Tibiofibular Joint (PTFJ) Dislocation/Fibular Head Dislocations**^{7,9,12,14,19}
 - Brief Anatomy PTFJ



- Anterior joint capsule
 - Composed of three ligamentous bands
 - Pass obliquely upward and attach to lateral tibial condyle
- Posterior tibiofibular ligament
 - 2 broad, thick ligamentous bands
 - Pass obliquely to the posterior aspect of the tibial condyle
- Stabilizers
 - LCL (aka fibular collateral ligament)
 - Fabellofibular ligament
 - Popliteofibular ligament
 - Politeus
 - Biceps femoris tendon
- In 10-12% of the population, the proximal tibiofibular joint communicates with the knee joint.
- Imaging:
 - AP/lateral knee
 - AP/lateral tib-fib

- AP/lateral/oblique ankle
 - Classification⁹

Type	Mechanism	Comment
Subluxation	Any	Treat symptomatically, RICE, cast 2–3 weeks
Anterolateral	Fall, knee flexed, foot inverted, and plantar flexed	Most common dislocation (85%)
Posteromedial	Direct trauma (e.g., car bumper)	Next most common (10%), peroneal nerve injury frequent
Superior	High-energy ankle injury	Evaluate knee stability; often has concomitant injuries

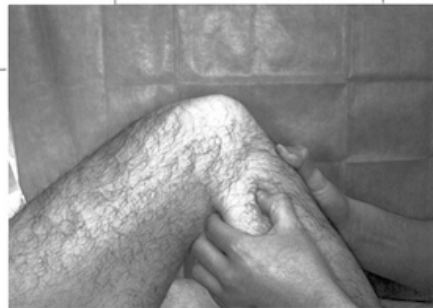

Anterolateral

Posteromedial

Superior


- Symptoms:
 - Pain near lateral knee
 - TTP over fibular head
 - Common peroneal neuropathy
- Physical Exam:
 - Complete neurovascular exam
 - Examine proximal tibiofibular joint (cite instability of the proximal tibiofibular joint article)
 - Knee flexed at 90 deg
 - Palpate fibular head and assess AP translation, compare to contralateral side





- Associated injuries/complications:
 - Proximal tibiofibular joint dislocation
- Epidemiology
 - Peroneal nerve symptoms most often present with posteromedial dislocation
- ED Management:
 - Reduction, based on reversing the injury pattern
 - Apply direct force to the fibular head with the knee flexed between 80-110 deg, relaxing the lateral collateral ligament and biceps femoris tendon (cite instability article)
 - Some authors believe its important to externally rotate, evert, and dorsiflex the foot to relax the peroneal, EHL, and EDL muscles (cite the instability article)
 - Long leg splint
 - Orthopaedic consultation for irreducible dislocation and open injuries
 - All other dislocations warrant outpatient orthopedic follow up
- Ortho Research:
 - *Instability of the Proximal Tibiofibular Joint (2003)*¹⁹
 - **Acute** dislocation treatment
 - Step 1) Closed reduction
 - Step 2) Immobilization (controversial)
 - Step 3) Protected weight bearing on crutches, progressing to full weight bearing by 6 weeks
 - Consider open reduction for posteromedial dislocations and failed closed reductions
 - Temporary screw fixation/K wires
 - Primary repair of the torn capsule and injured ligaments
- **Plafond/Pilon Fractures**^{7,9,12,14,18,22}
 - Distal tibial shaft fractures, metaphyseal with one or more fracture lines extending into the articular surface of the ankle⁹
 - Imaging:
 - AP/lateral ankle
 - AP/lateral entire leg
 - Mortise View



- Leg internally rotated 15-20 deg
- Evaluate for lateral talar shift (i.e. medial clear space, deltoid injury), talar tilt, fibular shortening (i.e. talocrural angle, tibiofibular line), fibular rotation, and syndesmotomic integrity.
- CT scan helpful in determining fracture pattern and extent of intraarticular involvement.

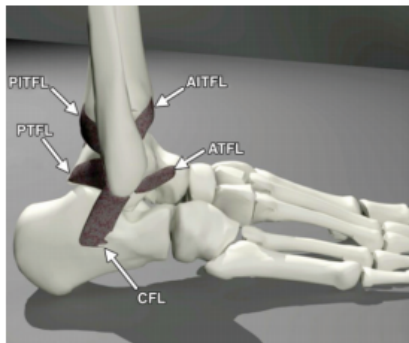
- Classification:
 - AO/OTA Classification:
 - Distal tibia fractures designated as 43
 - 43A- nonarticular
 - 43B- partial articular
 - 43C- total articular
 - Riedi and Allgower (historic, most commonly used)
 - Based on severity of comminution and displacement of the articular surface
 - 1) No comminution or joint line displacement
 - 

I - no comminution or displacement of joint fragments
 - 2) Some displacement but no comminution or impaction
 - 

II - some displacement but no comminution or impaction
 - 3) Comminution and/or impaction
 - 

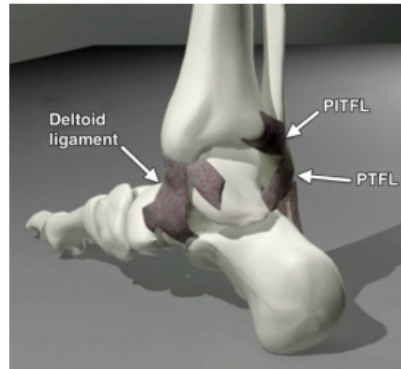
III - comminution and/or impaction of the joint surface
 - Topliss (newer)
 - Classification based on energy of injury, direction of force, and the age of the patient (cite anatomy of pilon fractures of the distal tibia by Topliss)
- Symptoms:
 - Ankle swelling, pain
 - Tenderness to palpation about the ankle
- Associated Injuries/complications:
 - 20-25% open fractures (ortho emergencies and Kentucky article)
 - 75% with associated fibular fractures
 - 50% with associated vascular injuries
 - Malunion
 - Nonunion
 - Skin edge necrosis (3%)
 - Posttraumatic arthritis- most common with poorly reduced fractures.
- Epidemiology:
 - 5-7% of all tibia fractures (cite pilon Kentucky article)

- Male predominance- bimodal peaks at 25 and 50 (Kentucky article)
- ED Management:
 - Primary stabilization
 - Reduce soft tissue tension with traction and short leg bulky cotton splint
 - Complete neurovascular examination
 - All require emergent Orthopaedic consultation- almost all require surgical intervention
- Ortho Research:
 - *In Brief: Pilon Fractures (2011)* ¹⁸
 - Salient Points:
 - Non-operative management extremely limited with this fracture type
 - Nondisplaced articular fractures
 - Patients with surgical contraindications
 - Patients with low demand aka nonambulatory/quadruplegic
 - Surgical approaches include anteromedial, anterolateral, anterior, lateral, posteromedial, and posterolateral approaches
 - Advised to respect the soft tissue with these injuries. Initially maintain length and alignment with an external fixator (approx. 10-14 days later) followed by surgical intervention.
 - Postoperative pain, swelling, and stiffness seen in 1/3 of patients.
- **Ankle Fractures**^{2,6,7,8,9,12,13,17,22}
 - Brief Anatomy
 - 3 Ligamentous Complexes stabilize the ankle
 - Lateral Collateral Ligament Complex
 - Anterior talofibular ligament, posterior talofibular ligament, calcaneofibular ligaments

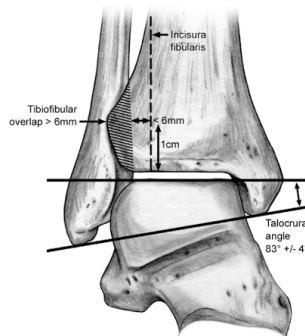


- Syndesmotic Ligament complex (aka **inferior talofibular syndesmosis**)
 - Anterior-inferior tibiofibular ligament, posterior-inferior tibiofibular ligament, transverse tibiofibular ligament, and interosseous membrane
- Medial Collateral Ligament Complex (Aka Deltoid ligament)
 - Lies deep to the medial flexor tendons

- Anterior tibiotalar, posterior tibiotalar, tibionavicular, tibiospring, and tibiocalcaneal ligaments



- Imaging:
 - AP/lateral/oblique ankle
 - Mortise view¹²
 - Equal medial, lateral, and superior joint spaces should be seen surrounding the talus on this view
 - Evaluate the position of the incisura in relation to the distal fibula.



- The fibula should overlap the tibia by greater than 6 mm.
 - AP/lateral tib-fib
 - CT scan to assess intraarticular involvement or guide surgical intervention (controversial)
- Classification:
 - Lauge-Hansen¹³
 - Based on mechanism of injury (2 criteria)
 - 1) Position of the foot at the time of injury (supination versus pronation)
 - 2) Direction of the deforming force (abduction versus adduction versus external rotation)
 - Rules:
 - **The injuries occur in a predictable sequence and stages cannot be skipped**
 - (i.e. findings from the previous stages are summed. SER stage III = SER stage II + SER stage I + rupture of posterior tibiofibular ligament or fracture of posterior malleolus of the tibia)
 - 3 views including AP, lateral, and mortise are required for classification

- Classifications
 - Pronation-abduction (3 stages)
 - Stage I: Transverse fracture of medial malleolus or rupture of deltoid ligament
 - Stage II: Rupture of both anterior and posterior tibiofibular ligaments with fracture of posterior tibia
 - Stage III: Bending fracture of the fibula. Short oblique fracture of the fibula upward from medial to lateral.
 - Pronation external rotation (4 stages)
 - Stage I: Rupture of the deltoid ligament
 - Stage II: Involvement of the AITFL extending into the interosseous membrane
 - Stage III: Spiral or oblique fracture of the fibula
 - Stage IV: Involvement of posterior ankle structures, i.e. PITFL or posterior malleolus
 - Supination-adduction (2 stages)
 - Stage I: Traction fracture of lateral malleolus at or below
 - Stage II: Near vertical fracture of medial malleolus
 - Supination external rotation (most common mechanism-accounts for 40-70% of all ankle fractures)
 - Stage I: AITFL disruption with/without avulsion fracture at its tibial or fibular attachments
 - Stage II: AITFL ruptures with a spiral fracture of the fibular malleolus
 - Stage III: Rupture of the PITFL or fracture of the posterior malleolus of the tibia
 - Stage IV: Fracture through medial malleolus or disruption of the deltoid ligament
- Variants:⁷
 - Maisonneuve fracture
 - PER type injury
 - Spiral fracture of the proximal third of the fibula with disruption of the distal tibiofibular syndesmosis and interosseous membrane
 - Curbstone fracture
 - Avulsion fracture off of the posterior tibia
 - LeForte Wagstaffe fracture
 - Anterior fibular tubercle avulsion fracture by the ATFL
- Animated Recreations:
 - <http://orthoanimations.com/ankle/>
- Symptoms:
 - Pain in the ankle (medial, lateral, or both)
 - Swelling
 - Deformity
 - Neurovascular compromise (relatively rare)

- Associated injuries/complications:
 - Malunion
 - Nonunion
 - Skin edge necrosis
 - Infection
 - Posttraumatic arthritis
 - Compartment syndrome (rare)
 - Loss of ankle ROM
- Epidemiology:
 - Accounts for 9% of fractures (ankle fx: radiographic approach)
 - Bimodal age distribution- young males, older females (ankle fracture: radiographic approach)
 - Open ankle fractures approx. 5% (cite evidence based treatment of open ankle fractures)
 - Most are isolated malleolar fractures (2/3), bimalleolar (1/4), trimalleolar (5-10%)
- ED Management:
 - Reduce fracture-dislocations (taken directly from proceduresconsult.com)
 - Posterior dislocations
 - 1) Grasp the foot with both hands, placing one hand on the heel and the other on the forefoot
 - 2) Flex the foot slightly plantar while applying traction
 - 3) While the distal tibia is stabilized with downward pressure applied by an assistant, move the heel anteriorly
 - 4) Hold the foot in dorsiflexion until the splint is applied and hardens

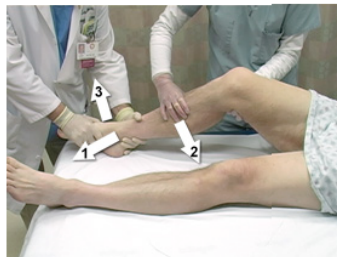

Figure 5 : 1: Plantar flexion and axial traction. 2: Downward pressure on tibia. 3: Anterior translation.

- Anterior dislocations
 - Place the patient supine and have an assistant hold the knee in flexion or move the patient so that the knee hangs over the end of the bed
 - Grasp the foot with both hands, placing one hand on the heel and the other on the forefoot.
 - Dorsiflex the foot to free the talus
 - While the distal tibia is stabilized with upward pressure applied by an assistant, apply traction and push the foot posteriorly.

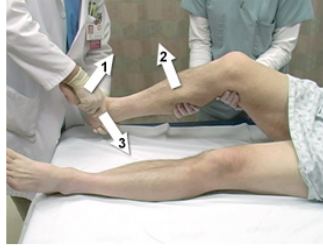

Figure 6 : 1: Dorsiflexion. 2: Upward pressure on tibia. 3: Posterior translation.

○ Lateral Dislocations

- Place the patient supine and have an assistant hold the knee in flexion or move the patient so that the knee hangs over the end of the bed
- Grasp the foot with both hands, placing one hand on the heel and the other on the forefoot.
- Flex the foot slightly plantar, apply traction to the foot
- While an assistant stabilizes the distal tibia with downward pressure, apply traction to the foot and move it medially.

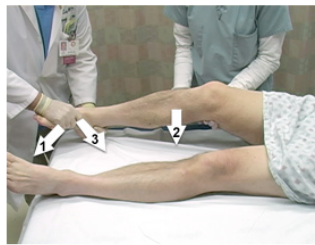


Figure 7 : 1: Plantar flexion and axial traction. 2: Tibial stabilization. 3: Medial translation.

References

1. Antonova, Evgeniya, T. Le, Russel Burge, and John Mershon. "Tibia Shaft Fractures: Costly Burden of Nonunions." *BMC Musculoskeletal Disorders* 14.1 (2013): 42. Print.
2. Asloum, Y., B. Bedin, J. L. Charissoux, and C. Mabit. "Internal Fixation of the Fibula in Ankle Fractures. A Prospective, Randomized and Comparative Study: Plating versus Nailing." *Orthopaedics and Traumatology: Surgery & Research*(2014): n. pag. Web.
3. Bhadra, Arup K., Craig S. Roberts, and Peter V. Giannoudis. "Nonunion of Fibula: A Systematic Review." *International Orthopaedics* 36.9 (2012): 1757-765. Print.
4. Blokhuis, Taco J., Giorgio M. Calori, and Gerhard Schmidmaier. "Autograft versus BMPs for the Treatment of Non-unions: What Is the Evidence?" *Injury* 44 (2013): S40-42. Print.
5. Craig, J., M. Jenks, K. Fleetwood, D. Franz, J. Iff, and M. Raschke. "Systematic Review and Meta-analysis of the Additional Benefit of Local Prophylactic Antibiotic Therapy for Infection Rates in Open Tibia Fractures Treated with Intramedullary Nailing." *International Orthopaedics* 38.5 (2014): 1025-030. Web.
6. Dean, D. Brian. "Field Management of Displaced Ankle Fractures: Techniques for Successful Reduction." *Wilderness & Environmental Medicine* 20.1 (2009): 57-60. Print.

7. Egol, Kenneth A., Kenneth J. Koval, Joseph D. Zuckerman, and Kenneth J. Koval. *Handbook of Fractures*. Philadelphia: Wolters Kluwer/Lippincott Williams & Wilkins Health, 2010. Print.
8. Hulsker, Caroline C. C., Sanne Kleinveld, Chris B. L. Zonnenberg, Mike Hogervorst, and Michel P. J. Bekerom. "Evidence-based Treatment of Open Ankle Fractures." *Archives of Orthopaedic and Trauma Surgery* 131.11 (2011): 1545-553. Print.
9. Humbyrd, Casey Jo. *Orthopaedic Emergencies*. Oxford: Oxford UP, 2012. Print.
10. Kim, Paul H., MD, and Seth S. Leopold, MD. "Gustilo-Anderson Classification." *Clinical Orthopaedics and Related Research*® 470 (2012): n. pag. Web.
11. Miller, Mark D., Stephen R. Thompson, and Jennifer Hart. *Review of Orthopaedics*. Philadelphia, PA: Elsevier/Saunders, 2012. Web.
12. Morrey, Bernard F. *Master Techniques in Orthopaedic Surgery*. Philadelphia: Wolters Kluwer Health / Lippincott Williams & Wilkins, 2007. Print.
13. Okanobo, Heitor, Bharti Khurana, Scott Sheehan, Alejandra Duran-Mendicuti, Afshin Arianjam, and Stephen Ledbetter. "Simplified Diagnostic Algorithm for Lauge-Hansen Classification of Ankle Injuries." *RadioGraphics* 32.2 (2012): E71-84. Print.
14. "Orthopaedics References and Discussions for Physicians." - *Wheeless' Textbook of Orthopaedics*. Duke Orthopaedics, n.d. Web. 28 Apr. 2014.
15. Pneumaticos, Spiros G., Michalis Panteli, Georgios K. Triantafyllopoulos, Costas Papakostidis, and Peter V. Giannoudis. "Management and Outcome of Diaphyseal Aseptic Non-unions of the Lower Limb: A Systematic Review." *The Surgeon* (2013): n. pag. Print.
16. "Procedures Consult." *Procedures Consult*. N.p., n.d. Web. 28 Apr. 2014.
17. Russo, A., A. Reginelli, M. Zappia, C. Rossi, O. Fabozzi, M. Cerrato, L. Macarini, and F. Coppolino. "Ankle Fracture: Radiographic Approach According to the Lauge-Hansen Classification." *Musculoskeletal Surgery* 97.S2 (2013): 155-60. Print.
18. Scolaro, John, and Jaimo Ahn. "In Brief: Pilon Fractures." *Clinical Orthopaedics and Related Research*® 469.2 (2011): 621-23. Print.
19. Sekiya, Jon K., and John E. Kuhn. "Instability of the Proximal Tibiofibular Joint." *Journal of the American Academy of Orthopaedic Surgeons* 11.2 (2003): 120-28. Web.
20. Thompson, Jon C., and Frank H. Netter. *Netter's Concise Orthopaedic Anatomy*. Philadelphia, PA: Saunders Elsevier, 2010. Print.
21. Thompson, Stephen R., and Dan A. Zlotolow. *Handbook of Splinting and Casting*. Philadelphia, PA: Elsevier/Mosby, 2012. Print.
22. Topliss, C. J. "Anatomy of Pilon Fractures of the Distal Tibia." *Journal of Bone and Joint Surgery - British Volume* 87-B.5 (2005): 692-97. Print.