

UC Irvine

UC Irvine Previously Published Works

Title

Long-term neurophysiologic outcome after neonatal extracorporeal membrane oxygenation

Permalink

<https://escholarship.org/uc/item/3ks821kk>

Journal

The Journal of Pediatrics, 116(3)

ISSN

0022-3476

Authors

Lott, IT
McPherson, D
Towne, B
[et al.](#)

Publication Date

1990

DOI

10.1016/S0022-3476(05)82818-5

License

[CC BY 4.0](#)

Peer reviewed

Long-term neurophysiologic outcome after neonatal extracorporeal membrane oxygenation

Ira T. Lott, MD, David McPherson, PhD, Barbara Towne, MD, David Johnson, MD, and Arnold Starr, MD

From the Departments of Pediatrics and Neurology, University of California, Irvine, and Children's Hospital of Orange County, Orange, California

We examined clinical and neurophysiologic measures in 10 children 4 to 9 years after neonatal extracorporeal membrane oxygenation. Electroencephalograms did not correlate with clinical or other neurophysiologic measures of interhemispheric asymmetry. By ultrasound imaging, the right internal carotid artery velocity was approximately 62% of that on the left, and right internal carotid flow was reduced by 74% ($p \leq 0.01$), whereas an age-matched control group showed no differences. A decrease in the amplitude of the long-latency auditory and somatosensory evoked potentials was noted over the right hemisphere after left-sided stimulation compared with the left hemispheric potentials after right-sided stimulation ($p \leq 0.005$). No significant differences in hemispheric symmetry were noted in the amplitudes for wave V of the auditory brain-stem response or in the P₃₀ component of the middle-latency auditory evoked potentials. Likewise, latency measures of the evoked potentials were symmetric. We conclude that (1) neonatal extracorporeal membrane oxygenation is associated with long-lasting decreased right internal carotid blood flow with compensatory increased flow through the left carotid system and (2) there is a consistent reduction in the amplitude of right hemispheric long-latency evoked potentials. These latter findings may reflect redirected cerebral blood flow patterns after extracorporeal membrane oxygenation. (J PEDIATR 1990;116:343-9)

Extracorporeal membrane oxygenation is a cardiopulmonary bypass procedure used to substitute for heart and lung functions in patients with temporary failure of those organs.¹ Neurologic sequelae of this procedure are theoretically possible because the technique often involves cannulation of the right internal jugular vein and right common carotid artery. In many centers, these vessels remain permanently ligated. Glass et al.² found that ligation of the right carotid artery is not associated with a consistent lat-

eralizing lesion, but Campbell et al.³ noted a significant incidence of left versus right focal seizures after ECMO, suggesting an effect of the procedure on right hemispheric function.

We studied the clinical and neurophysiologic aspects of

dBnHL	Decibels re normalized hearing level
ECMO	Extracorporeal membrane oxygenation
EEG	Electroencephalogram
EPs	Evoked potentials

Supported in part by National Institutes of Health grant No. NS 11876: Auditory Evoked Brain Potentials in Neurological Disease.

Submitted for publication June 9, 1989; accepted Sept. 19, 1989.

Reprint requests: Ira T. Lott, MD, University of California Irvine Medical Center, 101 City Dr., Bldg. 27, Rt. 81, PO Box 14091, Orange, CA 92613-4091.

9/20/16835

development in survivors of neonatal ECMO whose major carotid and jugular supplies to the right hemisphere had been surgically altered. In a preliminary publication, we reported the initial clinical assessment of 18 children who were available for follow-up examination for periods ranging from 4 to 11 years after the ECMO procedure.⁴ This

Table I. Neurodevelopmental status and EEG findings in 10 patients

Patient No.	Age (yr)/sex	Indication for ECMO	Duration of ECMO (days)	Neonatal course	Subsequent development	EEG
1	4½/M	MAS	4	Uneventful	Normal	NL
2	5/M	MAS	3	Uneventful	Mild developmental immaturity	L mid and posterior temporal sharp waves
3	9/F	MAS	7	Uneventful	Spasticity, cognitive delay	Photoconvulsive response
4	6/F	MAS	3	Seizures	Severe delay, R cerebral encephalomalacia, L hemiparesis	NL
5	6/F	MAS	3	Uneventful	Minimal brain dysfunction	NL
6	8/F	MAS	3	Seizures	NL	NL
7	5½/F	MAS	5	PDA ligation on ECMO seizures	NL	NL
8	8/M	MAS	2½	Uneventful	NL	NL
9	6/M	MAS	3	Uneventful	NL	NL
10	4/F	RDS	7	33 wk premature infant seizures R cerebral hemisphere	Delayed development, hydrocephalus	R cerebral dysrhythmia

MAS, Meconium aspiration syndrome; NL, normal; R, right; L, left; PDA, patent ductus arteriosus; RDS, respiratory distress syndrome.

subpopulation was drawn from the first large pediatric series of infants and children undergoing ECMO at the University of California Irvine Medical School and Children's Hospital of Orange County. Thirteen patients in this group (72%) had normal growth and development; five children (28%) were handicapped, two severely.

The purpose of our report is to describe carotid blood flow and cerebral evoked potentials in this group of patients. The results demonstrate an alteration in right carotid blood flow and an asymmetry in the amplitude of hemispheric EPs in survivors of neonatal ECMO.

METHODS

Patients. Of the 18 children previously studied in the preliminary follow-up project,⁴ 10 (6 girls) were available for neurophysiologic testing. Their ages ranged from 4 to 9 years. One of the children is considered as an "ECMO control" subject because he had ligation of the right axillary artery and vein rather than the right carotid artery. Fifteen age-matched control subjects were studied. The neurodevelopmental examination was carried out as previously described.⁴ A model DRF-400 duplex scanner (Diasonics, Inc., South San Francisco, Calif.) was used to evaluate the carotid bifurcations. Internal carotid artery diameters were estimated from images obtained with a 10 MHz transducer. A 4.5 MHz pulsed Doppler probe was used to determine the peak velocity and timed average velocity from the mid-stream of the internal carotid artery. These values are computed by the scanner from the angle of incidence and the

Doppler frequency for each vessel. The flow rate for each internal carotid artery was calculated from the diameter and timed average velocity. The velocities were obtained from an 0.7 mm³ sample volume in the center of each vessel. Since friction produces slower velocities near the vessel wall, the calculated flow rates must be considered as relative estimates for each vessel rather than true values.

Electroencephalography. Each electroencephalogram consisted of a 16-channel recording during the waking and sleeping states, performed in accordance with the guidelines of the American Electroencephalographic Society.

Auditory EPs (brain-stem, middle-latency and long-latency components) were recorded along with somatosensory EPs to median nerve stimulation. The auditory EPs were recorded from surface electrodes on the vertex referenced to each mastoid separately. Somatosensory potentials were recorded from surface electrodes 3 cm posterior to C₃ and C₄ referenced to an electrode at F_{pz}. A cervical potential was recorded from C_{vii} referenced to F_{pz}. The nerve potential over the brachial plexus was referenced to F_{pz}. Thus, in both the auditory and the somatosensory modalities, it was possible to record activity over each hemisphere simultaneously. After amplification, the potentials were filtered at the following settings (3 dB down, 6 dB/octave): (1) for brain-stem auditory EPs, 150 to 3000 Hz; (2) for middle-latency auditory EPs, 10 to 500 Hz; (3) for long-latency auditory EPs, 1 to 200 Hz; and (4) for somatosensory EPs, 20 to 2000 Hz. The respective sensory systems were stimulated by the following paradigms: (1) brain-stem auditory

Table II. Estimated carotid blood flow in ECMO survivors

Patient No.	Right internal vessel			Left internal vessel		
	TVA (cm/sec)	Diameter (mm)	Flow (ml/min)	TVA (cm/sec)	Diameter (mm)	Flow (ml/min)
1	26	3.8	17.7	40	6.9	89.7
2	16	5.5	22.8	31	6.3	57.9
3	21	3.1	9.5	21	5.5	29.9
4	18	4.2	15.0	57	5.0	67.1
5	37	3.8	25.2	48	5.5	68.4
6	23	3.8	15.6	66	5.5	94.0
7	33	3.4	18.0	42	5.0	49.5
8	24	3.8	16.3	38	6.9	85.2
9	34	2.5	10.0	30	5.5	42.7
Range	16-37	2.5-5.5	9.5-25.2	21-66	5.0-6.9	29.9-94.0
Average	25.8 ± 7.38*	3.8 ± 0.82*	16.7 ± 5.16*	41.4 ± 13.97	5.8 ± 0.73	64.9 ± 22.07
Patient 10: "ECMO control subject"	22	6.3	41.1	19	5.6	28

TVA, Timed average velocity.

* $p \leq 0.01$.

clicks at 11.1/sec at 75 dBnHL, (2) middle-latency auditory-tone pips of 1000 Hz at 70 dBnHL, (3) long-latency auditory-tone bursts of 1000 Hz at 70 dBnHL, and (4) somatosensory potentials evoked with a constant current stimulator that was adjusted until a twitch of the thenar muscle was observed. For each of the EPs, replicate averages were collected to ensure reliability. For the auditory EPs, recordings were made for both left and right monaural stimulation; for the somatosensory EPs, recordings were made for both left and right median nerve stimulation. Latency and amplitude measures were taken from the combined average of the two replicate averages obtained for each sensory EP as follows: (1) for brain-stem auditory EPs, the latency and amplitude of wave V from baseline to peak; (2) for middle-latency auditory EPs, the latency from component P₃₅, with peak-to-peak amplitudes taken from P₃₅ to N₄₀, (3) for long-latency auditory EPs, the latency from P₁₃₀ to P₁₃₅ (corresponding to P₂₀₀ in the normal adult), with peak-to-peak amplitudes taken from P₁₃₀ to N₂₀₀; and (4) for somatosensory EPs, the amplitude of the brachial plexus component (N₁₂) to the next sequential positivity (P₁₆), and the latency from P₂₂ with peak-to-peak amplitudes from N₁₇ to P₂₂.

Data analysis. To evaluate the hemispheric amplitude symmetry of the EPs, we determined the potentials over each side of the scalp to contralateral input. A particular hemispheric potential was then divided by the sum of the potentials for each hemisphere. The following equation was used for this evaluation of symmetry:

$$\%RH = RH / (LH + RH)$$

where RH is the right hemispheric response to left-sided stimulation and LH is the left hemispheric response to right-sided stimulation for a given sensory modality. We assumed that the input to one side of the body (median nerve, ear) is the principal contributor to the potentials recorded over the contralateral hemisphere.⁵ Thus, if there were hemispheric symmetry of the EPs, the amplitude of the potentials recorded over the right hemisphere in response to the left-sided stimulation should be equal to the potentials recorded over the left hemisphere in response to right-sided stimulation. A sign test was used to determine whether there was a significant difference between the two hemispheres in the ECMO group and age-matched control subjects, with a strict level of confidence used for significance ($p \leq 0.005$).

Means and standard deviations were used to describe the flow characteristics of velocity, vessel diameters, and internal flow. A *t* test was used to evaluate differences between right and left ultrasound measures ($p \leq 0.01$).

RESULTS

Electroencephalography. In Table I the EEG findings are compared with neurodevelopmental status in the 10 patients. Three of the 10 tracings were abnormal, but in only one was there evidence of a focal dysrhythmia involving the right hemisphere; in patient 10, right mid-temporal sharp waves were noted but results of the neurodevelopmental examination were normal. The one child with left hemiparesis (No. 4) had a normal EEG.

Ultrasound imaging. Ultrasound imaging of the carotid vessels is summarized in Table II. For patients 1 to 9 studied by this technique, all had permanent ligation of the right

Table III. Mean percentage of contribution of right and left hemispheres to sensory EPs in group of nine ECMO patients, one control subject undergoing axillary artery subclavian ligation for ECMO, and 10 age-matched control subjects

Sensory modality	Left hemisphere response			Right hemisphere response		
	Mean	SD	AASL	Mean	SD	AASL
Auditory Brain-stem EP, wave V	45 (50)	1 (2)	48	54 (50)	1 (2)	52
Middle latency auditory EPs: P ₃₅	46 (49)	5 (3)	49	54 (52)	5 (3)	51
Long latency auditory EPs: P ₁₃₅ *	59 (50)	5 (1)	52	41 (50)	5 (1)	48
Somatosensory EPs						
N ₁₂	50 (50)	2 (2)	49	50 (50)	2 (2)	51
P ₂₂ *	61 (49)	6 (1)	47	39 (50)	6 (1)	53

Numbers in parentheses represent normal subjects.

AASL, Axillary artery subclavian ligation.

*Difference between hemispheres in the ECMO subjects statistically significant at $p \leq 0.005$.

common carotid artery. The internal and external carotid vessels were found to be patent in every case. Right internal carotid timed average velocities were approximately 62% of those on the left, and the diameter of the right internal carotid artery averaged 3.8 mm compared with 5.8 mm on the left. The right internal carotid flow was only 26% of the flow readings from the left internal carotid artery. In each instance, the differences between the right- and left-sided means were significant at the $p \leq 0.01$ level of confidence. There were no significant differences between the left and right carotid measures in the control group. Patient 10 is described in the separate category of "ECMO control subject" (see the Methods section, above). In the interest of objectivity, his study results were interpreted under the diagnosis of "carotid occlusion," whereas he actually had an ECMO procedure at 2 years of age, with ligation of the right axillary artery and sparing of the carotid artery. In this child the diameter of the right and left internal carotid arteries, along with timed average velocities, were approximately equal, and there was no enhancement in the left internal carotid artery flow rate in comparison with right-sided measures noted in patients 1 to 9.

Evoked potential studies. Hearing levels were within normal limits and had threshold differences <5 dB between the two ears. No significant differences were seen between the hemispheres in the latency measures of the various components of the EPs studied in the ECMO patients. There was also no significant difference in latency between the age-matched control group and the ECMO patients. There were no significant differences in the hemispheric symmetry of amplitudes for wave V of the auditory brain-stem, component P₃₀ of the middle-latency auditory EPs and N₁₂ of the somatosensory EPs (Table III for group means). There were no differences between the amplitude of the peripheral nerve potentials and the amplitude recorded over the Erb point, evoked by stimulation of either median nerve. How-

ever, significant differences in hemispheric amplitude symmetry were found for both long-latency auditory EPs (P₁₃₅) and somatosensory EPs (P₂₂) from median nerve stimulation, with a decrease in the amplitude of the potentials recorded over the right hemisphere relative to those recorded over the left hemisphere when compared with the normal control values (Table III). In the Figure, a representative tracing of the EPs from one of the patients is shown.

DISCUSSION

We identified changes in blood flow and EPs in survivors of neonatal ECMO. There were differences in the diameter of the right internal carotid artery compared with the left as determined by ultrasound imaging, with retrograde flow to the right internal carotid system from the right external carotid circulation being noted in every patient in whom carotid artery ligation was carried out. The flow through the right internal carotid artery was reduced relative to the left carotid flow. In contrast, a child whose ECMO procedure involved ligation of the right axillary artery showed no change in the diameter of the right internal carotid artery, with no asymmetry in timed average velocities and flow. The EEG did not appear to be a particularly sensitivity measure for noting interhemispheric differences after ECMO; localizing findings correlated with neither the presence nor the absence of right hemispheric signs.

A more sensitive measure of hemispheric asymmetry in these patients turned out to be the amplitude of the long-latency cortical components. To somatosensory stimulation, the amplitude of the N₁₇₋₁₀-P₂₂ components over the right hemisphere to left-sided stimulation was significantly smaller than the N₁₇₋₁₀-P₂₂ components over the left hemisphere to right-sided input. In contrast, the peripheral nerve volleys recorded over the Erb point and C_{vii} were of equal amplitude. The asymmetry of cortical components was also noted in the long-latency auditory response. In contrast,

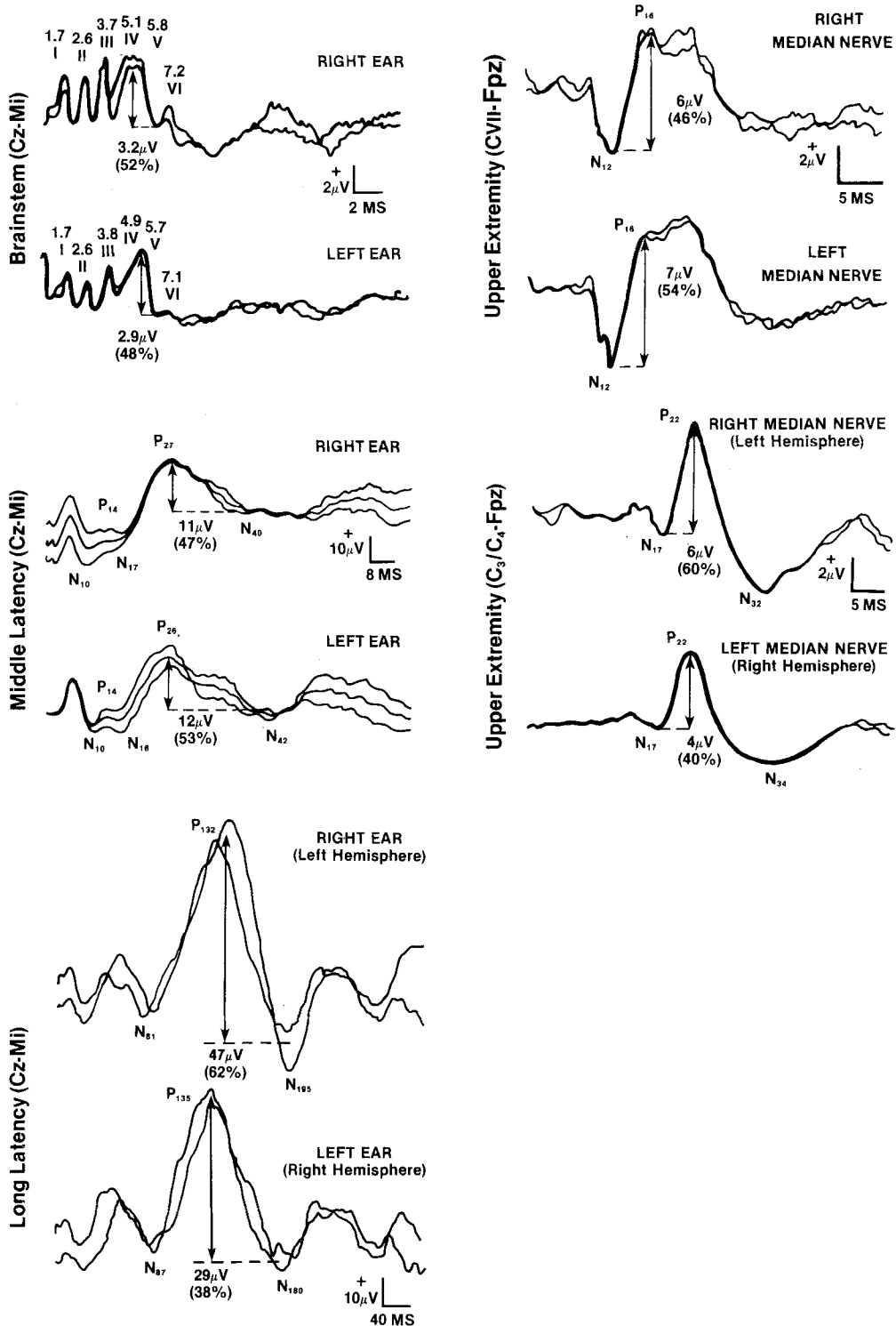


Figure. Tracings from representative patient are displayed to show the various EPs tested in ECMO patients and in normal subjects. Auditory EPs are at *left* and somatosensory EPs are at *right*. Arrows indicate component selected for amplitude measurement. Numbers represent value (in microvolts) and hemispheric symmetry of component (percentage). (See Methods section for calculations used.) Note relative symmetry of amplitude of wave V and component P₂₇ of auditory EPs and component N₁₂ of somatosensory EPs but asymmetry of component P₁₈₀ and components N₁₇ to P₂₂ for long-latency auditory and somatosensory potentials, respectively.

amplitude asymmetry was not noted for brain-stem or middle-latency auditory EPs. Taken together, the results of the long-latency auditory EPs and the somatosensory EPs in the ECMO patients show a decrease in the responsiveness of the right hemisphere compared with the left hemisphere after contralateral inputs. The finding of smaller-amplitude long-latency potentials to left-sided auditory or somatosensory stimulation has several possible explanations: (1) There may be a decrease in the numbers of neurons and fibers in the right hemisphere compared with the left hemisphere; (2) the numbers of active elements may be the same, but their orientations may differ in the two hemispheres; and (3) the resistance of the calvarium over the two hemispheres may differ because of changes in the thickness of the bone. For the auditory modality, the vertex electrode is common to both right and left hemisphere recordings. Thus the finding of a lower amplitude over the right hemisphere relative to the left must represent differences in the recording at the reference electrodes (i.e., the right mastoid vs the left mastoid). The amplitude of the potential recorded over the scalp from a cortical generator can be affected by the orientation of the dipole source for that component.⁶ Shifts of the dimension, orientation, or location of the dipole will have profound effects on the scalp distribution of the resulting potential fields. Thus the finding of asymmetric amplitudes over the two hemispheres may represent a change in the orientation of the dipole generating these potentials and not necessarily a decrease in responsiveness. For the amplitude asymmetry of the somatosensory potentials, a change in dipole orientation or location could also account for the observed differences in amplitude. The finding of symmetric responses of the auditory brain-stem potentials suggests that there is no alteration in lateralized brain-stem function in these subjects and that there is no asymmetry of the bone overlying the two hemispheres sufficient to affect the distribution of the voltage fields. The lack of asymmetry of the middle-latency auditory EPs is somewhat surprising because these components are thought to be generated in the temporal lobe.⁷

Normal adult populations do not have significant asymmetry in latency or amplitude measures of the auditory brain-stem responses.^{5, 8, 9} However, Levine and McGaffigan⁸ noted asymmetry in the amplitudes of waves I, III, and IV, with mean amplitude larger for right-ear than for left-ear stimulation. These percentages were slightly less than those identified in our study of the ECMO patients. The lack of asymmetry in our control subjects is more in agreement with the findings of Hixon and Mosko,⁹ whose procedures most closely resemble our own. Levine and McGaffigan used nonreferential recordings that change the characteristics of EPs, whereas we used referential readings.

The hemispheric asymmetry in long-latency components

of the auditory and somatosensory EPs in long-term survivors of ECMO may be a reflection either of permanently altered cerebral blood flow in the right internal carotid artery system or of permanently altered right hemispheric responsiveness consequent to the ECMO procedure. Alternative possible explanations include (1) reduction of right internal carotid blood flow at a critical period of neonatal hemispheric organization and (2) the fact that left internal carotid flow is "supranormal" in comparison with retrograde and collateral flow in the right internal carotid system.

Several authors¹⁰⁻¹² have noted a relationship between cerebral blood flow and amplitude alterations in the cortical component of EP measures, supporting our suggestion that the asymmetric amplitudes of EPs in the ECMO patients are related to reduced cerebral blood flow through the right internal carotid artery system.

The significance of the asymmetric findings in the EP studies are uncertain but may represent an abnormality not detected by current clinical methods. Mitchell et al.¹³ found retrograde flow in the distal internal carotid artery and the proximal (A₁) segment of the anterior cerebral artery after ECMO. These findings, along with those presented in this article, suggest that a major collateral pathway after ECMO exists through a left-to-right shunt in the anterior communicating artery. Taylor et al.^{14, 15} noted wide-ranging variations in cerebral blood flow after ECMO therapy as measured by intracranial Doppler ultrasonography, but these changes were well tolerated. These authors argued that a combination of ultrasonography and computed cranial tomography was necessary to appreciate intracranial lesions during and after ECMO, and that a neuroimaging score based on these measures was related to outcome. Krummel et al.,¹⁶ reporting a short-term follow-up study of six of nine infants who survived neonatal ECMO, found anterograde flow in the ophthalmic artery in five infants and retrograde flow in one infant.

The carotid flow studies reported in our current series are in agreement with the altered flow patterns cited above. Our findings of asymmetric amplitudes in the long-latency EPs may be a persisting hemispheric effect of this redirected cerebral blood flow.

REFERENCES

1. Hirschl RB, Bartlett RH. Extracorporeal membrane oxygenation support in cardiorespiratory failure. *Adv Surg* 1987; 21:189-212.
2. Glass P, Miller M, Short B. Morbidity for survivors of extracorporeal membrane oxygenation: neurodevelopmental outcome at 1 year of age. *Pediatrics* 1989;83:72-8.
3. Campbell LR, Bunyapen C, Holmes GL, Howell CG, Kanto WP. Right common carotid artery ligation in extracorporeal membrane oxygenation. *J PEDIATR* 1988;113:110-3.
4. Towne BH, Lott IT, Hicks DA, Healey T. Long-term follow-

- up of infants and children treated with extracorporeal membrane oxygenation (ECMO). *J Pediatr Surg* 1985;20:410-4.
5. Woods DL. Generators of middle- and long-latency auditory evoked potentials: implications from studies of patients with bitemporal lesions. *Electroencephalogr Clin Neurophysiol* 1987;68:132-48.
 6. McPherson D, Hirasugi Y, Starr A. Auditory brain stem potentials recorded at different scalp locations in neonates and adults. *Ann Otolaryngol* 1985;94:236-43.
 7. Lott IT, McPherson DL, Starr A. Cerebral cortical contributions to sensory evoked potentials. *Electroencephalogr Clin Neurophysiol Evoked Potentials* 1986;64:218-23.
 8. Levine RA, McGaffigan PM. Right-left asymmetries in the human brain stem auditory evoked potentials. *Electroencephalogr Clin Neurophysiol Evoked Potentials* 1983;55:532-7.
 9. Hixon W, Mosko J. Normative bilateral brainstem evoked response data for a naval aviation student population: group statistics, NAMRL-1262. Pensacola, Fla.: Naval Aerospace Medical Research Laboratory, 1978:27-28.
 10. Symon L, Wang AD, Costa E, Silva IE, Gentili F. Perioperative use of somatosensory evoked responses in aneurysm surgery. *J Neurosurg* 1984;60:269-75.
 11. Branston NM, Symon L, Crockard HA, Pasztor E. Relationship between the cortical evoked potential and local cortical blood flow following acute middle cerebral artery occlusion in the baboon. *Exp Neurol* 1974;45:195-208.
 12. Hargadine JR, Branston NM, Symon L. Central conduction time in primate brain ischemia: a study in baboons. *Stroke* 1980;11:637-42.
 13. Mitchell DG, Merton D, Desai H, et al. Neonatal brain: color Doppler imaging: altered flow patterns from extracorporeal membrane oxygenation. *Radiology* 1988;167:307-10.
 14. Taylor GA, Catena LM, Garin DB, Miller MK, Short BL. Intracranial flow patterns in infants undergoing extracorporeal membrane oxygenation: preliminary observations with Doppler US. *Radiology* 1987;165:671-4.
 15. Taylor GA, Short BL, Glass P, Ichord R. Cerebral hemodynamics in infants undergoing extracorporeal membrane oxygenation: further observations. *Radiology* 1988;168:163-7.
 16. Krummel TM, Greenfield LJ, Kirkpatrick BV, et al. The early evaluation of survivors after extracorporeal membrane oxygenation for neonatal pulmonary failure. *J Pediatr Surg* 1984;19:585-90.