

UCSF

UC San Francisco Previously Published Works

Title

Tocilizumab as a steroid sparing agent for the treatment of Graves' orbitopathy

Permalink

<https://escholarship.org/uc/item/3mb9m14r>

Authors

Russell, David J
Wagner, Lilly H
Seiff, Stuart R

Publication Date

2017-09-01

DOI

10.1016/j.ajoc.2017.07.001

Peer reviewed



Case report

Tocilizumab as a steroid sparing agent for the treatment of Graves' orbitopathy

David J. Russell^{a, b}, Lilly H. Wagner^{a, b, *}, Stuart R. Seiff^{a, b}^a California Pacific Medical Center, 2100 Webster Street, Suite 214, San Francisco, CA 94115, USA^b University of California San Francisco, 400 Parnassus Avenue, 7th floor, San Francisco, CA 94143, USA

ARTICLE INFO

Article history:

Received 10 January 2017

Received in revised form

12 June 2017

Accepted 6 July 2017

Available online 8 July 2017

Keywords:

Graves' disease

Thyroid associated orbitopathy

Tocilizumab

Interleukin-6

ABSTRACT

Purpose: To describe the effect of tocilizumab in two patients with thyroid associated orbitopathy (TAO).
Observations: We present two patients with TAO who could not tolerate corticosteroids and had a reduction in clinical and laboratory markers of inflammatory activity with subsequent tocilizumab therapy.

Conclusions and importance: The IL-6 receptor antibody tocilizumab is a promising candidate for the treatment of TAO because it selectively targets a key inflammatory mediator and has a favorable side effect profile. Our report demonstrates that tocilizumab can achieve further reduction in inflammatory activity after treatment with corticosteroids. Importantly, we and others have observed a decrease in the level of thyroid stimulating immunoglobulin (TSI) with tocilizumab treatment. This suggests an upstream effect in the inflammatory cascade. Although the impact of tocilizumab on long-term outcome is unknown at this time, we believe that early disruption of the inflammatory process may prevent late complications and decrease the need for rehabilitative surgery.

© 2017 The Authors. Published by Elsevier Inc. This is an open access article under the CC BY-NC-ND license (<http://creativecommons.org/licenses/by-nc-nd/4.0/>).

1. Introduction

For the inflammatory stage of TAO, the most commonly used initial pharmacologic treatment are intravenous or oral corticosteroids. Although suppression of inflammatory activity can often be achieved, the effect of corticosteroids is pleiotropic and involves transcriptional activation and repression of a wide range of genes. Because of their pleiotropic nature, corticosteroids are associated with significant morbidity including worsening of diabetes mellitus, osteoporosis, insomnia, psychosis, and hepatic injury.¹ Steroid sparing agents such as methotrexate and cyclosporine have been reported to be successful second-line agents.^{2,3} More recently, biologic agents including rituximab, adalimumab, tocilizumab, and most recently teprotumumab have also been shown to be effective.^{4–7} Tocilizumab (ACTEMRA[®], Genentech, South San Francisco, USA) is a recombinant humanized IgG₁ monoclonal antibody directed against IL-6 receptors. It is FDA approved for the treatment of rheumatoid arthritis in cases of inadequate response to other

disease modifying anti-rheumatic drugs. Prior in-vitro studies have demonstrated that activation of the TSH receptor induces expression of the pro-inflammatory cytokine IL-6 in orbital fibroblasts. In turn, IL-6 stimulates expression of the TSH receptor in orbital fibroblasts of TAO patients.^{8,9} By directly blocking IL-6 receptors, tocilizumab interrupts this inflammatory cascade. Tocilizumab has already been reported to be effective in patients with TAO who have been unresponsive to steroids.⁶ We present two cases of patients with TAO who initially had positive responses to corticosteroids and methotrexate, but could not tolerate continuation of treatment due to adverse side effects. Both patients were successfully treated with tocilizumab without complications. The collection and evaluation of all protected health information used for this report was compliant with the Health Insurance Portability and Accountability Act. The study adhered to the principles of the declaration of Helsinki.

2. Findings

Case 1: An 81-year-old Asian female presented with right upper lid retraction. A diagnosis of Graves' disease had been made two months prior during a work up for a myocardial infarction. She had no current or past smoking history. Her best corrected visual acuity

* Corresponding author. California Pacific Medical Center, 2100 Webster Street, Suite 214, San Francisco, CA 94115, USA.

E-mail addresses: daverussell.doc@gmail.com (D.J. Russell), lilly.droll@gmail.com (L.H. Wagner), sseiff@gmail.com (S.R. Seiff).

(VA) was 20/40 OD and 20/25 OS with a Clinical Activity Score (CAS) of 3 and a thyroid stimulating immunoglobulin (TSI) of 832%. She could not tolerate methimazole without concurrently taking diphenhydramine to suppress pruritus, and this was causing incapacitating sedation. Within one month of presentation her CAS score rose to 6 and her TSI rose to 954% (Fig. 1), she had severe upper lid retraction with exposure keratopathy right greater than left and bilateral upgaze restriction. She was started on oral prednisone and underwent a right lateral tarsorrhaphy. She was also referred for surgical thyroidectomy. The patient did not improve after the thyroidectomy. While on an oral steroid taper, her VA decreased to CF OD and 20/200 OS. She was started on IV methylprednisolone and methotrexate, and although she showed clinical improvement, treatment had to be discontinued because she suffered from uncontrolled blood sugar levels, insomnia and greater than 30-pound weight gain as well as gastrointestinal pain and diarrhea. She underwent bilateral transantral orbital decompression and showed postoperative improvement of VA, but her CAS remained high. At this point she was started on tocilizumab (8mg/kg once a month). Within 2 months of starting tocilizumab therapy her VA improved to 20/30 in each eye and her CAS decreased to 2 (Fig. 1A); her TSI dropped to 225% 5 months after the initial dose (from max. of 954%, Fig. 1B).

Case 2: A 34-year old Asian female presented with bilateral eyelid swelling, orbital pain, redness and tearing. She had been diagnosed with Graves' disease 17 months prior and had undergone thyroid radioablation therapy 11 months before her first visit with us. In addition, she had a history of atypical rheumatoid arthritis (RA) currently treated with etanercept. The patient had no

current or past smoking history. Her VA was 20/20 OD and 20/25 OS, she had bilateral upgaze restriction and upper lid retraction. Her CAS was 6 and her TSI was 432% (Fig. 2). She showed some clinical improvement after 3 weekly doses of 500mg IV methylprednisolone, but developed weight gain, bloating, and insomnia. Since tocilizumab is approved for the treatment of RA and concurrent use of anti-TNF alpha therapy is contraindicated, etanercept was discontinued. She was started on tocilizumab at an intravenous dose of 8mg/kg per month as a combined treatment for TAO and RA. The patient showed immediate clinical improvement, and over the course of 4 months her CAS dropped to 1 (Fig. 2A) and her TSI to 165% (Fig. 2B). In addition, she also had significant improvement of her RA related joint pain.

3. Discussion

Currently available treatment options for moderate or severe TAO mainly consist of non-targeted immunosuppressive agents, including corticosteroids and antimetabolites. Corticosteroid therapy is frequently associated with adverse events and may be contraindicated in patients with pre-existing liver or kidney disease, poorly controlled diabetes or hypertension, or psychiatric disease. Furthermore, long-term complications such as lid retraction, proptosis due to deposition of glycosaminoglycans and hyaluronate, and diplopia due to restrictive myopathy frequently occur in spite of medical treatment and may require rehabilitative surgery. While monoclonal antibodies targeting B-cells or TNF α have been reported to achieve promising results, randomized clinical trials and long-term results are lacking.^{4,5} Given the central role that IL-6

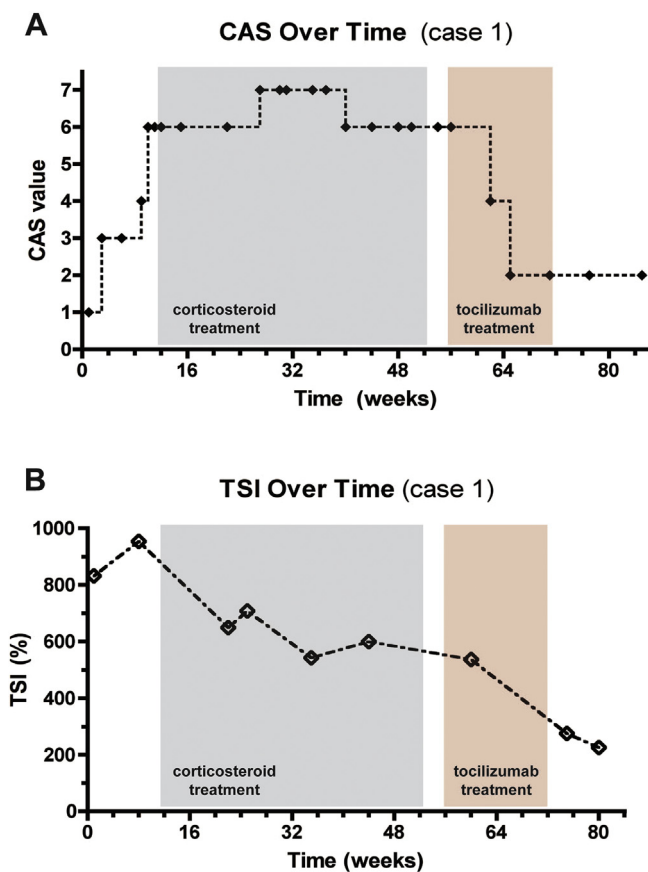


Fig. 1. Clinical activity score (CAS) value (A) and Thyroid stimulating immunoglobulin (TSI) value (B) for case 1 over time, initiation and duration of corticosteroid and tocilizumab treatments indicated with shaded areas.

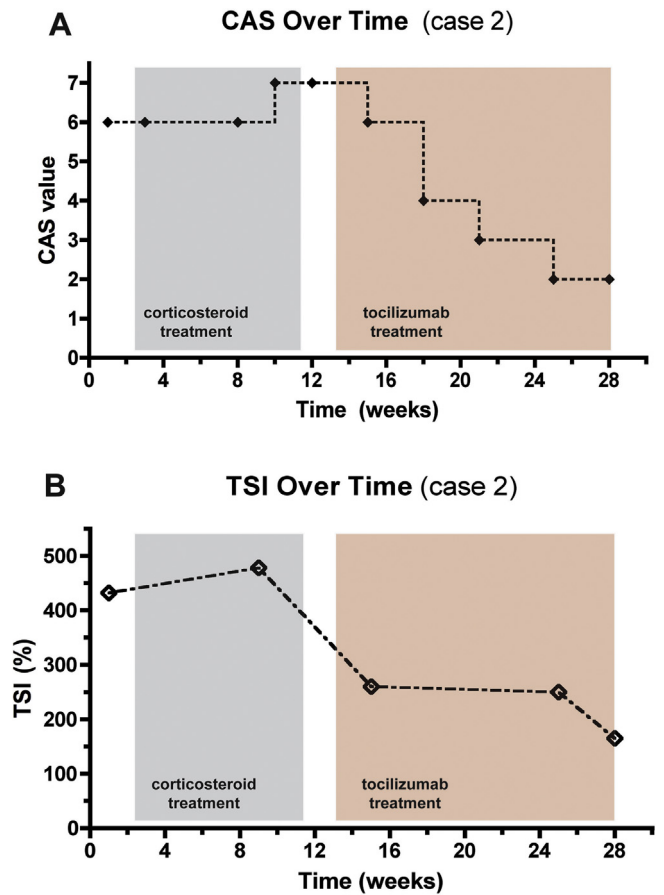


Fig. 2. Clinical activity score (CAS) value (A) and Thyroid stimulating immunoglobulin (TSI) value (B) for case 2 over time, initiation and duration of corticosteroid and tocilizumab treatments indicated with shaded areas.

plays in upregulating the inflammatory process in TAO,^{8,9} it represents a promising target to possibly achieve early control of inflammation and prevention of long-term complications.

In the United States, the monoclonal anti-IL-6 receptor antibody tocilizumab is currently only approved for the treatment of rheumatoid arthritis. Pérez-Moreiras et al. and Sy et al. have demonstrated that treatment with tocilizumab achieved significant clinical improvement in TAO patients who did not respond to corticosteroids.^{6,10} The two cases we present did initially show a clinical response to corticosteroid therapy but had to discontinue their treatment because of adverse side effects. Both patients showed dramatic improvement in their clinical disease activity with final CAS scores of 2 and 1, respectively, as well as a rapid decrease of TSI levels. Based on these cases, we propose that tocilizumab could potentially be given early on in the inflammatory process of Graves' orbitopathy as it is highly effective with a better side effect profile than corticosteroids.

4. Conclusion

Early disruption of the inflammatory cascade may prevent acute vision threatening events as well as the more common late sequelae of TAO, and decrease the need for rehabilitative surgery. We believe that it is important for ophthalmologists and ophthalmic surgeons to know that tocilizumab can potentially be used as a steroid-sparing agent. A randomized clinical trial investigating the use of tocilizumab for TAO is currently being completed.¹¹ Results from this trial as well as future reports of long-term outcomes will further clarify the value of tocilizumab or other IL-6 targeted therapies.

Patient consent

Consent to publish the case report was not obtained. This report does not contain any personal information that could lead to the identification of the patient.

Acknowledgements and disclosures

Funding: No funding or grant support was obtained for this study.

Conflict of interest: The following authors have no financial disclosures: DR, LW, SS.

Authorship: All authors attest that they meet the current ICMJE criteria for Authorship.

Acknowledgements: None.

References

1. Zang S, Ponto KA, Kahaly GJ. Clinical review: intravenous glucocorticoids for Graves' orbitopathy: efficacy and morbidity. *J Clin Endocrinol Metab.* 2011;96(2):320–332.
2. Strianese D, Iuliano A, Ferrara M et al. Methotrexate for the treatment of thyroid eye disease. *J Ophthalmol.* <http://dx.doi.org/10.1155/2014/128903>.
3. Kahaly G, Schrezenmeier J, Krause U, et al. Cyclosporin and prednisone v. prednisone in treatment of Graves' ophthalmopathy: a controlled, randomized and prospective study. *Eur J Clin Invest.* 1986;16(5):415–422.
4. Salvi M, Vannucchi G, Currò N, et al. Efficacy of B-cell targeted therapy with rituximab in patients with active moderate to severe Graves' orbitopathy: a randomized controlled study. *J Clin Endocrinol Metab.* 2015;100(2):422–431.
5. Ayabe R, Rootman DB, Hwang CJ, et al. Adalimumab as steroid-sparing treatment of inflammatory-stage thyroid eye disease. *Ophthalm Plast Reconstr Surg.* 2014;30(5):415–419.
6. Pérez-Moreiras JV, Alvarez-López A, Gómez EC, et al. Treatment of active corticosteroid-resistant graves' orbitopathy. *Ophthalm Plast Reconstr Surg.* 2014;30(2):162–167.
7. Smith TJ, Kahaly GJ, Ezra DG, et al. Teprotumumab for thyroid-associated ophthalmopathy. *N Engl J Med.* 2017;376(18):1748–1761.
8. Kumar S, Schiefer R, Coenen MJ, et al. A stimulatory thyrotropin receptor antibody (M22) and thyrotropin increase interleukin-6 expression and secretion in Graves' orbital preadipocyte fibroblasts. *Thyroid.* 2010;20(1):59–65.
9. Jyonouchi SC, Valyasevi RW, Harteneck DA, et al. Interleukin-6 stimulates thyrotropin receptor expression in human orbital preadipocyte fibroblasts from patients with Graves' ophthalmopathy. *Thyroid.* 2001;11(10):929–934.
10. Sy A, Eliasieh K, Silkiss RZ. Clinical response to tocilizumab in severe thyroid eye disease. *Ophthalm Plast Reconstr Surg.* 2017;33(3):e55–e57.
11. Tocilizumab Treatment in Graves' Ophthalmopathy. Identifier NCT01297699. Available at <https://clinicaltrials.gov>. Accessed May 21, 2017.