

# Congenital Stenosis of the Duodenum due to Duodenal Web in a Neonate: A Case Report

Yoo SS, MD | Chen J, MD

**Author Affiliation:** Department of Radiological Sciences, David Geffen School of Medicine at UCLA

**Corresponding Author:** S.S.Y. ([shannonyoo@mednet.ucla.edu](mailto:shannonyoo@mednet.ucla.edu))

*UCLA Radiol Sci Proc.* 2022;2(3):31-33

**Abstract:** Congenital stenosis of the duodenum secondary to duodenal web is a rare and predominantly pediatric condition due to incomplete recanalization of the duodenal lumen during early gestation. The windsock appearance on a fluoroscopic examination of the upper gastrointestinal tract is pathognomonic for obstructive processes in the duodenum. Here, we report a surgically proven case of duodenal web in an infant.

**Keywords:** *duodenal web, windsock sign, congenital duodenal obstruction, intraluminal duodenal diverticulum*

## Case Presentation

A full-term one-week-old boy with unremarkable prenatal history was brought to the emergency department with concern for poor feeding and the loss of 12% of the birth weight. Caregivers recalled the newborn experiencing frequent episodes of spitting up and forceful nonbilious and nonbloody emesis approximately 30 minutes after feeds. The results of initial physical and radiographic examinations were normal. Ultrasound showed a patent gastric outlet with normal pyloric muscle thickness and length. The subsequent fluoroscopic upper gastrointestinal series revealed a diffuse dilation of the first, the second, and the third parts of the duodenum, a minimal passage of contrast through an apparent area of partial duodenal obstruction, and an abrupt termination of the duodenum at the midline of the abdomen (Figure 1). In addition, multiple bouts of forceful gastroesophageal reflux of contrast were seen during the procedure (Figure 2). The overhead radiograph obtained 10 minutes after the

## Key Points

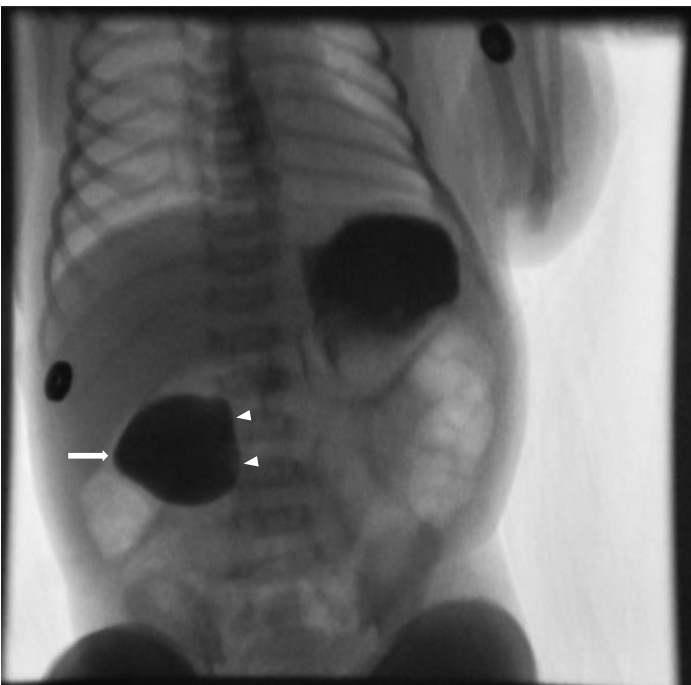
- Duodenal web is one of the causes of duodenal obstruction in neonates.
- The characteristic imaging appearance of duodenal web on upper GI fluoroscopy is a windsock sign.

completion of fluoroscopic examination showed relatively decompressed, contrast-opacified jejunal loops in the left abdomen (Figure 2). With concerns for partial duodenal obstruction, the patient was referred for surgical treatment. The intraoperative findings were notable for two adjacent intraluminal webs causing near-complete obstruction of the small bowel. The patient underwent duodenoplasty with partial resection of the webs. Postoperatively, the patient required a brief period of bowel rest and total parenteral nutrition. The patient convalesced quickly, however, and was discharged from the hospital five days after surgery, once full feeds were tolerated. During subsequent follow-up visits, the patient showed good feeding tolerance and no symptoms of duodenal obstruction.

## Discussion

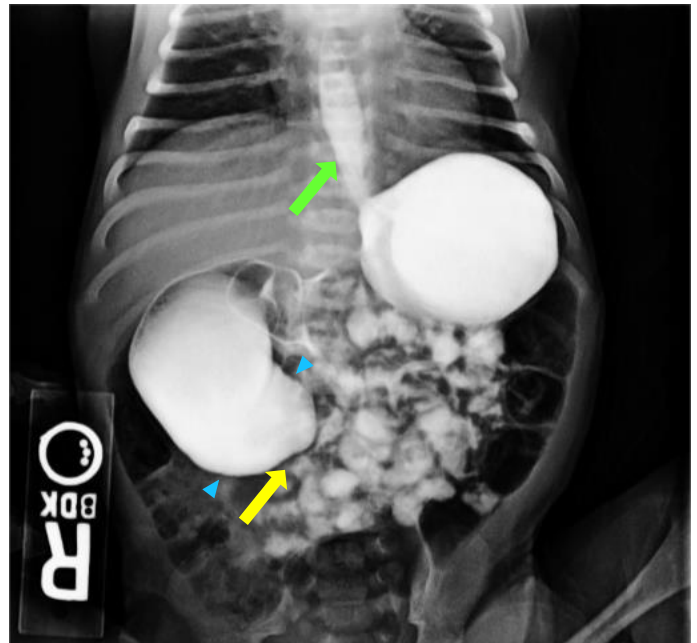
Duodenal web, which was first described in the literature<sup>1</sup> in 1845, is a rare cause of intrinsic duodenal obstruction. Its pathogenesis is attributed to incomplete recanalization of the duodenum and the formation of a thin transverse partition obstructing the duodenal lumen and consisting of only mucosa and submucosa.<sup>2,3</sup> Although congenital duodenal web (CDW) is often associated with other congenital anomalies such as Down syndrome, malrotation of the gut, or annular pancreas,<sup>3,4</sup> it can occur in isolation,<sup>3</sup> as described in this case report. Duodenal web is considered predominantly a pediatric diagnosis. Because duodenal obstruction due to duodenal web rarely manifests beyond infancy,<sup>5</sup> a high index of suspicion is required for this diagnosis in older children and adults.<sup>6</sup> The most common symptoms of duodenal obstruction due to CDW, in the order of decreasing frequency, are vomiting, abdominal distension, dehydration, and weight loss,<sup>2,3</sup> all of which are nonspecific and explained by impeded passage of bowel content through the

**Figure 1.** Iohexol-enhanced Fluoroscopic Spot Image of the Abdomen in a One-week-old Boy with Partial Duodenal Obstruction.



The image shows a dilated proximal part of the duodenum (arrow) with an abrupt midline cutoff (arrowheads).

**Figure 2.** Radiograph of the Abdomen, Approximately 10 minutes after Completion of the Upper Gastrointestinal Series in a One-week-old Boy with Partial Duodenal Obstruction.



Supine kidneys-ureters-bladder view shows contrast moved beyond the dilated duodenum and formed a windsock sign (blue arrowheads), with the duodenal web, a thin radiolucent line at the border of the contrast (yellow arrow), protruded into the relatively decompressed jejunal loops, suggesting a partial duodenal obstruction. Gastroesophageal reflux is also seen (green arrow).

gastrointestinal tract and subsequent peristalsis against duodenal web.

Duodenal web has been traditionally treated surgically,<sup>2,3</sup> as it was done in our case. However, the use of minimally invasive techniques, such as endoscopic dilation with or without resection of duodenal web as well as fluoroscopy-guided balloon dilation, with good clinical outcomes and decreased morbidity compared to surgical intervention has been reported.<sup>6</sup> Approximately 85%-90% of reported cases of duodenal web occurred in the second portion of the duodenum, in the region of the ampulla of Vater.<sup>7</sup> Depending on anatomic position of duodenal web to the ampulla of Vater, distal or proximal, vomitus can be bilious or nonbilious, respectively.<sup>8</sup> Careful identification of an anatomic relation between duodenal web and the ampulla of Vater is crucial for the prevention of ampullary injury during surgical repair of congenital duodenal obstruction caused by the web.<sup>4,5,6</sup>

**Figure 3.** Windssock<sup>9</sup>

A conically shaped segmented tube devised to measure the speed and direction of wind gave its name to a characteristic radiologic appearance of intraluminal duodenal diverticulum formed by passive elongation of congenital duodenal web due to peristalsis.

Republished under the Creative Commons Attribution (CC BY-SA 2.0). (<https://creativecommons.org/licenses/by-sa/2.0/>)

Passive elongation of CDW caused by peristalsis results in the formation of intraluminal duodenal diverticulum (IDD), a radiographic appearance of which, the duodenal windssock sign (Figures 2 and 3), is pathognomonic of duodenal obstruction due to CDW.<sup>10</sup> The sign is the result of contrast filling a sac of IDD and forming a fine radiolucent line around the web.<sup>10</sup> A windssock sign can be seen not only on the upper gastrointestinal series, but also on ultrasound, in the fluid-filled duodenum when fluid or air bubbles are present distally to the web.<sup>11</sup> The clinical symptoms of IDD are often nonspecific, and radiologic findings play the key role in the diagnosis of this congenital disease.<sup>10</sup> Therefore, radiologists should know about the diagnostic significance of, and be familiar with, a windssock sign, the pathognomonic appearance of intraluminal duodenal diverticulum caused by congenital duodenal web.

### Author Contributions

Conceptualization, J.C. and S.S.Y.; Writing – original draft preparation, S.S.Y.; Review and editing, J.C. and S.S.Y.; Supervision, J.C. All authors agree to be accountable for all aspects of the work in ensuring that questions related to the accuracy or integrity of any part of the work are appropriately investigated and resolved. All authors had full access to all the data in the study and take responsibility for the integrity of the data and the accuracy of the data analysis.

### Disclosures

None to report.

### References

1. Boyd R. Description of a malformation of the duodenum, with notices of analogous cases. *Med Chir Trans.* 1845;28:329–335. PMID: [PMC2116986](https://pubmed.ncbi.nlm.nih.gov/16986/)
2. Krieg EG. Duodenal diaphragm. *Ann Surg.* 1937;106(1):33-41. doi: [10.1097/0000658-193707000-00004](https://doi.org/10.1097/0000658-193707000-00004)
3. Bailey PV, Tracy Jr TF, Connors RH, Mooney DP, Lewis JE, Weber TR. Congenital duodenal obstruction: a 32-year review. *J Pediatr Surg.* 1993;28(1):92-95. DOI: [10.1016/s0022-3468\(05\)80364-1](https://doi.org/10.1016/s0022-3468(05)80364-1)
4. Sarin YK, Sharma A, Sinha S, Deshpande VP. Duodenal webs: an experience with 18 patients. *J Neonatal Surg.* 2012;1(2):20. Published 2012 Apr 1. PMID: [26023379](https://pubmed.ncbi.nlm.nih.gov/26023379/)
5. Ladd AP, Madura JA. Congenital duodenal anomalies in the adult. *Arch Surg.* 2001;136(5):576-584. DOI: [10.1001/archsurg.136.5.576](https://doi.org/10.1001/archsurg.136.5.576)
6. AlGhannam R, Yousef YA. Delayed presentation of a duodenal web. *J Pediatr Surg Case Rep.* 2015;3(12):530-533. <https://doi.org/10.1016/j.epsc.2015.10.014>
7. Melek M, Edirne YE. Two cases of duodenal obstruction due to a congenital web. *World J Gastroenterol.* 2008;14(8):1305-1307. DOI: [10.3748/wjg.14.1305](https://doi.org/10.3748/wjg.14.1305)
8. Sigmon DF, Eovaldi BJ, Cohen HL. Duodenal atresia and stenosis. In: *StatPearls*. NCBI Bookshelf version. StatPearls Publishing; 2022. Accessed July 8, 2022. <https://www.ncbi.nlm.nih.gov/books/NBK470548/> [updated 05-15-2022].
9. Burger C. Windssock at Departure Bay. Flickr. <https://www.flickr.com/photos/coreyburger/4802829390/sizes/l/ Published July 13, 2010. Accessed April 10, 2021.>
10. Materne R. The duodenal wind sock sign. *Radiology.* 2001;218(3):749-750. DOI: [10.1148/radiology.218.3.r01mr02749](https://doi.org/10.1148/radiology.218.3.r01mr02749)
11. Yoon CH, Goo HW, Kim EA, Kim KS, Pi SY. Sonographic windssock sign of a duodenal web. *Pediatr Radiol.* 2001;31(12):856-857. DOI: [10.1007/s002470100005](https://doi.org/10.1007/s002470100005)