

# UCSF

## UC San Francisco Previously Published Works

### Title

Ovarian cancer reporting lexicon for computed tomography (CT) and magnetic resonance (MR) imaging developed by the SAR Uterine and Ovarian Cancer Disease-Focused Panel and the ESUR Female Pelvic Imaging Working Group.

### Permalink

<https://escholarship.org/uc/item/3nv2t28w>

### Journal

European Radiology, 32(5)

### Authors

Shinagare, Atul  
Sadowski, Elizabeth  
Park, Hyesun  
et al.

### Publication Date

2022-05-01

### DOI

10.1007/s00330-021-08390-y

Peer reviewed



# HHS Public Access

Author manuscript

*Eur Radiol.* Author manuscript; available in PMC 2023 May 01.

Published in final edited form as:

*Eur Radiol.* 2022 May ; 32(5): 3220–3235. doi:10.1007/s00330-021-08390-y.

## Ovarian Cancer Reporting Lexicon for Computed Tomography (CT) and Magnetic Resonance (MR) Imaging Developed by the SAR Uterine and Ovarian Cancer Diseased Focused Panel and the ESUR Female Pelvic Imaging Working Group

Atul B. Shinagare, MD,

Correspondence to: ashinagare@bwh.harvard.edu, Phone: 617-732-6304.

\*Equal contribution to first author

Co-Author: Andrea Rockall, MD, MRCP, FRCR, Division of Surgery and Cancer, Imperial College London, Hammersmith Campus, ICTEM Building, Du Cane Rd, W12 0NN, UK

Compliance with Ethical Standards

Guarantor:

The scientific guarantor of this publication is Atul Shinagare, Elizabeth Sadowski, Andrea Rockall.

Conflict of Interest:

The authors of this manuscript declare the following relationships outside the subject matter:

---

Author: Atul B. Shinagare, MD

Disclosures: Not relevant to subject of this paper: Consultant, Virtualscopics, Imaging Endpoints

Author: Yulia Lakhman, MD

Disclosures: National Cancer Institute of Health P30 CA008748 (paid to the institution) outside the scope of this work: shareholder Y-mAbs Inc

Name: Susanna I Lee MD, PhD

Disclosures: Wolters-Kluwer and Springer (Royalties)

Author: Isabelle Thomassin-Naggara, MD, PhD

Disclosures: GE, Siemens, Hologic, Canon, Guebet (remunerated lecture in breast imaging not related to the subject of the paper)

Full name: Hebert Alberto Vargas, MD

Disclosures: Dr Vargas is supported in part by a National Institutes of Health/National Cancer Institute Cancer Center Support Grant to Memorial Sloan Kettering Cancer Center (P30-CA008748).

Co-Author: Andrea Rockall, MD, MRCP, FRCR

Disclosures: Reports personal fees from Guerbet Laboratories, outside the submitted work. Institution received academic grants from the Imperial Cancer Research UK Centre and Imperial National Institute of Health Research Biomedical Research Centre, outside the submitted work.

---

Statistics and Biometry:

No complex statistical methods were necessary for this paper.

Informed Consent:

Written informed consent was not required for this study because this was a quality improvement study that did not include human or animal subjects.

Ethical Approval:

Institutional Review Board approval was not required for this study because this was a quality improvement study that did not include human or animal subjects.

Study subjects or cohorts overlap:

This study or part of it has not been previously reported. Summary of the study was presented as oral presentation at RSNA 2020.

Methodology

- Multicenter expert consensus

Department of Radiology, Brigham and Women's Hospital/ Harvard Medical School, Boston, 75 Francis Street, Boston, MA 02115

**Elizabeth A. Sadowski, MD\***,

Departments of Radiology, Obstetrics and Gynecology, University of Wisconsin School of Medicine and Public Health, 600 Highland Ave, E3/372, Madison, WI 53792-3252

**Hyesun Park, MD,**

Department of Radiology, Brigham and Women's Hospital/ Harvard Medical School, Boston, 75 Francis Street, Boston, MA 02115

**Olga Brook, MD,**

Beth Israel Deaconess Medical Center, 1 Deaconess Rd, Boston, MA, 02215

**Rosemarie Forstner, MD,**

Department of Radiology. Universitätsklinikum Salzburg, PMU Salzburg, Müllner Hauptstr. 48, 5020 Salzburg, Austria

**Sumer Wallace, MD,**

University of Wisconsin School of Medicine and Public Health, Division of Gynecologic Oncology, 600 Highland Ave. H4/664A Madison, WI 53792

**Jeanne M. Horowitz, MD,**

Northwestern University Feinberg School of Medicine, 676 N Saint Clair, Chicago Illinois 60611

**Neil Horowitz, MD,**

Division of Gynecologic Oncology, Brigham and Women's Hospital, Boston, 75 Francis Street, Boston, MA 02115

**Marcia Javitt, MD,**

Medical Imaging, Rambam Health Care Campus, Haifa, Israel

**Priyanka Jha, MD,**

Department of Radiology, University of California San Francisco, 505 Parnassus Avenue, Box 0628, San Francisco, CA 94143-0628

**Aki Kido, MD,**

Graduate School of Medicine, Kyoto University, 54 Shogoinawahara-cho, Sakyo-ku, Kyoto city, Kyoto, Japan, 6068507

**Yulia Lakhman, MD,**

Department of Radiology, Memorial Sloan Kettering Cancer Center, 300 East 66 Street New York NY 10065

**Susanna Lee, MD,**

Massachusetts General Hospital, Harvard Medical School, 55 Fruit Street, White 270, Boston, MA 02114

**Lucia Manganaro, MD,**

Department of Radiological, Oncological and Pathological Sciences, Sapienza University of Rome, V.le Regina Elena 324 00161 Rome Italy

**Katherine E Maturen, MD, MS,**

Department of Radiology and Obstetrics and Gynecology, University of Michigan Hospitals, 1500 E Med Ctr Dr, Ann Arbor, MI 48109

**Stephanie Nougaret, MD,**

Department of Radiology, IRCM INSERM, U1194 SIRIC, Montpellier

**Liina Poder, MD,**

Obstetrics, Gynecology and Reproductive Sciences, Director of Ultrasound, Department of Radiology and Biomedical Imaging, UCSF, 505 Parnassus Ave, L-374, San Francisco, CA 94143-0628

**Gaiane Margishvili Rauch, MD,**

University of Texas MD Anderson Cancer Center, 1515 Holcombe Blvd, Houston, TX 77030

**Caroline Reinhold, MD,**

McGill University Health Center, McGill University, Montreal, Canada; Co-Director, Augmented Intelligence & Precision Health Laboratory of the Research Institute of McGill University Health Centre, 1001 Decarie boul., Montreal, Quebec, Canada, H4A 3J1

**Evis Sala, MD,**

Department of Radiology, University of Cambridge, Box 218, Cambridge Biomedical Campus, Cambridge CB2 0QQ, United Kingdom

**Isabelle Thomassin-Naggara, MD, PhD,**

Sorbonne Université, Assistance Publique – Hôpitaux de Paris, Service d'Imagerie, 4 rue de la Chine, 75020 Paris, France

**Alberto Vargas, MD,**

Memorial Sloan Kettering Cancer Center, 1275 York Av. New York, NY 10065 USA

**Aradhana Venkatesan, MD,**

Dept. of Abdominal Imaging, Division of Diagnostic Imaging, The University of Texas MD Anderson Cancer Center, 1400 Pressler St., FCT 15.6074, MSC 1182, Houston TX 77030

**Olivera Nikolic, MD,**

University of Novi Sad, Faculty of Medicine, Center of Radiology, Clinical Center of Vojvodina, 1-9 Hajduk Veljkova str. 21000 Novi Sad, Serbia

**Andrea G. Rockall, MBBS MRCP**

Division of Surgery and Cancer, Imperial College London, Hammersmith Campus, ICTEM Building, Du Cane Rd, W12 0NN, UK

## **Abstract**

Imaging evaluation is an essential part of treatment planning for patients with ovarian cancer. Variation in the terminology used for describing ovarian cancer on computed tomography (CT) and magnetic resonance (MR) imaging can lead to ambiguity and inconsistency in clinical radiology reports. The aim of this collaborative project between Society of Abdominal Radiology (SAR) Uterine and Ovarian Cancer (UOC) Disease-focused Panel (DFP) and the European Society of Uroradiology (ESUR) Female Pelvic Imaging (FPI) Working Group was to develop an ovarian cancer reporting lexicon for CT and MR imaging. Twenty-two members of the SAR UOC

DFP and ESUR FPI working group, one radiology clinical fellow, and two gynecologic oncology surgeons formed the Ovarian Cancer Reporting Lexicon Committee. Two attending radiologist members of the committee prepared a preliminary list of imaging terms that was sent as an online survey to 173 radiologists and gynecologic oncologic physicians, of whom 67 responded to the survey. The committee reviewed these responses to create a final consensus list of lexicon terms. This lexicon for CT and MR imaging evaluation of ovarian cancer patients has the capacity to improve the clarity and consistency of reporting disease sites seen on imaging.

## Keywords

Ovarian cancer; CT; MRI; lexicon; staging

---

## Introduction

Ovarian cancer is the most lethal of all gynecological malignancies with high-grade serous carcinoma responsible for the majority of cases. The National Cancer Institute currently estimated that one in 78 women will develop ovarian cancer and one in 108 women will die from ovarian cancer over their lifetime [1]. Approximately 70% of epithelial ovarian cancer is metastatic at initial presentation, which partly accounts for the poor prognosis [2]. Although ovarian cancer is primarily staged surgically, imaging is used to identify sites of disease in ovarian cancer patients and aids in selection of the best primary treatment, especially for those who have clear radiographic evidence of advanced stage disease (Table 1). Patients with ovarian cancer are treated with either immediate primary surgery followed by chemotherapy, or neoadjuvant chemotherapy with interval cytoreduction or delayed primary surgery. Extent and location of disease on pre-treatment imaging, in addition to other clinical factors, is often used to aid in the initial decision to proceed with upfront surgery or neoadjuvant chemotherapy. Both computed tomography (CT) and magnetic resonance (MR) imaging are used to identify difficult to resect or potentially unresectable disease, both of which are impediments to achieving optimal debulking [3–9].

While the management of advanced ovarian cancer is often significantly impacted by imaging, there is significant variability in the reporting of these studies in terms of report content and use of various terms to describe disease spread. This can lead to incomplete reporting or confusion about the extent of disease, and this missing information can be critical for management decisions, including surgical planning. Lack of standardized definitions can also result in discrepancy in research studies, limiting their generalizability. Therefore, there is a need for a standardized approach uniform terminology to describe the relevant findings on imaging in patients with ovarian cancer.

Several lexicons have been developed under the direction of the American College of Radiology (ACR) for standardized reporting mainly in the imaging characterization of primary lesions (e.g. breast, thyroid, liver, lung, ovary). The widespread implementation of standardized reporting terminology for lesion characterization on imaging improves consistency in interpretation, decreases reporting ambiguity and enables multicenter data analysis and research [10–21]. In the spirit of standardizing the content and terminology

in the radiology reports to improve the communication between radiologists and referring physicians, as well as between physicians and researchers, the Society of Abdominal Radiology (SAR) Uterine and Ovarian Cancer (UOC) Disease-focused Panel (DFP) and the European Society of Uroradiology (ESUR) Female Pelvic Imaging (FPI) working group has developed a lexicon for Ovarian Cancer Reporting for CT and MR imaging to assess disease sites at initial diagnosis and in the follow-up setting.

## Lexicon Terms and Definition Development Methodology

This multi-institutional, multidisciplinary international initiative included members of the SAR UOC DFP and the ESUR FPI working group and produced the Ovarian Cancer Reporting Lexicon. Only terms relevant to CT and MRI were included because these modalities are used for assessment of disease sites in ovarian cancer patients. Selected terms describing adnexal lesions were included in this lexicon, but previously described definitions were used for these terms to maintain consistency with ACR Ovarian-Adnexal Reporting & Data System (O-RADS) lexicon [14, 22]. Other terms used in the O-RADS lexicon were not included as this lexicon focuses on staging of known ovarian cancer, and therefore detailed description of each imaging feature of the ovarian mass is not necessary in the radiology report.

### Committee Structure

The Ovarian Cancer Reporting Lexicon Committee was formed in the Spring of 2019 and included the following members: 21 attending radiologist members from the SAR UOC DFP (n=12) and ESUR FPI working group (n=9), one radiology clinical fellow and two gynecologic oncologic surgeons, who collaboratively developed the final reporting lexicon. A.S. and L.S. were the representative leaders from the SAR UOC DFP and A.R. was the representative leader from the ESUR FPI working group.

### Selection of Lexicon Terms and On-line Survey

Two attending radiologists from the Ovarian Cancer Reporting Lexicon Committee (A.S. and L.S.) led and oversaw the entire effort, serving as the ‘co-coordinators’. Together with the help of a radiology clinical fellow (H.P.), the coordinators compiled the list of terms using a review of literature, as well as the CT and MRI case report forms from the National Institute for Health Research (NIHR) MR in Ovarian Cancer (MROC) study and the ACR O-RADS lexicon [14, 22, 23]. A PubMed (<https://www.ncbi.nlm.nih.gov/pubmed/>) search through recent literature over a period of two years from Mar 2017 to Feb 2019 using the following search string: “(imaging or CT or MRI or PET/CT) and (ovarian or ovary) and (staging or preoperative)” and yielded total 165 publications, which were manually screened in consensus to identify the relevant publications. Publications were considered relevant if they were peer-reviewed and included at least one CT or MRI descriptor or definition related to ovarian cancer staging. The coordinators screened the full text of these publications and extracted a list of 73 imaging terms used in description of ovarian cancer staging for inclusion in the on-line survey. Major categories of morphological descriptors were developed as follows: General, Adnexal lesion-specific, Peritoneal carcinomatosis-specific, Lymph node-specific, Metastatic disease-specific, and Fluid-specific. Each major category

was sub-classified with a list of individual imaging terms. Various peritoneal disease scoring indices (eg. peritoneal carcinomatosis index, Eisenkop score, etc.) were included at the end of the survey to determine if these should be included in the lexicon.

An online survey containing the list of selected terms was created using REDCap (<https://redcap.partners.org/redcap/index.php>), a secure web application for building and managing online surveys. For each term, the recipients were asked to select “Yes”, “No” or “Maybe” to help decide inclusion of the term in the lexicon. Our sampling goal was to assess opinions among gynecologic specialty radiologists and gynecologic oncology specialists. The existing SAR and ESUR working groups provided a sampling frame for radiologists. We opted to include data from both radiologists and gynecologic oncology specialists in order to ensure multi-disciplinary input in selection of lexicon terms.

The survey was sent to a total of 173 recipients, including 54 members of the SAR UOC DFP, 61 members of the ESUR FPI working group and 58 gynecologic oncologic physicians at the Ovarian Cancer Staging Dictation Lexicon Committee members’ institutions. Each recipient received a unique link to access their survey, followed by up to three automated reminders, one week apart, to complete the survey. All responses were submitted anonymously. Survey recipients were blinded to the responses of the other participants.

Sixty-seven of 173 survey recipients (38.7%) completed the survey. The respondents were comprised of 51 radiologists and 16 gynecologic oncologists. Fifty-four respondents were from the North America and 13 from outside of North America (Table 2).

### Selection of Final Lexicon Terms

Based on the survey results, if at least 80% of the survey participants selected “Yes”, then the term was included as a ‘core’ term. If at least 80% “Yes” vote was not achieved, but 80% of the recipients selected a combination of “Yes” or “Maybe”, then the term was considered an ‘optional’ term and was further discussed by the Ovarian Cancer Reporting Lexicon Committee. If less than 80% of the survey participants selected “Yes” or “Maybe” the term was discussed by the committee to determine if it should be excluded.

Of the 73 terms included in the survey, 48 were deemed ‘core’ terms and 15 were deemed ‘optional’ terms (Appendix A). All ‘core’ terms were accepted by the Ovarian Cancer Reporting Lexicon committee as part of the lexicon except the term ‘simple cyst’. The committee agreed that ‘simple cyst’ was not necessary, because this lexicon is for ovarian cancer therefore the lexicon term ‘cystic’ would suffice because it encompassed all fluid containing findings in the adnexa, including simple cysts. All ‘optional’ terms were discussed by the committee and all terms were included in the final reporting lexicon except for ‘measurable disease’, ‘non-measurable disease’ and ‘complex cyst’. The terms ‘measurable disease’ and ‘non-measurable disease’ were excluded because these are defined by RECIST criteria [24] and are mainly used in the context of clinical trials; the committee felt it was not necessary to include these terms in the lexicon. ‘Complex cyst’ was excluded because the use of the word ‘complex’ has been discouraged by the ACR O-RADS committee, due to the word’s lack of specificity [22]. Ten terms did not meet either criteria to be considered as ‘core’ or ‘optional’ terms after the survey, and these

were discussed by the Ovarian Cancer Reporting Lexicon committee. Of these 10 terms, all but one, 'oval' lymph node morphology, were excluded from the final lexicon. The committee members agreed that 'oval' lymph node morphology is an essential feature to be considered and hence agreed to include this term. Three terms were added to the lexicon based on the comments from survey participants. 'Peritoneal cavity' was added to peritoneal carcinomatosis-specific terms, 'internal mammary lymph nodes' was added under lymph nodes-specific terminology, and 'bowel/stomach metastases' was added under metastatic disease to differentiate these from the serosal implants which fall under peritoneal disease. Table 3 is the final Ovarian Cancer Reporting Lexicon terms and definition table.

### Creation of the Final Lexicon Terms and Definitions

The SAR UOC DFP and ESUR FPI working group leaders of the Ovarian Cancer Reporting Lexicon Committee (A.S., L.S., A.R.) created draft definitions of the lexicon terms that were circulated to the entire committee. Based on committee feedback, minor grammar and verbiage usage edits were made to the definitions. Two teleconferences were conducted to finalize the list of lexicon terms and definitions. The final terms and definitions were incorporated into this manuscript and the manuscript was circulated to the Ovarian Cancer Staging Reporting Lexicon Committee members for their input.

### Discussion

The Ovarian Cancer Reporting Lexicon committee developed a consensus-based list of reporting lexicon terms and definitions for CT and MRI (Table 3). This is a multidisciplinary, multi-institutional international effort to standardize radiological reporting of sites of ovarian cancer on imaging at initial diagnosis and in the follow-up setting. The goal of the lexicon is to improve consistency in reporting disease, facilitate communication between radiologists and clinicians, and promote optimized patient management [15, 17–19]. This reporting lexicon will also allow for standardization of multi-institutional research and collaborations [15, 16].

The final, consensus-based standardized Ovarian Cancer Reporting Lexicon has 6 major categories of terms: General, Adnexal lesion-specific, Peritoneal carcinomatosis-specific, Lymph node-specific, Metastatic disease -specific, and Fluid-specific. The lexicon has been grouped into categories to aid the radiologist in identifying specific sites of disease, with a focus on anatomical regions that have implications on resectability and/or provide information about disease stage. Although ovarian cancer is primarily staged surgically, identifying difficult to resect disease or disease in anatomical regions which may upstage the final assessment (for example, inoperable hepatic or lung metastases or mesenteric root involvement) can allow surgeons to avoid unsuccessful primary surgical management [6, 25–27].

Unlike many other types of carcinoma, ovarian cancer does not become unresectable when there is extensive disease and intraperitoneal carcinomatosis. Instead, the extent and distribution of tumor deposits govern the surgical approach and timing, so accurate description in radiology reports is important. Figure 1 depicts the common sites of ovarian cancer which should be mentioned in the report, as disease in these anatomical regions



may be difficult to resect and/or may result in upstaging [4, 6–8]. Differentiation between hepatic or splenic invasion from peritoneal disease (stage III disease) versus parenchymal liver or splenic metastases (stage IV disease) is important, both because of worse prognosis of hematogeneous spread in the latter and because of the potential inability to resect parenchymal lesions in some cases [28]. Hematogeneous metastases occur in the liver or splenic parenchyma. If a liver lesion is located near the surface of the organ, it is helpful to ensure that there is no adjacent capsular lesion invading into the parenchyma. If there is a peritoneal implant adjacent to liver, a smooth lesion contour suggests there is no adjacent capsular invasion, whereas an ill-defined, irregular, or obliterated lesion-liver interface suggests parenchymal invasion [28]. In equivocal cases, careful review of coronal and sagittal plane images may be helpful in differentiating between these. It is also important to look for and communicate perihepatic implants along the diaphragmatic surface along the bare area of the liver, because this area potentially can be difficult to visualize and the surgeon may need more time to explore these regions to achieve complete cytoreduction. Involvement of the root of the small bowel mesentery, presence of upper abdominal and suprarenal retroperitoneal lymph nodes is important, as disease in these regions is associated with higher rate of suboptimal cytoreduction [6]. Implants in the lesser sac or along the gastrocolic ligament should be clearly noted in the report, as these are areas that may be overlooked by laparoscopy that is sometimes done before laparotomy. Furthermore, disease in these areas may be difficult to resect or require morbid surgical procedures that maybe avoided if neoadjuvant chemotherapy had been used. Extensive bowel involvement is important to mention, as these cases may require pre-operative review and evaluation of serum albumin to determine resectability. It is often challenging to differentiate bowel wall metastases (Stage IV metastatic disease) from serosal implants (Stage III peritoneal disease). While imaging may not be able to differentiate between the two with absolute accuracy, in our experience, the epicenter of the lesion can serve as a useful feature. For bowel wall metastases, the epicenter of the lesion is often located in the bowel wall and can be located in any portion of the bowel wall. On the other hand, epicenter of serosal implant is adjacent to the bowel wall and usually these implants are located along the mesenteric side of the bowel wall. Mesenteric implants can be sometimes difficult to differentiate from mesenteric lymph nodes. Reactive mesenteric nodes are usually multiple, subcentimeter in short axis, elongated and situated along the mesenteric vessels. Mesenteric nodes involved by disease are often round, enlarged, heterogeneous and irregular/spiculated. On the other hand, mesenteric peritoneal disease is often accompanied by other peritoneal findings such as peritoneal involvement elsewhere, ill-defined mesenteric soft tissue or nodularity, mesenteric root retraction, or fluid between the mesenteric folds. Despite these differences, at times it may not be possible to differentiate between pathologically involved mesenteric nodes and mesenteric implants. Pelvic sidewall invasion should also be conveyed in the radiology report because the extent of involvement and structures involved may have a significant impact on cytoreductive surgery. Finally, any disease outside of the abdominal cavity, including thoracic disease and inguinal lymph node disease, upstages the patient to FIGO Stage IV and has implications on the patient's treatment and prognosis. Finally, the lexicon does not include the various peritoneal carcinomatosis indices. The initial survey included 5 indices for possible inclusion (Peritoneal carcinomatosis index, Eisenkop score, Fagotti score, Fagotti-modified score, Aletti score) but only 0–16% respondents answered

“Yes” to including these in the report. Further, there is no consensus among the radiologists or the gynecologic oncology specialists about the peritoneal index of choice, and the correlation between the imaging and clinical scoring of these indices has not been validated in large multi-center studies.

There are several points to address regarding this lexicon. The Ovarian Cancer Reporting Lexicon Committee members were selected based on their involvement in SAR UOC DFP and ESUR FPI working group, and included diverse members from the North America, Europe and Asia with extensive research and clinical experience in the field of ovarian cancer. This group of experts created the lexicon based on the literature, an on-going multi-center trial protocol, the ACR O-RADS lexicon and from the input from 67 survey recipients with a broad range of experience in gynecologic oncology imaging and treatment (51 radiologists, 16 gynecologic oncologists; 54 from the North America and 13 from outside of North America). All authors were allowed to propose edits to the definitions and the final manuscript. We used an online survey to create an initial list of the terms to be included in the lexicon. For survey recipients in non-European countries, the investigators sent the survey directly to the recipient’s e-mails, in addition to three automated e-mail reminders. Per the European GDPR guidelines, the lexicon survey to the ESUR members could only be sent via the ESUR office and no reminder e-mails were sent. This may have diminished the response rate from the ESUR members. It is also important to note that mere availability of this lexicon may not necessarily translate into excellent inter-reader agreement for use of various anatomic terms, which would require adoption of this lexicon, education, and some experience with its use in clinical practice. In addition, interpretation of the anatomical regions by different radiologists and surgeons may vary. The peritoneum is a complex anatomical space, and therefore it is likely that there will be variability in interpretation of the lexicon terms when applied to CT or MRI. Further work is needed to ensure inter-reader agreement in the assignment of disease to particular lexicon specific sites.

The Ovarian Cancer Reporting Lexicon provides a list of consensus-based, standardized reporting lexicon terms and definitions for the assessment of sites of ovarian cancer on CT and MRI. We hope that the implementation of this standardized reporting lexicon will promote consistent reporting and improve interdisciplinary communication. Furthermore, the consistent use of these descriptors has the potential for optimizing patient management and provides a basis for future high impact outcomes-based research and multi-institutional collaborations.

### **Funding:**

The authors state that this work has not received any funding.

### **Abbreviations:**

<b>ACR</b>	American College of Radiology
<b>CT</b>	computed tomography

<b>ESUR FPI</b>	European Society of Uroradiology Female Pelvic Imaging working group
<b>MR</b>	magnetic resonance
<b>O-RADS</b>	Ovarian-Adnexal Reporting & Data System
<b>PET/CT</b>	positron emission tomography/computed tomography
<b>SAR</b>	Society of Abdominal Radiology
<b>UOC DFP</b>	Uterine and Ovarian Cancer Disease-focused Panel

## References

1. Ovarian Cancer Statistics – Ovarian Cancer Research Alliance. In: OCRA. <https://ocrahope.org/patients/about-ovarian-cancer/statistics/>. Accessed 16 Mar 2020
2. Torre LA, Trabert B, DeSantis CE, et al. (2018) Ovarian cancer statistics, 2018. *CA Cancer J Clin* 68:284–296. 10.3322/caac.21456 [PubMed: 29809280]
3. Chi DS, Musa F, Dao F, et al. (2012) An analysis of patients with bulky advanced stage ovarian, tubal, and peritoneal carcinoma treated with primary debulking surgery (PDS) during an identical time period as the randomized EORTC-NCIC trial of PDS vs neoadjuvant chemotherapy (NACT). *Gynecol Oncol* 124:10–14. 10.1016/j.ygyno.2011.08.014 [PubMed: 21917306]
4. Forstner R, Sala E, Kinkel K, et al. (2010) ESUR guidelines: ovarian cancer staging and follow-up. *Eur Radiol* 20:2773–2780. 10.1007/s00330-010-1886-4 [PubMed: 20839002]
5. Expert Panel on Women’s Imaging, Kang SK, Reinhold C, et al. (2018) ACR Appropriateness Criteria® Staging and Follow-Up of Ovarian Cancer. *J Am Coll Radiol JACR* 15:S198–S207. 10.1016/j.jacr.2018.03.015 [PubMed: 29724422]
6. Suidan RS, Ramirez PT, Sarasohn DM, et al. (2017) A multicenter assessment of the ability of preoperative computed tomography scan and CA-125 to predict gross residual disease at primary debulking for advanced epithelial ovarian cancer. *Gynecol Oncol* 145:27–31. 10.1016/j.ygyno.2017.02.020 [PubMed: 28209497]
7. Rizzo S, De Piano F, Buscarino V, et al. (2020) Pre-operative evaluation of epithelial ovarian cancer patients: Role of whole body diffusion weighted imaging MR and CT scans in the selection of patients suitable for primary debulking surgery. A single-centre study. *Eur J Radiol* 123:108786. 10.1016/j.ejrad.2019.108786
8. Castellani F, Nganga EC, Dumas L, et al. (2019) Imaging in the pre-operative staging of ovarian cancer. *Abdom Radiol N Y* 44:685–696. 10.1007/s00261-018-1779-6
9. Chandrashekhara SH, Triveni GS, Kumar R (2016) Imaging of peritoneal deposits in ovarian cancer: A pictorial review. *World J Radiol* 8:513–517. 10.4329/wjr.v8.i5.513 [PubMed: 27247717]
10. Elsayes KM, Kielar AZ, Chernyak V, et al. (2019) LI-RADS: a conceptual and historical review from its beginning to its recent integration into AASLD clinical practice guidance. *J Hepatocell Carcinoma* 6:49–69. 10.2147/JHC.S186239 [PubMed: 30788336]
11. Grant EG, Tessler FN, Hoang JK, et al. (2015) Thyroid Ultrasound Reporting Lexicon: White Paper of the ACR Thyroid Imaging, Reporting and Data System (TIRADS) Committee. *J Am Coll Radiol JACR* 12:1272–1279. 10.1016/j.jacr.2015.07.011 [PubMed: 26419308]
12. Weinreb JC, Barentsz JO, Choyke PL, et al. (2016) PI-RADS Prostate Imaging - Reporting and Data System: 2015, Version 2. *Eur Urol* 69:16–40. 10.1016/j.eururo.2015.08.052 [PubMed: 26427566]
13. D’Orsi CJ SE, et al. ACR BI-RADS® Atlas, Breast Imaging Reporting and Data System. Reston, VA, American College of Radiology. 2013
14. Andreotti RF, Timmerman D, Strachowski LM, et al. (2020) O-RADS US Risk Stratification and Management System: A Consensus Guideline from the ACR Ovarian-Adnexal Reporting and Data System Committee. *Radiology* 294:168–185. 10.1148/radiol.2019191150 [PubMed: 31687921]

15. Burnside ES, Sickles EA, Bassett LW, et al. (2009) The ACR BI-RADS experience: learning from history. *J Am Coll Radiol JACR* 6:851–860. 10.1016/j.jacr.2009.07.023 [PubMed: 19945040]
16. Chhatwal J, Alagoz O, Lindstrom MJ, et al. (2009) A logistic regression model based on the national mammography database format to aid breast cancer diagnosis. *AJR Am J Roentgenol* 192:1117–1127. 10.2214/AJR.07.3345 [PubMed: 19304723]
17. Lee B, Whitehead MT (2017) Radiology Reports: What YOU Think You're Saying and What THEY Think You're Saying. *Curr Probl Diagn Radiol* 46:186–195. 10.1067/j.cpradiol.2016.11.005 [PubMed: 28069356]
18. Magnetta MJ, Donovan AL, Jacobs BL, et al. (2018) Evidence-Based Reporting: A Method to Optimize Prostate MRI Communications With Referring Physicians. *AJR Am J Roentgenol* 210:108–112. 10.2214/AJR.17.18260 [PubMed: 29091009]
19. Wibmer A, Vargas HA, Sosa R, et al. (2014) Value of a standardized lexicon for reporting levels of diagnostic certainty in prostate MRI. *AJR Am J Roentgenol* 203:W651–657. 10.2214/AJR.14.12654 [PubMed: 25415731]
20. Franconeri A, Boos J, Fang J, et al. (2019) Adnexal mass staging CT with a disease-specific structured report compared to simple structured report. *Eur Radiol* 29:4851–4860. 10.1007/s00330-019-06037-7 [PubMed: 30820722]
21. Margolies LR, Pandey G, Horowitz ER, Mendelson DS (2016) Breast Imaging in the Era of Big Data: Structured Reporting and Data Mining. *AJR Am J Roentgenol* 206:259–264. 10.2214/AJR.15.15396 [PubMed: 26587797]
22. O-RADS MR Lexicon Categories, Terms and Definitions. <https://www.acr.org/-/media/ACR/Files/RADS/O-RADS/O-RADS-MR-Lexicon-Terms-Table-November-2020.pdf>. Accessed 31 Oct 2020
23. ISRCTN - ISRCTN51246892: MR in ovarian cancer. <http://www.isrctn.com/ISRCTN51246892>. Accessed 31 Oct 2020
24. Eisenhauer EA, Therasse P, Bogaerts J, et al. (2009) New response evaluation criteria in solid tumours: revised RECIST guideline (version 1.1). *Eur J Cancer Oxf Engl* 1990 45:228–247. 10.1016/j.ejca.2008.10.026
25. Prat JFIGO Committee on Gynecologic Oncology (2014) Staging classification for cancer of the ovary, fallopian tube, and peritoneum. *Int J Gynaecol Obstet Off Organ Int Fed Gynaecol Obstet* 124:1–5. 10.1016/j.ijgo.2013.10.001
26. Berek JS, Kehoe ST, Kumar L, Friedlander M (2018) Cancer of the ovary, fallopian tube, and peritoneum. *Int J Gynaecol Obstet Off Organ Int Fed Gynaecol Obstet* 143 Suppl 2:59–78. 10.1002/ijgo.12614
27. Eskander RN, Kauderer J, Tewari KS, et al. (2018) Correlation between Surgeon's assessment and radiographic evaluation of residual disease in women with advanced stage ovarian cancer reported to have undergone optimal surgical cytoreduction: An NRG Oncology/Gynecologic Oncology Group study. *Gynecol Oncol* 149:525–530. 10.1016/j.ygyno.2018.03.043 [PubMed: 29550184]
28. O'Neill AC, Somarouthu B, Tirumani SH, et al. (2017) Patterns and Prognostic Importance of Hepatic Involvement in Patients with Serous Ovarian Cancer: A Single-Institution Experience with 244 Patients. *Radiology* 282:160–170. 10.1148/radiol.2016152595 [PubMed: 27479640]
29. Andreotti RF, Timmerman D, Benacerraf BR, et al. (2018) Ovarian-Adnexal Reporting Lexicon for Ultrasound: A White Paper of the ACR Ovarian-Adnexal Reporting and Data System Committee. *J Am Coll Radiol JACR* 15:1415–1429. 10.1016/j.jacr.2018.07.004 [PubMed: 30149950]
30. Pannu HK, Bristow RE, Montz FJ, Fishman EK (2003) Multidetector CT of peritoneal carcinomatosis from ovarian cancer. *Radiogr Rev Publ Radiol Soc N Am Inc* 23:687–701. 10.1148/rg.233025105
31. Pannu HK, Oliphant M (2015) The subperitoneal space and peritoneal cavity: basic concepts. *Abdom Imaging* 40:2710–2722. 10.1007/s00261-015-0429-5 [PubMed: 26006061]
32. Hauptmann S, Friedrich K, Redline R, Avril S (2017) Ovarian borderline tumors in the 2014 WHO classification: evolving concepts and diagnostic criteria. *Virchows Arch Int J Pathol* 470:125–142. 10.1007/s00428-016-2040-8
33. Hansell DM, Bankier AA, MacMahon H, et al. (2008) Fleischner Society: glossary of terms for thoracic imaging. *Radiology* 246:697–722. 10.1148/radiol.2462070712 [PubMed: 18195376]



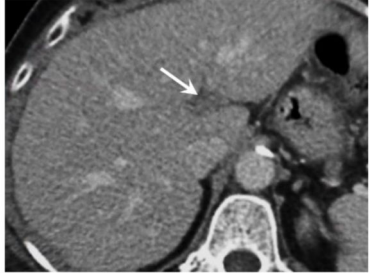
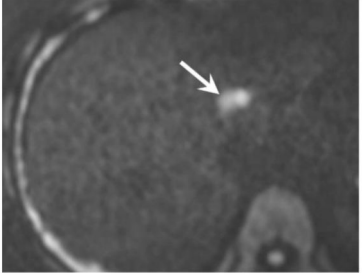
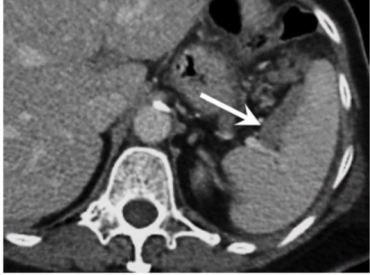
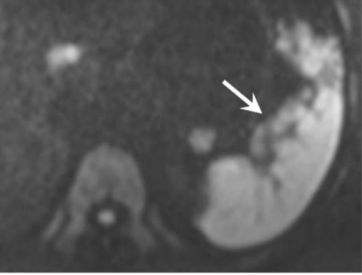


34. Vargas HA, Huang EP, Lakhman Y, et al. (2017) Radiogenomics of High-Grade Serous Ovarian Cancer: Multireader Multi-Institutional Study from the Cancer Genome Atlas Ovarian Cancer Imaging Research Group. *Radiology* 285:482–492. 10.1148/radiol.2017161870 [PubMed: 28641043]
35. (2011) NCI Dictionary of Cancer Terms. In: Natl. Cancer Inst. <https://www.cancer.gov/publications/dictionaries/cancer-terms>. Accessed 8 Aug 2019
36. Seltzer SE (1987) Analysis of the tethered-bowel sign on abdominal CT as a predictor of malignant ascites. *Gastrointest Radiol* 12:245–249 [PubMed: 3596144]
37. Tirkes T, Sandrasegaran K, Patel AA, et al. (2012) Peritoneal and retroperitoneal anatomy and its relevance for cross-sectional imaging. *Radiogr Rev Publ Radiol Soc N Am Inc* 32:437–451. 10.1148/rg.322115032
38. Brink JA, Wagner BJ (2018) Pathways for the Spread of Disease in the Abdomen and Pelvis. In: Hodler J, Kubik-Huch RA, von Schulthess GK (eds) *Diseases of the Abdomen and Pelvis 2018–2021: Diagnostic Imaging - IDKD Book*. Springer International Publishing, Cham, pp 57–65
39. Nougaret S, Addley HC, Colombo PE, et al. (2012) Ovarian carcinomatosis: how the radiologist can help plan the surgical approach. *Radiogr Rev Publ Radiol Soc N Am Inc* 32:1775–1800; discussion 1800–1803. 10.1148/rg.326125511
40. Nougaret S, Lakhman Y, Reinhold C, et al. (2016) The Wheel of the Mesentery: Imaging Spectrum of Primary and Secondary Mesenteric Neoplasms--How Can Radiologists Help Plan Treatment?: Resident and Fellow Education Feature. *Radiogr Rev Publ Radiol Soc N Am Inc* 36:412–413. 10.1148/rg.2016150186
41. Auh YH, Rubenstein WA, Markisz JA, et al. (1986) Intraperitoneal paravesical spaces: CT delineation with US correlation. *Radiology* 159:311–317. 10.1148/radiology.159.2.3515415 [PubMed: 3515415]
42. Sahdev A (2016) CT in ovarian cancer staging: how to review and report with emphasis on abdominal and pelvic disease for surgical planning. *Cancer Imaging Off Publ Int Cancer Imaging Soc* 16:19. 10.1186/s40644-016-0076-2
43. Jager GJ, Barentsz JO, Oosterhof GO, et al. (1996) Pelvic adenopathy in prostatic and urinary bladder carcinoma: MR imaging with a three-dimensional T1-weighted magnetization-prepared-rapid gradient-echo sequence. *AJR Am J Roentgenol* 167:1503–1507. 10.2214/ajr.167.6.8956585 [PubMed: 8956585]
44. Rockall AG, Sohaib SA, Harisinghani MG, et al. (2005) Diagnostic performance of nanoparticle-enhanced magnetic resonance imaging in the diagnosis of lymph node metastases in patients with endometrial and cervical cancer. *J Clin Oncol Off J Am Soc Clin Oncol* 23:2813–2821. 10.1200/JCO.2005.07.166
45. Ganeshalingam S, Koh D-M (2009) Nodal staging. *Cancer Imaging Off Publ Int Cancer Imaging Soc* 9:104–111. 10.1102/1470-7330.2009.0017
46. Shinagare AB, Davenport MS, Park H, et al. (2020) Lexicon for renal mass terms at CT and MRI: a consensus of the society of abdominal radiology disease-focused panel on renal cell carcinoma. *Abdom Radiol N Y*. 10.1007/s00261-020-02644-x
47. Go JL, Zee CS (1998) Unique CT imaging advantages. Hemorrhage and calcification. *Neuroimaging Clin N Am* 8:541–558 [PubMed: 9673312]
48. El-Sherief AH, Lau CT, Wu CC, et al. (2014) International association for the study of lung cancer (IASLC) lymph node map: radiologic review with CT illustration. *Radiogr Rev Publ Radiol Soc N Am Inc* 34:1680–1691. 10.1148/rg.346130097
49. Bazemore AW, Smucker DR (2002) Lymphadenopathy and malignancy. *Am Fam Physician* 66:2103–2110 [PubMed: 12484692]
50. Efremidou EI (2012) Surgical anatomy of the axilla. *Hell J Surg* 84:128–133. 10.1007/s13126-012-0015-z
51. McIntosh LJ, O'Neill AC, Bhanusupriya S, et al. (2017) Prognostic significance of supradiaphragmatic lymph nodes at initial presentation in patients with stage III high-grade serous ovarian cancer. *Abdom Radiol N Y* 42:2513–2520. 10.1007/s00261-017-1158-8
52. Hynninen J, Auranen A, Carpen O, et al. (2012) FDG PET/CT in staging of advanced epithelial ovarian cancer: frequency of supradiaphragmatic lymph node metastasis challenges the traditional

- pattern of disease spread. *Gynecol Oncol* 126:64–68. 10.1016/j.ygyno.2012.04.023 [PubMed: 22542580]
53. Restrepo CS, Erasó A, Ocazonez D, et al. (2008) The diaphragmatic crura and retrocrural space: normal imaging appearance, variants, and pathologic conditions. *Radiogr Rev Publ Radiol Soc N Am Inc* 28:1289–1305. 10.1148/rg.285075187
  54. Im H-J, Kim Y-I, Paeng JC, et al. (2012) Retrocrural Lymph Node Metastasis Disclosed by (18)F-FDG PET/CT: A Predictor of Supra-diaphragmatic Spread in Ovarian Cancer. *Nucl Med Mol Imaging* 46:41–47. 10.1007/s13139-011-0115-7 [PubMed: 24900031]
  55. Mirilas P, Skandalakis JE (2010) Surgical anatomy of the retroperitoneal spaces, Part III: Retroperitoneal blood vessels and lymphatics. *Am Surg* 76:139–144
  56. Lucey BC, Stuhlfaut JW, Soto JA (2005) Mesenteric lymph nodes seen at imaging: causes and significance. *Radiogr Rev Publ Radiol Soc N Am Inc* 25:351–365. 10.1148/rg.252045108
  57. Valentini V, Gambacorta MA, Barbaro B, et al. (2016) International consensus guidelines on Clinical Target Volume delineation in rectal cancer. *Radiother Oncol J Eur Soc Ther Radiol Oncol* 120:195–201. 10.1016/j.radonc.2016.07.017
  58. Bontumasi N, Jacobson JA, Caoili E, et al. (2014) Inguinal lymph nodes: size, number, and other characteristics in asymptomatic patients by CT. *Surg Radiol Anat SRA* 36:1051–1055. 10.1007/s00276-014-1255-0 [PubMed: 24435023]
  59. Akin O, Sala E, Moskowitz CS, et al. (2008) Perihepatic metastases from ovarian cancer: sensitivity and specificity of CT for the detection of metastases with and those without liver parenchymal invasion. *Radiology* 248:511–517. 10.1148/radiol.2482070371 [PubMed: 18519739]
  60. Kerr VE, Cadman E (1985) Pulmonary metastases in ovarian cancer. Analysis of 357 patients. *Cancer* 56:1209–1213. 10.1002/1097-0142(19850901)56:5<1209::aid-cncr2820560542>3.0.co;2-y [PubMed: 4016709]
  61. Shinagare AB, O'Neill AC, Cheng S, et al. (2015) Advanced High-Grade Serous Ovarian Cancer: Frequency and Timing of Thoracic Metastases and the Implications for Chest Imaging Follow-up. *Radiology* 277:733–740. 10.1148/radiol.2015142467 [PubMed: 26053310]
  62. NCCN Clinical Practice Guidelines in Oncology (NCCN Guidelines) Ovarian Cancer—ovarian.pdf.

**Key Points:**

- This reporting lexicon for CT and MR imaging provides a list of consensus-based, standardized terms and definitions for reporting sites of ovarian cancer on imaging at initial diagnosis or follow-up.
- Use of standardized terms and morphologic imaging descriptors can help improve interdisciplinary communication of disease extent and facilitate optimal patient management.
- The radiologists should identify and communicate areas of disease, including difficult to resect or potentially unresectable disease that may limit the ability to achieve optimal resection.

(A)

Location	CT	MRI
Bare area of the liver (arrows)		
Porta hepatis (arrows)		
Splenic hilum (arrows)		
Lesser sac (arrows)		

Author Manuscript

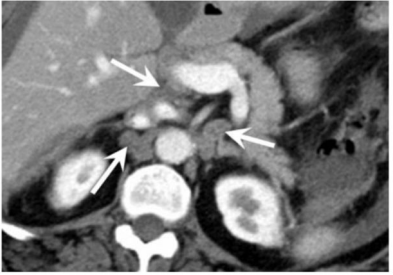


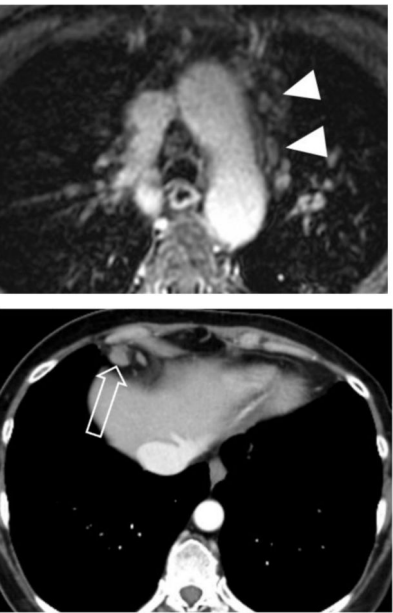
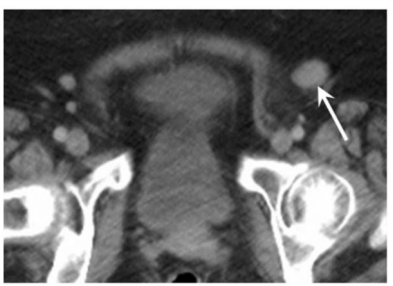
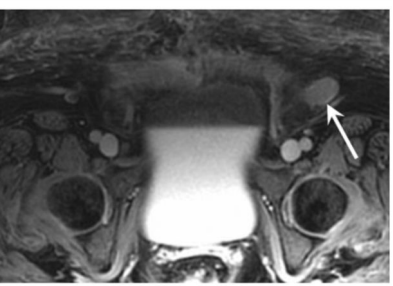
Author Manuscript

Author Manuscript

Author Manuscript



(B)

Location	CT	MRI
Upper abdominal lymph nodes (arrows)		
Lymph nodes in the chest: Supraclavicular (solid arrow), mediastinal (arrowheads), hilar, axillary, supradiaphragmatic /epiphrenic (open arrow), retrocrural (thick arrow)		
Inguinal lymph nodes (arrows)		

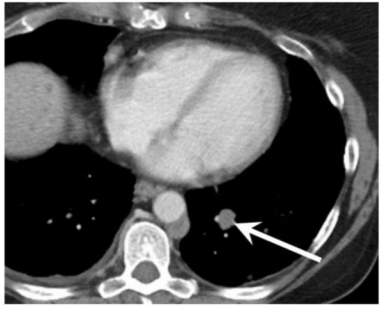
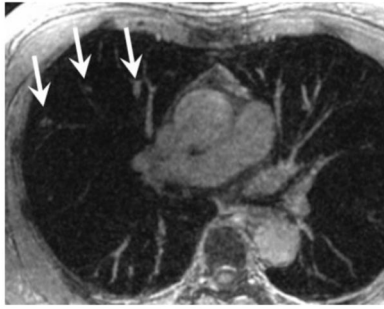

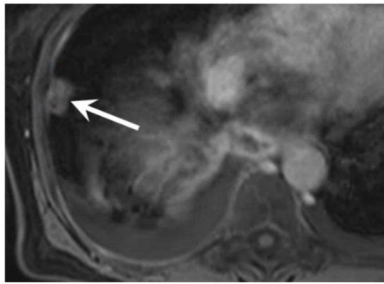
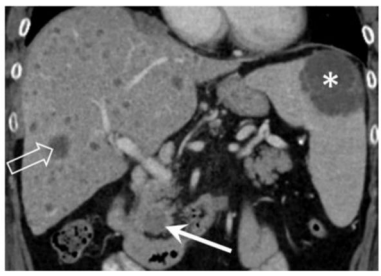
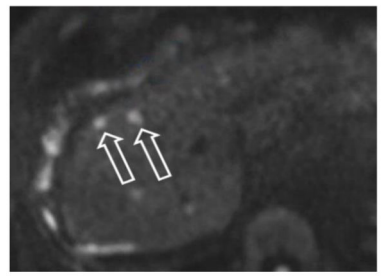
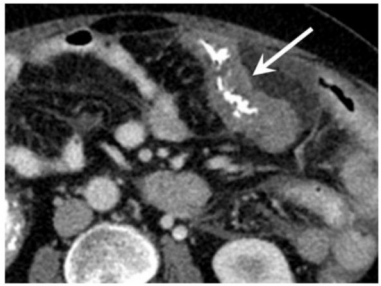
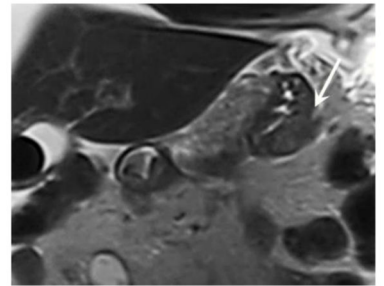
Author Manuscript

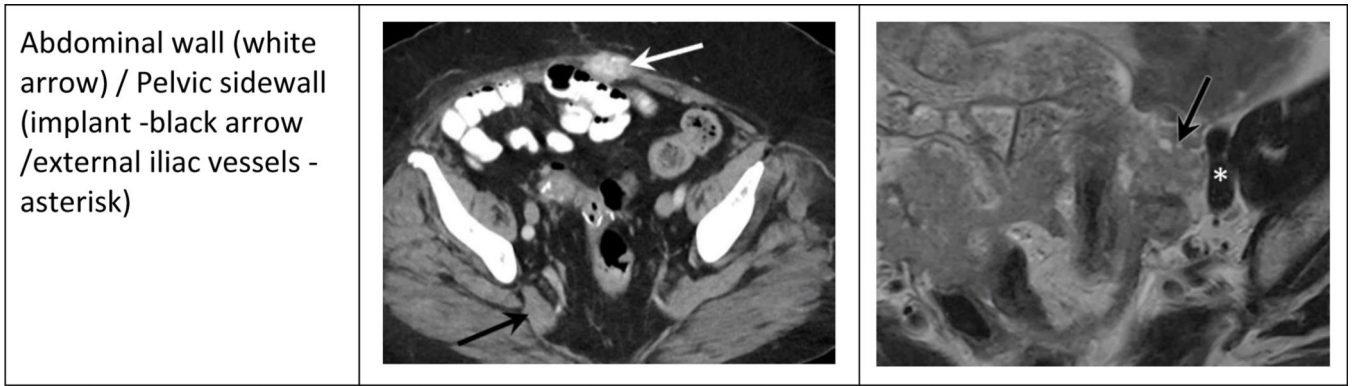
Author Manuscript

Author Manuscript

Author Manuscript

(C)

Location	CT	MRI
Pulmonary nodules (arrows)		
Pleural disease (arrows)		
Parenchymal lesions: liver (open arrow), spleen (asterisks), and pancreas (solid arrow)		
Invasion of the stomach/bowel (arrows)		



**Figure 1:** Schematic chart illustrating peritoneal sites that would present either a challenge or obstacle to resection or would upstage the disease, using lexicon descriptors for peritoneal disease (A), lymph nodes (B), and metastatic disease other than peritoneal carcinomatosis (C).

**Table 1:**

2018 FIGO Staging classification for cancer of the ovary, fallopian tube, and peritoneum (25).

FIGO Stage	Description
I	The cancer is confined to the ovaries or fallopian tubes IA: Limited to one ovary (capsule intact) or fallopian tube IB: Limited to both ovaries (capsule intact) or fallopian tubes IC: Limited to one or both ovaries plus cancer cells on ovarian or fallopian tube surface or in ascites
II	The cancer is in one or both ovaries or fallopian tubes or is primary peritoneal cancer, and has spread to other pelvic organs IIA: Tumor involved the uterus and adnexal structures IIB: Tumor involves the intraperitoneal surfaces and structures in the pelvis (i.e. bladder and bowel)
III	The cancer is in one or both ovaries or fallopian tubes or is primary peritoneal cancer, and has spread to other pelvic organs and beyond, but not outside the abdominal cavity IIIA: Tumor involves the pelvic structures and the abdominal/pelvic retroperitoneal lymph nodes, without macroscopic visible tumor outside of the pelvis IIIB: Tumor involves structures outside of the pelvis (<2cm); +/- retroperitoneal lymph nodes IIIC: Tumor involves structures outside the pelvis (>2cm) including surface implants along abdominal organs, without parenchymal involvement; +/- involvement of retroperitoneal lymph nodes
IV	Distal metastasis disease excluding peritoneal disease IVA: Pleural effusion with positive cytology IVB: Parenchymal metastases and metastases to extra-abdominal organs (including inguinal lymph nodes and thoracic lymph nodes)

**Table 2.**

Survey participants by specialty, experience and practice location (n=67).

	Number of participants	Percentage
<b>Specialty</b>		
Radiology	51	76.1
Gynecologic Oncology	16	23.9
<b>Years in Practice</b>		
<5 years	11	16.4
5–9 years	14	20.9
10–14 years	19	28.4
15 years	23	34.3
<b>Practice Location</b>		
North America	54	80.6
Europe	12	17.9
Asia	1	1.5

Author Manuscript

Author Manuscript

Author Manuscript

Author Manuscript

**Table 3:**

List of reporting lexicon terms for ovarian cancer staging.

<b>1. General Terminology</b>		
<b>Term</b>	<b>Definition</b>	<b>Additional info/ Comments</b>
Size [4, 24]	- Axial bi-dimensional measurements for non-nodal lesions - Short axis measurement in axial plane for lymph nodes	- Ensure that the short axis measurement is at 90 degrees to the long axis - These measurements can be used for RECIST1.1 target lesion measurement
Adnexa [22, 29]	- The anatomic region of the ovaries, fallopian tubes and their supporting structures (broad ligament, vessels)	
Lesion [22, 29]	- A finding, that is judged by imaging to be not part of normal physiology	
Carcinomatosis [30, 31]	- Metastatic disease involving the peritoneum	
Implant [32]	- Lesion on the serosa or surface of an organ, but many invade into the underlying organ tissue	- May also be referred to as a deposit
Parenchymal lesion [28]	- Space occupying lesions within the solid organs or replacing soft tissue of the organ via hematogenous spread; not direct invasion from an implant	
<b>2. Adnexal Lesion Specific Terminology</b>		
<b>Term</b>	<b>Definition</b>	<b>Additional info/ Comments</b>
Unilateral [22, 29]	- Affecting one side of the body	
Bilateral [22, 29]	- Affecting both sides of the body	If multiple/bilateral, mention the features of up to two largest masses, preferably the largest on each side
Adnexal Lesion [22, 29]	- An abnormality involving the ovaries, fallopian tubes, broad ligament, or vessels of the adnexa	Can be used instead of the term "mass"
Cystic [22, 29]	- Portion of an adnexal lesion which is fluid	
Solid component [22, 29]	- A component of an adnexal lesion which is not fluid;	
i. Solid tissue [22]	- A solid component that typically demonstrates enhancement AND that conforms to the following morphology: - Papillary projection - Mural nodule - Irregular septation - Solid enhancing part of an adnexal lesion	Does NOT include normal ovarian stroma
ii. Other solid components [22]	- Includes smooth septations/walls (thin or thick), debris, fat, calcification or clot	
<b>3. Peritoneal carcinomatosis Specific Terminology</b>		
<b>Term</b>	<b>Definition</b>	<b>Additional info/ Comments</b>
<b>Morphology</b>		
i. Nodule [33]	- Rounded or irregular tissue, well or poorly defined, measuring 3 cm or less in longest dimension ( ≤ 3cm)	
ii. Mass [33]	- Rounded or irregular tissue, well or poorly defined, measuring greater than 3 cm (>3cm) in longest dimension	
iii. Stranding or infiltration [34]	- Hazy appearance of the peritoneal, omental or mesenteric fat	- This may also be seen as a result of prior surgery or inflammation or even ascites - Occasionally the term 'haziness' is used but it is not recommended

1. General Terminology		
Term	Definition	Additional info/ Comments
iv. Omental cake [34]	- Confluent omental involvement by the carcinomatosis	
v. Peritoneal thickening or nodularity [34]	- Smooth or nodular/irregular thickening of peritoneal lining	
vi. Invasion [35]	- Growth or direct extension/penetration into surrounding organs or tissues	- Sometimes peritoneal disease may invade an adjacent organ such as liver, spleen, bowel loop or abdominal wall
vii. Tethering [36]	- Binding or attachment between bowel and/or other organs	- Tethering could be a result of tumor involvement, postsurgical adhesions or an infectious or inflammatory process involving the peritoneum
<b>Locations</b>		
i. Peritoneal cavity <sup>^</sup> [4, 31, 37]	- The potential space between the parietal and visceral peritoneum that envelops the abdominal organs	- Peritoneum includes the peritoneal lining, mesentery and omentum
ii. *Subdiaphragmatic [37]	- Peritoneal cavity along the surface of the diaphragm, and consists of right and left subdiaphragmatic space	- Best evaluated on multiplanar CT or MRI
iii. Perihepatic [4, 37]	- Tumor in close approximation with the liver, including the gastrohepatic ligament, porta hepatis or peri-portal region, right or part of left subdiaphragmatic space, right or part of left subhepatic space, lesser sac, falciform ligament, left intersegmental fissure, gallbladder fossa, Morrison's pouch	- There is an overlap between subdiaphragmatic and perihepatic/perisplenic locations: Even if perihepatic or perisplenic terms are used, presence of subdiaphragmatic disease should be clearly indicated in the radiology report
iv. Perisplenic [4, 37]	- Tumor in close approximation with the spleen, and this space includes part of left subdiaphragmatic and left subhepatic space, gastrosplenic, splenocolic ligament, splenic hilum	
v. *Lesser sac [4, 37]	- A peritoneal space that extends through the foramen of Winslow posterior to the stomach, anterior to the pancreas	
vi. Omentum [4, 37]	- Fat between a double layer of peritoneum that extends from the stomach and duodenal bulb to adjacent organs	- Greater omentum: attached to the stomach and hangs like an apron from the transverse colon - Lesser omentum: made of two contiguous components called the gastrohepatic and hepatoduodenal ligaments, attaches the stomach and duodenal bulb to the liver
vii. *Gastrocolic ligament [6]	- Refers to the space between the anterior stomach and the transverse colon	
viii. Gastrosplenic ligament [38]	- The ligament that connects the superior third of the greater curvature of the stomach to the splenic hilum	
ix. *Mesenteric [4, 6, 39, 40]	- Mesentery refers to a double-fold of peritoneum that attaches the bowel to the posterior abdominal wall, and contains soft tissue and vessels	- Mesenteric involvement indicates tumor deposit(s) in the mesentery. Mesenteric involvement is suspected in case of mesenteric retraction, nodules or tethering of small bowel loops
x. Serosal [4, 31]	- Visceral peritoneum surrounding bowel or solid organs	
xi. Paracolic gutters/posterior peritoneal lining [4, 37]	- The space located lateral to the peritoneal reflections of the left and right sides of the colon	- The right paracolic gutter is larger than the left and communicates freely with the right subdiaphragmatic space - The connection between the left paracolic gutter and the left subdiaphragmatic space is partially limited by the splenocolic ligament - Both the right and left paracolic gutters communicate with the pelvic spaces and serve as routes of peritoneal disease spread

1. General Terminology		
Term	Definition	Additional info/ Comments
xii. Paravesical [41]	- Spaces adjacent to the bladder, including anterior paravesical, supramesical, vesicouterine spaces and medial and lateral inguinal fossae	
xiii. *Pelvic sidewall [4, 42]	- Pelvic sidewall includes to muscular sidewall (defined as the obturator internus, piriformis, or levator muscles) and the iliac vessels and nerves	- Pelvic sidewall invasion should be suspected if the disease is less than 3 mm from the muscular sidewall (defined as the obturator internus, piriformis, or levator muscles), ureteral involvement/hydronephrosis and/or there is involvement or encasement of the iliac vessels
xiv. Pouch of Douglas/ cul-de-sac [37]	- Retrouterine space between the rectum and posterior wall of the uterus, and is the most dependent portion of the peritoneal cavity	
4. Lymph Node Specific Terminology		
Term	Definition	Additional info/ Comments
Morphology		
Oval	- The long axis of the lymph node is greater in diameter than the short axis	- Both benign and malignant nodes may be oval in morphology
Round	- The long axis and short axis are similar	- Ratio of short to long axis >0.8 is considered likely to be metastatic for nodes between 8 and 10 mm short axis [43, 44]
Irregular/ spiculated	- Jagged or saw-tooth like contour of node	- Associated with metastatic nodal disease
Fatty hilum	- Preservation of central fat within a node with thin, regular rim of nodal tissue	- Considered a feature of a benign lymph node
Heterogeneous [45]	- Inhomogeneous or variable attenuation/signal intensity or enhancement	- Associated with metastatic nodal disease
Necrotic appearance [45, 46]	- Presence of non-enhancing components of variable CT attenuation or MRI signal intensity are identified	- This feature is non-specific and may be seen with malignancy or in certain benign conditions such as abscess, tuberculosis or fungal infection - "Necrosis" is a pathology term and cannot be diagnosed with certainty at imaging; necrosis, fibrosis and cystic change can appear similar on imaging
Calcification [45, 47]	- Presence of calcium-containing deposits within tissue	- May be related to tumor subtype (low-grade or borderline tumors) - May be seen in other cancers such as colorectal or bladder cancers, as well as granulomatous disease or treated cancer
Location		
*Thoracic lymph nodes		
i. Supraclavicular [48, 49]	- Located between the lower margin of the cricoid cartilage to clavicles bilaterally and, in the midline, the upper border of the manubrium	- 0.5 cm short axis dimension or suspicious features
ii. Mediastinal [48]	- Located centrally from the level of apex of both lungs to diaphragm - Includes right/left upper and lower paratracheal, prevascular, retrotracheal, aortopulmonary window, subcarinal, paraesophageal, and pulmonary ligament, right/left hilar and segmental nodes	- 1 cm short axis dimension or suspicious features
iii. Hilar [48]	- Located immediately adjacent to the mainstem bronchus and hilar vessels, including the proximal portions of the pulmonary veins and main pulmonary artery	- 1 cm short axis dimension or suspicious features
iv. Axillary [50]	- Located in a space confined by muscles/fascial layers which is anteriorly bound by pectoralis major muscle, medially by the serratus anterior and	- 1 cm short axis dimension or suspicious features



<b>1. General Terminology</b>		
<b>Term</b>	<b>Definition</b>	<b>Additional info/ Comments</b>
	posteriorly by the subscapularis and latissimus dorsi muscles	
v. Internal mammary	- Located adjacent to the junction of the ribs and sternum along the internal mammary vessels	- 0.5 cm short-axis dimension or suspicious features
vi. Supradiaphragmatic / epiphrenic [4, 51, 52]	- Located just above the diaphragm, including pre and paracardiac or cardiophrenic lymph nodes	- 0.5 cm short-axis dimension or suspicious features - definition of supradiaphragmatic lymphadenopathy
vii. Retrocrural [53, 54]	- Located within the small triangular area within the most inferior posterior mediastinum and is bordered by the diaphragmatic crura	- 0.5 cm short axis dimension or suspicious features - Retrocrural lymph nodes drain the posterior part of the diaphragm and communicate with the posterior mediastinal nodes and para-aortic nodes in the upper abdomen
*Upper abdominal [4, 6]	- Lymph nodes above the renal artery, and includes gastrohepatic, peripancreatic, celiac axis, portacaval and periportal lymph nodes	- 1 cm short axis dimension or suspicious features, except for portocaval nodes 1.5cm short axis dimension
Abdominal retroperitoneal [6, 55]	- Nodal stations deep to the peritoneal lining, surrounding the aorta and the inferior vena cava, below the level of the diaphragm.	- 0.8 cm short axis dimension or suspicious features - Pelvic lymph nodes, below the level of the aortic bifurcation, should be described separately from para-aortic lymph nodes
Mesenteric [56]	- Located at the mesenteric root and throughout the mesentery	- 0.8 cm short axis dimension or suspicious features
Pelvic retroperitoneal (excludes inguinal) [57]	- Located deep to the peritoneal lining below the bifurcation of the aorta, including the common iliac, external iliac, and internal iliac lymph nodes	- 0.8 cm short axis dimension or suspicious features - Pelvic lymph nodes should be described separately from the abdominal lymph nodes
*Inguinal [58]	- Located distal to the inguinal ligament. Superficial: Within the femoral triangle (bordered by the inguinal ligament, sartorius, and adductor longus). Deep: Located medial to the femoral vasculature	- 1.5 cm short axis dimension or suspicious features
<b>5. Metastatic disease other than peritoneal carcinomatosis</b>		
<b>Term</b>	<b>Definition</b>	<b>Additional info/ Comments</b>
*Hepatic parenchymal [4, 28, 59]	- Space occupying metastatic disease involving the hepatic parenchyma	- Hepatic parenchymal metastasis indicates hematogenous liver involvement and should be distinguished from direct invasion of liver parenchyma by perihepatic peritoneal implants that may have ill-defined, irregular or obliterated lesion-liver interface
*Splenic parenchymal [4]	- Space occupying metastatic disease involving the splenic parenchyma	- Similar to hepatic metastasis, splenic parenchymal disease indicates hematogenous spread and should be distinguished from splenic invasion by surrounding peritoneal disease
*Bowel/Stomach <sup>^</sup>	- Tumor spread to the wall of the gastrointestinal tract	- A description of gastrointestinal tumor involvement should specify which segments are involved
*Pulmonary [60, 61]	- Tumor spread to the lung in the form of nodules/ masses or lymphangitic spread	
*Pleural [61, 62]	- Presence of metastatic disease within the pleural space	
*Other visceral <sup>^</sup>	- Space occupying metastatic disease of other sites such as pancreas, adrenal, kidneys, bones and brain	- Involvement of other sites such as pancreas, adrenal, kidneys, bones and brain is rare
*Abdominal wall [4]	- Spread to the subcutaneous tissues and muscle of the abdominal wall	
<b>6. Fluid Specific Terminology</b>		

1. General Terminology		
Term	Definition	Additional info/ Comments
Pleural effusion [4]	- Non-physiologic fluid in the pleural space	- Pleural effusion is not considered metastatic unless accompanied by pleural nodularity or cytological proven to be metastatic
Pleural effusion volume	- Small/large or small/medium/large	- Pleural effusion volume is subjectively assessed
Ascites [4, 29]	- Non-physiologic fluid in the peritoneal cavity.	- The presence of ascites does not indicate peritoneal disease without other imaging findings of peritoneal involvement such as peritoneal nodularity, omental cake or nodular peritoneal thickening, or cytologic confirmation of peritoneal disease
Ascites volume	- Small/large or small/medium/large	- Ascites volume is subjectively assessed

<sup>^</sup> Added after the survey from survey participant comments

\* Potential sites of difficult to resect or unresectable disease