

UC Davis

UC Davis Previously Published Works

Title

Immunohistochemical Localization of Bone Morphogenetic Proteins (BMPs) and their Receptors in Solitary and Multiple Human Osteochondromas

Permalink

<https://escholarship.org/uc/item/3sw899c5>

Journal

Journal of Histochemistry & Cytochemistry, 62(7)

ISSN

0022-1554

Authors

Cuellar, Araceli
Inui, Atsuyuki
James, Michelle A
[et al.](#)

Publication Date

2014-07-01

DOI

10.1369/0022155414535781

Peer reviewed

Immunohistochemical Localization of Bone Morphogenetic Proteins (BMPs) and their Receptors in Solitary and Multiple Human Osteochondromas

Araceli Cuellar, Atsuyuki Inui, Michelle A. James, Dariusz Borys and A Hari Reddi
J Histochem Cytochem published online 30 April 2014
DOI: 10.1369/0022155414535781

The online version of this article can be found at:
<http://jhc.sagepub.com/content/early/2014/04/29/0022155414535781.citation>

Published by:



<http://www.sagepublications.com>

On behalf of:



Official Journal of The Histochemical Society

Additional services and information for *Journal of Histochemistry & Cytochemistry* can be found at:

Email Alerts: <http://jhc.sagepub.com/cgi/alerts>

Subscriptions: <http://jhc.sagepub.com/subscriptions>

Reprints: <http://www.sagepub.com/journalsReprints.nav>

Permissions: <http://www.sagepub.com/journalsPermissions.nav>

>> [Accepted Manuscript](#) - Apr 30, 2014

[What is This?](#)

Immunohistochemical Localization of Bone Morphogenetic Proteins (BMPs) and their Receptors in Solitary and Multiple Human Osteochondromas

Araceli Cuellar, Atsuyuki Inui, Michelle A. James, Dariusz Borys, and A. Hari Reddi

Lawrence Ellison Center for Tissue Regeneration and Repair (AC, AI, AHR), Department of Orthopaedic Surgery (AC, AI, AHR) and Department of Pathology (DB) University of California Davis, Sacramento, California and Shriners Hospital for Children, Northern California (MAJ), Sacramento, California

Address for Correspondence:

A. Hari Reddi, PhD

Research Building I, Room 2000

4635 Second Avenue

Sacramento, CA 95817

Phone: 916-734-5749

Fax: 916-734-5750

Email: ahreddi@ucdavis.edu

#

Abstract:

The expression of bone morphogenetic proteins (BMPs) and their cognate receptors (BMPRs) in osteochondromas has not been investigated. We determined the immunohistochemical localization and distribution of BMPs 2/4, 6 and 7, and BMP receptors BMPR-1A, BMPR-1B and BMPR-2, signal transducing proteins phosphorylated Smads 1/5/8 and BMP antagonist noggin in the cartilaginous cap of solitary (SO) and multiple (MO) human osteochondromas and compared these with bovine growth plate and articular cartilage. Distribution and localization patterns for BMP-6, BMP-7, BMPR-1A and BMPR-2 were similar between the cartilaginous cap and the growth plate. BMP-2/4 and BMPR-1B were present throughout the growth plate. However, BMP-2/4 and phosphorylated Smads 1/5/8 were mainly detected in proliferating chondrocytes of the cartilaginous cap. Also, BMPR-1B was found in hypertrophic chondrocytes of SO and proliferating chondrocytes of MO. Noggin was observed in resting chondrocytes and to a lesser extent in clustered proliferating chondrocytes in SO. On the other hand, noggin in MO was observed in proliferating chondrocytes. Since BMPs can stimulate proliferation and hypertrophic differentiation of chondrocytes, these findings suggest that there is an imbalance of BMP-2/4 and noggin interactions that may lead to abnormal regulation of chondrocyte proliferation and differentiation in the cartilaginous cap of human osteochondromas.

Keywords: bone morphogenetic protein, solitary osteochondroma, multiple osteochondroma, immunohistochemistry, localization, distribution

INTRODUCTION

Bone morphogenetic proteins (BMPs) are multifunctional proteins involved in the morphogenesis of a variety of tissues including bone and cartilage (Reddi, 2001). BMPs exert their effects by binding to both serine/threonine kinase receptors BMP type 1 (BMPR-1) and BMP type 2 (BMPR-2), forming a signal-transducing complex (Reddi, 2001, Reddi, 1997). BMPR-1 phosphorylates signal transduction proteins Smad 1, 5 or 8 (R-Smads) which interact with Smad 4 to form a complex. The complex enters the nucleus and activates the transcriptional machinery for BMP-response genes (Kawabata et al., 1998, Reddi, 1998). BMP-2, -4, -6, and -7 induce bone and cartilage formation *in vivo* while BMP-2, -4 and -7 are shown to regulate chondrocyte growth and maturation *in vitro* (Fujii et al., 1999, Wozney and Rosen, 1998, Kawabata et al., 1998). BMPs are the critical regulators of the different steps in progenitor/stem cell proliferation and differentiation into cartilage and bone formation during mammalian endochondral ossification. During endochondral ossification chondrocytes exit a resting stage and enter a proliferating stage where they undergo several rounds of cell division. As they exit the cell cycle, chondrocytes undergo hypertrophy in which they increase secretion of their matrix as they enlarge and mature. Hypertrophic chondrocytes further differentiate to mineralize their surrounding matrix; eventually undergoing apoptosis (Kronenberg, 2003, Burdan et al., 2009). Osteochondromas, also called exostoses, are dysplastic cartilaginous bony outgrowths arising from the surface of endochondral bones. An osteochondroma resembles a displaced growth plate as its cartilaginous cap recapitulates all of the zones of the mammalian epiphyseal growth plate during endochondral bone development (Dorfman, 1998). The spatial distribution of chondrocytes is irregular, containing chondrocytes in clusters and in lacunae, and nuclear atypia may be present (Vigorita, 2008, Du et al., 2011). In nearly all cases, orderly cartilaginous

#

columnar progression similar to that of a growth plate is apparent towards the base of the osteochondroma where endochondral ossification takes place (Vigorita, 2008, Unni, 1996). The appearance of the cartilage cap is hypocellular; chondrocytes appear enlarged and hyperchromatic (Unni, 1996). Proliferative chondrocytes seem to be larger in osteochondromas but less numerous than in a normal mammalian growth plate and hypertrophic chondrocytes can be found within the calcified cartilaginous matrix (Benoist-Lasselin et al., 2006). An osteochondroma continues to grow until skeletal maturation is reached. The spectrum of osteochondromas ranges from single lesions (solitary osteochondroma, SO) to multiple lesions (multiple osteochondroma, MO). Multiple hereditary exostoses (MHE) is an autosomal dominant trait characterized by a high incidence of osteochondromas and skeletal deformities (Jennes et al., 2009). Clinical manifestations of MHE lead to pain, functional problems and morbidity due to the entrapment of blood vessels, nerves and tendons (Bovee, 2008). The possibility of transformation into a low-grade chondrosarcoma increases to 5% in MHE (Bové et al., 2000). Fibrodysplasia ossificans progressiva (FOP)—caused by abnormal activation of a BMPR-1—is a rare condition characterized by congenital skeletal malformations and progressive heterotopic ossification of skeletal muscle and soft connective tissue (Kaplan et al., 2008). Like MHE, patients with FOP experience a high incidence of osteochondroma formation (Deirmengian et al., 2008). This similarity leads to suggest that BMP signaling may play a role in the formation of osteochondromas.

Heparan sulfate proteoglycans (HSPGs) are known to bind to BMPs and are involved in BMP-mediated morphogenesis by regulating their gradient formation and activity (Jiao et al., 2007, Reddi, 1997). Extracellular and membrane-bound HSPGs sequester BMPs at the cell surface and move BMPs across cells through restricted diffusion (Jiao et al., 2007, Yan and Lin, 2009). In

#

the absence of HSPGs, the spatial range of BMP signaling was found to be dysregulated during limb development (Matsumoto et al., 2010b); demonstrating a regulator role for HSPGs with regards to BMP signaling activity. Heparan sulfate-deficient cells were capable of transducing BMP signals in the limb bud but the tight spatial regulation of BMP signaling—as seen in wild-type cells—was disrupted (Matsumoto et al., 2010b). Mutations in the *exostosin1* (EXT1) and *exostosin2* (EXT2) genes, which encode glycosyltransferases involved in the chain elongation step of heparan sulfate (HS) biosynthesis, are strongly associated with MHE (Nadanaka and Kitagawa, 2008, Benoist-Lasselin et al., 2006, Hameetman et al., 2007, Reijnders et al., 2010). Inactivation mutations in either EXT1 or EXT2 disrupt the function of the EXT1/2 complex, leading to abnormal elongation of HS chains (Okada et al., 2010). Consequently, intracellular accumulation of HSPGs in the Golgi apparatus, diminished and abnormal distribution of HSPGs has been reported in osteochondromas (Hameetman et al., 2007, Hecht et al., 2002). Abnormal distribution of HSPGs seems to maintain the proliferative capacity of chondrocytes in osteochondromas (Benoist-Lasselin et al., 2006, Hameetman et al., 2007). Thus, abnormal chondrocyte proliferation and differentiation have been proposed as a pathogenesis of MHE. Since HS-binding BMPs are multifunctional proteins involved in the regulation of chondrocyte proliferation and differentiation during mammalian endochondral bone development, their role in osteochondroma formation is intriguing.

Insight into the expression of BMPs and BMPRs in osteochondromas is limited. BMP-2 and BMPRII mRNA were localized in chondrocyte-like cells in the cartilaginous matrix of osteochondromas (Nakase et al., 2001). Phosphorylated R-Smads were detected in osteochondromas, indicating BMP signaling is functional (Reijnders et al., 2010). Nonetheless, the role of BMP signaling in osteochondroma pathogenesis has yet to be elucidated. In the

#

present study, we assessed immunohistochemically the localization and distribution of BMP-2/4, -6, and -7, noggin and receptors BMPR-1A, BMPR-1B and BMPR-2 in the cartilaginous cap of solitary and multiple human osteochondromas. To receive insight into a potential alteration in BMP signaling in the cartilaginous cap of human osteochondromas signal transducing proteins phosphorylated Smads 1/5/8 (p-Smads1/5/8) were also investigated. Since osteochondromas histologically resemble the mammalian growth plate, we compared their distribution to that observed in bovine tibial growth plates and articular cartilage.

MATERIALS AND METHODS

Human and Animal Samples

All cartilaginous caps from human osteochondroma samples were obtained from MO patients (n=10) and SO patients (n=9) undergoing surgical resections following medical advice after informed consent in accordance to our Institutional Review Board. Articular cartilage and tibial growth plates of stifle (knee) joints from 3-month-old calves were obtained from a local abattoir and harvested. All samples were fixed in 4% paraformaldehyde, decalcified in Morse solution (10% sodium citrate, 20% formic acid), embedded in paraffin and sectioned (5 μ m thick). To characterize the gross morphology, paraffin sections (5 μ m thick) were stained with Harris hematoxylin solution and counterstained in eosin Y solution or analyzed by immunohistochemistry.

Antibodies

Goat polyclonal antibodies against human BMP-2/4, BMP-6 and BMPR-1A, goat monoclonal antibody against human BMPR-2 and mouse monoclonal antibody against human BMPR-1B were purchased from R&D Systems (Minneapolis, MN). Rabbit polyclonal antibodies against

≠

human BMP-7 and noggin were purchased from Abcam (Cambridge, MA). Rabbit polyclonal antibodies against Ki-67 and Collagen X were purchased from Bioss (Woburn, MA). Rabbit polyclonal antibody against phosphoSmad1/5/8 and mouse monoclonal antibody against human type II collagen were purchased from EMD Millipore (Billerica, MA). Purchased antibodies were used according to manufacturer's recommendations.

Immunohistochemistry

Immunohistochemistry was performed using a R.T.U. Vectastain Universal Quick Kit (Vector Laboratories; Burlingame, CA). After deparaffinization and hydration, endogenous peroxidase was blocked with 3% H₂O₂ for 10 min. Nonspecific reactions were blocked using 5% normal horse serum for 20 min at room temperature. Samples were incubated in 10 mM sodium citrate buffer (pH 6.0) and heated in a water bath at 60°C for 20 min to retrieve antigen. Samples were incubated with the appropriate diluted primary antibodies at room temperature for 2 hours in a humidified chamber. Primary antibodies were diluted in PBS as follows: anti-BMP-7, -collagen X, -Ki-67 and -noggin, 1:200; anti-BMP-6, -BMPR-1A, -BMPR-1B and -BMPR-2, 1:100; anti-phosphoSmad 1/5/8, 1:75; anti-BMP-2/4, -type II collagen, 1:50. Incubation with a biotinylated pan-specific universal secondary antibody was performed for 20 min at room temperature, followed by incubation in a streptavidin/peroxidase complex reaction for 10 min at room temperature. Color was developed using ImmPACT DAB Peroxidase Substrate (Vector Laboratories; Burlingame, CA). Some sections were counterstained with 1% Alcian Blue solution in 0.1N HCl. As a negative control, normal rabbit IgG (Santa Cruz Biotechnology; Santa Cruz, CA) was used instead of the primary antibodies. Section images were captured using a Nikon Eclipse TE2000-E microscope and Nikon NIS Elements Imaging Software (Melville, NY).

≠

Data Analysis

For immunohistochemical analysis, negatively and positively stained chondrocytes of the cartilaginous cap of osteochondromas were counted. To determine the positive index, the number of positively stained chondrocytes were divided by the total number of counted chondrocytes and multiplied by 100 to calculate the percentage. We used unpaired Student's t-test to evaluate the statistical significance of the experiments. All values were expressed as mean \pm standard deviation. Differences were considered significant at $p > 0.05$.

RESULTS

Osteochondroma

Cartilaginous cap of osteochondromas displayed visible chondrocyte disorganization compared to a typical mammalian growth plate, with the presence of proliferating chondrocytes in clusters rather than columns. Ossification among chondrocyte clusters was also observed. Nearly all cartilaginous caps of SO samples collected were characterized by a growth plate-like morphology with large hypertrophic chondrocytes observed near the ossification zone (Figure 1A). More apparent fibrous tissue was observed surrounding the cartilaginous tissue in MO compared to SO. The morphology of the cartilaginous caps of MO varied among samples collected. However, mainly all samples demonstrated an abundant amount of cartilage matrix consisting of randomly dispersed chondrocytes (Figure 1B). For this reason, classifying chondrocytes as resting, proliferating or hypertrophic within the cartilaginous cap based on morphology alone was challenging at times. To better classify the chondrocyte subtypes present in the cartilaginous cap of osteochondromas, type II collagen, Ki-67 and type X collagen were analyzed (Figure 2). Type II collagen is expressed by chondrocytes. Ki-67 is used as a marker of

#

cell proliferation and is absent in resting (G_0) cells. Type X collagen is expressed by hypertrophic chondrocytes during endochondral ossification. Along with characteristic morphology features, proliferating chondrocytes in the cartilaginous cap of osteochondromas were classified as positive for type II collagen and Ki-67 and negative for type X collagen whereas hypertrophic chondrocytes were classified as negative for type II collagen and Ki-67 and positive for type X collagen. Chondrocytes positive for type II collagen and negative for Ki-67 and type X collagen were classified as resting chondrocytes. Chondrocytes are seldom well preserved and fixation of cartilage usually causes a degree of shrinkage between the chondrocyte cytoplasm and the lacunar wall (Hunziker et al., 1982). Lacunae appear to be more prominent and the shrinkage makes it difficult to make out the details of these cells with the light microscope. The chondrocytes, shrunken with tissue preparation, give the appearance of a densely stained atypical nucleus within lacunae. Thus, staining of chondrocytes occasionally appeared to be nuclear-like. BMP-2/4 was detected in resting and proliferating chondrocytes (Figure 2E). Cytoplasmic staining for BMP-6 was observed in resting chondrocytes; proliferating chondrocytes demonstrated nuclear-like staining (Figure 2F). However, staining for BMP-6 was weak in MO compared to SO. BMP-7 was observed in resting and proliferating chondrocytes (Figure 2G). Cytoplasmic staining for BMP-7 was more visible in some proliferating chondrocytes. Rare weak staining for BMP-1A was observed in small resting and proliferating chondrocytes (Figure 2H). Membranous staining for BMP-1B was detected in hypertrophic chondrocytes of SO (Figure 2I) while enlarged and proliferating chondrocytes in MO displayed cytoplasmic and nuclear-like staining (Figure 2J). Cytoplasmic staining for BMP-2 was weakly observed in proliferating chondrocytes (Figure 2K). Also, BMP-2 staining was detected in calcifying hypertrophic chondrocytes in SO. In SO, noggin was observed mostly in resting

#

chondrocytes but was also detected at times in clustered proliferating chondrocytes. On the other hand, noggin was observed mainly in proliferating chondrocytes in MO where staining appeared to be more nuclear-like than cytoplasmic due to prominent lacunae and cytoplasm shrinkage (Figure 2L). p-Smads1/5/8 were observed in proliferating chondrocytes (Figure 2M) and were detected weakly in hypertrophic chondrocytes. A summary of the localization and distribution of BMPs, BMPR, p-Smads1/5/8 and noggin among the different tissues studied is presented in Table 1. Immunohistochemistry for BMPs and BMPRs allowed us to determine the positive index for MO and SO. The positive index values for different entities are presented in Table 2. The positive index values of cartilaginous cap of osteochondromas from MO patients revealed no significant difference compared with values obtained from SO patients.

Growth Plate

The bovine growth plate served as a model of a typical mammalian growth plate as it demonstrated typical columnar arrangement of chondrocytes into resting, proliferative and hypertrophic zones; showing orderly columnar progression towards endochondral ossification (Figure 3A). Type II collagen was observed in resting zone chondrocytes. Positive staining for type II collagen and Ki-67 was observed in proliferative zone chondrocytes whereas hypertrophic zone chondrocytes stained positive for type X collagen. Shrinkage between the chondrocyte cytoplasm and the lacunar wall was noted; thus, the appearance of chondrocytes as a densely stained atypical nucleus within lacunae was present. BMP-2/4 was observed in resting, proliferative and hypertrophic zone chondrocytes, but staining of the cytoplasm was more apparent in proliferating chondrocytes (Figure 3E). The presence of BMP-6 was detected in both resting and proliferative zone chondrocytes (Figure 3F); however, nuclear-like staining for BMP-6 was visible. Nuclear-like and cytoplasmic staining for BMP-7 was detected throughout the

#

growth plate with proliferative zone chondrocytes demonstrating prominent staining (Figure 3G). BMPR-1A was observed mainly in resting zone chondrocytes (Figure 3H). BMPR-1B was detected throughout the growth plate with stronger staining in the resting and hypertrophic zones (Figure 3I). Staining for BMPR-2 was weakly visible in proliferative zone chondrocytes (Figure 3J). Nuclear-like staining for noggin was observed mainly in resting zone chondrocytes and to a lesser extent in proliferating chondrocytes (Figure 3K). Staining for p-Smads1/5/8 was present in both resting and proliferating zone chondrocytes (Figure 3L).

Articular Cartilage

Bovine articular cartilage demonstrated typical organization of superficial, middle and deep zones. Zones were distinguished by cell shape; presence of elongated chondrocytes in the superficial zone and round chondrocytes in the middle and deep zones. Staining for BMP-2/4, BMP-7, BMPR-1A and BMPR-1B was detected in chondrocytes of all zones (Figure 4). Weak staining for BMP-6 was found in the superficial and middle zones (Figure 4C). Weak staining was observed for BMPR-2 in the deep zone (Figure 4G). Noggin was observed in all zones of the articular cartilage with strong staining more visible in the middle zone (Figure 4H). Detection for p-Smads1/5/8 was rare and weakly observed in the deep zone (Figure 4I).

DISCUSSION

Mammalian endochondral ossification depends on controlled proliferation, differentiation and apoptosis of chondrocytes. BMP signaling induces chondrocyte proliferation and delays the differentiation of terminal hypertrophic chondrocytes (Minina et al., 2001). Previous reports have focused on the distribution of BMPs in the mammalian growth plate, a typical model of endochondral ossification. In the growth plate, BMP-2, -4 and -7 are reported in proliferating and

≠

hypertrophic chondrocytes and BMP-6 in hypertrophic chondrocytes (Anderson et al., 2000, Nilsson et al., 2007, Yazaki et al., 1998, Sakou et al., 1999, McCullough et al., 2007). Our study found similar staining patterns for BMPs as reported in previous studies. In addition, we detected BMP-6 in resting and proliferative zone chondrocytes. BMP receptors are found in all zones of the growth plate in slightly different patterns (Nilsson et al., 2007, Sakou et al., 1999). Similar to those reports, we detected BMPR-1B in all zones of the bovine growth plate; with greater concentration in the resting and hypertrophic zones. The detection of BMPR1A and BMPR-2 was limited to the resting zone and proliferating zone, respectively. Expression of Smads 1, 5, and 8 has been reported in proliferating chondrocytes, primarily near the zone of proliferating and hypertrophied chondrocytes in the growth plate (Sakou et al., 1999, Kobayashi et al., 2005). Likewise, phosphorylated Smads 1/5/8 in the bovine growth plate were detected within proliferating and resting chondrocytes. Overall, our study found the distribution of BMPs, BMPRs and their signal transducing proteins in the bovine growth plate to be reasonably similar to other mammalian growth plates reported in the literature. Thus, ensuring the bovine growth plate is a model of a typical mammalian growth plate and is suitable to be used as a comparison for the cartilaginous cap of osteochondromas.

In this study, we demonstrated the localization and distribution patterns of BMPs and BMP receptors in the cartilaginous cap of both solitary and multiple human osteochondromas using immunohistochemistry. Since the cartilaginous cap of human osteochondromas histologically resembles the mammalian growth plate, distribution and localization pattern comparisons were made between the cartilaginous cap and the bovine growth plate. The present findings showed similarities in the staining patterns for BMP-6 between the cartilaginous cap of human osteochondromas and the growth plate. Besides cytoplasmic staining, nuclear-like staining in

#

proliferating chondrocytes was also present. In addition, the cartilaginous cap and growth plate shared similar localization patterns for BMP-7, BMPR-1A and BMPR-2. However, BMP-7 appeared to be absent in hypertrophic chondrocytes of the cartilaginous cap of osteochondromas whereas BMPR-2 was also present in calcifying hypertrophic chondrocytes in SO. While present in all zones of the growth plate, a difference in staining patterns for BMP-2/4 and BMPR-1B was observed between the cartilaginous cap of human osteochondromas and the growth plate. BMP-2/4 was present in clusters of proliferating chondrocytes in SO while cytoplasmic and nuclear-like staining was observed in chondrocytes of MO. Membranous expression of BMPR-1B was found in hypertrophic chondrocytes of SO; yet, staining in MO was mostly cytoplasmic and nuclear-like in enlarged and proliferating chondrocytes. Expression of BMP-2 and BMP-6 in the layer of hypertrophic chondrocytes stimulates further differentiation of less differentiated chondrocytes (Kobayashi et al., 2005). The lack of detectable BMP-2/4 and BMP-6 in hypertrophic chondrocytes of the cartilaginous cap of osteochondromas supports the indication that delayed hypertrophic differentiation may contribute to osteochondroma development as chondrocytes fail to terminally differentiate. Studies conducted in mouse models of MHE have shown that conditional ablation of *Ext1* in chondrocytes of the growth plate results in the formation of osteochondromas with a mosaic of wild-type and HS-deficient cells (Matsumoto et al., 2010a, Jones et al., 2010). Also, human osteochondroma are a heterogeneous composition of both normal and PG-deficient cells (de Andrea et al., 2011). One possibility for our observations in the study is that HS deficiency gives growth factors such as BMPs the freedom to interact and act on chondrocytes with less space and time restrictions. Interference with the function of HS was recently shown to increase cellular responsiveness to endogenous and exogenous BMPs (Huegel et al., 2013). To receive insight into a potential alteration in BMP signaling in the

#

cartilaginous cap of human osteochondromas phosphorylated Smads 1/5/8 was investigated. In the cartilaginous cap of both MO and SO phosphorylated Smads 1/5/8 were mainly localized in proliferating chondrocytes similar to that of the growth plate. A difference between the cartilaginous cap and the growth plate was noticed as no detectable staining patterns were observed for phosphorylated Smads 1/5/8 in resting chondrocytes but occasional weak staining in hypertrophic chondrocytes of the cartilaginous cap was noted. Postnatal growth influences the degree in which chondrocytes of the growth plate response to BMP signaling pathways (Dahia et al., 2011). Therefore it is sensible to suggest that the growth stage at which our tissue samples were collected could account for the difference in localization and distribution patterns.

Background staining was observed in MO due to the large amount of matrix present, compared to SO and the growth plate, which could account for the differences observed in the staining patterns. Also, due to the random dispersal of chondrocytes within the cartilaginous tissue of MO, identifying the developmental stage of chondrocytes, in reference to endochondral ossification, was a challenge. Type II collagen, Ki-67 and type X collagen were analyzed to classify the chondrocyte subtypes present in the cartilaginous cap of osteochondromas.

Consistent with previous study (Huch et al., 2002), proliferating chondrocytes in the cartilaginous cap of osteochondromas stained positive for type II collagen and Ki-67 and negative for type X collagen whereas hypertrophic chondrocytes stained negative for Ki-67 and positive for type X collagen. Chondrocytes positive for type II collagen and negative for Ki-67 and type X collagen were classified as resting chondrocytes. Fixation of cartilage usually causes some shrinkage between the chondrocyte surface and the lacunar wall (Hunziker et al., 1982).

Lacunae appeared to be more prominent and the shrinkage of the cytoplasm makes it difficult to make out the details of these cells with the light microscope. For this reason, the chondrocytes

≠

give the appearance of a densely stained atypical nucleus within lacunae which can account for the nuclear-like BMP staining observed.

BMP binding proteins, such as noggin, act as extracellular antagonist of BMP signaling by binding directly to BMP; thus, preventing them from interacting with their cognate receptors on the cell surface. Increased noggin activity results in skeletal dysplasia (Krause et al., 2011). Our study demonstrated a difference in the distribution of noggin between the cartilaginous cap of SO and MO compared to the growth plate. Noggin was observed mainly in resting zone chondrocytes of the growth plate. To a lesser extent, noggin was also found in proliferative zone chondrocytes of the growth plate. Interestingly, noggin was observed in resting chondrocytes and in few clustered proliferating chondrocytes in the cartilaginous cap of SO; thus demonstrating a similarity to the growth plate. To our surprise, noggin in MO was observed in proliferating chondrocytes. HSPGs can regulate the distribution of noggin. Noggin has been shown to bind strongly to HSPGs, independent of its action as a BMP antagonist (Paine-Saunders et al., 2002). Thus, HS abnormalities associated with osteochondromas could explain the difference in noggin distribution.

In addition, we studied the localization and distribution of BMPs and BMPRs in articular cartilage. Earlier studies reported BMP-7 in the superficial zone (Muehleman et al., 2002) and BMP-2, -4, -6 and -7 in the middle zone of articular cartilage (Anderson et al., 2000). BMPR-1B has been reported in the middle and deep zones and to a lesser extent in the superficial zone (Muehleman et al., 2002). Expression of Smads 1, 5, and 8 has been reported in developing articular cartilage (Pogue and Lyons, 2006, Kobayashi et al., 2005). In the present study, BMP-2/4 and -7 and BMPR-1A and -1B were present in all zones of the articular cartilage. BMP-6 and noggin were mainly localized in the middle zone; however, weak staining was observed in the

#

superficial zone. Weak BMPR-2 expression was observed in the deep zone of articular cartilage.

Detection for phosphorylated Smads 1/5/8 was rare and weakly observed in the deep zone.

In conclusion, we have demonstrated by immunohistochemistry the distribution of BMPs, their receptors and their signal transducing proteins in the cartilaginous cap of solitary and multiple human osteochondromas. Thus, the distribution and localization of BMPs and BMPRs in osteochondromas is similar to the growth plate. To our knowledge, this represents the first demonstration of BMPs and BMPRs in human osteochondromas. Since BMPs can stimulate proliferation and hypertrophic differentiation of chondrocytes, these findings suggest that BMP signaling in the cartilaginous cap of osteochondromas may help maintain these cells in a maturing state. Therefore, BMP signaling may be a key mechanism responsible for abnormal regulation of chondrocyte proliferation and differentiation in the cartilaginous cap of human osteochondromas.

Acknowledgements

This work was supported by funds from the Lawrence J. Ellison endowment. We appreciate the assistance of the pediatric orthopaedic staff at Shriners Hospital for Children, Northern California.

References

- ANDERSON, H. C., HODGES, P. T., AGUILERA, X. M., MISSANA, L. & MOYLAN, P. E. 2000. Bone morphogenetic protein (BMP) localization in developing human and rat growth plate, metaphysis, epiphysis, and articular cartilage. *J Histochem Cytochem*, 48, 1493-502.
- BENOIST-LASSELIN, C., DE MARGERIE, E., GIBBS, L., CORMIER, S., SILVE, C., NICOLAS, G., LEMERRER, M., MALLET, J. F., MUNNICH, A., BONAVENTURE, J., ZYLBERBERG, L. & LEGEAI-MALLET, L. 2006. Defective chondrocyte proliferation and differentiation in osteochondromas of MHE patients. *Bone*, 39, 17-26.
- BOVEE, J. V. 2008. Multiple osteochondromas. *Orphanet J Rare Dis*, 3, 3.
- BOVÉE, J. V., VAN DEN BROEK, L. J., CLETON-JANSEN, A. M. & HOGENDOORN, P. C. 2000. Up-regulation of PTHrP and Bcl-2 expression characterizes the progression of osteochondroma towards peripheral chondrosarcoma and is a late event in central chondrosarcoma. *Laboratory investigation; a journal of technical methods and pathology*, 80, 1925-34.
- BURDAN, F., SZUMILO, J., KOROBOWICZ, A., FAROOQUEE, R., PATEL, S., PATEL, A., DAVE, A., SZUMILO, M., SOLECKI, M., KLEPACZ, R. & DUDKA, J. 2009. Morphology and physiology of the epiphyseal growth plate. *Folia Histochem Cytobiol*, 47, 5-16.
- DAHIA, C. L., MAHONEY, E. J., DURRANI, A. A. & WYLIE, C. 2011. Intercellular signaling pathways active during and after growth and differentiation of the lumbar vertebral growth plate. *Spine (Phila Pa 1976)*, 36, 1071-80.
- DE ANDREA, C. E., PRINS, F. A., WIWEGER, M. I. & HOGENDOORN, P. C. 2011. Growth plate regulation and osteochondroma formation: insights from tracing proteoglycans in zebrafish models and human cartilage. *J Pathol*, 224, 160-8.
- DEIRMENGIAN, G. K., HEBELA, N. M., O'CONNELL, M., GLASER, D. L., SHORE, E. M. & KAPLAN, F. S. 2008. Proximal tibial osteochondromas in patients with fibrodysplasia ossificans progressiva. *J Bone Joint Surg Am*, 90, 366-74.
- DORFMAN, H. D. C. B. 1998. *Bone tumors*, St. Louis, Mosby.
- DU, K., PENG, Y., ZHANG, L., LIANG, A. & HUANG, D. 2011. Expression of the Stem Cell Marker Nestin in Pre/hypertrophic Chondrocytes in Osteochondroma. *Journal of International Medical Research*, 39, 348-357.

- FUJII, M., TAKEDA, K., IMAMURA, T., AOKI, H., SAMPATH, T. K., ENOMOTO, S., KAWABATA, M., KATO, M., ICHIJO, H. & MIYAZONO, K. 1999. Roles of bone morphogenetic protein type I receptors and Smad proteins in osteoblast and chondroblast differentiation. *Mol Biol Cell*, 10, 3801-13.
- HAMEETMAN, L., DAVID, G., YAVAS, A., WHITE, S. J., TAMINIAU, A. H., CLETON-JANSEN, A. M., HOGENDOORN, P. C. & BOVEE, J. V. 2007. Decreased EXT expression and intracellular accumulation of heparan sulphate proteoglycan in osteochondromas and peripheral chondrosarcomas. *J Pathol*, 211, 399-409.
- HECHT, J. T., HALL, C. R., SNUGGS, M., HAYES, E., HAYNES, R. & COLE, W. G. 2002. Heparan sulfate abnormalities in exostosis growth plates. *Bone*, 31, 199-204.
- HUCH, K., MORDSTEIN, V., STOVE, J., NERLICH, A. G., AMHOLDT, H., DELLING, G., PUHL, W., GUNTHER, K. P. & BRENNER, R. E. 2002. Expression of collagen type I, II, X and Ki-67 in osteochondroma compared to human growth plate cartilage. *Eur J Histochem*, 46, 249-58.
- HUEGEL, J., MUNDY, C., SGARIGLIA, F., NYGREN, P., BILLINGS, P. C., YAMAGUCHI, Y., KOYAMA, E. & PACIFICI, M. 2013. Perichondrium phenotype and border function are regulated by Ext1 and heparan sulfate in developing long bones: a mechanism likely deranged in Hereditary Multiple Exostoses. *Dev Biol*, 377, 100-12.
- HUNZIKER, E. B., HERRMANN, W. & SCHENK, R. K. 1982. Improved cartilage fixation by ruthenium hexammine trichloride (RHT). A prerequisite for morphometry in growth cartilage. *J Ultrastruct Res*, 81, 1-12.
- JENNES, I., PEDRINI, E., ZUNTINI, M., MORDENTI, M., BALKASSMI, S., ASTEGGIANO, C. G., CASEY, B., BAKKER, B., SANGIORGI, L. & WUYTS, W. 2009. Multiple osteochondromas: mutation update and description of the multiple osteochondromas mutation database (MOdb). *Hum Mutat*, 30, 1620-7.
- JIAO, X., BILLINGS, P. C., O'CONNELL, M. P., KAPLAN, F. S., SHORE, E. M. & GLASER, D. L. 2007. Heparan sulfate proteoglycans (HSPGs) modulate BMP2 osteogenic bioactivity in C2C12 cells. *J Biol Chem*, 282, 1080-6.
- JONES, K. B., PIOMBO, V., SEARBY, C., KURRIGER, G., YANG, B. L., GRABELLUS, F., ROUGHLEY, P. J., MORCUENDE, J. A., BUCKWALTER, J. A., CAPECCHI, M. R., VORTKAMP, A. & SHEFFIELD, V. C. 2010. A mouse model of osteochondromagenesis from clonal inactivation of Ext1 in chondrocytes. *Proceedings of the National Academy of Sciences of the United States of America*, 107, 2054-2059.
- KAPLAN, F. S., LE MERRER, M., GLASER, D. L., PIGNOLO, R. J., GOLDSBY, R. E., KITTERMAN, J. A., GROPE, J. & SHORE, E. M. 2008. Fibrodysplasia ossificans progressiva. *Best Pract Res Clin Rheumatol*, 22, 191-205.
- KAWABATA, M., IMAMURA, T. & MIYAZONO, K. 1998. Signal transduction by bone morphogenetic proteins. *Cytokine Growth Factor Rev*, 9, 49-61.
- KOBAYASHI, T., LYONS, K. M., MCMAHON, A. P. & KRONENBERG, H. M. 2005. BMP signaling stimulates cellular differentiation at multiple steps during cartilage development. *Proc Natl Acad Sci U S A*, 102, 18023-7.
- KRAUSE, C., GUZMAN, A. & KNAUS, P. 2011. Noggin. *Int J Biochem Cell Biol*, 43, 478-81.

- KRONENBERG, H. M. 2003. Developmental regulation of the growth plate. *Nature*, 423, 332-6.
- MATSUMOTO, K., IRIE, F., MACKEM, S. & YAMAGUCHI, Y. 2010a. A mouse model of chondrocyte-specific somatic mutation reveals a role for Ext1 loss of heterozygosity in multiple hereditary exostoses. *Proc Natl Acad Sci U S A*, 107, 10932-7.
- MATSUMOTO, Y., MATSUMOTO, K., IRIE, F., FUKUSHI, J., STALLCUP, W. B. & YAMAGUCHI, Y. 2010b. Conditional ablation of the heparan sulfate-synthesizing enzyme Ext1 leads to dysregulation of bone morphogenetic protein signaling and severe skeletal defects. *J Biol Chem*, 285, 19227-34.
- MCCULLOUGH, K. A., WAITS, C. A., GARIMELLA, R., TAGUE, S. E., SIPE, J. B. & ANDERSON, H. C. 2007. Immunohistochemical localization of bone morphogenetic proteins (BMPs) 2, 4, 6, and 7 during induced heterotopic bone formation. *J Orthop Res*, 25, 465-72.
- MININA, E., WENZEL, H. M., KRESCHER, C., KARP, S., GAFFIELD, W., MCMAHON, A. P. & VORTKAMP, A. 2001. BMP and Ihh/PTHrP signaling interact to coordinate chondrocyte proliferation and differentiation. *Development*, 128, 4523-34.
- MUEHLEMAN, C., KUETTNER, K. E., RUEGER, D. C., TEN DIJKE, P. & CHUBINSKAYA, S. 2002. Immunohistochemical localization of osteogenetic protein (OP-1) and its receptors in rabbit articular cartilage. *J Histochem Cytochem*, 50, 1341-50.
- NADANAKA, S. & KITAGAWA, H. 2008. Heparan sulphate biosynthesis and disease. *J Biochem*, 144, 7-14.
- NAKASE, T., MYOUI, A., SHIMADA, K., KURIYAMA, K., JOYAMA, S., MIYAJI, T., TOMITA, T. & YOSHIKAWA, H. 2001. Involvement of BMP-2 signaling in a cartilage cap in osteochondroma. *J Orthop Res*, 19, 1085-8.
- NILSSON, O., PARKER, E. A., HEGDE, A., CHAU, M., BARNES, K. M. & BARON, J. 2007. Gradients in bone morphogenetic protein-related gene expression across the growth plate. *J Endocrinol*, 193, 75-84.
- OKADA, M., NADANAKA, S., SHOJI, N., TAMURA, J. & KITAGAWA, H. 2010. Biosynthesis of heparan sulfate in EXT1-deficient cells. *Biochem J*, 428, 463-71.
- PAINE-SAUNDERS, S., VIVIANO, B. L., ECONOMIDES, A. N. & SAUNDERS, S. 2002. Heparan sulfate proteoglycans retain Noggin at the cell surface: a potential mechanism for shaping bone morphogenetic protein gradients. *J Biol Chem*, 277, 2089-96.
- POGUE, R. & LYONS, K. 2006. BMP signaling in the cartilage growth plate. *Curr Top Dev Biol*, 76, 1-48.
- REDDI, A. H. 1997. Bone morphogenetic proteins: an unconventional approach to isolation of first mammalian morphogens. *Cytokine Growth Factor Rev*, 8, 11-20.
- REDDI, A. H. 1998. Role of morphogenetic proteins in skeletal tissue engineering and regeneration. *Nat Biotechnol*, 16, 247-52.
- REDDI, A. H. 2001. Interplay between bone morphogenetic proteins and cognate binding proteins in bone and cartilage development: noggin, chordin and DAN. *Arthritis research*, 3, 1-5.
- REIJNDERS, C. M., WAAIJER, C. J., HAMILTON, A., BUDDINGH, E. P., DIJKSTRA, S. P., HAM, J., BAKKER, E., SZUHAI, K., KARPERIEN, M., HOGENDOORN, P. C., STRINGER, S. E. & BOVEE,

- J. V. 2010. No haploinsufficiency but loss of heterozygosity for EXT in multiple osteochondromas. *Am J Pathol*, 177, 1946-57.
- SAKOU, T., ONISHI, T., YAMAMOTO, T., NAGAMINE, T., SAMPATH, T. & TEN DIJKE, P. 1999. Localization of Smads, the TGF-beta family intracellular signaling components during endochondral ossification. *J Bone Miner Res*, 14, 1145-52.
- UNNI, K. K. D. D. C. 1996. *Dahlin's bone tumors : general aspects and data on 11,087 cases*, Philadelphia, Lippincott-Raven.
- VIGORITA, V. J. G. B. M. D. 2008. *Orthopaedic pathology*, Philadelphia, Lippincott Williams and Wilkins.
- WOZNEY, J. M. & ROSEN, V. 1998. Bone morphogenetic protein and bone morphogenetic protein gene family in bone formation and repair. *Clin Orthop Relat Res*, 26-37.
- YAN, D. & LIN, X. 2009. Shaping morphogen gradients by proteoglycans. *Cold Spring Harb Perspect Biol*, 1, a002493.
- YAZAKI, Y., MATSUNAGA, S., ONISHI, T., NAGAMINE, T., ORIGUCHI, N., YAMAMOTO, T., ISHIDOU, Y.,
IMAMURA, T. & SAKOU, T. 1998. Immunohistochemical localization of bone morphogenetic proteins and the receptors in epiphyseal growth plate. *Anticancer Res*, 18, 2339-44.

Figures

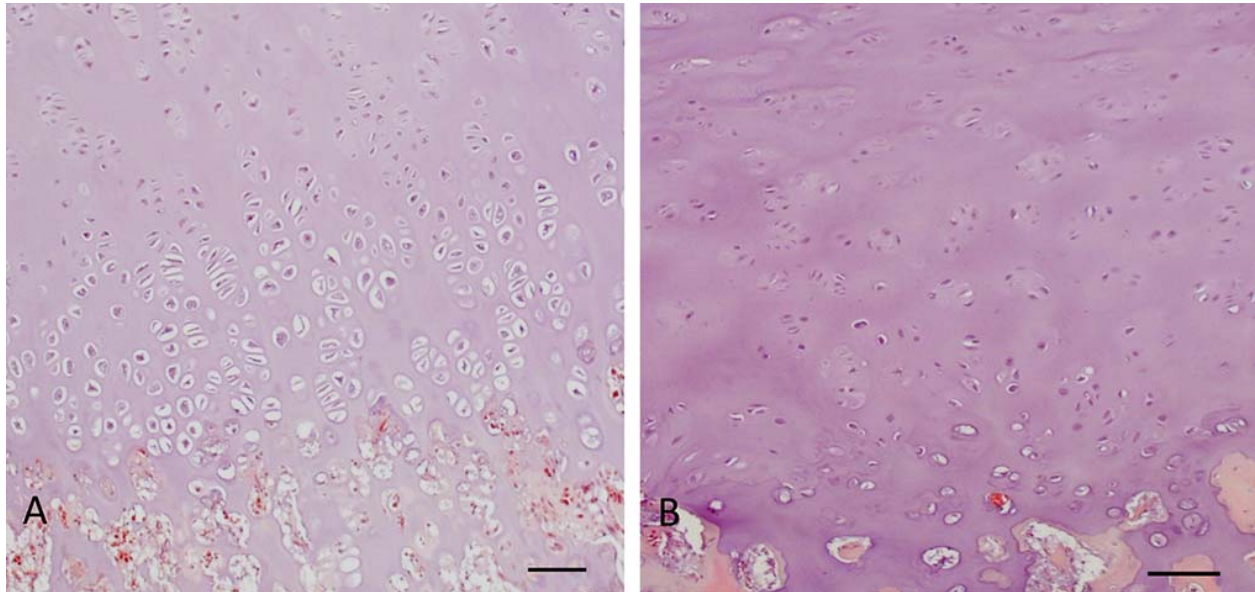


Figure 1 Hematoxylin and eosin histological features of cartilaginous cap of human osteochondromas. (A) SO shows growth plate-like morphology with cluster of chondrocytes rather than columns. (B) MO shows abundant cartilage matrix with randomly distributed chondrocytes. Note the prominent lacunae in some lower proliferating and hypertrophic chondrocytes. Bar = 100 μm .

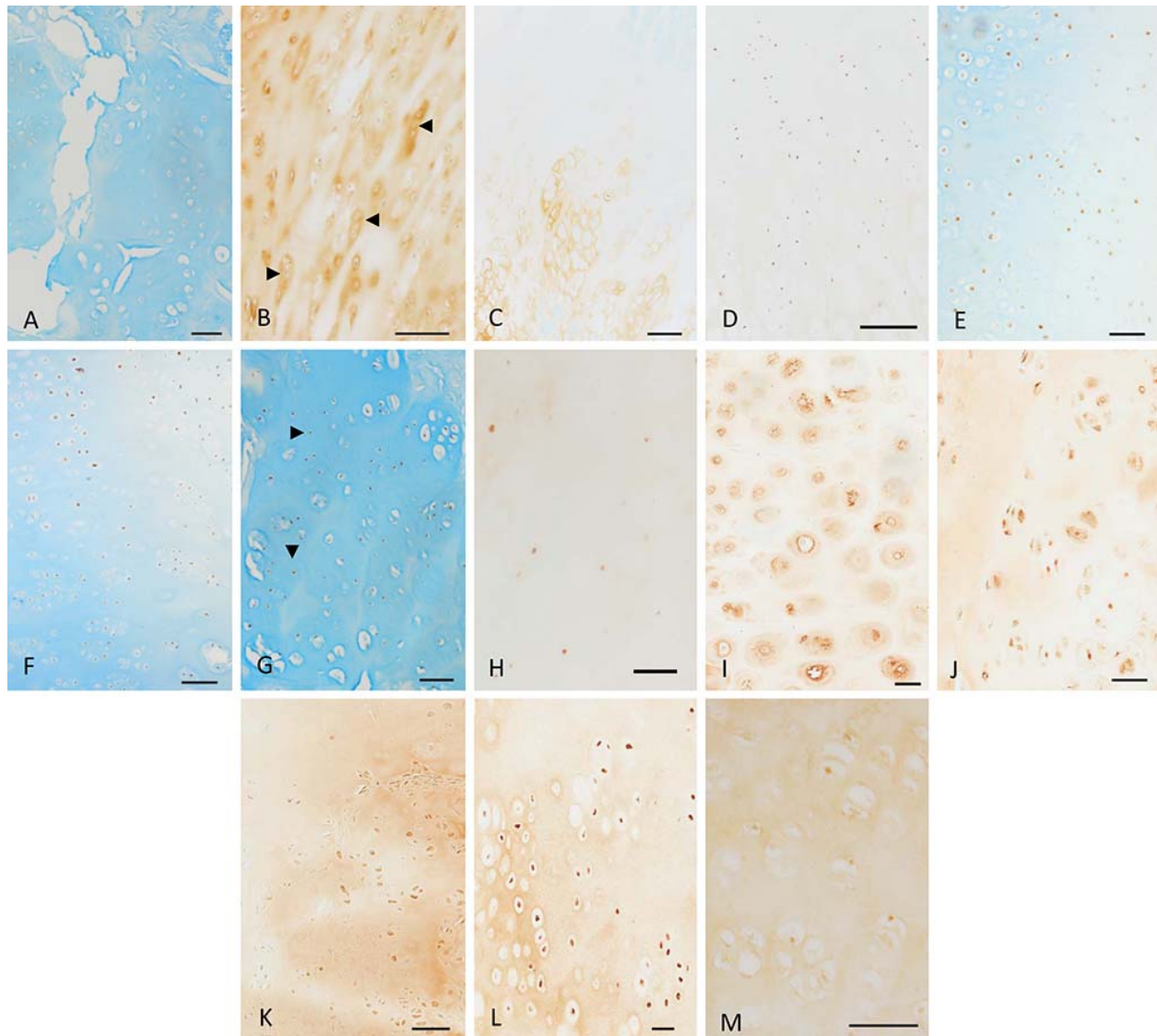


Figure 2 Immunostaining of cartilaginous cap of human osteochondroma. (A) Non-immune serum control shows no BMP staining. (B) Staining for type II collagen present in resting chondrocytes and proliferating (arrowheads) chondrocytes. (C) Type X collagen in hypertrophic chondrocytes. (D) Staining for Ki-67 in proliferating chondrocytes. (E) Staining for BMP-2/4 in clusters of proliferating chondrocytes in SO. (F) BMP-6 staining in proliferating chondrocytes. (G) Staining for BMP-7 present in resting chondrocytes (arrowheads) and proliferating chondrocytes. (H) BMPR-1A staining in small resting chondrocytes. (H)

#

Membranous staining for BMPR-1B in hypertrophic chondrocytes of SO. (J) Cytoplasmic and nuclear-like staining for BMPR-1B in enlarged and proliferating chondrocytes of MO. (K) Weak cytoplasmic staining for BMPR-2 was observed in proliferating chondrocytes. (L) Cytoplasmic staining for noggin in proliferating chondrocytes of MO. (M) Positive staining for phosphorylated smads 1/5/8 in proliferating chondrocytes. (A, C-H) Stained with Alcian Blue. (A-G, I-L) Bar = 100 μ m, (H, M) Bar = 50 μ m.

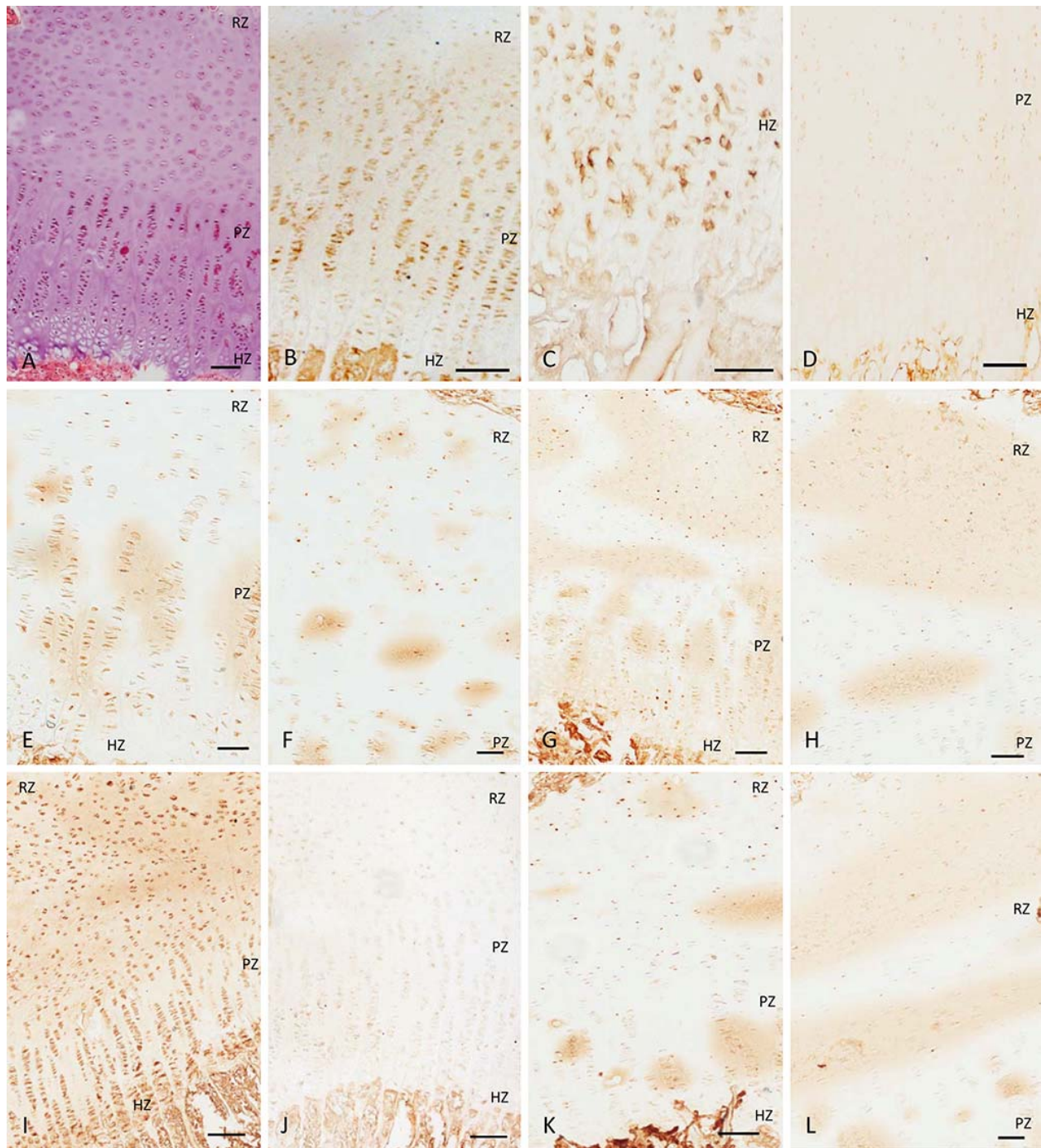


Figure 3 Bovine growth plate. (A) Bovine growth plate shows normal columnar arrangement of chondrocytes. (B) Type II collagen staining in resting and proliferating zone chondrocytes. (C) Type X collagen in hypertrophic zone chondrocytes. (D) Ki-67 staining in proliferating zone chondrocytes. (E) BMP-2/4 staining in chondrocytes of all zones; cytoplasmic staining more

#

visible the proliferating zone. (F) Staining for BMP-6 in resting zone chondrocytes. (G) BMP-7 staining observed in all zones of the growth plate; also, prominent cytoplasmic staining was present in proliferative zone. (H) BMPR-1A staining in resting zone chondrocytes. (I) Staining for BMPR-1B detected in all zones of the growth plate; strong staining visible in the resting and hypertrophic zones. (J) Weak BMPR-2 staining in proliferative chondrocytes. (K) Staining for noggin in resting chondrocytes and proliferating chondrocytes. (L) Phosphorylated smads 1/5/8 staining in resting and proliferative zones. RZ, resting zone; PZ, proliferating zone; HZ, hypertrophic zone. Bar = 100 μ m.

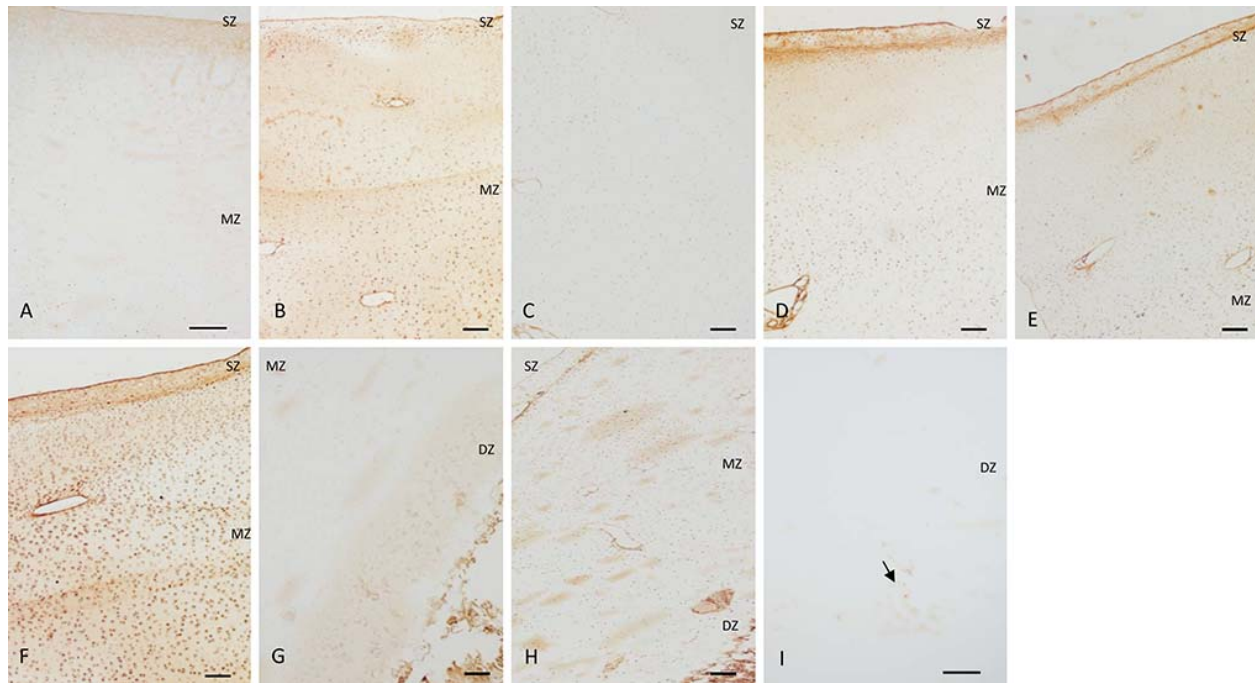


Figure 4 Immunostaining of bovine articular cartilage. (A) Non-immune serum control shows no BMP staining. (B) Cytoplasmic staining was observed for BMP-2/4 in all zones. (C) Weak staining for BMP-6 was found in the middle zones. (D-F) BMP-7, BMPR-1A and BMPR-1B, respectively, were observed in all zones. (G) Weak BMPR-2 staining was detected in the deep zone. (H) Noggin was found in all zones with strong staining more visible in the middle zone. (I) Weak staining for phosphorylated smads 1/5/8 was found in the deep zone (arrow). SZ, superficial zone; MZ, middle zone; DZ, deep zone. Bar = 100 μ m

Tables**TABLE 1.** Immunohistochemical localization and distribution of BMPs, BMPR and noggin ^a

	BMP-2/4	BMP-6	BMP-7	BMPR-1A	BMPR-1B	BMPR-2	Noggin	p-Smads 1/5/8
MO Chondrocytes								
Resting	++	+	++	+	0	0	+	0
Proliferating	++	+	++	+	+++	+	+++	++
Hypertrophic	0	0	0	0	++	0	0	+
SO Chondrocytes								
Resting	++	++	++	+	0	0	+++	0
Proliferating	++	++	+++	+	++	+	+	++
Hypertrophic	0	0	0	0	+++	+	0	+
Growth Plate Chondrocytes								
Resting	++	+++	+++	++	+++	0	+++	+++
Proliferating	++	++	++	0	++	+	++	++
Hypertrophic	++	++	++	0	+++	0	0	0
Articular Chondrocytes								
Superficial	++	+	++	++	++	0	++	0
Middle	++	+	++	++	++	0	+++	0
Deep	++	0	++	++	+++	+	++	+

^a 0, not detected; +, weak staining; ++, moderate staining; +++, maximal staining.

TABLE 2. Positive index values for different entities in the cartilaginous cap of human osteochondromas ^a

	MO ^b	SO ^c	<i>p</i> -value
BMP-2/4	47.9 ± 4.0	48.9 ± 9.6	0.876
BMP-6	34.7 ± 14.5	32.0 ± 11.0	0.811
BMP-7	47.3 ± 15.2	43.3 ± 12.7	0.747
BMPR-IA	34.4 ± 12.2	32.6 ± 13.1	0.871
BMPR-IB	31.1 ± 3.2	42.0 ± 10.8	0.169
BMPR-II	26.7 ± 21.2	24.0 ± 12.6	0.858
Noggin	41.1 ± 3.2	25.7 ± 12.6	0.110
p-Smads 1/5/8	22.7 ± 8.4	22.8 ± 11.2	0.985

^a average ± standard deviation in %^b multiple osteochondromas^c solitary osteochondromas