UC Irvine
Clinical Practice and Cases in Emergency Medicine

Title
Wernicke-Korsakoff Syndrome Associated with Tirzepatide Use: A Case Report

Permalink
https://escholarship.org/uc/item/3t0259pf

Journal
Clinical Practice and Cases in Emergency Medicine, 0(0)

Authors
Bischel, Claire
Samir, Eglal
Krandel, Jessica
et al.

Publication Date
2026-11-24

DOI
10.5811/cpcem.65743

Copyright Information
This work is made available under the terms of a Creative Commons Attribution License, available at https://creativecommons.org/licenses/by/4.0/

Peer reviewed

eScholarship.org Powered by the California Digital Library
University of California

Wernicke-Korsakoff Syndrome Associated with Tirzepatide Use: A Case Report

Claire Bischel, BS*†
Eglal Samir, DO‡
Jessica Krandel, DO§
Ramalakshmi Thulluri, MD‡
Daniel Kurtz, MD§
Chelsea Johnson, MD¶‖

*Michigan State University College of Osteopathic Medicine, East Lansing, Michigan
†McLaren Greater Lansing Hospital, Lansing, Michigan
‡McLaren Greater Lansing Hospital, Internal Medicine, Lansing, Michigan
§McLaren Greater Lansing Hospital, Pulmonary Disease and Critical Care Medicine, Lansing, Michigan
¶McLaren Greater Lansing Hospital, Emergency Medicine, Lansing, Michigan
‖Wayne State University School of Medicine, Detroit, Michigan

Section Editor: Lev Levit, MD
Submission history: Submitted May 15, 2026; Revision received August 14, 2026; Accepted: August 15, 2026
Electronically published [date]
Full text available through open access at http://escholarship.org/uc/uciem_cpcem
DOI: 10.5811/cpcem.65743

Introduction: Wernicke-Korsakoff syndrome (WKS), a debilitating neurologic disorder caused by thiamine deficiency, can lead to irreversible brain damage if not promptly addressed. Although traditionally associated with chronic alcohol use, nonalcoholic etiologies are increasingly recognized, particularly in the setting of rapid weight loss and malnutrition related to tirzepatide, a glucagon-like peptide-1 (GLP-1) and glucose-dependent insulinotropic polypeptide (GIP) receptor agonist (RA).

Case Report: We present the case of a 37-year-old man with morbid obesity presenting with six weeks of progressive functional decline and rapid weight loss shortly after initiating tirzepatide.

Magnetic resonance imaging of the brain demonstrated abnormal T2/fluid attenuated inversion recovery hyperintense signals consistent with WKS. Despite initiation of intravenous (IV) thiamine on hospital day four, the patient did not demonstrate improvement in neurologic status.

Conclusion: This case underscores the importance of recognizing gastrointestinal side effects of GLP-1/GIP RA therapy as a risk factor for thiamine deficiency and WKS, and the need for prompt empiric IV thiamine supplementation in such patients. Early nutritional assessment and timely, prophylactic thiamine supplementation in high-risk patients may mitigate this rare but potentially devastating complication. [Clin Pract Cases Emerg Med. 2026;X(X):XXX–XXX.]

Keywords: *Wernicke-Korsakoff syndrome; malnutrition; tirzepatide; case report.*

INTRODUCTION

Wernicke-Korsakoff syndrome (WKS) is a debilitating neurologic condition caused by thiamine deficiency, a crucial component of cerebral energy metabolism. Wernicke encephalopathy, the acute and potentially reversible phase, classically presents with confusion, ataxia, and ophthalmoplegia. Without timely thiamine replacement, it may progress to Korsakoff syndrome, leading to irreversible neurologic injury. Although treatment with thiamine replacement is safe, effective, and readily available, WKS remains under-recognized and subsequently undertreated in clinical practice, with many cases identified postmortem.[1]

Wernicke-Korsakoff syndrome is traditionally associated with chronic alcohol use; however, other recognized causes include bariatric surgery, intestinal malabsorption, and malnutrition.[2] As a dual glucagon-like peptide-1 (GLP-1) and glucose-dependent insulinotropic polypeptide (GIP) receptor agonist (RA), tirzepatide has gained popularity for its effectiveness in weight reduction and type 2 diabetes management.[3] The gastrointestinal side effects of tirzepatide, including nausea, vomiting, appetite suppression, and delayed gastric emptying,[3] may predispose some patients to rapid

weight loss and malnutrition. Nutritional deficiencies may go unnoticed, particularly in patients who retain the diagnosis of obesity despite weight loss, as they may not be perceived as nutritionally vulnerable.[4] Thus, such patients are less likely to be identified as at risk for WKS, contributing to a delay in diagnosis and treatment.

CPC-EM Capsule

What do we already know about this clinical entity?
Wernicke-Korsakoff syndrome (WKS) is a neurologic disorder driven by thiamine deficiency.

What makes this presentation of disease reportable?
This case describes severe, irreversible neurologic injury from WKS associated with malnutrition following rapid weight loss in the setting of tirzepatide use.

What is the major learning point?
WKS should be considered in patients on tirzepatide who present with unexplained encephalopathy, particularly in those with rapid weight loss.

How might this improve emergency medicine practice?
Recognizing tirzepatide as a risk factor for thiamine deficiency allows for prompt thiamine replacement in patients with unexplained encephalopathy.

CASE REPORT

A 37-year-old man with a history of type 2 diabetes and obesity presented to the emergency department with several weeks of malaise and progressive functional decline characterized by worsening weakness and multiple falls. He became bedbound 10 days prior to presentation due to profound weakness limiting ambulation, and he subsequently developed a stage 1 decubitus ulcer of the cheek. History was limited by encephalopathy and obtained primarily from family members. The social and family histories were unremarkable.

Six weeks prior to admission, shortly after initiating tirzepatide, he developed dysgeusia, followed by nausea, vomiting, and markedly reduced oral intake. He sustained a weight loss of approximately 34 kg from the start of tirzepatide therapy up to hospital admission, weighing 176 kg on admission.

On arrival, the patient was hemodynamically stable. Vital signs included the following: heart rate, 95 beats per minute; blood pressure, 130/103 mm Hg; respiratory rate, 18 breaths per minute; temperature, 36.9 °C; and SpO_2, 95% on room air. Neurologic examination revealed lethargy without focal neurological deficits. The patient appeared withdrawn and had limited participation with examination. He was arousable and capable of brief conversation but exhibited hypersomnia, repeatedly falling asleep during the examination, and was unable to ambulate due to diffuse weakness. He had exotropia of the left eye, which his family described as being present for many years, limiting diagnostic significance.

Initial evaluation, including computed tomography of the brain, spine, thorax, abdomen, and pelvis, and laboratory studies, was unremarkable except for an anion gap metabolic acidosis with an arterial pH of 7.298 (reference range, 7.35-7.45); anion gap of 16.1 mEq/L (4-12 mEq/L), and a mildly elevated lactate level of 2.4 mmol/L (< 2.0 mmol/L). Given his clinical presentation, empiric treatment for meningoencephalitis was initiated with ceftriaxone, vancomycin, and acyclovir, and he was admitted for encephalopathy of unclear etiology.

During hospitalization, the patient's mental status further declined, necessitating endotracheal intubation for airway protection. Subsequent investigations included cerebrospinal fluid (CSF) analysis and evaluation for infectious, nutritional, autoimmune, and malignant etiologies. In the setting of prolonged poor oral intake and significant weight loss, empiric intravenous (IV) thiamine supplementation (400 mg 3 times daily) was initiated on hospital day 4 while awaiting laboratory results. Whole blood thiamine level later returned at 31 nmol/L (70-180 nmol/L).

Magnetic resonance imaging (MRI) of the brain was initially delayed due to body habitus and concern for scanner limitations but was successfully obtained on hospital day 13. The radiology report described linear foci of enhancement around the third ventricle and aqueduct of Sylvius, interpreted as nonspecific changes concerning for an infectious, inflammatory, or neoplastic process with recommendation for correlation with CSF analysis and further diagnostic evaluation. Despite nutritional replacement and empiric antimicrobial therapy for meningoencephalitis with ceftriaxone, vancomycin, and acyclovir, the patient did not demonstrate neurologic improvement, prompting a repeat MRI on hospital day 26. Repeat MRI demonstrated abnormal T2/fluid attenuated inversion recovery (FLAIR) hyperintense signal in the periaqueductal gray matter, medial thalami, periventricular region of the third ventricle, and mammillary bodies, consistent with WKS (Image).[5]

The patient remained ventilator-dependent and hemodynamically stable with no meaningful improvement in neurologic status despite thiamine and micronutrient replacement.

DISCUSSION

The diagnosis of WKS is particularly challenging in the emergency setting due to nonspecific neurologic symptoms,

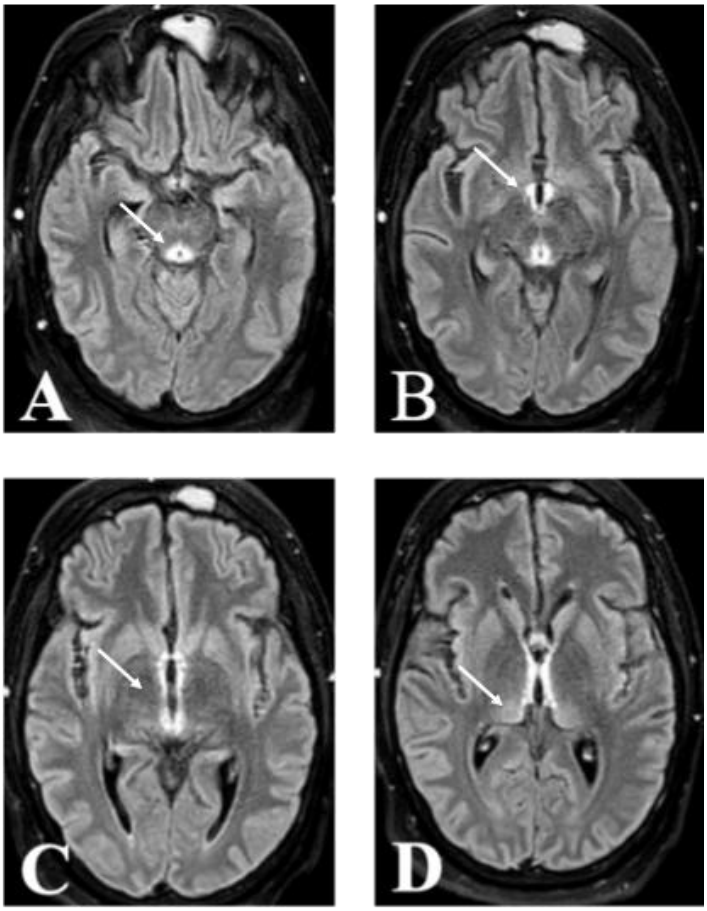

Image. Select T2/fluid attenuated inversion recovery magnetic resonance imaging cuts obtained on hospital day 26 demonstrating hyperintensities in the periaqueductal gray matter (**A**), mammillary bodies (**B**), periventricular region of the third ventricle (**C**), and periventricular thalamus (**D**).

frequent absence of the classic triad of symptoms, under-recognition in nonalcoholic patients, and lack of a single definitive diagnostic test.[1] The syndrome is classically described as a triad of confusion, ataxia, and ophthalmoplegia, yet the complete triad of symptoms is present in only 16% of patients.[1] Recognizing the broad spectrum of clinical presentations is essential for facilitating timely thiamine replacement and preventing progression to irreversible neurologic damage. The precise timeline over which untreated Wernicke encephalopathy progresses to Korsakoff syndrome has not been established; however, delayed recognition remains a significant concern. Autopsy studies consistently demonstrate that Wernicke encephalopathy is far more common than clinical recognition suggests, with many cases identified only on postmortem examination.[1] This lack of recognition exemplifies the importance of prompt thiamine administration, because the point at which irreversible neurologic damage occurs has yet to be identified.

Emerging evidence suggests that tirzepatide, a GLP-1/GIP RA, may contribute to thiamine deficiency; however, current data remain limited to case reports and pharmacovigilance data.[6] While generally well-tolerated, gastrointestinal side effects including nausea, vomiting, and reduced oral intake can precipitate thiamine deficiency.[6] Although the rate at which thiamine deficiency develops depends upon the severity of malnutrition and metabolic demand, total body thiamine stores may be depleted within 3 weeks of inadequate intake, after which thiamine-dependent metabolic processes become impaired.[1] A pharmacovigilance study and literature review reported cases of Wernicke encephalopathy in the setting of tirzepatide and other GLP-1 RA therapy that emerged within several months of treatment initiation and demonstrated neurological improvement following thiamine replacement.[6] In contrast, our case describes severe, progressive functional decline, worsening mentation, and malnutrition leading to tracheostomy dependence despite treatment of Wernicke encephalopathy. To our knowledge, this is the first reported case associated with irreversible neurologic injury, underscoring the need for heightened vigilance in recognizing nutritional deficiencies in patients receiving these therapies.

The initial presentation of WKS in the emergency setting can be nearly indistinguishable from other causes of encephalopathy. According to the Caine criteria, the diagnosis of WKS is supported when two of the following four features are present: dietary thiamine deficiency, ocular abnormalities, cerebellar dysfunction, and either altered mental status or memory impairment.[7] In our patient, history and examination were limited by profound encephalopathy, and a broad evaluation including neuroimaging, laboratory studies, and cerebrospinal fluid analysis was largely unremarkable, creating diagnostic uncertainty. Subtle manifestations of Wernicke encephalopathy may go unrecognized upon initial presentation, particularly in patients using GLP-1/GIP RA therapy who may not be perceived as nutritionally compromised, increasing the risk of progression from the acute phase to chronic, irreversible Korsakoff syndrome.

Given the role of thiamine in aerobic metabolism, deficiency may result in type B lactic acidosis.[8] Although data directly linking WKS to metabolic acidosis remain inconclusive, previous case reports have suggested an association.[8,9] In the emergency setting, where rapid clinical decision-making is essential, an otherwise unexplained anion gap metabolic acidosis with elevated lactate level should prompt the consideration of thiamine deficiency, even in the absence of well-known risk factors.

Although MRI can be difficult to obtain and interpret in a timely manner in the emergency setting, characteristic abnormalities can strengthen the clinical suspicion of WKS. Typical features include bilateral, symmetric hyperintensities on T2-weighted/FLAIR sequences in regions particularly vulnerable to thiamine deficiency, such as the periaqueductal gray matter, mammillary bodies, periventricular regions of the third ventricle, and periventricular thalamus.[5] In our patient, the aforementioned MRI features were observed and proved instrumental in confirming the diagnosis. Identification of characteristic lesions can facilitate prompt thiamine administration, even when clinical signs are subtle or atypical.

Suspected WKS is a medical emergency, because neurologic injury may become irreversible without timely thiamine replacement.[1,10] Heightened clinical suspicion, timely recognition of characteristic imaging findings, and early initiation of high-dose IV thiamine in patients at risk for WKS are essential to mitigate neurologic damage. Clinicians should maintain a very low threshold for immediate thiamine administration, and treatment should not be delayed for further diagnostic testing. Empiric initiation of high-dose IV thiamine carries minimal risk and represents a potentially life-saving intervention in this population.

CONCLUSION

Wernicke-Korsakoff syndrome is a potentially reversible neurological disorder caused by thiamine deficiency but remains frequently under-recognized and subsequently undertreated. While classically associated with chronic alcohol use, thiamine deficiency in the setting of GLP-1/GIP RA therapy should be considered as a possible etiology in patients presenting with encephalopathy of unknown origin. Thiamine replacement is readily available and well tolerated, and prompt initiation of high-dose IV thiamine may reverse the neurologic manifestations of Wernicke encephalopathy and prevent progression to irreversible neurologic damage.

Patient consent has been obtained and filed for the publication of this case report.

Address for Correspondence: Claire Bischel, BS, Michigan State University College of Osteopathic Medicine, 865 Wilson Rd, East Lansing, MI 48824. Email: bischelc@msu.edu.

Conflicts of Interest: By the *CPC-EM* article submission agreement, all authors are required to disclose all affiliations, funding sources and financial or management relationships that could be perceived as potential sources of bias. The authors disclosed none.

Copyright: © 2026 Bischel et al. This is an open access article distributed in accordance with the terms of the Creative Commons Attribution (CC BY 4.0) License. See: http://creativecommons.org/licenses/by/4.0/

REFERENCES

1. Sechi G and Serra A. Wernicke's encephalopathy: new clinical settings and recent advances in diagnosis and management. *Lancet Neurol*. 2007;6(5):442-455.
2. Oudman E, Wijnia JW, Oey MJ, et al. Wernicke-Korsakoff syndrome despite no alcohol abuse: a summary of systematic reports. *J Neurol Sci*. 2021;426:117482.
3. Karrar HR, Nouh MI, Nouh YI, et al. Tirzepatide-induced gastrointestinal manifestations: A systematic review and meta-analysis. *Cureus*. 2023;15(9):e46091.
4. Mwala NN, Borkent JW, van der Meij BS, et al.. Challenges in identifying malnutrition in obesity: an overview of the state of the art and directions for future research. *Nutr Rev*. 2024;38(1):219-228.
5. Zuccoli G and Pipitone N. Neuroimaging findings in acute Wernicke's encephalopathy: review of the literature. *AJR Am J Roentgenol*. 2009;192(2):501-508.
6. Lev D, Leibowitz A, Lang A, et al. Glucagon-like peptide-1 receptor agonists and Wernicke encephalopathy: a pharmacovigilance study and literature review. *Clin Nutr*. 2026;57:106571.
7. Caine D, Halliday GM, Kril JJ, et al. Operational criteria for the classification of chronic alcoholics: identification of Wernicke's encephalopathy. *J Neurol Neurosurg Psychiatry*. 1997;62(1):51-60.
8. Agedal KJ, Steidl KE, Burgess JL. An overview of type B lactic acidosis due to thiamine (B1) deficiency. *J Pediatr Pharmacol Ther*. 2023;28(5):397-408.
9. Donnino MW, Vega J, Miller J, et al. Distinctive acid-base pattern in Wernicke's encephalopathy. *Ann Emerg Med*. 2007;50(6):722-725.
10. Cantu-Weinstein A, Branning R, Alamir M, et al. Diagnosis and treatment of Wernicke's encephalopathy: a systematic literature review. *Gen Hosp Psychiatry*. 2024;87(6):48-59.