

# UCLA

## UCLA Previously Published Works

### Title

Guided surgery with tooth-supported templates for single missing teeth: A critical review.

### Permalink

<https://escholarship.org/uc/item/3tp4s703>

### Journal

International journal of oral implantology (Berlin, Germany), 9 Suppl 1(2)

### ISSN

2631-6420

### Authors

Pozzi, Alessandro

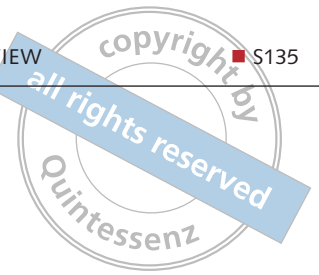
Polizzi, Giovanni

Moy, Peter K

### Publication Date

2016

Peer reviewed



Alessandro Pozzi, Giovanni Polizzi, Peter K. Moy

## Guided surgery with tooth-supported templates for single missing teeth: A critical review



**Alessandro Pozzi, DDS, PhD**

Interim Chair Oral Surgery-Implant Dentistry, Marche Polytechnic University, Ancona, Italy

**Giovanni Polizzi, MD, DDS**

Director, Private Clinic BSC, Verona, Italy

**Peter K. Moy, DMD**

Nobel Biocare Endowed Chair, Surgical Implant Dentistry, Department of Oral & Maxillofacial Surgery, UCLA School of Dentistry, California, USA

**Correspondence to:**

Prof Alessandro Pozzi DDS, PhD  
Viale Liegi 44, 00198, Rome, Italy.  
Tel: +39 (335)6584894  
Email: studiopozzi@me.com

**Key words** *computer-assisted surgery, computer guided surgery, single-tooth implant*

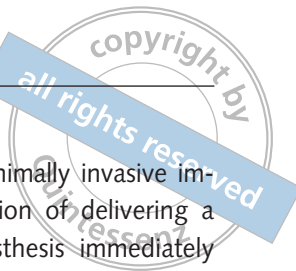**Aim:** To systematically scrutinise the scientific literature to evaluate the accuracy of computer-guided implant placement for single missing teeth, as well as to analyse the eventual clinical advantages and treatment outcomes.

**Material and methods:** The electronic and manual literature search of clinical studies published from January 2002 up to November 2015 was carried out using specified indexing terms. Outcomes were accuracy; implant and prosthetic failures; biological and mechanical complications; marginal bone loss (MBL); sulcus bleeding index (SBI); plaque score (PS); pink esthetic score [PES]; aesthetic and clinical outcomes.

**Results:** The search yielded 1027 relevant titles and abstracts, found during the electronic (n = 1020) and manual (n = 7) searches. After data extraction, and screening of titles, abstracts, and full-texts, 32 studies fulfilled inclusion criteria and were included in the critical review: two randomised controlled clinical trials, six prospective observational single cohort studies, one retrospective observational study, three *in vitro* comparative studies, 10 case reports and 10 systematic reviews. A total of 209 patients (18 to 67 years old) were treated with 342 implants using computer-guided implant surgery. The follow-up ranged from 12 to 52 months. The cumulative survival rate ranged from 96.5% to 100%. Eleven implant planning softwares and guided surgery systems were used and evaluated.

**Conclusions:** Computer-guided surgery for single missing teeth provides comprehensive treatment planning, reliable implant positioning, favourable clinical outcomes and aesthetics. A tooth-supported template for the treatment of single missing teeth results in greater accuracy of implant positioning than with mucosa-supported or bone-supported templates. The limited scientific evidence available suggests that guided surgery leads to implant survival rates as good as conventional freehand protocols. Computer-guided surgery implies additional costs, that should be analysed in terms of cost-effectiveness, considering the reduction of surgery time, postoperative pain and swelling, as well as, the potential increased accuracy. Long-term randomised clinical trials are eagerly needed to investigate the clinical performance of guided surgery in partially edentate patients.

**Conflict-of-interest statement:** *This review was performed by invitation from the Foundation for Oral Rehabilitation (FOR). This foundation is an independent, international initiative that unites professionals from various disciplines to improve oral health care and support humanitarian leadership and which provides no compensation for authors. The study was self-supported and the authors report no conflict of interest.*



## ■ Introduction

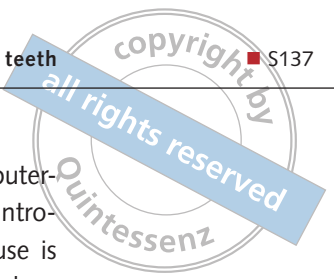
The actual standard of care for oral rehabilitation by means of implants expects not only the replacement of missing teeth in terms of function, but also the achievement of satisfactory aesthetics<sup>1</sup>. Optimal positioning of the implant through prosthetically driven decision-making is mandatory to achieve these goals<sup>2,3</sup>.

Since its development in the mid-nineties, computer-guided implant surgery has quickly gained popularity<sup>4-6</sup>. The introduction of cone beam computed tomography (CBCT), allowing volumetric jaw bone imaging at reasonable costs and low radiation doses<sup>7,8</sup>, facilitates the preoperative acquisition of large amounts of information<sup>9</sup> such as the available bone volume and quality, the presence and location of relevant anatomical structures and pathologies, and their relationship with the future rehabilitation.

Computer-aided methods may offer significant advantages in the treatment planning and help clinicians to perform successful implant-based rehabilitation while avoiding elevation of large mucoperiosteal flaps or eliminating them at all, causing less pain and discomfort to patients<sup>10-12</sup>. The surgeons, when operating freehand, commonly elevate mucoperiosteal flaps to better visualise the recipient site. This may become unnecessary when computer-guided implant placement is performed since the surgeon may trust the guidance provided by the surgical template.

Patients can benefit from having implants placed flapless and loaded immediately. However, to achieve this, the implant-based rehabilitation has to be carefully planned in advance<sup>10</sup>. The conventional freehand implant placement is challenged by several factors including patient movement during drilling, a restricted visualisation of the operative field which is limited to the tissues surface, interpretation and transfer of two-dimensional radiographs into the three-dimensional surgical environment, and the integration of aesthetic, biomechanical and functional constraints. Thus the surgeon has to take numerous decisions ranging from surgical aspects to the implant positioning in a limited time period. A thorough preoperative planning will free the surgeon's mind, allowing more time to concentrate on the patient and the tissue handling<sup>13</sup>.

The growing interest in minimally invasive implant placement with the option of delivering a pre-fabricated temporary prosthesis immediately to restore function and aesthetics, have led to the development of numerous three-dimensional (3D) planning software programmes<sup>4,14-19</sup>. The 3D visualisation of the implant recipient site characteristics and neighbouring anatomy provides the clinicians with more insight into the surgical, prosthetic and aesthetic requirements of the treatment and may enhance decision-making, increasing the reliability of the overall implant treatment<sup>10</sup>. Computer-guided implant placement implies 3D imaging of both the jaw bone and the planned prosthesis. Such integration of the planned prosthesis within the craniofacial model can be achieved through a double-scan technique with fiducial marker-based matching i.e. gutta-percha<sup>20</sup>. First, the patient is scanned with the prosthesis in the mouth, stabilised in the proper position by an occlusal silicone index. The planned prosthesis is then scanned separately, with different exposure parameters in order to allow its 3D visualisation in the software independently or overlapped to the patient anatomy. As the markers are visible in both sets of scans, they can be fused and the prosthesis properly positioned within the maxillofacial structures<sup>6,14</sup>. The double-scan technique with fiducial marker-based matching (i.e. gutta-percha) can also be a possible source for deviation both in partially edentulous and edentulous patients, if the matching is incorrect<sup>21</sup>. Furthermore, Pettersson et al<sup>22</sup> experienced that the automatic superimposing procedure of gutta-percha markers sometimes proceeded without any notification of errors, while motion artifacts were present. Therefore, the surgeon remains responsible for checking the accuracy of the procedure. A double-scan technique can be applied in partially edentulous patients, but the introduction of a novel digital integrated workflow offers an appealing alternative. A recently introduced 3D implant planning software (NobelClinician, Nobel Biocare, Kloten, Switzerland), automatically combines the Digital imaging and communications in medicine (DICOM) data belonging to the CT/CBCT examination of the patient with the STL data derived from the optical digital high-resolution scan of the preoperative patient master cast and tooth setup through a proprietary algorithm process (SmartFusionTM,



Nobel Biocare, Kloten, Switzerland). Therefore the cast is scanned and integrated with the craniofacial model to create a more accurate 3D model of the teeth<sup>23,24</sup>. It is thus possible to visualise hard and soft tissue anatomy and to obtain a more precise segmentation of the residual dentition.

An additional benefit to streamline the workflow comes from the use of an intraoral optical scanner to retrieve the surface scanning of the residual dental arch and soft tissue architecture<sup>25</sup>. A virtual digital wax-up is usually used to visualise the ideal prosthetic setup. Once the planning is completed and approved by the clinician, the digital information is used to produce the surgical stent or template that will be tooth-supported, with CAM rapid prototyping (milling or 3D printing).

Peri-implant soft tissue aesthetics constitute a relevant aspect of implant success and also one of the main motivating factors for a patient's decision toward implant therapy in the anterior maxilla<sup>26</sup>. Implant treatment in the aesthetic zone still represents a challenging task from both the surgical as well as the prosthodontic perspective<sup>27-29</sup>. It is well established that sufficient bone volume and favourable implant positioning are prerequisites for long-term aesthetic success<sup>26,29,30</sup>, even if peri-implant mucosal conditions depend heavily upon the underlying bone topography. Potential advantages of a computer-guided implant placement in the aesthetic site include a reduced mucosal recession and maximum preservation of peri-implant papillae in case the implant is properly positioned.<sup>29-32</sup>

However, after a few enthusiastic preliminary reports<sup>14,33</sup>, some prospective studies<sup>16,17,34-37</sup> drew attention to the potential 3D deviations between virtual planning and the actual final position of the implants. Computer-guided implant placement is technique-sensitive and perioperative complications have to be taken into account<sup>38</sup>. Although, in general, tooth-supported templates are more accurate than mucosa-supported ones<sup>15</sup>, the application of guided surgery to enhance single-tooth implant positioning and aesthetic outcome have so far not been widely reported in the literature.

One might assume that, in case of complex clinical scenarios, as immediate post-extraction implant placement, aesthetic zone and bone atrophy with closeness of critical anatomic structures, both

patients and clinicians could benefit from computer-guided template-assisted surgery. However, introducing new treatment methods for clinical use is always challenging. Moreover, in the rapid development of computer technology, the clinical benefit of computer-guided implant placement has to be consistently evaluated<sup>39</sup>. Otherwise the commercially driven marketing may become the guiding principle.

## ■ Aim

The aim of the present review was to systematically scrutinise the current scientific literature regarding the eventual clinical advantages of computer guidance of implant placement for single-tooth replacement using template-assisted surgery. The following question was addressed: is there scientific evidence supporting the hypothesis of a clinical advantage to the use of such computer-guided template-assisted implant placement for the rehabilitation of single missing teeth compared to conventional treatment protocols?

## ■ Materials and methods

### ■ Protocol

Prior to the systematic literature search, a review protocol was determined with the software Review Manager, version 5.2.

### ■ Structure of the review

The systematic review was edited according to the Preferred Reporting Items for Systematic Reviews and Meta-Analyses (PRISMA)<sup>40</sup>.

### ■ Eligibility criteria

The focused question was formulated according to the PICOS (P = Population/Patients; I = Intervention; C = Comparator/Control; O = Outcomes; S = Study Design) format, as suggested by the Center for Evidence-Based Medicine and served as a basis for the systematic literature search (Asking Focused Questions 2014):

- Patients: partial edentate patients (both jaws or either the maxilla or mandible) with single-tooth implant-retained fixed prosthesis.
- Interventions: insertion of either machined or rough-surfaced endosseous titanium single implants with a tapered or cylindrical form, by means of a computer-guided template-assisted implant surgery, irrespective of implant number, length, diameter, position, or angulation, into either residual or augmented bone, prosthodontic rehabilitation with fixed single dental prostheses, either screw-retained or cement-retained, according to an immediate, early or conventional loading protocol.
- Comparisons: single implant placement using different surgical procedures (computer-guided template-assisted vs conventional freehand approach), in one or between both jaws.
- Outcomes: accuracy, implant and prosthetic failures, biological and mechanical complications, marginal bone loss (MBL), sulcus bleeding index (SBI), plaque score (PS), pink esthetic score (PES), after an observation period of at least 1 year. However, no specific follow-up period was required to evaluate accuracy, surgical or prosthetic complications at implant insertion or patient-centered outcomes of surgery and immediate postoperative period.
- Study design: systematic reviews, randomised controlled trials (RCTs), prospective clinical studies, whose enrolled population needed to have at least five patients in each group. Retrospective clinical studies, clinical reports, or technical notes, were included, when providing relevant scientific information on the subject. Excluded from this review were studies not reporting on the above listed outcome variables, or publications with a follow-up < 12 months. The initial search included data from *in vivo*, *ex vivo* and *in vitro* studies written in English, and published from 2002 up to November 2015 in referred journals.
- Definitions: An implant planning using a 3D software and an implant placement by means of a computer-aided design-computer-aided manufacturing (CAD-CAM) surgical template was defined as 'computer-guided surgery'. An implant placement either freehand or assisted by a laboratory fabricated template was defined as

'conventional free hand surgery'. 'Accuracy' was defined as the difference in location or angulation between the computer-guided implant positioning and the final implant position in the patient mouth and evaluated as deviations at entry point, at the tip of the implant, in height, and at the implant axis. The loading protocols were defined as 'immediate loading', within 1 week after implant insertion, 'early loading', between 1 week and 2 months, and 'conventional loading' after a healing period of more than 2 months<sup>41</sup>. An implant was considered an 'implant failure' if it presented mobility, assessed by tapping or rocking the implant head with the metallic handles of two instruments, and/or any signs of radiolucency, progressive marginal bone loss or infection, and any mechanical complications (e.g. implant fracture) rendering the implant unusable, although still mechanically stable in the bone. A prosthesis was considered a 'prosthesis failure' if it needed to be replaced by an alternative prosthesis.

### ■ Information sources

The following electronic databases were scrutinised: PubMed database of the US National Library of Medicine (<http://www.ncbi.nlm.nih.gov/pubmed/>), SCOPUS scientific abstract and citation database ([www.scopus.com](http://www.scopus.com)) and the Cochrane Library (<http://www.cochranelibrary.com/>). According to the AMSTAR (<http://amstar.ca/index.php>) checklist, the grey literature was screened at the New York Academy of Medicine Grey Literature Report (<http://catalog.nyam.org>) in order to find possible unpublished works. A supplementary manual search in private databases (End Note libraries) and in the database of the following journals was conducted: Clinical Implant Dentistry and Related Research; Clinical Oral Implants Research; European Journal of Oral Implantology, International Journal of Oral and Maxillofacial Implants, Journal of Prosthetic Dentistry, Journal of Oral Implantology, International Journal of Computerized Dentistry, The International Journal of Periodontics and Restorative Dentistry. Additionally, new research excluding 'Dental/Oral Implants' and 'Single-Tooth' from the previously used MeSH terms was performed, followed by a manual search, in order to find single-tooth dental

implants placed using computer-assisted template-based surgery in larger cohorts of patients. Moreover, the authors used personal contacts in an attempt to identify unpublished or ongoing eligible studies. The authors of the eligible manuscripts were contacted, in case further information or data were needed. The results were limited to studies published between January 2002 and December 2015 in referred journals and written in English and Italian. The last date of the search was November 8, 2015.

### ■ Search strategy

The electronic search complied with the PICOS question addressing Patients, Intervention, Comparison, Outcome and Study design. An electronic literature search was carried out with the intention of collecting relevant information about accuracy; implant and prosthetic failures; biological and mechanical complications; MBL; clinical and aesthetic outcomes of single implants placed using computer-assisted template-based surgery. The electronic databases were searched using the following MeSH (Medical Subject Headings) terms: („Surgery, Computed/r-Assisted“ [Mesh] OR „Therapy, Computed/r-Assisted“ [Mesh] OR „Computer-Aided Design“ [Mesh]) AND („Dental/Oral Implants“ [Mesh] OR „Dental Implants, Single-Tooth“ [Mesh] OR „Dental Prosthesis, Implant-Supported“ [Mesh]).

Free text terms (“Implant treatment” OR “Computed guided” OR “Single-tooth gap” OR “Guided surgery”) were added to all searches.

### ■ Study selection

Study selection and data extraction were performed by two assessors (MT and SM) who independently read the articles and recommended inclusion or exclusion according to the predetermined criteria. To assess consistency among the reviewers, the inter-reviewer reliability using Cohen’s Kappa statistic ( $\kappa$ ) was analysed. Any disagreements were resolved by a discussion with the aim of reaching a consensus. The resulting initial hits of the above-mentioned search were screened, and a first preselection by title was undertaken. Titles were sequentially excluded if they indicated non-relevant content (e.g. no oral or dental implants, no single missing teeth, no single im-

plant-supported fixed dental prostheses). In case of any uncertainty, an additional abstract reading was performed. Abstracts of the selected titles were inspected for relevance resulting in a choice of possibly eligible full texts. If studies were published by the same author or institution several times, these manuscripts were thoroughly read and compared to avoid the inclusion of duplicate data. After full-text selection and data extraction, it was decided whether the publication was adequate for the intended systematic review. When at least one author considered that a publication met the initial inclusion criteria, the paper was ordered and read using the full text version.

### ■ Risk of bias within and across studies

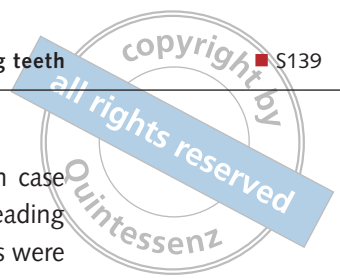
The potential risk of bias within the included studies was assessed using the methodology checklists provided by the Scottish Intercollegiate Guidelines Network (SIGN), which comprise the critical appraisal of the selection of subjects, the assessment used, potential confounders, the statistical analysis and the overall methodological quality of the study:

- High quality: (++) Majority of criteria met. Little or no risk of bias. Results unlikely to be changed by further research.
- Acceptable quality: (+) Most criteria met. Some flaws in the study with an associated risk of bias, conclusions may change in the light of further studies.
- Low quality: (-) Either most criteria not met, or significant flaws relating to key aspects of the study design. Conclusions are likely to change in the light of further studies.

The review included data extraction of only articles that reached a consensus between the reviewers as ‘High and Acceptable quality’

### ■ Data extraction, interpretation and evaluation of evidence from retrieved literature

Extracted data were added to predefined forms, which included the following parameters: author, year, total number of patients/prostheses investigated, observation period, total number of implants,



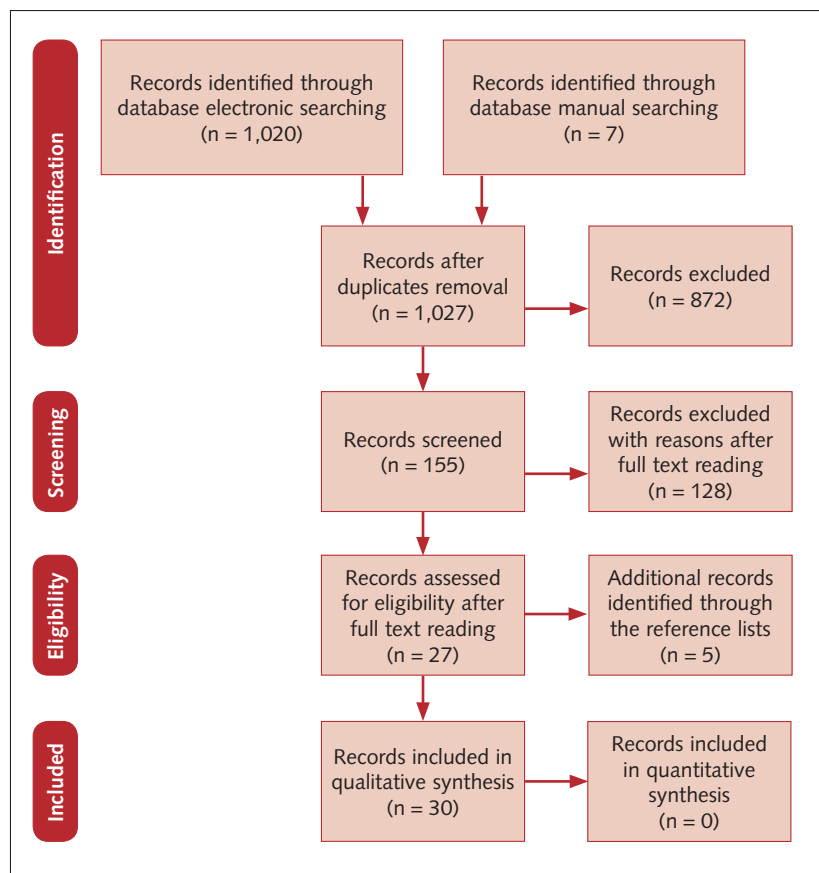
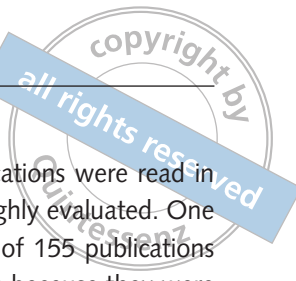

Fig 1 Flow chart of search process and retrieval of publications.

number and time of dropouts on implant level, number of implants per patient, type of implant prosthesis, type of anchorage system, implant survival and implant losses before and after loading. In addition, implant system, implant surface, loading protocol and bone augmentation procedures were noted. All variables were predetermined and no additional variables were added after the reviewing had started.

## ■ Results

### ■ Literature search

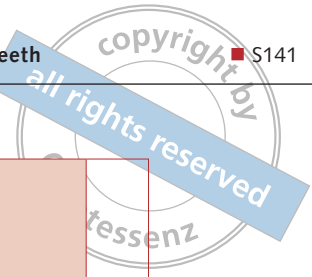
Figure 1 depicts a flow chart of the selection process for publications relevant to our review. The first step of the search, using a series of combined search terms, yielded 1027 potentially relevant titles and abstracts, found during the electronic ( $n = 1020$ ) and manual ( $n = 7$ ) searches. During the first step of study selection, 872 publications were excluded based on their title and abstract (inter-reviewer agreement;

$k = 0.72$ ). Therefore 155 publications were read in the full text version and thoroughly evaluated. One hundred and twenty-eight out of 155 publications had to be excluded at this stage because they were 'low quality' due to either most criteria not being met, or because significant flaws relating to key aspects of study design were found (inter-reviewer agreement;  $k = 0.99$ ). A manual search of reference lists and systematic reviews provided five additional publications for inclusion which fulfilled the inclusion criteria and quality assessment required for this critical review. A total of 32 manuscripts reporting on guided surgery for single missing teeth were identified and included in the review: two randomised controlled clinical trials<sup>10,43</sup>, six prospective single cohort studies<sup>17,44-48</sup>, one retrospective study<sup>32</sup>, three *in vitro* comparative study<sup>48-50</sup>, 10 cases reports<sup>51-61</sup> and 10 reviews of the literature<sup>13,38,39,62-68</sup>.

### ■ Accuracy of computer-guided template-assisted surgery for missing single teeth

The most common concern in implant surgery regarding computer-guided surgery is the accuracy associated with transference of the virtual data for the planned implant position to the actual surgical procedure to place the implant and its final position intraorally. Accuracy is defined as the deviation between the position of the 'planned' and the 'inserted' implant<sup>13</sup>. The accuracy is most often verified via a second, postoperative CBCT, through dedicated software that allow the matching of preoperative and postoperative implant positioning. Alternatively, preoperative and postoperative master casts can be compared ('model matching')<sup>34</sup>. The accuracy is commonly investigated at four levels: deviation at the entry point, deviation at the apex, deviation of the long axis (angulation) and deviation in depth. More recently, additional attention has been given to deviations in mesiodistal and buccolingual direction<sup>13, 21</sup>.

Understanding the accuracy of a computer-guided implant surgery system is of paramount importance for the clinician during virtual implant position planning and accounting for the 'safety zone' that is factored in all implant planning software programs. The 'safety zone' feature establishes a dimension measured in mm to provide a margin of



safety from vital anatomic structures or neighbouring components such as the implant body<sup>9</sup>.

Several reviews of scientific literature have been performed to evaluate the accuracy of stereolithographic surgical templates<sup>13,38,39,61-68</sup>. Schneider and colleagues<sup>65</sup> calculated a mean deviation of 1.1 mm (95% CI: 0.8 to 1.2 mm) at the implant shoulder and 1.6 mm (95% CI: 1.3 to 2.0 mm) at the apex; 0.5 mm in height and 5° to 6° in axis. D'haese and colleagues<sup>68</sup> reported coronal deviations ranging between 0.20 and 1.45 mm (mean 1.04 mm), apical deviations ranging between 0.95 and 2.99 mm (mean 1.64 mm) and mean angular deviation ranging between 0.17° and 7.90° (mean 3.54). Van Assche and colleagues (meta-analysis)<sup>61</sup> reported a mean error of 1.0 mm (95% CI: 0.7 to 1.3 mm) at the entry, 1.4 mm (95% CI: 1.1 to 1.7 mm) at the apex, and a mean angular deviation of 4.2° (95% CI: 3.6° to 5.0°) when analysing *in vivo* studies. They took into consideration up to nine different computer-assisted systems, *in vivo*, *ex vivo* and *in vitro* studies, stereolithographic and laboratory fabricated templates, different surgical templates classified according to the type of support provided for the surgical template based on specific anatomic structures (bone, mucosa or teeth), and different preoperative and operative workflows (fully guided, semi-guided, freehand dilation of the borehole and freehand implant placement). These studies address the accuracy of computer-guided implant placement in different ways, making interstudy comparison difficult. A standardisation of research parameters will lead to a better comparison of research outcome data.

Although various clinical studies have specifically measured the accuracy of tooth-supported CAD/CAM templates for missing single teeth, most of these investigations due to the intrinsic nature of their study design, were unable to determine whether the computer-guided implant surgery was more accurate than the freehand conventional implant placement. The data is summarised in Table 1. Two *in vivo* prospective studies and 1 *in vivo* retrospective study investigated the accuracy of 55 implants placed with computer-guided template-assisted surgery<sup>31,43,44</sup>. One *in vivo* prospective study reported on the accuracy of 18 implants planned with computer-assisted method and placed

**Table 1** In vivo accuracy of computer-guided/computer assisted surgery for missing single teeth: deviations from the planned position (mean ± SD [range]).

Study	Implant Number	Implant procedure	Entry Point mm (range mm)	Apex Point mm (range mm)	Angle ° (range °)	
Behneke et al 2012*	19	Computer-guided planning laboratory-fabricated template.	0.21 ± 0.16 (0.01-0.92)	0.32 ± 0.34 (0.03-0.59)	1.35±1.11 (0.07-3.33)	
Ersoy et al 2008**	9	Computer-guided planning stereolithographic-template.	0.74 ± 0.40	1.66 ± 0.28	3.71 ± 0.93	
Furhauser et al 2014***	27	Computer-guided planning stereolithographic-template.	0.84 ± 0.44 (0-1.6)	1.16 ± 0.69 (0-2.6)	2.7 ± 2.6 (0-12.7)	
<b>Study</b>	<b>Implant Number</b>	<b>Implant procedure</b>	<b>MI Distance: mesial tooth to the implant fixture</b>	<b>DI Distance: distal tooth to the implant fixture</b>	<b>LI Distance: lingual plan to the implant fixture</b>	<b>IT angle: clinical crown to the implant fixture</b>
Bencharit et al 2015#	18	Computer-guided planning hand-free implant placement	-0.02 (-0.40, 0.37)	-0.02 (-0.42, 0.39)	-0.11 (-0.73, 0.50)	1.23 (-1.59, 4.05)
<b>Study</b>	<b>Implant Number</b>	<b>Implant procedure</b>	<b>Entry Point mm (range mm)</b>	<b>Apex Point mm (range mm)</b>		
Farley et al 2012§	10	Computer-guided planning stereolithographic-template	-1.20 ± 0.70 mm vertical	-1.24 ± 0.68 mm vertical	1.11 ± 0.71 mm horizontal	
			0.638 ± 0.370 mm horizontal	-1.59 ± 1.09 mm vertical	1.84 ± 0.97 mm horizontal	
10	Computer-guided planning laboratory-fabricated template	-1.51 ± 1.02 mm vertical	1.15 ± 0.57 mm horizontal			

\* Software implant 3D (med3D GmbH, Heidelberg, Germany system) and the Schick Hexapod positioning device (X1med3D positioner; SchickDental GmbH, Schemmerhofen, Germany).  
 \*\* Stent Cad (Media Lab Software, La Spezia, Italy).  
 \*\*\* NobelClinician (Nobel Biocare, AG, Zurich, Switzerland).  
 # SimPlant Pro 15 (Dentsply, Waltham, Massachusetts, USA).  
 § iDent software (iDent Imaging, Ft. Lauderdale, Florida, USA)





**Table 2** Comparison of the potential sources of deviations in the double scan protocol and in the integrated digital workflow for tooth supported CAD/CAM surgical template.

	Impression taking	Master cast pouring	Rx template Scan prostheses laboratory fabrication	Fit Rx template patient mouth	Optical scanning master cast tooth set-up	Intraoral optical scanning	CBCT intrinsic errors CBCT/patient movements	Correct segmentation matching process	Adequate implant planning	CAD/CAM template production	CAD/CAM template fitting	Tolerance surgical sleeve/drill guide/drill	Limited mouth opening reduced inter-arch clearance tight surgical space Kennedy Class I-II
Double Scan	√	√	√	√	-	-	√	√	√	√	√	√	√
Conventional digital workflow	√	-	-	-	√	-	√	√	√	√	√	√	√
Fully Digital workflow	-	-	-	-	-	√	√	√	√	√	√	√	√


with a conventional freehand approach<sup>47</sup>. Only one randomised split-mouth prospective trial has compared the accuracy of computer-guided surgery CAD/CAM templates with conventional laboratory fabricated templates for the treatment of a single-tooth gap<sup>41</sup>. The split-mouth design used by Farley et al<sup>42</sup>, allowed for a comparison of the accuracy of the two templates within the same patients, minimising bias and variability, and is the only source of evidence that was able to determine whether the computer-guided implant surgery was more accurate than the freehand conventional implant placement. All the implants were planned with the same 3D implant planning software and then allocated toward one of the two groups. Twenty single implants were placed in 10 patients. At entry point, implants placed with the CAD/CAM guides deviated more from the planned positions in a vertical direction ( $-1.20 \pm 0.70$  mm) than in the horizontal direction ( $0.638 \pm 0.37$  mm), while conventional guides had greater vertical and horizontal distance deviations ( $-1.51 \pm 1.02$  mm and  $1.15 \pm 0.57$  mm, respectively) than CAD/CAM guides. At the tip of the implant, vertical ( $-1.24 \pm 0.68$  mm) and horizontal ( $1.11 \pm 0.71$  mm) differences for CAD/CAM guides were similar, while for conventional guides the vertical error was  $-1.59 \pm 1.09$  and the horizontal error was  $1.84 \pm 0.97$  mm. Single implants placed with CAD/CAM surgical guides were generally closer to

the planned positions in all eight categories examined, however statistically significant differences ( $P = 0.0409$ ) were shown only at the entry point per horizontal deviation, providing greater accuracy than implants placed with conventional guides. In addition, CAD/CAM guides were more consistent in their deviation from the planned locations than conventional guides.

Several factors leading to inaccuracy have been identified: presence of debris in the drilled hole preventing the implant from reaching its final position, resilience of mucosal tissues, setting of the radiological Gray values during segmentation, improper seating of the template and deformation of the guide during surgery<sup>20,37,69,70</sup>.

Deviations may reflect the sum of all errors occurring, which includes imaging, the transformation of data into a guide and the improper positioning of the latter during surgery. All errors can eventually have a cumulative effect (Table 2).

The present paper reviewed the computer-guided surgery accuracy according to four factors that presumably may influence the overall outcome: type of arch (maxilla/mandible), kind of template (single-tooth gap/interrupted dental arch/shortened dental arch/reduced residual dentition), type of guided surgery (fully guided placement/freehand placement/freehand dilation of the borehole) and the surgical technique (flapless/open flap)<sup>43</sup>.



### ■ Type of arch (maxilla/ mandible)

In a prospective study<sup>44</sup>, 52 partially edentulous subjects received 132 implants. Nineteen implants were placed to restore a single-tooth gap in 19 partially edentate patients. Preoperative planning was merged with postoperative CBCT data to identify linear and angular deviations between virtually planned and placed implants. No essential differences could be found regarding the influence of the type of arch. After the matching procedure, a borderline significant difference was found between maxillae and mandibles for the linear deviation at the tip of the implants, which was larger in the maxillae (0.50 vs 0.40 mm,  $P = 0.033$ ), while no significant differences were found for the linear regarding the linear deviation at the neck or the angular deviation. These low deviations are clinically not meaningful. These findings are in partial agreement with previously published studies not limited to missing single teeth<sup>16,71,72</sup>, reporting that the maxilla is more susceptible to transfer inaccuracies than the compact mandibular bone. The lower accuracy in the maxillary cases may be determined by the type of template support. In completely edentulous patients the mucosal resilience could result in micromovements and lack of accuracy, where as in the single missing tooth situation, the surgical template will always be tooth-borne, providing more stability.

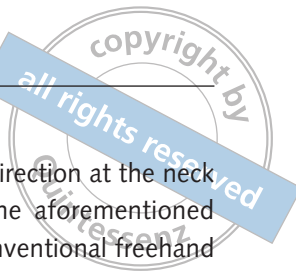### ■ Type of template (single-tooth gap/ interrupted dental arch/shortened dental arch/reduced residual dentition)

Low deviations can be observed, if single-tooth gaps with mesial and distal tooth-supported templates are treated. A mean error of  $0.21 \pm 0.16$  mm (range 0.01 to 0.92) at the entry point,  $0.32 \pm 0.34$  mm (range 0.03 to 0.59) at the tip of the implant, and  $1.35^\circ \pm 1.11^\circ$  (range  $0.07^\circ$  to  $3.33^\circ$ ) of the radial deviation at the tip were reported for single-tooth gap surgery<sup>42</sup>. Thus there was significantly less deviation at the tip for the single-tooth loss group than for the partially edentulous group. A wider variation of values was reported for sites with a reduced residual dentition, as only a few teeth could ensure the support of the guide. Therefore a larger deviation for templates with unilateral anchorage could be

expected due to tilting and bending of the template itself<sup>42</sup>. The use of a rigid material for fabricating the surgical template or the relining of the templates in order to obtain sufficient stiffness to prevent such tilting should be advocated. This observation corroborates findings previously reported by Ersoy et al<sup>45</sup>, reporting a mean error of  $0.74 \pm 0.40$  mm at the implant neck,  $1.66 \pm 0.28$  mm at the tip, and an angular deviation of  $3.71^\circ \pm 0.93^\circ$  for nine implants placed with single tooth gap supported templates; and  $1.23 \pm 0.67$  at the implant neck,  $1.59 \pm 0.74$  at the apex, and an angular deviation of  $4.78 \pm 1.86$  for 20 implants placed with free-ending tooth-supported templates in Kennedy Class I or II partial edentate patients. A statistically significant higher accuracy was measured for single tooth gap supported templates compared to partially and edentulous patients. These results agreed with D'haese et al<sup>63</sup>, a systematic review indicating that tooth-supported guides showed significantly smaller deviations compared with mucosal- and bone-supported guides:  $0.87 \pm 0.40$  mm (coronal deviation),  $0.95 \pm 0.60$  mm (apical deviation) and  $2.94^\circ$  (angular deviation) These results are also in accordance with the third EAO Consensus Conference 2012 concluding that tooth- and mucosa-supported templates can give more accurate results than bone-supported templates<sup>62,73</sup>.

### ■ Type of guided surgery (fully guided placement, semi-guided placement/ pilot drilling with freehand dilation of the borehole and freehand implant placement)

The titanium sleeves fixed in the surgical template may be used for different steps of the site preparation up to the implant placement. The use of the template can be limited to guide the pilot drilling or for the entire osteotomy up to the implant placement. Nevertheless, particularly in situations with limited mouth opening or restricted interarch clearance, surgical guides may interfere with the effective use of the drills in the posterior quadrants and therefore the templates may be used only for the initial steps of implant bed preparation, affecting the overall accuracy of the procedure. Moreover, intrinsic inaccuracies of hardware must be addressed to



minimise inaccuracies resulting from the fit of instrumentation through the surgical template and the fit of the template to the dentition<sup>74-79</sup>.

Behneke et al<sup>44</sup> reported in partially edentulous patients that the freehand dilation of the borehole, results in significantly less accuracy than that achieved with fully template-guided drilling and implant placement. A mean error of  $0.21 \pm 0.20$  mm (range 0.03 to 0.60) at the entry point,  $0.28 \pm 0.24$  mm (range 0.03 to 0.77) at the implant tip, and  $1.49^\circ \pm 1.39^\circ$  (range  $0.07^\circ$  to  $4.53^\circ$ ) of apical radial deviation were reported for fully guided implant placement, which means that maximum deviations measured were 0.6 mm at the entrance, 0.77 mm at the tip, and thus distinctly lower than the safety zone of 1.5 mm, usually recommended by most of the planning softwares<sup>10</sup>.

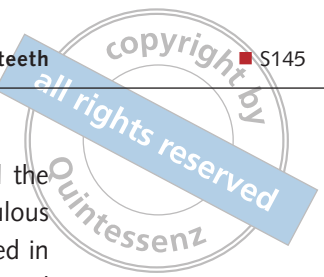
The aforementioned mean deviations are also lower than those experienced by Fürhauser et al<sup>32</sup> using stereolithographic templates for the rehabilitation of single-tooth implants in the anterior maxilla by superimposition of CBCT scans, with a mean follow-up of 2.3 years. The mean deviation between planned and actual implant position was  $0.84 \pm 0.44$  mm at the implant shoulder (range: 0 to 1.6 mm) and  $1.16 \pm 0.69$  mm at the implant tip (range: 0–2.6 mm). Mean angular deviation was  $2.7^\circ \pm 2.6^\circ$  (range:  $0^\circ$ – $12.7^\circ$ ) and was significantly correlated to the deviation at the tip but not at the implant shoulder.

To clarify whether computer-guided surgery offers a better accuracy it is important to compare it to the accuracy of the freehand implant placement. Two *in vitro* studies examined this issue. They reported a maximum error at the entry point ranging from 0.80 to 1.00 mm<sup>49</sup> and a mean error at the entry point of 1.35 mm<sup>50</sup> for the conventional freehand surgery. Both studies demonstrated a statistically significant higher accuracy for the computer-guided systems compared to the freehand implant placement. This is in agreement with the clinical findings of Farley et al<sup>42</sup>, who in a split-mouth comparison of implant placement for missing single teeth, which compared planned and actual implant positions using three-dimensional analyses, showing that implants placed with CAD/CAM guides were closer to the planned positions in all eight categories examined, but this reached sig-

nificance only in a horizontal direction at the neck of the implants. Therefore, the aforementioned deviations reported for the conventional freehand surgery seem higher than the similar deviations reported using computer-guided surgery for the rehabilitation of single missing teeth<sup>32,44,45</sup>.

### ■ Regarding the surgical technique (flapless/open flap)

In a prospective clinical study, Behneke et al<sup>44</sup>, compared the computer-guided surgery accuracy when the soft tissue was punched (flapless implant placement) with the conventional technique when a full-thickness flap was raised. A borderline significance ( $P = 0.027$ ) was found between both conditions for the implant neck radial deviations (slightly higher values for the flapless approach). For the linear deviation at the implant apex, and for the angular deviation, no significant differences were found. Flap elevation did not negatively influence the positioning of the tooth-supported surgical templates. These findings were in agreement with the results reported by the clinical study of Ersoy et al<sup>45</sup>, who could not find any difference in accuracy for the open flap procedure vs the flapless procedure for completely or partially edentulous patients. In a retrospective study, Fürhauser et al<sup>32</sup> reported on the 3D accuracy of 27 single-tooth implants placed for delayed replacement of upper incisors, using stereolithographic templates. Regardless of the mean deviations reported, highly aesthetic and predictable results were achieved by flapless implant placement using guided surgery in the anterior maxilla. The aesthetic outcome was evaluated using the PES<sup>80</sup>. The authors found that the 3D inaccuracy is low in guided implant surgery (median PES: 13,  $P = 0.039$ ), but, on the other hand, small deviations, toward the labial/buccal aspect  $\geq 0.8$  mm, resulted in significantly worse implant aesthetics in the anterior maxilla (median PES: 9.5) compared with more accurate implant positions. These results confirm the hypothesis that the three-dimensional implant position has an important influence on the aesthetic outcome, for example an implant position angled too far to the facial will result in an increased crown length compared to the contralateral tooth as well as mid-facial (bone or gingival) recession over time<sup>81</sup>.



Avoidance of flap elevation seems to benefit peri-implant mucosal conditions, particularly in terms of maximum preservation of peri-implant papillae and reduced mucosal recession when there is sufficient mesial-distal dimension, in agreement with previous evidence<sup>82</sup>. However, soft tissue punching and removal, generally associated with a flapless approach, may not be indicated in patients with a narrow zone of keratinized mucosa and limited soft tissue volume or mesial-distal space. In such instances, surgical modifications, such as punch reposition or limited flap technique<sup>83</sup> may be favoured.

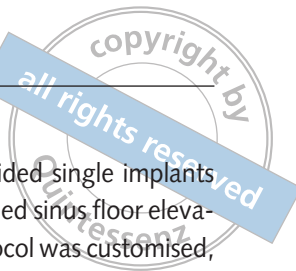### ■ Clinical outcomes of computer-guided template-assisted surgery for single missing teeth

Computer-guided surgery has been developed to allow for more comprehensive preoperative planning and a implant placement, with adequate consideration of the future prosthetic suprastructure, in terms of efficiency and aesthetics. Only few clinical studies investigating the clinical outcome of the computer-guided surgery for missing single teeth have been published to date. Two randomised controlled clinical trials<sup>10,42</sup>, six prospective single cohort studies<sup>17,43-47</sup>, one retrospective study<sup>32</sup> and 10 case reports<sup>51-60</sup> treating single-tooth gaps were identified and included in the review. A total amount of 342 single implants were placed in 209 patients (18 to 67 years old). The follow-up ranged from 12 to 52 months. The cumulative survival rate ranged from 96.5% to 100.0%.

The NobelClinician software and the pristine version NobelGuide (Nobel Biocare, Kloten, Switzerland) software was the most investigated<sup>10,17,32,84</sup>. Other 3D implant software programs evaluated include: SimPlant (Dentsply, Massachusetts, USA)<sup>47,59,60</sup>, Implant 3D (med3D, Heidelberg, Germany)<sup>44</sup>, iDent software (iDent Imaging, Florida, USA)<sup>42</sup>, Stent Cad (Media Lab Software, La Spezia, Italy)<sup>45</sup>, Codiagnostix (Dental Wings Inc, Montreal, Canada)<sup>51</sup>, Facilitate (Astra Tech, Dentsply Implants, Mölndal, Sweden)<sup>53</sup>, Dental Slice Program version 2.7.2 (BioParts Prototipagem Biomedica, Brasilia, Brazil)<sup>54</sup>, Micerium Implant Planning software (Micerium, Avegno, Italy)<sup>55</sup>, Ray Set implant software (Biaggini Medical Devices, La Spezia, Italy)<sup>57</sup> and ImplantMaster (I-Dent, Hod Hasharon, Israel)<sup>58</sup>.

However, most of these studies examined the clinical performance in completely edentulous patients, with little or no evaluations performed in the partially edentulous patients. Only two clinical randomised controlled trials<sup>10,42</sup> have been published reporting the clinical outcomes of computer-guided template-assisted implant placement, compared to freehand surgery, for the treatment of a single-tooth gap. Pozzi et al<sup>10</sup> used the 3D implant planning software (NobelClinician, Nobel Biocare, Kloten, Switzerland) to plan 51 patient treatments (partially edentate:  $n = 22$ ; fully edentate:  $n = 29$ ). They were randomly allocated toward either the flapless or mini-flap approach. All were immediately loaded. A total of 202 implants were placed, where 37 implants were used to rehabilitate a missing single tooth either by means of computer-guided surgery (19 implants in nine patients) or freehand surgery (18 implants in 10 patients). No dropouts occurred and all patients were followed up to 1 year after loading. No implant or prosthesis failures have been observed at 1 year follow-up yielding implant and prosthetic survival rates of 100%. Extrapolating the data related to the treatment of the single-tooth gaps 1 year after loading, implants of the computer-guided group lost  $0.71 \pm 0.44$  mm of marginal bone versus  $0.95 \pm 0.25$  mm for the freehand surgery group ( $P = 0$ ). All patients followed a tight recall appointment schedule and at 1 year, no bleeding on probing and only small amounts of plaque were recorded. Papilla improvement over time was observed (PI: 93.7%). This multicenter randomised controlled trial was conducted to understand which procedure is preferred after having planned the treatment with a dedicated implant software on the 3D CBCT scan. Both techniques were able to achieve the planned goals. The only significant difference was more postoperative discomfort (self-reported pain and swelling) for patients having implants placed freehand, most likely due to more frequent use of flap elevation in the latter group.

The split-mouth study used by Farley et al<sup>42</sup> compared the accuracy of computer-guided surgery assisted by a CAD/CAM template to conventional freehand surgery, which was assisted by a laboratory hand-crafted template, in the treatment of the single-tooth gap. Ten patients were selected for this study with symmetric edentulous areas in the mandible



and with similar bone heights. This accommodated the use of the same implant size on each side. The iDent software was used to plan the implant positioning of both groups and to design the CAD/CAM surgical template. The authors did not report any difference regarding the clinical outcomes between the groups for the 20 implants placed. Neither implant nor prosthesis failures were experienced.

Vasak et al<sup>17</sup>, conducted a 12-month prospective clinical study on the use of computer-guided surgery (NobelClinician) with respect to implant success and survival rates, which resulted in peri-implant soft tissue conditions and potential surgical and prosthetic complications. Thirty patients with partially dentate and edentulous maxillae or mandibles were included. All patients were treated using computer-guided surgery. Overall, 163 implants were placed (mandible/maxilla = 107/56 implants). All 30 patients and 161 implants completed the 1-year follow-up resulting in a cumulative survival rate of 98.8%. For eight patients it concerned the restoration of single missing teeth using one-stage implant surgery achieving a primary stability  $\geq 35$  Ncm, and immediately restored with single crowns, which achieved occlusal contact. Both implant and prosthetic survival rates were 100%. Clinical soft tissue parameters improved in a majority of the implants.

Nikzad et al<sup>46</sup>, evaluating the outcome of computer-guided flapless surgery for the treatment of partially edentulous patients in a prospective 12-month clinical study also reported an overall implant survival rate of 96.5% (57 implants placed in the mandible of 16 patients). The mean marginal bone loss after 1 year of follow-up was  $0.6 \pm 0.2$  mm mesially and  $0.5 \pm 0.1$  mm distally, meaning the authors concluded that CAD/CAM technology and flapless implant surgery is reliable in partially edentulous patients. Ersoy et al<sup>45</sup> reported on 21 consecutive patients (seven with missing single teeth and seven partially edentulous) treated with computer-generated stereolithographic surgical guides. The cumulative implant survival rate was 100%.

Pozzi and Moy<sup>84</sup> designed a prospective, cohort study to validate the proof of concept of a minimally invasive surgical technique for sinus elevation using computer-guided surgery and CAD/CAM fabricated templates (NobelClinician), in combination with expander-condensing osteotomes. In 66 consecu-

tive patients, 136 computer-guided single implants were placed by transcresal-guided sinus floor elevation technique. The drilling protocol was customised, based on the bone density of each implant site to achieve an insertion torque ranging between 45 and 55 Ncm, thus allowing immediate provisionalisation. Mean follow-up was 43.96 (range: 36 to 52) months. Cumulative implant survival rate was 98.53%. No biological or mechanical complications were encountered and no prosthetic failures occurred during the entire follow-up period. Mean marginal bone loss during the first year of function was  $0.33 \pm 0.36$  mm, while at the 3-year follow-up, the mean MBL was  $0.51 \pm 0.29$  mm. The mean residual bone height of the alveolar crest prior to surgery was  $6.7 \pm 1.6$  mm (range 5.1 to 9.2 mm), while, the mean bone height gained was  $6.4 \pm 1.6$  mm (range 3.2 to 8.1 mm). All patients reported low levels of postoperative pain.

In some single-tooth gaps, the proper seating of the CAD/CAM template can be hampered due to the limited amount of space available thus limiting the use of a fully guided sleeve. As an alternative, Edelmann et al<sup>47</sup>, recently reported that the 3D implant planning performed on dedicated software coupled a semi guided sleeve and a conventional freehand 1-to-2-drill osteotomy preparation protocol may allow appropriate implant placement, overcoming the problem related to the fitting of the fully guided template in tight surgical spaces. They enrolled 18 patients requiring extraction of a tooth followed by a single immediate implant placement. Small volume preoperative CBCT scans were used. The planning of implant positioning and implant size was performed using SimPlant Pro 15 software. Eighteen tapered screw implants were immediately placed in the aesthetic zone into fresh extraction sockets and immediately loaded. The implant and prosthesis cumulative survival rate reached 100%. Postoperative CBCTs were used for the analysis of actual implant positionings. The analysis showed no statistical difference between the planned position and final implant placement position in any measurement.

Using the software program Implant 3D, Behneke et al<sup>44</sup> reported on the clinical outcomes of 52 partially edentulous patients. Guidance was provided by laboratory-fabricated tooth-borne templates. Out of a total of 132 implants 19 were placed to rehabili-



tate single missing teeth. The cumulative implant survival rate was 100%. The implants were placed fully guided, with freehand implant placement after having drilled through the template sleeve, and freehand final drilling and implant placement. Significant differences were seen at all aspects of measurement (implant shoulder level, apical level and angulation), yielding generally higher deviations for the freehand final drilling and implant placement group.

For the aesthetic outcomes of computer-guided surgery, compared to freehand surgery for managing a single tooth gap, limited data are available. In a retrospective study, Fürhauser et al<sup>85</sup> reported the 3D accuracy of 27 single-tooth implants, placed for delayed replacement of upper incisors, using computer-assisted implant treatment planning software (NobelClinician) and stereolithographic templates. No implant or prosthetic failures were reported. They assessed the aesthetic outcome using the PES<sup>80</sup>. The authors found that the 3D inaccuracy is low in computer-guided implant surgery. Nevertheless, deviations toward the buccal side  $\geq 0.8$  mm resulted in significantly worse implant aesthetics (median PES: 9.5, IQR: 8 to 11) compared with more accurate implant positions (mean PES: 13, IQR: 12 to 13). These results confirm the hypothesis that the three-dimensional implant position has an important influence on the aesthetic outcome. Within the deviations reported, the inaccuracy toward the buccal side was the most frequent at 70%, and may result in an increased crown length compared to the contralateral tooth and in midfacial gingival recession over time.

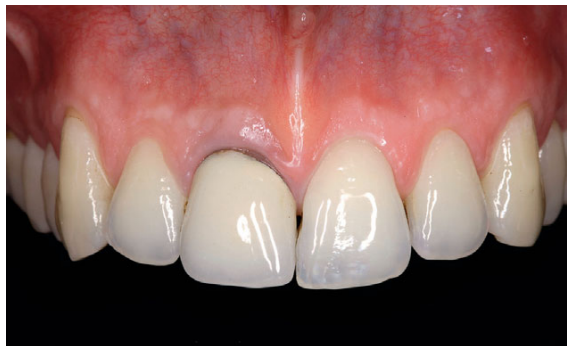Moreover, computer-guided surgery showed significantly better results regarding mesial papilla presence (89% vs 57%,  $P < 0.001$ ), distal papilla presence (81% vs 61%,  $p = 0.010$ ), as well as natural soft tissue contour (67% vs 43%,  $p = 0.004$ ) with a mean follow-up of 2.3 years<sup>32</sup>, compared with other studies<sup>85-87</sup>, in which the PES score was used to evaluate the outcome of single-tooth implant aesthetics in the anterior maxilla following delayed placement with flap elevation. These findings may be attributed to less damage to interdental gingiva and favourable mucosal contouring by soft tissue punching using the flapless surgical approach. High aesthetic and predictable results may be achieved by flapless computer-guided implant placement, demonstrating that preplanned implant positions in

the 3D software are precisely translated into surgical reality and, therefore, enhanced the achievement of a favourable emergence profile and soft tissue architecture in the aesthetic zone<sup>54,56,59,85</sup>, as well as in the posterior quadrants<sup>58</sup>.

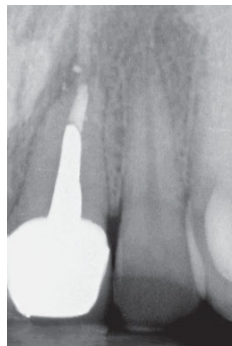Kamposiora et al<sup>53</sup> published a clinical report of two patients who belong to a larger ongoing clinical trial of 20 patients with missing single tooth in the aesthetic zone. The Facilitate 3D implant planning software was used to fabricate stereolithographic models, surgical templates and a zirconium dioxide definitive abutment with a provisional crown. The implants were placed with a flapless approach and the abutments immediately delivered and provisionalised. A final restoration was fabricated from all-ceramic material after several months. The stereolithographic model was used to simulate the surgical procedure and allow a real zirconia implant abutment to be fabricated and placed in position using the surgical template. The authors were contacted in order to implement their data, by considering the entire sample of 20 patients. No implant and prosthetic failures were experienced at 1-year follow-up. The only complication reported were small occlusal adjustments to compensate for the inaccuracy of the guidance system in the z axis. Mandelaris et al<sup>60</sup>, more recently, confirmed how the digital integrated workflow allow novel streamline tooth replacement strategies as the fabrication of a CAD/CAM patient-specific abutment before surgical treatment. They performed a flapless minimal invasive implant placement with simultaneous delivery of a CAD/CAM customised abutment and a provisional crown with no occlusal contact, in a single visit. The result was a preserved emergence profile in the presence of high aesthetic results<sup>57</sup>.

#### ■ Clinical relevance and recent developments

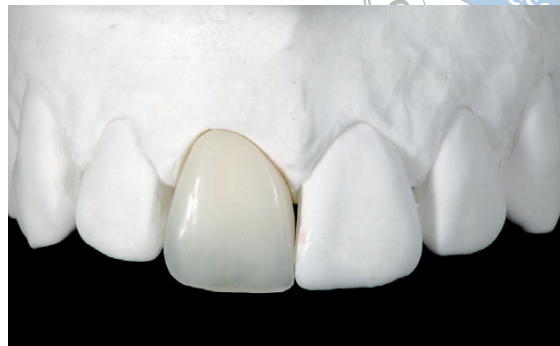The surgeons should not put blind trust on the transfer precision from the 3D virtual planning. Although, in general, tooth-supported templates are accurate, the application of guided surgery to enhance single-tooth implant positioning and aesthetic outcome have so far not been widely investigated. Clinicians should not only consider the mean inaccuracy but the largest reported, in order to treat with adequate safety.



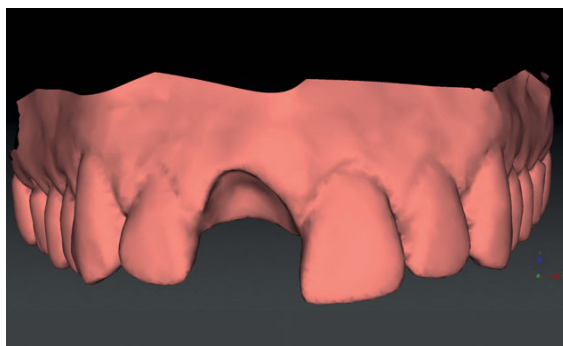
**Fig 2** Pre-operative frontal view of anterior maxilla with failed PFM crown and fistula; thin gingival biotype.



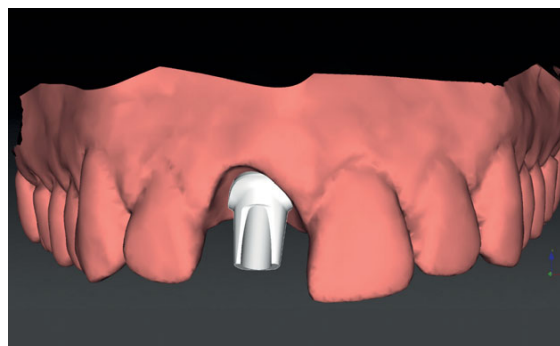
**Fig 3** Preoperative radiograph showed the metal post the periapical infection. The inter-proximal bone peaks are maintained.



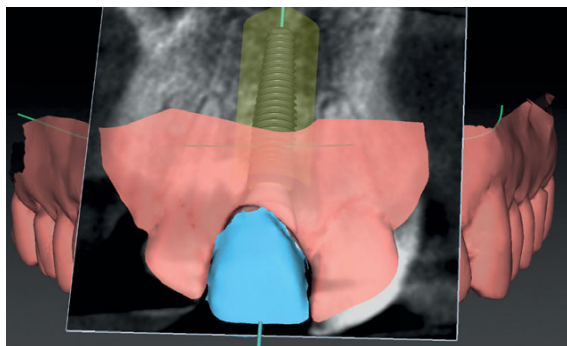
**Fig 4** Preoperative master cast with the temporary crown to be delivered the day of the tooth extraction and implant placement. The patient model was scanned with a digital high resolution optical scanner.



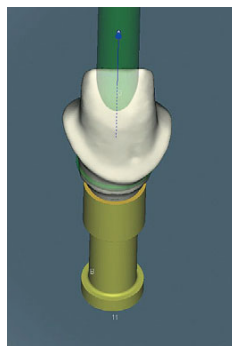
**Fig 5** Three-dimensional visualisation of the patient upper arch surface anatomy without the central incisor to show the ideal soft tissue architecture and prosthetic emergence.



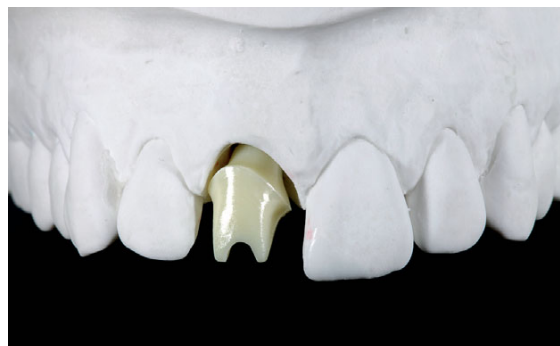**Fig 6a** Three-dimensional visualisation of the patient upper arch surface anatomy with the CAD-designed anatomic abutment in accordance with the ideal gingival margin, papilla height and prosthetic emergence.



**Fig 6b** Three-dimensional visualisation of the patient surface anatomy, tooth design, implant positioning and the related CBCT cross-section in accordance with the ideal gingival margin, papilla height and prosthetic emergence.



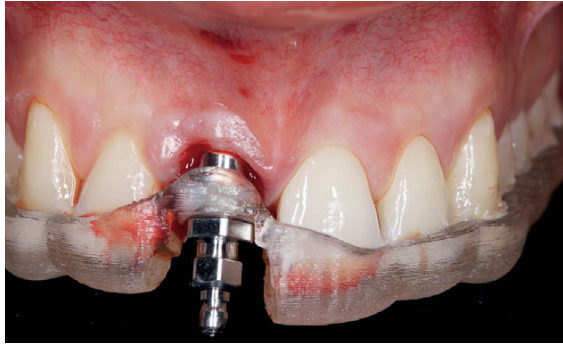**Fig 7** Preoperative CAD design of the Zirconia definitive abutment.



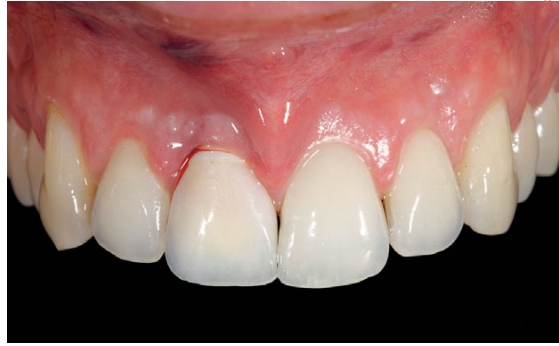**Fig 8** CSAD-CAM Zirconia abutment try-in onto the pre-operative master cast.

Flapless surgery reduces patient discomfort<sup>10,12,88,89</sup>. Flapless computer-guided surgery may allow implant treatment in medically compromised patients who would be excluded due to the stress related to the length of the surgical intervention and the

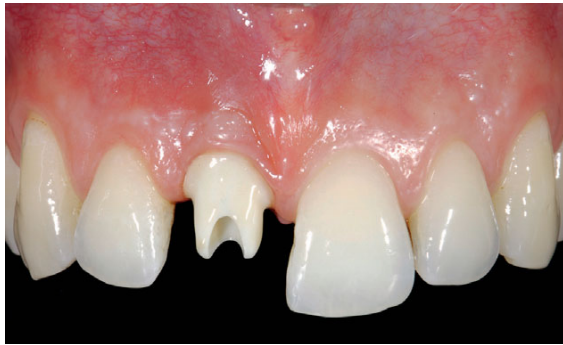higher risk of intraoperative and postoperative complications<sup>90</sup>. Flapless surgery in patients with newly grafted bone may also reduce the bone resorption associated with interruption of the periosteal blood supply<sup>91</sup>. Planning based on CBCT data often over-



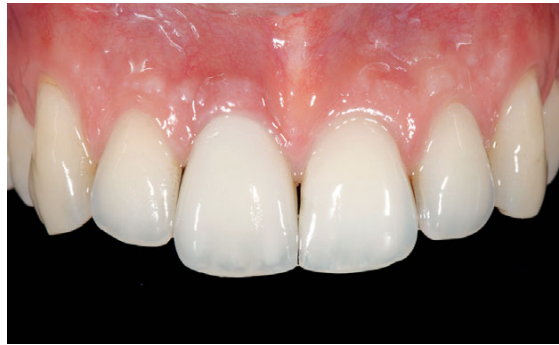**Fig 9** Immediate provisionalization the day of tooth extraction and implant placement.



**Fig 10** Fully guided surgery and implant placement through the sleeve.



**Fig 11** Five months after the healing of the soft tissue around the anatomically shaped Zirconia abutment delivered the day of the surgery.



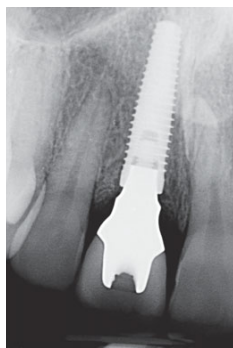
**Fig 12** One -year clinical outcome of the definitive crown cemented onto the zirconia abutment delivered the day of the tooth extraction and implant placement.

looks the soft tissue anatomy<sup>62</sup>. New technologies combining CT/CBCT DICOM data with information on the soft tissues and crown morphology, obtained through digital high-resolution optical scanners, should be encouraged (Figs 2 to 14). Ritter et al<sup>92</sup>, assessed the accuracy of this newly developed digital workflow on 16 patients through 1792 measurements. All data pairs were matched successfully and mean deviations between CBCT and 3D surface data were between 0.03 ( $\pm$  0.33) and 0.14 ( $\pm$  0.18) mm. According to the results of this study, they concluded that registration of 3D surface data and CBCT data works reliably and is sufficiently accurate for implant planning. The recently introduced 3D software program (NobelClinician), automatically combines the DICOM data from CT/CBCT examination of the patient with the STL data from the surface high-resolution optical scanning of the patient preoperative master cast and tooth setup, through a proprietary

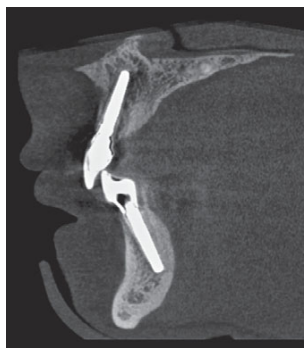algorithm process (SmartFusionTM, Nobel Biocare). Technically, the accuracy of this automatic matching workflow is 1 voxel size below (internal data, Nobel Biocare), manual segmentation workflow based on pairing, at least three points on the surface of the patient CT/CBCT anatomy with the equivalent ones of the patient anatomy achieved by the digital high-resolution optical scanning. Thus, the current workflow is reversed so that CBCT/CT scans can be performed as a first step prior to any laboratory fabrication of a radiographic template or wax-up, which can later be scanned and merged with the CBCT/CT data. The availability of tooth morphology digital libraries within the planning software will streamline the digital planning further.

Fully digitally planned guided surgery and prosthetics can thus be performed in two visits without the need for conventional intraoral impressions, laboratory procedures and advanced manual skills<sup>51</sup>.





**Fig 13** One-year periodical radiographs assessing the bone levels with the bone overgrowth onto the implant platform.



**Fig 14** One-year CBCT evaluation of the fully guided implant placement.

### ■ Learning curve-experience

Several clinical trials pointed out the importance of the learning curve<sup>10,16,17</sup>, while other studies did not<sup>48,72,79,93</sup>. Recently published *in vitro* research on computer-guided surgery for missing single teeth in the posterior mandible<sup>48</sup> did not find significant differences in the angular and linear deviations between experienced and inexperienced operators. Almost all implants (95%) were placed more coronally than the planned position. The amount of vertical deviation in the coronal direction of the implants placed by the inexperienced operators was about twice that placed by the experienced ones. Nevertheless, these results suggest that the vertical position control of the computer-guided system provides adequate safety features, as most of the errors were in the coronal direction; therefore, the risk of encroaching on vital structures (such as the inferior alveolar nerve and the maxillary sinus) when dealing with missing single molars is minimal.

Computer-guided implant surgery remains technically demanding and is not free from complications, such as fracture of the template, incorrect implant positioning or misfitting of the prostheses<sup>37,94</sup>. A recently published review<sup>38</sup> reported template fracture (3.6%), change in surgical plan (2%) and lack of primary stability (1.3%) as the most frequent complications.

### ■ Conclusions

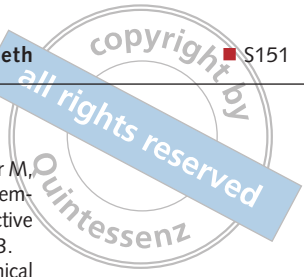
The evidence supporting the hypothesis that there is a clinical advantage using computer-guided surgery compared to conventional freehand implant placement for the treatment of single-tooth gap is still limited. Nevertheless 19 clinical studies, investigating the clinical outcomes of the computer-guided surgery for missing single teeth, were identified and included in this review, accounting for an overall amount of 342 single implants placed in 209 patients (18 to 67 years old), with a follow-up between 12 and 52 months and a cumulative survival rate ranging from 96.5% to 100%. The survival rates of computer-guided surgery were comparable with those of conventional freehand implant placement after an observation time of 12 to 60 months<sup>65</sup>, and therefore this systematic review revealed no obvious differences between the two clinical workflows.

The specific computer-guided surgery-related complications, such as fracture of the template, incorrect implant positioning, change in surgical plan, lack of primary stability or misfitting of the prostheses were not experienced by the clinical studies included in the review. Clinicians should take into consideration the software specific differences and their mean inaccuracy, in order to perform the implant placement procedures with adequate safety.

Given the recently developed fully digital workflow with 3D soft tissue virtual visualisation, the computer-guided surgery minimal-invasive flapless implant placement is becoming a more predictable procedure in terms of improved planning, accuracy and survivability. Avoidance of flap elevation seems to benefit peri-implant mucosal outcome, particularly in terms of maximum preservation of peri-implant papillae and reduced mucosal recession. When the width of keratinized mucosa is limited, specific surgical approaches may be favoured.

Clinicians should inform patients that computer-guided surgery implies additional costs. However, these costs should be analysed in terms of cost-effectiveness and assessed towards the reduction of surgery time and postoperative discomfort as well as, the potentially increased accuracy. Randomised clinical trials comparing computer-guided surgery with conventional 'freehand' implant placement for the treatment of missing single teeth are very much required.





## References

- Rosenfeld AL, Mandelaris GA, Tardieu PB. Prosthetically directed implant placement using computer software to ensure precise placement and predictable prosthetic outcomes. Part 1: diagnostics, imaging, and collaborative accountability. *Int J Periodontics Restorative Dent* 2006;26:215–221.
- Rosenfeld AL, Mandelaris GA, Tardieu PB. Prosthetically directed implant placement using computer software to ensure precise placement and predictable prosthetic outcomes. Part 2: rapid-prototype medical modeling and stereolithographic drilling guides requiring bone exposure. *Int J Periodontics Restorative Dent* 2006;26:347–353.
- Rosenfeld AL, Mandelaris GA, Tardieu PB. Prosthetically directed implant placement using computer software to ensure precise placement and predictable prosthetic outcomes. Part 3: stereolithographic drilling guides that do not require bone exposure and the immediate delivery of teeth. *Int J Periodontics Restorative Dent* 2006;26:493–499.
- Verstreken K, Van Cleynenbreugel J, Marchal G, Naert I, Suetens P, van Steenberghe D. Computer-assisted planning of oral implant surgery: a three-dimensional approach. *Int J Oral Maxillofac Implants* 1996;11:806–810.
- Verstreken K, Van Cleynenbreugel J, Martens K, Marchal G, van Steenberghe D, Suetens P. An image-guided planning system for endosseous oral implants. *IEEE Trans Med Imaging* 1998;17:842–852.
- Jacobs R, Adriansens A, Verstreken K, Suetens P, van Steenberghe D. Predictability of a three-dimensional planning system for oral implant surgery. *Dentomaxillofac Radiol* 1999;28:105–111.
- Guerrero ME, Jacobs R, Loubele M, Schutyser F, Suetens P, van Steenberghe D. State-of-the-art on cone beam CT imaging for preoperative planning of implant placement. *Clin Oral Invest* 2006;10:1–7.
- Loubele M, Bogaerts R, Van Dijck E, Pauwels R, Vanheusden S, Suetens P, Marchal G, Sanderink G, Jacobs R. Comparison between effective radiation dose of CBCT and MSCT scanners for dentomaxillofacial applications. *Eur J Radiol* 2009;71:461–468.
- Jacobs R, Quirynen M. Dental cone beam computed tomography: justification for use in planning oral implant placement. *Periodontol* 2000 2014;66:203–213.
- Pozzi A, Tallarico M, Marchetti M, Scarfo B, Esposito M. Computer-guided versus free-hand placement of immediately loaded dental implants: 1-year post-loading results of a multicentre randomised controlled trial. *Eur J Oral Implantol* 2014;7:229–242.
- Esposito M, Maghaireh H, Grusovin MG, Ziounas I, Worthington HV. Interventions for replacing missing teeth: management of soft tissues for dental implants. *Cochrane Database Syst Rev* 2012;(2):CD006697.
- Fortin T, Bosson JL, Isidori M, Blanchet E. Effect of flapless surgery on pain experienced in implant placement using an image-guided system. *Int J Oral Maxillofac Implants* 2006;21:298–304.
- Vercruyssen M, Laleman I, Jacobs R, Quirynen M. Computer-supported implant planning and guided surgery: a narrative review. *Clin Oral Impl Res* 2015;26(Suppl 11):69–76.
- van Steenberghe D, Glauser R, Blombäck U, Andersson M, Schutyser F, Pettersson A, Wendelhag I. A computed tomographic scan-derived customized surgical template and fixed prosthesis for flapless surgery and immediate loading of implants in fully edentulous maxillae: a prospective multicenter study. *Clin Implant Dent Relat Res* 2005;7(Suppl 1):S111–S120.
- Sicilia A, Botticelli D; Working Group 3. Computer-guided implant therapy and soft- and hard-tissue aspects. The Third EAO Consensus Conference 2012. *Clin Oral Implants Res* 2012;23(Suppl 6):157–161.
- Vasak C, Watzak G, Gahleitner A, Strbac G, Schemper M, Zechner W. Computed tomography-based evaluation of template (NobelGuide™)-guided implant positions: a prospective radiological study. *Clin Oral Impl Res* 2011;22:1157–1163.
- Vasak C, Kohal RJ, Lettner S, Rohner D, Zechner W. Clinical and radiological evaluation of a template-guided (NobelGuide™) treatment concept. *Clin Oral Impl Res* 2014;25:116–123.
- Cannizzaro G, Felice P, Leone M, Checchi V, Esposito M. Flapless versus open flap implant surgery in partially edentulous patients subjected to immediate loading: 1-year results from a split-mouth randomised controlled trial. *Eur J Oral Implantol* 2011;4:177–188.
- Cannizzaro G, Leone M, Consolo U, Ferri V, Esposito M. Immediate functional loading of implants placed with flapless surgery versus conventional implants in partially edentulous patients: a 3-year randomized controlled clinical trial. *Int J Oral Maxillofac Implants* 2008;23:867–875.
- van Steenberghe D, Naert I, Andersson M, Brajnovic I, Van Cleynenbreugel J, Suetens P. A custom template and definitive prosthesis allowing immediate implant loading in the maxilla: a clinical report. *Int J Oral Maxillofac Implants* 2002;17:663–670.
- Verhamme LM, Meijer GJ, Boumans T, de Haan AF, Bergé SJ, Maal TJJ. A clinically relevant accuracy study of computer-planned implant placement in the edentulous maxilla using mucosa-supported surgical templates. *Clin Implant Dent Relat Res* 2015 17:343–352.
- Pettersson A, Komiyama A, Hultin M, Näsström K, Klinge B. Accuracy of virtually planned and template guided implant surgery on edentate patients. *Clin Implant Dent Relat Res* 2012;14:527–537.
- Vandenbergh B, Jacobs R, Bosmans H. Modern dental imaging: a review of the current technology and clinical applications in dental practice. *Eur Rad* 2010;20:2637–2655.
- Al-Rawi B, Hassan B, Vandenbergh B, Jacobs R. Accuracy assessment of three-dimensional surface reconstructions of teeth from cone beam computed tomography scans. *J Oral Rehabil* 2010;37:352–358.
- Reich S, Kern T, Ritter L. Options in virtual 3D, optical-impression-based planning of dental implants. *Int J Comput Dent* 2014;17:101–113.
- Chen S, Buser D. Esthetic outcomes following immediate and early implant placement in the anterior maxilla—a systematic review. *Int J Oral Maxillofac Implants* 2014;29(Suppl):186–215.
- Esposito M, Grusovin MG, Polyzos IP, Felice P, Worthington HV. Interventions for replacing missing teeth: dental implants in fresh extraction sockets (immediate, immediate-delayed and delayed implants). *Cochrane Database Syst Rev* 2010;(8):CD005968.
- Quirynen M, Van Assche N, Botticelli D, Berglundh T. How does the timing of implant placement to extraction affect outcome? *Int J Oral Maxillofac Implants* 2007;22(Suppl):203–223.
- Grunder U, Gracis S, Capelli M. Influence of the 3-D bone-to-implant relationship on esthetics. *Int J Periodontics Restorative Dent* 2005;25:113–119.
- Buser D, Martin W, Belser UC. Optimizing esthetics for implant restorations in the anterior maxilla: anatomic and surgical considerations. *Int J Oral Maxillofac Implants* 2004;19(Suppl):43–61.
- Belser UC, Grütter L, Vailati F, Bornstein MM, Weber HP, Buser D. Outcome evaluation of early placed maxillary anterior single-tooth implants using objective esthetic criteria: a cross-sectional, retrospective study in 45 patients with a 2- to 4-year follow-up using pink and white esthetic scores. *J Periodontol* 2009;80:140–151.

32. Fürhauser R, Mailath-Pokorny G, Haas R, Busenlechner D, Watzek G, Pommer B. Esthetics of Flapless Single-Tooth Implants in the Anterior Maxilla Using Guided Surgery: Association of Three-Dimensional Accuracy and Pink Esthetic Score. *Clin Implant Dent Relat Res* 2014;17(suppl 2):e427–e433.
33. Sanna AM, Molly L, van Steenberghe D. Immediately loaded CAD-CAM manufactured fixed complete dentures using flapless implant placement procedures: a cohort study of consecutive patients. *J Prosthet Dent* 2007;97:331–339.
34. Komiyama A, Pettersson A, Hultin M, Näsström K, Klinge B. Virtually planned and template-guided implant surgery: an experimental model matching approach. *Clin Oral Impl Res* 2011;22: 308–313.
35. Komiyama A, Klinge B, Hultin M. Treatment outcome of immediately loaded implants installed in edentulous jaws following computer-assisted virtual treatment planning and flapless surgery. *Clin Oral Impl Res* 2008;19:677–685.
36. Johansson B, Friberg B, Nilson H. Digitally Planned, immediately loaded dental implants with prefabricated prostheses in the reconstruction of edentulous maxillae: a 1-Year prospective, multicenter study. *Clin Implant Dent Relat Res* 2009;11: 194–200.
37. Merli M, Bernardelli F, Esposito M. Computer-guided flapless placement of immediately loaded dental implants in the edentulous maxilla: a pilot prospective case series. *Eur J Oral Implantol* 2008;1:61–69.
38. Tahmaseb A, Wismeijer D, Coucke W, Derksen W. Computer technology applications in surgical implant dentistry: a systematic review. *Int J Oral Maxillofac Implants* 2014; 29(Suppl):25–42.
39. Hultin M, Svensson KG, Trulsson M. Clinical advantages of computer-guided implant placement: a systematic review. *Clin Oral Implants Res* 2012;23(Suppl 6):124–135.
40. Moher D, Liberati A, Tetzlaff J, Altman DG;PRISMA Group. Preferred reporting items for systematic reviews and meta-analyses: the PRISMA Statement. *Open Med* 2009;3:e123–e130.
41. Esposito M, Grusovin MG, Willings M, Coulthard P, Worthington HV. The effectiveness of immediate, early, and conventional loading of dental implants: a Cochrane systematic review of randomized controlled clinical trials. *Int J Oral Maxillofac Implants* 2007;22:893–904.
42. Farley NE, Kennedy K, McGlumphy EA. Split-mouth comparison of the accuracy of computer-generated and conventional surgical guides. *Int J Oral Maxillofac Implants* 2013;28:563–572.
43. Pozzi A, Moy PK. Minimally invasive transcresal guided sinus lift (TGSL): a clinical prospective proof-of-concept cohort study up to 52 months. *Clin Implant Dent Relat Res* 2014;16:582–593.
44. Behneke A, Burwinkel M, Behneke N. Factors influencing transfer accuracy of cone beam CT-derived template-based implant placement. *Clin Oral Implants Res* 2012;23:416–423.
45. Ersoy AE, Turkyilmaz I, Ozan O, McGlumphy EA. Reliability of implant placement with stereolithographic surgical guides generated from computed tomography: clinical data from 94 implants. *J Periodontol* 2008;79:1339–1345.
46. Nikzad S, Azari A. Custom-made radiographic template, computed tomography, and computer-assisted flapless surgery for treatment planning in partial edentulous patients: a prospective 12-month study. *J Oral Maxillofac Surg* 2010;68:1353–1359.
47. Edelmann AR, Hosseini B, Byrd WC, Preisser JS, Tyndall DA, Nguyen T, Bencharit S. Exploring effectiveness of computer-aided planning in implant positioning for a single immediate implant placement [Epub ahead of print]. *J Oral Implantol*
48. Rungcharassaeng K, Caruso JM, Kan JY, Schutyser F, Boumans T. Accuracy of computer-guided surgery: A comparison of operator experience. *J Prosthet Dent* 2015;114: 407–413.
49. Kramer FJ, Baethge C, Swennen G, Rosahl S. Navigated vs. conventional implant insertion for maxillary single tooth replacement. *Clin Oral Implants Res* 2004;16:60–68.
50. Brief J, Edinger D, Hassfeld S, Eggers G. Accuracy of image-guided implantology. *Clin Oral Implants Res* 2005;16: 495–501.
51. Schnitman PA, Han RK. Completely Digital Two-Visit Immediately Loaded Implants: Proof of Concept. *J Oral Implantol* 2015;41:429–436.
52. Ganz SD. Three-dimensional imaging and guided surgery for dental implants. *Dent Clin North Am* 2015;59:265–290.
53. Kamposiora P, Papavasiliou G, Madianos P. Presentation of two cases of immediate restoration of implants in the esthetic region, using facilitate software and guides with stereolithographic model surgery prior to patient surgery. *J Prosthodont* 2012;21:130–137.
54. Margonar R, Queiroz TP, Luvizuto ER, Santos PL, Wady AF, Paleari AG. Anterior tooth rehabilitation with frozen homogenous bone graft and immediately loaded titanium implant using computer-guided surgery. *J Craniofac Surg* 2012;23:e470–e472.
55. Rossi R, Morales RS, Frascaria M, Benzi R, Squadrito N. Planning implants in the esthetic zone using a new implant 3D navigation system. *Eur J Esthet Dent* 2010;5:172–188.
56. Arnetzl GV, Arnetzl G. From the drilling template to the temporary restoration. *Int J Comput Dent* 2009;12: 345–355.
57. Bonaudo D, Raimondo C, Rubino G. Single-tooth restorative treatment using an immediate-loading CAD/CAM technique. *Int J Comput Dent* 2006;9:321–331.
58. Almog DM, LaMar J, LaMar FR, LaMar F. Cone beam computerized tomography-based dental imaging for implant planning and surgical guidance, Part 1: Single implant in the mandibular molar region. *J Oral Implant* 2006;32:77–81.
59. Sudbrink SD. Computer-guided implant placement with immediate provisionalization: a case report. *J Oral Maxillofac Surg* 2005;63:771–774.
60. Mandelaris GA, Vlk SD. Guided implant surgery with placement of a presurgical CAD/CAM patient-specific abutment and provisional in the esthetic zone. *Compend Contin Educ Dent* 2014;35:494–504.
61. Van Assche N, Vercruyssen M, Coucke W, Teughels W, Jacobs R, Quirynen M. Accuracy of computer-aided implant placement. *Clin Oral Implants Res* 2012;23(Suppl 6):112–123.
62. Sicilia A, Botticelli D; Working Group 3. Computer-guided implant therapy and soft- and hard-tissue aspects. The Third EAO Consensus Conference 2012. *Clin Oral Implants Res* 2012;23(Suppl 6):157–161.
63. D'haese J, Van De Velde T, Komiyama A, Hultin M, De Bruyn H. Accuracy and complications using computer-designed stereolithographic surgical guides for oral rehabilitation by means of dental implants: A Review of the Literature. *Clin Implant Dent Relat Res* 2010;14:321–335.
64. Jung RE, Schneider D, Ganeles J, Wismeijer D, Zwahlen M, Hämmerle CH, Tahmaseb A. Computer technology applications in surgical implant dentistry: a systematic review. *Int J Oral Maxillofac Implants* 2009;24(Suppl):92–109.
65. Schneider D, Marquardt P, Zwahlen M, Jung RE. A systematic review on the accuracy and the clinical outcome of computer-guided template-based implant dentistry. *Clin Oral Implants Res* 2009;20(Suppl 4):73–86.
66. Kapos T, Ashy LM, Gallucci GO, Weber HP, Wismeijer D. Computer-aided design and computer-assisted manufacturing in prosthetic implant dentistry. *Int J Oral Maxillofac Implants* 2009;24(Suppl):110–117.
67. Widmann G, Bale RJ. Accuracy in computer-aided implant surgery--a review. *Int J Oral Maxillofac Implants* 2006;21: 305–313.

68. D'haese J, Van De Velde T, Komiyama A, Hultin M, De Bruyn H. Accuracy and complications using computer-designed stereolithographic surgical guides for oral rehabilitation by means of dental implants: a review of the literature. *Clin Implant Dent Relat Res* 2012;14:321–335.
69. Stumpel LJ. Congruency of stereo lithographically produced surgical guide bases made from the same CBCT file: a pilot study. *Clin Implant Dent Relat Res* 2013;15:531–537.
70. Tahmaseb A, van de Weijden JJ, Mercelis P, De Clerck R, Wismeijer D. Parameters of passive fit using a new technique to mill implant-supported superstructures: an in vitro study of a novel three-dimensional force measurement-misfit method. *Int J Oral Maxillofac Implants* 2010;25:247–257.
71. Ozan O, Turkiylmaz I, Ersoy AE, McGlumphy EA, Rosenstiel SF. Clinical accuracy of 3 different types of computed tomography-derived stereolithographic surgical guides in implant placement. *J Oral Maxillofac Surg* 2009;67:394–401.
72. Valente F, Schirotti G, Sbrenna A. Accuracy of computer-aided oral implant surgery: a clinical and radiographic study. *Int J Oral Maxillofac Implants* 2009;24:234–242.
73. Tahmaseb A, Wismeijer D, Coucke W, Derksen W. Computer technology applications in surgical implant dentistry: a systematic review. *Int J Oral Maxillofac Implants* 2014;29(Suppl):25–42.
74. Pozzi A, Sannino G, Barlattani A. Minimally invasive treatment of the atrophic posterior maxilla: a proof-of-concept prospective study with a follow-up of between 36 and 54 months. *J Prosthet Dent* 2012;108:286–297.
75. Schneider D, Schober F, Grohmann P, Hämmerle CH, Jung RE. In-vitro evaluation of the tolerance of surgical instruments in templates for computer-assisted guided implantology produced by 3-D printing. *Clin Oral Impl Res* 2015;26:320–325.
76. Cassetta M, Di Mambro A, Giansanti M, Stefanelli LV, Cavallini C. The intrinsic error of a stereolithographic surgical template in implant guided surgery. *Int J Oral Maxillofac Surg* 2013;42:264–275.
77. Koop R, Verduyssen M, Vermeulen K, Quirynen M. Tolerance within the sleeve inserts of different surgical guides for guided implant surgery. *Clin Oral Implants Res* 2013;24:630–634.
78. Park JM, Yi TK, Koak JY, Kim SK, Park EJ, Heo SJ. Comparison of five-axis milling and rapid prototyping for implant surgical templates. *Int J Oral Maxillofac Implants* 2014;29:374–383.
79. Cassetta M, Stefanelli LV, Giansanti M, Di Mambro A, Calasso S. Accuracy of a computer-aided implant surgical technique. *Int J Periodontics Restorative Dent* 2013;33:317–325.
80. Fürhauser R, Florescu D, Benesch T, Haas R, Mailath G, Watzek G. Evaluation of soft tissue around single-tooth implant crowns: the pink esthetic score. *Clin Oral Implants Res* 2005;16:639–644.
81. Cosyn J, Hooghe N, De Bruyn H. A systematic review on the frequency of advanced recession following single immediate implant treatment. *J Clin Periodontol* 2012;39:582–589.
82. Koutrach M, Nimmo A. Preservation of existing soft-tissue contours in the transition from a tooth to an implant restoration in the esthetic zone using a flapless approach: a clinical report. *J Prosthodont* 2010;19:391–396.
83. Pommer B. Techniques to preserve keratinized peri-implant mucosa in CT-guided oral implant surgery. *Surg Tech Dev* 2012;2:24–27.
84. Pozzi A, Moy PK. Minimally invasive transcresal guided sinus lift (TGSL): a clinical prospective proof-of-concept cohort study up to 52 months. *Clin Implant Dent Relat Res* 2014;16:582–593.
85. Fürhauser R, Mailath-Pokorny G, Haas R, Busenlechner D, Watzek G, Pommer B. Esthetics of Flapless Single-Tooth Implants in the Anterior Maxilla Using Guided Surgery: Association of Three-Dimensional Accuracy and Pink Esthetic Score. *Clin Implant Dent Relat Res* 2015;17(Suppl 2):e427–e433.
86. Cosyn J, Eghbali A, De Bruyn H, Dierens M, De Rouck T. Single implant treatment in healing versus healed sites of the anterior maxilla: an aesthetic evaluation. *Clin Implant Dent Relat Res* 2012;14:517–526.
87. Lai HC, Zhang ZY, Wang F, Zhuang LF, Liu X, Pu YP. Evaluation of soft-tissue alteration around implant-supported single-tooth restoration in the anterior maxilla: the pink esthetic score. *Clin Oral Implants Res* 2008;19:560–564.
88. Hof M, Pommer B, Ambros H, Jesch P, Vogl S, Zechner W. Does Timing of Implant Placement Affect Implant Therapy Outcome in the Aesthetic Zone? A Clinical, Radiological, Aesthetic, and Patient-Based Evaluation. *Clin Implant Dent Relat Res* 2015;17:1188–1199.
89. Ansan V, Karabuda CZ, Özdemir T. Implant surgery using bone- and mucosa-supported stereolithographic guides in totally edentulous jaws: surgical and post-operative outcomes of computer-aided vs. standard techniques. *Clin Oral Implants Res* 2010;21:980–988.
90. Ansan V, Bölükbaşı N, Öksüz L. Computer-assisted flapless implant placement reduces the incidence of surgery-related bacteremia. *Clin Oral Investig* 2013;17:1985–1993.
91. Araújo MG, Sukekava F, Wennstrom JL, Lindhe J. Ridge alterations following implant placement in fresh extraction sockets: an experimental study in the dog. *J Clin Periodontol* 2005;32:645–652.
92. Ritter L, Reiz SD, Rothamel D, Dreiseidler T, Karapetian V, Scheer M, Zoller JE. Registration accuracy of three-dimensional surface and cone beam computed tomography data for virtual implant planning. *Clin Oral Implants Res* 2012;23:447–452.
93. Verduyssen M, De Laat A, Coucke W, Quirynen M. An RCT comparing patient-centred outcome variables of guided surgery (bone or mucosa supported) with conventional implant placement. *J Clin Periodontol* 2014;41:724–732.
94. D'haese J, Vervaeke S, Verbanck N, De Bruyn H. Clinical and radiographic outcome of implants placed using stereolithographic guided surgery: a prospective monocenter study. *Int J Oral Maxillofac Implants* 2013;28:205–215.