

# UCSF

## UC San Francisco Previously Published Works

### Title

Severe left diaphragmatic hernia limits size of fetal left heart more than does right diaphragmatic hernia

### Permalink

<https://escholarship.org/uc/item/3v3493xs>

### Journal

Ultrasound in Obstetrics and Gynecology, 46(6)

### ISSN

0960-7692

### Authors

Byrne, FA  
Keller, RL  
Meadows, J  
et al.

### Publication Date

2015-12-01

### DOI

10.1002/uog.14790

Peer reviewed

# Severe left diaphragmatic hernia limits size of fetal left heart more than does right diaphragmatic hernia

F. A. BYRNE\*, R. L. KELLER†, J. MEADOWS\*, D. MINIATI‡§, M. M. BROOK\*,  
N. H. SILVERMAN\* and A. J. MOON-GRADY\*§

\*Department of Pediatrics, Divisions of Cardiology, University of California, Benioff Children's Hospital, San Francisco, CA, USA;

†Department of Pediatrics, Division of Neonatology, University of California, Benioff Children's Hospital, San Francisco, CA, USA;

‡Department of Surgery, Division of Pediatric Surgery, University of California, San Francisco, CA, USA; §Fetal Treatment Center, University of California, San Francisco, CA, USA

**KEYWORDS:** cardiac development; congenital diaphragmatic hernia; congenital heart defects; fetal cardiac output; left heart hypoplasia

## ABSTRACT

**Objectives** To assess whether severity of congenital diaphragmatic hernia (CDH) correlates with the degree of left heart hypoplasia and left ventricle (LV) output, and to determine if factors leading to abnormal fetal hemodynamics, such as compression and reduced LV preload, contribute to left heart hypoplasia.

**Methods** This was a retrospective cross-sectional study of fetuses at 16–37 weeks' gestation that were diagnosed with CDH between 2000 and 2010. Lung-to-head ratio (LHR), liver position and side of the hernia were determined from stored ultrasound images. CDH severity was dichotomized based on LHR and liver position. The dimensions of mitral (MV) and aortic (AV) valves and LV were measured, and right and left ventricular outputs were recorded.

**Results** In total, 188 fetuses with CDH were included in the study, 171 with left CDH and 17 with right CDH. Fetuses with severe left CDH had a smaller MV ( $Z = -2.24 \pm 1.3$  vs  $-1.33 \pm 1.08$ ), AV ( $Z = -1.39 \pm 1.21$  vs  $-0.51 \pm 1.05$ ) and LV volume ( $Z = -4.23 \pm -2.71$  vs  $-2.08 \pm 3.15$ ) and had lower LV output ( $26 \pm 10\%$  vs  $32 \pm 10\%$ ) than those with mild CDH. MV and AV in fetuses with right CDH (MV,  $Z = -0.83 \pm 1.19$  and AV,  $Z = -0.71 \pm 1.07$ ) were larger than those in fetuses with left CDH, but LV outputs were similarly diminished, regardless of hernia side. Severe dextroposition and abnormal liver position were associated independently with smaller left heart, while LHR was not.

**Conclusion** The severity of left heart hypoplasia correlates with the severity of CDH. Altered fetal hemodynamics, leading to decreased LV output, occurs in both

right- and left-sided CDH, but the additional compressive effect on the left heart is seen only when the hernia is left-sided. Improved knowledge of the physiology of this disease may lead to advances in therapy and better risk assessment for use in counseling affected families. Copyright © 2015 ISUOG. Published by John Wiley & Sons Ltd.

## INTRODUCTION

Left-sided congenital diaphragmatic hernia (CDH) has been associated with small left heart structures *in utero*<sup>1–3</sup>. There are several theories regarding the etiology of this finding: (1) it is due to external compression of the heart by herniated abdominal viscera in the thoracic cavity<sup>1,2</sup>; (2) it is due to reduced left heart filling via distortion of the ductus venosus flow across the foramen ovale<sup>4–6</sup>; or (3) it is due to reduced pulmonary blood flow return to the left heart (secondary to lung hypoplasia). The common pathway for these latter two mechanisms is decreased filling of the left ventricle (LV) contributing to an underdeveloped left heart<sup>7</sup>.

However, the relationship and pathophysiology between CDH and left heart hypoplasia in the fetus remain uncharacterized, and as of yet it has not been demonstrated clearly that the severity of CDH correlates with the severity of left heart hypoplasia. Furthermore, it was shown recently that LV cardiac output is decreased in CDH fetuses compared with normal fetuses<sup>3</sup>, but the mechanism remains uncertain. There are also no published data evaluating the effect of right CDH on the fetal heart.

Although most patients with CDH experience normalization of left heart hypoplasia after birth and CDH repair,

Correspondence to: Dr A. J. Moon-Grady, Fetal Cardiovascular Program, UCSF Benioff Children's Hospital, 550 16<sup>th</sup> Street 5<sup>th</sup> Floor, San Francisco, CA 94158, USA (e-mail: anita.moongrady@ucsf.edu)

Accepted: 12 January 2015

a small subset of newborns (~5%) has persistent left heart obstruction requiring surgical intervention<sup>3</sup>. Moreover, it has been shown that, even in the absence of anatomical obstruction, a lower LV mass at birth is associated with an increased need for extracorporeal membrane oxygenation and increased perinatal mortality<sup>5,8–10</sup>. Identifying the patients who will develop significant left heart hypoplasia may be helpful for prenatal counseling and perinatal therapies.

In this study, we sought to define the relationship between CDH and left heart hypoplasia, and to gain insight into the pathophysiology involved through exploration of fetal cardiac anatomy and flow. Our primary hypothesis was that both right- and left-sided CDH severity correlate with worsening left heart hypoplasia and lower LV cardiac output in the fetus. As a secondary aim, we analyzed the factors that potentially lead to these findings, such as compression of the heart by the abdominal contents, or altered flow dynamics from changes in ductus venosus or pulmonary venous return.

## METHODS

This was a retrospective cross-sectional study based on clinical obstetric ultrasound and echocardiographic data of fetuses with CDH evaluated by the Fetal Treatment Center at the University of California, San Francisco (UCSF), USA, from 2000 to 2010. We recorded gestational age at time of echo (based on last menstrual period or first-trimester ultrasound dating), neonatal survival and the presence of associated cardiac anomalies. Subjects with significant structural congenital heart malformation or known aneuploidy were excluded. We reviewed stored obstetric ultrasound images for liver position, side of herniated abdominal contents (hernia side), other non-cardiac anomalies and lung-to-head ratio (LHR). The LHR is a sonographically measured ratio of the contralateral lung size compared with head circumference, which minimizes the lung size differences owing to gestational age. LHR has been shown to correlate with severity of pulmonary hypoplasia and to be an independent predictor of postnatal survival in fetuses with left CDH, when measured at 24–34 weeks of gestation at our institution<sup>7,11,12</sup>.

Fetal echocardiography was performed using Sequoia C256 and C512 ultrasound systems (Acuson, Siemens, Mountain View, CA, USA) using a combination of curvilinear and phased-array probes operating at 6–8 MHz, with images stored digitally in standard DICOM format. All studies included a complete two-dimensional (2D) evaluation of cardiac structures and systolic ventricular function with full Doppler examination. 2D grayscale imaging at high magnification for measurement of pulmonary artery dimensions was standard during most of the study period.

A single echocardiographer (F.A.B.) who was blinded to the ultrasound results and pregnancy and neonatal outcomes reviewed echocardiograms from the first

evaluation. Ventricular dimensions, maximum width of the right and left ventricular cavities, and atrioventricular valve annuli were measured in end-diastole, while semilunar valve annuli, and size of ductus arteriosus (DA) and branch pulmonary arteries were measured in systole.

The following calculations were made.

LV end-diastolic volume was calculated using the bullet method<sup>13</sup>:

$$\text{end-diastolic volume} = (5/6 \text{ area} \times \text{length}).$$

Ventricular output (VO) was calculated from 2D and Doppler measurements:

$$\text{VO} = \text{velocity time integral (VTI)}$$

$$\times \text{heart rate} \times \text{semilunar valve area.}$$

$$\begin{aligned} \text{LV output (LVO)} + \text{right ventricular output (RVO)} \\ = \text{combined ventricular output (CVO)}. \end{aligned}$$

Flow in the branch pulmonary arteries and DA (taken at the mid-way point between the left pulmonary artery and the descending aorta) was estimated from the cross-sectional area of the vessel, multiplied by the product of the VTI and heart rate. Pulmonary blood flow (PBF) was then calculated as:

$$\text{PBF} = \text{RVO} - \text{DA flow.}$$

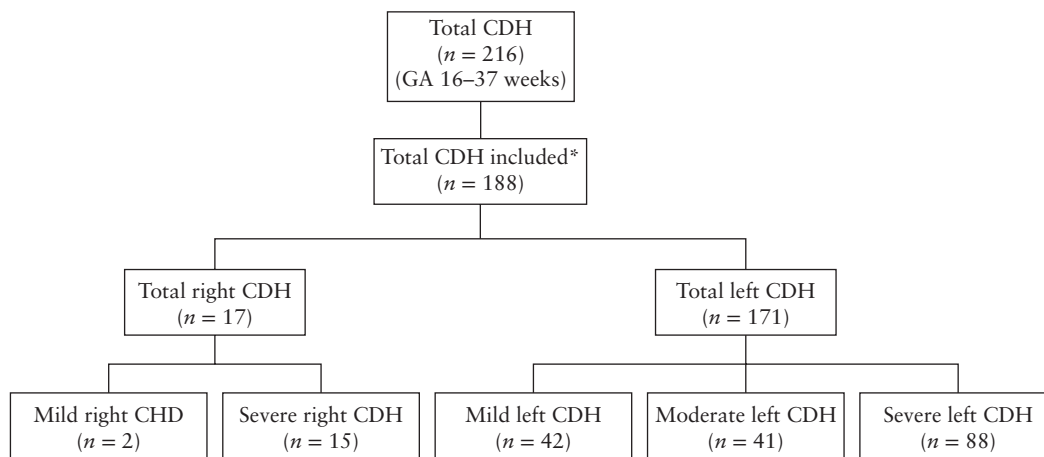
Foramen ovale (FO) flow was calculated as:

$$\text{FO flow} = \text{LVO} - \text{PBF.}$$

Left CDH severity was categorized based on LHR and liver position: LHR  $\leq 1$  and liver up as severe; LHR  $> 1$  and liver up as moderate; and liver down as mild. Although LHR in right CDH is not as well validated, right CDH was arbitrarily dichotomized based on LHR alone, given that liver herniation is always present with right CDH: LHR  $\leq 1$  as severe and LHR  $> 1$  as mild.

Our secondary analysis superimposed a theoretical framework on the collected data, utilizing the ultrasound information as above. We divided patients into groups based on an *a-priori* assumption of altered pattern of DV blood flow, altered pulmonary venous return, or external compression as follows: fetuses with left CDH with liver herniated into the thorax and fetuses with severe right CDH were assumed to exhibit 'altered ductus venosus flow' due to abnormal position of the ductus venosus in these cases. LHR  $\leq 1$  defined lung hypoplasia, in which case 'altered pulmonary venous return' would be expected. Fetuses with left CDH with liver herniated (LHR  $\leq 1$ ) and severe dextroposition would be expected to exhibit an element of left heart 'compression' that would not be present in right CDH patients.

In order to normalize for differences in gestational age among the fetuses in our cohort, Z-scores for heart chamber size and valve structures were generated from previously published normative data<sup>14–17</sup>. LV outputs were indexed to estimated fetal weight and expressed as a percentage of CVO, and compared with



**Figure 1** Study population of fetuses with congenital diaphragmatic hernia (CDH) diagnosed between 2000 and 2010. \*Two fetuses with bilateral CDH, 11 without lung-to-head ratio (LHR) recorded and 15 with significant congenital heart disease were excluded. Left CDH: mild = liver down, moderate = LHR > 1 and liver up, severe = LHR ≤ 1 and liver up; right CDH: mild = LHR > 1, severe = LHR ≤ 1. GA, gestational age at fetal echocardiography.

previously published data in normal fetuses<sup>18,19</sup>. All fetal measurements were repeated by a second observer for assessment of interobserver variability and by the same observer for intraobserver variability, via calculation of mean percent difference between the two observations.

### Statistical analysis

Descriptive analyses of continuous variables with normal distribution are presented as mean ± SD. Comparison of continuous variables with normal distribution was performed using an unpaired *t*-test and ANOVA for trends between groups, and a Bonferroni correction was applied. A *P*-value < 0.001 was considered statistically significant, given the number of predictor variables. The study was approved by the UCSF Committee on Human Research (CHR approval number H8215-18407-09A) with a waiver of consent.

### RESULTS

Between 2000 and 2010, 220 patients were referred to the Fetal Treatment Center at UCSF with fetal diagnosis of CDH. A complete fetal echo was performed in 216 cases. We excluded two fetuses with midline or bilateral CDH and 11 that did not have a recorded LHR. We also excluded an additional 15 fetuses with significant congenital heart disease, with effects on the fetal circulation that would have confounded our analysis, including critical coarctation, large ventricular septal defect, aortic atresia, d-transposition of the great arteries, pulmonary atresia with a ventricular septal defect, tetralogy of Fallot, interrupted inferior vena cava, Ebstein anomaly, double outlet right ventricle and atrioventricular canal defect. Fetuses with mild-to-moderate arch hypoplasia were included. The remaining cohort of 188 fetuses comprised the study population, 171 with left CDH and 17 with right CDH (Figure 1).

The mean gestational age of fetuses at the time of the ultrasound examination was 25 (range, 16–37) weeks. Mean gestational ages were similar among subgroups of right and left CDH and severity groupings. Pregnancy and neonatal outcome were known in 94% of the study population. The vast majority of fetuses with right CDH were classified as severe, which limited our ability to perform a dichotomized analysis for this group.

As shown in Table 1, in both right and left CDH, fetuses demonstrated lower LVO as a percentage of CVO ( $32 \pm 10\%$  and  $29 \pm 10\%$ , respectively) than the 44% that is expected in the normal fetus<sup>18,19</sup>. MV and AV Z-scores in fetuses with right CDH were larger than those in fetuses with left CDH (although only MV difference was statistically significant,  $P = 0.0013$ ). In our comparison of right *vs* left CDH, severe right lesions showed a trend towards a higher LVO as a percentage of CVO than did severe left CDH ( $32 \pm 11\%$  *vs*  $27 \pm 13\%$ ) but were similar to those of mild left CDH ( $31 \pm 10\%$ ) (test for trend,  $P = 0.04$ ). RVO was normal in all cases (data not shown). The right-sided lesions were also more likely to have left-sided heart structures within the normal range and a higher mitral-to-tricuspid valve ratio than the left CDH group ( $0.94$  *vs*  $0.77$ ;  $P < 0.001$ ).

Fetuses with severe left CDH were more likely to have smaller mitral valve ( $Z = -2.24 \pm 1.30$  *vs*  $-1.33 \pm 1.08$ ;  $P < 0.001$ ), aortic valve ( $Z = -1.39 \pm 1.21$  *vs*  $-0.51 \pm 1.05$ ;  $P < 0.001$ ) and LV end-diastolic volume Z-scores ( $Z = -4.23 \pm 2.71$  *vs*  $-2.08 \pm 3.15$ ;  $P = 0.006$ ) compared with those with mild left CDH (Figure 2).

We then grouped patients according to extracardiac compression effect, with severe effect defined as left CDH with severe dextroposition, liver herniation and LHR ≤ 1 *vs* mild or no dextroposition. We also grouped patients according to blood flow effect: liver herniation with altered ductus venosus flow *vs* normal liver position. These data are shown in Figure 3. We found that both abnormal cardiac position (compression) and abnormal liver position (altered blood flow) were associated with

**Table 1** Prenatal echocardiographic Z-scores and dimension ratios in 188 fetuses with congenital diaphragmatic hernia (CDH)

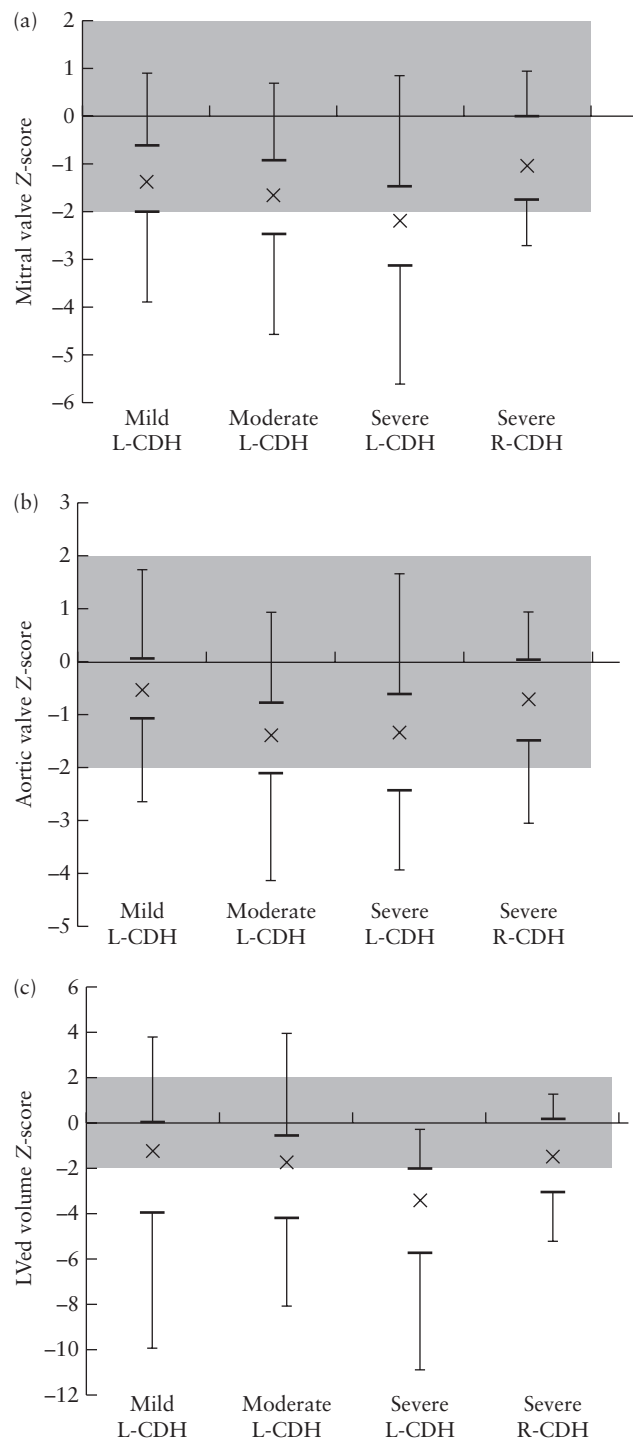
Parameter	Left CDH (n = 171)	Right CDH (n = 17)
MV	-1.92 ± 1.32	-0.83 ± 1.19
TV	0.0 ± 1.26	-0.38 ± 1.24
AV	-1.18 ± 1.23	-0.71 ± 1.07
PV	0.35 ± 1.17	0.37 ± 1.57
LV length	-1.49 ± 1.40	-1.85 ± 1.70
RV length	-0.83 ± 1.14	-1.71 ± 1.05
LVED volume	-3.14 ± 2.29	-1.41 ± 2.29
MV:TV ratio	0.77 ± 0.14	0.94 ± 0.15
AV:PV ratio	0.70 ± 0.14	0.74 ± 0.16
LV:RV ratio	1.0 ± 0.10	1.11 ± 0.13
LVO (% of CVO)	29 ± 10	32 ± 10

Data are given as mean ± SD. AV, aortic valve; CVO, combined ventricular output; LV, left ventricle; LVED, left ventricular end-diastolic; LVO, left ventricular output; MV, mitral valve; PV, pulmonary valve; RV, right ventricle; TV, tricuspid valve.

significantly smaller left heart dimensions ( $P < 0.001$ ). There was very little difference observed in group measurements when dichotomizing based on LHR as a surrogate for reduced pulmonary blood flow (Figure 3).

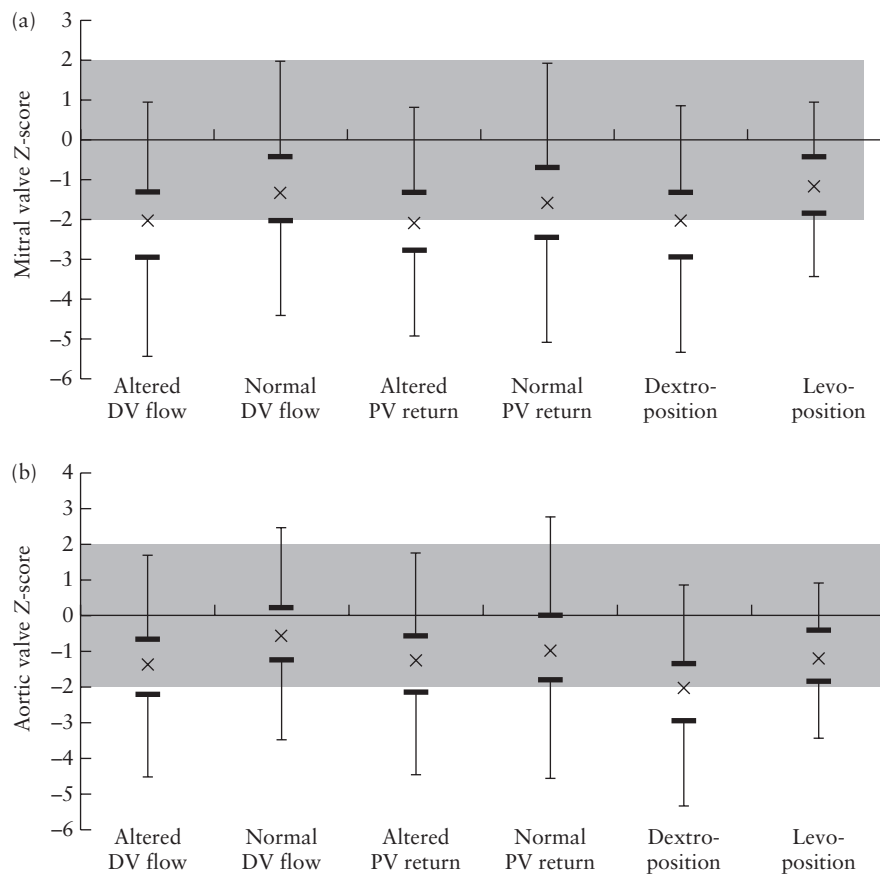
We next examined associations between cardiac output/blood flow measurements and CDH severity. Compared with values in normal fetuses, CVO indexed to fetal weight was decreased amongst all CDH patients, but indexed LVO was decreased most in fetuses with severe left CDH ( $86 \pm 32$  mL/min/kg *vs c.* 200 mL/min/kg in normal fetuses)<sup>18,19</sup>. Indexed RVO was normal amongst all groups (severe left CDH,  $239 \pm 80$  mL/min/kg; moderate left CDH,  $229 \pm 69$  mL/min/kg; mild left CDH,  $229 \pm 90$  mL/min/kg; right CDH,  $242 \pm 72$  mL/min/kg *vs* 250 mL/min/kg in normal fetuses). Ductus arteriosus flow was greater than that expected in normal fetuses for all groups ( $177 \pm 85$  mL/min/kg *vs* normal, 140 mL/min/kg). Pulmonary blood flow was lowest in the severe left CDH group ( $51 \pm 42$  mL/min/kg *vs* 110 mL/min/kg in normal controls). Median foramen ovale flow was also decreased for all CDH groups when combined compared with normal fetuses (19.7 (range, -36 to 175) mL/kg/min *vs* expected, 90 mL/min/kg). This measurement is problematic due to the wide variation owing to the small sample size (fewer than five measurements for each subcategory of severity) and due to the method of calculating flow from non-temporally related RVO, LVO and DA flow. RVO was preserved but not augmented, while LVO was decreased leading to reduction in CVO in fetuses with CDH compared with the expected indexed value for gestational age ( $342 \pm 102$  mL/min/kg *vs* 450 mL/min/kg, respectively).

Fetuses with severe left CDH showed a trend towards higher risk of neonatal death compared with those with mild left CDH (48% *vs* 25%; relative risk, 2.2; 95% CI, 0.7–13.0). Outcomes in right CDH, for which the majority were severe, were similar to mild left CDH, with 3/10 continuing pregnancies resulting in neonatal deaths.



**Figure 2** Left heart hypoplasia stratified according to side of congenital diaphragmatic hernia (CDH) and severity at fetal assessment, showing Z-scores for mitral valve (a;  $P < 0.0001$ ), aortic valve (b;  $P = 0.001$ ) and left ventricular end-diastolic volume (LVED volume) (c;  $P = 0.003$ ). Left (L)-CDH: mild ( $n = 42$ ) = liver down; moderate ( $n = 41$ ) = LHR > 1 and liver up; severe ( $n = 88$ ) = LHR ≤ 1 and liver up. Right (R)-CDH: severe ( $n = 15$ ) = LHR ≤ 1. For left heart measurements (mitral and aortic valves and LVED volume), severity of hypoplasia increased with increasing severity of L-CDH, while the effect in fetuses with R-CDH was less pronounced. Median (x) and interquartile range (IQR) (bars, upper and lower quartiles, whiskers 1.5 × IQR) are shown for each variable. Shaded areas represent normal Z-score range.





**Figure 3** Left heart hypoplasia in the mitral valve (a) and aortic valve (b) in 188 fetuses with congenital diaphragmatic hernia (CDH), stratified according to cardiac findings. Groups were categorized as follows: 'altered ductus venosus (DV) flow' was defined in fetuses with left CDH with liver herniated into thorax, and in fetuses with severe right CDH; lung hypoplasia and consequent 'altered pulmonary venous (PV) return' was defined as lung-to-head ratio (LHR)  $\leq 1$ ; external left side 'compression' (or severe dextro-position) was assigned to fetuses with left CDH with herniated liver and LHR  $\leq 1$ . 'Levo-position' was assigned to fetuses with right CDH. Left ventricular length is not shown as it was a non-significant finding.

Interobserver variability showed a mean difference of 16%, 11%, 12% and 15% in MV, AV and LV length, and LV outflow tract velocity time integral, respectively; and intraobserver mean difference was  $\leq 12\%$  for all measurements (Table 2).

**Table 2** Inter- and intraobserver variability between cardiac measurements in 188 fetuses with congenital diaphragmatic hernia

Variability	Interobserver	Intraobserver
MV	16	9
TV	13	9
AV	11	8
PV	7	8
LV length	12	12
RV length	8	10
LV width	22	11
LV area	19	10
LVOT-VTI	15	5
RVOT-VTI	20	5
MPA	16	7

Data are given as mean difference (%) between measurements. AV, aortic valve; LV, left ventricle; LVOT, left ventricular outflow tract; MPA, main pulmonary artery; MV, mitral valve; PV, pulmonary valve; RV, right ventricle; RVOT, right ventricular outflow tract; TV, tricuspid valve; VTI, velocity time integral.

## DISCUSSION

In a population of fetuses with both right and left CDH, we found that hernia severity correlated with left heart hypoplasia only if the hernia was left-sided, while left heart output was decreased in both right- and left-sided lesions. Our results support a pathophysiological framework wherein left heart compression with severe dextro-position contributes to, but is likely not the sole etiology for, left heart abnormality; altered left heart filling, likely via alteration in ductus venosus blood flow, appears to have a significant impact on the fetal heart in CDH regardless of hernia side. Pulmonary venous return did not, in this cohort, have a measurable effect on left heart development. However, since only 11–25% of CVO circulates to the lungs in normal fetuses<sup>18,19</sup>, a small change may have been beyond our ability to identify. Nevertheless, our study suggests that external compression may contribute to abnormal loading of the left heart by limiting filling and growth.

Our data agree with those of other studies that mild-to-moderate hypoplasia of the left heart structures and reduced left heart flow are common in fetuses with left CDH<sup>2,3,7</sup>. The fetus with severe left CDH is more

likely to have a smaller MV, AV and LV end-diastolic volume compared with those with mild left CDH. Ours is the first study to report that, although LVO is decreased to a similar degree in both right and left CDH, left heart hypoplasia does not occur to the same degree in right CDH.

Similar to our study, Stressig and Kohl found an association between intrathoracic liver herniation and left heart hypoplasia<sup>4,6</sup>. They established that 93% of fetuses with liver-up anatomy exhibited preferential streaming of ductus venosus flow toward the right heart by 2D and color Doppler imaging, compared with only 29% of those with liver-down CDH ( $P=0.0003$ ). This is in contrast to normal fetal physiology in which preferential shunting of ductus venosus blood flow across the foramen ovale provides a major source of left heart filling. The authors concluded that abnormal hemodynamics due to leftward distortion of the ductus venosus results in left heart underfilling and subsequent underdevelopment<sup>4,6</sup>. They also compared intrathoracic liver herniation in left *vs* right CDH and found that predominant left heart hypoplasia with preferential streaming to the right heart was observed in 11 of the 15 fetuses with left CDH but in none of the 10 fetuses with right CDH ( $P < 0.001$ )<sup>20</sup>. The authors concluded that intrathoracic herniation of the liver is associated with predominant left heart hypoplasia in left but not right CDH. Our data are the first to show that LVO is decreased in both right and left CDH. We conclude that abnormal hemodynamics based on liver herniation plus external compression results in reduced LVO and left heart hypoplasia in fetuses with left CDH.

As shown in our analysis, the right ventricle only partially compensates for decreased left-sided cardiac output although there is a measureable increase in DA flow in the fetus with severe CDH. We speculate that, with decreased LVO, a commensurate decrease in isthmus flow combined with an increase in DA flow to the descending aorta may predispose these fetuses to aortic arch hypoplasia and may be the mechanism behind the small, yet increased, incidence of coarctation reported previously in this population<sup>3,21</sup>. Our data showing that severe right and severe left CDH do not exhibit the same left heart phenotype *in utero* fit into the clinical context of long-term survival in these different subsets of patients. Future prospective studies in animal models of CDH that allow direct measurements of flow will provide insight as to the fetal hemodynamics and potential resulting structural aberrations including decreases in LV mass and increase in left heart obstructive lesions such as coarctation.

Limitations in our study include analysis of stored images, and retrospective data collection that included a certain degree of measurement error. The inter- and intraobserver error may limit reproducibility in clinical practice but nonetheless does not change the overall physiological conclusions of the study. Further, although LHR has been shown to be very reliable in predicting outcome in fetuses when measured at 24–34 weeks' gestation in our institution<sup>11</sup>, it may be less valid for fetuses outside this range of gestational age.

Observed-to-expected LHR has been used in other studies, but is not routinely employed in our center and, regardless, would be unlikely to change significantly the group assignments used in our analyses. Additionally, LHR is neither a measure of total lung volume nor a measure of lung blood flow, and therefore may not be an appropriate surrogate for pulmonary blood flow; however the number of fetuses with complete data for direct measurement of flow in the branch pulmonary arteries was too small for analysis. Use of calculated, rather than measured, foramen ovale flow with temporal differences in flow measurements occasionally led to non-physiological estimations (i.e. negative numbers for flow), and therefore this part of the analysis should be treated as exploratory. Statistical limitations include the use of categorical analysis, although it was felt that this would allow the results to be extrapolated to other work in the area in which severities are often compared in categorical fashion.

In conclusion, we found in a large retrospective cohort of fetuses with CDH that left heart output is decreased regardless of hernia side, which we hypothesize is due to alteration of ductus venosus streaming to the left heart. In addition, there is further left heart hypoplasia seen when the hernia is left-sided but not when the hernia is right-sided, supporting that in left CDH there is a compressive effect on the left heart limiting *in-utero* growth. Our observations are a step towards understanding the origins of left heart hypoplasia in CDH, though future studies that include additional postnatal data analysis are needed to confirm the significance of these observations in CDH patients. Better understanding of fetal alterations in left heart development and hemodynamics may have important clinical implications regarding fetal counseling, management and interventions such as tracheal occlusion<sup>22</sup>.

## ACKNOWLEDGMENT

We thank Dr Abraham Rudolph for his advice and input during the design and data analysis phases of this project.

## REFERENCES

1. VanderWall KJ, Kohl T, Adzick NS, Silverman NH, Hoffman JI, Harrison MR. Fetal diaphragmatic hernia: Echocardiography and clinical outcome. *J Pediatr Surg* 1997; 32: 223–225.
2. Siebert JR, Haas JE, Beckwith JB. Left ventricular hypoplasia in congenital diaphragmatic hernia. *J Pediatr Surg* 1984; 19: 567–571.
3. Vogel M, McElhinney DB, Marcus E, Morash D, Jennings RW, Tworetzky W. Significance and outcome of left heart hypoplasia in fetal congenital diaphragmatic hernia. *Ultrasound Obstet Gynecol* 2010; 35: 310–317.
4. Kohl T, Stressig R. Preferential ductus venosus streaming towards the right side of the heart may contribute to poorer outcomes in fetuses with left diaphragmatic hernia and intrathoracic liver herniation ('liver-up'). *Ultrasound Obstet Gynecol* 2010; 36: 259.
5. Schwartz SM, Vermilion RP, Hirschl RB. Evaluation of left ventricular mass in children with left-sided congenital diaphragmatic hernia. *J Pediatr* 1994; 125: 447–451.
6. Stressig R, Fimmers R, Eising K, Gembruch U, Kohl T. Preferential streaming of the ductus venosus and inferior caval vein towards the right heart is associated with left heart underdevelopment in human fetuses with left-sided diaphragmatic hernia. *Heart* 2010; 96: 1564–1568.
7. Allan LD, Irish MS, Glick PL. The fetal heart in diaphragmatic hernia. *Clin Perinatol* 1996; 23: 795–812.
8. Thebaud B, Azancot A, de Lagaucie P, Vuillard E, Ferkadji L, Benali K, Beauflis F. Congenital diaphragmatic hernia: Antenatal prognostic factors. Does cardiac

- ventricular disproportion in utero predict outcome and pulmonary hypoplasia? *Intensive Care Med* 1997; **23**: 10062–10069.
9. Crawford DC, Wright VM, Drake DP, Allan LD. Fetal diaphragmatic hernia: The value of fetal echocardiography in the prediction of postnatal outcome. *Br J Obstet Gynaecol* 1989; **96**: 705–710.
  10. Baumgart S, Paul JJ, Huhta JC, Katz AL, Paul KE, Spettell C, Spitzer AR. Cardiac malposition, redistribution of fetal cardiac output, and left heart hypoplasia reduce survival in neonates with congenital diaphragmatic hernia requiring extracorporeal membrane oxygenation. *J Pediatr* 1998; **133**: 57–62.
  11. Yang SH, Nobuhara KK, Keller RL, Ball RH, Goldstein RB, Feldstein VA, Callen PW, Filly RA, Farmer DL, Harrison MR, Lee H. Reliability of the lung-to-head ratio as a predictor of outcome in fetuses with isolated left congenital diaphragmatic hernia at gestation outside 24–26 weeks. *Am J Obstet Gynecol* 2007; **197**: 30.e1–30.e7.
  12. Metkus AP, Filly RA, Stringer MD, Harrison MR, Adzick NS. Sonographic predictors of survival in fetal diaphragmatic hernia. *J Pediatr Surg* 1996; **31**: 148–151.
  13. Lopez L, Colan SD, Frommelt PC, Ensing GJ, Kendall K, Younoszai AK, Lai WW, Geva T. Recommendations for quantification methods during the performance of a pediatric echocardiogram: A report from the Pediatric Measurements Writing Group of the American Society of Echocardiography Pediatric and Congenital Heart Disease Council. *J Am Soc Echocardiogr* 2010; **23**: 465–495.
  14. Lytrivi ID, Bhatla P, Ko HH, Yau J, Geiger MK, Walsh R, Parness IA, Srivastava S, Nielsen JC. Normal values for left ventricular volume in infants and young children by the echocardiographic subxiphoid five-sixth area by length (bullet) method. *J Am Soc Echocardiogr* 2011; **24**: 214–218.
  15. Schneider C, McCrindle BW, Carvalho JS, Hornberger LK, McCarthy KP, Daubeney PE. Development of Z-scores for fetal cardiac dimensions from echocardiography. *Ultrasound Obstet Gynecol* 2005; **26**: 599–605.
  16. Pasquini L, Mellander M, Seale A, Matsui H, Roughton M, Ho SY, Gardiner HM. Z-scores of the fetal aortic isthmus and duct: An aid to assessing arch hypoplasia. *Ultrasound Obstet Gynecol* 2007; **29**: 628–633.
  17. Pettersen MD, Du W, Skeens ME, Humes RA. Regression equations for calculation of z scores of cardiac structures in a large cohort of healthy infants, children, and adolescents: An echocardiographic study. *J Am Soc Echocardiogr* 2008; **21**: 922–934.
  18. Rudolph AM. *Congenital Diseases of the Heart: Clinical-Physiological Considerations (3<sup>rd</sup> edn)*. Wiley-Blackwell: Chichester, UK, 2009.
  19. Mielke G, Benda N. Cardiac output and central distribution of blood flow in the human fetus. *Circulation* 2001; **103**: 1662–1668.
  20. Stressig R, Fimmers R, Axt-Fliedner R, Gembruch U, Kohl T. Association of intrathoracic herniation of the liver with left heart hypoplasia in fetuses with a left diaphragmatic hernia but not in fetuses with a right diaphragmatic hernia. *Ultraschall Med* 2011; **32** Suppl 2: E151–156.
  21. Tani LY, Minich LL, Hawkins JA, Pagotto LT, Shaddy RE. Influence of left ventricular cavity size on interventricular shunt timing and outcome in neonates with coarctation of the aorta and ventricular septal defect. *Am J Cardiol* 1999; **84**: 750–752, A759.
  22. Alves da Rocha L, Byrne FA, Keller RL, Miniati D, Brook MM, Silverman NH, Moon-Grady AJ. Left heart structures in human neonates with congenital diaphragmatic hernia and the effect of fetal endoscopic tracheal occlusion. *Fetal Diagn Ther* 2014; **35**: 36–43.