

# UCLA

## UCLA Previously Published Works

### Title

Intravascular ultrasound imaging following balloon angioplasty

### Permalink

<https://escholarship.org/uc/item/3v34z6vg>

### Journal

The International Journal of Cardiovascular Imaging, 6(3-4)

### ISSN

1569-5794

### Authors

Tobis, JM  
Mahon, DJ  
Moriuchi, M  
[et al.](#)

### Publication Date

1991-09-01

### DOI

10.1007/bf01797851

### Copyright Information

This work is made available under the terms of a Creative Commons Attribution License, available at <https://creativecommons.org/licenses/by/4.0/>

Peer reviewed

## **Intravascular ultrasound imaging following balloon angioplasty**

J.M. Tobis,<sup>1</sup> D.J. Mahon,<sup>1</sup> M. Moriuchi,<sup>2</sup> J. Honye<sup>2</sup> & M. McRae<sup>3</sup>

<sup>1</sup>Division of Cardiology, University of California, Irvine, USA; <sup>2</sup>Division of Cardiology, Nihon University, Tokyo, Japan; <sup>3</sup>Department of Pathology, Long Beach Veterans Administration Medical Center, USA

*Key words:* intravascular ultrasound, balloon angioplasty, coronary arteries

### **Abstract**

Despite its long history and reliability, contrast angiography has several inherent limitations. Because it is a two-dimensional projection image of the lumen contour, the wall thickness cannot be measured and the plaque itself is not visualized. This results in an underestimation of the amount of atherosclerotic disease by angiography. An assessment of atherosclerosis could be improved by an imaging modality: (1) that has an inherent larger magnification than angiography and (2) that directly visualizes the plaque. Intravascular ultrasound fulfils these criteria. This presentation will provide evidence that intravascular ultrasound may prove complimentary or even superior to angiography as an imaging modality.

Intravascular ultrasound demonstrates excellent representations of lumen and plaque morphology of *in vitro* specimens compared with histology. There is very close intraobserver and interobserver variability of measurements made from intravascular ultrasound images. Phantom studies of stenoses in a tube model demonstrate that angiography can misrepresent the severity of stenosis when the lumen contour is irregular and not a typical ellipse, whereas intravascular ultrasound reproduces the cross-sectional morphology more accurately since it images the artery from within. *In vitro* studies of the atherosclerotic plaque tissue characteristics compare closely with the echo representation of fibrosis, calcification, and lipid material. In addition, *in vitro* studies of balloon angioplasty demonstrate that intravascular ultrasound accurately represents the changes in the structure of artery segments following balloon dilatation.

### **Introduction**

To understand the mechanism of balloon angioplasty, intravascular ultrasound imaging was performed in a series of human atherosclerotic arteries *in vitro* [1] and in human coronary arteries *in vivo* following balloon dilatation [2]. The purpose of the project was to visualize the morphologic effects of balloon inflation, and to measure the lumen and the atheroma cross-sectional areas at the site of balloon angioplasty.

### ***In vitro* study**

The ultrasound imaging catheter used in this study is a mechanically rotating device that spins within a protective sheath. A single 20 MHz ultrasound transducer transmits the ultrasound energy against a mirror placed at 45° to deflect the sound waves perpendicular to the long axis of the catheter. The transducer and mirror are separated by 2 mm to permit the ringdown artifact to occur within the catheter so that useful imaging information can be obtained up to the edge of the catheter shaft. The initial design of this catheter was 1.3 mm in diameter which was inserted into a 1.7 mm plastic sheath. The most recent design is a 1.0 mm diameter

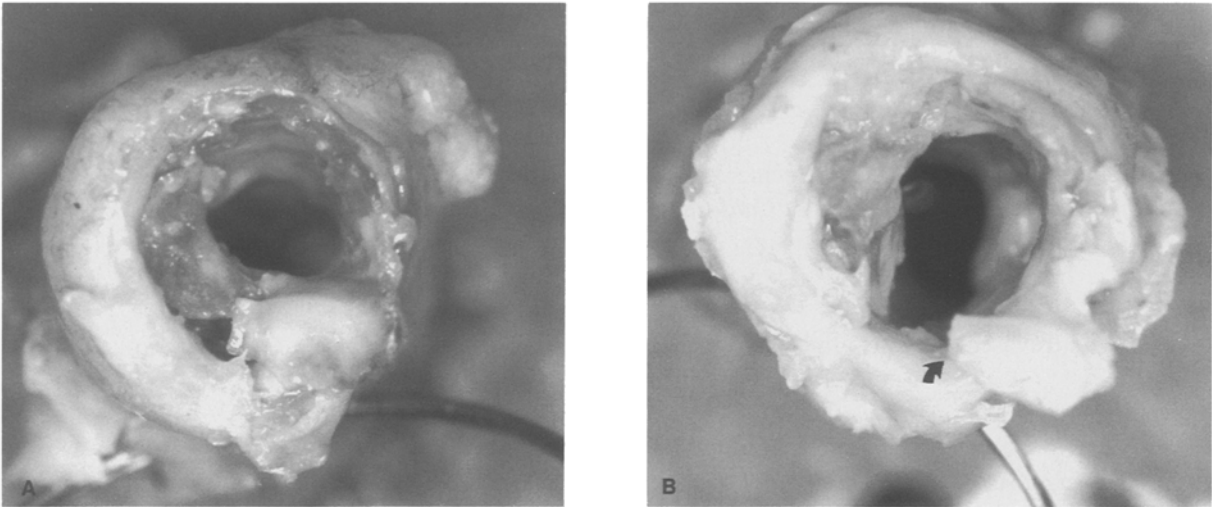


Fig. 1. A, Photograph showing an artery segment on end with a surgical needle passed perpendicular to the wall of the artery. The surgical needle was visualized with the ultrasound device to establish a reference plane so that the ultrasound images and the histologic sections could be correlated. B, The same arterial segment following balloon dilatation. There is a tear in the plaque along the inferior wall with separation of the torn ends (arrow). (Reprinted with American Heart Association's permission.)

ultrasound subassembly which passes through a 1.3 mm external diameter plastic sheath. During the *in vitro* studies, cross-sectional images were obtained by manually rotating the transducer 360° while the catheter was placed within the arterial lumen. As the catheter was rotated, the position of the catheter and the ultrasound reflections were integrated through a computer to provide a cross-sectional image on a video monitor.

Human atherosclerotic arteries were obtained at autopsy or after lower extremity amputation. Arteries were obtained from the coronary, iliac, femoral, and tibial systems. A variety of arteries were used to assess the ability of the catheter to image a wide range of lumen and atheroma dimensions. Each artery was cut into 2-cm long segments. The artery segments were mounted on end on a plastic platform using a quick-drying glue. The tip of the ultrasound catheter and the mounted artery segment were placed in a small beaker of saline. Care was taken to wash all air bubbles from the artery segment and catheter tip. The short artery sections were firm enough to permit the catheter to remain coaxial with the long axis of the artery. This alignment assisted in obtaining optimal images. If the long axis of the catheter is more than 15° off the

long axis of the artery, then there is some loss of the reflected ultrasound energy.

Seventeen artery sections were imaged at 1-mm intervals along the length of the artery segment before dilatation by adjusting a calibrated screw attached to the transducer mount. To obtain correct alignment and reference with the histologic sections, a surgical needle (that could be visualized with the ultrasound device) was passed perpendicular to the long axis of the artery and used as a reference (Fig. 1). After initial imaging, the artery segment was removed from the plastic mount and dilated with an appropriately sized coronary or peripheral artery balloon. The balloon diameter was chosen so that the inflated diameter of the balloon was 1.0 to 1.3 times the diameter of the artery. After dilatation, the artery sections were remounted onto the plastic base with glue and replaced within the beaker of saline. Care was taken to align the artery in an orientation similar to the one used to obtain the initial images. A second set of ultrasound images were then acquired at 1-mm increments, at the same levels as were imaged prior to dilatation.

After the study of each artery was completed, the computer images were restored from the disk. Measurements were made of the cross-sectional

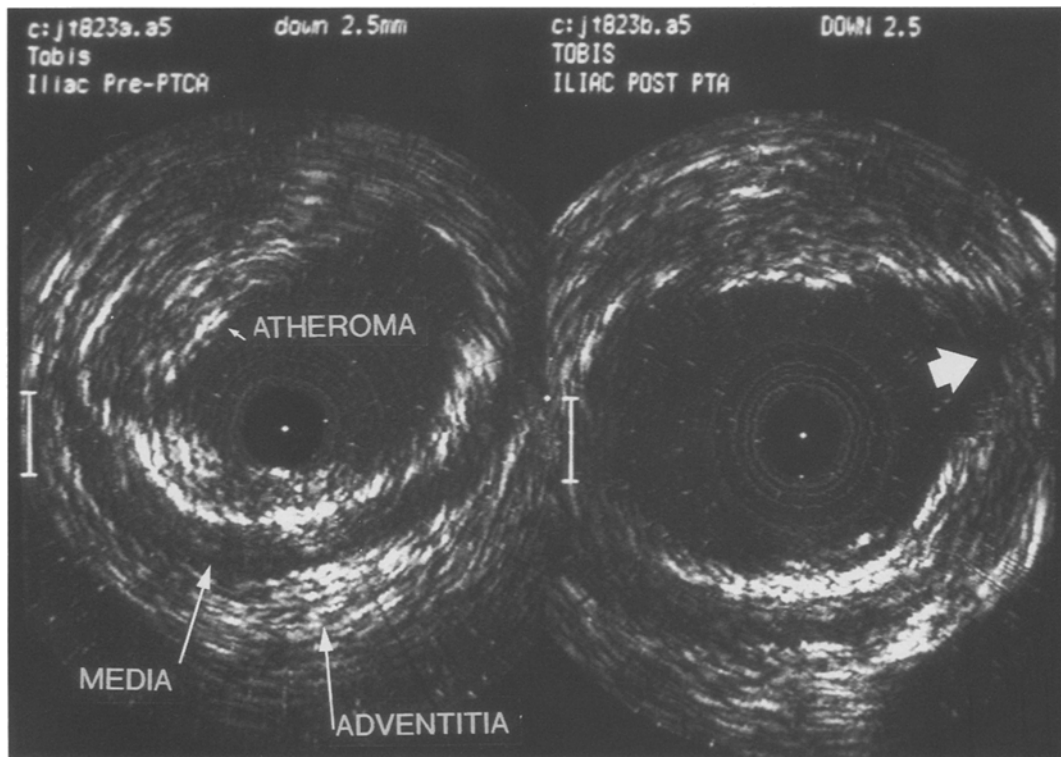


Fig. 2. Photograph from the computer monitor showing a pair of ultrasound images from an iliac artery before dilatation (left) and following dilatation (right). The image was obtained 2.5 mm below the reference line of the needle. This artery was only moderately diseased. The central black area is where the transducer is located. The echo free lumen is clearly delineated from the fibrous plaque which has high echo reflectance. The muscular media has low echogenicity and the surrounding adventitia shows high echo reflectance. Following balloon dilatation, the artery cross-sectional area is increased and there is a minor tear in the plaque (arrow). (Reprinted with American Heart Association's permission.)

area of the lumen predilatation and postdilatation along the length of the artery, and compared by a paired t-test. Histologic sections were prepared from the arterial segments. The arteries were marked with india ink at the level where the reference needle had been placed. They were embedded in paraffin blocks and cut into 6- $\mu$ m-thick segments at intervals of 1 mm. The sections were stained with hematoxylin and eosin. Quantitative measurements were made from photographs of the histologic sections using a calibrated digitized pad. The histologic cross-sectional measurements were compared by linear regression analysis to the post-dilatation ultrasound image measurements.

### Results

A representative ultrasound image pair, before and after balloon dilatation, is demonstrated in Fig. 2 from an artery section that was only moderately diseased. In all 15 of the specimens in which adequate images were obtained, the echo-free lumen was clearly delineated. Of the 15 arteries, the fibrous lesion was noted as a region of high echo reflectance, as was the adventitia, whereas the muscular media was seen as a region of low echogenicity. In four arteries, extensive fibrosis and calcification present within the plaque strongly reflected the ultrasound waves and prevented visualization of large regions of the media and adventitial layers (Fig. 3).

The ultrasound and histologic images were ana-

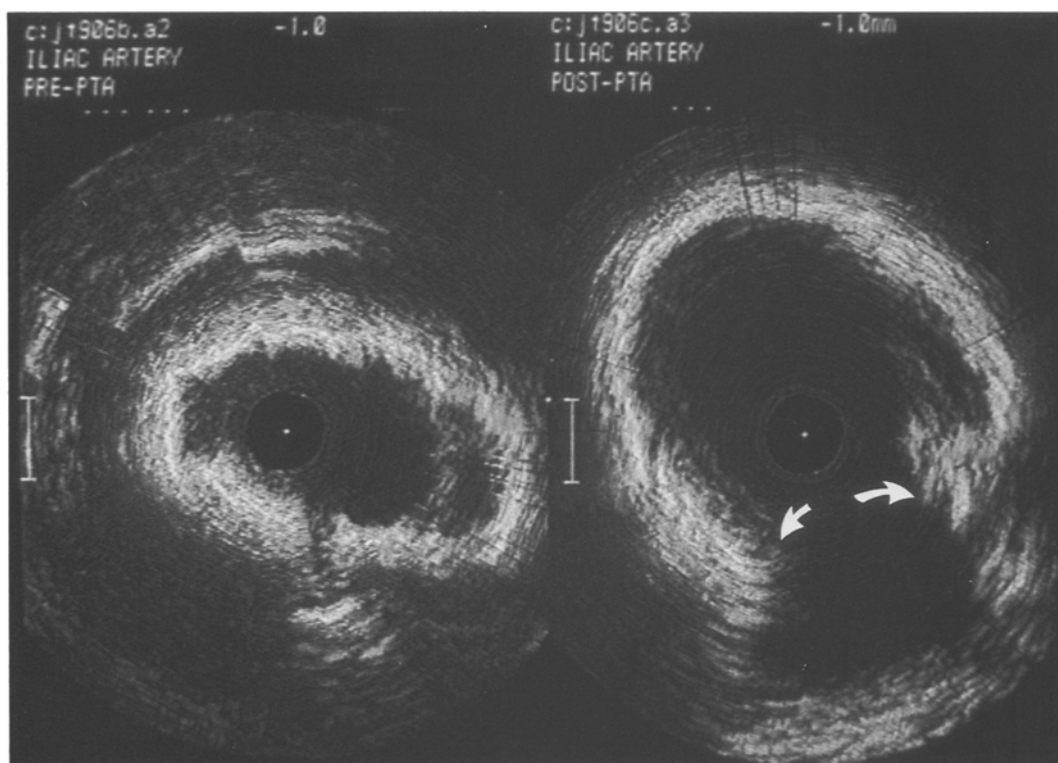

Fig. 3. Pair of ultrasound images obtained from the arterial segment shown in Fig. 1. In the ultrasound image prior to balloon angioplasty (left), although the outline of the internal lumen is well demarcated, extensive fibrosis and calcification present within the plaque strongly reflected the ultrasound waves and prevented visualization of much of the media and adventitia layers. Following balloon dilatation (right), the lumen has increased substantially in area, primarily due to separation of the torn ends of the plaque (arrows). (Reprinted with American Heart Association's permission.)

lyzed for evidence of plaque tears and dissection postdilatation. The criterion for making a diagnosis of a plaque tear was the observation of a fracture of the intimal plaque with separation of the torn ends as shown in the postdilatation image in Fig. 4. There also appears to be a new lucency caused by separation of the intimal plaque from the media. The corresponding histologic cross-section also demonstrates a fracture of the intimal plaque with separation of the torn ends, as well as separation of the plaque from the media. In most arteries studied, balloon dilatation created a tear through the plaque, which typically was located through the thinnest region of the plaque or at the junction plaque and normal artery wall. The artery was stretched in this region, which resulted in enlargement of the internal lumen. The tear was frequently associated with a dissection plane between the

plaque and the internal elastic membrane. These observations by intravascular ultrasound are similar to previously reported histologic *in vitro* studies or pathologic studies in patients who died following coronary balloon angioplasty [3]. In several instances, the ultrasound images also visualized the presence of an intimal flap (Fig. 5).

The number of tears in the arterial plaque seen by ultrasound and by histology following balloon dilatation is shown in Fig. 6. The ultrasound images accurately predicted the histologic presence or absence of tears in 11 of the 13 artery segments in which matched ultrasound and histologic sections were available.

To determine the accuracy of the intravascular ultrasound measurement of lumen area, the lumen cross-sectional area obtained by ultrasound was compared with measurements obtained from the

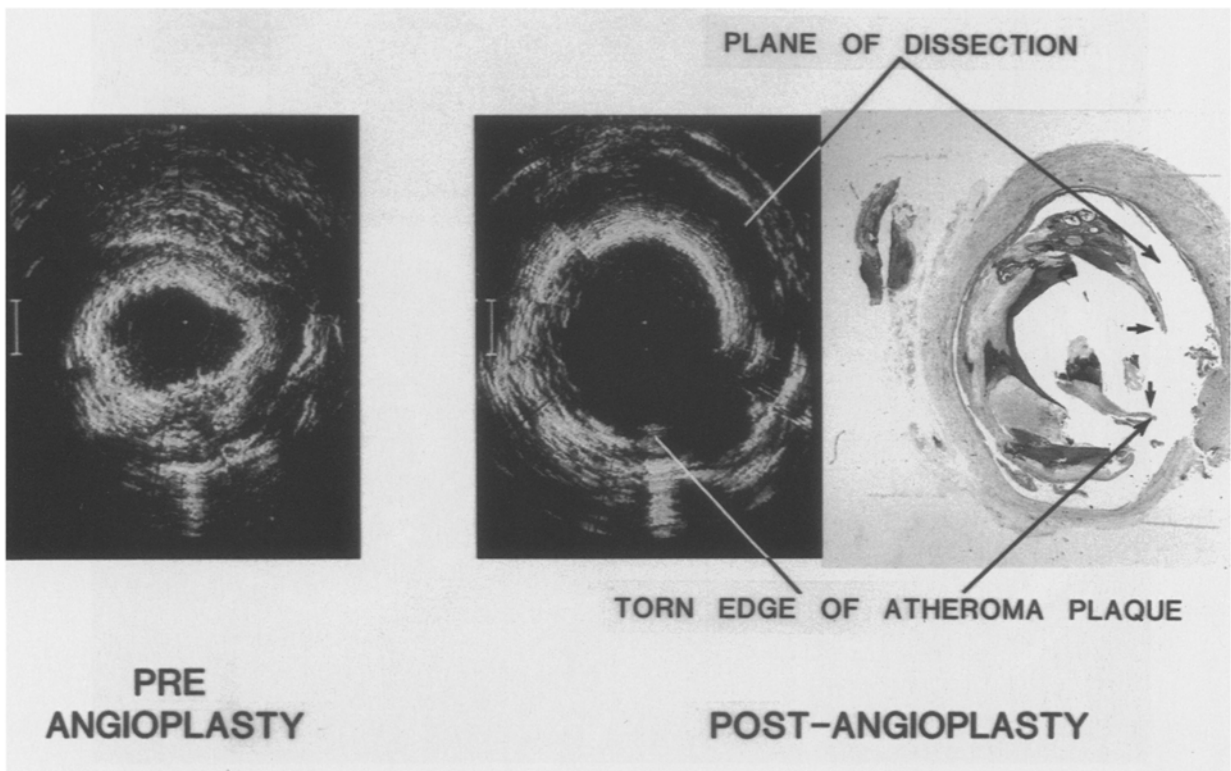


Fig. 4. Composite photograph demonstrating the ultrasound images from a severely diseased artery before and after dilatation. The needle artifact is seen in the inferior aspect of the images. The lumen is enlarged with a fracture of the densely calcified plaque and separation of the torn ends (arrows). Moreover there is a new lucency (arrow) which may represent a dissection with separation of the intimal plaque from the media. The histologic section was obtained from the same artery segment as the ultrasound images. There is disruption of the intimal plaque with separation of the torn ends. In addition, there is separation of the plaque from the medial wall (arrow). The ultrasound image has correctly predicted the position and extent of the dissection as seen on histology. (Reprinted with American Heart Association's permission.)

histology sections at multiple sites along the length of each artery segment. Images were obtained at the level of the reference needles, as well as 1 and 2 mm above and below the needle. The number of measurement pairs available for each artery varied between three and five. Figure 7 demonstrates the correlation of cross-sectional area obtained with the intravascular ultrasound catheter to those obtained from histology for 39 paired postdilatation sections. The correlation coefficient was 0.88 and the standard error of the estimate was  $3.2 \text{ mm}^2$ . The measurements were related by the equation: Lumen area (ultrasound) =  $(0.94 \times \text{lumen area [histology]}) + 0.52 \text{ mm}^2$ .

Ultrasound cross-sectional areas were compared before and after balloon dilatation to assess the

magnitude of the increase in lumen area produced by balloon inflation. In each of the 15 artery segments in which adequate ultrasound images were obtained, the cross-section that showed the greatest percent change in lumen area following dilatation was determined. The maximal luminal area increased on average from  $8.7$  to  $15.1 \text{ mm}^2$  ( $p < 0.01$ ) following dilatation.

#### *Tissue characteristics determined by intravascular ultrasound*

During human clinical studies with intravascular imaging, one does not have the luxury of comparing the cross-sectional images with histologic prep-

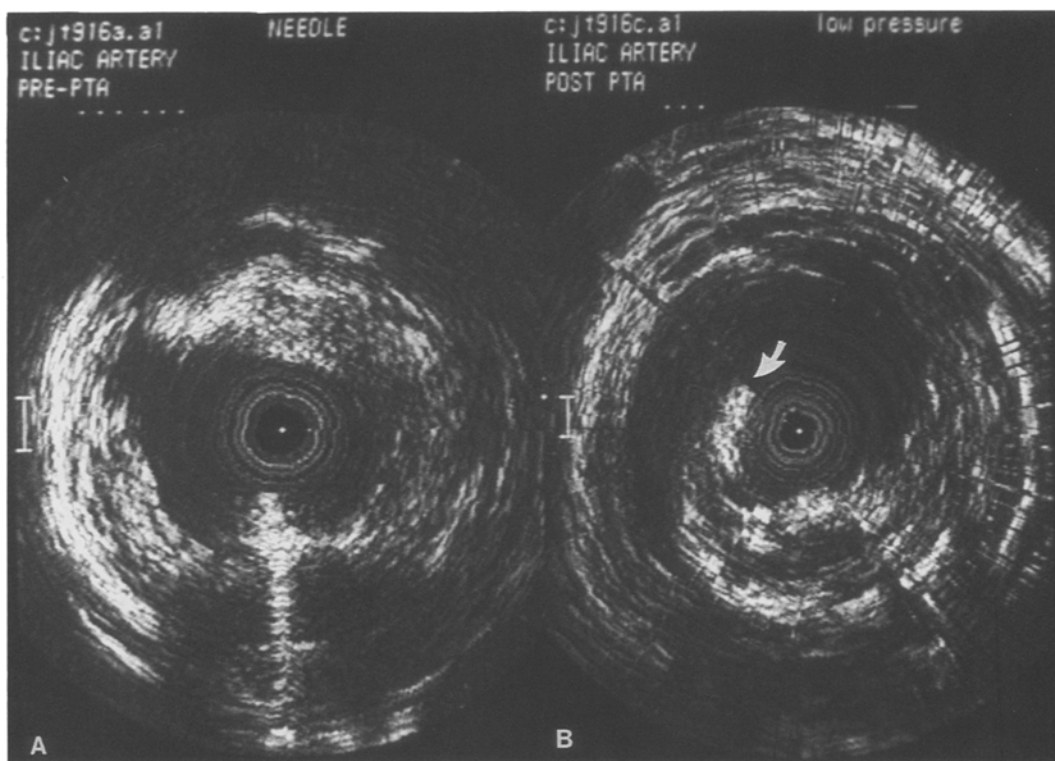


Fig. 5. In this composite photograph of ultrasound images from another artery before (A) and after (B) balloon dilatation, not only was the arterial plaque torn, but an intimal flap is seen to protrude into the lumen (arrow). (Reprinted with American Heart Association's permission.)

**ARTERIAL TEARS OBSERVED**

		HISTOLOGY	
		+	-
ULTRA SOUND	+	10	0
	-	2	1

Fig. 6. The presence of a tear in the arterial plaque as seen by ultrasound and by histology following balloon dilatation is demonstrated in this chart. The criteria for making a diagnosis of the tear was the observation of a fracture of the intimal plaque with separation of the torn ends. The ultrasound images accurately predicted the histologic presence or absence of tears in 11 of 13 cases. (Reprinted with American Heart Association's permission.)

arations. Therefore, the basis for interpreting the ultrasound images *in vivo* depends on the morphology and tissue characteristics of the ultrasound pattern which are confirmed by prior histologic studies *in vitro*. Figures 8–10 show some of the usual ultrasound reflective patterns compared with the tissue characteristics as demonstrated on corresponding histologic sections. Figure 8 shows a human carotid artery which has an eccentric fibrous plaque without calcification, thrombus or lipid. The corresponding ultrasound image demonstrates a homogeneous pattern of reflection from the fibrous tissue. The first intense reflection between the lumen and the wall of the plaque atheroma is due to the internal elastic membrane which covers the media in the uninvolved segment of the artery; but the same echo reflection continues around the circumference of the artery behind the plaque and central to the media exactly corresponding to the

position of the internal elastic membrane on the histologic section.

The majority of the atherosclerotic artery segments that were observed both in the *in vitro* and the *in vivo* clinical series demonstrate some evidence of calcification. A representative example is shown in Fig. 9 where an eccentric atherosclerotic plaque has histologic evidence of a small amount of calcium at its base, adjacent to the media. It is frequently observed that the media is attenuated and partially or completely destroyed at the base of these chronic atherosclerotic plaques. This is an important caveat for intravascular ultrasound imaging which uses the outline of the echolucent media to define the extent of the atheroma. On the corresponding ultrasound image, the echogenic signature of calcium is shown as an intense reflection of ultrasound energy, with dropout of information or 'shadowing' peripheral to the area of calcium. In our clinical series, small areas of calcium were seen in 82% of the arterial segments at the site of balloon angioplasty. However, this calcium is too small to be perceived by fluoroscopy or cineangiography, and only 8% of the angiograms demonstrated calcium at the level of the balloon angioplasty, although calcium was seen in more proximal areas of the artery by fluoroscopy in 15% of the pa-

#### ULTRASOUND IMAGING CATHETER HISTOLOGIC CORRELATION

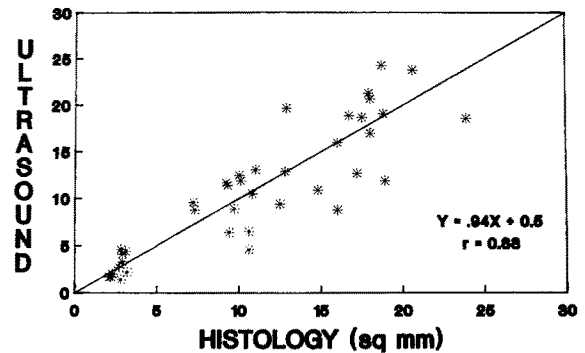


Fig. 7. In order to determine the accuracy of the measurements of lumen area, the ultrasound lumen cross-sectional area was compared with measurements obtained from the histologic sections at multiple sites along the length of each artery segment. The correlation coefficient was 0.88 for measurements of cross-sectional area obtained with the intravascular ultrasound catheter (y-axis) as compared with the measurements from histology (x-axis). (Reprinted with American Heart Association's permission.)

tients. Both in the histologic samples *in vitro* as well as the ultrasound images *in vivo*, the calcium usually occurs at the base of the plaque. However, there were occasional episodes where the fibrous

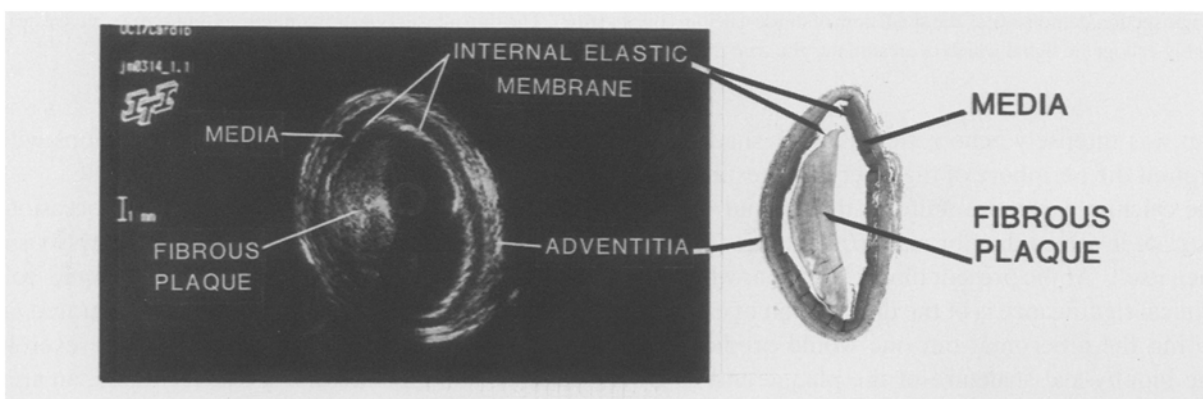
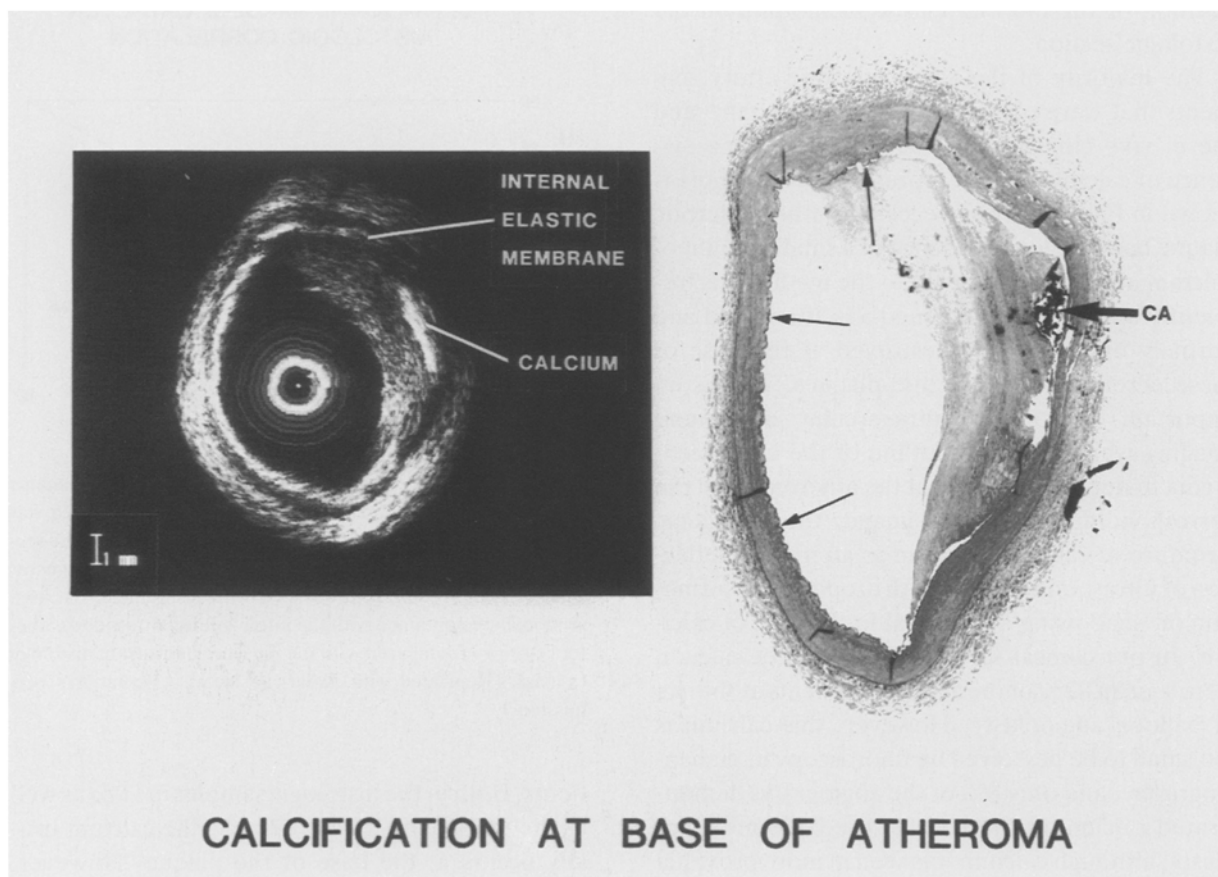


Fig. 8. Ultrasound image of a human carotid artery showing fibrous intimal thickening, but no calcification. The fibrous plaque is a good echo-reflector, but is not as brightly reflective as calcification, and no shadowing is observed. The companion histologic section shows the eccentric fibrous plaque without calcification. The intimal plaque has been separated artificially during histologic preparation from the media, and the lumen shape is distorted. The internal elastic membrane is represented by a thicker echo-reflective line which extends behind the atheroma. (Reprinted with American Heart Association's permission.)



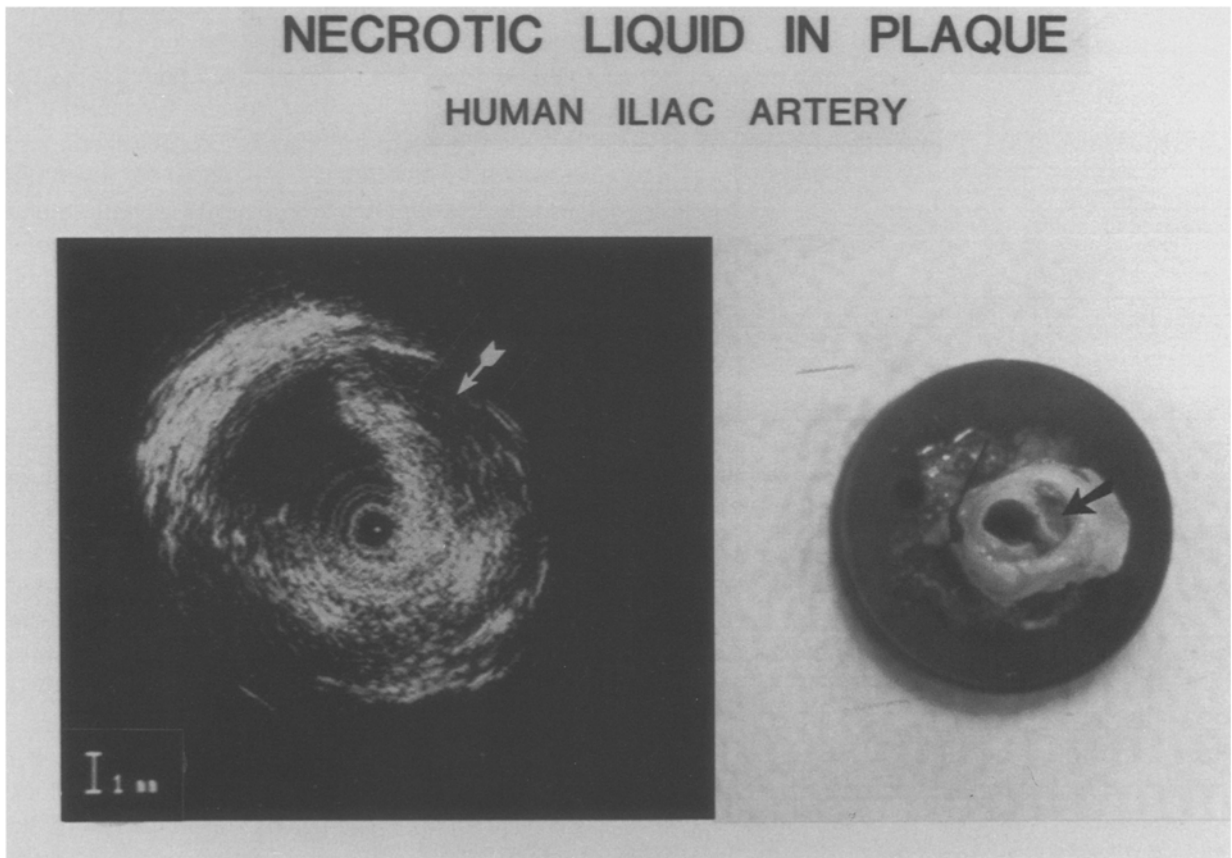


*Fig. 9.* An ultrasound image of a diseased human carotid artery. The eccentric intimal plaque contains a small region of calcification at its base which causes shadowing or dropout of echo information. The echolucent media is seen circumferentially. The corresponding histologic section demonstrates the small area of dense calcium (thick arrow). The thin internal elastic membrane (thin arrows) generates a highly echogenic signal which overestimates the true thickness of this echo reflective structure.

cap was intensely echo reflective with shadowing around the periphery of the artery, suggesting that the calcium was more uniform throughout the lesion, or involved the fibrous cap adjacent to the lumen itself. At the present time it is unclear what the clinical significance is of the distribution of calcium within the atheroma, but one would predict that the biophysical structure of the plaque and its fibroelastic properties would be an important predictor of the plaque's response to various interventions such as balloon dilatation, atherectomy, laser ablation, or use of the rotablator. Intravascular ultrasound imaging of the tissue characteristics of the atheroma plaque will provide significant contributions in future long-term studies which attempt to

compare the results of various interventions with the type of tissue present within the plaque.

Another variety of tissue that was seen occasionally in peripheral arteries, but has been rarely visualized in coronary vessels, is the lipid liquid collection within the atheroma as demonstrated in Fig. 10. When the gross specimen from a severely diseased human iliac artery was sectioned, an area of green liquid oily material was visualized (arrow). During the ultrasound interrogation of this artery segment, a densely reflective fibrotic cap and atheroma were visualized, but behind the atheroma was an echolucent area which corresponded to the position of the liquid pool on the gross specimen. This area is distinguished from calcification because



*Fig. 10.* This ultrasound image from a severely diseased artery illustrates a large echolucent region (arrow). The companion gross specimen shows a large space to the right of the lumen (arrow) which contained a lipid. (Reprinted with American Heart Association's permission.)

there is not a complete dropout of echoes and shadowing behind the fibrous cap, but a rim of echo reflections from the outer wall of the artery is still visualized.

#### ***In vivo* clinical studies**

Intracoronary ultrasound images were obtained in 50 of the 56 patients studied after balloon angioplasty [2]. Ultrasound images were not obtained in six patients because of technical difficulty in placing the introducer sheath into the coronary artery in the early stages of this study. There was a 'learning curve' phenomenon in the use of the ultrasound sheath and imaging subassembly. In addition, there have been several modifications made in the

sheath and subassembly which facilitate the use of the device. In the last 35 patients there has been no difficulty in placing the sheath and transducer into the coronary artery. Coronary artery imaging was performed following standard balloon angioplasty. The introducing sheath was passed over an extension guidewire into the coronary artery. The guidewire was removed and the ultrasound subassembly was then inserted into the sheath. The imaging subassembly is rotated at 1800 RPM to produce real-time cross-sectional images at 30 times per second. The most recent design uses a quick exchange sheath system similar to the Monorail<sup>®</sup> catheter. This design significantly increases the facility to perform imaging following balloon angioplasty and the lower profile 1.3 mm sheath makes it feasible to image stenotic arteries before as well as following

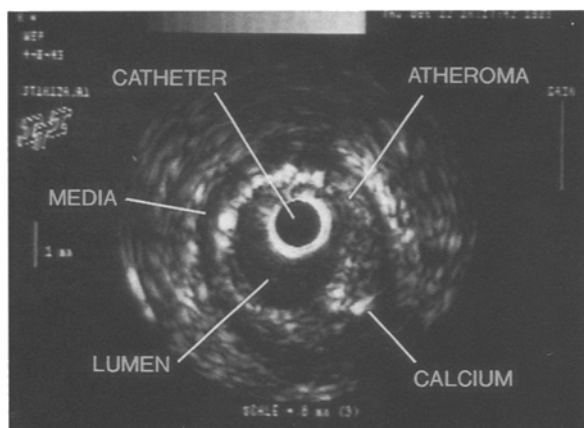


Fig. 11. A representative intravascular ultrasound image of the mid LAD. This ultrasound image was taken from a section of the artery that appeared normal on angiography. (Reprinted with American Heart Association's permission.).

balloon angioplasty. The ultrasound images are recorded on super VHS videotape, and the position of the ultrasound transducer within the artery is documented by capturing sequential fluoroscopic images and recording them on the videotape with the simultaneous ultrasound image. Intermittent saline flushes by hand injection through a 3 ml syringe are used to help dislodge minute air bubbles from adhering to the transducer surface.

A representative intravascular ultrasound cross-sectional image from the mid portion of the LAD is shown in Fig. 11. The central black area represents the ultrasound catheter. Surrounding the black circle is a white band that corresponds to the echo reflection from the 1.7-mm plastic sheath. Around the plastic sheath is the lumen of the artery represented by a dark echolucent area with occasional small echogenic reverberations. The atheroma is exposed as a mildly eccentric plaque around the entire circumference of the artery with more intense echo reflections between 9 and 10 o'clock and at 5 o'clock. Based on the prior observations from the *in vitro* histologic studies, these intense echo reflections probably represent small flecks of calcification within a fibrous matrix. The dropout of echoes behind the echo-dense material at 5 and 12 o'clock is typical of calcification. Surrounding the echogenic atheroma is a black band of echolucent area (ap-

proximately 0.2 mm in width) that corresponds to the media. Despite the dropout of some echoes behind the small area of calcium, the boundary of the atheroma-media interface can still be determined for quantitative purposes. Beyond the media are echogenic structures corresponding to adventitia with poor distinction between the adventitia and surrounding tissues. The dimensions of the lumen are  $2.3 \times 2.8$  mm, and the cross-sectional luminal area is  $5.1 \text{ mm}^2$ . The total cross-sectional area within the boundary of the media is  $12.2 \text{ mm}^2$ . The atheroma subtends an area of  $7.1 \text{ mm}^2$  or 58% of the available arterial area.

Figure 12 demonstrates a composite series of intravascular ultrasound images that were obtained in a patient with aneurysmal dilatation of the right coronary artery. In the first panel (A), it is interesting to note that the intravascular ultrasound image is capable of discriminating the takeoff of the sinus node artery which measures 0.8 mm in diameter. The level of the balloon angioplasty was performed in the mid right coronary artery corresponding to the segment shown in panel C. A section of calcified atheroma between 5 and 12 o'clock has been separated at 4 o'clock from the rest of the mass of atheroma which permits improvement of the lumen cross-sectional area. Panel D demonstrates aneurysmal dilatation of the coronary artery. It is important to note that none of these images reveals a discernible media; this is consistent with destruction of the media from Mönckeberg's degeneration of the media with resultant aneurysmal dilatation.

The angiogram of a circumflex artery that was dilated at its mid portion is demonstrated in Fig. 13. In the proximal segment of the circumflex artery, there is minimal notching in the angiogram, which corresponds to mild eccentric atheroma visualized on the intravascular ultrasound image. In the mid portion of the artery, following successful balloon dilatation, the lumen diameter appears widely patent. However, the intravascular ultrasound images demonstrate significant residual concentric atheroma with dissection behind the atheroma which is not contiguous with the lumen and, therefore, did not show up on the angiogram.

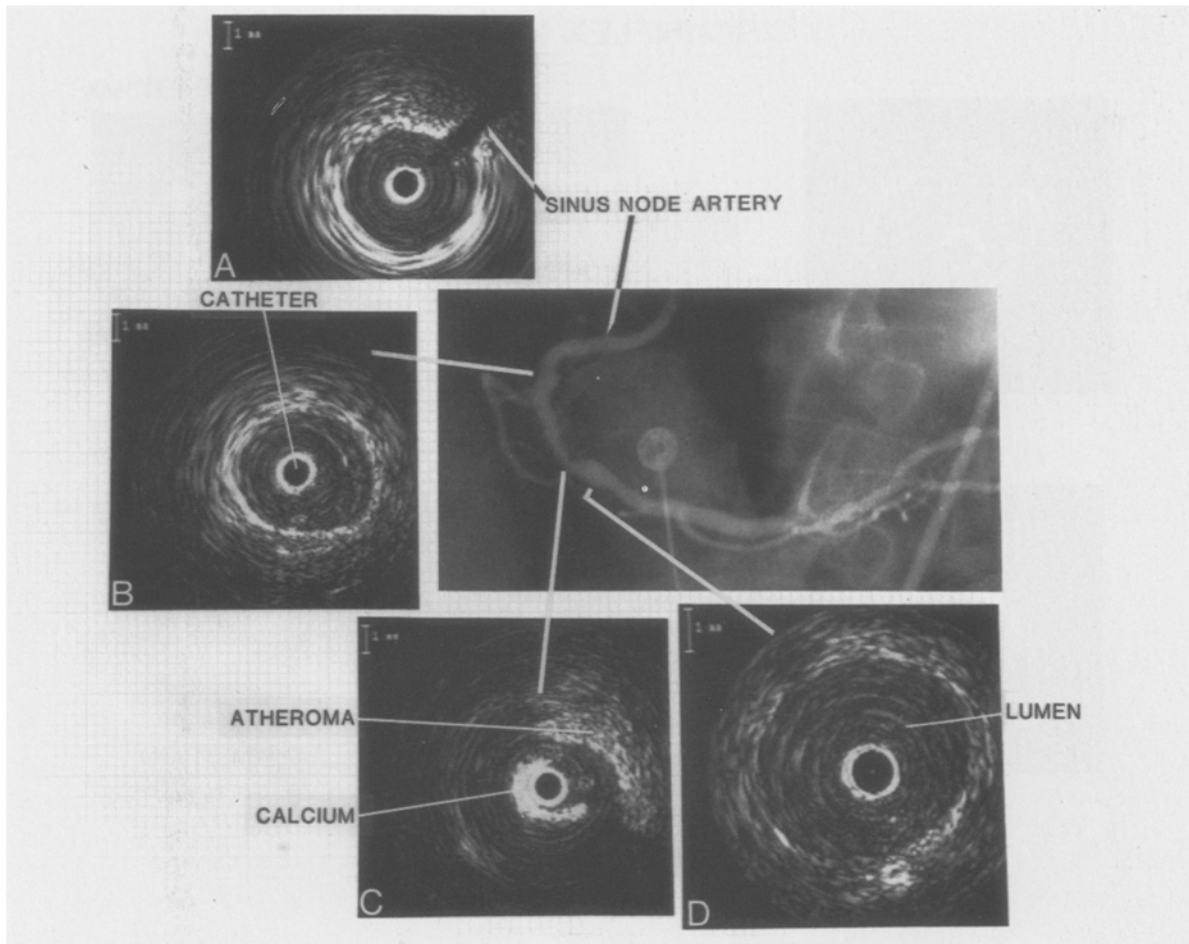


Fig. 12. Aneurysmal dilatation of the right coronary artery without apparent media. Coronary balloon angioplasty was performed at the middle segment corresponding to panel C.

### Quantitative analysis

The lumen cross-sectional areas and diameters measured directly from the ultrasound images and the lumen diameters measured by angiography (which were used to calculate cross-sectional area) are shown in Table 1 for both the angiographically uninvolved segments and for the site of the prior balloon dilatation. The mean lumen cross-sectional area on the ultrasound images ( $9.2 \pm 4.6 \text{ mm}^2$ ) was larger than the mean area from angiography ( $7.1 \pm 2.5 \text{ mm}^2$ ) for the angiographically normal segments ( $p < 0.05$ ). Moreover, the mean lumen area at the previously dilated site by ultrasound ( $5.0 \pm 2.0 \text{ mm}^2$ ) was larger than the mean area calculated by angio-

graphy ( $3.3 \pm 1.3 \text{ mm}^2$ ,  $p < 0.01$ ). In addition, a poor correlation was found between the individual measurements of the dilated area by ultrasound and by angiography as demonstrated in Fig. 14. When only the normal segments were compared, the correlation was still poor between the ultrasound images and angiography for measuring the arterial lumen ( $Y = 0.48X + 5.8$ ,  $r = 0.26$ ).

Atheroma cross-sectional areas determined from the ultrasound images are presented in Table 2. A significant amount of atheroma was observed on the ultrasound images that was not discernible by angiography at both the previously dilated sites and the apparently normal (by angiography) segments. The ability to obtain adequate images of the

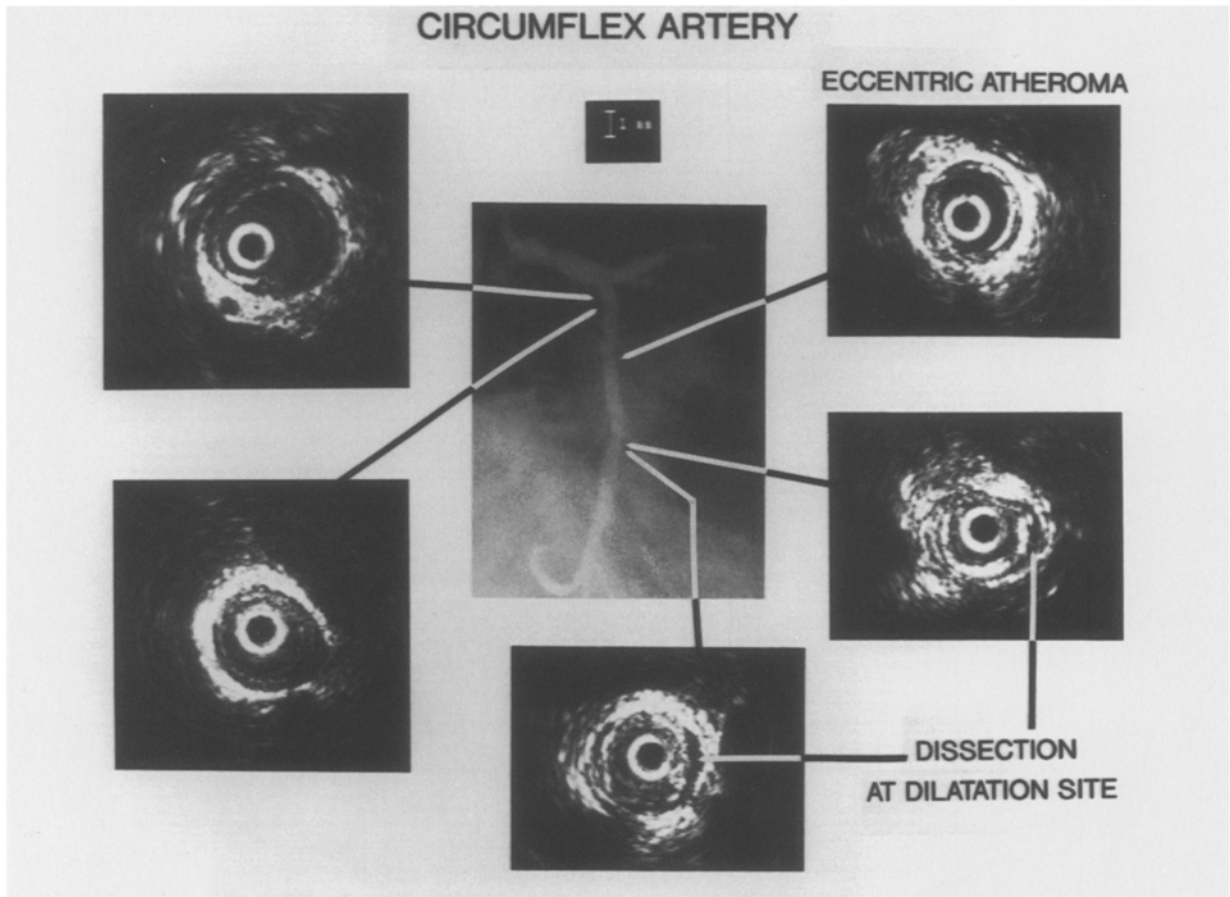


Fig. 13. Circumflex artery following balloon dilatation of middle segment. There is an eccentric atheroma with a dissection behind it.

atheroma area during the *in vivo* studies was enhanced by the motor driven unit that obtained cross-sectional images at 30 times/sec compared with the hand-rotated device used during the *in vitro* studies.

### Discussion

These studies demonstrate that intravascular ultrasound imaging provides real-time cross-sectional views of coronary arteries *in vivo* that correspond very closely to the histologic morphology and tissue characteristics that were observed during the *in vitro* studies. From these intravascular images, it is possible to describe the lumen geometry in terms of eccentricity of the plaque and to calculate the cross-

sectional area of the lumen and atheroma [4, 5]. The ultrasound images are also capable of distinguishing certain characteristics such as fibrous tissue, calcification and lipid or liquid material within the atheroma plaque [6]. This type of information about cross-sectional geometry, plaque morphology, and tissue characterization is unobtainable from angiographic studies [7]. Significant involvement of the arterial wall with atheroma can be demonstrated on the ultrasound images even in the coronary segments that appear normal on angiography. Small areas of calcification within the atheroma are visualized by ultrasound but not by angiography. In addition, the ultrasound images demonstrate the effects of balloon angioplasty with tears in the plaque and separation of the ends of the atheroma along with dissection. The information

provided by intravascular ultrasound is complimentary to angiography, and often provides more detail about the plaque morphology than is visualized by angiography.

The correlation between the lumen area measured by ultrasound and angiography was very poor ( $r = 0.12$ ). This poor correlation was due in part to the dissections from balloon dilatation that resulted in irregular crescentic pathways with unclear borders of the lumen on angiography. However, even in the angiographically normal segments, the correlation between the measurements from angiography and ultrasound was not close ( $r = 0.26$ ). Although other investigators have found a closer correlation between intravascular ultrasound and angiography at the normal segments [5], we suspect the poor correlation is also explained by errors in measurement of absolute lumen area using the catheter tip to calibrate the magnification factor on angiography. We believe that the intravascular ultrasound images are more accurate than angiography for measuring the cross-sectional area provided that the quality of the ultrasound image is such that the boundary of the lumen and the atheroma is clearly displayed.

In the cases where the angiogram and the ultrasound images correlate poorly, two sources of *in vitro* data suggest that the ultrasound images provide the more accurate representation. Several studies have shown excellent correlations between the lumen cross-sectional area measured from ul-

### CORONARY ARTERY LUMEN AREA POST BALLOON ANGIOPLASTY

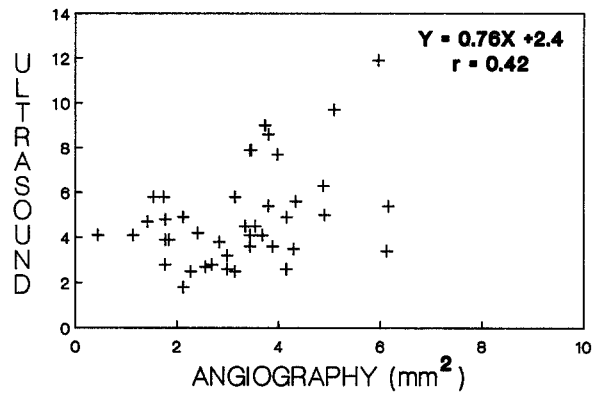


Fig. 14. Comparison of cross-sectional lumen area at the level of balloon dilatation as measured directly on the ultrasound images and calculated from lumen diameters on orthogonal angiograms.

trasound images compared with direct measurements from histologic cross-sections [1, 5, 6, 8, 9]. In addition, an *in vitro* study using acrylic casts of a phantom model has demonstrated that contrast angiography overestimates the true lumen cross-sectional area compared with intravascular ultrasound when the lumen is not elliptical but irregular [10]. This can result in an underestimation of lesion stenosis on diagnostic angiography or an overestimation of the beneficial results after balloon angioplasty.

Upon viewing intravascular ultrasound images,

Table 1. Coronary artery lumen measurements.

Ultrasound		Angiography			
Diameters (mm)		Diameters (mm)		Lumen area (mm <sup>2</sup> )	
Major	Minor	RAO	LAO		
At the previously dilated segment					
2.7 ± 0.7	2.2 ± 0.6	5.0 ± 2.0 <sup>+</sup>	2.0 ± 0.6	1.9 ± 0.5	3.3 ± 1.3 <sup>+</sup>
At the angiographically normal segments					
3.4 ± 1.2	3.0 ± 1.1	9.2 ± 4.6 <sup>*</sup>	3.0 ± 1.0	3.1 ± 0.9	7.1 ± 2.5 <sup>*</sup>

<sup>+</sup>  $p < 0.01$ .

<sup>\*</sup>  $p < 0.05$ .

RAO = Right anterior oblique.

LAO = Left anterior oblique.

Table 2. Coronary artery atheroma area by ultrasound.

	Atheroma cross-sectional area	Percent of area within media filled with atheroma
At the previously dilated site	$8.7 \pm 3.4 \text{ mm}^2$	$63.1 \pm 12.7\%$
At the angiographically normal segments	$4.7 \pm 3.2 \text{ mm}^2$	$34.6 \pm 23.2\%$

experienced interventional angiographers are impressed by the huge amount of residual atheroma that remains at the site of balloon angioplasty. Because angiography only visualizes the lumen and not the atheroma in the arterial wall, the angiographer has limited appreciation of the amount of material that coats the artery and produces the stenosis. Although pathologic studies have told us repeatedly that angiography underestimates the extent of atherosclerotic disease [11], angiographers remain skeptical because they are more familiar with the visual appearance of angiograms than with pathologic studies performed on a subset of people who come to autopsy. Intravascular ultrasound imaging provides stark evidence that what is documented in pathologic studies indeed occurs on a routine basis in patients with ischemic heart disease. In this study, the mean cross-sectional area of the atheroma after dilatation was  $8.7 \pm 3.4 \text{ mm}^2$  which represented  $63.1 \pm 12.7\%$  of the available arterial cross-sectional area inside the media. Given these ultrasound observations on the massive residual atheroma, it is not surprising that acute occlusion or restenosis occur, if anything, it is intriguing that the incidence of these events is not higher.

Of particular concern is the observation that the amount of atheroma was underestimated in the 'normal' segments by angiography compared with the cross-sectional ultrasound images. In the segments of the artery that were considered angiographically normal, the ultrasound images revealed that atheroma plaque encompassed a mean of 35% of the cross-sectional area. This finding from the ultrasound images *in vivo* is consistent with previous pathologic studies that suggested

that angiography underestimates the amount of atherosclerosis present in coronary arteries [7]. In addition, the results of these intravascular ultrasound studies may explain why angiography is not reliable in predicting the progression of atherosclerosis in patients with mild-to-moderate disease as defined by angiography [12]. What appears as minimal disease by angiography may, in fact, correspond to atheroma subtending 50% of the cross-sectional area. This degree of plaque may not be morphologically stable and could appear to progress rapidly or proceed to occlusion despite the apparently benign angiogram.

These initial observations will require confirmation by other researchers and longitudinal studies. The results raise the question whether intravascular ultrasound imaging should challenge contrast angiography as the standard for quantitative analysis of the extent of atherosclerotic involvement of coronary arteries. We believe the future of intravascular ultrasound imaging is bright, and will make a significant contribution to the understanding of atherosclerotic morphology and physiology as well as complement angiography during clinical diagnostic studies.

## References

1. Tobis JM, Mallery JA, Gessert J, Griffith J, Mahon D, Bessen M, McLeay L, Moriuchi M, McRae M, Henry WL. Intravascular Ultrasound cross-sectional arterial imaging before and after balloon angioplasty *in vitro*. *Circulation* 1989; 80: 873-82.
2. Tobis JA, Mallery JA, Lehmann K, Zalesky P, Griffith J, Gessert J, Moriuchi M, McRae M, Bessen M, Dwyer M-L, Greep N, Henry WL. Intravascular ultrasound imaging of human coronary arteries *in vivo*: analysis of tissue characterizations with comparison to *in vitro* histologic specimens. *Circulation* 1991; 83: 913-26.
3. Lyon RT, Zarins CK, Lu C-T, Yang C-F, Glagov S. Vessel, plaque, and lumen morphology after transluminal balloon angioplasty: Quantitative study in distended human arteries. *Arteriosclerosis* 1987; 7: 306-14.
4. Yock PG, Johnson EL, Linker DT. Intravascular ultrasound: Development and clinical potential. *Am J Card Imaging* 1988; 2: 185-93.
5. Nissen SE, Grines CL, Gurley JC, Sublett K, Haynie D, Diaz C, Booth DC, DeMaria AN. Application of a new phased-array ultrasound imaging catheter in the assess-

- ment of vascular dimensions. In vivo comparison to cineangiography. *Circulation* 1990; 81: 660–6.
6. Gussenhoven EJ, Essed CE, Lancée CT, Mastik F, Frietman P, Van Egmond FC, Reiber J, Bosch H, Van Urk H, Roelandt J, Bom N. Arterial wall characteristics determined by intravascular ultrasound imaging: an in vitro study. *J Am Coll Cardiol* 1989; 14: 947–52.
  7. Vlodaver Z, Frech R, Van Tassel RA, Edwards JE. Correlation of the antemortem coronary arteriogram and the postmortem specimen. *Circulation* 1973; 47: 162–9.
  8. Mallery JA, Tobis JM, Griffith J, Gessert J, McRae M, Moussabeck O, Bessen M, Moriuchi M, Henry WL. Assessment of normal and atherosclerotic arterial wall thickness with an intravascular ultrasound imaging catheter. *Am Heart J* 1990; 119 (6): 1392–1400.
  9. Potkin BN, Bartorelli AL, Gessert JM, Neville RF, Almagor Y, Roberts WC, Leon MB. Coronary artery imaging with intravascular high-frequency ultrasound. *Circulation* 1990; 81: 1575–85.
  0. Moriuchi M, Tobis JM, Gordon I, Bergman A, Griffith J, Henry WL. Functional significance of arterial stenoses predicted by angiography and intravascular ultrasound imaging catheter. *J Am Coll Cardiol* 1990; 15 (2) A: 106.
  11. Waller BF, Roberts WC. Amount of narrowing by the atherosclerotic plaque in 44 non-bypassed and 52 bypassed major epicardial coronary arteries in 32 necropsy patients who died within one month of aortocoronary bypass grafting. *Am J Cardiol* 1980; 46: 956–62.
  12. Little WC, Constantinescu M, Applegate RJ, Kutcher MA, Burrows MT, Kahl FR, Santamore WP. Can coronary angiography predict the site of a subsequent myocardial infarction in patients with mild-to-moderate coronary artery disease? *Circulation* 1988; 78: 1157–66.

*Address for offprints:*

J. Tobis,  
 Division of Cardiology,  
 UCI Medical Center,  
 P.O. Box 14091,  
 Orange, CA 9213-4091, USA