Title
Intravascular Ultrasound Imaging: A New Method for Guiding Interventional Vascular Procedures

Journal
Echocardiography, 7(4)

ISSN
0742-2822

Authors
TOBIS, JONATHAN M
MALLERY, JOHN A
MAHON, DONALD
et al.

Publication Date
1990-07-01

DOI
10.1111/j.1540-8175.1990.tb00382.x

Intravascular Ultrasound Imaging: A New Method for Guiding Interventional Vascular Procedures

JONATHAN M. TOBIS, M.D., JOHN A. MALLERY, M.D., DONALD MAHON, M.D., JAMES GRIFFITH, PH.D., JIM GESSERT, B.A., KENNETH LEHMANN, M.D., and WALTER L. HENRY, M.D.
Cardiology Division, University of California, Irvine; Cardiology Division, Veterans Administration Hospital, Long Beach; and InterTherapy, Inc., Costa Mesa, California

A wide variety of therapeutic procedures have been developed to intervene in patients with coronary artery disease. Whether the intervention is intended to increase lumen size by dilating the artery or to decrease atheroma mass by laser ablation, mechanical atherectomy, or by lowering serum cholesterol, it will be important to quantitate atherosclerotic plaque volume before and after treatment. Current diagnostic methods include angiography that provides an assessment of the narrowing of the lumen due to the atheroma and intravascular angioscopy which reveals information about the appearance and topography of the luminal surface.[1,2] Angioscopy identifies ulcerated plaques and thrombus, but does not provide quantitative information about the extent of atheroma involvement in the arterial wall.[3] Neither angiography nor angioscopy allows assessment of the size, location, and composition of the atheroma. Ultrasound is an imaging modality that potentially could provide this information.[4] Until now, ultrasound imaging of coronary arteries has been limited because of difficulty in visualizing the coronary tree with a transcutaneous approach. Coronary images have been obtained with conventional 12-MHz external ultrasound imaging devices in vitro or at the time of open heart surgery on exposed epicardial coronary arteries.[5-7] Such external ultrasound devices have obvious limitations for evaluating human coronary arteries in vivo. An intravascular ultrasound transducer placed on the end of a catheter has been used in vitro and in vivo animal studies to image coronary and peripheral arteries.[8-11] This approach allows the arterial wall to be imaged in cross section from inside the artery, opening the possibility of imaging human coronary arteries in the catheterization laboratory as a routine complement to diagnostic angiography as well as before, during, and after balloon angioplasty, laser, or atherectomy intervention.

Presented at the Tufts Intravascular Imaging Symposium, New Orleans, November 11, 1989.

Address for correspondence: Jonathan M. Tobis, M.D., F.A.C.C., Acting Chief, Division of Cardiology, Director, Catheterization Laboratory, University of California, Irvine, P.O. Box 14091, Route 81, Orange, CA 92613-4091.

General Description of the Catheter

The catheter consists of a single 20-MHz ultrasound transducer oriented so that the ultrasound beam is aimed parallel to the long axis of the catheter. The ultrasound beam is reflected from a metal mirror at 45° so that the beam exits the catheter perpendicular to the long axis of the catheter. This design permits imaging up to the surface of the catheter since the initial transducer oscillations occur in the space between the transducer and the mirror and not between the catheter and the wall of the artery. The diameter of the catheter is 1.2 mm with the expectation that future derivations may be able to provide catheters of even smaller diameter. In the preliminary studies, the catheter was hand rotated through 360° inside of an artery. During rotation, the B-mode ultrasound representation was painted as a circle on the video screen using position information provided by an angular po-

tentiometer attached to the proximal end of the catheter. The catheter has now been adapted to a motor drive which rotates 1,800 rpm to provide real-time cross-sectional images at 30 frame/sec.

For the in vitro studies, the catheter was mounted in a precision positioning device that was used during imaging to control the height, angle, and rotation of the catheter. Human artery segments were imaged in saline at 1-mm increments. Accurate location within the artery was obtained by placing a surgical needle through the wall of the artery, providing an acoustic reference point. The image appeared on a video monitor and was stored on a Sony Video Image Transcriber (Sony Medical Electronics, Park Ridge, NJ, USA) and archived onto a computer disk.

Ultrasound Imaging During Interventions: Balloon Angioplasty

The ultrasound imaging catheter was evaluated before and after balloon dilatation in human atherosclerotic artery segments in vitro.[12] Prior to balloon dilatation, 17 artery segments were imaged at 1-mm intervals along the length of the artery. After the initial imaging, the artery segment was dilated with an appropriately sized coronary or peripheral artery

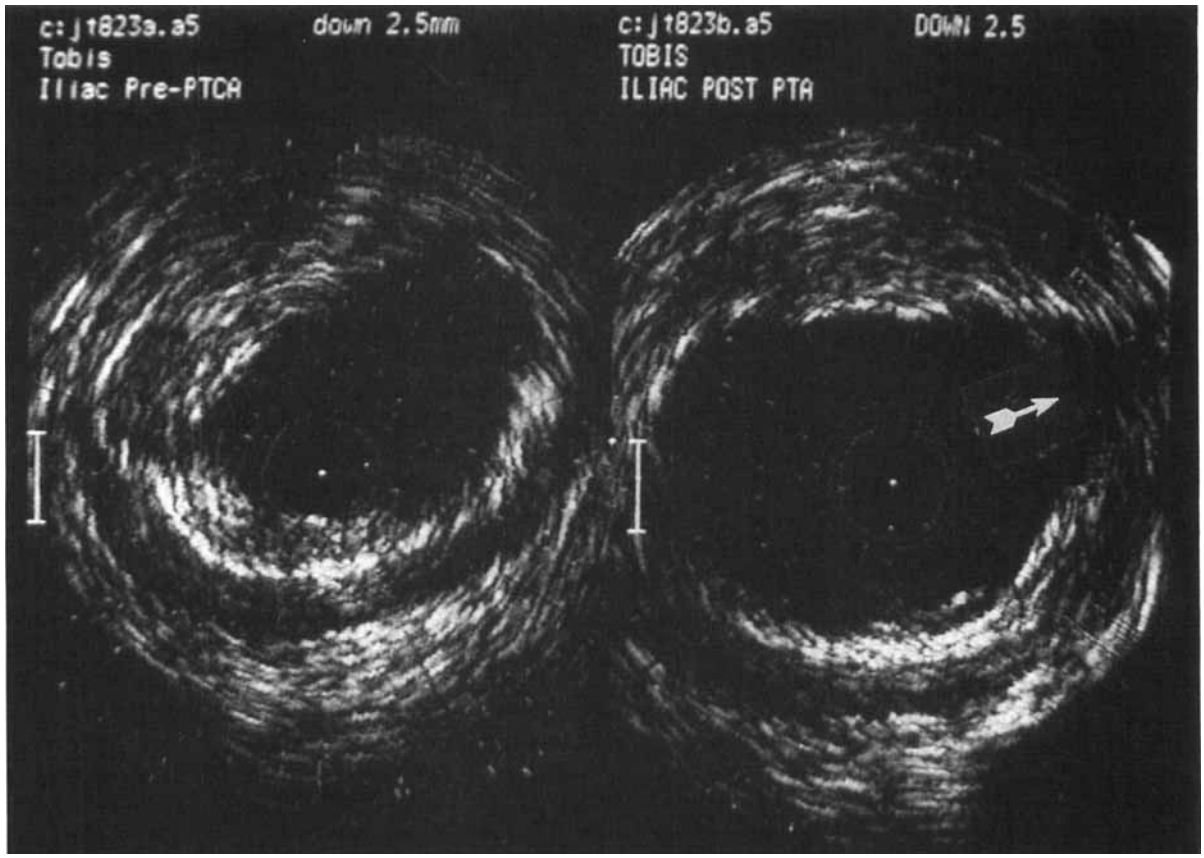

Figure 1. *This photograph from the computer monitor shows a pair of ultrasound images from an artery before dilation (on the left) and following dilatation (on the right). The image was obtained 2.5 mm below the reference line of the needle. This artery was only moderately diseased. The central black area is where the transducer is located. The echo-free lumen is clearly delineated from the fibrous atheroma plaque that has high echogenic reflectance. The muscular media has low echogenicity and the surrounding adventitia shows high echogenic reflectance. Following balloon dilatation, the artery cross-sectional area is increased and there is a minor tear in the plaque (Reproduced with permission from the American Heart Association, Circulation).*

balloon. The balloon diameter was chosen so that the inflated diameter of the balloon was 1.0 to 1.3 times the diameter of the artery. After dilatation, the artery sections were remounted on to the plastic base and replaced within the beaker of saline. Care was taken to align the artery in a similar orientation to the one used to obtain the initial images. A second set of ultrasound images were then acquired at 1-mm increments at the same levels as were imaged prior to dilatation using the surgical needle as an acoustic reference. After the imaging study of each artery was completed, the computer images were restored from the disk. Measurements were made of the cross-sectional area of the lumen pre- and postdilatation along the length of the artery and compared by paired Student's *t*-test. Histologic sections were prepared and quantitative measurements were made from photographs of the histologic sections. The histologic cross-sectional measurements were compared by linear regression analysis to the postdilatation ultrasound image measurements.

A representative ultrasound image pair, before and after balloon dilatation, is demonstrated in Figure 1 from an artery section that was only moderately diseased. In all 15 of the specimens in which adequate images were obtained, the echo-free lumen was clearly delineated. Of the 15 arteries, the fibrous plaque was seen as a region of high echogenic reflectance, as was the adventitia, while the muscular media was seen as a region of low echogenicity.

The ultrasound and histologic images were analyzed for evidence of plaque tears and dissection postdilatation. The criteria for making a

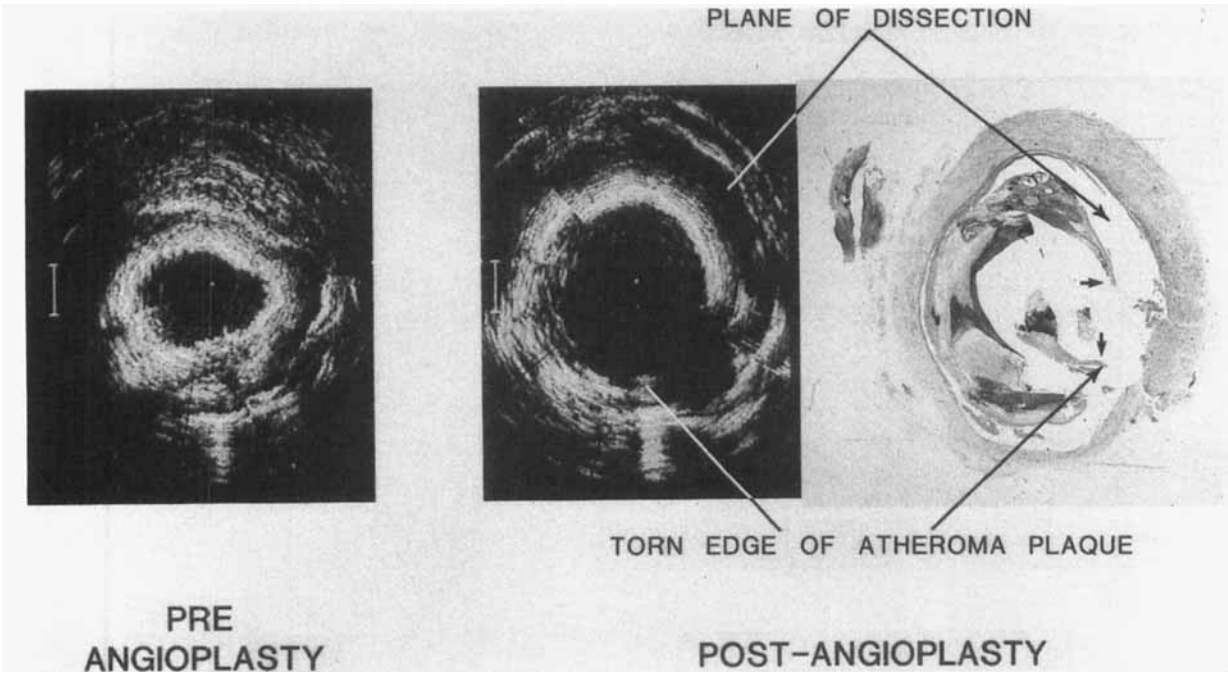

Figure 2. *The results of balloon angioplasty on a densely calcified and fibrotic human iliac artery are demonstrated above. The ultrasound image before angioplasty demonstrates dense fibrocalcific plaque with dropout of echocardiographic information distal to the atheroma. There is an artifact at the base of each ultrasound image corresponding to the acoustic reference needle placed on the outside wall of the artery. The postangioplasty ultrasound image demonstrates dilatation of the lumen with tearing of the edges of the plaque and separation of the torn edges. Additionally, there is a new echolucent area behind the dense fibrocalcific plaque at the top right hand corner. This plane of dissection was also observed on the histologic cross section to extend behind the atheromatous plaque. The area of the atheroma that was torn was the thinnest section of the plaque, approximately at 3 to 4 o'clock on the image (Reproduced with permission from the American Heart Association, Circulation).*

diagnosis of plaque tear was the observation of a fracture of the intimal plaque with separation of the torn ends as shown in the postdilatation image in Figure 2. There also appears to be a new lucency caused by separation of the intimal plaque from the media. The corresponding histologic cross section from the artery segment is also shown in Figure 2. A fracture of the intimal plaque with separation of the torn ends as well as separation of the plaque from the media are seen. In most arteries studied, balloon dilatation created a tear through the plaque that typically was located through the thinnest region of the atheroma or at the junction of the plaque and normal artery wall. The tear also produced a dissection plane between the plaque and the internal elastic membrane. The artery was stretched in this region which resulted in enlargement of the internal lumen. In several instances, the ultrasound images also visualized the presence of an intimal flap (Fig. 3). The ultrasound images accurately predicted the histologic presence or absence of tears in 11 of the 13 artery segments in which matched ultrasound and histologic sections were available. In order to determine the accuracy of the intravascular ultrasound measurement of lumen area, the lumen cross-sectional area obtained by ultrasound was compared with measurements obtained from the histology sections at multiple sites along the length of each artery segment. The correlation of cross-sectional area from the intravascular ultrasound catheter compared to histology was close for 39 paired, postdilatation sections (Fig. 4). The correlation coefficient was 0.88 and the standard error of the estimate was 3.2 mm^2. The measurements were related by the equation:

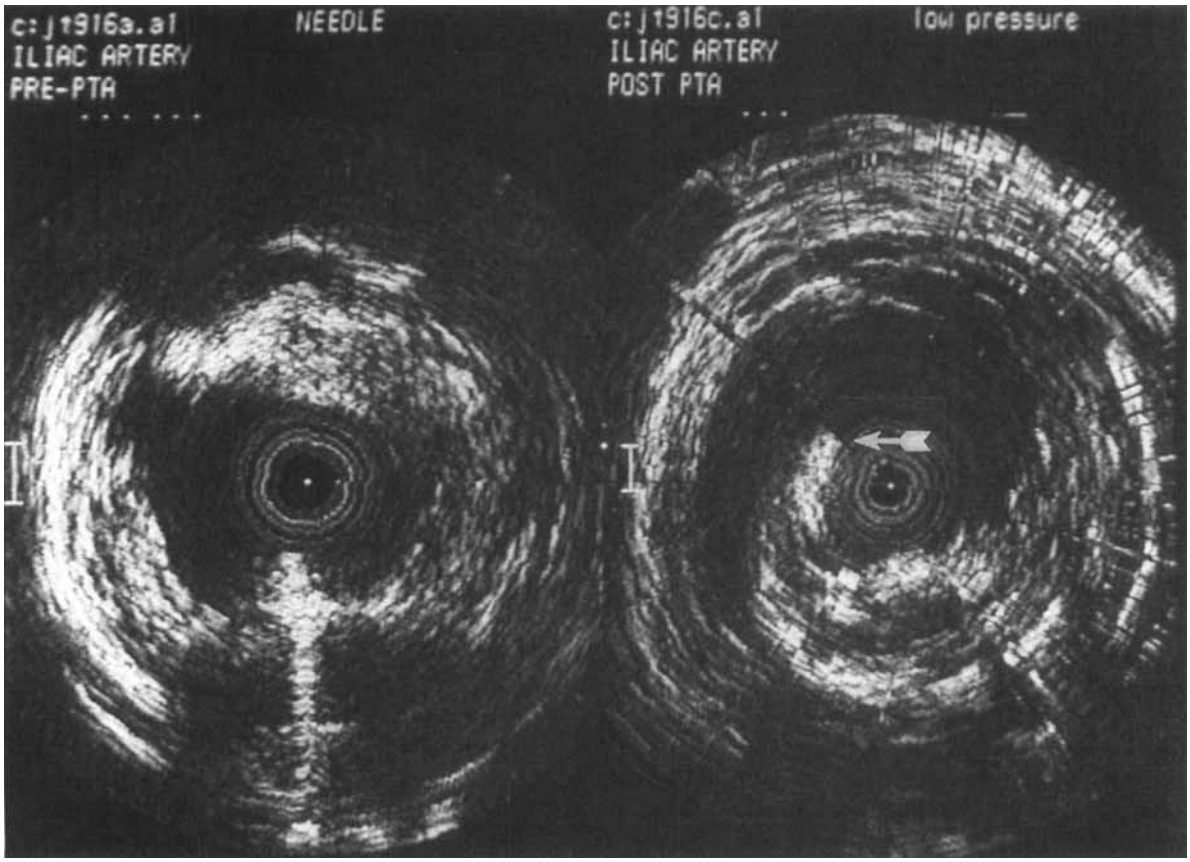

Figure 3. *In this composite photograph of ultrasound images from another artery before (A) and after (B) balloon dilation, not only was the arterial plaque torn, but an intimal flap is seen to protrude into the lumen (arrow) (Reproduced with permission from the American Heart Association, Circulation).*

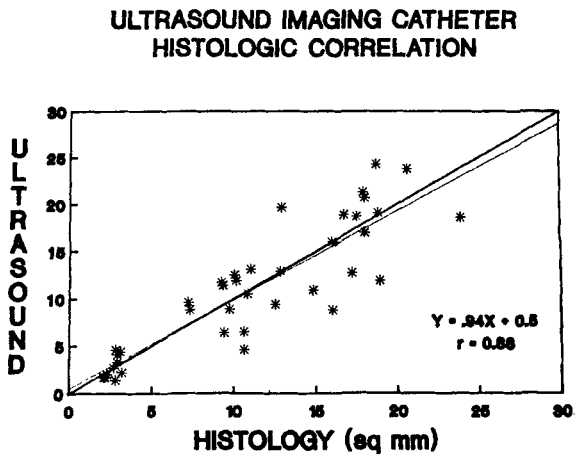

Figure 4. *In order to determine the accuracy of the measurements of lumen area, the ultrasound lumen cross-sectional area was compared with measurements obtained from the histologic sections at multiple sites along the length of each artery segment. The correlation coefficient was 0.88 for measurements of cross-sectional area obtained with the intravascular ultrasound catheter (y axis) as compared with the measurements from histology (x axis) (Reproduced with permission from the American Heart Association, Circulation).*

Lumen Area (ultrasound) = 0.94 × Lumen Area (histology) + 0.52 mm^2

Ultrasound cross-sectional areas were compared before and after balloon dilatation to assess the magnitude of the increase in lumen area produced by balloon dilatation. In each of the 15 artery segments in which adequate ultrasound images were obtained, the cross section that showed the greatest percent change in lumen area following dilatation was determined. The maximal luminal area increased on average from 8.7 to 15.1 mm^2 ($P < 0.01$) following dilatation.

There are several sources of error in trying to compare the area by ultrasound in vitro with histologic sections. The histologic preparation may produce artifactual compression and distortion, especially after balloon angioplasty when the integrity of the arterial wall may be compromised. Additionally, fixation in formalin may produce shrinkage of the tissue. Our ultrasound images that were performed before and after formalin fixation demonstrated a 4% difference between the two measurements, which may account for some of the variation in area between the ultrasound and histologic sections. For these reasons, it is possible to speculate that ultrasound calculations in vivo may be a more accurate determination of the true size of anatomical structures than are measurements derived after histologic preparation. The results

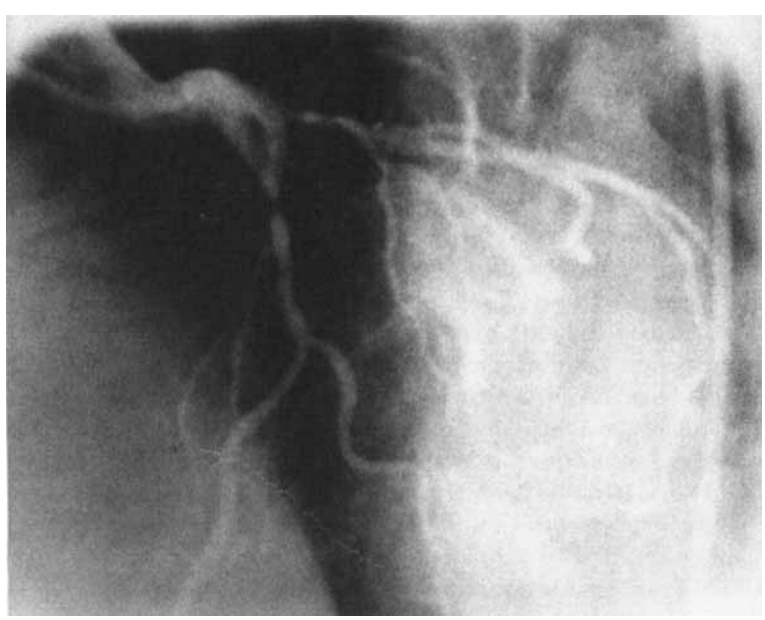

Figure 5A. *Stenosis of the proximal left anterior descending coronary artery prior to balloon dilatation.*

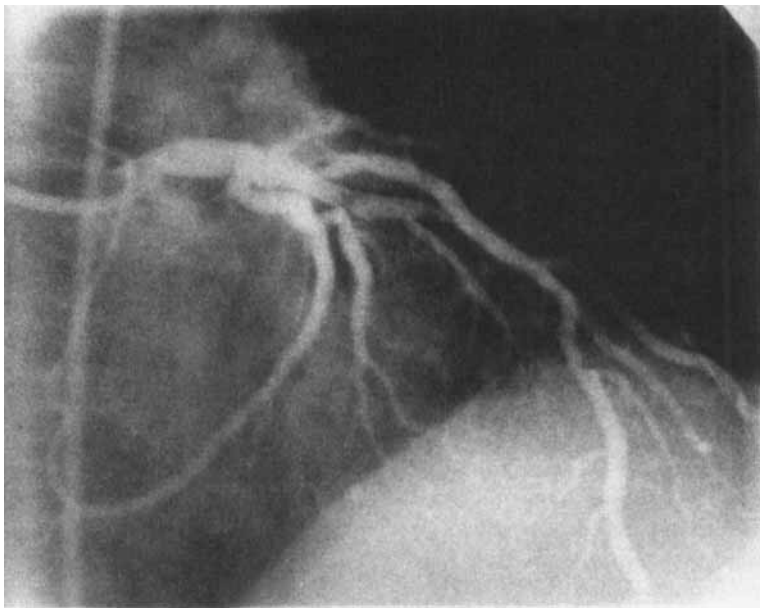

Figure 5B. *RAO cranial projection post percutaneous coronary angioplasty demonstrates a residual angiographic lucency at the level of the previous dilatation despite complete inflation with a 4.0-mm balloon.*

from these studies are encouraging and suggest that ultrasound energy can be configured with a small catheter to intravascularly interrogate and quantitate human atherosclerosis before and after an intervention such as balloon angioplasty.

Clinical Trials

Several clinical trials are currently in progress which use the motor driven ultrasound imaging catheter. These studies include patients with peripheral artery disease at the time of balloon angioplasty or atherectomy; imaging of coronary arteries during open heart bypass surgery; and intracoronary imaging during coronary angioplasty. In order to protect the arteries during mechanical rotation, an introducing sheath is placed across the area of interest with a standard angioplasty guidewire. The ultrasound subassembly is then inserted separately through the introducing sheath. The diameter of the plastic sheath is 1.6 mm that is advanced through a 9 Fr guiding catheter. After the plastic sheath is passed over the guidewire and across the stenosis, the guidewire is removed and the ultrasound imaging subassembly is placed into the back end of the sheath through a hemostatic O ring. The ultrasound imaging subassembly is advanced under fluoroscopic control through the plastic sheath to the distal end. Images are obtained at multiple levels of the artery as the ultrasound subassembly is moved back and forth along the plastic sheath which remains stationary across the stenosis.

The preliminary results from these clinical studies indicate that the ultrasound imaging catheter yields high quality images of the arterial wall and lumen that provide information about the eccentricity of the plaque and tissue characterization, such as the presence of fibrosis, calcification, or thrombus. Additionally, an interesting physiological observation has been made, that the arteries contract only in the portion of the wall that is free of atheroma. The section of the artery that is subtended by thick atheroma, or if calcium is present, does not expand with each heartbeat, whereas the normal section dilates appropriately during the cardiac cycle. The potential benefit of this device is

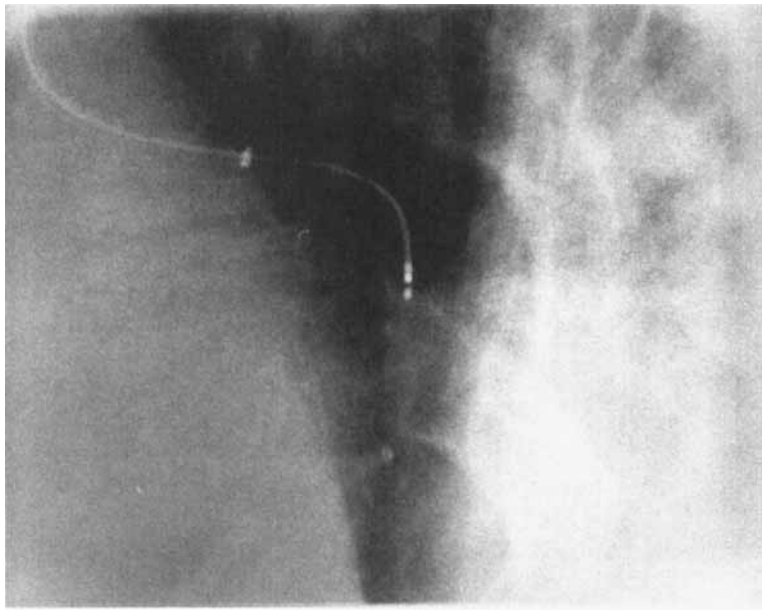

Figure 5C. *The ultrasound imaging subassembly is inserted through a 9 Fr catheter into a protective sheath in the left anterior coronary angioplasty.*

demonstrated in the following percutaneous coronary angioplasty case example. The patient had an eccentric obstruction of the mid-left anterior descending coronary artery that was dilated with a 4.0-mm balloon (Fig. 5A). Following dilatation, there appeared to be a hazy density on angiography (Fig. 5B). As the artery was observed on sequential angiography, it appeared that the lumen continued to diminish. Multiple repeat dilatations were performed at increasing pressures for longer duration. The ultrasound imaging catheter was inserted (Fig. 5C) and revealed dense calcification at the area of the previous dilatation with localized dissection. Additionally, the lumen area was sharply delineated along the length of the artery until the site of the dilatation, at which time the lumen became filled with a mildly echo-reflective density (Fig. 6A). This density existed for approximately 0.5 cm and almost occluded the residual lumen. From prior tissue characterization studies in vitro we believe that this echogenic source within the lumen of the artery corresponds to intraluminal atheroma or thrombus that was either pre-existent or was formed at the time of balloon angioplasty. The observations of this intravascular interrogation were used in the decision to repeat the balloon dilatation instead of terminating the procedure.

Beyond the level where the angioplasty was performed, there was also a moderate stenosis with eccentric plaque and calcification that was not appreciated on angiography (Fig. 6B).

Summary

A method to assess the degree to which an atheroma plaque has been disrupted by percutaneous interventional methods could be of considerable benefit. An intravascular ultrasound catheter could provide quantitative information about the distribution and quality of the atheroma prior to and following a balloon dilatation, laser, or atherectomy procedure. Additionally, the ultrasound transducer could be configured within an angioplasty balloon to visualize the arterial wall in cross section during the dilatation. Visualization of the atheroma and arterial wall also might be of benefit to help characterize the type of tissue within the plaque, which may potentially help suggest which of several alternative therapies may be most effective. The in-

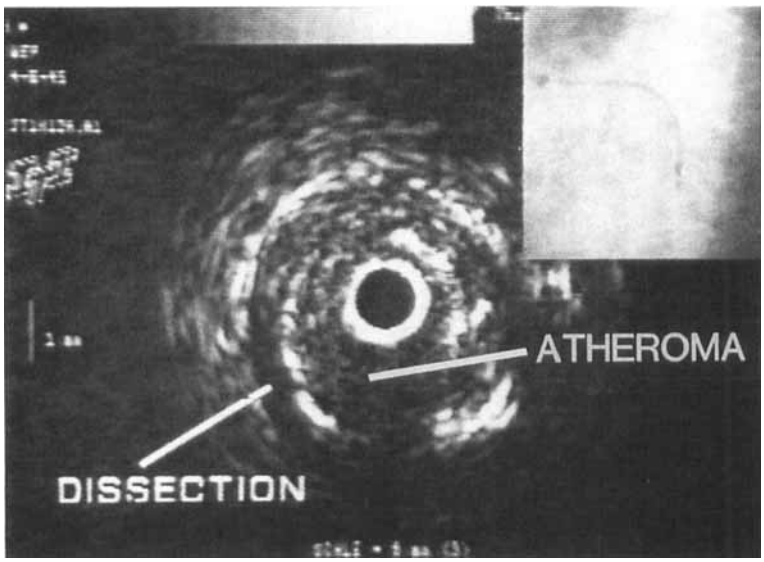

Figure 6A. *The intravascular ultrasound image: There is a dissection and separation between the internal elastic membrane and the media. Additionally, the area of the lumen just below the central catheter circle is not completely echolucent, but is filled with echogenic material that represents a large residual atheroma or thrombus (Reproduced with permission from the American Heart Association, Circulation).*

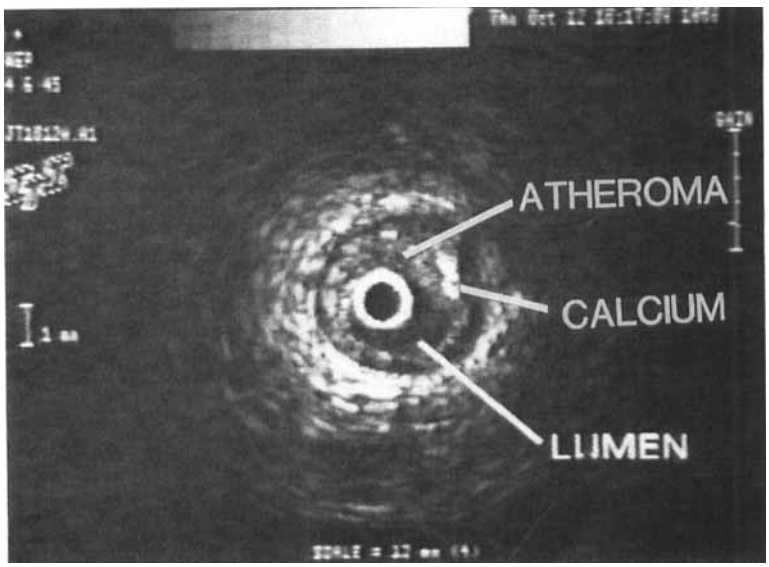

Figure 6B. *The mid-left anterior coronary artery (which was not dilated) has a residual lumen 2.0 × 1.5 mm in dimension with a large amount of atheroma and calcification with shadowing (at 3 o'clock), neither of which was appreciated by angiography (Reproduced with permission from the American Heart Association, Circulation).*

Figure 7. *This human iliac artery shows destruction of the atherosclerotic plaque at 5 o'clock due to photoablation with a bare fiber Argon laser. This in vitro feasibility study was performed under visual guidance, but it demonstrates how the ultrasound imaging catheter can identify the area of the arterial wall that is involved with the atheroma so that the laser is pointed toward the atheroma mass and away from the section of the artery wall that has a thin intima.*

travascular imaging catheter would provide a feasible method of identifying normal and diseased arterial wall structures during diagnostic and interventional angiographic procedures. This distinction is critical during laser therapy of eccentric plaques to prevent exposure of the uninvolved wall (Fig. 7). These high quality ultrasound images may allow quantitative assessment of the extent of atheromatous involvement of artery walls as well as the character of the atheroma tissue. Such an approach, performed percutaneously in the catheterization lab, could represent a fundamental departure from traditional angiographic methods for assessing the severity of coronary, carotid, or peripheral arterial disease.

References

1. Vlodaver Z, Frech R, Van Tassel RA, et al: Correlation of the antemortem coronary arteriogram and the postmortem specimen. Circulation 47:162, 1973.
2. Eusterman JH, Achor RWP, Kincaid OW, et al: Atherosclerotic disease of the coronary arteries: A pathologic-radiologic correlative study. Circulation 26:1288, 1962.
3. Forrester JS, Litvak F, Grundfest W, et al: A perspective of coronary artery disease seen through the arteries of living man. Circulation 75:505, 1987.
4. Yao JS, Flinn WR, Bergan JJ: Noninvasive vascular diagnostic testing: Techniques and clinical applications. Prog Cardiovasc Dis 26:459, 1984.
5. Hiratzka LF, McPherson DD, Lamberth WC, et al: Intraoperative evaluation of coronary artery bypass graft anastomoses with high-frequency epicardial echocardiography: Experimental validation and initial patient studies. Circulation 73:1199, 1986.
6. Sahn DJ, Barratt-Boyes BG, Graham K, et al: Ultrasound imaging of the coronary arteries in open-chested humans: Evaluation of coronary atherosclerotic lesions during cardiac surgery. Circulation 66:1033, 1982.
7. McPherson DD, Hiratzka LF, Lamberth WC, et

al: Delineation of the extent of coronary atherosclerosis by high-frequency epicardial echocardiography. N Engl J Med 316:304, 1987.
8. Pandian NG, Kreis A, Brockway B, et al: Ultrasound angioscopy: Real-time, two dimensional, intraluminal ultrasound imaging of blood vessels. Am J Cardiol 62:493, 1988.
9. Yock PG, Johnson EL, Linker DT: Intravascular ultrasound: Development and clinical potential. Am J Cardiac Imaging 2:185, 1988.
10. Roelandt JR, Bom N, Serruys PW, et al: Intravascular high-resolution realtime cross-sectional echocardiography. Echocardiography 6:9, 1989.
11. Mallery J, Griffith J, Gessert J, et al: Intravascular ultrasound imaging catheter assessment of normal and atherosclerotic arterial wall thickness. (Abstract) J Am Coll Cardiol 11:22A, 1988.
12. Tobis JM, Mallery J, Gessert J, et al: Intravascular ultrasound cross-sectional arterial imaging before and after balloon angioplasty in vitro. Circulation 80:873, 1989.