

# UC Davis

## UC Davis Previously Published Works

### Title

Efficacy, Cost, and Complications of Demineralized Bone Matrix in Instrumented Lumbar Fusion: Comparison With rhBMP-2

### Permalink

<https://escholarship.org/uc/item/47g4s51n>

### Journal

Global Spine Journal, 11(8)

### ISSN

2192-5682

### Authors

Eleswarapu, Ananth  
Rowan, F Andrew  
Le, Hai  
[et al.](#)

### Publication Date

2021-10-01

### DOI

10.1177/2192568220942501

Peer reviewed

# Efficacy, Cost, and Complications of Demineralized Bone Matrix in Instrumented Lumbar Fusion: Comparison With rhBMP-2

Global Spine Journal  
2021, Vol. 11(8) 1223–1229  
© The Author(s) 2020  
Article reuse guidelines:  
sagepub.com/journals-permissions  
DOI: 10.1177/2192568220942501  
journals.sagepub.com/home/gsj



Ananth Eleswarapu, MD<sup>1</sup>, F. Andrew Rowan, MD<sup>1</sup>, Hai Le, MD<sup>1</sup> ,  
Joseph B. Wick, MD<sup>1</sup> , Rolando F. Roberto, MD<sup>1</sup>,  
Yashar Javidan, MD<sup>1</sup>, and Eric O. Klineberg, MD, MS<sup>1</sup>

## Abstract

**Study Design:** Retrospective cohort study.

**Objectives:** To evaluate demineralized bone matrix as an adjunct for instrumented lumbar spine fusion compared with recombinant human bone morphogenetic protein–2 (rhBMP-2).

**Methods:** Clinical and radiographic review was performed of 43 patients with degenerative spine disease treated with posterolateral spinal fusion with or without posterior or transforaminal lumbar interbody fusion. Final analysis included sixteen patients treated with demineralized bone matrix (DBM; Accell Evo3, SeaSpine) compared with a retrospective matched group of 21 patients treated with rhBMP-2 (rhBMP-2, Infuse, Medtronic). All patients were followed for 24 months. Fusion was evaluated by computed tomography and/or x-ray. Clinical outcomes included visual analogue scale (VAS), Oswestry Disability Index (ODI), and Short Form 12 (SF-12).

**Results:** Overall fusion rate, including posterolateral and/or interbody fusion, was 100% for both groups, though the fusion rates in the posterolateral space alone were 93.5% and 100% for the DBM and rhBMP-2 groups, respectively. Clinical outcomes were similar between groups, with the DBM group showing greater improvement in ODI. The rhBMP-2 group showed higher rates of radiographic complications with 7 of 21 patients (33.3%) demonstrating either adjacent level fusion or ectopic bone formation, compared with zero in the DBM group. Average biologic cost per level was \$1522 for DBM and \$3505 for rhBMP-2.

**Conclusions:** DBM and rhBMP-2 demonstrated similar radiographic and clinical outcomes in instrumented lumbar fusions. rhBMP-2 was associated with higher rates of radiographic complications and significantly higher costs.

## Keywords

lumbar fusion, biologics, bone morphogenetic protein, complications, pseudarthrosis, demineralized bone matrix, interbody fusion, posterolateral lumbar fusion

## Introduction

Instrumented lumbar spinal fusion is a common procedure for treating patients with a variety of lumbar spinal pathologies. A successful outcome depends, in large part, on the establishment of a solid bony union. This is usually achieved in the posterolateral space by placing bone graft or bone graft substitute on either side of the vertebral column to form a continuous bridge of new bone spanning between the transverse processes from one level to the next. Historically, autologous iliac crest bone graft (ICBG) was used to increase fusion rates. While ICBG is the gold standard, drawbacks associated with its use

include donor site pain and morbidity, limited quantity, variable quality, and potentially increased operating time and blood loss.<sup>1,2</sup> As a result, the use of biologic agents has become more common.<sup>3</sup>

<sup>1</sup> University of California Davis, Sacramento, CA, USA

### Corresponding Author:

Eric O. Klineberg, Department of Orthopaedic Surgery, University of California, Davis, 4860 Y Street, Suite 3800, Sacramento, CA 95817, USA.  
Email: eoklineberg@ucdavis.edu



Creative Commons Non Commercial No Derivs CC BY-NC-ND: This article is distributed under the terms of the Creative Commons Attribution-Non Commercial-NoDerivs 4.0 License (<https://creativecommons.org/licenses/by-nc-nd/4.0/>) which permits non-commercial use, reproduction and distribution of the work as published without adaptation or alteration, without further permission provided the original work is attributed as specified on the SAGE and Open Access pages (<https://us.sagepub.com/en-us/nam/open-access-at-sage>).

There are a wide variety of choices to augment local bone to achieve a solid fusion. With increasing focus on cost-effectiveness, there is a need for data comparing clinical outcomes and costs between commercially available options. A large body of clinical data has demonstrated high fusion rates with the use of recombinant human bone morphogenetic protein-2 (rhBMP-2, Infuse, Medtronic) as an adjunct to posterolateral lumbar fusion.<sup>4,5</sup> However, there can be dosing and containment challenges, and the use of rhBMP-2 has been associated with complications including ectopic bone growth, osteolysis, and soft tissue swelling leading to dysphagia and/or radicular symptoms.<sup>3,6</sup> Furthermore, there are concerns related to rhBMP-2's relatively high cost. Consequently, many surgeons have sought alternative products that may offer a lower risk of complications and price without compromising fusion rates.

Demineralized bone matrix substitutes may represent a viable alternative to rhBMP-2 for augmenting bony fusion. For example, Accell Evo3 (SeaSpine) is a bone graft substitute featuring an open-structured, dispersed form of demineralized bone matrix (DBM) tissue that greatly increases the surface area, in turn allowing for greater osteoinductive properties. DBM is produced by removing cellular and mineral components from human corticocancellous cadaver bone, leaving the extracellular matrix molecules, including bone morphogenic proteins, which are osteoinductive. The present study compares the fusion rates among patients undergoing lumbar spinal fusion with either rhBMP-2 or Accell Evo3 DBM as an adjunct to local bone autograft in the posterolateral space. We hypothesized that DBM would not demonstrate a significant difference in radiographic fusion rates compared with rhBMP-2.

## Methods

### Patient Enrollment and Surgical Technique

This single center, retrospective review of nonrandomized, prospectively collected data was conducted in accordance with STROBE (Strengthening The Reporting of OBServational Studies in Epidemiology) guidelines after institutional review board approval was obtained. Patients undergoing posterolateral lumbar fusion with DBM were prospectively enrolled and compared with an age- and sex-matched retrospectively identified cohort of patients who had undergone posterolateral lumbar fusion with the use of rhBMP-2. The concentration of rhBMP-2 used in this study was 1.5 mg rhBMP-2/mL bone graft. Patients in the prospectively enrolled DBM cohort were enrolled consecutively and provided written consent for participation. Inclusion criteria for both the DBM and rhBMP-2 groups included posterolateral fusion performed alone or in combination with posterior interbody fusion of 1 to 3 levels between L3 and S1, age greater than 18 years, and minimum 24 months clinical and radiographic follow-up. Patients were excluded if they were using medications known to inhibit fusion formation, were immunosuppressed, had prior radiotherapy treatment, had bone metabolic disease including

**Table 1.** Lenke Classification<sup>a</sup> of Posterolateral Fusion.

Grade	Definition
A	Definitely solid fusion with bilateral robust bridging bone
B	Probably solid fusion with unilateral robust bridging bone and contralateral thin fusion mass
C	Probably not solid fusion with a thin unilateral fusion mass and a probable pseudarthrosis on the contralateral side
D	Definitely not solid fusion with thin fusion masses bilaterally with obvious pseudarthrosis or bone graft dissolution bilaterally

<sup>a</sup>Lenke classification as originally described in *J Spinal Disord*, 1992;5:433-442.

osteoporosis, were pregnant, or were incarcerated. Baseline patient characteristics and surgical variables were obtained from the electronic medical record and compared between groups. The baseline characteristics included risk factors for pseudarthrosis and worsened clinical outcomes, such as smoking status,<sup>7</sup> age,<sup>8</sup> and obesity.<sup>9</sup>

Patients in both cohorts underwent surgery by 1 of 3 orthopedic spine surgeons. All patients underwent fusion with pedicle screw instrumentation, decortication of dorsal bony elements, and placement of local autograft bone, allograft cancellous chips, and biologic augmentation with either DBM or rhBMP-2 in the posterolateral space. Interbody fusion was added at the discretion of the surgeon and was performed via either transforaminal (TLIF) or posterior lumbar interbody fusion (PLIF). Interbody graft material was either a cage or structural allograft, followed by local autograft bone. No DBM or rhBMP-2 was used in the interbody space.

### Outcomes and Data Analysis

The primary outcome measure was radiographic fusion as assessed by computed tomography (CT) and plain radiographs. CT was performed for all patients at the 12-month postoperative time point, and final radiographic assessment was made at the 24-month postoperative time point for all patients. The Lenke scale (Table 1) was used for radiographic grading of posterolateral fusion.<sup>10</sup> CT scans were assessed using a modified Glassman CT grading scale (Table 2), which evaluates both posterolateral fusion and the interbody space.<sup>11</sup> Two blinded spine surgeons graded each of the radiographs and CT scans to determine final fusion status. Levels with scores A and B for posterolateral fusion or grades I or II for interbody fusion were considered "fused," whereas scores C and D for posterolateral fusion or grades III and IV for interbody fusion were considered "not fused." X-rays that were not interpretable were labeled "unable to assess," and these data points were excluded from the evaluation. Combined fusion rates utilizing CT and x-ray data were also calculated. Specifically, when combining fusion rates, patients were considered "fused" if they had demonstration of fusion on 12-month CT scan, 24-month x-ray, or both.

Secondary outcomes, including the visual analogue scale (VAS), Oswestry Disability Index (ODI), and Short Form 12

**Table 2.** Modified Glassman Scale for Grading of Lumbar Fusion on CT Imaging.

Posterolateral left-side grade		Posterolateral right -side grade	
A	Definitely fused	A	Definitely fused
B	Probably fused	B	Probably fused
C	Probably not fused	C	Probably not fused
D	Definitely not fused	D	Definitely not fused
N/A	Unable to assess	N/A	Unable to assess

Interbody fusion grading and definitions

I: Complete fusion	Cortical union of the allograft and central trabecular continuity
II: Partial fusion	Cortical union of the structural allograft with partial trabecular incorporation
III: Unipolar pseudarthrosis	Superior or inferior cortical non-union of the central allograft with partial trabecular discontinuity centrally
IV: Bipolar pseudarthrosis	Both superior and inferior cortical non-union with a complete lack of central trabecular continuity
N/A	Unable to assess

Glassman scale as described in: *Spine (Phila Pa 1976)*, 2005. **30**(15): p. 1694-8.

(SF-12) were obtained preoperatively and at 6, 12, and 24 months postoperatively. Costs of biologics used were calculated by multiplying the volume used by the charge rate per unit volume at our institution.

Statistical significance was established by Fisher's exact and chi-square test for categorical data and Student's *t* test for continuous data. Microsoft Excel (Microsoft Corp) was used for all statistical calculations with level of significance defined as  $P = .05$ .

## Results

### Patients and Clinical Characteristics

Twenty patients were enrolled and 16 were included in the final analysis in the prospective DBM group, which included a total of 23 treated levels. The retrospective rhBMP-2 group had 23 patients enrolled and 21 included in the final analysis, with a total of 37 treated levels. Baseline clinical and demographic factors were similar between the two groups (Table 3). There was no significant difference between the number of levels fused in in the DBM and rhBMP-2 groups, with mean number of levels fused per patient being 1.43 and 1.57, respectively. A greater proportion of patients in the DBM group underwent single level procedures (63% vs 48%), but this difference was not significant. Similarly, there was no significant difference between groups in the number of patients undergoing revision surgery. However, significantly more patients in the rhBMP-2 group underwent PLIF, whereas a significantly greater

**Table 3.** Baseline Patient Demographics and Surgical Variables.

Covariate	DBM	rhBMP-2	<i>P</i>
No. of levels fused, mean (SD)	1.43 (0.63)	1.57 (0.60)	.51
No. of patients undergoing single level procedures, n (%)	10 (63)	10 (48)	.37
No. of patients undergoing PLIF, n (%)	0 (0)	5 (24)	.04
No. of patients undergoing TLIF, n (%)	6 (38)	2 (9.5)	.04
Age in years (mean)	60	60	.99
% Female	56%	38%	.29
Body mass index (mean)	30	30	.75
Percent of patients with body mass index >30 kg/m <sup>2</sup>	38	29	.58
Current smoker, %	50	57	.68
Prior spine surgery, %	40	35	.33

Abbreviations: DBM, demineralized bone matrix; rhBMP-2, recombinant human bone morphogenic protein-2; PLIF, posterior lumbar interbody fusion; TLIF, transforaminal lumbar interbody fusion.

**Table 4.** Comparison of Bone Allograft Usage Volume and Costs.

Parameter	DBM	rhBMP-2 <sup>a</sup>	<i>P</i>
Bone graft volume per level, mL, mean (SD)	8.55 (4.12)	5.35 (2.48)	
Biologic cost per level, \$	1522	3505	<.001
Mean total cost of biologic per patient, \$	1899	4757	<.001

Abbreviations: DBM, demineralized bone matrix; rhBMP-2, recombinant human bone morphogenic protein-2.

<sup>a</sup>The concentration of rhBMP-2 used was 1.5 mg/mL.

proportion of patients in the DBM group underwent TLIF. The most common diagnoses in both groups were degenerative spondylolisthesis and lumbar spinal stenosis. The incidence of risk factors for pseudarthrosis and diminished clinical outcomes, including age, body mass index, and smoking status, were similar between both the DBM and rhBMP-2 groups. While the volume of biologics used was higher in the DBM group, both the total cost and cost of biologics per level were higher in the rhBMP-2 group (Table 4). The mean volume of bone allograft utilized per level fused in the DBM group was 8.55 mL versus 5.35 mL of allograft per level fused in the rhBMP-2 group. At a concentration of 1.5 mg rhBMP-2/mL bone graft, this represents a mean of 8.03 mg of rhBMP-2 utilized per level fused.

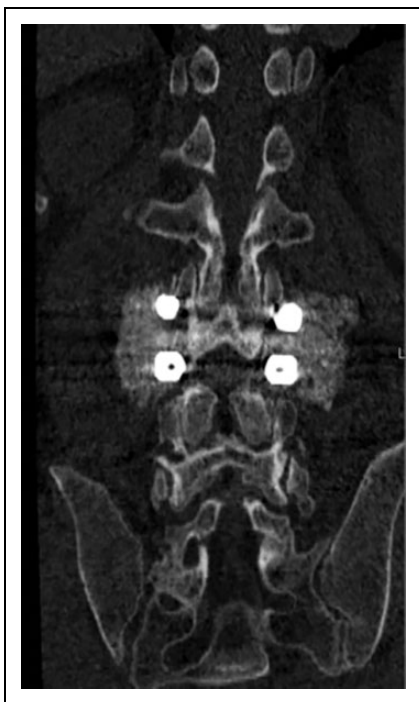
### Fusion Rates

Table 5 shows that posterolateral fusion rates were significantly higher in the rhBMP-2 group as assessed by both CT and x-ray at final assessment by each imaging modality (12 months for CT and 24 months for x-ray), and approached statistical significance ( $P = .054$ ) when results from imaging modalities were combined to minimize the impact of false negatives from each imaging modality. No significant difference was found in the rate of interbody fusion between the

**Table 5.** Comparison of Fusion Rates.

Fusion parameter	DBM, %	rhBMP-2, %	P
CT posterolateral fusion at 12 months	87	98.5	.02
X-ray posterolateral fusion at 24 months	77	100	<.001
Posterolateral fusion on either CT or x-ray	93.5	100	.054
Interbody fusion	69	92	.32
Successful posterolateral and/or interbody fusion	100	100	—

Abbreviations: DBM, demineralized bone matrix; rhBMP-2, recombinant human bone morphogenic protein 2; CT, computed tomography.

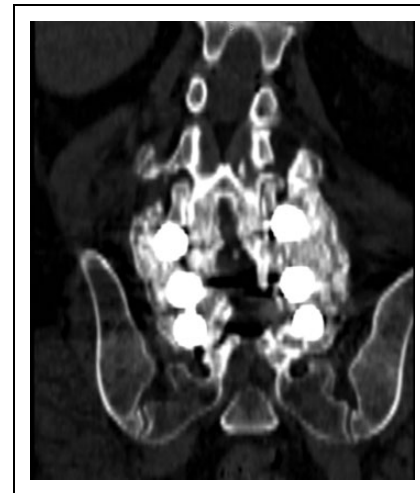

**Figure 1.** Coronal plane computed tomography (CT) image at the 12 months postoperative time point showing solid bilateral fusion from L3-L4 in a patient treated with demineralized bone matrix.

groups. Occurrence of fusion in either the posterolateral or interbody space was 100% for both groups. Figure 1 is a 12-month postoperative coronal CT image of a patient treated with DBM demonstrating solid posterolateral fusion.

### Complications and Clinical Outcomes

No significant difference was found between the groups in the rate of postoperative radiculopathy (DBM 56% vs rhBMP-2 29%;  $P = .11$ ), dural tear (19% vs 19%) or hematoma/seroma (6% vs 5%,  $P = 1.0$ ). The rate of adjacent level fusion due to ectopic bone formation was 33% in the rhBMP-2 group, with no such events occurring in the DBM group ( $P = .01$ ). Figure 2 is a 12-month postoperative coronal CT image of a patient



**Figure 2.** Coronal plane computed tomography (CT) image at the 12 months postoperative time point showing solid fusion from L4-S1 and ectopic bone extending to L3 in a patient treated with recombinant human bone morphogenic protein-2 (rhBMP-2).

treated with rhBMP-2 demonstrating ectopic bone formation extending cranially to L3, resulting in adjacent level fusion. Improvements in patient-reported clinical outcomes between the preoperative and 24-month postoperative visits were similar between the groups, with the exception of ODI, which favored the DBM group (Table 6, Figures 3-5).

### Discussion

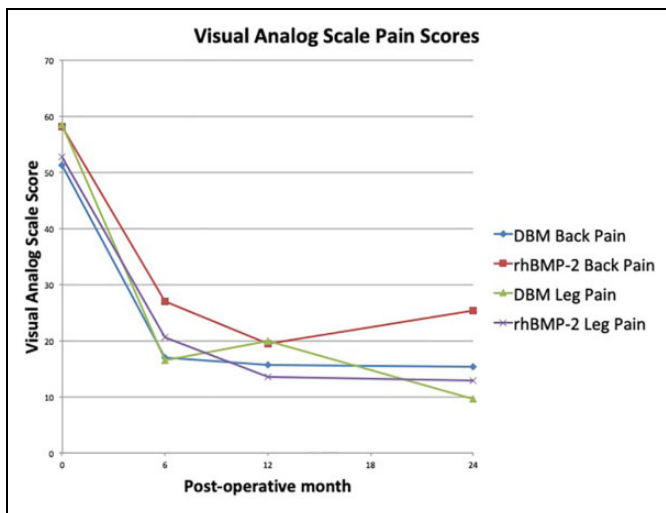
Autograft bone taken from local decompression is commonly used for posterolateral fusion, although the use of local bone is limited by the volume of graft available and risk of nonunion, particularly for multilevel or revision fusions.<sup>1</sup> ICBG is the historical gold standard and is both osteoinductive and osteoconductive. However, concerns over donor site morbidity and pain have prompted a search for other osteogenic adjuncts that can extend graft volume and promote fusion.<sup>3</sup> rhBMP-2 has shown powerful osteogenic potential in both animal and human models, with fusion rates equal to or superior to those achieved with ICBG.<sup>4-6</sup> While rhBMP-2 is not approved by the Food and Drug Administration for primary posterolateral lumbar fusion, off-label use for this purpose is common.<sup>3</sup> A significant criticism of rhBMP-2 is its substantial cost, representing around 5% to 10% of the total cost of lumbar fusion in prior studies.<sup>2,13</sup> High costs of rhBMP-2 are compounded by lack of consensus on the optimal dose of rhBMP-2 per level of fusion performed; previously recommended and reported values have ranged from 4.2 to 40 mg per level fused.<sup>12</sup> rhBMP-2 is also associated with significant complications, including seroma formation, radiculopathy, adjacent level fusion, and malignancy.<sup>3,6,14,15</sup>

Given the costs and complications associated with rhBMP-2, we conducted this study to compare the efficacy of a DBM compound to rhBMP-2 in the promotion of posterolateral lumbar fusion using matched-cohort analysis. Our results demonstrated a significantly higher rate of posterolateral fusion in the rhBMP-2 group; however, rhBMP-2 was also associated

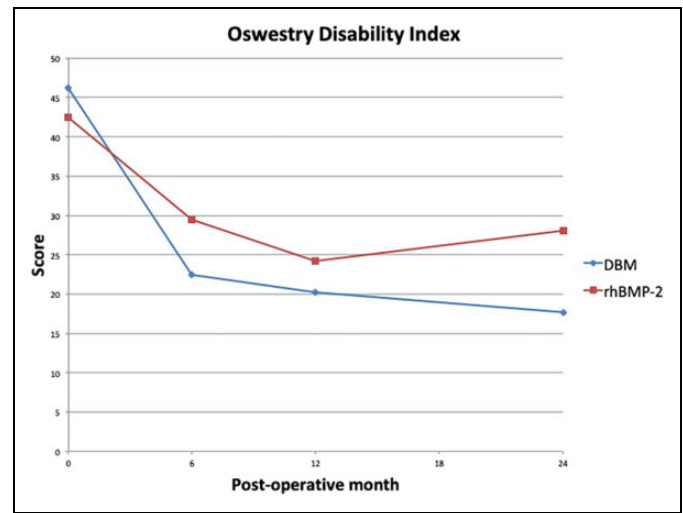
**Table 6.** Twenty-Four-Month Improvement in Patient-Reported Outcomes Compared With Baseline.

Outcome, mean (SD)	DBM			rhBMP-2			% change P
	Baseline	24-month	% change	Baseline	24-month	% change	
VAS leg pain	58.6 (23.1)	9.6 (17.2)	84	52.7 (29.2)	12.9 (18.8)	76	.41
VAS back pain	51.3 (27.9)	15.3 (13.6)	70	58.2 (28.6)	25.4 (29.0)	56	.18
ODI	46.2 (16.5)	17.7 (13.2)	62	42.5 (14.0)	28.1 (21.7)	34	.002
SF-12 PCS	31.8 (7.6)	46.3 (7.2)	37	31.2 (6.9)	43.0 (11.5)	27	.32
SF-12 MCS	48.3 (12.8)	54.1 (7.7)	7	49.4 (11.5)	53.4 (13.6)	11	.85

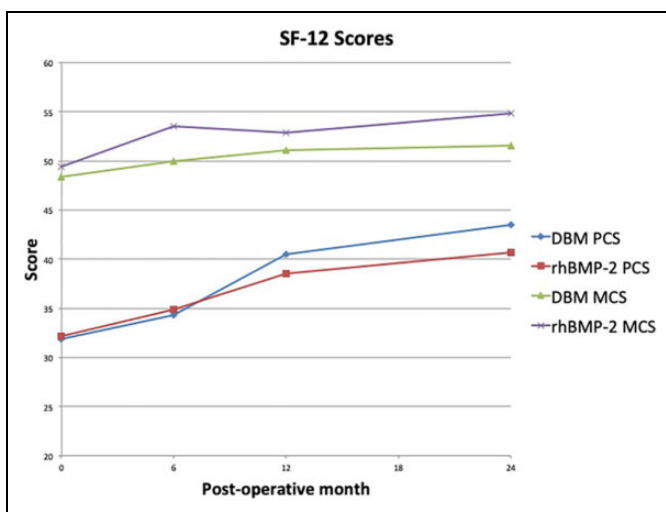
Abbreviations: VAS, visual analogue scale; ODI, Oswestry Disability Index; SF-12 PCS, Short-Form 12 Physical Component Score; SF-12 MCS, Short-Form 12 Mental Component Score; DBM, demineralized bone matrix; rhBMP-2, recombinant human bone morphogenetic protein-2.



**Figure 3.** Comparison of visual analogue scale (VAS) pain scores at baseline, 6-month, 12-month, and 24-month postoperative time points in patients treated with demineralized bone matrix (DBM) and recombinant human bone morphogenetic protein-2 (rhBMP-2).



**Figure 5.** Comparison of Oswestry Disability Index (ODI) scores at baseline, 6-month, 12-month, and 24-month postoperative time points in patients treated with demineralized bone matrix (DBM) and recombinant human bone morphogenetic protein-2 (rhBMP-2).



**Figure 4.** Comparison of Short Form 12 (SF-12) Physical Composite Scale (PCS) and Mental Composite Scale (MCS) scores at baseline, 6-month, 12-month, and 24-month postoperative time points in patients treated with demineralized bone matrix (DBM) and recombinant human bone morphogenetic protein-2 (rhBMP-2).

with significantly increased costs and significantly increased rates of ectopic bone formation. It is worth noting that the high rate of ectopic bone formation observed amongst patients in our study occurred despite rhBMP-2 dosing in our study being at the lower end of previously reported dosing per level fused. This suggests that rhBMP-2 has very significant potential for exuberant and ectopic bone formation and unintentional fusion of adjacent levels.

Fusion rates in the DBM and rhBMP-2 cohorts were compared between fusion observed with 12-month CT alone, 24-month x-ray alone, and combined fusion on either 12-month CT or 24-month x-ray. In combining CT and x-ray fusion rates, patients were considered “fused” if they had evidence of fusion on either their 12-month postoperative CT scan, their 24-month postoperative x-rays, or both. It is possible that excessive bony growth achieved with rhBMP-2 may have falsely biased our results toward showing a lower nonunion rate amongst rhBMP-2-treated patients than DBM-treated patients, as fusion via excessive rhBMP-2 bone growth may be more radiographically apparent. In other words, excessive bony growth achieved with rhBMP-2 may have made fusions more

radiographically evident on either x-ray or CT within the rhBMP-2 group, whereas adequate fusion may have been achieved with DBM but may not have been as radiographically apparent as DBM does not result in as much bony overgrowth. To minimize the impact of false negative radiographs and CT scans on overall fusion rates, we chose to combine CT and x-ray fusion rates at final imaging follow-up for each modality. The importance of minimizing the effect of false negatives is highlighted in Table 5, which shows 87% of patients treated with DBM had posterolateral fusion on 12-month postoperative CTs, while only 77% of patients treated with DBM had 24-month postoperative x-rays demonstrating fusion. Clearly, both CT and x-ray have imperfect sensitivity for detecting fusion. The limitations of CT and x-ray are further reflected in the 2008 study by Fogel et al<sup>16</sup> comparing fusion as assessed by CT, x-ray, and surgical exploration. Additionally, their study showed that both CT and x-ray had good sensitivity for non-union, as both modalities had no instances in which they demonstrated fusion in patients who went on to have pseudarthrosis discovered via surgical exploration. Based on that data, it is unlikely that our method of combining fusion rates from CT and x-rays would have biased our results toward falsely counting patients as fused, when they truly were not fused. Finally, clinical outcomes may further highlight the utility of combining CT and x-ray fusion rates to help maximize accuracy in determining whether patients in both groups achieved fusion. For example, while higher fusion rates were observed in the rhBMP-2 group, 24-month improvements in patient-reported outcomes, including pain, were similar between the 2 groups, with the exception of ODI favoring the DBM group. This is worth noting, as pain may be a symptom of nonunion or pseudarthrosis, yet 24-month pain scores did not differ between groups. Additionally, rates of other complications, including radiculopathy and seroma formation, were similar between patients treated with rhBMP-2 and DBM.

To our knowledge, no prior studies have directly compared efficacy, complications, and costs of DBM to rhBMP-2. Our results suggest that DBM may offer equivalent clinical outcomes at a lower cost without the risk of ectopic bone formation compared with rhBMP-2. While we found similar rates of radiculopathy and seroma formation between patients treated with rhBMP-2 and DBM, our study was not powered specifically to look at these complications, and they remain an important consideration, especially as ectopic bone may impinge on neural structures or cause unintended adjacent level fusion.<sup>14,15</sup> Importantly, patients in both groups who underwent combined interbody and posterolateral fusion had a 100% fusion rate in either the interbody or posterolateral space. For these patients especially, the added cost and risk of rhBMP-2 does not seem to justify its use. Conversely, in patients receiving posterolateral fusion alone who are at high risk of nonunion (diabetics, smokers, revision cases), the higher fusion rate of rhBMP-2 may offset the associated cost and risk of additional surgery or pseudarthrosis.

Results of our study are consistent with those of prior studies. Our fusion rates, specifically the posterolateral fusion rate of 87% for DBM on 12-month postoperative CT, are consistent

with previously reported rates for DBM products.<sup>6,17</sup> Similarly, we found a high incidence (33%) of ectopic bone formation and adjacent level fusion in the rhBMP-2 cohort, which is consistent with previous reports of rhBMP-2 causing excessive bone growth. Conversely, while our results are consistent with prior studies in that they showed increased costs associated with rhBMP-2, our reported average cost of biologics used in the rhBMP-2 group (\$4757) is higher than that previously reported in the literature.<sup>2,13</sup> Despite our higher reported costs, the dose of rhBMP-2 used per level of fusion in our patient population was at the lower end of the range of previously reported rhBMP-2 dosing.<sup>12</sup>

Our study has several limitations. First, our study was underpowered to detect slight differences in fusion rates given the high fusion rates in both the DBM and rhBMP-2 groups. Our study was also underpowered to detect significant differences in specific complications such as seroma formation and radiculopathy. Additionally, fusion and complication rates may differ between various commercial preparations of DBM.<sup>18</sup> While 24-month follow-up has been shown to be adequate for assessing long-term patient improvement following lumbar spine surgery,<sup>19</sup> our 24-month follow-up may have missed cases of pseudarthrosis that presented with longer-term follow-up, as the average reported time to detection of lumbar pseudarthrosis is 3.5 years.<sup>20</sup> It is also known that postoperative patients with pseudarthrosis may initially have good relief of symptoms, which subsequently deteriorates over longer-term follow-up.<sup>21</sup> As such, our results may underestimate the benefits of rhBMP-2. Our study is also limited by its nonrandomized design, which we attempted to address with the matched-cohort comparison. Finally, our study is limited by radiographic assessment of fusion; correlation with surgical exploration of fusion, the gold standard for assessment of fusion, has been reported to be 69% for plain radiography<sup>22</sup> and 89% for CT.<sup>23</sup> Despite these limitations, we believe this study represents a valuable objective assessment of DBM, which performed favorably when compared with historical reports of other commercially available DBM products, and showed similar clinical outcomes to rhBMP-2 but at lower cost. An additional and important strength of our study is that we utilized a commercially available rhBMP-2 kit at previously reported dosing levels, which increases the generalizability of our results. In light of our findings, surgeons should consider the use of DBM, rather than rhBMP-2, as an adjunct to lumbar fusion, especially in patients not at high risk for nonunion.

## Conclusions

DBM combined with locally harvested bone had similar radiographic and clinical outcomes compared with rhBMP-2 in patients undergoing instrumented lumbar fusion. rhBMP-2 was associated with a higher number of radiographic complications including spontaneous adjacent level fusions, with a 68% higher cost compared with DBM. Surgeons should carefully

consider the costs of biologics when performing posterolateral fusions, especially in the setting of similar clinical outcomes.


### Declaration of Conflicting Interests


The author(s) declared no potential conflicts of interest with respect to the research, authorship, and/or publication of this article.

### Funding

The author(s) received no financial support for the research, authorship, and/or publication of this article.

### ORCID iD

Hai Le  <https://orcid.org/0000-0002-9111-9060>

Joseph B. Wick  <https://orcid.org/0000-0002-0030-0367>

### References

1. Sengupta DK, Truumees E, Patel CK, et al. Outcome of local bone versus autogenous iliac crest bone graft in the instrumented posterolateral fusion of the lumbar spine. *Spine (Phila Pa 1976)*. 2006;31:985-991.
2. Carreon LY, Glassman SD, Djurasovic M, et al. RhBMP-2 versus iliac crest bone graft for lumbar spine fusion in patients over 60 years of age: a cost-utility study. *Spine (Phila Pa 1976)*. 2009;34:238-243.
3. Hustedt JW, Blizzard DJ. The controversy surrounding bone morphogenetic proteins in the spine: a review of current research. *Yale J Biol Med*. 2014;87:549-561.
4. Simmonds MC, Brown JV, Heirs MK, et al. Safety and effectiveness of recombinant human bone morphogenetic protein-2 for spinal fusion: a meta-analysis of individual-participant data. *Ann Intern Med*. 2013;158:877-889.
5. Hurlbert RJ, Alexander D, Bailey S, et al. rhBMP-2 for posterolateral instrumented lumbar fusion: a multicenter prospective randomized controlled trial. *Spine (Phila Pa 1976)*. 2013;38:2139-2148.
6. Hoffmann MF, Jones CB, Sietsema DL. Adjuncts in posterior lumbar spine fusion: comparison of complications and efficacy. *Arch Orthop Trauma Surg*. 2012;132:1105-1110.
7. Jackson KL 2nd, Devine JG. The effects of smoking and smoking cessation on spine surgery: a systematic review of the literature. *Global Spine J*. 2016;6:695-701.
8. How NE, Street JT, Dvorak MF, et al. Pseudarthrosis in adult and pediatric spinal deformity surgery: a systematic review of the literature and meta-analysis of incidence, characteristics, and risk factors. *Neurosurg Rev*. 2019;42:319-336.
9. Soroceanu A, Burton DC, Diebo BG, et al. Impact of obesity on complications, infection, and patient-reported outcomes in adult spinal deformity surgery. *J Neurosurg Spine*. 2015;23:656-664.
10. Lenke LG, Bridwell KH, Bullis D, Betz RR, Baldus C, Schoenecker PL. Results of in situ fusion for isthmic spondylolisthesis. *J Spinal Disord*. 1992;5:433-442.
11. Glassman SD, Dimar JR, Carreon LY, Campbell MJ, Puno RM, Johnson JR. Initial fusion rates with recombinant human bone morphogenetic protein-2/compression resistant matrix and a hydroxyapatite and tricalcium phosphate/collagen carrier in posterolateral spinal fusion. *Spine (Phila Pa 1976)*. 2005;30:1694-1698.
12. Hoffmann MF, Jones CB, Sietsema DL. Recombinant human bone morphogenetic protein-2 in posterolateral spinal fusion: what's the right dose? *Asian Spine J*. 2016;10:457-464.
13. Glassman SD, Carreon LY, Campbell MJ, et al. The perioperative cost of Infuse bone graft in posterolateral lumbar spine fusion. *Spine J*. 2008;8:443-448.
14. Ahn J, Jorgensen AY, Bohl DD, et al. Neuroforaminal bone growth following minimally invasive transforaminal lumbar interbody fusion with bmp: a computed tomographic analysis. *Clin Spine Surg*. 2017;30:E754-E758.
15. Wong DA, Kumar A, Jatana S, Ghiselli G, Wong K. Neurologic impairment from ectopic bone in the lumbar canal: a potential complication of off-label PLIF/TLIF use of bone morphogenetic protein-2 (BMP-2). *Spine J*. 2008;8:1011-1018.
16. Fogel GR, Toohey JS, Neidre A, Brantigan JW. Fusion assessment of posterior lumbar interbody fusion using radiolucent cages: X-ray films and helical computed tomography scans compared with surgical exploration of fusion. *Spine J*. 2008;8:570-577.
17. Kang J, An H, Hilibrand A, Yoon ST, Kavanagh E, Boden S. Grafton and local bone have comparable outcomes to iliac crest bone in instrumented single-level lumbar fusions. *Spine (Phila Pa 1976)*. 2012;37:1083-1091.
18. Peterson B, Whang PG, Iglesias R, Wang JC, Lieberman JR. Osteoinductivity of commercially available demineralized bone matrix. Preparations in a spine fusion model. *J Bone Joint Surg Am*. 2004;86:2243-2250.
19. Ayling OGS, Ailon T, McIntosh G, et al. Clinical outcomes research in spine surgery: what are appropriate follow-up times? *J Neurosurg Spine*. 2018;30:397-404.
20. Kim YJ, Bridwell KH, Lenke LG, Cho KJ, Edwards CC 2nd, Rinella AS. Pseudarthrosis in adult spinal deformity following multisegmental instrumentation and arthrodesis. *J Bone Joint Surg Am*. 2006;88:721-728.
21. Kornblum MB, Fischgrund JS, Herkowitz HN, Abraham DA, Berkower DL, Ditkoff JS. Degenerative lumbar spondylolisthesis with spinal stenosis: a prospective long-term study comparing fusion and pseudarthrosis. *Spine (Phila Pa 1976)*. 2004;29:726-733.
22. Blumenthal SL, Gill K. Can lumbar spine radiographs accurately determine fusion in postoperative patients? Correlation of routine radiographs with a second surgical look at lumbar fusions. *Spine (Phila Pa 1976)*. 1993;18:1186-1189.
23. Carreon LY, Djurasovic M, Glassman SD, Sailer P. Diagnostic accuracy and reliability of fine-cut CT scans with reconstructions to determine the status of an instrumented posterolateral fusion with surgical exploration as reference standard. *Spine (Phila Pa 1976)*. 2007;32:892-895.