UC Irvine
UC Irvine Previously Published Works

Title
Microvascular blood flow dynamics associated with photodynamic therapy, pulsed dye laser irradiation and combined regimens

Permalink
https://escholarship.org/uc/item/47v5h6h0

Journal
Lasers in Surgery and Medicine, 38(5)

ISSN
0196-8092

Authors
Smith, Tia K
Choi, Bernard
Ramirez-San-Juan, Julio C
et al.

Publication Date
2006-06-01

DOI
10.1002/lsm.20335

Copyright Information
This work is made available under the terms of a Creative Commons Attribution License, availalbe at https://creativecommons.org/licenses/by/4.0/

Peer reviewed

eScholarship.org Powered by the California Digital Library
University of California

Microvascular Blood Flow Dynamics Associated With Photodynamic Therapy, Pulsed Dye Laser Irradiation and Combined Regimens

Tia K. Smith, MS,[1] Bernard Choi, PhD,[1] Julio C. Ramirez-San-Juan, PhD,[1,2] J. Stuart Nelson, MD, PhD,[1,3] Kathryn Osann, PhD,[4] and Kristen M. Kelly, MD[1,3]*

[1]*Beckman Laser Institute, University of California, Irvine, California 92612*
[2]*Instituto Nacional de Astrofísica, Óptica y Electrónica, Puebla, México 72000*
[3]*Department of Dermatology, University of California, Irvine, California 92697*
[4]*Department of Medicine, University of California, Irvine, California 92697*

Background and Objectives: Previous in vitro studies demonstrated the potential utility of benzoporphyrin derivative monoacid ring A (BPD) photodynamic therapy (PDT) for vascular destruction. Moreover, the effects of PDT were enhanced when this intervention was followed immediately by pulsed dye laser (PDL) irradiation (PDT/PDL). We further evaluate vascular effects of PDT alone, PDL alone and PDT/PDL in an in vivo rodent dorsal skinfold model.

Study Design/Materials and Methods: A dorsal skinfold window chamber was installed surgically on female Sprague–Dawley rats. One milligram per kilogram of BPD solution was administered intravenously via a jugular venous catheter. Evaluated interventions were: control (no BPD, no light), PDT alone (576 nm, 16 minutes exposure time, 15 minutes post-BPD injection, 10 mm spot), PDL alone at 7 J/cm^2 (585 nm, 1.5 ms pulse duration, 7 mm spot), PDL alone at 10 J/cm^2, PDT/PDL (PDL at 7 J/cm^2), and PDT/PDL (PDL at 10 J/cm^2). To assess changes in microvascular blood flow, laser speckle imaging was performed before, immediately after, and 18 hours post-intervention.

Results: Epidermal irradiation was accomplished without blistering, scabbing or ulceration. A reduction in perfusion was achieved in all intervention groups. PDT/PDL at 7 J/cm^2 resulted in the greatest reduction in vascular perfusion (56%).

Conclusions: BPD PDT can achieve safe and selective vascular flow reduction. PDT/PDL can enhance diminution of microvascular blood flow. Our results suggest that PDT and PDT/PDL should be evaluated as alternative therapeutic options for treatment of hypervascular skin lesions including port wine stain birthmarks. Lasers Surg. Med. 38:532–539, 2006. © 2006 Wiley-Liss, Inc.

Key words: photodynamic therapy; pulsed dye laser; Benzoporphyrin; laser speckle imaging

INTRODUCTION

The pulsed dye laser (PDL) is the device of choice for treating cutaneous vascular lesions, achieving impressive results with facial telangiectasia [1]. Port wine stain (PWS) birthmarks are amenable to PDL treatment; however, the blanching response is variable and unpredictable [2].

A variety of factors limit the efficacy of PDL therapy of PWS. First, and perhaps most significant, is the limited ability of the PDL to remove small, superficial vessels (<20 μm) [3,4]. Second, considerable light absorption by epidermal melanin limits the maximum permissible radiant exposure that can be used safely. Epidermal cooling has diminished the magnitude of this problem, but this remains a primary limitation in treatment of patients with darker skin types [5]. Third, even with high radiant exposures, some vessels are not adequately damaged due to limited PDL light penetration depth and presence of vessel clusters which "compete" for light and optically shield deeper vessels [6]. Finally, vessel size and depth vary among PWS and even from site to site on the same patient. As we currently do not have an established noninvasive method for accurate determination of vessel size and depth, laser parameters are selected by the clinician based on limited subjective information and as such are generally not optimized.

Photodynamic therapy (PDT) utilizes a photosensitizer and light to generate reactive oxygen species, presenting an alternative approach for targeted PWS destruction [7]. PDT has been used to treat a wide range of benign, premalignant and malignant conditions, including age-related macular degeneration [8], actinic keratoses [9], and cancers of the skin, lung and gastrointestinal tract [10]. Despite the ability of PDT to destroy selectively the tumor vascular compartment [11–13], PDT has been applied infrequently to treat cutaneous vascular lesions [14–16].

Contract grant sponsor: National Institutes of Health; Contract grant numbers: EB002495, AR47551, AR51443; Contract grant sponsor: Sturge Weber Foundation; Contract grant sponsor: Arnold and Mabel Beckman Fellows Program; Contract grant sponsor: American Society for Laser Medicine and Surgery, Inc.

K.M.K. has disclosed a potential financial conflict of interest with this study.

*Correspondence to: Kristen M. Kelly, MD, 1002 Health Sciences Road East, Irvine, CA 92612. E-mail: KMKelly@uci.edu

Accepted 28 February 2006
Published online 13 April 2006 in Wiley InterScience (www.interscience.wiley.com).
DOI 10.1002/lsm.20335

© 2006 Wiley-Liss, Inc.

PDT offers several important advantages for vascular treatment as compared to PDL. PDT uses a low power continuous wave (CW) light source to induce photochemical reactions with negligible heat generation as compared to short-pulsed, high-intensity PDL irradiations. PDT can be used to destroy all vessels containing a sufficient quantity of photosensitizer, irrespective of size [17], and treatment depth can be regulated with CW light exposure time.

While PDT offers many advantages for treatment of vascular lesions, careful protocol design is required because the potential exists for complete vascular network destruction, which can result in necrosis, ulceration and subsequent scarring. Further, in the past, the period of required light avoidance post-photosensitizer administration was 2–4 weeks, limiting practical use of PDT for vascular lesion treatments.

Taking these issues into account and in an effort to maximize the benefits of both PDL and PDT approaches, we have designed a protocol for treatment of cutaneous vascular lesions [18] whereby we initiate therapy with PDT exposure, using yellow light ($\lambda = 576$ nm) absorbed by the photosensitizer, benzoporphyrin derivative monoacid ring A (BPD), causing initial vascular damage and presumably leaving PWS blood vessels more vulnerable to subsequent photothermal damage [19]. PDL irradiation is then used to heat selectively the pre-treated vessels compromised by PDT. We believe BPD is an excellent choice as a photosensitizer for PDT of cutaneous vascular lesions based on three key attributes: (1) Vascular predominance at early time points after administration [20–22]; (2) proven safety and efficacy in humans [8,23], and (3) photosensitivity of relatively short duration (1–5 days for BPD depending on the dose administered) [23].

A preliminary in vitro study [24] evaluating the vascular effects of PDT, PDL, and PDT/PDL was conducted in a chick chorioallantoic membrane (CAM) model. Significant vascular injury was observed with PDT and PDL groups; however, PDT/PDL resulted in significantly ($P<0.01$) more severe vascular damage than was observed with any other study group: 127% more than PDT and 47% more than PDL.

The preliminary CAM evaluations demonstrated proof of concept for the efficacy of PDT/PDL in treatment of cutaneous vascular lesions. However, disadvantages of the CAM model include lack of an epidermis or equivalent barrier and limited intravenous access. Consequently, as a prelude to a planned clinical study, we assessed safety and compared vascular effects of PDT, PDL, and PDT/PDL in an in vivo rodent dorsal skinfold model.

MATERIALS AND METHODS

Our experimental protocol was approved by the University of California, Irvine Institutional Animal Care and Use Committee. Twenty-seven female Sprague–Dawley rats weighing 400–425 g were obtained with intravenous access via an installed jugular venous catheter (Zivic Laboratories, Pittsburgh, PA).

Rodent Dorsal Skinfold Model

The rodent dorsal skinfold model has been used in investigations of laser light effects on the microcirculation [25–28]. Briefly, the dorsal skin was shaved with clippers, depilated with Nair®, stretched upwards and sutured to a C-clamp. A 1-cm diameter region was cut from one side of the skinfold, thus exposing subdermal blood vessels of the underlying intact skin. An aluminum chamber was then sutured to both sides of the skin allowing observation of blood vessels from the subdermal side and intervention from either the epidermal or subdermal side.

Two control animals underwent surgery but did not receive BPD or any light irradiation.

The below described interventions were performed immediately post-surgery while the animals were still anesthetized.

Epidermal Irradiation

In initial experiments, to determine whether a given intervention would result in adverse cutaneous effects such as blistering, scabbing or ulceration, epidermal irradiations were performed on four animals (one PDT, two PDL at 10 J/cm^2, and one PDT/PDL at 10 J/cm^2—see Table 1).

TABLE 1. Summary of Study Groups

Study group	# of Animals	BPD	PDT	PDL
Control	2	n/a	n/a	n/a
Epidermal irradiation				
PDT	1	1 mg/kg	96 J/cm^2	n/a
PDL	2	n/a	n/a	10 J/cm^2
PDT/PDL	1	1 mg/kg	96 J/cm^2	10 J/cm^2
Subdermalirradiation				
PDT	4	1 mg/kg	96 J/cm^2	n/a
PDL	4	n/a	n/a	7 J/cm^2
PDL	4	n/a	n/a	10 J/cm^2
PDT/PDL	5	1 mg/kg	96 J/cm^2	7 J/cm^2
PDT/PDL	4	1 mg/kg	96 J/cm^2	10 J/cm^2

For the PDT and PDL columns, the entries represent the total radiant exposure delivered to the treatment site.

Subdermal Irradiation

While epidermal irradiation allowed evaluation of the cutaneous surface effects of these interventions, it did not allow evaluation of vascular effects. Incident yellow light is absorbed primarily by more superficial cutaneous vessels, and hence an insignificant quantity of yellow light reaches the subdermal blood vessels exposed by the skinfold surgery which are at a depth of ~2 mm. In order to assess vascular treatment effects, laser irradiations on subsequent animals were performed directly on the subdermal side of the skinfold. It is important to note that in cutaneous vascular lesions such as PWS birthmarks, the lesional vessels or at least those contributing to visible erythema, lie at a depth of 1 mm or less.

Twenty-one animals underwent evaluation after subdermal irradiation under the following conditions: PDT alone (576 nm, 16 minutes exposure time, 15 minutes post-BPD injection, 10 mm spot), PDL alone at 7 J/cm^2 (585 nm, 1.5 ms pulse duration, 7 mm spot), PDL alone at 10 J/cm^2, PDT/PDL (PDL at 7 J/cm^2), and PDT/PDL (PDL at 10 J/cm^2).

Lasers

For PDT, a CW argon pumped dye laser (Coherent, Santa Clara, CA) tuned to 576 nm, was used. For PDL irradiations, a flashlamp pumped PDL (ScleroPlus™, Candela, Wayland, MA) was used at a wavelength of 585 nm, pulse duration of 1.5 ms, and flat-top profile laser spot size of 7 mm diameter.

Photodynamic Therapy

BPD (Verteporfin®, QLT, Vancouver, BC, Canada) liposomal powder was reconstituted in water at a concentration of 1 mg/ml. This working solution was protected from light and used within 4 hours of preparation. One milligram per kilogram of BPD solution was administered intravenously via the installed jugular venous catheter using a Hamilton syringe with a 20-gauge needle. In humans, the dose of BPD for ophthalmologic indications is generally 6 mg/m^2 [8] although up to 14 mg/m^2 has been used in studies for treatment of nonmelanoma skin cancers [29]. Calculation of surface area is difficult in rats but a proposed formula in a recently encountered article [30] indicates that 1 mg/kg in the animals utilized in our study is roughly equivalent to 8 mg/m^2.

Rats were kept in the dark post-BPD injection and further manipulations performed under subdued light conditions. Fifteen minutes after BPD injection, 576 nm CW laser irradiation was performed at an irradiance of 100 mW/cm^2 for 16 minutes, yielding a total radiant exposure of 96 J/cm^2 ("PDT" entry in Table 1).

PDL Irradiation

PDL irradiation was performed at a radiant exposure of either 7 or 10 J/cm^2 (Table 1). For epidermal irradiation experiments, cryogen spray cooling was used with a 30 ms spurt duration and a 20 ms delay between the end of the spurt and onset of the laser pulse, to mimic a typical clinical treatment. Cooling was not used with subdermal irradiations (see below).

PDT/PDL

Animals in the PDT/PDL groups received PDT as described above followed immediately by PDL as described above.

Laser Speckle Imaging

Laser speckle imaging was performed prior to, immediately after and 18 hours post-intervention. For control animals, imaging was performed at the same time points but no drug was administered and no light irradiations were performed. Laser speckle imaging has been used previously to measure blood flow dynamics in the rodent dorsal skinfold model with PDL therapy [28]. Briefly, a HeNe laser ($\lambda = 633$ nm, 30 mW, Edmund Industrial Optics, Barrington, NJ) was used to irradiate the exposed subdermal skin. A planoconvex lens was then used to expand the laser beam to irradiate uniformly an area of approximately 1.5 cm in diameter. The speckle pattern was imaged with an 8-bit monochrome CCD camera (Model XC-70, Sony, Japan) equipped with a macro lens. The field of view was set to an area of approximately 5×4 mm^2. The

TABLE 2. Average Percent Change in Speckle Flow Index (SFI) Calculated for Control and Subdermal Irradiation Study Groups Immediately After and 18 hours Post-Intervention

	Percent change in SFI immediately after		Percent change in SFI 18 hours post-intervention	
Study group	Mean	SD	Mean	SD
A Control	+10	13	+12	4
B PDT	+17	24	−19	36
C PDL 7 J/cm^2	−21	18	−11	27
D PDL 10 J/cm^2	−35	15	−35	26
E PDT/PDL 7 J/cm^2	−34	32	−56	15
F PDT/PDL 10 J/cm^2	−22	39	−39	37

*Differences tested by repeated measures ANOVA: B versus E, $P = 0.04$; B versus F, $P = 0.25$; C versus E, $P = 0.03$; D versus F, $P = 0.71$.

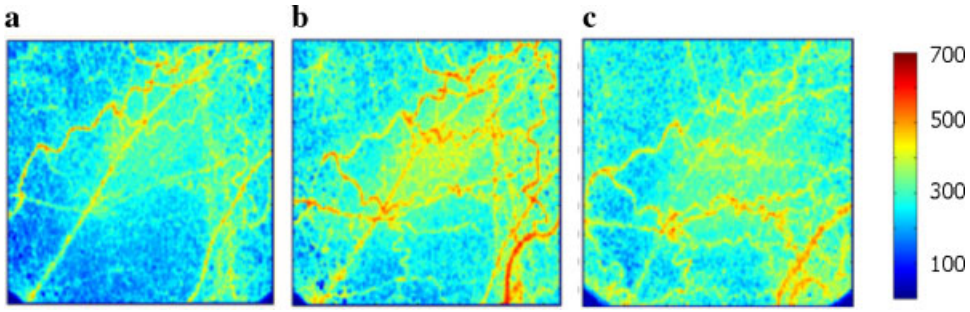

Fig. 1. Representative speckle flow index (SFI) images [5×4 mm^2 (640×480 pixels)] of a control animal (**a**) immediately after positioning (**b**) 16 minutes post-positioning and (**c**) 18 hours after image (a). [Color figure can be viewed in the online issue, available at www.interscience.wiley.com.]

image integration time was 10 ms, and the lens f/# selected to match approximately the speckle size (15 μm) with the camera pixel size. Video images acquired at 30 frames per second were transferred from the camera to a PC equipped with a frame grabber (National Instruments, Austin, TX). Custom software written in LabVIEW (Version 7, National Instruments) and MATLAB (Version 6.1, The MathWorks, Inc., Natick, MA) was used to acquire and process the images. The image processing algorithm has been described previously in detail [31,32]. With this algorithm, raw speckle images were converted to relative speckle flow index (SFI) images.

Statistical Analysis

To quantify changes in microvascular blood flow, the mean and standard deviation of each SFI image were calculated. Mean percent change and standard errors from before treatment to immediately after and 18 hours post-treatment were estimated for each study group and tested with paired *t*-tests. Changes over time were tested using a repeated measures analysis of variance model with three repeated measures (before treatment, immediately after treatment, and 18 hours post-intervention). Group differences in the change over time in SFI were tested by including a grouping factor to compare PDT/PDL at 7 and 10 J/cm^2 to PDT alone and PDL alone.

RESULTS

Epidermal Irradiation

Following epidermal irradiation up to 18 hours post-intervention, we found no clinically relevant skin changes (specifically, no erythema, blistering, scabbing, or ulceration) with any of the animals.

Subdermal Irradiation

Table 2 provides the average percent change in SFI for control and subdermal irradiation study groups immediately after and 18 hours post-intervention. Figures 1 through 6 depict representative examples of laser speckle imaging images taken from control, PDT alone, PDL alone (7 J/cm^2), PDL alone (10 J/cm^2), PDT/PDL (7 J/cm^2) and PDT/PDL (10 J/cm^2) groups, respectively.

In the control group (Table 2, Fig. 1), we observed a slight but statistically insignificant increase in SFI immediately (average percent change of +10%) and 18 hours (+12%) post-intervention (repeated measures ANOVA, $F = 1.95$, $P = 0.334$).

With PDT alone (Table 2, Fig. 2), we observed an initial increase (+17%; paired *t*-test, $P = 0.21$) in SFI followed by a decrease (−19%, paired *t*-test, $P = 0.35$) in SFI at 18 hours post-intervention.

With PDL alone (Table 2, Figs. 3 and 4), we observed an immediate decrease (−21% at 7 J/cm^2 and −35% at 10 J/cm^2)

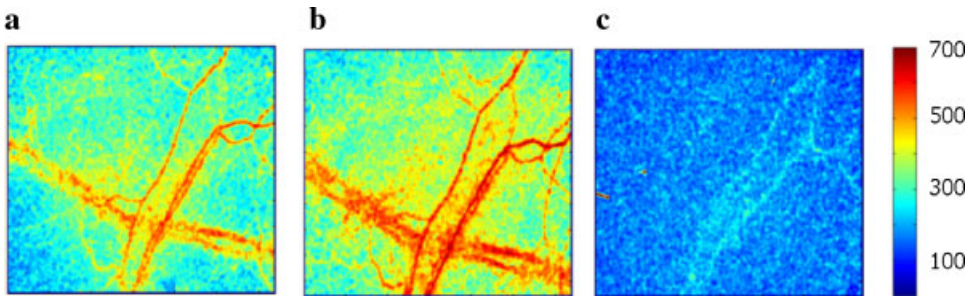

Fig. 2. Representative SFI images [5×4 mm^2 (640×480 pixels)] of a photodynamic therapy (PDT) animal (**a**) before intervention, and (**b**) immediately after and (**c**) 18 hours—post-intervention. [Color figure can be viewed in the online issue, available at www.interscience.wiley.com.]

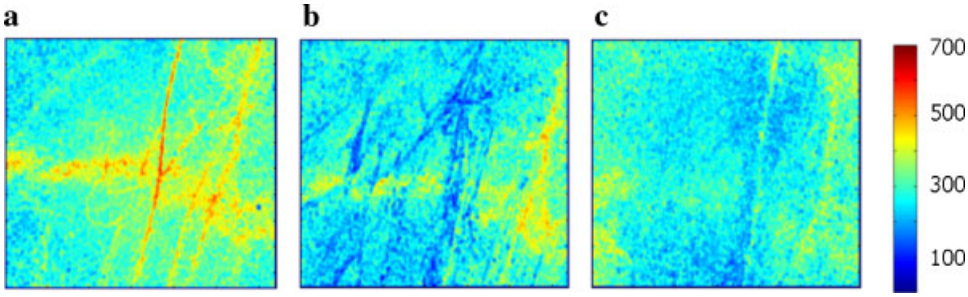

Fig. 3. Representative SFI images [5×4 mm^2 (640×480 pixels)] of a pulsed dye laser (PDL) (7 J/cm^2) animal (**a**) before intervention, and (**b**) immediately after and (**c**) 18 hours post-intervention. [Color figure can be viewed in the online issue, available at www.interscience.wiley.com.]

in SFI post-intervention (paired t-test, $P = 0.097$ and $P = 0.015$, respectively). At 18 hours, some reperfusion was noted as compared to immediately post-treatment in the 7 J/cm^2 group while the decrease in perfusion was maintained in the 10 J/cm^2 group (paired t-test, $P = 0.42$ and $P = 0.09$, respectively).

PDT/PDL (Table 2, Figs. 5 and 6) resulted in an initial decrease (−34% for 7 J/cm^2 and −22% for 10 J/cm^2) in SFI immediately post-intervention, with a further reduction 18 hours post-intervention (−56% for 7 J/cm^2 and −39% for 10 J/cm^2). PDT/PDL (7 J/cm^2) achieved the greatest (−56%) reduction in vascular perfusion at 18 hours. This percent reduction was statistically greater than that noted in the PDT alone or PDL (7 J/cm^2) alone groups, as determined with our repeated measures model [$F = 4.14$ (2 df), $P = 0.04$ and $F = 4.77$ (2 df), $P = 0.03$, respectively]. The differences in percent reduction in SFI between PDT/PDL (10 J/cm^2) and PDT or PDL (10 J/cm^2) alone were not statistically significant ($F = 1.58$, $P = 0.25$ and $F = 0.35$, $P = 0.71$, respectively). The sample size was smaller in the PDT/PDL (10 J/cm^2) group compared to the PDT/PDL (7 J/cm^2) group, hence there was less power to detect a significant difference of the same magnitude.

DISCUSSION

With epidermal irradiation, we did not observe any skin changes (specifically no erythema, blistering, scabbing, or ulceration) following PDL, PDT, or PDT/PDL irradiation. In conjunction with epidermal cooling, PDL treatment at the radiant exposures used in this study is known to be well tolerated [3,33]. However, in a previous study involving PDT of PWS birthmarks, epidermal injury was the primary factor limiting the efficacy of PDT [J.S. Nelson, unpublished data]. The working hypothesis explaining this observation was that PDT induced excessive vascular shutdown of both the superficial and deep blood vessel plexi resulting in skin necrosis. The PDT parameters used in the current study were carefully selected to attain superficial vascular damage without destruction of deep vascular plexi or epidermal injury, overcoming limitations of previous evaluations.

With PDT alone, we observed on average an initial increase in perfusion immediately after the intervention followed by a reduction in perfusion observed 18 hours post-intervention (Fig. 2). Major et al. [34] evaluated PDT effects within an hour post-intervention. Our results suggest that a longer observation period is required to assess accurately the efficacy of PDT protocols. Several mechanisms may be responsible for the increase in blood flow observed during and immediately after PDT, including a compensatory response to oxygen depletion occurring during PDT [35] and/or an acute inflammatory response. It is not known at what time point between immediately after and 18 hours post-intervention, that vascular shutdown occurs. Further evaluation is required.

At 18 hours post-intervention, PDT induced a comparable reduction in blood flow as compared to PDL treatment

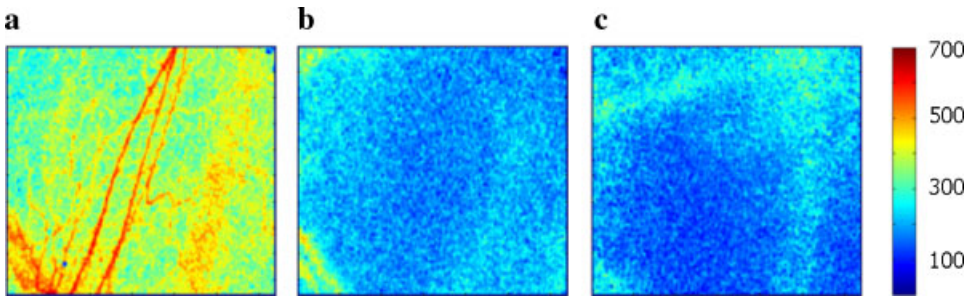

Fig. 4. Representative SFI images [5×4 mm^2 (640×480 pixels)] of a PDL (10 J/cm^2) animal (**a**) before intervention, and (**b**) immediately after and (**c**) 18 hours post-intervention. [Color figure can be viewed in the online issue, available at www.interscience.wiley.com.]



Fig. 5. Representative SFI images [5×4 mm^2 (640×480 pixels)] of a PDT/PDL (7 J/cm^2) animal (**a**) before intervention, (**b**) immediately after, and (**c**) 18 hours post-intervention. [Color figure can be viewed in the online issue, available at www.interscience.wiley.com.]

at 7 J/cm^2 (Figs. 2 and 3, Table 2). Increasing the PDL radiant exposure from 7 to 10 J/cm^2 (Figs. 3 and 4) resulted in two effects on average: (1) Augmented SFI reduction immediately after treatment and (2) persistence of this reduction at 18 hours, with incomplete restoration of blood flow noted in the PDL group treated at 7 J/cm^2. This data suggests that higher PDL radiant exposures achieve enhanced effect and are useful for consideration when PDL therapy is performed alone.

The greatest reduction in SFI was noted with the PDT/PDL treatment (7 J/cm^2), supporting our previous results obtained with the CAM model [24]. We propose two hypotheses that may explain the enhanced results achieved with the combined approach. One explanation is that PDT causes some initial microvascular injury, increasing the efficacy of the ensuing PDL therapy. Alternatively or perhaps additionally, vasodilatation observed with PDT (Fig. 2b) may increase the local concentration of hemoglobin molecules, resulting in enhanced photocoagulation of nominally small vessels that are typically resistant to standard PDL therapy [36,37].

An unexpected result was that PDT/PDL at 10 J/cm^2 achieved a comparable reduction in SFI to that observed with PDL alone at 10 J/cm^2. Furthermore, the reduction in SFI with PDT/PDL at 10 J/cm^2 was less than that achieved with PDT/PDL at 7 J/cm^2. The explanation of these observations is unclear but it is possible that the higher radiant exposure PDL reduced the effectiveness of the PDT induced biochemical cascade, which normally occurs after irradiation. Further study is required.

It should be noted that currently, the relationship between percent change in SFI values (Table 2) and degree of PWS blanching is unknown. Published studies [38,39] utilizing laser Doppler imaging for evaluation of PWS therapy do not provide quantitative data on the percent change in PWS skin perfusion. One evaluation performed laser speckle imaging data during laser therapy of upper extremity PWS skin, and reported an approximate 25% decrease in SFI, but no quantitative measure of PWS blanching was obtained [39]. In the future, we plan to quantify this relationship by utilizing laser speckle imaging during PDL PWS therapy.

Analyzing the SFI images (Figs. 2 through 6) and the percent change observed with intervention (Table 2), it may seem that the imaged vascular shutdown at 18 hours is greater than the measured values reported in Table 2. We hypothesize that persistent perfusion was in vessels deep to the area of irradiation and perhaps in very small capillaries beyond the resolution of our laser speckle imaging instrument. In laser PWS therapy, this would be analogous to photocoagulation of the targeted superficial PWS blood vessels and incomplete photocoagulation of deeper vessels, which do not contribute to observed PWS erythema. Such sparing of deep vessels may actually provide a protective effect during therapy, preventing cutaneous necrosis while not comprising desired lesional blanching.

Currently available treatments for cutaneous vascular lesions such as PWS birthmarks do not achieve consistent and complete blanching, and as such, alternative therapeutic modalities need to be sought. BPD, PDT, and PDT/

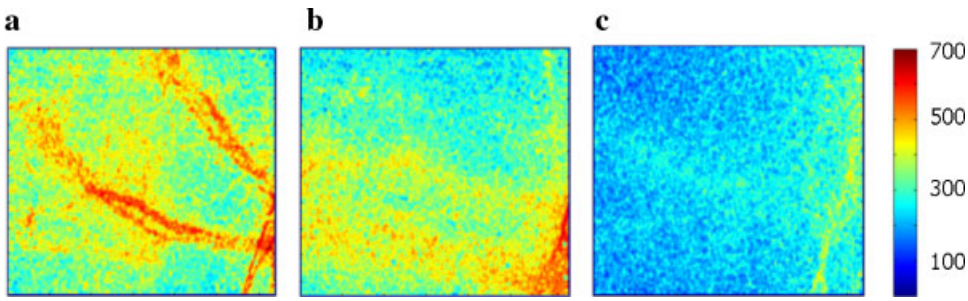

Fig. 6. Representative SFI images [5×4 mm^2 (640×480 pixels)] of a PDT/PDL (10 J/cm^2) animal (**a**) before intervention, (**b**) immediately after, and (**c**) 18 hours post-intervention. [Color figure can be viewed in the online issue, available at www.interscience.wiley.com.]

PDL can achieve safe and selective vascular injury and appear to have significant potential as alternative treatments. Clinical trials are required and are underway.

CONCLUSIONS

BPD, PDT can achieve safe and selective vascular flow reduction. PDT/PDL can enhance diminution of microvascular blood flow. Our results suggest that PDT and PDT/PDL should be evaluated as alternative therapeutic options for treatment of hypervascular skin lesions including PWS birthmarks.

ACKNOWLEDGMENTS

This work was supported in part by grants obtained from the National Institutes of Health EB002495 (T.K.S.), AR47551 (J.S.N.) and AR51443 (K.M.K.), Sturge Weber Foundation (K.M.K.), Arnold and Mabel Beckman Fellows Program (B.C.) and the American Society for Laser Medicine and Surgery, Inc. (B.C.). A BPD sample was generously provided by QLT (Vancouver, BC, Canada). We thank Laurie Newman for assistance with animal handling and Drs. Sol Kimel and Lars Svaasand for their advice and assistance.

REFERENCES

1. Morelli JG, Huff JC, Weston WL. Treatment of congenital telangiectatic vascular malformations with the pulsed-dye laser (585 nm). Pediatrics 1993;92:603–606.
2. Kelly KM, Choi B, McFarlane S, Motosue A, Jung B, Khan MH, Ramirez-San-Juan JC, Nelson JS. Description and analysis of treatments for port wine stain birthmarks. Arch Facial Plas Surg 2005;7:287–294.
3. Edstrom DW, Hedblad M-A, Ros AM. Flashlamp pulsed dye laser and argon-pumped dye laser in the treatment of port wine stains: A clinical and histological comparison. Br J Derm 2002;146:285–289.
4. Babilas P, Shafirstein G, Baumler W, Baier J, Landthaler M, Szeimies RM, Abels C. Selective photothermolysis of blood vessels following flashlamp-pumped pulsed dye laser irradiation: In vivo results and mathematical modeling are in agreement. J Invest Dermol 2005;125:343–352.
5. Norvang LT, Fiskerstrand EJ, Nelson JS, Berns MW, Svaasand LO. Epidermal melanin absorption in human skin. Proc SPIE 1996;2624:143–154.
6. van Gemert MJ, Smithies DJ, Verkruysse W, Milner TE, Nelson JS. Wavelengths for port wine stain laser treatment: Influence of vessel radius and skin anatomy. Phys Med Biol 1997;42:41–50.
7. Nelson JS, McCullough JL, Berns MW. Principles and applications of photodynamic therapy in dermatology. In: Arndt KA, Dover JE, Olbricht SA, eds. Lasers in Cutaneous and Aesthetic Surgery. Philadelphia, PA: Lippincott-Raven; 1997. pp 349–382.
8. Sickenberg M, Schmidt-Erfurth U, Miller JW, Pournaras CJ, Zografos L, Piguet B, Donati G, Laque H, Barbazetto I, Gragoudas ES, Lane A-M, Birngruber R, van den Bergh H, Strong A, Manjuris U, Gray T, Fsadni M, Bressler NM. A preliminary study of photodynamic therapy using verteporfin for choroidal neovascularization in pathologic myopia, ocular histoplasmosis syndrome, angioid streaks, and idiopathic causes. Arch Ophthalmol 2003;118:327–339.
9. Jeffes EW, McCullough JL, Weinstein GD, Fergin PE, Nelson JS, Shull TF, Simpson KR, Bukaty LM, Hoffman WL, Fong NL. Photodynamic therapy of actinic keratoses with topical 5-aminolevulinic acid (ALA): A pilot dose-ranging study. Arch Dermatol 1997;133:727–732.
10. Marcus SL. Lasers in Photodynamic Therapy. *Lasers in Medicine,* Boca Raton: CRC Press; 2002. pp 287–324.
11. Orenstein A, Nelson JS, Liaw LH, Kaplan R, Kimel S, Berns MW. Photochemotherapy of hypervascular dermal lesions: A possible alternative to photothermal therapy? Lasers Surg Med 1990;10:334–343.
12. Nelson JS, Liaw LH, Orenstein A, Roberts WG, Berns MW. The mechanism of tumor destruction following photodynamic therapy with hematoporphyrin derivative, chlorin and phthalocyanine. J Natl Cancer Inst 1988;80:1599–1605.
13. Star WM, Marijnissen HPA, van den Berg-Blok AE, Versteeg JAC, Franken KAP, Reinhold HS. Destruction of rat mammary tumor and normal tissue microcirculation by hematoporphyrin derivative photoradiation as observed in vivo in sandwich observation chambers. Cancer Res 1986;46:2532–2540.
14. Gu Y, Jun-heng L. The clinical study of argon laser PDT for port wine stain. 40 case reports. Chin J Laser Med 1992;1:1–4.
15. Jiang L, Gu Y, Li X, Zhao X, Li J, Wang K, Liang J, Pan Y, Zhang Y. Changes of skin perfusion after photodynamic therapy for port wine stain. Chin Med J 1998;111:136–138.
16. Lin XX, Wang W, Wu SF, Yang C, Chang TS. Treatment of capillary vascular malformation (port-wine stains) with photochemotherapy. Plast Reconstr Surg 1997;99:1826–1830.
17. Lin GC, Tsoukas MM, Lee MS, Gonzalez S, Vibhagool C, Anderson RR, Kollias N. Skin necrosis due to photodynamic action of benzoporphyrin depends on circulating rather than tissue drug levels: Implications for control of photodynamic therapy. Photochem Photobiol 1998;68:575–583.
18. Kimel S, Svaasand LO, Kelly KM, Nelson JS. Synergistic photodynamic and photothermal treatment of port wine stain? Lasers Surg Med 2004;34:80–82.
19. Hammer-Wilson MJ, Cao D, Kimel S, Berns MW. Photodynamic parameters in the chick chorioallantoic membrane (CAM) biosassay for photosensitizers administered intraperitoneally (IP) into the check embryo. Photochem Photobiol Sci 2002;9:721–728.
20. Tsoukas MM, Gonzalez S, Flotte TJ, Anderson RR, Sherwood ME, Kollias N. Wavelength and fluence effect on vascular damage with photodynamic therapy on skin. J Invest Dermatol 2000;114:303–308.
21. Fingar VH, Kik PK, Haydon PS, Cerrito PB, Tseng M, Abang E, Wieman TJ. Analysis of acute vascular damage after photodynamic therapy using benzoporphyrin derivative (BPD). Br J Cancer 1999;79:1702–1708.
22. Zhou X, Pogue BW, Chen B, Hasan T. Analysis of effective molecular diffusion rates for verteporfin in subcutaneous versus orthotopic Dunning prostate tumors. Photochem Photobiol 2004;79:323–331.
23. Houle JM, Strong A. Duration of skin photosensitivity and incidence of photosensitivity reactions after administration of verteporfin. Retina 2002;22:691–697.
24. Kelly KM, Kimel S, Smith T, Stacy A, Hammer-Wilson MJ, Svaasand LO, Nelson JS. Combined photodynamic and photothermal induced injury enhances damage to in vivo model blood vessels. Lasers Surg Med 2004;34:407–413.
25. Gourgouliatos ZF, Welch AJ, Diller KR. Measurements of argon laser light attenuation in the skin in vivo using a unique animal model. Lasers Med Sci 1992;7:63.
26. Barton JK, Vargas G, Pfefer TJ, Welch AJ. Laser fluence for permanent damage of cutaneous blood vessels. Photochem Photobiol 1999;70:916–920.
27. Vargas G, Chan KF, Thomsen SL, Welch AJ. Use of osmotically active agents to alter optical properties of tissue: Effects on the detected fluorescence signal measured through skin. Lasers Surg Med 2001;29:213–220.
28. Choi B, Kang NM, Nelson JS. Laser speckle imaging for monitoring blood flow dynamics in the in vivo rodent dorsal skin fold model. Microvasc Res 2004;68:143–146.
29. Hobbs LH, Tope WD, Lee PK, Elmets C, Provost N, Chan A, Neyndorff H, Su XY, Jain H, Hamzavi I, McLean D, Bissonette R. Photyndamic therapy of multiple nonmelanoma skin cancers with verteporfin and red light-emitting

diodes: Two-year results evaluating tumor response and cosmetic outcomes. Arch Dermatol 2004;149:26–32.
30. Hosnuter M, Babucuu O, Kargi E, Atinyazar C, Babbuccu B, Isikdemir A. Rat skin surface measurement: A practical formula. Plast Recon Surg 2003;112:1486–1487.
31. Dunn AK, Bolay H, Moskowitz MA, Boas DA. Dynamic imaging of cerebral blood flow using laser speckle. J Cereb Blood Flow Metab 2001;1:195–201.
32. Briers JD. Laser Doppler, speckle and related techniques for blood perfusion mapping and imaging. Physiol Meas 2001; 22:R35–R66.
33. Geronemus RG, Quintana AT, Lou WW, Kauvar AN. High-fluence modified pulsed dye laser photocoagulation with dynamic cooling of port-wine stains in infancy. Arch Dermatol 2000;136:942–943.
34. Major A, Kimel S, Mee S, Milner TE, Smithies DJ, Srinivas SM, Chen Z, Nelson JS. Microvascular photodynamic effects determined in vivo using optical Doppler tomography. IEEE J Sel Topics Quantum Electron 1999;5:1168–1175.
35. Yu GQ, Durduran T, Zhou C, Wang HW, Putt ME, Saunders HM, Sehgal CM, Glatstein E, Yodh AG, Busch TM. Noninvasive monitoring of mural tumor blood flow during and after photodynamic therapy provides early assessment of therapeutic efficacy. Clin Canc Res 2005;11:3543–3552.
36. Aguilar G, Svaasand LO, Nelson JS. Effects of hypobaric pressure on human skin: Feasibility study for port wine stain laser therapy (part I). Lasers Surg Med 2005;36:124–129.
37. Aguilar G, Franco W, Liu J, Svaasand LO, Nelson JS. Effects of hypobaric pressure on human skin: Implications for cryogen spray cooling (part II). Lasers Surg Med 2005;36:130–135.
38. Troilius A, Wardell K, Bornmyr S, Nilsson GE, Ljunggren B. Evaluation of port wine stain perfusion by laser Doppler imaging and thermography before and after argon laser treatment. Acta Derm Venereol 1992;72:6–10.
39. Troilius AM, Ljunggren B. Evaluation of port wine stains by laser Doppler perfusion imaging and reflectance photometry before and after pulsed dye laser treatment. Acta Derm Venereol 1996;76:291–294.