



Advances in progressive supranuclear palsy: new diagnostic criteria, biomarkers, and therapeutic approaches

Adam L Boxer, Jin-Tai Yu, Lawrence I Golbe, Irene Litvan, Anthony E Lang, Günter U Höglinger

Lancet Neurol 2017; 16: 552–63

Department of Neurology, Memory and Aging Center, University of California, San Francisco, CA, USA (Prof A L Boxer MD);

Department of Neurology, Qingdao Municipal Hospital, Qingdao University, Qingdao, China (Prof J-T Yu MD);

Department of Neurology, Rutgers Robert Wood Johnson Medical School, New Brunswick, NJ, USA

(Prof L I Golbe MD); Department of Neurology, University of California, San Diego, CA, USA (Prof I Litvan MD);

Department of Neurology, University of Toronto, Toronto, ON, Canada (Prof A E Lang MD);

Department of Neurology, Technical University of Munich, Munich, Germany (Prof G U Höglinger MD);

Department of Translational Neurodegeneration, German Center for Neurodegenerative Diseases (DZNE), Munich, Germany (Prof G U Höglinger);

and Munich Cluster for Systems Neurology SyNergy, Munich, Germany (Prof G U Höglinger)

Correspondence to: Prof Adam L Boxer, Memory and Aging Center, Department of Neurology, University of California, Sandler Neurosciences Center, San Francisco, CA 94158, USA
adam.boxer@ucsf.edu

Progressive supranuclear palsy (PSP), previously believed to be a common cause of atypical parkinsonism, is now recognised as a range of motor and behavioural syndromes that are associated with a characteristic 4-repeat tau neuropathology. New research criteria that recognise early presentations of PSP and operationalise diagnosis of the full spectrum of clinical phenotypes have been reported. The Movement Disorders Society PSP diagnostic criteria include syndromes with few or mild symptoms that are suggestive of underlying PSP pathology and could provide an opportunity for earlier therapeutic interventions in the future. These criteria also include definitions for variant PSP syndromes with different patterns of movement, language, or behavioural features than have been conclusively associated with PSP pathology. Data from new diagnostic biomarkers can be combined with the clinical features of disease to increase the specificity of the new criteria for underlying PSP pathology. Because PSP is associated with tau protein abnormalities, there is growing interest in clinical trials of new tau-directed therapies. These therapies are hypothesised to have disease-modifying effects by reducing the concentration of toxic forms of tau in the brain or by compensating for loss of tau function. Since tau pathology is also central to Alzheimer's disease and chronic traumatic encephalopathy, a successful tau therapeutic for PSP might inform treatment of other neurodegenerative diseases.

Introduction

Progressive supranuclear palsy (PSP) was initially believed to be a cause of atypical parkinsonism; however, during the past decade, PSP was found to encompass a range of clinical phenotypes involving behavioural, language, and movement abnormalities.¹ The classic movement disorder clinical phenotype, now referred to as Richardson's syndrome (PSP-RS), was first described in 1964 by Steele, Richardson, and Olszewski.² Since then, no effective treatments for this uniformly fatal disorder have been identified.³ However, because PSP is strongly linked to tau-protein abnormalities, both neuropathologically and genetically,⁴ there is an increased interest in clinical trials of new tau-directed therapies. PSP-RS is considered to be a rare disease, with a prevalence of about 5–7 cases per 100 000 people.⁵ A study in the UK⁵ showed a peak prevalence between the ages of 70 and 74 years of about 18 cases per 100 000 people. However, a study in Japan⁶ that included other PSP phenotypes in addition to PSP-RS found a total prevalence of 18 cases per 100 000 across all ages. This higher prevalence is consistent with estimates from autopsy series,⁷ and suggests that the prevalence of the full spectrum of PSP syndromes is substantially higher than prevalence estimates based on PSP-RS cases only. Findings from a cluster of PSP cases in an industrial city in France⁸ and a multicentre case-control study⁹ suggest that environmental risk factors affect PSP incidence.

In this Review, we describe advances in clinical diagnosis, neuropathology, genetics, biomarkers, and therapeutics of PSP. An important advance has been the development of the new International Parkinson's and Movement Disorder Society (MDS) Criteria for the Diagnosis of PSP,¹⁰ which recognise early, suggestive forms of PSP, and operationalise diagnosis of non-Richardson's PSP phenotypes.¹⁰

The spectrum of progressive supranuclear palsy

The MDS PSP Diagnostic Criteria¹⁰ were based on a comprehensive literature review by the MDS PSP Working Group, followed by a consensus conference in March, 2016, in collaboration with patient advocacy groups. In this Review, we outline the essential components and guidelines of these new criteria; the detailed criteria have been published elsewhere.¹⁰

Most neurodegenerative diseases begin with a pre-symptomatic phase in which neuropathological changes accumulate, but have not yet crossed the threshold necessary to produce clinical symptoms. A wealth of evidence supports this sequence of pathological events in Alzheimer's disease and Parkinson's disease,^{11,12} and the description of mild asymptomatic PSP pathology in some clinically healthy elderly people suggests that a similar sequence of events might occur in PSP.^{7,13,14} Therefore, it is likely that PSP starts with a presymptomatic phase, in which neuropathological abnormalities begin to accumulate but clinical features are absent, continues with a suggestive-of-PSP (soPSP) phase, in which individuals develop mild or isolated symptoms but do not meet the full MDS research criteria for a possible or probable PSP syndrome, and culminates with a fully symptomatic stage that, in many cases, would meet the research criteria for PSP-RS or another clinical variant of PSP (vPSP; figure 1). As PSP progresses, many patients with vPSP syndromes eventually develop features of PSP-RS.¹⁵ Patients who only display a vPSP phenotype are difficult to conclusively diagnose before death.¹⁶

Most patients with PSP syndromes eventually develop some or all of the clinical features of PSP-RS; however, in approximately two-thirds of the patients with neuropathologically defined PSP, as determined in brain bank studies, the initial presentation in the first 2 years is not

PSP-RS.^{1,15} Other vPSP syndromes, named according to their predominant clinical features, might account for about one-third to two-thirds of initial presentations, and include PSP with predominant parkinsonism (PSP-P),¹⁷ pure akinesia with gait freezing (formerly PAGF, and now PSP with progressive gait freezing [PSP-PGF]),¹⁸ corticobasal syndrome (PSP-CBS),^{15,19} primary progressive apraxia of speech or non-fluent variant primary progressive aphasia (nfvPPA; when caused by PSP, this disease is named PSP with predominant speech or language disorder [PSP-SL]),²⁰⁻²² behavioural variant frontotemporal dementia (bvFTD; when caused by PSP, this disease is named PSP with predominant frontal presentation [PSP-F]),^{15,23} and PSP with predominant cerebellar ataxia (PSP-C; figure 2).²⁵

Presymptomatic PSP phase

Presymptomatic PSP occurs in individuals who are asymptomatic but at high risk of developing symptoms of PSP. Currently, the presymptomatic phase can only be identified post mortem from evidence of PSP-associated neuropathological changes in individuals who are considered to be otherwise healthy.^{7,13,14} Because the new MDS PSP criteria focus on clinical diagnosis, they do not include the presymptomatic PSP phase, but the criteria are consistent with this notion. In one community-based autopsy series,²⁶ PSP neuropathology was present in five (2.1%) of 233 individuals. Another two studies with similar methodology found PSP pathology in five (4.2%) of 119 elderly individuals in a clinically healthy cohort¹³ and in 29 (4.6%) of 626 individuals older than 60 years in a large forensic autopsy series in Japan.⁷ These numbers are in striking contrast to the low estimated prevalence of PSP-RS in epidemiological studies,⁵ which suggests that, if these findings are correct, most individuals with presymptomatic PSP do not develop overt disease.

Suggestive-of-PSP phase

soPSP refers to the early symptomatic phase of PSP that occurs before development of a fully symptomatic PSP syndrome, during which a few clinical symptoms or signs are clearly present, but do not warrant a diagnosis of PSP. Inherent in the definition of soPSP is some uncertainty as to whether the individual will progress to PSP-RS, to vPSP, or to a non-PSP diagnosis. In the future, diagnostic biomarkers for PSP might help to mitigate this uncertainty. The soPSP category also includes individuals who have developed one or more major features of PSP-RS or of a vPSP syndrome, but do not fulfil diagnostic criteria for these syndromes (figure 1), such as individuals with isolated saccadic slowing or unexplained postural instability.¹⁵ A diagnosis of soPSP can be made only when individuals are suspected to have PSP pathology but do not fully meet the criteria for PSP diagnosis, and when other causes have been excluded. Recognition of individuals in the soPSP phase of disease might allow neuroprotective

treatment to be initiated early enough to stabilise these patients before the onset of substantial disability.

Symptomatic PSP phenotypes

The clinical features of the different PSP phenotypes have been described in detail in several reviews.^{1,27} Importantly, the language and behavioural presentations of PSP can also frequently meet criteria for frontotemporal lobar

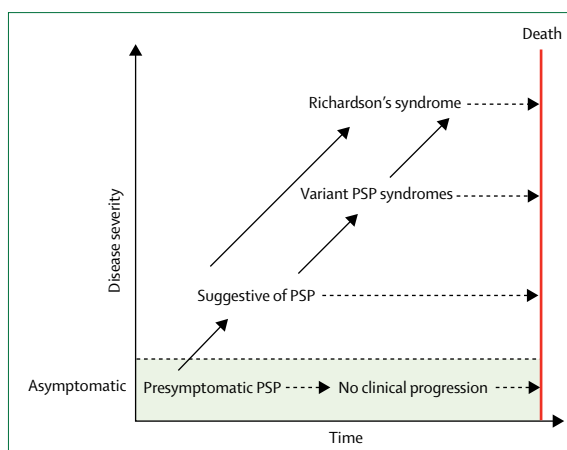


Figure 1: Hypothetical model of the clinical trajectories of progressive supranuclear palsy

Progressive supranuclear palsy is considered as a pathological continuum from a presymptomatic phase, through a suggestive phase, to a fully symptomatic phase that, in many cases, would meet research criteria for possible or probable PSP-Richardson's syndrome by the Movement Disorder Society criteria,²⁸ or a variant PSP syndrome. Not all cases of presymptomatic or suggestive PSP will progress to a PSP phenotype. PSP=progressive supranuclear palsy.

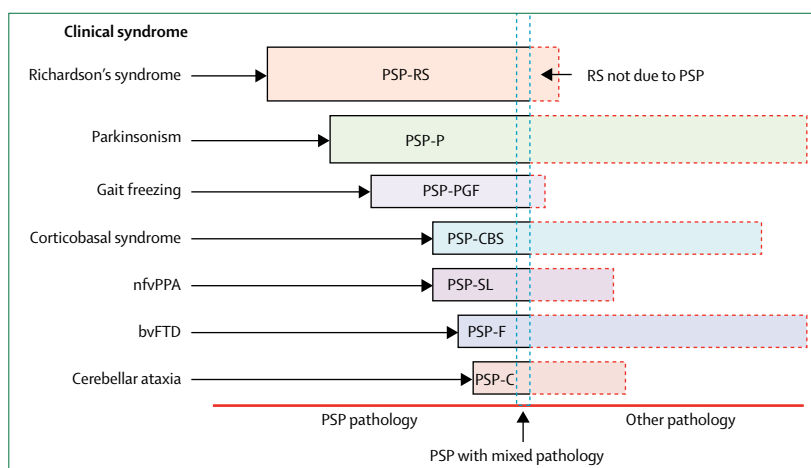


Figure 2: Clinical syndromes in progressive supranuclear palsy

PSP=progressive supranuclear palsy. RS=Richardson's syndrome. PSP-P=PSP with predominant parkinsonism. PSP-PGF=PSP with progressive gait freezing. PSP-CBS=PSP-corticobasal syndrome. nfvPPA=non-fluent variant primary progressive aphasia. PSP-SL=PSP with predominant speech or language disorder. bvFTD=behavioural variant frontotemporal dementia. PSP-F=PSP with predominant frontal presentation. PSP-C=PSP with predominant cerebellar ataxia. Relative proportions of each syndrome (illustrated by bar length) are speculative. PSP pathology means meeting neuropathological criteria for PSP.^{1,24} Mixed pathology means meeting neuropathological criteria for PSP plus another disorder such as Alzheimer's or Parkinson's disease. Other pathology means meeting neuropathological criteria for another disorder such as Parkinson's disease, but not meeting criteria for PSP. Nomenclature reflect Movement Disorder Society PSP diagnostic criteria.¹⁰

degeneration. We briefly describe each syndrome, as classified by the new MDS PSP criteria, in the following section, with particular attention to new evidence from the past 7 years. We also highlight the changes in nomenclature introduced by the new MDS PSP Criteria.¹⁰

Richardson's syndrome

PSP-RS refers to the classically described phenotype of PSP that was originally codified in the 1996 National Institute for Neurological Disorders and Society for PSP research criteria.²⁸ The most frequently reported symptoms at onset are unexplained falls, unsteady gait, bradykinesia, subtle personality changes (apathy, disinhibition), cognitive slowing (bradyphenia), executive dysfunction (difficulty planning or multitasking), slow, ataxic, spastic, and hypophonic speech, dysphagia, and impaired ocular movement (ie, slowing of vertical saccades, difficulty reading, or apraxia of eyelid opening).¹ Vertical supranuclear gaze palsy is the definitive diagnostic feature, but its onset is variable, and might not present until 3–4 years after disease onset. Decreased velocity (slowing) and gain (amplitude) of vertical greater than horizontal saccadic eye movements and decreased or absent optokinetic nystagmus are early signs of PSP-RS that are detected at neurological examination.²⁹

PSP-parkinsonism

PSP-P was first defined as a clinical phenotype of PSP on the basis of an autopsy series,¹ in which a subset of patients had early features of Parkinson's disease and a more benign disease course than patients with PSP would usually have. Patients with PSP-P often present with an asymmetric onset of tremor, bradykinesia, rigidity, a moderate initial response to levodopa therapy, and a slower rate of disease progression than patients with PSP-RS. The clinical presentation of PSP-P resembles idiopathic Parkinson's disease sufficiently that the two disorders are difficult to distinguish early on.¹⁷ Later in the disease course, most patients develop features of PSP-RS and they are retrospectively diagnosed with PSP-P. It is impossible to conclusively diagnose patients with PSP-P premortem if they do not develop symptoms of PSP-RS. However, later in the disease course, levodopa-induced dyskinesias, autonomic dysfunction, and visual hallucinations are much less common in patients with PSP-P than in those with Parkinson's disease, which can help to distinguish these diseases.²⁷

PSP with progressive gait freezing

Pure akinesia with gait freezing, now referred to as PSP-PGF, is a clinical phenotype of PSP that initially presents with an isolated gait disorder years before development of other PSP-RS features.¹⁸ PSP-PGF is characterised by progressive gait disturbance with start hesitation and subsequent freezing of gait, sometimes also involving difficulties with initiating or completing speech or writing, without tremor, rigidity, dementia, or

eye movement abnormalities during the first 5 years of the disease. PSP-PGF has been reported to be highly predictive of PSP pathology.¹

PSP-corticobasal syndrome

CBS is the best recognised presentation of corticobasal degeneration, a 4-repeat tauopathy closely related to PSP. Clinically and genetically, there is substantial overlap between corticobasal degeneration and PSP neuropathology. The diagnostic research criteria for corticobasal degeneration³⁰ acknowledge a syndrome caused by corticobasal degeneration pathology that resembles PSP-RS, which underscores this frequent overlap; both corticobasal degeneration and PSP feature 4-repeat tauopathy, but morphology, anatomical distribution, and biochemical features differ between these diseases. In contrast, PSP-CBS refers to the clinical CBS phenotype of neuropathologically defined PSP, characterised by a variable combination of progressive limb rigidity, apraxia, cortical sensory loss, alien limb, and bradykinesia, and that is unresponsive to levodopa. PSP-CBS is a rare presentation of PSP pathology and was present in only six of the 179 pathologically diagnosed PSP cases in the Queen Square Brain Bank series.¹⁹ Distinction of PSP-CBS from corticobasal degeneration-CBS based on clinical features is impossible ante-mortem¹⁹ and, for this reason, the new MDS PSP Criteria designate PSP-CBS as possible PSP, but probable 4-repeat tauopathy (either corticobasal degeneration or PSP pathology).¹⁰

PSP-speech language

nfvPPA is a progressive syndrome characterised by either agrammatism in language production or effortful, halting speech with inconsistent speech sound errors and distortions (apraxia of speech).³¹ The MDS PSP criteria¹⁰ recognise a clinical phenotype of PSP that initially presents with predominant speech or language disorder features of nfvPPA, before developing motor features of PSP-RS.^{20,21} A longitudinal study²⁰ of 13 patients with primary progressive apraxia of speech, which has similar initial symptoms to nfvPPA, found that five of these patients developed a syndrome similar to PSP-RS about 5 years after onset, and 22 of 25 patients with nfvPPA in a larger series²² were found to have tau pathology post mortem, most commonly 4-repeat tauopathy. Similar to PSP-CBS, the new PSP criteria designate PSP-SL as possible PSP, but probable 4-repeat tauopathy, because determination of which PSP-SL cases have PSP pathology based on clinical findings is impossible ante-mortem.¹⁰

PSP with frontal presentation

PSP-F refers to cases that present with clinical features of behavioural variant frontotemporal dementia years before the presentation of motor features of PSP-RS. bvFTD is a clinical syndrome characterised by an early and progressive deterioration of personality, social

comportment, behaviour (such as apathy, rigidity, disinhibition, and hyperorality), and cognition.³² PSP-F is uncommon. Only three (4.5%) of 66 autopsy-proven PSP cases in the Mayo Clinic series²³ presented with the behavioural and personality changes of bvFTD. However, a European series¹⁵ of autopsy-proven PSP suggested a higher prevalence of FTD-like symptoms at onset of 12 of 100 autopsy-confirmed PSP cases.

PSP with predominant cerebellar ataxia

PSP-C is a rare clinical phenotype. Patients present with cerebellar ataxia as the initial and principal symptom before developing cardinal features of PSP-RS, such as saccade impairments and falls, during the disease course. In contrast to the proportion of three cases of 22 patients reported in an earlier Japanese study,³³ a Mayo Clinic autopsy study²⁵ identified only five patients with PSP-C among 1085 pathologically confirmed PSP cases, four of whom were clinically misdiagnosed with multiple system atrophy type C. In these four patients, clinical features of PSP-C were similar to those of multiple system atrophy type C, but they did not have the dysautonomia required to meet criteria for a diagnosis of multiple system atrophy.²⁵ Because PSP-C is difficult to diagnose ante-mortem, and ataxia is more frequently suggestive of neurodegenerative diseases other than PSP, this variant is not included in the new MDS PSP criteria.

PSP with mixed pathology

Although strong associations exist between the hallmark neuropathological features of PSP and clinical features, there is an increased recognition that a subset of patients might have also other neuropathologies that affect their clinical phenotype. Various co-pathologies have been described in association with PSP including, most frequently, Alzheimer's disease pathology, but also Parkinson's disease pathology, TDP-43 deposition, argyrophilic grain disease, or cerebrovascular disease. In a study³⁴ evaluating 64 cases of pathologically proven PSP, 36% of patients had concomitant Alzheimer's disease, 20% had Parkinson's disease, 1% had dementia with Lewy bodies, 44% had argyrophilic grain disease, 52% had cerebral white matter rarefaction, and 25% had cerebral amyloid angiopathy.

Neuropathology

The National Institute of Neurological Disorders and Stroke neuropathological criteria for PSP were validated in 1996,²⁴ and require the presence of neurofibrillary tangles or neuropil threads (composed of tau protein), or both, in the basal ganglia and the brainstem. Microscopic features include neuronal loss, gliosis, neurofibrillary tangles, neuropil threads, tufted astrocytes, and oligodendroglial coiled bodies.³⁵

The regional distribution of tau pathology and neuronal loss is a source of pathological and, consequentially, clinical heterogeneity in PSP.³⁵ More severe and

widespread cortical tau pathology has been documented in PSP syndromes with more severe cortical symptoms ante-mortem, such as PSP-CBS,³⁶ PSP-SL,²² and PSP-F, than in movement-predominant PSP syndromes, such as PSP-P and PSP-PGF. Brainstem-predominant PSP syndromes, such as PSP-P and PSP-PGF, have less severe cortical tau pathology and more severe degeneration in the globus pallidus, subthalamic nucleus, and substantia nigra compared with PSP-RS.¹ Studies^{37,38} using brain tissue from patients with PSP have shown that inoculation of tau transgenic mice with human tissue can recapitulate PSP-associated tau inclusions in mouse brains and enable identification of specific strains of transmissible tau in cell culture models. It is hypothesised that the different PSP disease phenotypes might emerge from the preferential spread of tau through different brain networks that are functionally and neuroanatomically connected.³⁹

Genetics

MAPT polymorphisms and haplotypes

The locus most strongly linked with risk of PSP is the gene for the microtubule-associated protein tau (*MAPT*).⁴ Genetic studies,⁴ including genome-wide association studies, have identified both an inversion polymorphism and haplotype-specific *MAPT* polymorphisms that affect the risk of PSP (figure 3). The odds ratio (OR) for PSP in carriers of the *MAPT* H1/H1 haplotype is 5.5, which is higher than the OR for the *APOE* $\epsilon 3/\epsilon 4$ genotype (~ 3.0) as a risk factor for Alzheimer's disease.^{4,40} The underlying molecular mechanisms for PSP risk conferred by the H1 haplotype is unclear. A rare coding *MAPT* variant (152A \rightarrow T) alters microtubule assembly and is a strong risk factor for both PSP and frontotemporal dementia.⁴¹

MAPT mutations

PSP is a sporadic disease, but very rare familial forms of PSP have been described,^{42,43} and 12 (7%) of 172 patients with PSP-RS in one series⁴² fulfilled criteria for an autosomal dominant mode of inheritance; however, this finding was not replicated in a subsequent study.⁹ Although a causative mutation has not been identified for most familial cases, mutations in the *MAPT* gene have been identified as pathological mutations in several families with autosomal dominant pattern of disease inheritance, including some families with pathologically confirmed PSP.⁴³ Notably, most of these variants are located in exon 10 and its splicing regulatory region (figure 3). Insoluble 4-repeat tau protein deposits are characteristic of PSP pathology, therefore mutations that enhance splicing in *MAPT* exon 10 might promote disease by enhancing production of 4-repeat tau isoforms.⁴⁴

Emerging loci from genome-wide association studies

The first large genome-wide association study⁴ in patients with PSP identified three new genetic risk factors: *STX6*, *EIF2AK3*, and *MOBP*. The mechanisms by which these

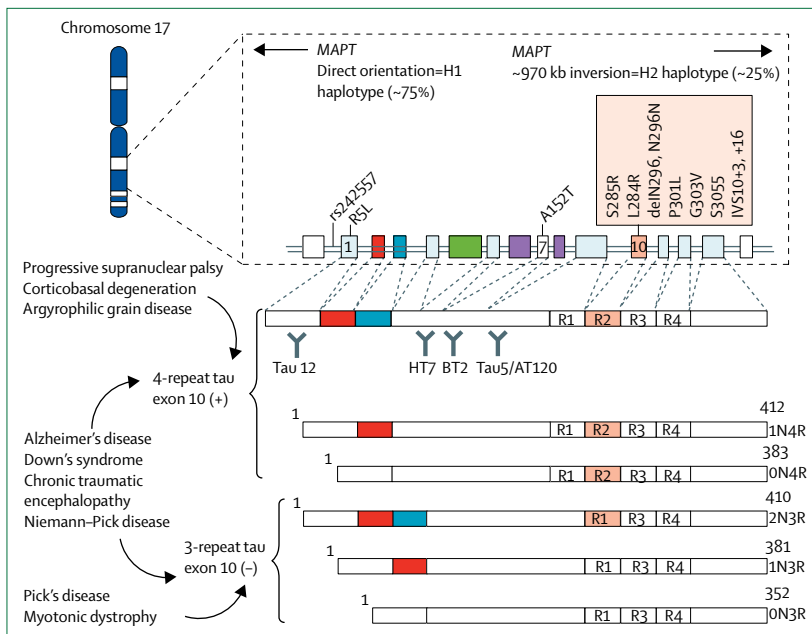


Figure 3: The MAPT locus, its pathological mutations, and tau protein isoforms

The MAPT locus, located on chromosome 17q21, exists as two major haplotypes, termed H1 and H2. Most people have the H1/H1 haplotype. Mutations producing progressive supranuclear palsy phenotypes are indicated as orange boxes. Alternative splicing of exons 2, 3, and 10 of the MAPT gene generates the six isoforms of the encoded tau protein expressed in the human brain. Increased 4 microtubule-binding domain-repeat tau, containing the aminoacids encoded by exon 10, is associated with progressive supranuclear palsy and corticobasal degeneration. An equal ratio of 3-repeat and 4-repeat tau is present in healthy adults and patients with Alzheimer's disease. Binding sites for monoclonal antibodies (tau 12, HT7, BT2, and tau5/AT120), used in CSF tau assays, are indicated. MAPT=microtubule-associated protein tau.

genes might increase risk for PSP are not known. The PSP-associated single nucleotide polymorphism near the *MOBP* gene correlates more strongly with increased expression of the *SLC25A38* gene, which encodes the protein apoptosin, than with *MOBP* expression.⁴⁵ Apoptosin overexpression in transgenic mice increases caspase-mediated tau cleavage, tau aggregation, synaptic dysfunction, and gait and balance deficits.⁴⁵ Loss-of-function of *EIF2AK3* in human beings appears to result in Wolcott-Rallison syndrome, a severe, childhood-onset disease with cerebral tau pathology.⁴⁶ These findings suggest that other genetic polymorphisms might also increase the risk of PSP via their effects on tau.

Advances in biomarkers

PSP-RS is a distinctive clinical syndrome, usually easily differentiated from other parkinsonian disorders. However, in suggestive or variant cases, biomarkers might help to improve diagnostic accuracy. During the past decade, several neuroimaging, biological, and neurophysiological biomarkers have been described as potentially helpful in differentiating PSP-RS from other parkinsonian syndromes (table 1). However, an important lesson learned from early studies is that the diagnostic value of these biomarkers cannot be established without adequately powered studies in cases confirmed by autopsy. For example, midbrain atrophy, alone or in combination

with other brainstem imaging measures, has been repeatedly identified as a biomarker of PSP,^{52–55,60,61} but could not differentiate RS due to pathological changes associated with PSP from pathological changes of corticobasal degeneration in some studies.^{47,51}

There is an urgent need for diagnostic biomarkers that can detect PSP pathology in very mildly symptomatic or presymptomatic individuals to enable early diagnosis and intervention with potentially disease-modifying therapies. Such biomarkers might permit the expansion of therapeutic studies to early disease stages in patients with vPSP or soPSP. Biomarkers that reflect the pharmacodynamic effects of new therapies on their intended targets are also needed to support clinical trials.

MRI

Atrophy of the midbrain and superior cerebellar peduncles is a useful marker in differentiating PSP-RS from other parkinsonian syndromes and can be tracked longitudinally with diffusion tensor imaging.^{47,56} In a cohort including patients with pathologically confirmed PSP, multiple system atrophy, Parkinson's disease, or corticobasal degeneration and matched healthy controls, conventional structural MRI was more specific but less sensitive than clinical diagnosis of PSP, and the hummingbird and morning glory flower signs each had 100% specificity for PSP but lower sensitivity (68.4% for the hummingbird sign and 50.0% for the morning glory sign).⁴⁷ Another cohort study⁵² that included patients with pathologically confirmed cases of PSP found that the magnetic resonance parkinsonism index (MRPI) yielded sensitivity of 100% and specificity of 99.2–100.0% for PSP-RS. The pons:midbrain ratio, as calculated from conventional MRI, had high specificity and sensitivity for the diagnosis of pathologically confirmed PSP.⁵³ In studies of the early stages of PSP,⁵³ MRPI was also able to predict development of PSP-RS in unclassifiable parkinsonism, and eye movement abnormalities in PSP-P.^{52,54}

Resting-state functional MRI (fMRI) is also a promising imaging biomarker for PSP. An intrinsic connectivity network anchored at the dorsal midbrain shows disruptions in PSP that are correlated with physiological and clinical features.³⁹

PET using fluorodeoxyglucose (FDG), ¹⁸F-AV1451, and other ligands

¹⁸FDG-PET in patients with 4-repeat tauopathy, including PSP variants (confirmed at autopsy), showed hypometabolism in the frontal cortex, caudate, midbrain, and thalamus.⁶⁰ PSP-related metabolic co-variance patterns might also help with differential diagnosis.⁶¹ However, despite these observations, the diagnostic utility of ¹⁸FDG-PET in PSP is not well established.

The development of tau-specific PET imaging ligands offers the opportunity for in-vivo topographical mapping and quantification of tau aggregation and deposition in parallel with clinical assessments of PSP.⁷⁹ One such

ligand, ^{18}F -AV1451, binds specifically to neurofibrillary tangles and paired helical filament-tau in Alzheimer's disease, and produces high-quality images in living patients;⁷⁰ however, its utility in measurement of patients with PSP is still uncertain. Previous data⁶² have suggested weak AV1451 binding to aggregated 4-repeat tau in autopsy tissue slices from patients with PSP. Preliminary PET data in patients suggest that AV1451 binds more strongly to areas of known tau pathology in patients with more advanced PSP-RS compared with age-matched healthy controls.^{63,64} Several other novel selective tau tracers, including ^{11}C -PBB3, have also been reported to bind to tau in patients with PSP, but insufficient data exist at this time to gauge their potential utility.⁸⁰

CSF and blood biomarkers

Several studies have attempted to identify CSF biomarkers that would allow accurate diagnosis of PSP.⁷² None of these studies were done in cases confirmed at autopsy. CSF phospho-tau and total tau concentrations

in patients with PSP are normal or low relative to healthy controls, in contrast with those in patients with Alzheimer's disease, in whom phospho-tau and total tau concentrations are increased.⁶⁷ Several CSF studies showed 2–5 times increased neurofilament light chain concentrations in patients with PSP compared with healthy controls, Parkinson's disease, Parkinson's disease dementia, and dementia with Lewy bodies, but not when compared with CBS and multiple system atrophy.^{69,72} The only CSF biomarker that changed over time in a multicentre PSP clinical trial was neurofilament light chain concentration.⁷⁰ Neurofilament light chain concentrations can now be measured in blood reliably, and patients with PSP-RS have elevated concentrations of plasma neurofilament light chain compared with age-matched healthy controls and patients with Parkinson's disease.⁷³ Baseline plasma neurofilament light chain concentrations predicted disease progression over the course of a year, as measured by various clinical and MRI measures.⁷⁴

	Potential uses						Post-mortem validation	Key insights
	Bedside diagnosis	Animal models	Progression biomarker	Diagnostic biomarker	Surrogate outcome	Pharmacodynamic outcome		
Imaging								
MRI								
Visual read on conventional MRI ^{47,48}	X	X	Yes	Hummingbird and morning glory signs were specific to PSP, but did not differentiate from CBD pathology
Volumetric ^{49,50}	..	X	Yes	Anti-tau therapy reduced brain atrophy in tau transgenic mouse models
Regional gray and white matter volume ^{30,21}	X	..	X	..	Yes	PSP-like atrophy was detectable in patients with non-fluent variant primary progressive aphasia and primary progressive apraxia of speech
Midbrain area and volume ^{48,51}	X	Yes	Midbrain atrophy was not specific to PSP and was also found in CBD pathology
Midbrain:pons ratio(s) such as magnetic resonance parkinsonism index ⁵²⁻⁵⁴	X	X	Yes	Ratio differentiated pathologically confirmed PSP from Parkinson's disease and multiple system atrophy; predicted gaze palsy and other Richardson's syndrome signs (in clinically diagnosed cases)
Volume of midbrain, pons, and other regions of interest ⁵⁵	X	..	Yes	Distinct atrophy rate was measurable in patients with PSP
DTI ^{56,57}	X	..	No	DTI differences in PSP phenotypes; DTI seemed sensitive to disease progression
Free-water imaging ⁵⁸	X	No	Improved differential diagnosis of PSP from Parkinson's disease
Resting-state functional MRI ³⁹	X	No	Reduced connectivity in midbrain-anchored network also present in healthy controls
Task functional MRI ³⁹	X	X	No	Enabled differential diagnosis of PSP from Parkinson's disease
PET								
FDG ^{60,61}	X	..	X	X	Yes	Medial frontal, caudate, and thalamic hypometabolism; measurement of changes in metabolism helped identify PSP
Tau tracers (AV1451 or PBB3) ⁶²⁻⁶⁵	X	X	..	X	Yes	Anecdotal reports of in-vivo binding for most tracers; AV1451 had low affinity for 4-repeat tau in brain tissue post mortem
Magnetoencephalography								
Binaural masking level difference ⁶⁶	X	X	No	Measurable evoked responses in PSP

(Table 1 continues on next page)

	Potential uses						Post-mortem validation	Key insights
	Bedside diagnosis	Animal models	Progression biomarker	Diagnostic biomarker	Surrogate outcome	Pharmacodynamic outcome		
(Continued from previous page)								
Fluid								
CSF								
Tau ^{67,68}	No	Total tau concentrations similar to those of healthy controls
Phospho181 Tau ^{67,68}	No	Phospho Tau concentrations similar to or lower than those in healthy controls
Neuro-filament light chain ⁶⁸⁻⁷¹	X	X	X	X	X	X	No	Neuro-filament light chain concentrations were elevated in patients with PSP and increased over time, and correlated with clinical rating scales and volumetric imaging measurements; also elevated in tau transgenic mice
YKL-40 ⁷²	X	No	Elevated concentrations in patients with PSP
Blood								
Neuro-filament light chain ^{71,73,74}	..	X	X	X	X	?	No	Plasma neuro-filament light chain concentrations elevated in patients with PSP, and predictive of rate of disease progression, measured by clinical rating scales and volumetric MRI
Physiological								
Eye movements								
Infrared oculography ^{29,70}	X	X	X	..	Yes	Decreased saccade velocity and gain in patients with PSP
Eyelid function								
Spontaneous and evoked blink rate ²⁵	X	X	..	No	Blink rate variables associated with PSP diagnosis
Retinal thickness								
Optical coherence tomography ⁷⁵	X	X	No	Decreased retinal thickness in patients with PSP
Activity								
Wrist actigraphy ⁷⁷	..	X	X	..	No	Disrupted circadian rhythms and sleep in patients with PSP
Finger taps								
Quantitative ⁷⁸	X	..	No	Distinct abnormalities between Richardson's syndrome and Parkinson's disease
CBD=corticobasal degeneration. PSP=progressive supranuclear palsy. DTI=diffusion tensor imaging.								

Table 1: Potential biomarkers for progressive supranuclear palsy

Physiological biomarkers

Slowing of vertical saccades to a greater extent than horizontal saccades is a distinctive feature of PSP-RS.⁸¹ Decreases in saccade velocity and gain account for the most characteristic PSP ocular motor deficits, and have been shown to be very specific findings that allow differentiation of autopsy-confirmed PSP from other disorders.²⁹ Profound changes in saccade velocity and gain over the course of 1 year have been shown in two cases of PSP that were confirmed by autopsy.⁸¹ Retinal optical coherence tomography is another promising biomarker for PSP, but remains in an early stage of investigation.⁷⁶

Therapeutic approaches

PSP is a uniformly fatal disease. Patients with PSP-P often initially experience a symptomatic benefit from levodopa therapy, as do a few patients with PSP-RS;³ however, this benefit is transient in most cases and has no known effect on disease duration. Physical therapy is helpful, and leads

to measurable improvements on clinical rating scales.⁸² Pretarsal botulinum toxin injections might be effective for apraxia of eyelid opening. Several randomised placebo-controlled clinical trials^{70,83} with small numbers of patients have been performed in patients with PSP-RS (table 2); however, none of these studies showed efficacy other than for co-enzyme Q10, which showed a modest symptomatic benefit in a small, 6-week study,⁹⁰ but this result was not replicated in a larger, albeit underpowered, 12-month study.⁸³ Deep brain stimulation of the pedunculo-pontine nucleus has been attempted in patients with advanced PSP-RS; however, no clear benefits were observed, and there were unacceptable side-effects.⁹¹

The rapid gain of knowledge on the pathogenesis of PSP has facilitated the implementation of a series of clinical studies with hypothesis-driven, disease-modifying therapeutic approaches targeting tau or mitochondrial dysfunction.^{70,92-94} Of these, three clinical trials were adequately powered to possibly show small to moderate

	Mode of action	Disease	Phase	ClinicalTrials.gov identifier
TPI-287 ⁸⁴	Microtubule stabiliser	Alzheimer's disease, corticobasal degeneration, PSP	1	NCT01966666, NCT02133846
AADvac1	Tau active vaccination	Alzheimer's disease	1	NCT01850238
ACI-35	Tau active vaccination	Alzheimer's disease	1	Not available
TRx0237 ⁸⁵	Tau-aggregation inhibitor	Alzheimer's disease, behavioural variant frontotemporal degeneration	3 (both negative)	NCT01689233, NCT01689246, NCT01626378
Abb-8E12 or C2N-8E12 ⁵⁰	Anti-tau monoclonal antibody	PSP, Alzheimer's disease	2	NCT02494024, NCT02880956
BMS-986168 ⁸⁶	Anti-tau monoclonal antibody	PSP	2	NCT02460094, NCT03068468
Salsalate ⁴⁹	Inhibitor of tau acetylation	PSP, Alzheimer's disease	1	NCT02422485
Young plasma transfusions ⁸⁷	Rejuvenation	PSP, Alzheimer's disease	1	NCT02460731
Various ⁸⁸	O-GlcNAcase inhibitors	PSP	Animal studies	Not available
Tau antisense oligonucleotides ^{44,89}	Reduce tau gene expression	Various	Animal studies	Not available

PSP=progressive supranuclear palsy.

Table 2: Planned or ongoing clinical trials involving tau therapeutics

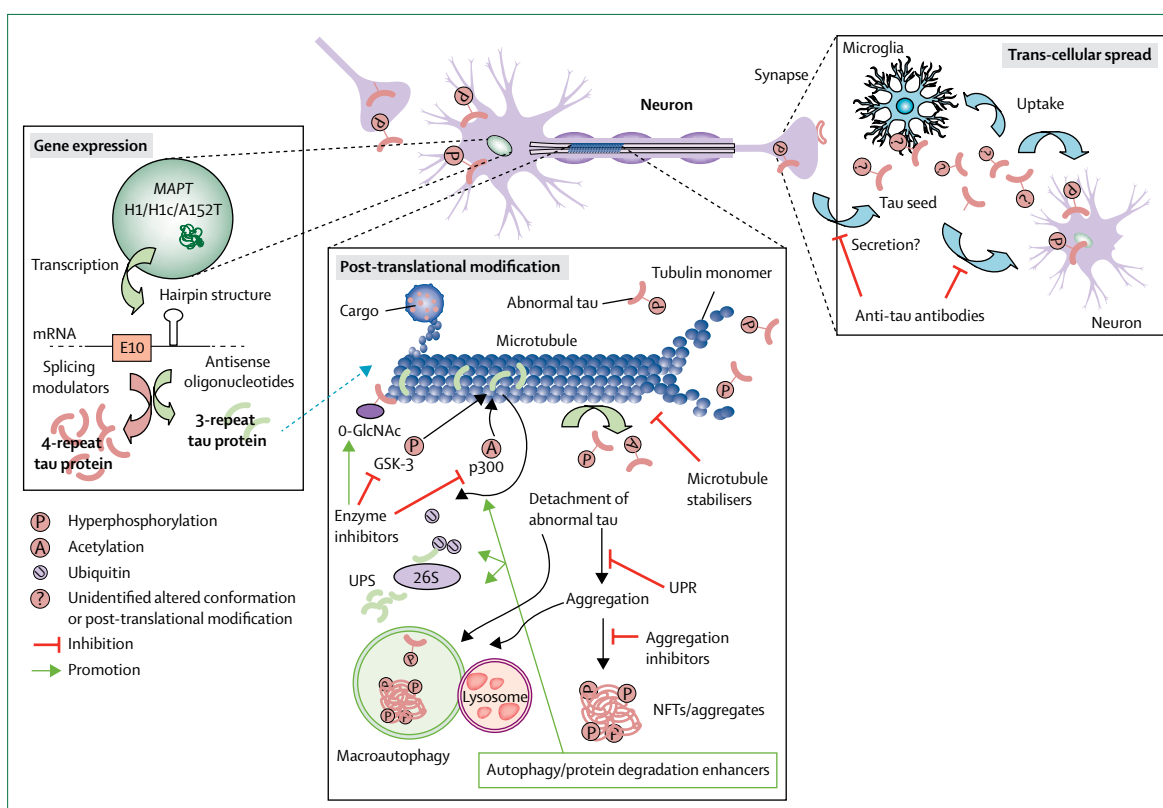


Figure 4: Potential therapeutic targets for progressive supranuclear palsy

Three categories of intervention are under development. (1) Modulation of MAPT gene expression, with antisense oligonucleotides or splicing modulators. (2) Modulation of tau protein post-translational modifications, including phosphorylation, acetylation, and O-GlcNAc modification; degradation by the UPS and autophagy pathways; and modulation of the UPR. (3) Inhibition of tau propagation via trans-synaptic pathways or mediated by microglia. Modulating inflammation might alter tau pathology. GSK=glycogen synthase kinase. p300=acetyltransferase. UPS=ubiquitin proteasome system. UPR=unfolded protein response. NFTs=neurofibrillary tangles. MAPT=microtubule-associated protein tau.

disease-modifying effects: the Neuroprotection and Natural History in Parkinson's Plus Syndromes (NNIPPS) study of riluzole,⁹³ a phase 2 trial of tideglusib,⁹⁴ and a phase 2–3 trial of davunetide.⁷⁰ All three trials failed to show efficacy on primary or secondary clinical endpoints. An important limitation of these studies was the absence of a

pharmacodynamic biomarker able to show that the experimental drug engaged its physiological target and produced its hypothesised biological effect. Thus, it is possible that the studies were negative because the proposed mechanism of action did not operate in human beings in the same manner as in animal models.

Neurodegeneration in PSP is strongly associated with tau pathology, but the mechanisms by which tau abnormalities lead to cell dysfunction and death are not well understood. Two types of tau dysfunction are thought to lead to neurodegeneration: loss of tau function or toxic gain of tau function.⁸⁴ These mechanisms are not mutually exclusive, and it is possible that toxic gain-of-function in one cellular compartment might lead to loss of tau function in others.

Tau loss-of-function therapies

The rationale for using microtubule stabilisers for the treatment of PSP is based on the notion that these drugs can compensate for the microtubule dysfunction that might result from loss of tau function (figure 4).⁸⁴ Several microtubule-stabilising drugs have been developed, and three have been explored in clinical trials of neurodegenerative disease. Davunetide is a microtubule-stabilising octapeptide that showed benefits in transgenic mouse models of tauopathy. However, a large clinical trial⁷⁰ of davunetide for PSP-RS did not show efficacy. TPI-287, a new blood–brain barrier-permeable taxane, has entered phase 1 clinical trials for Alzheimer's disease, PSP, and amyloid-negative PET CBS (table 2).

Tau gain-of-function therapies

Evidence that tau propagates between cells in a prion-like manner raises the possibility that blocking spread of pathogenic tau with anti-tau antibodies might be a viable approach to tauopathy treatment (figure 4).⁹⁵ Passive immunisation with anti-tau monoclonal antibodies not only suppresses tau pathology but also improves cognitive or motor function in tau transgenic mouse models.^{95,96} Certain three-dimensional conformations of tau seem particularly pathogenic and can be targeted by specific antibodies.⁹⁶ Two N-terminal tau-directed monoclonal antibodies, BMS-986168 and Abb-8E12, have progressed to phase 2 clinical trials for PSP (table 2).⁹⁷ Active vaccination against tau epitopes is also under investigation, and two tau vaccines have entered human clinical trials: AADvac1 and ACI-35.⁹⁷

Small molecules targeting tau aggregation or post-translational modifications

In PSP, tau aggregates into neurofibrillary tangles and neuropil threads. Therefore, inhibition of tau assembly and disassembly are potential therapeutic approaches.

Methylene blue derivatives, particularly leuco-methylthioninium bis(hydromethanesulfonate; LMTM), were investigated in phase 3 clinical trials for Alzheimer's disease and behavioural variant frontotemporal degeneration;⁸⁵ however, both trials were negative, which casts doubt on the potential use of LMTM in treatment of PSP.

Hyperphosphorylation of tau is a well studied post-translational modification and has historically been a focus for drug development (figure 4). Inhibition of glycogen synthase kinase 3 (GSK-3) reduces tau phosphorylation in vitro, and GSK-3 could be a therapeutic target for treatment of PSP.⁹⁴ However, the GSK-3 inhibitor tideglusib was not efficacious in a phase 2 clinical trial for PSP,⁹⁴ and a clinical trial of lithium, hypothesised to work by a similar mechanism, was stopped because of poor tolerability (ClinicalTrials.gov, number NCT00703677). Several studies suggest that acetylation of soluble tau species might precede hyperphosphorylation, and that inhibition of this process could be a potential therapeutic strategy.⁴⁹ Salsalate, a tau acetylation inhibitor, has entered a phase 1 clinical trial for PSP (table 2). Finally, inhibitors of the enzyme O-GlcNAcase, which cleaves the post-translational modification O-GlcNAc, protected against neurodegeneration in tau transgenic mice.⁸⁸ Clinical trials of O-GlcNAcase inhibitors are planned for PSP.

Antisense oligonucleotides and splicing modulators

Downregulation of tau gene expression might be beneficial in tauopathies by preventing build-up of toxic forms of tau.⁹⁸ A study⁸⁹ showed the feasibility of reducing human tau protein concentrations with *MAPT* antisense oligonucleotides both in vitro and in vivo. Exon 10 splicing is regulated by a hairpin RNA structure that is destabilised by pathological *MAPT* point mutations. Normalisation of the 3-repeat:4-repeat tau ratio with antisense oligonucleotides or splicing modulators might also be viable therapeutic approaches. Both antisense oligonucleotides and small molecules have been developed to stabilise the hairpin and inhibit 4-repeat tau expression.⁴⁴ Intrathecally administered antisense oligonucleotides have been used in clinical trials in patients with amyotrophic lateral sclerosis with *SOD1* mutations, and a similar delivery approach might be used in PSP in the future.⁸⁹

Other strategies

A growing body of evidence suggests that microglial activation drives tau pathology and contributes to the spread of pathological tau in the brain (figure 4).⁹⁹ Data from animal studies suggest that therapeutic strategies that target microglia-specific fractalkine receptors (such as CX3CR1) and interleukin-1 β signalling could also help stop the spread of tau.¹⁰⁰ Other strategies under development to target tau pathology include enhanced degradation of misfolded tau or neurofibrillary tangles by various proteolytic systems, including autophagy pathways¹⁰¹ and the unfolded protein response,⁴⁶ drugs that target mitochondrial dysfunction,⁸³ cell replacement,¹⁰² and young adult (<30 years of age)

Search strategy and selection criteria

We searched PubMed for articles published from Jan 01, 2009, to Feb 28, 2017, in English or Japanese (available in English) journals, using the search terms "progressive supranuclear palsy", "PSP", "Steel-Richardson-Olszewski syndrome", "Richardson's syndrome", "tau protein", "MAPT", "pure akinesia with gait freezing", and "tauopathy". Additional articles were included from reference lists, review articles, and the authors' own files. The final reference list was generated on the basis of originality and relevance to the topics covered in this Review.

plasma transfusions designed to reverse brain ageing.⁸⁸ A phase 1 study in a small number of patients with PSP given young plasma transfusions is underway (table 2).

Conclusions and future directions

There are no effective therapies for PSP; however, insights into the pathophysiology and ontogeny of PSP during the past decade have been fruitful in developing new experimental drugs that have entered clinical trials. Both neuropathological and genetic data suggest a central role of the tau protein in PSP pathogenesis. The new MDS diagnostic criteria for PSP expand the clinical spectrum of PSP by incorporating conditions suggestive of PSP and a variety of symptomatic PSP phenotypes. Several promising biomarkers for PSP have been described to aid in differential diagnosis and evaluation of novel therapeutics. Numerous clinical trials are planned, which offer promise for the possibility of effective PSP therapies. Since tau pathology is also central to Alzheimer's disease and chronic traumatic encephalopathy, it is believed that a successful tau therapeutic for PSP would also inform the treatment of other neurodegenerative diseases.

There is still a lot of work to be done. Although many clues have emerged from genetics, cell biology, and neuropathological studies of PSP and other tauopathies, the cellular mechanisms of PSP pathogenesis remain elusive. Transcellular spread of tau pathology is an attractive hypothesis with clear therapeutic implications, but evidence in human beings has yet to be convincingly shown. Moreover, it is unclear how well findings in preclinical tauopathy models will translate to patients.

Important challenges remain for clinicians. Many patients are still diagnosed too late, and that would preclude benefit from a disease-modifying therapy once an intervention is available. Although the new diagnostic criteria might alleviate this problem, international efforts will be necessary to better educate physicians and to establish reliable biomarkers for early and accurate differential diagnosis. These developments will enable clinical trials at early stages of disease, when new therapies are most likely to be efficacious. Such biomarkers will need to be validated in autopsy-confirmed cases. Tau-sensitive PET imaging is an attractive potential biomarker, but the low affinity of ligands for tau in PSP post-mortem specimens raises concerns about the utility of these tracers, which are not ready for widespread use yet.

Large, multicentre clinical trials have been successfully implemented in patients with PSP-RS, but PSP remains a rare disease. If several tau therapeutic programmes reach late-stage clinical development, there could be insufficient numbers of eligible patients to enrol in large, competing clinical trials. Careful planning and international partnerships involving patients, families, academic and industry researchers, and advocacy groups will be necessary to ensure the success of such studies. Moreover, ensuring that clinical trial results, data, and biospecimens are rapidly shared will also be crucial for advancing therapeutic development.

Contributors

ALB generated the outline, wrote sections of and revised the manuscript, reviewed the medical literature, and edited the figures. J-TY performed literature searches, wrote the first draft, produced the figures, and revised the manuscript. LIG, IL, AEL, and GUH contributed to the discussion, initial draft, and revision of the manuscript. AEL also edited the figures.

Declaration of interests

ALB receives research support from the National Institutes of Health (R01AG038791, U54NS092089), the University of California, the Tau Consortium, CBD Solutions, the Bluefield Project to Cure FTD, the Alzheimer's Association, and the following companies: Avid, Biogen, Bristol-Myers Squibb, C2N Diagnostics, Cortice Biosciences, Eli Lilly, Forum Pharmaceuticals, Genentech, Roche, and TauRx; has served as a consultant for Abbvie, Asceneuron, Celgene, Ionis Pharmaceuticals, Janssen, Merck, and Novartis; serves on a Data and Safety Monitoring Board for Neurogenetics Pharmaceuticals; and has stock in Delos and stock options in Alector. LIG is supported by research funding from Bristol-Myers Squibb, AbbVie, and the American Parkinson's Disease Association; and consults for BMS, AbbVie, SJO Research, and the University of California. IL is supported by the Parkinson Study Group, Michael J Fox Foundation, AVID Pharmaceuticals, C2N Diagnostics/Abbvie, and Bristol-Myers Squibb; was member of the advisory boards for Cynapsus, Lundbeck, Biogen, and Bristol-Myers Squibb; is a member of the Biotie/Parkinson Study Group Medical Advisory Board; and receives her salary from the University of California, San Diego, CA, USA. AEL has served as an advisor for Abbvie, Acorda, Avanir Pharmaceuticals, Bristol-Myers Squibb, Ceregene, Lilly, Merck, and UCB; has received honoraria from Medtronic, Teva, UCB, and AbbVie; has received grants from Brain Canada, Canadian Institutes of Health Research, Edmond J Safra Philanthropic Foundation, Michael J Fox Foundation, the Ontario Brain Institute, National Parkinson Foundation, Parkinson Society Canada, Physicians Services Incorporated (PSI), and W Garfield Weston Foundation; and has received publishing royalties from Saunders, Wiley-Blackwell, Johns Hopkins Press, and Cambridge University Press. GUH has received research support from CurePSP, the German Academic Exchange Service (DAAD), German Centre for Neurodegenerative Diseases (DZNE), German Research Foundation (DFG), German Ministry of Education and Research (BMBF), the Sellas Life Sciences Group, and Neuropore; has served as a consultant for Abbvie, Asceneuron, Bristol-Myers Squibb, Novartis, Roche, and UCB; and has received honoraria for scientific presentations from Abbvie, Roche, Teva, and UCB. J-TY declares no competing interests.

Acknowledgments

ALB is supported by National Institutes of Health (grant numbers. U54NS092089, R01AG038791, and U01AG045390) and the Tau Research Consortium. IL receives support from the US National Institutes of Health (grant nos. P50AG005131, T35HL007491, U01NS086659, and U54NS092089). GUH is funded by the Deutsche Forschungsgemeinschaft (DFG, HO2402/6-2 and Munich Cluster for Systems Neurology SyNergy).

References

- Williams DR, Lees AJ. Progressive supranuclear palsy: clinicopathological concepts and diagnostic challenges. *Lancet Neurol* 2009; **8**: 270–79.
- Steele JC, Richardson JC, Olszewski J. Progressive supranuclear palsy. A heterogeneous degeneration involving the brain stem, basal ganglia and cerebellum with vertical gaze and pseudobulbar palsy, nuchal dystonia and dementia. *Arch Neurol* 1964; **10**: 333–59.
- Lamb R, Rohrer JD, Lees AJ, Morris HR. Progressive supranuclear palsy and corticobasal degeneration: pathophysiology and treatment options. *Curr Treat Options Neurol* 2016; **18**: 42.
- Hoglinger GU, Melhem NM, Dickson DW, et al. Identification of common variants influencing risk of the tauopathy progressive supranuclear palsy. *Nat Genet* 2011; **43**: 699–705.
- Coyle-Gilchrist IT, Dick KM, Patterson K, et al. Prevalence, characteristics, and survival of frontotemporal lobar degeneration syndromes. *Neurology* 2016; **86**: 1736–43.
- Takigawa H, Kitayama M, Wada-Isoe K, Kowa H, Nakashima K. Prevalence of progressive supranuclear palsy in Yonago: change throughout a decade. *Brain Behav* 2016; **6**: e00557.

- 7 Yoshida K, Hata Y, Kinoshita K, Takashima S, Tanaka K, Nishida N. Incipient progressive supranuclear palsy is more common than expected and may comprise clinicopathological subtypes: a forensic autopsy series. *Acta Neuropathol* 2017; **133**: 809–23.
- 8 Caparros-Lefebvre D, Golbe LI, Deramecourt V, et al. A geographical cluster of progressive supranuclear palsy in northern France. *Neurology* 2015; **85**: 1293–300.
- 9 Litvan I, Lees PS, Cunningham CR, et al. Environmental and occupational risk factors for progressive supranuclear palsy: case-control study. *Mov Disord* 2016; **31**: 644–52.
- 10 Hoglinger G, Respondek G, Stamelou M, et al. Clinical diagnosis of progressive supranuclear palsy: The Movement Disorder Society criteria. *Mov Disord* 2017; published online May 3. DOI:10.1002/mds.26987.
- 11 Jack CR Jr, Holtzman DM. Biomarker modeling of Alzheimer's disease. *Neuron* 2013; **80**: 1347–58.
- 12 Berg D, Postuma RB, Adler CH, et al. MDS research criteria for prodromal Parkinson's disease. *Mov Disord* 2015; **30**: 1600–11.
- 13 Dugger BN, Hentz JG, Adler CH, et al. Clinicopathological outcomes of prospectively followed normal elderly brain bank volunteers. *J Neuropathol Exp Neurol* 2014; **73**: 244–52.
- 14 Nogami A, Yamazaki M, Saito Y, et al. Early stage of progressive supranuclear palsy: a neuropathological study of 324 consecutive autopsy cases. *J Nippon Med Sch* 2015; **82**: 266–73.
- 15 Respondek G, Stamelou M, Kurz C, et al. The phenotypic spectrum of progressive supranuclear palsy: a retrospective multicenter study of 100 definite cases. *Mov Disord* 2014; **29**: 1758–66.
- 16 Respondek G, Roeber S, Kretzschmar H, et al. Accuracy of the National Institute for Neurological Disorders and Stroke/Society for Progressive Supranuclear Palsy and neuroprotection and natural history in Parkinson plus syndromes criteria for the diagnosis of progressive supranuclear palsy. *Mov Disord* 2013; **28**: 504–09.
- 17 Williams DR, Lees AJ. What features improve the accuracy of the clinical diagnosis of progressive supranuclear palsy-parkinsonism (PSP-P)? *Mov Disord* 2010; **25**: 357–62.
- 18 Owens E, Josephs KA, Savica R, et al. The clinical spectrum and natural history of pure akinesia with gait freezing. *J Neurol* 2016; **263**: 2419–23.
- 19 Ling H, O'Sullivan SS, Holton JL, et al. Does corticobasal degeneration exist? A clinicopathological re-evaluation. *Brain* 2010; **133**: 2045–57.
- 20 Josephs KA, Duffy JR, Strand EA, et al. The evolution of primary progressive apraxia of speech. *Brain* 2014; **137**: 2783–95.
- 21 Santos-Santos MA, Mandelli ML, Binney RJ, et al. Features of patients with nonfluent/agrammatic primary progressive aphasia with underlying progressive supranuclear palsy pathology or corticobasal degeneration. *JAMA Neurol* 2016; **73**: 733–42.
- 22 Spinelli EG, Mandelli ML, Miller ZA, et al. Typical and atypical pathology in primary progressive aphasia variants. *Ann Neurol* 2017; **81**: 430–43.
- 23 Hassan A, Parisi JE, Josephs KA. Autopsy-proven progressive supranuclear palsy presenting as behavioral variant frontotemporal dementia. *Neurocase* 2012; **18**: 478–88.
- 24 Litvan I, Hauw JJ, Bartko JJ, et al. Validity and reliability of the preliminary NINDS neuropathologic criteria for progressive supranuclear palsy and related disorders. *J Neuropathol Exp Neurol* 1996; **55**: 97–105.
- 25 Koga S, Josephs KA, Ogaki K, et al. Cerebellar ataxia in progressive supranuclear palsy: an autopsy study of PSP-C. *Mov Disord* 2016; **31**: 653–62.
- 26 Kovacs GG, Milenkovic I, Wöhrer A, et al. Non-Alzheimer neurodegenerative pathologies and their combinations are more frequent than commonly believed in the elderly brain: a community-based autopsy series. *Acta Neuropathol* 2013; **126**: 365–84.
- 27 Ling H. Clinical approach to progressive supranuclear palsy. *J Mov Disord* 2016; **9**: 3–13.
- 28 Litvan I, Agid Y, Calne D, et al. Clinical research criteria for the diagnosis of progressive supranuclear palsy (Steele-Richardson-Olszewski syndrome): report of the NINDS-SPSP international workshop. *Neurology* 1996; **47**: 1–9.
- 29 Boxer AL, Garbutt S, Seeley WW, et al. Saccade abnormalities in autopsy-confirmed frontotemporal lobar degeneration and Alzheimer disease. *Arch Neurol* 2012; **69**: 509–17.
- 30 Armstrong MJ, Litvan I, Lang AE, et al. Criteria for the diagnosis of corticobasal degeneration. *Neurology* 2013; **80**: 496–503.
- 31 Gorno-Tempini ML, Hillis AE, Weintraub S, et al. Classification of primary progressive aphasia and its variants. *Neurology* 2011; **76**: 1006–14.
- 32 Rascovsky K, Hodges JR, Knopman D, et al. Sensitivity of revised diagnostic criteria for the behavioural variant of frontotemporal dementia. *Brain* 2011; **134**: 2456–77.
- 33 Kanazawa M, Shimohata T, Toyoshima Y, et al. Cerebellar involvement in progressive supranuclear palsy: a clinicopathological study. *Mov Disord* 2009; **24**: 1312–18.
- 34 Dugger BN, Adler CH, Shill HA, et al. Concomitant pathologies among a spectrum of parkinsonian disorders. *Parkinsonism Relat Disord* 2014; **20**: 525–29.
- 35 Dickson DW, Ahmed Z, Algom AA, Tsuboi Y, Josephs KA. Neuropathology of variants of progressive supranuclear palsy. *Curr Opin Neurol* 2010; **23**: 394–400.
- 36 Ling H, de Silva R, Massey LA, et al. Characteristics of progressive supranuclear palsy presenting with corticobasal syndrome: a cortical variant. *Neuropathol Appl Neurobiol* 2014; **40**: 149–63.
- 37 Clavaguera F, Akatsu H, Fraser G, et al. Brain homogenates from human tauopathies induce tau inclusions in mouse brain. *Proc Natl Acad Sci USA* 2013; **110**: 9535–40.
- 38 Sanders DW, Kaufman SK, DeVos SL, et al. Distinct tau prion strains propagate in cells and mice and define different tauopathies. *Neuron* 2014; **82**: 1271–88.
- 39 Gardner RC, Boxer AL, Trujillo A, et al. Intrinsic connectivity network disruption in progressive supranuclear palsy. *Ann Neurol* 2013; **73**: 603–16.
- 40 Hinze FI, Geschwind DH. Molecular genetics of neurodegenerative dementias. *Cold Spring Harb Perspect Biol* 2016; published online Dec 9. DOI:10.1101/cshperspect.a02370.
- 41 Coppola G, Chinnathambi S, Lee JJ, et al. Evidence for a role of the rare p.A152T variant in MAPT in increasing the risk for FTD-spectrum and Alzheimer's diseases. *Hum Mol Genet* 2012; **21**: 3500–12.
- 42 Donker Kaat L, Boon AJ, Azmani A, et al. Familial aggregation of parkinsonism in progressive supranuclear palsy. *Neurology* 2009; **73**: 98–105.
- 43 Fujioka S, Sanchez Contreras MY, Strongosky AJ, et al. Three sib-pairs of autopsy-confirmed progressive supranuclear palsy. *Parkinsonism Relat Disord* 2015; **21**: 101–05.
- 44 Schoch KM, DeVos SL, Miller RL, et al. Increased 4R-tau induces pathological changes in a human-tau mouse model. *Neuron* 2016; **90**: 941–47.
- 45 Zhao Y, Tseng IC, Heyser CJ, et al. Apoptosis-mediated caspase cleavage of tau contributes to progressive supranuclear palsy pathogenesis. *Neuron* 2015; **87**: 963–75.
- 46 Bruch J, Kurz C, Vasiljevic A, Nicolino M, Arzberger T, Höglinger GU. Early neurodegeneration in the brain of a child without functional PKR-like endoplasmic reticulum kinase. *J Neuropathol Exp Neurol* 2015; **74**: 850–57.
- 47 Massey LA, Micallef C, Paviour DC, et al. Conventional magnetic resonance imaging in confirmed progressive supranuclear palsy and multiple system atrophy. *Mov Disord* 2012; **27**: 1754–62.
- 48 Josephs KA, Whitwell JL, Dickson DW, et al. Voxel-based morphometry in autopsy proven PSP and CBD. *Neurobiol Aging* 2008; **29**: 280–89.
- 49 Min SW, Chen X, Tracy TE, et al. Critical role of acetylation in tau-mediated neurodegeneration and cognitive deficits. *Nat Med* 2015; **21**: 1154–62.
- 50 Yanamandra K, Jiang H, Mahan TE, et al. Anti-tau antibody reduces insoluble tau and decreases brain atrophy. *Ann Clin Transl Neurol* 2015; **2**: 278–88.
- 51 Whitwell JL, Jack CR Jr, Parisi JE, et al. Midbrain atrophy is not a biomarker of progressive supranuclear palsy pathology. *Eur J Neurol* 2013; **20**: 1417–22.
- 52 Morelli M, Arabia G, Novellino F, et al. MRI measurements predict PSP in unclassifiable parkinsonisms: a cohort study. *Neurology* 2011; **77**: 1042–47.
- 53 Massey LA, Jager HR, Paviour DC, et al. The midbrain to pons ratio: a simple and specific MRI sign of progressive supranuclear palsy. *Neurology* 2013; **80**: 1856–61.
- 54 Quattrone A, Morelli M, Williams DR, et al. MR parkinsonism index predicts vertical supranuclear gaze palsy in patients with PSP-parkinsonism. *Neurology* 2016; **87**: 1266–73.

- 55 Dutt S, Binney RJ, Heuer HW, et al. Progression of brain atrophy in PSP and CBS over 6 months and 1 year. *Neurology* 2016; **87**: 2016–25.
- 56 Zhang Y, Walter R, Ng P, et al. Progression of microstructural degeneration in progressive supranuclear palsy and corticobasal syndrome: a longitudinal diffusion tensor imaging study. *PLoS One* 2016; **11**: e0157218.
- 57 Agosta F, Pievani M, Svetel M, et al. Diffusion tensor MRI contributes to differentiate Richardson's syndrome from PSP-parkinsonism. *Neurobiol Aging* 2012; **33**: 2817–26.
- 58 Planetta PJ, Ofori E, Pasternak O, et al. Free-water imaging in Parkinson's disease and atypical parkinsonism. *Brain* 2016; **139**: 495–508.
- 59 Burciu RG, Chung JW, Shukla P, et al. Functional MRI of disease progression in Parkinson disease and atypical parkinsonian syndromes. *Neurology* 2016; **87**: 709–17.
- 60 Zalewski N, Botha H, Whitwell JL, Lowe V, Dickson DW, Josephs KA. FDG-PET in pathologically confirmed spontaneous 4R-tauopathy variants. *J Neurol* 2014; **261**: 710–16.
- 61 Tang CC, Poston KL, Eckert T, et al. Differential diagnosis of parkinsonism: a metabolic imaging study using pattern analysis. *Lancet Neurol* 2010; **9**: 149–58.
- 62 Marquié M, Normandin MD, Vanderburg CR, et al. Validating novel tau positron emission tomography tracer [F-18]-AV-1451 (T807) on postmortem brain tissue. *Ann Neurol* 2015; **78**: 787–800.
- 63 Cho H, Choi JY, Hwang MS, et al. Subcortical 18 F-AV-1451 binding patterns in progressive supranuclear palsy. *Mov Disord* 2017; **32**: 134–40.
- 64 Whitwell JL, Lowe VJ, Tosakulwong N, et al. [18 F]AV-1451 tau positron emission tomography in progressive supranuclear palsy. *Movement Disord* 2017; **32**: 124–33.
- 65 Smith R, Schain M, Nilsson C, et al. Increased basal ganglia binding of 18 F-AV-1451 in patients with progressive supranuclear palsy. *Mov Disord* 2017; **32**: 108–14.
- 66 Hughes LE, Rowe JB, Ghosh BC, Carlyon RP, Plack CJ, Gockel HE. The binaural masking level difference: cortical correlates persist despite severe brain stem atrophy in progressive supranuclear palsy. *J Neurophysiol* 2014; **112**: 3086–94.
- 67 Wagshal D, Sankaranarayanan S, Guss V, et al. Divergent CSF τ alterations in two common tauopathies: Alzheimer's disease and progressive supranuclear palsy. *J Neurol Neurosurg Psychiatry* 2015; **86**: 244–50.
- 68 Hall S, Öhrfelt A, Constantinescu R, et al. Accuracy of a panel of 5 cerebrospinal fluid biomarkers in the differential diagnosis of patients with dementia and/or parkinsonian disorders. *Arch Neurol* 2012; **69**: 1445–52.
- 69 Scherling CS, Hall T, Berisha F, et al. Cerebrospinal fluid neurofilament concentration reflects disease severity in frontotemporal degeneration. *Ann Neurol* 2014; **75**: 116–26.
- 70 Boxer AL, Lang AE, Grossman M, et al, for the AL-108-231 Investigators. Davunetide in patients with progressive supranuclear palsy: a randomised, double-blind, placebo-controlled phase 2/3 trial. *Lancet Neurol* 2014; **13**: 676–85.
- 71 Bacioglu M, Maia LF, Preische O, et al. Neurofilament light chain in blood and CSF as marker of disease progression in mouse models and in neurodegenerative diseases. *Neuron* 2016; **91**: 56–66.
- 72 Magdalino NK, Paterson RW, Schott JM, et al. A panel of nine cerebrospinal fluid biomarkers may identify patients with atypical parkinsonian syndromes. *J Neurol Neurosurg Psychiatry* 2015; **86**: 1240–47.
- 73 Hansson O, Janelidze S, Hall S, et al. Blood-based NfL: a biomarker for differential diagnosis of parkinsonian disorder. *Neurology* 2017; **88**: 930–37.
- 74 Rojas JC, Karydas A, Bang J, et al. Plasma neurofilament light chain predicts progression in progressive supranuclear palsy. *Ann Clin Transl Neurol* 2016; **3**: 216–25.
- 75 Bologna M, Agostino R, Gregori B, et al. Voluntary, spontaneous and reflex blinking in patients with clinically probable progressive supranuclear palsy. *Brain* 2009; **132**: 502–10.
- 76 Schneider M, Müller HP, Lauda F, et al. Retinal single-layer analysis in Parkinsonian syndromes: an optical coherence tomography study. *J Neural Transm* 2014; **121**: 41–47.
- 77 Walsh CM, Ruoff L, Varbel J, et al. Rest-activity rhythm disruption in progressive supranuclear palsy. *Sleep Med* 2016; **22**: 50–56.
- 78 Ling H, Massey LA, Lees AJ, Brown P, Day BL. Hypokinesia without decrement distinguishes progressive supranuclear palsy from Parkinson's disease. *Brain* 2012; **135**: 1141–53.
- 79 Dani M, Brooks DJ, Edison P. Tau imaging in neurodegenerative diseases. *Eur J Nucl Med Mol Imaging* 2016; **43**: 1139–50.
- 80 Ono M, Sahara N, Kumata K, et al. Distinct binding of PET ligands PBB3 and AV-1451 to tau fibril strains in neurodegenerative tauopathies. *Brain* 2017; **140**: 764–80.
- 81 Chen AL, Riley DE, King SA, et al. The disturbance of gaze in progressive supranuclear palsy: implications for pathogenesis. *Front Neurol* 2010; **1**: 147.
- 82 Clerici I, Ferrazzoli D, Maestri R, et al. Rehabilitation in progressive supranuclear palsy: effectiveness of two multidisciplinary treatments. *PLoS One* 2017; **12**: e0170927.
- 83 Apetauerova D, Scala SA, Hamill RW, et al. CoQ10 in progressive supranuclear palsy: a randomized, placebo-controlled, double-blind trial. *Neurol Neuroimmunol Neuroinflamm* 2016; **3**: e266.
- 84 Khanna MR, Kovalevich J, Lee VM, Trojanowski JQ, Brunden KR. Therapeutic strategies for the treatment of tauopathies: hopes and challenges. *Alzheimers Dement* 2016; **12**: 1051–65.
- 85 Gauthier S, Feldman HH, Schneider LS, et al. Efficacy and safety of tau-aggregation inhibitor therapy in patients with mild or moderate Alzheimer's disease: a randomised, controlled, double-blind, parallel-arm, phase 3 trial. *Lancet* 2016; **388**: 2873–84.
- 86 Bright J, Hussain S, Dang V, et al. Human secreted tau increases amyloid-beta production. *Neurobiol Aging* 2015; **36**: 693–709.
- 87 Villeda SA, Plambeck KE, Middeldorp J, et al. Young blood reverses age-related impairments in cognitive function and synaptic plasticity in mice. *Nat Med* 2014; **20**: 659–63.
- 88 Yuzwa SA, Shan X, Macauley MS, et al. Increasing O-GlcNAc slows neurodegeneration and stabilizes tau against aggregation. *Nat Chem Biol* 2012; **8**: 393–99.
- 89 DeVos SL, Miller RL, Schoch KM, et al. Tau reduction prevents neuronal loss and reverses pathological tau deposition and seeding in mice with tauopathy. *Sci Transl Med* 2017; **9**: eaag0481.
- 90 Stamelou M, Reuss A, Pilatus U, et al. Short-term effects of coenzyme Q10 in progressive supranuclear palsy: a randomized, placebo-controlled trial. *Mov Disord* 2008; **23**: 942–49.
- 91 Scelzo E, Lozano AM, Hamani C, et al. Pedunculopontine nucleus stimulation in progressive supranuclear palsy: a randomised trial. *J Neurol Neurosurg Psychiatry* 2017; published online Feb 15. DOI:10.1136/jnnp-2016-315192.
- 92 Tsai RM, Boxer AL. Clinical trials: past, current, and future for atypical Parkinsonian syndromes. *Semin Neurol* 2014; **34**: 225–34.
- 93 Bensimon G, Ludolph A, Agid Y, Vidailhet M, Payan C, Leigh PN, for the NNIPPS Study Group. Riluzole treatment, survival and diagnostic criteria in Parkinson plus disorders: the NNIPPS study. *Brain* 2009; **132**: 156–71.
- 94 Tolosa E, Litvan I, Höglinger GU, et al. A phase 2 trial of the GSK-3 inhibitor tideglusib in progressive supranuclear palsy. *Mov Disord* 2014; **29**: 470–78.
- 95 Yanamandra K, Kfoury N, Jiang H, et al. Anti-tau antibodies that block tau aggregate seeding in vitro markedly decrease pathology and improve cognition in vivo. *Neuron* 2013; **80**: 402–14.
- 96 Kondo A, Shahpasand K, Mannix R, et al. Antibody against early driver of neurodegeneration cis P-tau blocks brain injury and tauopathy. *Nature* 2015; **523**: 431–36.
- 97 Pedersen JT, Sigurdsson EM. Tau immunotherapy for Alzheimer's disease. *Trends Mol Med* 2015; **21**: 394–402.
- 98 Vossel KA, Zhang K, Brodbeck J, et al. Tau reduction prevents A β -induced defects in axonal transport. *Science* 2010; **330**: 198.
- 99 Asai H, Ikezu S, Tsunoda S, et al. Depletion of microglia and inhibition of exosome synthesis halt tau propagation. *Nat Neurosci* 2015; **18**: 1584–93.
- 100 Bhaskar K, Konerth M, Kokiko-Cochran ON, Cardona A, Ransohoff RM, Lamb BT. Regulation of tau pathology by the microglial fractalkine receptor. *Neuron* 2010; **68**: 19–31.
- 101 Gentry EG, Henderson BW, Arrant AE, et al. Rho kinase inhibition as a therapeutic for progressive supranuclear palsy and corticobasal degeneration. *J Neurosci* 2016; **36**: 1316–23.
- 102 Hampton DW, Webber DJ, Bilican B, Goedert M, Spillantini MG, Chandran S. Cell-mediated neuroprotection in a mouse model of human tauopathy. *J Neurosci* 2010; **30**: 9973–83.