

## **UC Davis**

### **UC Davis Previously Published Works**

#### **Title**

Interaction between Alzheimer's Disease and Cerebral Small Vessel Disease: A Review Focused on Neuroimaging Markers

#### **Permalink**

<https://escholarship.org/uc/item/4892h828>

#### **Journal**

International Journal of Molecular Sciences, 23(18)

#### **ISSN**

1661-6596

#### **Authors**

Kim, Si Eun

Kim, Hee Jin

Jang, Hyemin

et al.

#### **Publication Date**

2022

#### **DOI**

10.3390/ijms231810490

Peer reviewed



Review

# Interaction between Alzheimer's Disease and Cerebral Small Vessel Disease: A Review Focused on Neuroimaging Markers

Si Eun Kim <sup>1,2,3,4</sup>, Hee Jin Kim <sup>1,2,3</sup>, Hyemin Jang <sup>1,2,3</sup>, Michael W. Weiner <sup>5</sup>, Charles DeCarli <sup>6</sup>, Duk L. Na <sup>1,2,3,7,8</sup>  
and Sang Won Seo <sup>1,2,3,9,10,\*</sup>

- <sup>1</sup> Department of Neurology, Samsung Medical Center, Sungkyunkwan University School of Medicine, Seoul 06351, Korea
  - <sup>2</sup> Neuroscience Center, Samsung Medical Center, Seoul 06351, Korea
  - <sup>3</sup> Samsung Alzheimer Research Center, Samsung Medical Center, Seoul 06351, Korea
  - <sup>4</sup> Department of Neurology, Inje University College of Medicine, Haeundae Paik Hospital, Busan 48108, Korea
  - <sup>5</sup> Center for Imaging of Neurodegenerative Diseases, University of California, San Francisco, CA 94121, USA
  - <sup>6</sup> Department of Neurology and Center for Neuroscience, University of California, Davis, CA 95616, USA
  - <sup>7</sup> Department of Health Sciences and Technology, Samsung Advanced Institute for Health Sciences and Technology (SAIHST), Sungkyunkwan University, Seoul 06355, Korea
  - <sup>8</sup> Stem Cell and Regenerative Medicine Institute, Samsung Medical Center, Seoul 06351, Korea
  - <sup>9</sup> Department of Clinical Research Design and Evaluation, SAIHST, Sungkyunkwan University, Seoul 06355, Korea
  - <sup>10</sup> Center for Clinical Epidemiology, Samsung Medical Center, Seoul 06351, Korea
- \* Correspondence: sangwonseo@empas.com; Tel.: +82-2-3410-1233



**Citation:** Kim, S.E.; Kim, H.J.; Jang, H.; Weiner, M.W.; DeCarli, C.; Na, D.L.; Seo, S.W. Interaction between Alzheimer's Disease and Cerebral Small Vessel Disease: A Review Focused on Neuroimaging Markers. *Int. J. Mol. Sci.* **2022**, *23*, 10490. <https://doi.org/10.3390/ijms231810490>

Academic Editor: Isidro Ferrer

Received: 4 July 2022

Accepted: 7 September 2022

Published: 10 September 2022

**Publisher's Note:** MDPI stays neutral with regard to jurisdictional claims in published maps and institutional affiliations.



**Copyright:** © 2022 by the authors. Licensee MDPI, Basel, Switzerland. This article is an open access article distributed under the terms and conditions of the Creative Commons Attribution (CC BY) license (<https://creativecommons.org/licenses/by/4.0/>).

**Abstract:** Alzheimer's disease (AD) is characterized by the presence of  $\beta$ -amyloid ( $A\beta$ ) and tau, and subcortical vascular cognitive impairment (SVCI) is characterized by cerebral small vessel disease (CSVD). They are the most common causes of cognitive impairment in the elderly population. Concurrent CSVD burden is more commonly observed in AD-type dementia than in other neurodegenerative diseases. Recent developments in  $A\beta$  and tau positron emission tomography (PET) have enabled the investigation of the relationship between AD biomarkers and CSVD in vivo. In this review, we focus on the interaction between AD and CSVD markers and the clinical effects of these two markers based on molecular imaging studies. First, we cover the frequency of AD imaging markers, including  $A\beta$  and tau, in patients with SVCI. Second, we discuss the relationship between AD and CSVD markers and the potential distinct pathobiology of AD markers in SVCI compared to AD-type dementia. Next, we discuss the clinical effects of AD and CSVD markers in SVCI, and hemorrhagic markers in cerebral amyloid angiopathy. Finally, this review provides both the current challenges and future perspectives for SVCI.

**Keywords:** subcortical vascular cognitive impairment; Alzheimer's disease;  $\beta$ -Amyloid; tau; cerebral small vessel disease; interaction; positron emission tomography

## 1. Introduction

Dementia is a progressive and deteriorative syndrome that affects memory and other cognitive domains, which interferes with a daily living [1]. Alzheimer's disease (AD) and vascular dementia (VaD) are the two most common causes of dementia in the elderly [2]. AD is characterized by senile plaques formed by  $\beta$ -amyloid ( $A\beta$ ) and neurofibrillary tangles (NFTs) formed by hyperphosphorylated tau. These changes, along with loss of neurons, contribute to the symptoms of dementia [3]. Based on these core AD pathological features, including  $A\beta$  [A], tau [T], and neurodegeneration [N] biomarkers, the National Institute on Aging—Alzheimer's Association (NIA-AA) proposed the AT(N) classification system [4]. A and T biomarkers are specific for the  $A\beta$  plaques and tau NFTs that constitute the hallmark neuropathologic signs of AD, respectively, while biomarkers of (N) (such as atrophy on magnetic resonance imaging, MRI) are not disease specific [4,5]. Brain atrophy is indicative

of the considerable loss of neurons and synapses in the cerebral cortex [6]. Although the assessment of atrophy lacks specificity to determine whether the cause is cell loss or synaptic loss, cortical thickness is widely used as a surrogate marker for neuronal loss [7,8]. The NIA-AA research framework defines AD biologically based on neuropathologic change or biomarkers and considers cognitive impairment a symptom or sign of the disease rather than the definition of the disease [4].

Further, Alzheimer's disease is frequently associated with other aging-related disorders such as cerebrovascular disease, Lewy body disease, transactive response DNA-binding protein of 43 kDa (TDP-43) proteinopathies, and argyrophilic grain disease [6]. AD pathology mixed with vascular disease is more frequent in the elderly population (also known as mixed pathology in dementia or mixed dementia) [9]. Vascular diseases include arteriosclerosis, cerebral amyloid angiopathy (CAA), atherosclerosis, macroinfarcts, and microinfarcts [10]. In fact, previous studies have shown that AD combined with vascular disease is the most prevalent mixed pathology [9,11,12].

Vascular dementia is caused by ischemic or hemorrhagic brain lesions that are characterized by numerous clinical syndromes [13]. The most common forms of VaD in the elderly are subcortical vascular dementia (SVaD), strategic infarct dementia, and multi-infarct dementia [14]. VaD is generally known to be the second most common cause of dementia in later life among Caucasian populations, although it may be the most common cause in East Asia [15–17]. SVaD, one of the main forms of VaD, is characterized by extensive cerebral small vessel disease (CSVD), including white matter hyperintensities (WMHs) and multiple lacunes [18]. Vascular risk factors, such as age, hypertension, and diabetes mellitus, contribute to the development of CSVD MRI markers. These markers gradually form deposits in subcortical regions over several decades, eventually resulting in SVaD [19]. Thus, SVaD shows a progression pattern similar to that of AD, which reveals an insidious onset and gradual progression; however, it is dissimilar to that of multi-infarct dementia (another major form of vascular dementia). From this perspective, there is a prodromal state of SVaD, referred to as subcortical vascular mild cognitive impairment (svMCI). Subcortical vascular cognitive impairment (SVCi), which incorporates SVaD and svMCI, refers to cognitive impairment caused by subcortical vascular lesions [20–24].

AD-related cognitive impairment (ADCI) and SVCi are considered to lie on opposite ends of a single disease spectrum, where ADCI with non-ischemia lies at one end and SVCi without AD pathology lies at the other end [25]. One of the main reasons is that these two types of dementia share risk factors, such as age, hypertension, and diabetes [26]. In fact, these risk factors are known to be associated with AD-type dementia as well as SVCi [27]. The other reason is based on previous studies suggesting a strong association between AD and CSVD burden [28,29]. Several pathological studies have shown an overlap between AD and CSVD burden and their association with dementia. In particular, concurrent CSVD burdens are more commonly observed in AD-type dementia than in other neurodegenerative diseases [30]. AD dementia can develop in the presence of CSVD lesions [31]. Among patients with dementia, 38.0% (19/50) have AD and infarcts, 30.0% (15/50) have pure AD, and 12% (6/50) have vascular dementia [9]. The association between AD and CSVD could be explained by the possibility that CSVD hampers the clearance of A $\beta$  [32–34].

In most dementia cases, lesions are pathologically identified after death. Therefore, we do not have exact information on the patients when they were at earlier stages. However, with advancements in molecular imaging, AD biomarkers have been detected in living AD patients at earlier stages of dementia. Abnormal levels of AD imaging markers can be quantified with specific positron emission tomography (PET) tracers, such as <sup>11</sup>C-Pittsburgh Compound-B (PiB) [35], <sup>18</sup>F-florbetapir [36], <sup>18</sup>F-flutemetamol [37], and <sup>18</sup>F-florbetaben [38] for A $\beta$ , and <sup>18</sup>F-flortaucipir (AV-1451) [39], <sup>18</sup>FMK-6240 [40], <sup>18</sup>F-PI-2620 [41], and <sup>18</sup>F-RO-948 PET [42] for tau. Specifically, compared to cognitively normal individuals, patients with AD-type dementia show higher A $\beta$  uptakes in the brain [35]. Furthermore, 20–30% of cognitively normal individuals and 40–60% of individuals with mild cognitive impairment

(MCI) both show A $\beta$  positivity on PET [43,44]. According to a previous study, tau PET positivity in the temporal region has been shown to be 6.1% for cognitively normal individuals, 46.5% for MCI, and 88.6% for AD-type dementia [45]. Tracers for paired helical filament tau have also been reported to correspond to Braak's pathological NFT stage and to be correlated with disease severity and symptom progression [46–48]. However, compared to AD, there has been relatively little interest in research using molecular imaging for SVCI.

In this review, we discuss the interaction between AD and CSVD biomarkers and the clinical effects of these two biomarkers using molecular imaging studies. More specifically, we discuss the following topics: (1) the frequency of AD imaging markers, including A $\beta$  and tau in SVCI patients; (2) the relationship between AD markers and CSVD burdens; (3) potential distinct pathobiology of AD markers in SVCI compared to AD-type dementia; (4) the clinical effects of AD and CSVD markers in SVCI; (5) hemorrhagic markers in CAA and the clinical effects; and (6) current challenges and future perspectives.

## 2. Imaging Markers of Alzheimer's Disease (AD) and Cerebral Small Vessel Disease (CSVD) in Subcortical Vascular Cognitive Impairment (SVCI)

### 2.1. Frequency of AD Imaging Markers in SVCI

AD markers are more commonly observed in patients with SVCI than in cognitively unimpaired individuals. Specifically, in svMCI patients, the frequencies of A $\beta$  positivity have been reported to be about 30% [25,29,49]. SVaD patients tend to display more frequent A $\beta$  positivity than svMCI patients, ranging from 30% to 53% [25,50,51]. In terms of the tau marker, it has been shown that tau positivity is 70% (14/20) in A $\beta$  (+) ADCI patients, 25.9% (7/27) in A $\beta$  (+) SVCI patients, and 6.1% (2/33) in A $\beta$  (–) SVCI patients. [52].

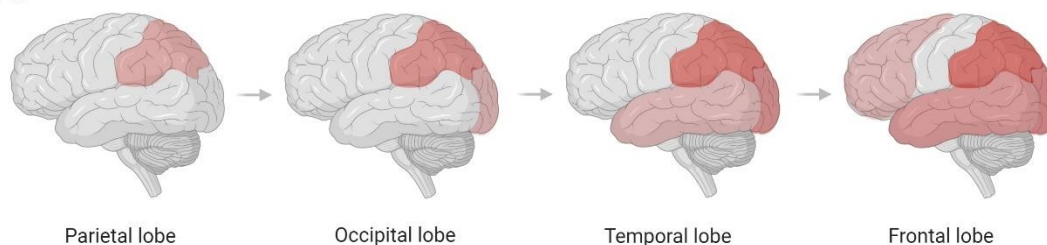
### 2.2. Correlation between AD and CSVD Imaging Markers

Molecular imaging studies have enabled us to investigate the relationship between AD markers and CSVD MRI markers throughout the whole brain. There is increasing evidence from these studies showing that AD marker uptake is correlated with WMH volume, which is a characteristic MRI marker of CSVD. This has been observed prominently in the posterior regions of the brain. In our previous study of 53 SVCI patients, a relationship between A $\beta$  uptake and WMH volume was observed in *APOE4* non-carriers [53]. WMH volume is correlated with A $\beta$  uptake in the posterior cerebral regions. Another study using clustering analyses classified SVCI patients and AD patients into the A $\beta$  occipital-predominant and A $\beta$  occipital-sparing groups. The frequency of the occipital-predominant group has been shown to be higher in SVCI patients (62.2%) than in AD patients (37.8%) [33]. Furthermore, the A $\beta$  spreading pattern in patients with SVCI is quite different from in patients with ADCI. Specifically, the A $\beta$  spreading pattern of patients with SVCI demonstrates that A $\beta$  accumulates in the occipital area before the temporal and frontal regions, whereas in patients with ADCI, the parietal and fronto-temporal regions precede the occipital region. (Figure 1a) [33,54–57]. The predominant A $\beta$  deposition in the occipital region, mainly observed in patients with SVCI, may be related to the distribution pattern of CAA or ischemic vulnerability of the posterior circulation [53]. CAA is primarily found in the occipital region [53,58]. Moreover, ischemic injury and dysfunction of the endothelial layer may lead to disruption of the blood–brain barrier (BBB), which in turn leads to the deposition of A $\beta$ . Since the vertebrobasilar system, which is responsible for the posterior circulation, may be vulnerable to ischemia, SVCI patients may show A $\beta$  deposition primarily in the posterior region [53]. Figure 1a illustrates the spreading pattern of A $\beta$  in AD, compared with that in SVCI. Interestingly, the A $\beta$  spreading pattern in patients with ADCI developed using molecular imaging evidence seems to be different from that based on pathological studies. That is, a pathologic study conducted by Braak and Braak showed an early pattern of A $\beta$  deposits in the basal parts of the frontal, temporal, and occipital lobes (Stage A) [46,59]. However, several molecular imaging studies suggest that there are diverse early A $\beta$  accumulating regions such as the precuneus, posterior cingulate, isthmus cingulate, insula, and

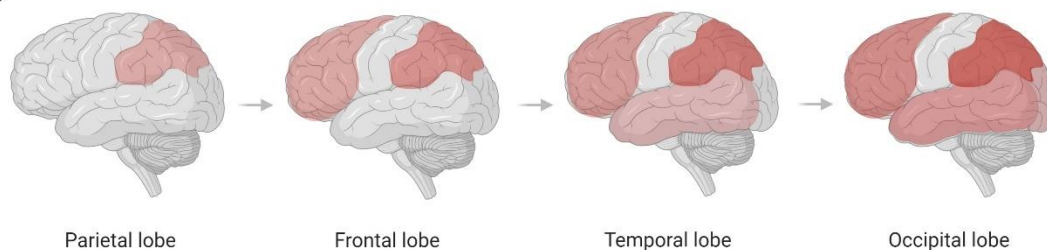
medial and lateral orbitofrontal cortices, in which several of the core regions of the default mode network are located [60–62].

## a. A $\beta$

### a-1. SVCI

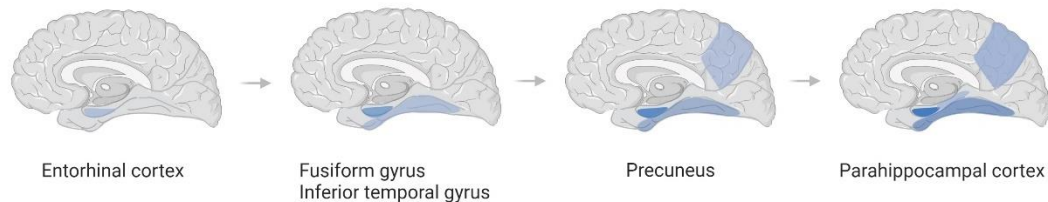


### a-2. AD

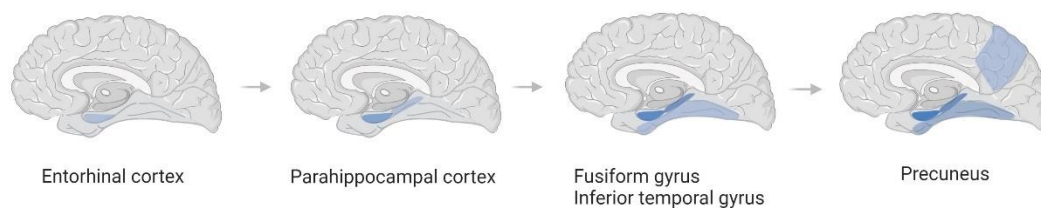


## b. Tau

### b-1. SVCI



### b-2. AD



**Figure 1.** Spreading order of A $\beta$  and tau in SVCI and AD, respectively. (a) Spreading pattern of A $\beta$  in SVCI (a-1) and AD (a-2); (b) Spreading pattern of tau in SVCI (b-1) and AD (b-2). In the order of spreading A $\beta$  in SVCI, unlike AD, A $\beta$  accumulates in the occipital area before the temporal and frontal regions. In contrast to AD, tau accumulates in the fusiform gyrus and inferior temporal gyrus before the parahippocampal cortex in SVCI patients. A $\beta$ — $\beta$ -amyloid; SVCI—subcortical vascular cognitive impairment; AD—Alzheimer’s disease.

In terms of the relationship between CSVD and tau, previous studies have suggested that ischemia might increase tau burdens regardless of the amyloid pathway [63]. Animal studies have also shown an association between increased cerebrovascular pathology and tau formation [64]. In vivo imaging studies have shown that CSVD burden may be associated with higher tau accumulation in the inferior temporal regions regardless of A $\beta$  positivity [65]. Furthermore, in terms of tau spreading order, patients with SVCI are quite different from patients with ADCI. Unlike in ADCI, tau accumulates earlier in the



fusiform gyrus and inferior temporal gyrus than in the parahippocampal cortex in SVCI (Figure 1b) [65,66].

### 2.3. Potential Distinct Pathobiology of AD Markers in SVCI

Considering that SVCI and ADCI patients show different spreading patterns of AD imaging markers, there may be differences in the potential pathobiology of AD biomarkers between SVCI and ADCI patients. In patients with SVCI, vascular risk factors may lead to A $\beta$  deposition. Several cohort studies have reported an association between vascular risk factors and A $\beta$  deposition (Table 1) [67–72]. This A $\beta$  deposition is increased by impaired A $\beta$  clearance via a deficit in perivascular drainage of A $\beta$  and breakdown of the BBB (Figure 2) [73,74]. BBB breakdown causes faulty transport of A $\beta$  through reduced levels of low-density lipoprotein receptor-related protein 1 (LRP1) and increased levels of receptor for advanced glycation end products (RAGE). These changes eventually lead to impaired clearance of toxic A $\beta$  species [75,76]. Furthermore, A $\beta$  accelerates the tau hyperphosphorylation by mediating the activation of protein kinases, including cyclin-dependent kinase 5 (CDK-5) and glycogen synthase kinase 3 $\beta$  (GSK-3 $\beta$ ) [77,78]. In addition, A $\beta$  induces the activation of caspase-3 and calpain-1 and the cleavage of tau, generating neurotoxic tau fragments (Figure 2) [79,80]. The link between A $\beta$  and tau aggregation may involve microglial activation [81]. Soluble A $\beta$  oligomers are known to activate microglial cells [82]. Mouse studies on transgenic AD have revealed that the microglial activation precedes tau aggregation [83] and facilitates tau hyperphosphorylation through cytokine release with subsequent NFT formation [84]. There are two potential mechanisms that may explain how vascular risk factors induce tau accumulation. One hypothesis is that ischemia may activate CDK-5 and GSK-3 $\beta$ , resulting in tau phosphorylation [85]. Activation of CDK-5 occurs when ischemia inhibits the pumping of calcium ions out of cells and raises intracellular calcium levels [86,87]. GSK-3 $\beta$  is activated by ischemia through decreased activity of the phosphatidylinositol 3-kinase/Akt pathway [88,89]. Moreover, vascular risk factors and the accumulation of A $\beta$  plaques lead to oxidative stress [90–92]. Oxidative stress may also be caused by several mechanisms, such as mitochondrial dysfunction or inflammatory responses [92]. It may manifest as damage to synapses and changes in Ca<sup>2+</sup> homeostasis, resulting in an apoptotic cascade and neurotoxicity [92] (Figure 2).

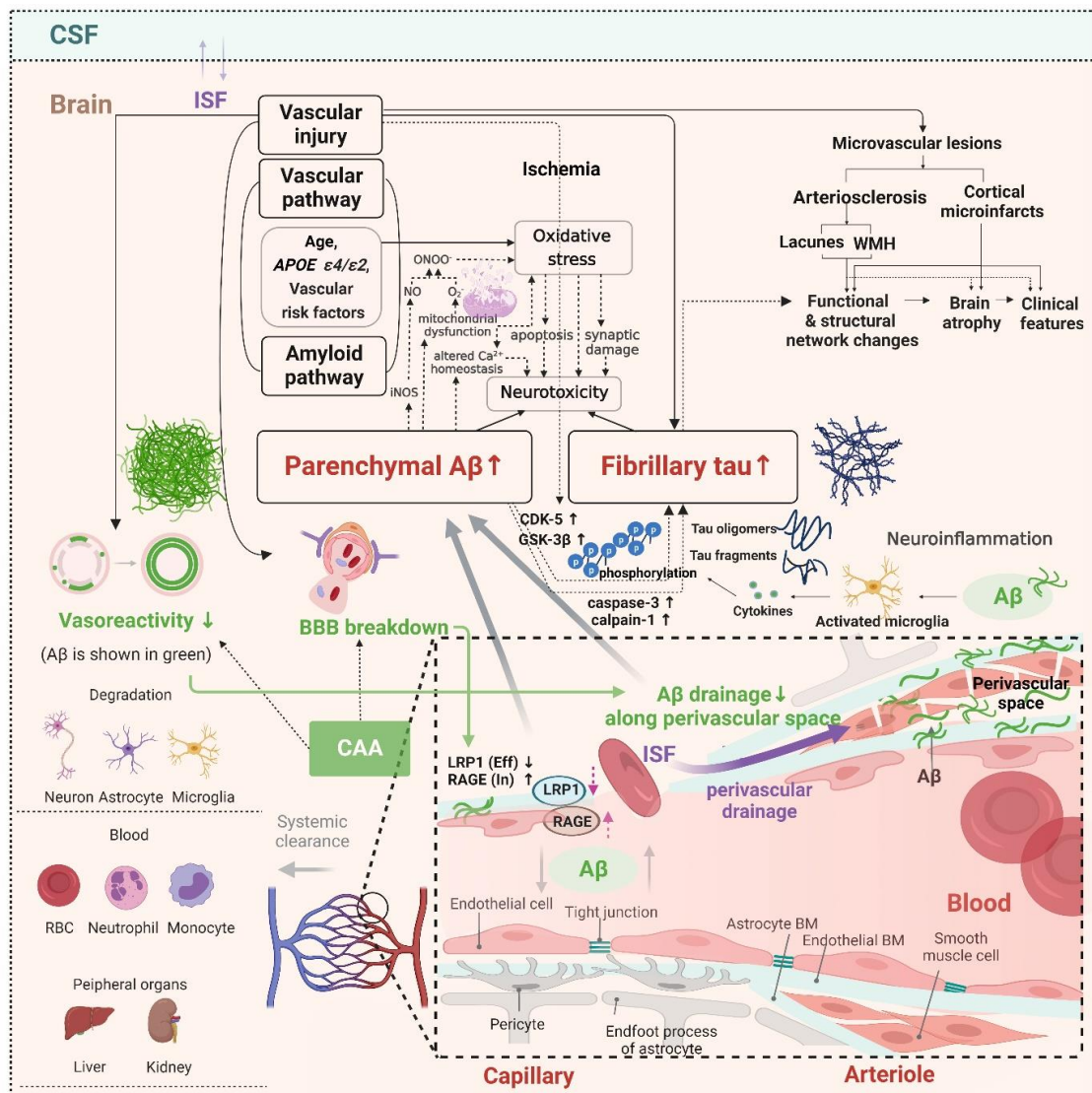
**Table 1.** Cohort studies investigating the association between vascular risk factors and brain  $\beta$ -amyloid deposition.

Study (Country)	Length of the Study	Number of Study Participants (Age, Mean [SD])	Vascular Risk Factors	Measurement of Brain $\beta$ -Amyloid Load	Results
Gottesman et al. (2017) (USA) [67]	Evaluation of vascular risk factors since 1987–1989 with <sup>18</sup> F-florbetapir PET scans in 2011–2013	322 without dementia (27% MCI) (75.8 [5.3])	HTN, DM, BMI $\geq$ 30, TC $\geq$ 200 mg/dL, current smoking status	<sup>18</sup> F-florbetapir PET (SUVR)	(1) Association between elevated BMI in midlife and elevated SUVR (OR: 2.06, 95% CI: 1.16–3.65) (2) OR for elevated SUVR and 1 vascular risk factor: 1.88 (95% CI: 0.95–3.72), OR for elevated SUVR and 2 or more vascular risk factors: 2.88 (95% CI: 1.46–5.69)
Hughes et al. (2018) (USA) [68]	Evaluation of vascular risk factors since 1987–1989 with <sup>18</sup> F-florbetapir PET scans in 2011–2013	321 (27% MCI) (76 [5])	Arterial stiffness by pulse wave velocity (PWV, carotid-femoral [cfPWV] and heart-carotid [hcPWV])	<sup>18</sup> F-florbetapir PET (SUVR)	(1) Association between greater central stiffness (hcPWV) and greater A $\beta$ deposition (OR: 1.31, 95% CI: 1.01–1.7) (2) Association between cfPWV and a higher odds of A $\beta$ -positive scans (OR: 1.4, 95% CI: 1.1–2.1).

Table 1. Cont.

Study (Country)	Length of the Study	Number of Study Participants (Age, Mean [SD])	Vascular Risk Factors	Measurement of Brain $\beta$ -Amyloid Load	Results
Rabin et al. (2018) (USA) [69]	7 years	223 clinically normal older adults (73.7 [6.0])	Framingham Heart Study general cardiovascular disease (FHS-CVD) risk score (age, sex, antihypertensive treatment, SBP, BMI, history of DM, and current cigarette smoking status)	$^{11}\text{C}$ -PiB PET (DVR)	(1) Associations of a higher FHS-CVD risk score ( $\beta = -0.064$ ; $-0.094$ to $-0.033$ ; $p < 0.001$ ) and higher A $\beta$ burden ( $\beta = -0.058$ ; $-0.079$ to $-0.037$ ; $p < 0.001$ ) with faster cognitive decline (2) Synergistic effect of FHS-CVD risk factors and A $\beta$ burden ( $\beta = -0.040$ , 95% CI: $-0.062$ to $-0.018$ ; $p < 0.001$ )
Arfanakis et al. (2020) (USA) [70]	25 years	603 (No cognitive impairment: 178, MCI: 154, dementia: 271) (age at death: 90 [7]; No cognitive impairment: 88 [7], MCI: 90 [6], dementia: 90 [7])	HTN, DM, smoking, history of heart disease	Neuropathologic examination	Association between WMH burden and both vascular and Alzheimer's pathologies (arteriolosclerosis ( $p < 10^{-4}$ ), gross ( $p < 10^{-4}$ ) and microscopic infarcts ( $p = 0.04$ ), A $\beta$ plaques ( $p = 0.028$ ))
Kobe et al. (2020) (Canada) [71]	7 years	215 participants (PREVENT-AD cohort of cognitively unimpaired individuals) (62.3 [5.0])	TC, HDL, LDL cholesterol levels, SBP, DBP, pulse pressure, Framingham Coronary Risk Profile (age, sex, SBP, DBP, HDL, LDL, smoking, DM)	$^{18}\text{F}$ -NAV 4694 PET (SUVR)	Association of vascular risk factors with A $\beta$ burden but not tau burden (only among individuals who were not using vascular medications) TC level ( $\beta = -0.002$ [SE, 0.001]; $p = 0.02$ ), LDL cholesterol level ( $\beta = -0.002$ [SE, 0.001]; $p = 0.006$ ), SBP ( $\beta = -0.006$ [SE, 0.002]; $p = 0.02$ ), pulse pressure ( $\beta = -0.007$ [SE, 0.002]; $p = 0.004$ ), and Framingham Coronary Risk Profile score ( $\beta = -0.038$ [SE, 0.011]; $p = 0.001$ )
Lockhart et al. (2022) (USA) [72]	19 years (enrollment, 2000–2002; 1 <sup>st</sup> cognitive abilities screening, 2010–2012; 2 <sup>nd</sup> screening, 2016–2018)	159 participants (49.7% African-American, 50.3% White) (baseline age 55.8 [6.7])	FSRP, CAIDE, ASCVD (All vascular risk factor scores include age, sex, SBP); FSRP, ASCVD (DM, antihypertensive treatment, smoking); CAIDE, ASCVD (TC)	$^{11}\text{C}$ -PiB PET (SUVR)	Association of higher baseline Framingham stroke risk profile (FSRP) ( $p = 0.014$ ) and Cardiovascular Risk Factors, Aging, and Incidence of Dementia (CAIDE) scores ( $p = 0.004$ ) with global brain A $\beta$

Abbreviations: Standard Deviation—SD; MCI—mild cognitive impairment; HTN—hypertension; DM—diabetes mellitus; BMI—body mass index; TC—total cholesterol; LDL—low-density lipoprotein; SUVR—standardized uptake value ratio; OR—odds ratio; SBP—systolic blood pressure; DBP—diastolic blood pressure; A $\beta$ — $\beta$ -amyloid; DVR—distribution volume ratio; WMH—white matter hyperintensity; PREVENT-AD—Presymptomatic Evaluation of Experimental or Novel Treatments for Alzheimer Disease; FSRP—Framingham stroke risk profile; CAIDE—Cardiovascular risk factors, aging and incidence of dementia risk score; ASCVD—Atherosclerotic cardiovascular disease risk estimate from the pooled cohort equation.



**Figure 2.** Potential mechanism of Aβ and tau deposition in SVCI. The CSVD burden is associated with Aβ and tau deposition in SVCI. Ischemic events can lead to Aβ deposition by reducing Aβ clearance via BBB breakdown or deficits in perivascular drainage of Aβ from the brain interstitial fluid. BBB breakdown causes faulty transport of Aβ by reducing LRP1 levels and increasing RAGE levels, resulting in impaired clearance of toxic Aβ species. Aβ accelerates the tau hyperphosphorylation by mediating the activation of protein kinases, including CDK-5 and GSK-3β. In addition, Aβ induces the activation of caspase-3 and calpain-1, and the cleavage of tau generates neurotoxic tau fragments. The association between Aβ and tau aggregation may involve microglial activation. Soluble Aβ oligomers have been known to activate microglial cells. Microglial activation precedes tau aggregation and facilitates tau hyperphosphorylation through cytokine release and the subsequent NFT formation. Vascular risk factors can also induce tau accumulation. Ischemia caused by vascular injury may activate CDK-5 and GSK-3β, resulting in tau phosphorylation. Moreover, vascular risk factors and the accumulation of Aβ plaques lead to oxidative stress. Oxidative stress may also be caused by several mechanisms, such as mitochondrial dysfunction or inflammatory responses. It may manifest as damage to synapses and changes in Ca<sup>2+</sup> homeostasis, resulting in an apoptotic cascade and neurotoxicity. CSVD—cerebral small vessel disease; Aβ—β-amyloid; BBB—blood–brain barrier; LRP1—low-density lipoprotein receptor-related protein 1; RAGE—receptor for advanced glycosylation end products; CDK-5—cyclin-dependent kinase 5; GSK-3β—glycogen synthase kinase 3β; NFTs—neurofibrillary tangles; ISF—interstitial fluid; CSF—cerebrospinal fluid; WMH—white matter hyperintensity; BM—basement membrane.



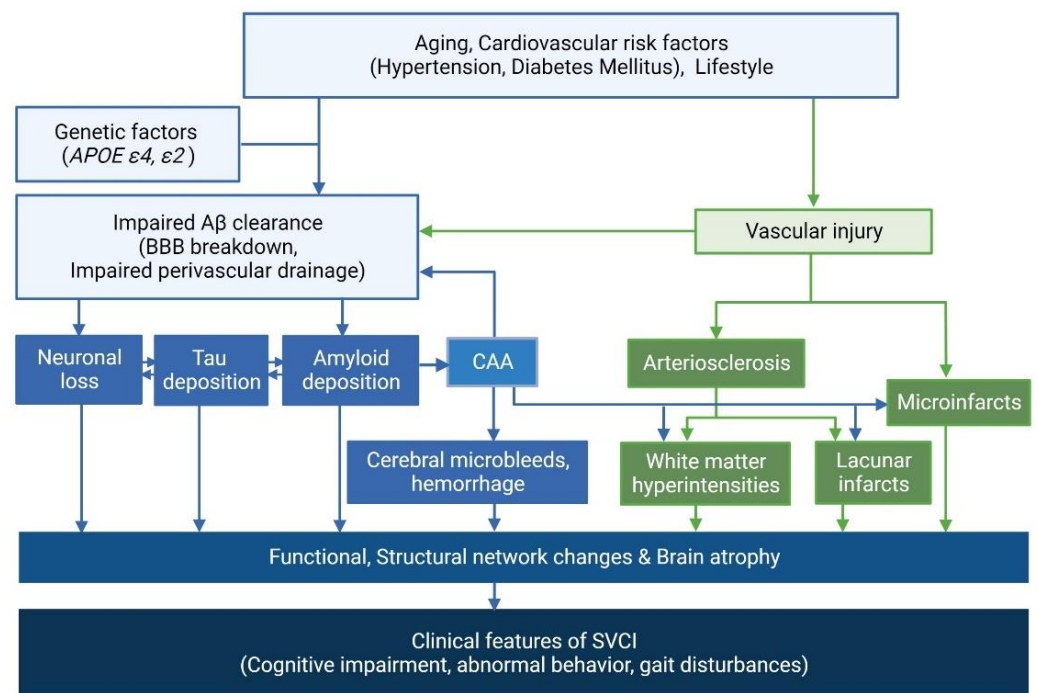
Notably, there are distinct effects of *APOE* genotyping on A $\beta$  deposition between patients with SVCI and ADCI. Specifically, apolipoprotein E4 (*APOE4*) is a risk factor for A $\beta$  positivity in patients with ADCI and SVCI. Apolipoprotein E2 (*APOE2*) is a protective factor in ADCI (OR = 0.43); however, it is a risk factor in SVCI (OR = 2.26) [93]. Thus, *APOE2* might accelerate apolipoprotein E leakage in the vessel walls of patients with SVCI, which in turn leads to impaired vascular drainage of A $\beta$ . This impaired drainage eventually results in increased A $\beta$  burdens in the brain parenchyma [93]. Alternatively, *APOE2* may contribute to the development of CAA, which in turn leads to increased CSVD [93].

#### 2.4. Clinical Effects of AD and CSVD Markers in SVCI Patients

There has been some debate related to the clinical effects of A $\beta$  and CSVD imaging markers. In fact, among patients with extensive WMHs, some tend to show severe dementia symptoms, while others have no symptoms. In this regard, our previous studies investigated which imaging markers might affect the clinical features of SVCI and found that AD biomarkers and CSVD independently affect cognition, abnormal behavior, and gait disturbances [29,32,51,65,94–96]. A cross-sectional study has reported that A $\beta$  uptake is only associated with memory dysfunction, whereas CSVD burden is associated with memory, visuospatial, and frontal executive functions [94]. Longitudinal cohort studies have also shown that A $\beta$  positivity is associated with faster cognitive decline in patients with SVaD [51] and higher conversion to dementia in patients with svMCI [32]. In terms of abnormal behavior, A $\beta$  predicts the signs of delusions and irritability, while CSVD burdens are associated with other behavioral symptoms, such as apathy and depression [97]. In addition, periventricular WMHs are the most important predictor of gait disturbances [98].

SVCI patients show distinct brain structural and cognitive trajectories based on AT (A $\beta$ /tau) biomarker profiles [52]. A previous study showed that patients in the A+T+ group predicted a more rapid decline in structural and cognitive trajectories than those in the A+T– group, followed by those in the A–T– group [52]. Moreover, AD markers and CSVD burden have a synergistic effect on cognitive decline. In a cross-sectional study, significant interactions between WMHs and A $\beta$  uptake were apparent in visuospatial function, suggesting that CSVD and A $\beta$  synergistically affect cognitive impairment [29]. A longitudinal study comparing patients with SVCI and ADCI who had similar tau levels has shown that as A $\beta$  turns positive, SVCI shows a steeper cognitive decline compared to the ADCI group [99]. In addition, as tau levels increase, the SVCI group shows a steeper cognitive decline than the ADCI group [99]. These findings indicate that there are interactive effects between AD markers and CSVD on cognitive decline.

Furthermore, A $\beta$  and CSVD affect specific downstream imaging markers, such as network changes and brain atrophy in specific regions, which in turn lead to the development of these corresponding clinical outcomes [32,95,100]. Specifically, A $\beta$  uptake is associated with cortical thinning in the medial temporal regions including hippocampal changes, which in turn leads to memory dysfunction. In contrast, CSVD burdens are primarily associated with frontal thinning [101] and white matter network disruption [95], which in turn leads to frontal dysfunction. In addition, a three-year longitudinal study has shown that time-varying A $\beta$  and CSVD affects the temporoparietal and frontal thinning, respectively, which in turn contributes to the corresponding cognitive decline [32]. Another cross-sectional study has demonstrated that A $\beta$  positivity and CSVD severity are independently associated with higher tau uptake in the medial and inferior temporal regions, respectively [65]. Moreover, increased tau uptake can mediate the relationship between A $\beta$  and CSVD uptake and cognitive impairment, indicating that tau is another important common downstream marker of A $\beta$  and CSVD burdens. The overall mechanisms of SVCI are summarized in Figure 3.



**Figure 3.** Mechanisms of SVCI. SVCI is caused by various factors, including increasing age, diabetes mellitus, hypertension, genetic predisposition such as *APOE ε4* and *ε2*, and arteriosclerosis. This can lead to A $\beta$  deposition by impairing A $\beta$  clearance. SVCI is also related to widespread white matter hyperintensities or multiple lacunar infarctions, which have been gradually deposited in subcortical regions for several decades. CAA is another factor known to be associated with SVCI. SVCI—subcortical vascular cognitive impairment; *APOE*—apolipoprotein E; A $\beta$ — $\beta$ -amyloid; BBB—blood–brain barrier; CAA—cerebral amyloid angiopathy.

### 2.5. Hemorrhagic Markers in Cerebral Amyloid Angiopathy (CAA) and the Clinical Effects

CAA is characterized by A $\beta$  deposition in the small arteries of the meninges and cortex, which causes vascular dysfunction and brain injury [102]. CAA is clinically and radiologically characterized by lobar intracerebral hemorrhage (ICH), strictly lobar cerebral microbleeds (CMBs) and cortical superficial siderosis (CSS) [103]. CAA is generally related to A $\beta$  parenchymal aggregates, such as neuritic and diffuse plaques, although it can also occur pathologically without evident AD neuropathological changes [104].

Generally, the anatomical location of CMBs reflects their underlying etiology. Specifically, deep CMBs are presumed to be due to hypertensive CSVD, whereas lobar CMBs may reflect CAA [105]. In a cross-sectional study, consistent with previous studies, A $\beta$  uptake has been shown to be associated with lobar CMBs [23]. CSVD is also associated with lobar CMBs as well as deep CMBs [23]. A $\beta$  uptake and CSVD synergistically affect the development of lobar CMB [23]. Furthermore, a longitudinal study demonstrated that longitudinal measures of A $\beta$  uptake and lacunes synergistically affect the development of lobar CMBs [69]. According to Thal’s CAA pathologic stage, CAA pathology extends sequentially from leptomenigeal and cortical vessels to cerebellar vessels and eventually to the striatum and brainstem vessels [106]. Patients with both cerebellar and lobar CMBs are more likely to present with CAA features, whereas deep CMBs, regardless of the presence of both lobar and cerebellar CMBs, are more likely to represent underlying hypertensive angiopathy than CAA features [107]. Interestingly, restricted superficial cerebellar CMBs refer to CAA imaging markers, whereas the involvement of the cerebellar dentate nucleus might be equivalent to deep CMB [107].

Our previous study showed that the frequency of *APOE4* was higher in A $\beta$  (+) CAA than in A $\beta$  (–) CAA, whereas *APOE2* was associated with overt hemorrhagic markers of CAA, such as lobar ICH and CSS [108]. These findings are consistent with other studies

showing that *APOE4* is related to the deposition of A $\beta$  burdens [109,110], and *APOE 2* is related to the breakdown of blood vessel walls [111]. In addition, the number of lobar CMB and the presence of CSS can predict A $\beta$  (+), whereas ischemic CSVD markers can predict A $\beta$  (–) [108].

A previous study investigating the clinical effects of CAA hemorrhagic markers has shown that multiple lobar CMBs are related to cortical thinning across all cortical regions, and that CSS is associated with frontal thinning, which in turn contributes to the corresponding cognitive decline [112]. Furthermore, path analyses have shown that the relationships between CAA hemorrhagic markers and cognitive impairments are partially mediated by thinning in cortical regions related to specific cognitive impairments [112]. A previous study investigated the clinical outcomes of parenchymal A $\beta$  in patients with CAA, and showed that A $\beta$  (+) CAA shows a steeper decline in multiple cognitive domains (including language, visuospatial, memory, and frontal dysfunctions) than A $\beta$  (–) CAA [108].

### 3. Current Challenges and Future Perspectives

In SVCI, numerous potential biomarkers have been discovered using neuroimaging techniques, which were the focus of this review, as well as neuropathological research or genetic testing. These can be grouped broadly into the following categories: clinical biomarkers (neurobehavioral assessment); neuroimaging biomarkers, including WMHs and lacunes; biochemical biomarkers (serum, plasma, and CSF biomarkers); pathological biomarkers; and genetic biomarkers [113,114]. However, due to the lack of specific biomarkers for SVCI, additional extensive research on new biomarkers is necessary. Furthermore, the expansion of the AT(N) system to an ATV(N) framework is recommended [115,116]. Adopting vascular imaging biomarkers will improve the depth and accuracy of biomarker characterization in people along the AD continuum [115–118].

Research on dementia could further advance by recognizing and incorporating abundant knowledge on therapies to modulate vascular dysfunction and how to prevent and treat vascular illnesses. Treatment strategies for SVCI include slowing the progression of CSVD and improving clinical symptoms. For example, the modification of vascular risk factors, including hypertension and diabetes, has been recommended for the prevention of AD and SVCI [119–123]. Additionally, studying the pathways associated with A $\beta$  deposition in SVCI may offer potential targets for treatment. For instance, strategies include cell-based therapies, which aim to promote the clearance of A $\beta$  through the perivascular drainage pathway and BBB, such as upregulation of LRP1 and blockage of RAGE [124–128]. These strategies may provide important therapeutic applications that prevent the buildup of A $\beta$  in the brain and protect vessels against damage in SVCI.

### 4. Conclusions

This review highlights the relationship between AD and SVCI. We focused on the interactions between AD and CSVD markers, potential distinct pathobiology, and clinical effects, based on molecular imaging studies. Therapeutic strategies are needed based on an understanding of the interactions between AD and CSVD markers in SVCI.

**Author Contributions:** Conceptualization, all authors; methodology, all authors; investigation, S.E.K., S.W.S.; visualization, S.E.K., S.W.S.; data curation, all authors; writing—original draft preparation, S.E.K., S.W.S.; writing—review and editing, all authors. All authors have read and agreed to the published version of the manuscript.

**Funding:** This research was supported by a grant from the Korea Health Technology R&D Project through the Korea Health Industry Development Institute (KHIDI), funded by the Ministry of Health & Welfare and Ministry of science and ICT, Republic of Korea (HI19C1132, HU20C0111, HU22C0170); the National Research Foundation of Korea (NRF) grant, funded by the Korean government (MSIT) (NRF-2019R1A5A2027340); Future Medicine 20\*30 Project of the Samsung Medical Center (SMX1220021); Research of Korea Disease Control and Prevention Agency (2021-ER1006-00); the “National Institute of Health” research project (2021-ER1006-01); and an Institute of Informa-

tion and communications Technology Planning and Evaluation (IITP) grant, funded by the Korean government (MSIT) (No. 2021-0-02068, Artificial Intelligence Innovation Hub).

**Institutional Review Board Statement:** Not applicable.

**Informed Consent Statement:** Not applicable.

**Data Availability Statement:** Not applicable.

**Acknowledgments:** Figures 1–3 were all created with [BioRender.com](https://BioRender.com) (accessed on 29 August 2022). The authors thank Gyeongmo Sohn (Inje University Sanggye-Paik Hospital, Seoul, Korea) for helping with manuscript correction.

**Conflicts of Interest:** The authors declare no conflict of interest.

## References

1. Scott, K.R.; Barrett, A.M. Dementia syndromes: Evaluation and treatment. *Expert Rev. Neurother.* **2007**, *7*, 407–422. [[CrossRef](#)] [[PubMed](#)]
2. Roman, G.C. Vascular dementia: Distinguishing characteristics, treatment, and prevention. *J. Am. Geriatr. Soc.* **2003**, *51* (Suppl. S5), S296–S304. [[CrossRef](#)] [[PubMed](#)]
3. Wenk, G.L. Neuropathologic changes in Alzheimer’s disease. *J. Clin. Psychiatry* **2003**, *64* (Suppl. 9), 7–10. [[PubMed](#)]
4. Jack, C.R., Jr.; Bennett, D.A.; Blennow, K.; Carrillo, M.C.; Dunn, B.; Haeberlein, S.B.; Holtzman, D.M.; Jagust, W.; Jessen, F.; Karlawish, J.; et al. NIA-AA Research Framework: Toward a biological definition of Alzheimer’s disease. *Alzheimer’s Dement. J. Alzheimer’s Assoc.* **2018**, *14*, 535–562. [[CrossRef](#)] [[PubMed](#)]
5. Jack, C.R., Jr.; Wiste, H.J.; Therneau, T.M.; Weigand, S.D.; Knopman, D.S.; Mielke, M.M.; Lowe, V.J.; Vemuri, P.; Machulda, M.M.; Schwarz, C.G.; et al. Associations of Amyloid, Tau, and Neurodegeneration Biomarker Profiles With Rates of Memory Decline Among Individuals Without Dementia. *Jama* **2019**, *321*, 2316–2325. [[CrossRef](#)] [[PubMed](#)]
6. DeTure, M.A.; Dickson, D.W. The neuropathological diagnosis of Alzheimer’s disease. *Mol. Neurodegener.* **2019**, *14*, 32. [[CrossRef](#)] [[PubMed](#)]
7. Lerch, J.P.; Pruessner, J.C.; Zijdenbos, A.; Hampel, H.; Teipel, S.J.; Evans, A.C. Focal decline of cortical thickness in Alzheimer’s disease identified by computational neuroanatomy. *Cereb. Cortex* **2005**, *15*, 995–1001. [[CrossRef](#)]
8. Márquez, F.; Yassa, M.A. Neuroimaging Biomarkers for Alzheimer’s Disease. *Mol. Neurodegener.* **2019**, *14*, 21. [[CrossRef](#)]
9. Schneider, J.A.; Arvanitakis, Z.; Bang, W.; Bennett, D.A. Mixed brain pathologies account for most dementia cases in community-dwelling older persons. *Neurology* **2007**, *69*, 2197–2204. [[CrossRef](#)]
10. Agrawal, S.; Schneider, J.A. Vascular pathology and pathogenesis of cognitive impairment and dementia in older adults. *Cereb. Circ.-Cogn. Behav.* **2022**, *3*, 100148. [[CrossRef](#)]
11. Attems, J.; Jellinger, K.A. The overlap between vascular disease and Alzheimer’s disease—lessons from pathology. *BMC Med.* **2014**, *12*, 206. [[CrossRef](#)] [[PubMed](#)]
12. Boyle, P.A.; Yu, L.; Nag, S.; Leurgans, S.; Wilson, R.S.; Bennett, D.A.; Schneider, J.A. Cerebral amyloid angiopathy and cognitive outcomes in community-based older persons. *Neurology* **2015**, *85*, 1930–1936. [[CrossRef](#)] [[PubMed](#)]
13. Gorelick, P.B.; Scuteri, A.; Black, S.E.; Decarli, C.; Greenberg, S.M.; Iadecola, C.; Launer, L.J.; Laurent, S.; Lopez, O.L.; Nyenhuis, D.; et al. Vascular contributions to cognitive impairment and dementia: A statement for healthcare professionals from the American heart association/American stroke association. *Stroke* **2011**, *42*, 2672–2713. [[CrossRef](#)] [[PubMed](#)]
14. Thal, D.R.; Grinberg, L.T.; Attems, J. Vascular dementia: Different forms of vessel disorders contribute to the development of dementia in the elderly brain. *Exp. Gerontol.* **2012**, *47*, 816–824. [[CrossRef](#)]
15. Jorm, A.F.; Jolley, D. The incidence of dementia: A meta-analysis. *Neurology* **1998**, *51*, 728–733. [[CrossRef](#)]
16. Lobo, A.; Launer, L.J.; Fratiglioni, L.; Andersen, K.; Di Carlo, A.; Breteler, M.M.; Copeland, J.R.; Dartigues, J.F.; Jagger, C.; Martinez-Lage, J.; et al. Prevalence of dementia and major subtypes in Europe: A collaborative study of population-based cohorts. Neurologic Diseases in the Elderly Research Group. *Neurology* **2000**, *54* (Suppl. 5), S4–S9.
17. Iadecola, C.; Dering, M.; Hachinski, V.; Joutel, A.; Pendlebury, S.T.; Schneider, J.A.; Dichgans, M. Vascular Cognitive Impairment and Dementia: JACC Scientific Expert Panel. *J. Am. Coll. Cardiol.* **2019**, *73*, 3326–3344. [[CrossRef](#)]
18. O’Brien, J.T.; Erkinjuntti, T.; Reisberg, B.; Roman, G.; Sawada, T.; Pantoni, L.; Bowler, J.V.; Ballard, C.; DeCarli, C.; Gorelick, P.B.; et al. Vascular cognitive impairment. *Lancet Neurol* **2003**, *2*, 89–98. [[CrossRef](#)]
19. Roman, G.C.; Erkinjuntti, T.; Wallin, A.; Pantoni, L.; Chui, H.C. Subcortical ischaemic vascular dementia. *Lancet Neurol.* **2002**, *1*, 426–436. [[CrossRef](#)]
20. Seo, S.W.; Cho, S.S.; Park, A.; Chin, J.; Na, D.L. Subcortical vascular versus amnesic mild cognitive impairment: Comparison of cerebral glucose metabolism. *J. Neuroimaging* **2009**, *19*, 213–219. [[CrossRef](#)]
21. Seo, S.W.; Ahn, J.; Yoon, U.; Im, K.; Lee, J.M.; Tae Kim, S.; Ahn, H.J.; Chin, J.; Jeong, Y.; Na, D.L. Cortical thinning in vascular mild cognitive impairment and vascular dementia of subcortical type. *J. Neuroimaging* **2010**, *20*, 37–45. [[CrossRef](#)] [[PubMed](#)]
22. Seo, S.W.; Im, K.; Lee, J.M.; Kim, Y.H.; Kim, S.T.; Kim, S.Y.; Yang, D.W.; Kim, S.I.; Cho, Y.S.; Na, D.L. Cortical thickness in single-versus multiple-domain amnesic mild cognitive impairment. *Neuroimage* **2007**, *36*, 289–297. [[CrossRef](#)] [[PubMed](#)]



23. Park, J.H.; Seo, S.W.; Kim, C.; Kim, G.H.; Noh, H.J.; Kim, S.T.; Kwak, K.C.; Yoon, U.; Lee, J.M.; Lee, J.W.; et al. Pathogenesis of cerebral microbleeds: In vivo imaging of amyloid and subcortical ischemic small vessel disease in 226 individuals with cognitive impairment. *Ann. Neurol.* **2013**, *73*, 584–593. [[CrossRef](#)]
24. Dubois, M.F.; Hebert, R. The incidence of vascular dementia in Canada: A comparison with Europe and East Asia. *Neuroepidemiology* **2001**, *20*, 179–187. [[CrossRef](#)] [[PubMed](#)]
25. Kang, S.H.; Kim, M.E.; Jang, H.; Kwon, H.; Lee, H.; Kim, H.J.; Seo, S.W.; Na, D.L. Amyloid Positivity in the Alzheimer/Subcortical-Vascular Spectrum. *Neurology* **2021**, *96*, e2201–e2211. [[CrossRef](#)] [[PubMed](#)]
26. Gorelick, P.B. Risk factors for vascular dementia and Alzheimer disease. *Stroke* **2004**, *35* (Suppl. 1), 2620–2622. [[CrossRef](#)]
27. Javanshiri, K.; Waldo, M.L.; Friberg, N.; Sjøvall, F.; Wickerstrom, K.; Haglund, M.; Englund, E. Atherosclerosis, Hypertension, and Diabetes in Alzheimer’s Disease, Vascular Dementia, and Mixed Dementia: Prevalence and Presentation. *J. Alzheimers Dis.* **2018**, *65*, 1247–1258. [[CrossRef](#)]
28. Saridin, F.N.; Hilal, S.; Villaraza, S.G.; Reilhac, A.; Gyanwali, B.; Tanaka, T.; Stephenson, M.C.; Ng, S.L.; Vrooman, H.; van der Flier, W.M.; et al. Brain amyloid beta, cerebral small vessel disease, and cognition: A memory clinic study. *Neurology* **2020**, *95*, e2845–e2853. [[CrossRef](#)]
29. Lee, M.J.; Seo, S.W.; Na, D.L.; Kim, C.; Park, J.H.; Kim, G.H.; Kim, C.H.; Noh, Y.; Cho, H.; Kim, H.J.; et al. Synergistic effects of ischemia and beta-amyloid burden on cognitive decline in patients with subcortical vascular mild cognitive impairment. *JAMA Psychiatry* **2014**, *71*, 412–422. [[CrossRef](#)]
30. Toledo, J.B.; Arnold, S.E.; Raible, K.; Brettschneider, J.; Xie, S.X.; Grossman, M.; Monsell, S.E.; Kukull, W.A.; Trojanowski, J.Q. Contribution of cerebrovascular disease in autopsy confirmed neurodegenerative disease cases in the National Alzheimer’s Coordinating Centre. *Brain A J. Neurol.* **2013**, *136 Pt 9*, 2697–2706. [[CrossRef](#)]
31. Petrovitch, H.; Ross, G.W.; Steinhorn, S.C.; Abbott, R.D.; Markesbery, W.; Davis, D.; Nelson, J.; Hardman, J.; Masaki, K.; Vogt, M.R.; et al. AD lesions and infarcts in demented and non-demented Japanese-American men. *Ann. Neurol.* **2005**, *57*, 98–103. [[CrossRef](#)] [[PubMed](#)]
32. Kim, H.J.; Yang, J.J.; Kwon, H.; Kim, C.; Lee, J.M.; Chun, P.; Kim, Y.J.; Jung, N.Y.; Chin, J.; Kim, S.; et al. Relative impact of amyloid-beta, lacunes, and downstream imaging markers on cognitive trajectories. *Brain* **2016**, *139 Pt 9*, 2516–2527. [[CrossRef](#)] [[PubMed](#)]
33. Jang, H.; Park, J.Y.; Jang, Y.K.; Kim, H.J.; Lee, J.S.; Na, D.L.; Noh, Y.; Lockhart, S.N.; Seong, J.K.; Seo, S.W. Distinct amyloid distribution patterns in amyloid positive subcortical vascular cognitive impairment. *Sci. Rep.* **2018**, *8*, 16178. [[CrossRef](#)] [[PubMed](#)]
34. Banerjee, G.; Kim, H.J.; Fox, Z.; Jager, H.R.; Wilson, D.; Charidimou, A.; Na, H.K.; Na, D.L.; Seo, S.W.; Werring, D.J. MRI-visible perivascular space location is associated with Alzheimer’s disease independently of amyloid burden. *Brain A J. Neurol.* **2017**, *140*, 1107–1116. [[CrossRef](#)]
35. Klunk, W.E.; Engler, H.; Nordberg, A.; Wang, Y.; Blomqvist, G.; Holt, D.P.; Bergstrom, M.; Savitcheva, I.; Huang, G.F.; Estrada, S.; et al. Imaging brain amyloid in Alzheimer’s disease with Pittsburgh Compound-B. *Ann. Neurol.* **2004**, *55*, 306–319. [[CrossRef](#)]
36. Johnson, K.A.; Sperling, R.A.; Gidicsin, C.M.; Carmasin, J.S.; Maye, J.E.; Coleman, R.E.; Reiman, E.M.; Sabbagh, M.N.; Sadowsky, C.H.; Fleisher, A.S.; et al. Flortbetapir (F18-AV-45) PET to assess amyloid burden in Alzheimer’s disease dementia, mild cognitive impairment, and normal aging. *Alzheimers Dement.* **2013**, *9* (Suppl. 5), S72–S83. [[CrossRef](#)]
37. Hatashita, S.; Yamasaki, H.; Suzuki, Y.; Tanaka, K.; Wakebe, D.; Hayakawa, H. [18F]Flutemetamol amyloid-beta PET imaging compared with [11C]PIB across the spectrum of Alzheimer’s disease. *Eur. J. Nucl. Med. Mol. Imaging* **2014**, *41*, 290–300. [[CrossRef](#)]
38. Barthel, H.; Sabri, O. Flortbetaben to trace amyloid-beta in the Alzheimer brain by means of PET. *J. Alzheimers Dis.* **2011**, *26* (Suppl. 3), 117–121. [[CrossRef](#)]
39. Schwarz, A.J.; Yu, P.; Miller, B.B.; Shcherbinin, S.; Dickson, J.; Navitsky, M.; Joshi, A.D.; Devous, M.D., Sr.; Mintun, M.S. Regional profiles of the candidate tau PET ligand 18F-AV-1451 recapitulate key features of Braak histopathological stages. *Brain* **2016**, *139 Pt 5*, 1539–1550. [[CrossRef](#)]
40. Pascoal, T.A.; Therriault, J.; Benedet, A.L.; Savard, M.; Lussier, F.Z.; Chamoun, M.; Tissot, C.; Qureshi, M.N.I.; Kang, M.S.; Mathotaarachchi, S.; et al. 18F-MK-6240 PET for early and late detection of neurofibrillary tangles. *Brain* **2020**, *143*, 2818–2830. [[CrossRef](#)]
41. Kroth, H.; Oden, F.; Molette, J.; Schieferstein, H.; Capotosti, F.; Mueller, A.; Berndt, M.; Schmitt-Willich, H.; Darmency, V.; Gabellieri, E.; et al. Discovery and preclinical characterization of [(18)F]PI-2620, a next-generation tau PET tracer for the assessment of tau pathology in Alzheimer’s disease and other tauopathies. *Eur. J. Nucl. Med. Mol. Imaging* **2019**, *46*, 2178–2189. [[CrossRef](#)] [[PubMed](#)]
42. Kuwabara, H.; Comley, R.A.; Borroni, E.; Honer, M.; Kitmiller, K.; Roberts, J.; Gapasin, L.; Mathur, A.; Klein, G.; Wong, D.F. Evaluation of (18)F-RO-948 PET for Quantitative Assessment of Tau Accumulation in the Human Brain. *J. Nucl. Med.* **2018**, *59*, 1877–1884. [[CrossRef](#)] [[PubMed](#)]
43. Aizenstein, H.J.; Nebes, R.D.; Saxton, J.A.; Price, J.C.; Mathis, C.A.; Tsopelas, N.D.; Ziolkowski, S.K.; James, J.A.; Snitz, B.E.; Houck, P.R.; et al. Frequent amyloid deposition without significant cognitive impairment among the elderly. *Arch. Neurol.* **2008**, *65*, 1509–1517. [[CrossRef](#)] [[PubMed](#)]
44. Wolk, D.A.; Price, J.C.; Saxton, J.A.; Snitz, B.E.; James, J.A.; Lopez, O.L.; Aizenstein, H.J.; Cohen, A.D.; Weissfeld, L.A.; Mathis, C.A.; et al. Amyloid imaging in mild cognitive impairment subtypes. *Ann. Neurol.* **2009**, *65*, 557–568. [[CrossRef](#)] [[PubMed](#)]



45. Ossenkoppele, R.; Leuzy, A.; Cho, H.; Sudre, C.H.; Strandberg, O.; Smith, R.; Palmqvist, S.; Mattsson-Carlgrén, N.; Olsson, T.; Jogi, J.; et al. The impact of demographic, clinical, genetic, and imaging variables on tau PET status. *Eur. J. Nucl. Med. Mol. Imaging* **2021**, *48*, 2245–2258. [[CrossRef](#)]
46. Braak, H.; Braak, E. Neuropathological staging of Alzheimer-related changes. *Acta Neuropathol.* **1991**, *82*, 239–259. [[CrossRef](#)]
47. Okamura, N.; Harada, R.; Ishiki, A.; Kikuchi, A.; Nakamura, T.; Kudo, Y. The development and validation of tau PET tracers: Current status and future directions. *Clin. Transl. Imaging* **2018**, *6*, 305–316. [[CrossRef](#)]
48. Saint-Aubert, L.; Lemoine, L.; Chiotis, K.; Leuzy, A.; Rodriguez-Vieitez, E.; Nordberg, A. Tau PET imaging: Present and future directions. *Mol. Neurodegener.* **2017**, *12*, 19. [[CrossRef](#)]
49. Chong, J.S.X.; Jang, H.; Kim, H.J.; Ng, K.K.; Na, D.L.; Lee, J.H.; Seo, S.W.; Zhou, J. Amyloid and cerebrovascular burden divergently influence brain functional network changes over time. *Neurology* **2019**, *93*, e1514–e1525. [[CrossRef](#)]
50. Lee, J.H.; Kim, S.H.; Kim, G.H.; Seo, S.W.; Park, H.K.; Oh, S.J.; Kim, J.S.; Cheong, H.K.; Na, D.L. Identification of pure subcortical vascular dementia using 11C-Pittsburgh compound B. *Neurology* **2011**, *77*, 18–25. [[CrossRef](#)]
51. Ye, B.S.; Seo, S.W.; Kim, J.H.; Kim, G.H.; Cho, H.; Noh, Y.; Kim, H.J.; Yoon, C.W.; Woo, S.Y.; Kim, S.H.; et al. Effects of amyloid and vascular markers on cognitive decline in subcortical vascular dementia. *Neurology* **2015**, *85*, 1687–1693. [[CrossRef](#)] [[PubMed](#)]
52. Jang, H.; Kim, H.J.; Park, S.; Park, Y.H.; Choe, Y.; Cho, H.; Lyoo, C.H.; Yoon, U.; Lee, J.S.; Kim, Y.; et al. Application of an amyloid and tau classification system in subcortical vascular cognitive impairment patients. *Eur. J. Nucl. Med. Mol. Imaging* **2020**, *47*, 292–303. [[CrossRef](#)] [[PubMed](#)]
53. Noh, Y.; Seo, S.W.; Jeon, S.; Lee, J.M.; Kim, J.H.; Kim, G.H.; Cho, H.; Yoon, C.W.; Kim, H.J.; Ye, B.S.; et al. White matter hyperintensities are associated with amyloid burden in APOE4 non-carriers. *J. Alzheimers Dis.* **2014**, *40*, 877–886. [[CrossRef](#)] [[PubMed](#)]
54. Lehmann, M.; Ghosh, P.M.; Madison, C.; Laforce, R., Jr.; Corbetta-Rastelli, C.; Weiner, M.W.; Greicius, M.D.; Seeley, W.W.; Gorno-Tempini, M.L.; Rosen, H.J.; et al. Diverging patterns of amyloid deposition and hypometabolism in clinical variants of probable Alzheimer's disease. *Brain A J. Neurol.* **2013**, *136 Pt 3*, 844–858. [[CrossRef](#)]
55. Jang, H.; Seo, S.W. Comparison of Amyloid and Tau Patterns and Neuropsychological Findings in Cerebral Amyloid Angiopathy and Hypertensive Small Vessel Disease. In Proceedings of the Conference of Korean Dementia Association, Seoul, Korea, 4 November 2017; Korea Dementia Association: Seoul, Korea, 2017.
56. Grothe, M.J.; Barthel, H.; Sepulcre, J.; Dyrba, M.; Sabri, O.; Teipel, S.J. In vivo staging of regional amyloid deposition. *Neurology* **2017**, *89*, 2031–2038. [[CrossRef](#)]
57. van der Kant, R.; Goldstein, L.S.B.; Ossenkoppele, R. Amyloid- $\beta$ -independent regulators of tau pathology in Alzheimer disease. *Nat. Rev. Neurosci.* **2020**, *21*, 21–35. [[CrossRef](#)] [[PubMed](#)]
58. Viswanathan, A.; Greenberg, S.M. Cerebral amyloid angiopathy in the elderly. *Ann. Neurol.* **2011**, *70*, 871–880. [[CrossRef](#)] [[PubMed](#)]
59. Braak, H.; Del Tredici, K. Neuroanatomy and pathology of sporadic Alzheimer's disease. *Adv. Anat. Embryol. Cell Biol.* **2015**, *215*, 1–162. [[PubMed](#)]
60. Mattsson, N.; Palmqvist, S.; Stomrud, E.; Vogel, J.; Hansson, O. Staging  $\beta$ -Amyloid Pathology with Amyloid Positron Emission Tomography. *JAMA Neurol.* **2019**, *76*, 1319–1329. [[CrossRef](#)]
61. Collij, L.E.; Heeman, F.; Salvadó, G.; Ingala, S.; Altomare, D.; de Wilde, A.; Konijnenberg, E.; van Buchem, M.; Yaqub, M.; Markiewicz, P.; et al. Multitracer model for staging cortical amyloid deposition using PET imaging. *Neurology* **2020**, *95*, e1538–e1553. [[CrossRef](#)]
62. Palmqvist, S.; Schöll, M.; Strandberg, O.; Mattsson, N.; Stomrud, E.; Zetterberg, H.; Blennow, K.; Landau, S.; Jagust, W.; Hansson, O. Earliest accumulation of  $\beta$ -amyloid occurs within the default-mode network and concurrently affects brain connectivity. *Nat. Commun.* **2017**, *8*, 1214. [[CrossRef](#)] [[PubMed](#)]
63. Song, B.; Ao, Q.; Wang, Z.; Liu, W.; Niu, Y.; Shen, Q.; Zuo, H.; Zhang, X.; Gong, Y. Phosphorylation of tau protein over time in rats subjected to transient brain ischemia. *Neural. Regen. Res.* **2013**, *8*, 3173–3182. [[CrossRef](#)] [[PubMed](#)]
64. Bennett, R.E.; Robbins, A.B.; Hu, M.; Cao, X.; Betensky, R.A.; Clark, T.; Das, S.; Hyman, B.T. Tau induces blood vessel abnormalities and angiogenesis-related gene expression in P301L transgenic mice and human Alzheimer's disease. *Proc. Natl. Acad. Sci. USA* **2018**, *115*, E1289–E1298. [[CrossRef](#)] [[PubMed](#)]
65. Kim, H.J.; Park, S.; Cho, H.; Jang, Y.K.; San Lee, J.; Jang, H.; Kim, Y.; Kim, K.W.; Ryu, Y.H.; Choi, J.Y.; et al. Assessment of Extent and Role of Tau in Subcortical Vascular Cognitive Impairment Using 18F-AV1451 Positron Emission Tomography Imaging. *JAMA Neurol.* **2018**, *75*, 999–1007. [[CrossRef](#)] [[PubMed](#)]
66. Cho, H.; Choi, J.Y.; Hwang, M.S.; Kim, Y.J.; Lee, H.M.; Lee, H.S.; Lee, J.H.; Ryu, Y.H.; Lee, M.S.; Lyoo, C.H. In vivo cortical spreading pattern of tau and amyloid in the Alzheimer disease spectrum. *Ann. Neurol.* **2016**, *80*, 247–258. [[CrossRef](#)]
67. Gottesman, R.F.; Schneider, A.L.; Zhou, Y.; Coresh, J.; Green, E.; Gupta, N.; Knopman, D.S.; Mintz, A.; Rahmim, A.; Sharrett, A.R.; et al. Association Between Midlife Vascular Risk Factors and Estimated Brain Amyloid Deposition. *JAMA* **2017**, *317*, 1443–1450. [[CrossRef](#)]
68. Hughes, T.M.; Wagenknecht, L.E.; Craft, S.; Mintz, A.; Heiss, G.; Palta, P.; Wong, D.; Zhou, Y.; Knopman, D.; Mosley, T.H.; et al. Arterial stiffness and dementia pathology: Atherosclerosis Risk in Communities (ARIC)-PET Study. *Neurology* **2018**, *90*, e1248–e1256. [[CrossRef](#)]

69. Rabin, J.S.; Schultz, A.P.; Hedden, T.; Viswanathan, A.; Marshall, G.A.; Kilpatrick, E.; Klein, H.; Buckley, R.F.; Yang, H.S.; Properzi, M.; et al. Interactive Associations of Vascular Risk and beta-Amyloid Burden with Cognitive Decline in Clinically Normal Elderly Individuals: Findings From the Harvard Aging Brain Study. *JAMA Neurol.* **2018**, *75*, 1124–1131. [[CrossRef](#)]
70. Arfanakis, K.; Evia, A.M.; Leurgans, S.E.; Cardoso, L.F.C.; Kulkarni, A.; Alqam, N.; Lopes, L.F.; Vieira, D.; Bennett, D.A.; Schneider, J.A. Neuropathologic Correlates of White Matter Hyperintensities in a Community-Based Cohort of Older Adults. *J. Alzheimers Dis.* **2020**, *73*, 333–345. [[CrossRef](#)]
71. Köbe, T.; Gonneaud, J.; Pichet Binette, A.; Meyer, P.F.; McSweeney, M.; Rosa-Neto, P.; Breitner, J.C.S.; Poirier, J.; Villeneuve, S. Association of Vascular Risk Factors with  $\beta$ -Amyloid Peptide and Tau Burdens in Cognitively Unimpaired Individuals and Its Interaction with Vascular Medication Use. *JAMA Netw. Open.* **2020**, *3*, e1920780. [[CrossRef](#)]
72. Lockhart, S.N.; Schaich, C.L.; Craft, S.; Sachs, B.C.; Rapp, S.R.; Jung, Y.; Whitlow, C.T.; Solingapuram Sai, K.K.; Cleveland, M.; Williams, B.J.; et al. Associations among vascular risk factors, neuroimaging biomarkers, and cognition: Preliminary analyses from the Multi-Ethnic Study of Atherosclerosis (MESA). *Alzheimers Dement.* **2022**, *18*, 551–560. [[CrossRef](#)] [[PubMed](#)]
73. Charidimou, A.; Boulouis, G.; Gurol, M.E.; Ayata, C.; Bacsikai, B.J.; Frosch, M.P.; Viswanathan, A.; Greenberg, S.M. Emerging concepts in sporadic cerebral amyloid angiopathy. *Brain A J. Neurol.* **2017**, *140*, 1829–1850. [[CrossRef](#)] [[PubMed](#)]
74. Gmitter, T.; Faust, M.; Auer, F.; Alexopoulos, P.; Forstl, H.; Henriksen, G.; Perneczky, R.; Sorg, C.; Yousefi, B.H.; Drzezga, A.; et al. White matter hyperintensities predict amyloid increase in Alzheimer's disease. *Neurobiol. Aging* **2012**, *33*, 2766–2773. [[CrossRef](#)] [[PubMed](#)]
75. Sweeney, M.D.; Sagare, A.P.; Zlokovic, B.V. Blood-brain barrier breakdown in Alzheimer disease and other neurodegenerative disorders. *Nat. Rev. Neurol.* **2018**, *14*, 133–150. [[CrossRef](#)] [[PubMed](#)]
76. Montagne, A.; Zhao, Z.; Zlokovic, B.V. Alzheimer's disease: A matter of blood-brain barrier dysfunction? *J. Exp. Med.* **2017**, *214*, 3151–3169. [[CrossRef](#)]
77. Terwel, D.; Muyliaert, D.; Dewachter, I.; Borghgraef, P.; Croes, S.; Devijver, H.; Van Leuven, F. Amyloid activates GSK-3 $\beta$  to aggravate neuronal tauopathy in bigenic mice. *Am. J. Pathol.* **2008**, *172*, 786–798. [[CrossRef](#)]
78. Hernandez, P.; Lee, G.; Sjoberg, M.; Maccioni, R.B. Tau phosphorylation by cdk5 and Fyn in response to amyloid peptide A $\beta$  (25–35): Involvement of lipid rafts. *J. Alzheimers Dis.* **2009**, *16*, 149–156. [[CrossRef](#)]
79. Gamblin, T.C.; Chen, F.; Zambrano, A.; Abraha, A.; Lalgalwar, S.; Guillozet, A.L.; Lu, M.; Fu, Y.; Garcia-Sierra, F.; LaPointe, N.; et al. Caspase cleavage of tau: Linking amyloid and neurofibrillary tangles in Alzheimer's disease. *Proc. Natl. Acad. Sci. USA* **2003**, *100*, 10032–10037. [[CrossRef](#)]
80. Park, S.-Y.; Ferreira, A. The Generation of a 17 kDa Neurotoxic Fragment: An Alternative Mechanism by which Tau Mediates  $\beta$ -Amyloid-Induced Neurodegeneration. *J. Neurosci.* **2005**, *25*, 5365–5375. [[CrossRef](#)]
81. Ismail, R.; Parbo, P.; Madsen, L.S.; Hansen, A.K.; Hansen, K.V.; Schaldemose, J.L.; Kjeldsen, P.L.; Stokholm, M.G.; Gottrup, H.; Eskildsen, S.F.; et al. The relationships between neuroinflammation, beta-amyloid and tau deposition in Alzheimer's disease: A longitudinal PET study. *J. Neuroinflamm.* **2020**, *17*, 151. [[CrossRef](#)]
82. Heneka, M.T.; Carson, M.J.; Khoury, J.E.; Landreth, G.E.; Brosseron, F.; Feinstein, D.L.; Jacobs, A.H.; Wyss-Coray, T.; Vitorica, J.; Ransohoff, R.M.; et al. Neuroinflammation in Alzheimer's disease. *Lancet Neurol.* **2015**, *14*, 388–405. [[CrossRef](#)]
83. Yoshiyama, Y.; Higuchi, M.; Zhang, B.; Huang, S.M.; Iwata, N.; Saido, T.C.; Maeda, J.; Suhara, T.; Trojanowski, J.Q.; Lee, V.M. Synapse loss and microglial activation precede tangles in a P301S tauopathy mouse model. *Neuron* **2007**, *53*, 337–351. [[CrossRef](#)] [[PubMed](#)]
84. Maphis, N.; Xu, G.; Kokiko-Cochran, O.N.; Jiang, S.; Cardona, A.; Ransohoff, R.M.; Lamb, B.T.; Bhaskar, K. Reactive microglia drive tau pathology and contribute to the spreading of pathological tau in the brain. *Brain A J. Neurol.* **2015**, *138 Pt 6*, 1738–1755. [[CrossRef](#)]
85. Korte, N.; Nortley, R.; Attwell, D. Cerebral blood flow decrease as an early pathological mechanism in Alzheimer's disease. *Acta Neuropathol.* **2020**, *140*, 793–810. [[CrossRef](#)] [[PubMed](#)]
86. Liu, S.L.; Wang, C.; Jiang, T.; Tan, L.; Xing, A.; Yu, J.T. The Role of Cdk5 in Alzheimer's Disease. *Mol. Neurobiol.* **2016**, *53*, 4328–4342. [[CrossRef](#)] [[PubMed](#)]
87. Toro-Fernández, L.F.; Zuluaga-Monares, J.C.; Saldarriaga-Cartagena, A.M.; Cardona-Gómez, G.P.; Posada-Duque, R. Targeting CDK5 in Astrocytes Promotes Calcium Homeostasis Under Excitotoxic Conditions. *Front. Cell. Neurosci.* **2021**, *15*, 643717. [[CrossRef](#)] [[PubMed](#)]
88. Mottet, D.; Dumont, V.; Deccache, Y.; Demazy, C.; Ninane, N.; Raes, M.; Michiels, C. Regulation of hypoxia-inducible factor-1 $\alpha$  protein level during hypoxic conditions by the phosphatidylinositol 3-kinase/Akt/glycogen synthase kinase 3 $\beta$  pathway in HepG2 cells. *J. Biol. Chem.* **2003**, *278*, 31277–31285. [[CrossRef](#)]
89. Curtis, D.; Bandyopadhyay, S. Mini-review: Role of the PI3K/Akt pathway and tyrosine phosphatases in Alzheimer's disease susceptibility. *Ann. Hum. Genet.* **2021**, *85*, 1–6. [[CrossRef](#)]
90. Grochowski, C.; Litak, J.; Kamieniak, P.; Maciejewski, R. Oxidative stress in cerebral small vessel disease. Role of reactive species. *Free Radic. Res.* **2018**, *52*, 1–13. [[CrossRef](#)]
91. Hort, J.; Vališ, M.; Kuča, K.; Angelucci, F. Vascular Cognitive Impairment: Information from Animal Models on the Pathogenic Mechanisms of Cognitive Deficits. *Int. J. Mol. Sci.* **2019**, *20*, 2405. [[CrossRef](#)]
92. Yuste, J.E.; Tarragon, E.; Campuzano, C.M.; Ros-Bernal, F. Implications of glial nitric oxide in neurodegenerative diseases. *Front. Cell. Neurosci.* **2015**, *9*, 322. [[CrossRef](#)] [[PubMed](#)]

93. Lee, J.S.; Lee, H.; Park, S.; Choe, Y.; Park, Y.H.; Cheon, B.K.; Hahn, A.; Ossenkoppele, R.; Kim, H.J.; Kim, S.; et al. Association between APOE epsilon2 and Abeta burden in patients with Alzheimer- and vascular-type cognitive impairment. *Neurology* **2020**, *95*, e2354–e2365. [[CrossRef](#)] [[PubMed](#)]
94. Park, J.H.; Seo, S.W.; Kim, C.; Kim, S.H.; Kim, G.H.; Kim, S.T.; Jeon, S.; Lee, J.M.; Oh, S.J.; Kim, J.S.; et al. Effects of cerebrovascular disease and amyloid beta burden on cognition in subjects with subcortical vascular cognitive impairment. *Neurobiol. Aging* **2014**, *35*, 254–260. [[CrossRef](#)] [[PubMed](#)]
95. Kim, H.J.; Im, K.; Kwon, H.; Lee, J.M.; Kim, C.; Kim, Y.J.; Jung, N.Y.; Cho, H.; Ye, B.S.; Noh, Y.; et al. Clinical effect of white matter network disruption related to amyloid and small vessel disease. *Neurology* **2015**, *85*, 63–70. [[CrossRef](#)] [[PubMed](#)]
96. Jang, Y.K.; Kwon, H.; Kim, Y.J.; Jung, N.Y.; Lee, J.S.; Lee, J.; Chin, J.; Im, K.; Jeon, S.; Lee, J.M.; et al. Early- vs late-onset subcortical vascular cognitive impairment. *Neurology* **2016**, *86*, 527–534. [[CrossRef](#)] [[PubMed](#)]
97. Kim, H.J.; Ye, B.S.; Yoon, C.W.; Cho, H.; Noh, Y.; Kim, G.H.; Choi, Y.S.; Kim, J.H.; Jeon, S.; Lee, J.M.; et al. Effects of APOE epsilon4 on brain amyloid, lacunar infarcts, and white matter lesions: A study among patients with subcortical vascular cognitive impairment. *Neurobiol. Aging* **2013**, *34*, 2482–2487. [[CrossRef](#)] [[PubMed](#)]
98. Kim, Y.J.; Kwon, H.K.; Lee, J.M.; Cho, H.; Kim, H.J.; Park, H.K.; Jung, N.Y.; San Lee, J.; Lee, J.; Jang, Y.K.; et al. Gray and white matter changes linking cerebral small vessel disease to gait disturbances. *Neurology* **2016**, *86*, 1199–1207. [[CrossRef](#)]
99. Jang, H.; Kim, H.J.; Choe, Y.S.; Kim, S.J.; Park, S.; Kim, Y.; Kim, K.W.; Lyoo, C.H.; Cho, H.; Ryu, Y.H.; et al. The Impact of Amyloid-beta or Tau on Cognitive Change in the Presence of Severe Cerebrovascular Disease. *J. Alzheimers Dis.* **2020**, *78*, 573–585. [[CrossRef](#)]
100. Byeon, H. A Prediction Model for Mild Cognitive Impairment Using Random Forests. *Int. J. Adv. Comput. Sci. Appl. (IJACSA)* **2015**, *6*, 1–5. [[CrossRef](#)]
101. Ye, B.S.; Seo, S.W.; Kim, G.H.; Noh, Y.; Cho, H.; Yoon, C.W.; Kim, H.J.; Chin, J.; Jeon, S.; Lee, J.M.; et al. Amyloid burden, cerebrovascular disease, brain atrophy, and cognition in cognitively impaired patients. *Alzheimers Dement.* **2015**, *11*, 494–503.e3. [[CrossRef](#)]
102. Weller, R.O.; Massey, A.; Newman, T.A.; Hutchings, M.; Kuo, Y.M.; Roher, A.E. Cerebral amyloid angiopathy: Amyloid beta accumulates in putative interstitial fluid drainage pathways in Alzheimer's disease. *Am. J. Pathol.* **1998**, *153*, 725–733. [[CrossRef](#)]
103. Yamada, M. Cerebral amyloid angiopathy: Emerging concepts. *J. Stroke* **2015**, *17*, 17–30. [[CrossRef](#)] [[PubMed](#)]
104. Greenberg, S.M.; Bacskai, B.J.; Hernandez-Guillamon, M.; Pruzin, J.; Sperling, R.; van Veluw, S.J. Cerebral amyloid angiopathy and Alzheimer disease—one peptide, two pathways. *Nat. Rev. Neurol.* **2020**, *16*, 30–42. [[CrossRef](#)] [[PubMed](#)]
105. Greenberg, S.M.; Vernooij, M.W.; Cordonnier, C.; Viswanathan, A.; Al-Shahi Salman, R.; Warach, S.; Launer, L.J.; Van Buchem, M.A.; Breteler, M.M.; Microbleed Study, G. Cerebral microbleeds: A guide to detection and interpretation. *Lancet Neurol.* **2009**, *8*, 165–174. [[CrossRef](#)]
106. Thal, D.R.; Ghebremedhin, E.; Orantes, M.; Wiestler, O.D. Vascular pathology in Alzheimer disease: Correlation of cerebral amyloid angiopathy and arteriosclerosis/lipohyalinosis with cognitive decline. *J. Neuropathol. Exp. Neurol.* **2003**, *62*, 1287–1301. [[CrossRef](#)] [[PubMed](#)]
107. Jung, Y.H.; Jang, H.; Park, S.B.; Choe, Y.S.; Park, Y.; Kang, S.H.; Lee, J.M.; Kim, J.S.; Kim, J.; Kim, J.P.; et al. Strictly Lobar Microbleeds Reflect Amyloid Angiopathy Regardless of Cerebral and Cerebellar Compartments. *Stroke* **2020**, *51*, 3600–3607. [[CrossRef](#)] [[PubMed](#)]
108. Jang, H.; Jang, Y.K.; Kim, H.J.; Werring, D.J.; Lee, J.S.; Choe, Y.S.; Park, S.; Lee, J.; Kim, K.W.; Kim, Y.; et al. Clinical significance of amyloid beta positivity in patients with probable cerebral amyloid angiopathy markers. *Eur. J. Nucl. Med. Mol. Imaging* **2019**, *46*, 1287–1298. [[CrossRef](#)]
109. Schmechel, D.E.; Saunders, A.M.; Strittmatter, W.J.; Crain, B.J.; Hulette, C.M.; Joo, S.H.; Pericak-Vance, M.A.; Goldgaber, D.; Roses, A.D. Increased amyloid beta-peptide deposition in cerebral cortex as a consequence of apolipoprotein E genotype in late-onset Alzheimer disease. *Proc. Natl. Acad. Sci. USA* **1993**, *90*, 9649–9653. [[CrossRef](#)]
110. Kok, E.; Haikonen, S.; Luoto, T.; Huhtala, H.; Goebeler, S.; Haapasalo, H.; Karhunen, P.J. Apolipoprotein E-dependent accumulation of Alzheimer disease-related lesions begins in middle age. *Ann. Neurol.* **2009**, *65*, 650–657. [[CrossRef](#)]
111. Greenberg, S.M.; Vonsattel, J.-P.G.; Segal, A.Z.; Chiu, R.I.; Clatworthy, A.E.; Liao, A.; Hyman, B.T.; Rebeck, G.W. Association of apolipoprotein E epsilon2 and vasculopathy in cerebral amyloid angiopathy. *Neurology* **1998**, *50*, 961–965. [[CrossRef](#)]
112. Jang, Y.K.; Kim, H.J.; Lee, J.S.; Kim, Y.J.; Kim, K.W.; Kim, Y.; Jang, H.; Lee, J.; Lee, J.M.; Kim, S.J.; et al. Distinctive Clinical Effects of Haemorrhagic Markers in Cerebral Amyloid Angiopathy. *Sci. Rep.* **2017**, *7*, 15984. [[CrossRef](#)] [[PubMed](#)]
113. Jagtap, A.; Gawande, S.; Sharma, S. Biomarkers in vascular dementia: A recent update. *Biomark. Genom. Med.* **2015**, *7*, 43–56. [[CrossRef](#)]
114. Wahlund, L.O.; Westman, E.; van Westen, D.; Wallin, A.; Shams, S.; Cavallin, L.; Larsson, E.M. Imaging biomarkers of dementia: Recommended visual rating scales with teaching cases. *Insights Imaging* **2017**, *8*, 79–90. [[CrossRef](#)] [[PubMed](#)]
115. Sweeney, M.D.; Montagne, A.; Sagare, A.P.; Nation, D.A.; Schneider, L.S.; Chui, H.C.; Harrington, M.G.; Pa, J.; Law, M.; Wang, D.J.J.; et al. Vascular dysfunction—The disregarded partner of Alzheimer's disease. *Alzheimers Dement.* **2019**, *15*, 158–167. [[CrossRef](#)]
116. Hampel, H.; Cummings, J.; Blennow, K.; Gao, P.; Jack, C.R., Jr.; Vergallo, A. Developing the ATX(N) classification for use across the Alzheimer disease continuum. *Nat. Rev. Neurol.* **2021**, *17*, 580–589. [[CrossRef](#)]

117. Cummings, J. The National Institute on Aging-Alzheimer's Association Framework on Alzheimer's disease: Application to clinical trials. *Alzheimers Dement.* **2019**, *15*, 172–178. [[CrossRef](#)] [[PubMed](#)]
118. Mattsson-Carlgen, N.; Leuzy, A.; Janelidze, S.; Palmqvist, S.; Stomrud, E.; Strandberg, O.; Smith, R.; Hansson, O. The implications of different approaches to define AT(N) in Alzheimer disease. *Neurology* **2020**, *94*, e2233–e2244. [[CrossRef](#)]
119. Duron, E.; Hanon, O. Vascular risk factors, cognitive decline, and dementia. *Vasc. Health Risk Manag.* **2008**, *4*, 363–381.
120. Cheng, Y.W.; Chiu, M.J.; Chen, Y.F.; Cheng, T.W.; Lai, Y.M.; Chen, T.F. The contribution of vascular risk factors in neurodegenerative disorders: From mild cognitive impairment to Alzheimer's disease. *Alzheimers Res. Ther.* **2020**, *12*, 91. [[CrossRef](#)]
121. Middleton, L.E.; Yaffe, K. Promising strategies for the prevention of dementia. *Arch. Neurol.* **2009**, *66*, 1210–1215. [[CrossRef](#)]
122. Tariq, S.; Barber, P.A. Dementia risk and prevention by targeting modifiable vascular risk factors. *J. Neurochem.* **2018**, *144*, 565–581. [[CrossRef](#)] [[PubMed](#)]
123. Kuang, H.; Zhou, Z.-F.; Zhu, Y.-G.; Wan, Z.-K.; Yang, M.-W.; Hong, F.-F.; Yang, S.-L. Pharmacological Treatment of Vascular Dementia: A Molecular Mechanism Perspective. *Aging Dis.* **2021**, *12*, 308–326. [[CrossRef](#)] [[PubMed](#)]
124. Shinohara, M.; Tachibana, M.; Kanekiyo, T.; Bu, G. Role of LRP1 in the pathogenesis of Alzheimer's disease: Evidence from clinical and preclinical studies. *J. Lipid Res.* **2017**, *58*, 1267–1281. [[CrossRef](#)] [[PubMed](#)]
125. Cheng, Y.; Tian, D.Y.; Wang, Y.J. Peripheral clearance of brain-derived Abeta in Alzheimer's disease: Pathophysiology and therapeutic perspectives. *Transl. Neurodegener.* **2020**, *9*, 16. [[CrossRef](#)]
126. Ramanathan, A.; Nelson, A.R.; Sagare, A.P.; Zlokovic, B.V. Impaired vascular-mediated clearance of brain amyloid beta in Alzheimer's disease: The role, regulation and restoration of LRP1. *Front. Aging Neurosci.* **2015**, *7*, 136. [[CrossRef](#)]
127. Deane, R.; Singh, I.; Sagare, A.P.; Bell, R.D.; Ross, N.T.; LaRue, B.; Love, R.; Perry, S.; Paquette, N.; Deane, R.J.; et al. A multimodal RAGE-specific inhibitor reduces amyloid beta-mediated brain disorder in a mouse model of Alzheimer disease. *J. Clin. Investig.* **2012**, *122*, 1377–1392. [[CrossRef](#)]
128. Schreiner, T.G.; Menéndez-González, M.; Popescu, B.O. The “Cerebrospinal Fluid Sink Therapeutic Strategy” in Alzheimer's Disease-From Theory to Design of Applied Systems. *Biomedicines* **2022**, *10*, 1509. [[CrossRef](#)]