

# UC Davis

## UC Davis Previously Published Works

### Title

Arthroscopic Anatomic Anterior Talofibular Ligament Repair for Anterolateral Ankle Instability

### Permalink

<https://escholarship.org/uc/item/48f8d4k7>

### Journal

Arthroscopy Techniques, 9(1)

### ISSN

2212-6287

### Authors

Malinowski, Konrad  
Paszkowski, Jan  
Góralczyk, Adrian  
et al.

### Publication Date

2020

### DOI

10.1016/j.eats.2019.08.008

Peer reviewed

# Arthroscopic Anatomic Anterior Talofibular Ligament Repair for Anterolateral Ankle Instability



Konrad Malinowski, M.D., Ph.D., Jan Paszkowski, M.D., Adrian Góralczyk, M.D., Eric Giza, M.D., and Krzysztof Hermanowicz, M.D., Ph.D.

**Abstract:** Ankle instability is due to repetitive inversion injuries and is usually treated conservatively; however, after repeated sprains, chronic instability occurs and usually requires a surgical procedure. Recently, arthroscopic repair of a torn anterior talofibular ligament (ATFL) has become more popular owing to its minimal invasiveness and high efficacy. An all-inside technique allows for anatomic restoration of the injured ATFL, provides stability to the ankle joint, prevents a limitation of ankle range of motion, and may prevent arthritic development. We present an all-inside arthroscopic ATFL repair technique.

Ankle sprains are reported as the most common injuries sustained during sports activities. Most ankle sprains fully recover with nonoperative treatment, but chronic ankle instability develops in 20% to 30% of patients and surgical intervention is then required.<sup>1</sup> Chronic ankle instability is generally caused by an anterior talofibular ligament (ATFL) tear. It is agreed that an avulsion is more common at the fibular attachment than at the talar attachment of the ligament.<sup>2</sup> Several arthroscopic techniques have been described recently. They can be divided into 2 categories: ligament repair or ligament reconstruction using a tendon graft or transfer.<sup>3-12</sup> The surgical procedure should be selected based on the tissue quality determined during arthroscopic assessment of the ATFL remnant.<sup>11,13</sup> The aim of this article was to present an arthroscopic technique for all-inside ATFL

repair that allows for restoration of the ankle joint stability in a minimally invasive way.

## Surgical Technique

### Indications and Contraindications

The indication for the described procedure is symptomatic, chronic anterolateral ankle instability due to an ATFL tear. The contraindication is a poor-quality or absent ATFL remnant.

### Patient Positioning

The patient is positioned supine. The foot and ankle joint should protrude over the distal end of the operating table. A nonsterile thigh tourniquet is placed on the operated leg. The ankle is draped and prepared in a sterile fashion. Indirect ankle traction is not used.

### Diagnostic Arthroscopy

Diagnostic arthroscopy is performed with a 30° arthroscope (Smith & Nephew, London, England) through standard anteromedial and low anterolateral portals. The position of the anterolateral portal, which allows for proper access to the lateral malleolus, should be identified under direct visualization with a needle. The portal is created using a No. 11 surgical blade (Fig 1). When the diagnosis of the ATFL tear is confirmed, the quality of the ATFL remnant should be assessed (Fig 2). When the tissue is not severely attenuated, an all-inside arthroscopic anatomic repair can be performed.

### All-Inside Arthroscopic Anatomic ATFL Repair

When the diameter of the lateral malleolus is greater than 15 mm, a 5-mm double-loaded titanium anchor

From Artromedical Orthopaedic Clinic (K.M., J.P.), Belchatów, Poland; ORTIM Orthopaedic Clinic (A.G., K.H.), Białystok, Poland; and Department of Orthopaedics, University of California, Davis (E.G.), Sacramento, California, U.S.A.

The authors report that they have no conflicts of interest in the authorship and publication of this article. Full ICMJE author disclosure forms are available for this article online, as [supplementary material](#).

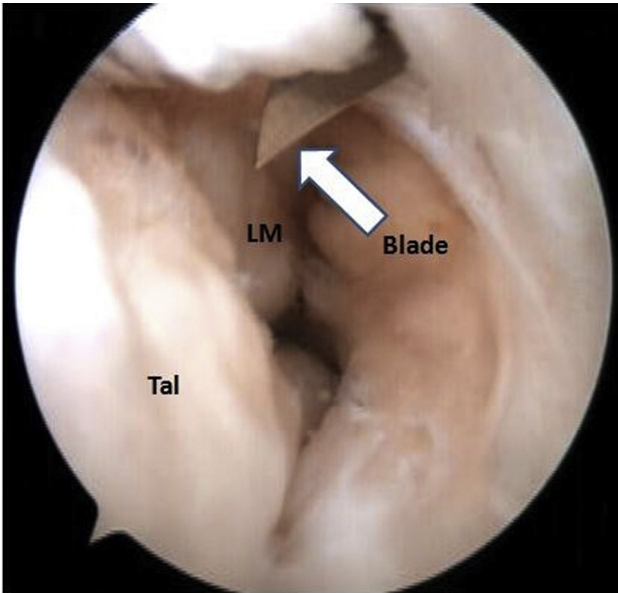
Received July 21, 2019; accepted August 24, 2019.

Address correspondence to Konrad Malinowski, M.D., Ph.D., Artromedical Orthopaedic Clinic, Chrobrego 24, 97-400 Belchatów, Poland. E-mail: [malwin8@wp.pl](mailto:malwin8@wp.pl)

© 2019 by the Arthroscopy Association of North America. Published by Elsevier. This is an open access article under the CC BY-NC-ND license (<http://creativecommons.org/licenses/by-nc-nd/4.0/>).

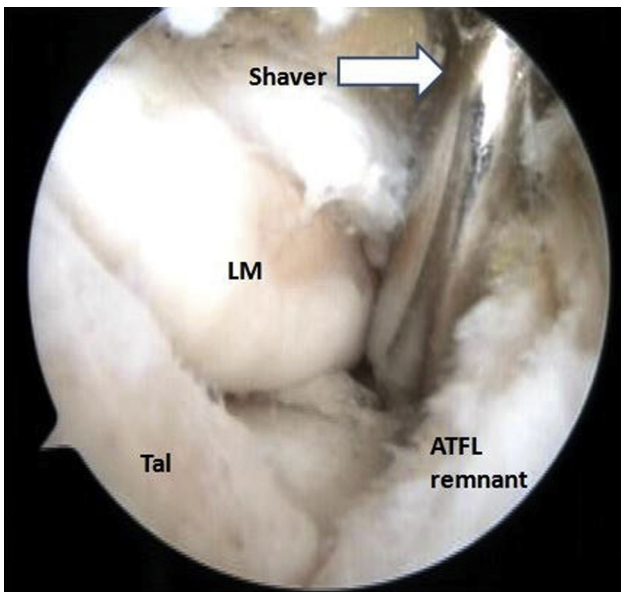
2212-6287/19922

<https://doi.org/10.1016/j.eats.2019.08.008>

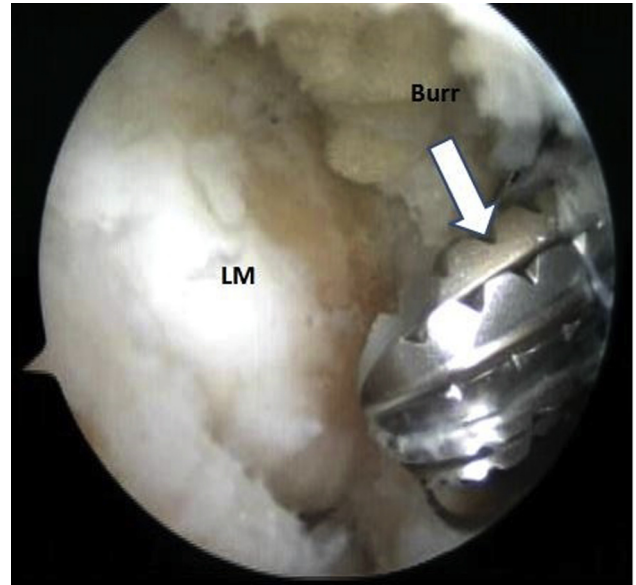


**Fig 1.** Arthroscopic view from anteromedial viewing portal in left ankle joint. A low anterolateral portal is created with a No. 11 surgical blade (arrow). (LM, lateral malleolus; Tal, talus.)

(Super Revo; ConMed, Utica, NY) is used. Under visual control, a radiofrequency probe (Smith & Nephew) and surgical scissors (Arthrocare, Austin, TX) are introduced through the anterolateral portal and used to remove the hypertrophied portion of the anterior inferior tibiofibular ligament, which can cause anterior impingement. This allows for better visualization of the lateral malleolus. Then, a shaver or arthroscopic burr (ConMed) is used to remove the hypertrophied

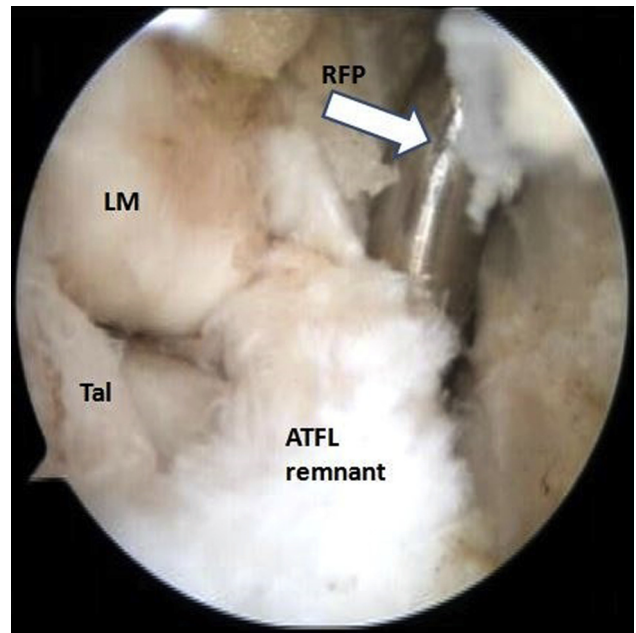


**Fig 2.** Arthroscopic view from anteromedial viewing portal in left ankle joint. Anterior talofibular ligament (ATFL) detachment from the lateral malleolus (LM) is assessed with a shaver (arrow). A good-quality ATFL remnant is present. (Tal, talus.)

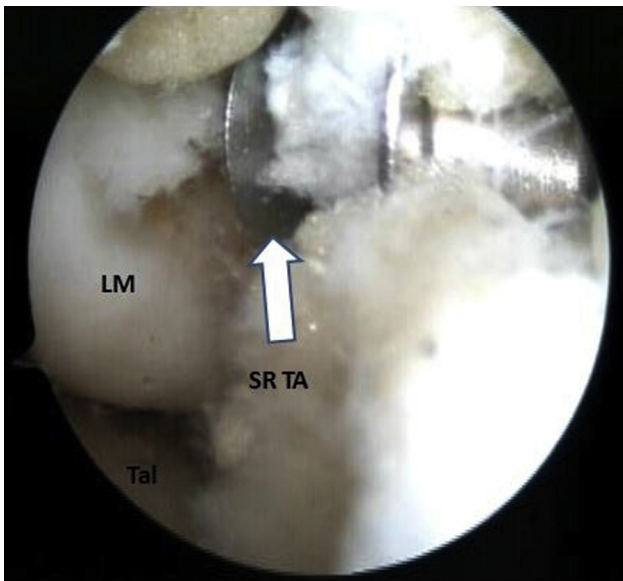


**Fig 3.** Arthroscopic view from anteromedial viewing portal in left ankle joint. An arthroscopic burr (arrow) is used to prepare the bony bed in the natural footprint of the anterior talofibular ligament on the lateral malleolus (LM).

synovium above the ATFL and prepare the bony bed in the native proximal ATFL attachment on the lateral malleolus (Fig 3). Next, the native ATFL remnant is thoroughly released from the surrounding soft tissue with a shaver and radiofrequency probe (Arthrocare) (Fig 4). The dissection begins at the talar ATFL insertion



**Fig 4.** Arthroscopic view from anteromedial viewing portal in left ankle joint. The anterior talofibular ligament (ATFL) remnant is released from the surrounding soft tissue using a radiofrequency probe (RFP, arrow). (LM, lateral malleolus; Tal, talus.)



**Fig 5.** Arthroscopic view from anteromedial viewing portal in left ankle joint. A Super Revo double-loaded titanium anchor (SR TA, arrow) is placed in the natural footprint of the anterior talofibular ligament on the lateral malleolus (LM). (Tal, talus.)

and proceeds proximally to the apex of the fibula. Finally, the ATFL remnant should be released from the joint capsule and all adhesions.

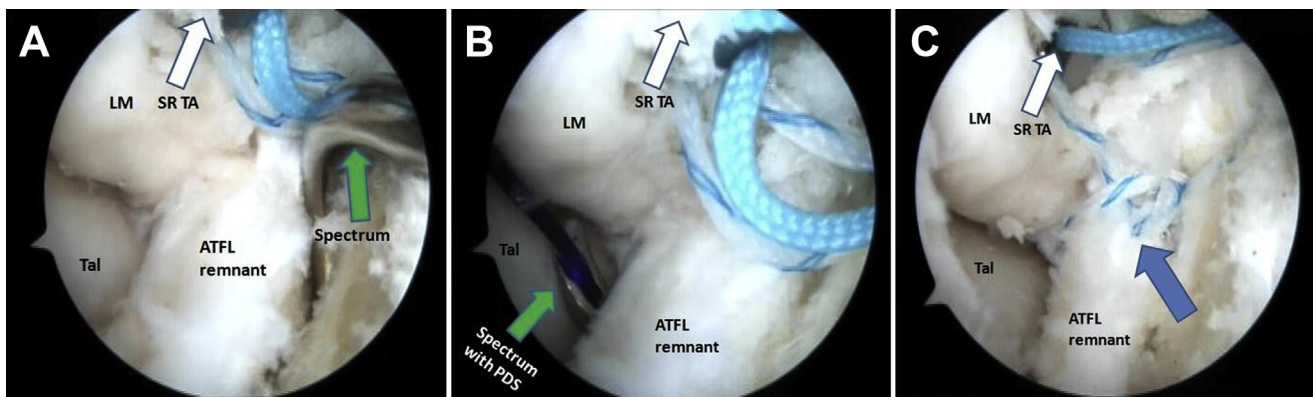
In the next step, a 5-mm double-loaded titanium anchor (Super Revo) is placed in the previously prepared bony bed in the native fibular ATFL attachment, 5 to 8 mm proximal to the apex of the lateral malleolus, in a line parallel to the ankle joint line (Fig 5). By use of a 90° left-curved Spectrum I suture passer (ConMed), a PDS I suture (Ethicon, Somerville, NJ) is pierced through the proximal part of the ATFL remnant (Fig 6). The intra-articular part of the PDS I suture and 1 strand

of the Super Revo titanium anchor are moved out of the joint using a suture retriever (ConMed) and tied at the midpoint of the Super Revo strand. The free end of the PDS I suture is pulled, passing the strand through the ATFL remnant. When the strand is not yet completely passed through the ATFL, it forms a loop outside the joint. The free end of the same strand should be passed through this loop to form a lasso-loop suture on the ATFL remnant. Then, a knot pusher (ConMed) is used to tie the sutures (Fig 7). The aforementioned maneuvers are repeated with the second strand from the Super Revo titanium anchor. The final result of surgery is shown in Figure 8.

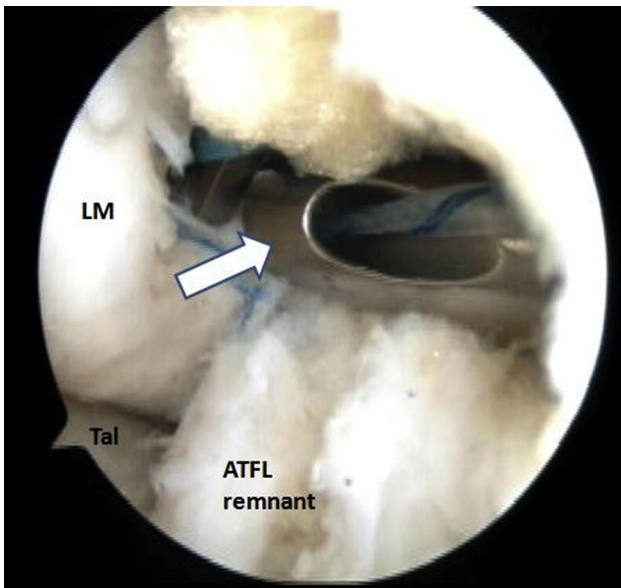
When the lateral malleolus is small, with a diameter below 15 mm, or the ATFL remnant has a small diameter, a single-loaded all-suture anchor (1.5-mm JuggerKnot Soft Anchor; Zimmer Biomet, Warsaw, Poland) can be used while performing the same steps described earlier. After repair, the sufficiency of the ATFL can be checked by using an arthroscopic hook probe or by performing the anterior drawer test and talar tilt test under arthroscopic visualization. Video 1 illustrates the surgical technique.

### Rehabilitation

The patient is immobilized in a Genesis pneumatic shoe (Breg, Carlsbad, CA) with toe-touch weight bearing using crutches for 6 weeks. Scar massage and soft-tissue mobilization start in the second post-operative week. After the third week, active ankle dorsiflexion between 0° and maximum can be performed, with a flexed and extended knee and with weight bearing as tolerated. Between 6 and 12 weeks postoperatively, a dynamic Ankle Axiom brace (Breg) is used for walking without range-of-motion restrictions. A gradual progression in ankle plantar flexion and muscle exercises occurs. After 12 weeks and up to



**Fig 6.** Arthroscopic view from anteromedial viewing portal in left ankle joint. A Spectrum I suture passer (green arrow) loaded with PDS suture is pierced through the proximal part of the anterior talofibular ligament (ATFL) remnant (A), and the PDS suture is slid into the joint (B) and then changed with 1 strand from the Super Revo titanium anchor (SR TA, white arrow) such that it forms a “lasso loop” (blue arrow) on the ATFL remnant (C). The maneuver should be repeated with the second strand. (LM, lateral malleolus; Tal, talus.)

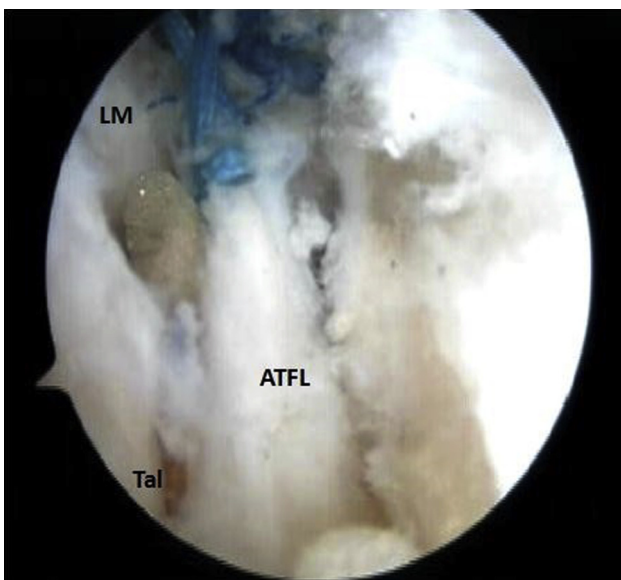


**Fig 7.** Arthroscopic view from anteromedial viewing portal in left ankle joint. An arthroscopic knot pusher (arrow) is used to tie knots on the lasso loops; this reattaches the anterior talofibular ligament (ATFL) remnant to its natural footprint on the lateral malleolus (LM). (Tal, talus.)

6 months, the brace is only used during activity, with gradual weaning.

### Discussion

This article describes an all-inside arthroscopic anatomic ATFL repair that allows restoration of ankle joint stability. As shown, different implants can be used depending on the size of the lateral malleolus. A



**Fig 8.** Arthroscopic view from anteromedial viewing portal in left ankle joint. The repaired anterior talofibular ligament (ATFL) is shown. (LM, lateral malleolus; Tal, talus.)

**Table 1.** Advantages and Disadvantages of Arthroscopic Anatomic ATFL Repair for Anterolateral Ankle Instability

#### Advantages

- Anatomic reconstruction is performed, which avoids overloading the ankle joint and prevents early arthritis development.
- Invasiveness is low, which reduces postoperative pain and enables a faster recovery.
- Synovial injury is reduced, which limits adhesion formation.
- It is possible to diagnose and treat concomitant intra-articular lesions.
- Proper implant selection avoids most complications of surgery.

#### Disadvantages

- The technique is only possible when the quality of the ATFL remnant is good.
- High surgical skills are required.
- The technique entails specific risks such as superficial fibular nerve injury, lateral malleolus cortex fracture, and implant migration or loosening.

ATFL, anterior talofibular ligament.

double-loaded suture anchor is used in the case of a complete ATFL tear, providing a firm repair that allows for proper stability and a high rate of healing. This implant should be used only when the diameter of the lateral malleolus is at least 3 times greater than the diameter of the double-loaded suture anchor. Keeping this rule in mind will prevent the serious complication of a lateral malleolus fracture or impingement of the anchor on the surrounding soft tissue.<sup>4,10</sup> In the case of a partial ATFL tear or a small diameter of the lateral malleolus, a single-loaded suture anchor should be sufficient. This provides adequate stability and reduces the risk of the aforementioned complication.

As an arthroscopic technique, an all-inside anatomic ATFL repair provides all the advantages of minimally invasive surgical techniques (Table 1). There is less trauma to the surrounding tissue than in the case of open surgery, which reduces postoperative pain and permits an early rehabilitation protocol, leading to a faster recovery.<sup>3-6,8,10,11</sup> Using only 2 arthroscopic portals limits synovial injury, which reduces the risk of excessive edema and avoids extensive adhesion formation. Moreover, arthroscopic visualization of the joint enables one to anatomically restore the course of the ATFL from its fibular to talar footprint. It has been proved that an anatomic repair provides proper joint stability and permits a full range of ankle motion and an adequate load distribution in the ankle and subtalar joints, which in consequence diminishes the risk of future osteoarthritis development.<sup>14</sup> Moreover, direct visualization of the ankle joint gives one a chance to recognize and treat concomitant intra-articular pathologies such as soft-tissue impingement, ossicles at the lateral malleolus, syndesmosis widening, or osteochondral lesions in a 1-stage procedure.<sup>15</sup> Arthroscopic visualization of the ATFL also allows one to decide whether to perform repair or reconstruction.

The described technique also has some disadvantages. First, this surgical procedure has a high learning curve and needs to be performed by a surgeon with experience in arthroscopy of the ankle joint because it is technically difficult. Second, the specific instruments and implants can raise the cost of procedure. The key factor influencing the final result is proper patient selection. An anatomic repair can be performed only in patients with preservation of a good-quality ATFL remnant.<sup>13</sup> Moreover, the presented surgical technique has some specific risks, such as superficial fibular nerve (intermediate dorsal cutaneous nerve) injury during anterolateral portal creation, improper suture anchor placement causing impingement with soft tissue, suture anchor migration or loosening, or fracture of the lateral malleolus cortex. However, these complications can be avoided when surgery is performed carefully using the steps outlined in this article. Advantages and disadvantages of arthroscopic anatomic ATFL repair are summarized in Table 1.

## References

- Guillo S, Bauer T, Lee JW, et al. Consensus in chronic ankle instability: Aetiology, assessment, surgical indications and place for arthroscopy. *Orthop Traumatol Surg Res* 2013;99:S411-S419 (suppl).
- Kumai T, Takakura Y, Rufai A, Milz S, Benjamin M. The functional anatomy of the human anterior talofibular ligament in relation to ankle sprains. *J Anat* 2002;200:457-465.
- Takao M, Matsui K, Stone JW, et al. Arthroscopic anterior talofibular ligament repair for lateral instability of the ankle. *Knee Surg Sports Traumatol Arthrosc* 2016;24:1003-1006.
- Vega J, Guelfi M, Malagelada F, Peña F, Dalmau-Pastor M. Arthroscopic all-inside anterior talofibular ligament repair through a three-portal and no-ankle-distraction technique. *JBJS Essent Surg Tech* 2018;8:e25.
- Matsui K, Takao M, Miyamoto W, Innami K, Matsushita T. Arthroscopic Broström repair with Gould augmentation via an accessory anterolateral port for lateral instability of the ankle. *Arch Orthop Trauma Surg* 2014;134:1461-1467.
- Vega J, Golanó P, Pellegrino A, Rabat E, Peña F. All-inside arthroscopic lateral collateral ligament repair for ankle instability with a knotless suture anchor technique. *Foot Ankle Int* 2013;34:1701-1709.
- Guillo S, Archbold P, Perera A, Bauer T, Sonnery-Cottet B. Arthroscopic anatomic reconstruction of the lateral ligaments of the ankle with gracilis autograft. *Arthrosc Tech* 2014;3:e593-e598.
- Cottom JM, Rigby RB. The “all inside” arthroscopic Broström procedure: A prospective study of 40 consecutive patients. *J Foot Ankle Surg* 2013;52:568-574.
- Acevedo J, Mangone PG. Arthroscopic lateral ankle ligament reconstruction. *Tech Foot Ankle Surg* 2011;10:111-116.
- Pereira H, Vuurberg G, Gomes N, et al. Arthroscopic repair of ankle instability with all-soft knotless anchors. *Arthrosc Tech* 2016;5:e99-e107.
- Vega J, Montesinos E, Malagelada F, Baduell A, Guelfi M, Dalmau-Pastor M. Arthroscopic all-inside anterior talofibular ligament repair with suture augmentation gives excellent results in case of poor ligament tissue remnant quality [published online August 20, 2018]. *Knee Surg Sports Traumatol Arthrosc*, <https://doi.org/10.1007/s00167-018-5117-x>.
- Gui J, Jiang Y, Li Y, et al. All arthroscopic remnant-preserving technique to reconstruct the lateral ankle ligament complex. *Arthrosc Tech* 2017;6:e549-e557.
- Yasui Y, Takao M. Comparison of arthroscopic and histological evaluation of the injured anterior talofibular ligament. Presented at the Annual Meeting of the American Academy of Orthopaedic Surgeons, Chicago, IL, March 2013.
- Nery C, Raduan F, Del Buono A, Asaumi ID, Cohen M, Maffulli N. Arthroscopic-assisted Broström-Gould for chronic ankle instability: A long-term follow-up. *Am J Sports Med* 2011;39:2381-2388.
- Choi WJ, Lee JW, Han SH, Kim BS, Lee SK. Chronic lateral ankle instability: The effect of intra-articular lesions on clinical outcome. *Am J Sports Med* 2008;36:2167-2172.