

UC Irvine

UC Irvine Previously Published Works

Title

Correlation between confirmed sites of neurological lesions and abnormalities of far-field auditory brainstem responses

Permalink

<https://escholarship.org/uc/item/49d3g4km>

Journal

Clinical Neurophysiology, 41(6)

ISSN

1388-2457

Authors

Starr, A
Hamilton, AE

Publication Date

1976-12-01

DOI

10.1016/0013-4694(76)90005-5

Copyright Information

This work is made available under the terms of a Creative Commons Attribution License, available at <https://creativecommons.org/licenses/by/4.0/>

Peer reviewed

CORRELATION BETWEEN CONFIRMED SITES OF NEUROLOGICAL LESIONS AND ABNORMALITIES OF FAR-FIELD AUDITORY BRAINSTEM RESPONSES *

A. STARR ** and A.E. HAMILTON

Division of Neurology, Department of Psychobiology, and Department of Pathology, University of California, Irvine, Calif. 92664 (U.S.A.)

(Accepted for publication: April 8, 1976)

Auditory brainstem responses are presumed to be the far-field reflection of electrical events generated in the lower portions of the auditory pathway (Jewett 1970). The response, when recorded in man with scalp electrodes and computer averaging techniques, consists of seven components during the initial 10 msec following click signals with amplitudes in the submicrovolt range (Jewett and Williston 1971). Both the amplitude and latency of the response components change in an orderly manner as a function of signal intensity (Hecox and Galambos 1974; Starr and Achor 1975). Alterations of auditory brainstem responses have been described in various neurological disorders in which the correlations between the response abnormalities and the site of pathology has depended principally on clinical information (Sohmer et al. 1974; Starr and Achor 1975; Starr 1976). This paper presents the auditory brainstem responses from eight cases in whom the distribution of the brainstem lesions was confirmed at autopsy. Two additional patients in whom the site of brainstem pathology was defined at the time of operation are also presented.

Methods

The technique of recording and measuring auditory brainstem responses has been described previously (Starr and Achor 1975). In brief, responses are recorded at the bedside from conventional surface electrodes at the vertex and the earlobes (C_z to A_1 or A_2). Click signals are presented monaurally through cushion type earphones at signal intensities from threshold to 75 dB H.L. (hearing level of normal adult subjects). The click rate employed is 10/sec and a total of 2,048 click trials comprises a single average. Duplicate averages are made at each signal intensity to assess reproducibility of results. The results are plotted and the latency and amplitude of the various components are measured from these records.

All of the patients included in the study were examined for neurological abnormalities. A brief case description of the salient clinical findings with appropriate laboratory data are included.

Autopsies were performed on the patients. The whole brain was fixed by immersion in neutral buffered 10% formalin. The brainstem was serially sectioned into 0.5 cm slices in a plane perpendicular to its base. The right side of each slice was notched and the pieces were embedded in paraffin. From each block, one slide was prepared and stained with Hematoxylin and eosin, Luxol fast blue, and the Bielschowski ammoniacal silver method. If any of the portions of the auditory tract and

* The study was supported in part by Grant PHS NS 11876 from the U.S. Public Health Service. Presented in brief at the American Academy of Neurology Meeting, Miami Beach, Fla., April 1975.

** Reprint requests should be sent to Dr. Arnold Starr, Neurology, 101 City Drive South, Orange, Calif. 92668.

nuclei were missed additional step sections of the appropriate block were taken.

The slides were examined under the microscope by one of us (AH) who had not seen the auditory brainstem response studies. The distribution of the pathology was marked off on the slide with a felt tip pen. Then the three slides of each area were aligned and placed on a Buhl overhead projector. The composite image was projected onto outline diagrams of the brainstem. The areas with pathology were traced onto the diagrams to define the distribution of the pathological changes.

I. Auditory brainstem responses in extra-medullary lesions of the cerebello-pontine angle

Case 1

The patient was a 22-year-old man who felt unsteady. Skull X-rays revealed erosion of the internal auditory canal on the left. The neurological and audiological examinations were entirely normal. Vestibular tests defined a slight canal paresis on the left.

Auditory brainstem responses to left monaural clicks at 65 dB H.L. contained a Wave I at 1.9 msec and a Wave II at 3.2 msec without any other components (Fig. 1, "Neuroma"). A normal response pattern is included at the top of the figure ("Normal"). The latencies of these two components in neurologically intact and normal hearing subjects at these signal intensities are 1.6 and 2.8 msec respectively.

At time of operation an acoustic neuroma was found on the left.

Case 2

The patient was a 45-year-old man with a meningioma on the left side of the brainstem extending from the level of the glossopharyngeal nerve to the cerebello-pontine angle defined at time of operation. His neurological findings included decreased sensation on the left side of the face, slight paresis of the left lateral rectus, weakness of the left side of the face, "diminished" hearing in the left ear,

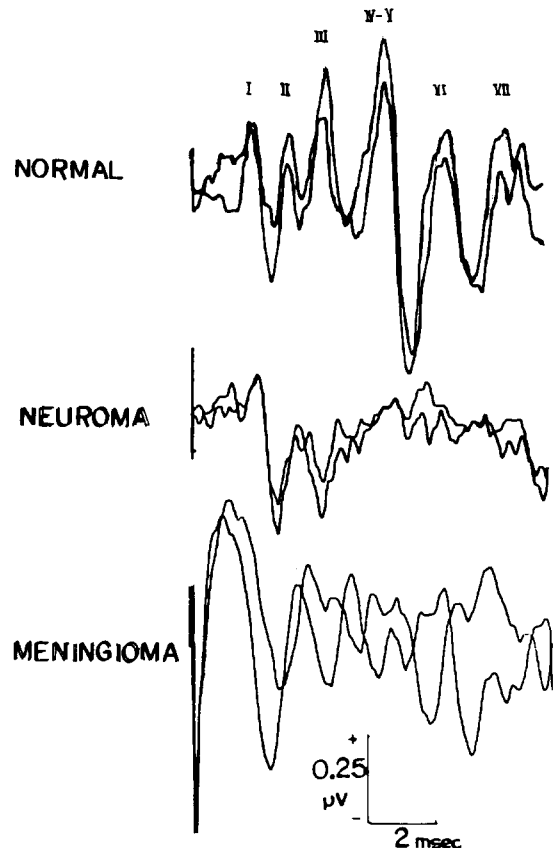


Fig. 1. Auditory brainstem responses from a normal subject (top) compared with responses from two patients with lesions of the cerebello-pontine angle. The middle tracing is the response from a case with an acoustic neuroma. The bottom tracing is the response from a case with a meningioma. The roman numerals above the normal response designate the various components. Signal intensity was 65 dB H.L. Recordings are between vertex (C_z) and the earlobe on the side receiving the click signal. Two separate averages of 2,048 click trials at 10/sec make up the responses. The deflections at the onset of the tracings in this and the subsequent figures represent the inadvertent recording of the stimulus voltage applied to the earphones.

absent ocular responses to cold caloric stimulation of the left labyrinth, and depressed gag reflex on the left. There was a slight intention tremor of the left arm. There was no paresis, the plantar responses were flexor, and sensation over the body was normal.

Auditory brainstem responses to left

monaural clicks at 65 dB H.L. (Fig. 1, "Meningioma") contained a Wave I at 1.5 msec without any other components evident.

Comment. In these two cases of extramedullary lesions at the level of the VIII cranial nerve's entrance to the brainstem there was a loss of the auditory brainstem response components numbered III through VII. Wave I in both cases and Wave II in Case 1 were the only elements that persisted. Thus the initial components (I, and perhaps II) of the response most likely represent activity in the VIII nerve extrinsic to the brainstem.

II. Auditory brainstem responses in focal brainstem lesions

Case 3

The patient was an 18-year-old man with a midbrain tumor. The initial symptoms were of headache, diplopia, left-sided weakness and personality change. The examination showed papilledema, paralysis of upward gaze, and a left hemiparesis. Contrast studies showed that the lateral and third ventricles were enlarged and that a mass impinged on the aqueduct of Sylvius. A ventricular-atrial shunt was placed but the patient continued to deteriorate. Two weeks before death the patient was comatose with dilated and fixed pupils. The eye movements evoked by cold caloric vestibular stimulation were compatible with a medial longitudinal fasciculus syndrome.

Auditory brainstem response (Fig. 2) to monaural clicks showed Waves I, II and III to be intact but the subsequent components were absent except for a small IV-V wave at prolonged latency to monaural right stimulation. Waves II and III were prolonged in latency compared to normal values whereas Wave I was of normal latency. In this and all subsequent figures the representations of the distribution of the neuropathological abnormalities are in the left hand side of figure, the normal pattern of auditory brainstem responses are in the top right of the figure, and the responses from the patient to

both right (R) and left (L) click signals are in the lower right of the figure.

Pathologic description. Most of the midbrain and the tegmentum of the pons was obliterated by a hemorrhagic mass (Fig. 2). Microscopically, the mass consisted of a ring of germinoma cells surrounding a large hematoma. Except for portions of cerebral peduncles, the mass replaced the midbrain. The caudal pons was replaced by blood and tumor ventrally to the medial lemniscus. The caudal portion of the floor of the fourth ventricle and the right medial and the lateral lemnisci were obliterated by the tumor. The left lateral lemniscus was not affected. The medulla was normal.

Diagnosis. Germinoma of the pineal gland involving the upper brainstem with hemorrhage into the tumor.

Case 4

The patient was a 22-year-old female with tuberous sclerosis. She was mentally retarded with petit mal and grand mal seizures from infancy. In March 1970, bilateral carotid angiogram revealed a right frontal tumor which was biopsied and found to be an astrocytoma. Bilateral ventricular shunts were placed and she received 5000 rads of radiation to the brain. In August 1973, the pertinent clinical findings included adenoma sebaceum of the face. She would close her eyes to command but would only say the word "fine". She was blind. The pupils were 4 mm and only slightly reactive to light. There was fine nystagmus present both at rest and on lateral gaze. She tended not to look to the left. The corneal reflexes were present bilaterally. There was a left central facial paresis. The gag reflex was present. The limbs were bilaterally paretic. The deep tendon reflexes were 2+ in the upper extremity and absent in the lower extremities. Plantar stimulation did not evoke a Babinski response. She gradually deteriorated over the next 3 weeks becoming comatose with decerebrate postures in the left upper extremity and decorticate postures in the right upper extremity. There were now

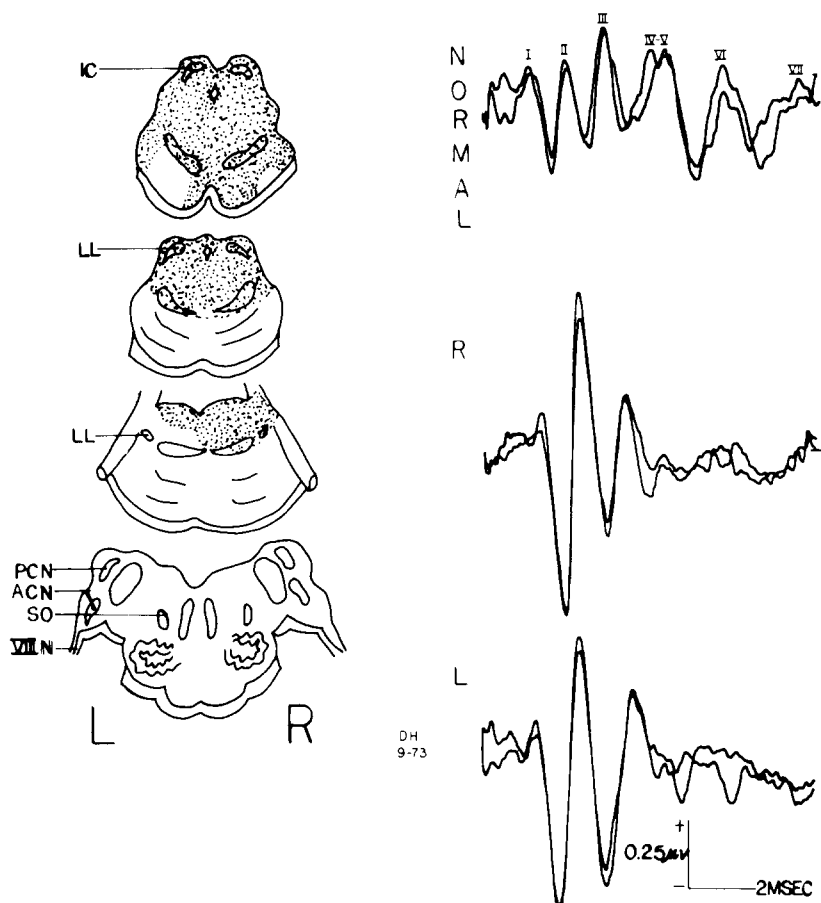


Fig. 2. A composite of the distribution of the neuropathology indicated by stipples (left) and auditory brainstem responses from a patient with a germinoma. A normal response pattern is included for comparison. R and L refer to the side of monaural click presentation, right (R) or left (L). This same format is used in all subsequent figures. IC, inferior colliculus; LL, lateral lemniscus; PCN, posterior cochlear nucleus; ACN, anterior cochlear nucleus; SO, superior olivary nucleus; VIII N, VIII cranial nerve.

bilateral Babinski responses. The corneal reflexes were reduced and there was only a trace of a gag response. She expired 2 weeks later.

Auditory brainstem responses were tested 2 weeks before death (Fig. 3). Responses to left monaural clicks at 65 dB H.L. showed only a Wave I without any other components. Responses to the clicks in the right ear showed all components to be present but the amplitude of the IV–V complex was approximately one-half of the amplitude of Wave I. In normal individuals the ratio of the amplitudes of the IV–V complex to Wave I at 65

dB H.L., i.e., IV–V/I, is usually greater than 1.0 (mean ratio, 1.60).

Pathologic description. The left inferior colliculus and lateral lemniscus, the periaqueductal gray matter, the floor of the fourth ventricle, and the left vestibular and cochlear nuclei were replaced by uniform sheets of gemistocytic tumor astrocytes (Fig. 3). A small focus of tumor was also present in the mid portion of the right vestibular nucleus.

Diagnosis. Tuberosus sclerosis with gemistocytic astrocytoma involving the left midbrain and brainstem.

Comment. The relationship between the

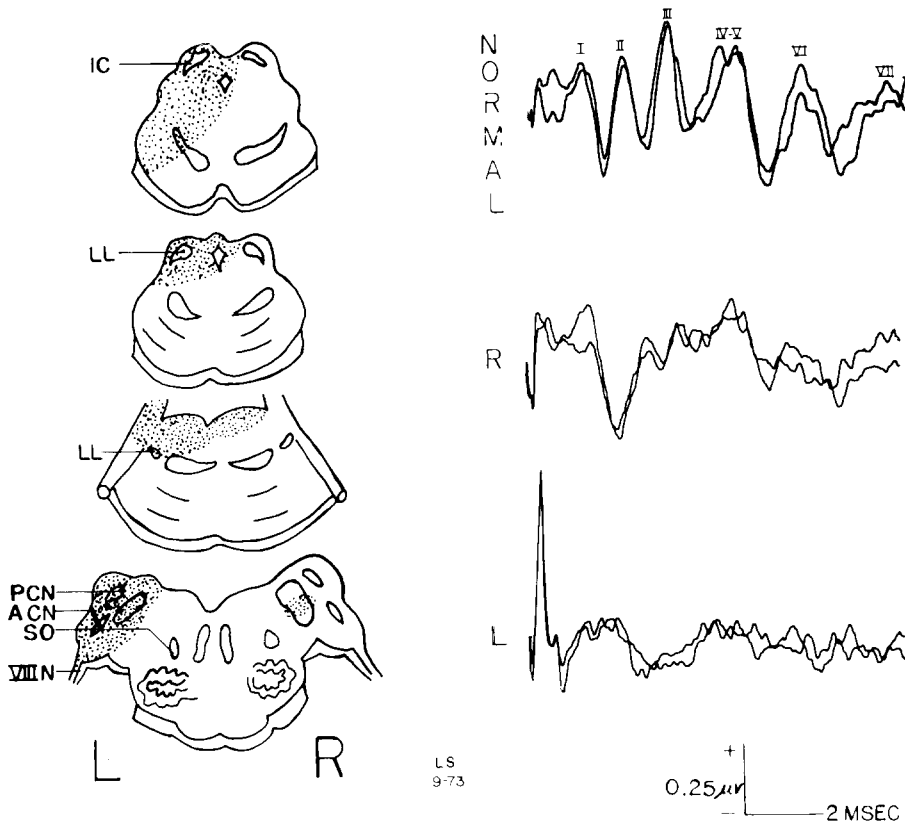


Fig. 3. The distribution of neuropathology and auditory brainstem responses in a patient with tuberous sclerosis.

site of brainstem pathology and alterations of auditory brainstem responses is instructive in these two patients. In Case 3, the tumor totally destroyed the midbrain and a portion of the rostral pons. The caudal brainstem containing the cochlear nuclei, trapezoid bodies and superior olive were grossly spared. Correspondingly Waves IV through VII were essentially absent from the response. The intactness of the midbrain is therefore essential for the detection of components IV through VII. The prolonged latencies of Waves II and III could reflect the effects of pressure from the tumor on conduction along the auditory pathway within the medulla.

In Case 4, the presence of tumor in the cochlear nuclei on the left was associated with the presence of only a Wave I similar to the results obtained in the patients with the cerebellopontine angle tumors (Cases 1 and 2). Thus

blockade of the auditory pathway at the level of the VIII nerve due either to extrinsic or to intrinsic brainstem pathology is accompanied by the loss of all response components after Wave I. Case 4 also demonstrates that partial midbrain lesions can depress the amplitude of the IV–V complex.

III. Auditory brainstem responses in widespread brainstem lesions due to tumor, infarction and encephalomalacia

Case 5

The patient was an 8-year-old boy with a brainstem glioma. The initial symptoms were of altered behavior and diplopia. At the time of auditory brainstem response testing he was comatose with fixed and dilated pupils. Cold caloric stimulation of the right ear caused a slow tonic deviation of the left eye towards

the stimulated side but no movement of the right eye. Cold caloric stimulation of the left ear was without effect. He was bilaterally spastic with extensor plantar responses.

Auditory brainstem responses (Fig. 4) consisted of only a Wave I to clicks in the left ear and no discernable components to clicks in the right ear.

Pathologic description. The architecture of the midbrain and pons was completely obliterated by a diffuse astrocytoma (Fig. 4). The tumor ended just caudal to the pontomedullary junction.

Diagnosis. Brainstem glioma.

Case 6

The patient was a 55-year-old hypertensive man who was found unresponsive one morn-

ing. He appeared unconscious except for the ability to make slight vertical eye movements and weak lid closure to command. The respirations were slow at 8/sec. Blood pressure was 180/110. The pupils were miotic but reacted to light. The corneal reflexes were weakly present. Lateral eye movements could not be elicited by either oculoccephalic reflexes or cold caloric stimulation of the labyrinths. The patient's hearing was sufficient to enable him to shut his eyes on verbal command. The upper limbs were flaccid and the lower limbs were spastic with sustained ankle clonus. The tendon reflexes were absent and the plantar responses were extensor. The sensory exam could not be satisfactorily evaluated.

The clinical impression was of a brainstem infarction producing the "locked-in" syn-

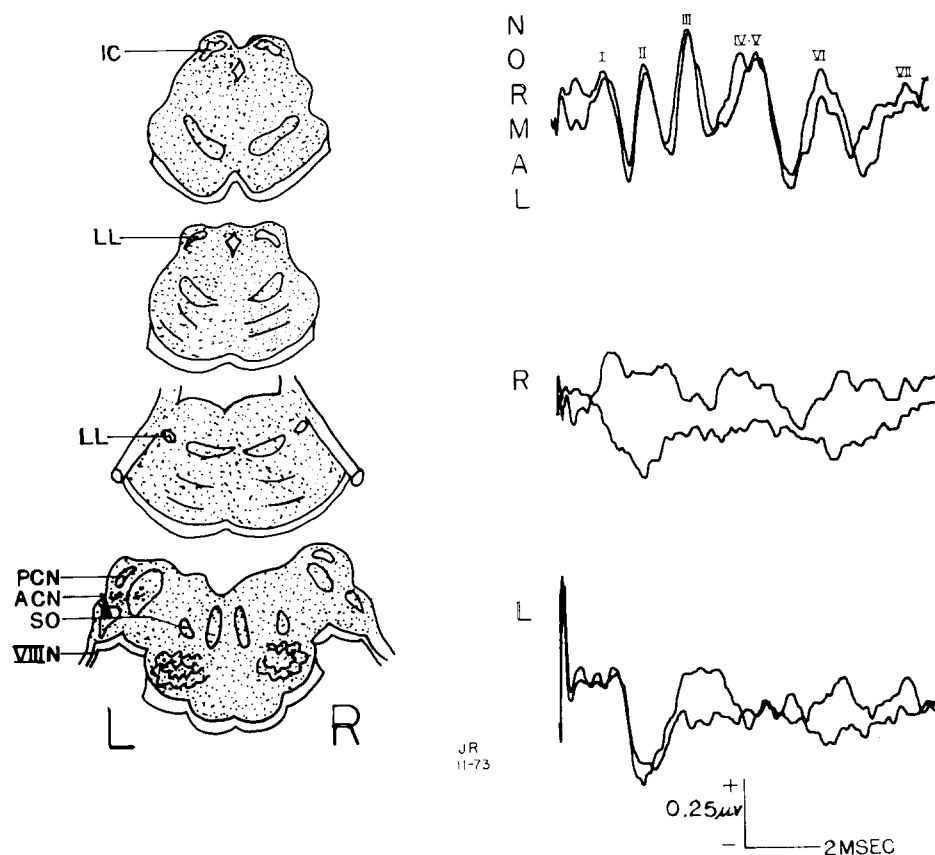


Fig. 4. The distribution of neuropathology and auditory brainstem responses in a patient with a brainstem glioma.

drome. Over the next few days the clinical condition remained unchanged except for the appearance of ocular bobbing and ataxic respiration. On the sixth hospital day he became unresponsive and expired.

Auditory brainstem responses on the second hospital day showed the presence of low amplitude components (Waves I and IV—V complex) to clicks in the right ear but no response to clicks in the left ear (Fig. 5). The amplitude of the IV—V complex was approximately one fourth of that normally encountered.

Pathologic description. Only the pons and medulla were available for gross examination. They consisted of a mass of pale necrotic tissue (Fig. 5).

Diagnosis. Brainstem infarction, recent.

Case 7

The patient was a 21-year-old heroin addict admitted to hospital in coma. The respirations were irregular in rate and depth requiring mechanical assistance for adequate ventilation. The pupils were miotic and unreactive to light. Eye movements could not be elicited

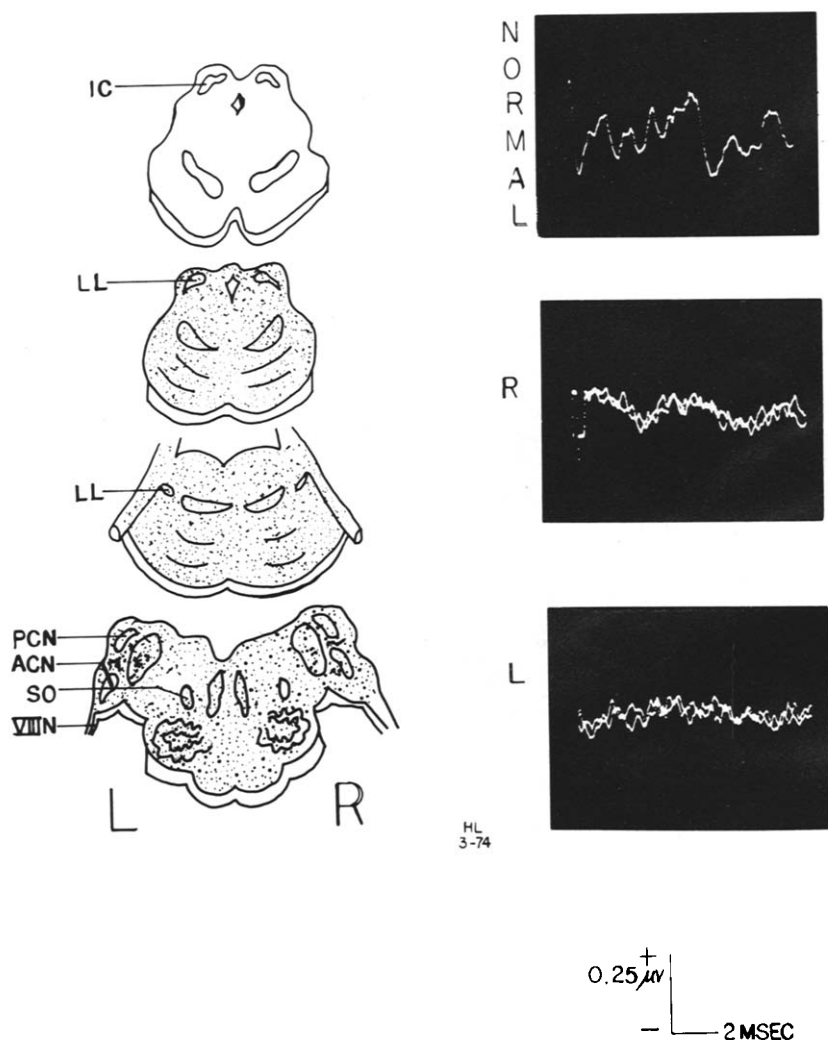


Fig. 5. The distribution of neuropathology and auditory brainstem responses in a patient with a brainstem infarction. The most rostral section was not available for study.

by oculocephalic or caloric vestibular tests. The patient expired on the fifth hospital day.

Auditory brainstem responses were recorded on the second hospital day (Fig. 6). To clicks in the right ear the initial three waves (I, II, III) were evident but of slightly prolonged latency. The response to clicks in the left ear was obscure but a Wave I and a component at the appropriate latency for the IV-V wave was evident. All of the response components were reduced in amplitude compared to normal.

Pathologic description. The abnormalities were evident only on microscopic examination (Fig. 6). There were patches of recent encephalomalacia consisting of disintegration of the nerve fibers and myelin with micro-

cystic changes. They involved the collicular plate, the left border of the midbrain from the colliculus to the left edge of the cerebral peduncle, and a small portion of the right substantia nigra. The right lateral lemniscus was involved in the anterior pons. There were patchy lesions affecting portions of the left lateral and medial portions of the basis pontis, the periaqueductal gray matter, and the right lateral and medial lemnisci. The superior aspect of the left vestibular nucleus was necrotic.

Diagnosis. Early encephalomalacia.

Comment. In these three patients with widespread brainstem lesions, auditory brainstem responses were significantly altered. Wave I was the clearest component detected

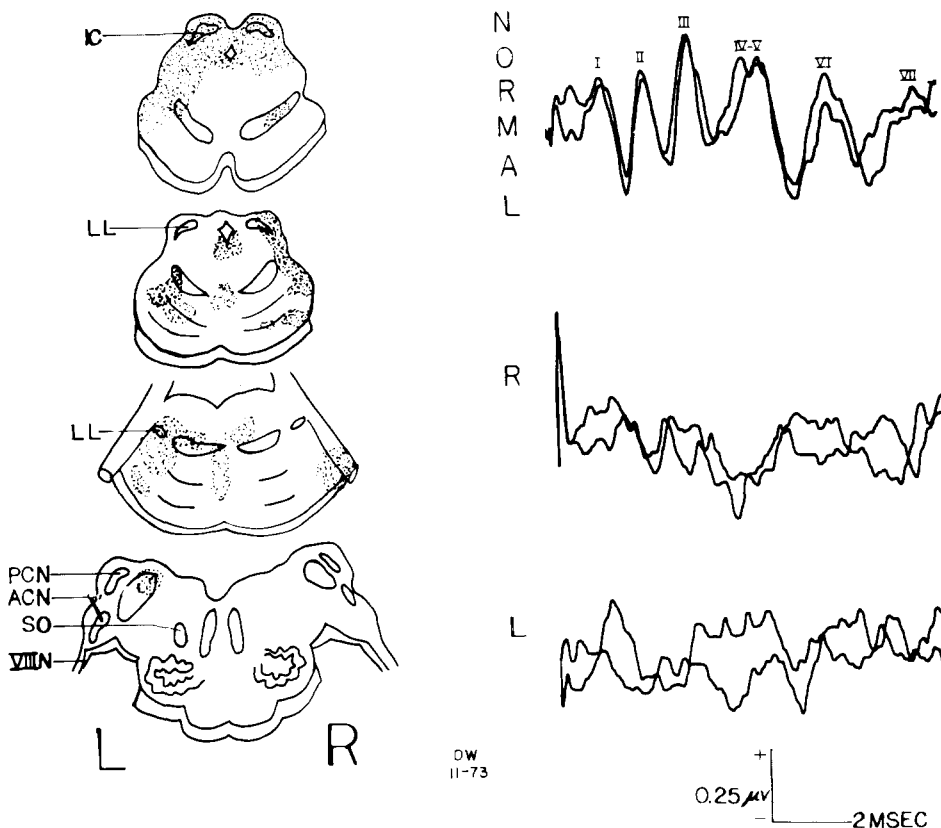


Fig. 6. The distribution of neuropathology and auditory brainstem responses in a patient with patchy encephalomalacia.

in these three individuals whereas the subsequent components were either absent or significantly altered in latency or amplitude rendering their designation difficult.

IV. Auditory brainstem responses in widespread brainstem lesions due to anoxia

Case 8

The patient was a 21-year-old man who suffered an anoxic episode due to aspiration of a food particle and was subsequently resuscitated. He remained in coma over the next 14 days when he expired. Initially he had generalized seizures, then became decerebrate, and finally lost brain and brainstem functions.

Auditory brainstem responses were recorded on the tenth hospital day at a time when his neurological exam and EEG were compatible with brain death (Fig. 7). Note

that the response to a 65 dB H.L. click consisted of only a Wave I of prolonged latency compared to the normal record.

Pathologic description. The lesions, which could be seen only by microscopy, consisted of patches of smudging and microvacuolization of the neuropil. The neurons were swollen. No microgliosis, astrocytosis, or inflammatory exudates were seen.

The pathology involved included the entire right inferior colliculus and portions of the left inferior colliculus, the periaqueductal gray matter, the right substantia nigra, and part of the right cerebral peduncle (Fig. 7). With the exception of the most anterior 2 mm, the entire base of the superior pons was involved and the pathological changes extended superiorly to involve the medial lemnisci. In the caudal pons, there were patchy changes

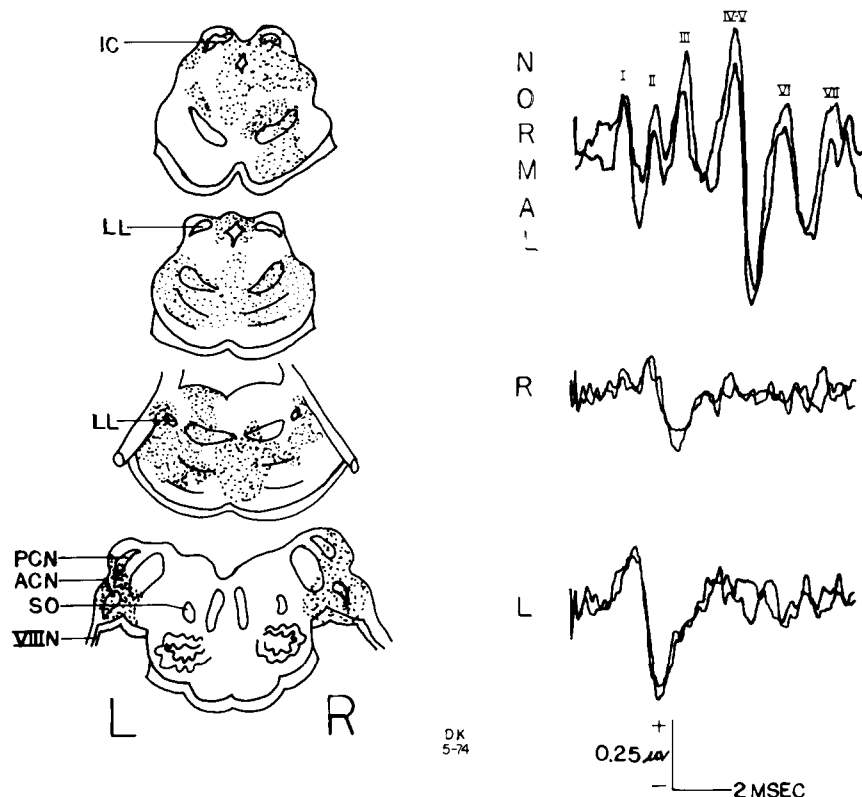


Fig. 7. The distribution of neuropathology and auditory brainstem responses in a patient with anoxic brain damage.

involving both lateral lemnisci, portions of the medial lemnisci, and the left tegmentum. In the rostral medulla, both the anterior and posterior cochlear nuclei were abnormal.

Diagnosis. Anoxic encephalopathy.

Case 9

On the day of admission this 15-month-old child fell from his bed onto a carpeted floor, then walked into his parent's room and had a generalized seizure lasting 2–3 min. On admission to the hospital he was in coma, the respirations were shallow and irregular, the blood pressure was 120/80, and the pulse was 80 and regular. The pupils were dilated to 6 mm and unresponsive to light. There were hemorrhages in the right fundus. The oculocephalic, oculovestibular, and corneal reflexes

were absent. The limbs were flaccid and movements were limited to spinal reflex leg withdrawal to painful stimuli. The deep tendon reflexes were 1+ and the plantar responses were flexor. The day after admission bilateral subdural taps were performed which did not produce blood. Spontaneous respirations ceased at that point and artificial respiration was required. The patient expired on the second hospital day.

Auditory brainstem responses to 65 dB H.L. clicks in the left ear showed that only Wave I was present.

Pathologic description. The microscopically recognizable lesions consisted of coagulative necrosis of the neuropil, swelling and pyknosis of neurons, and vacuolization of the gray and white matter. In the rostral pons irregular foci

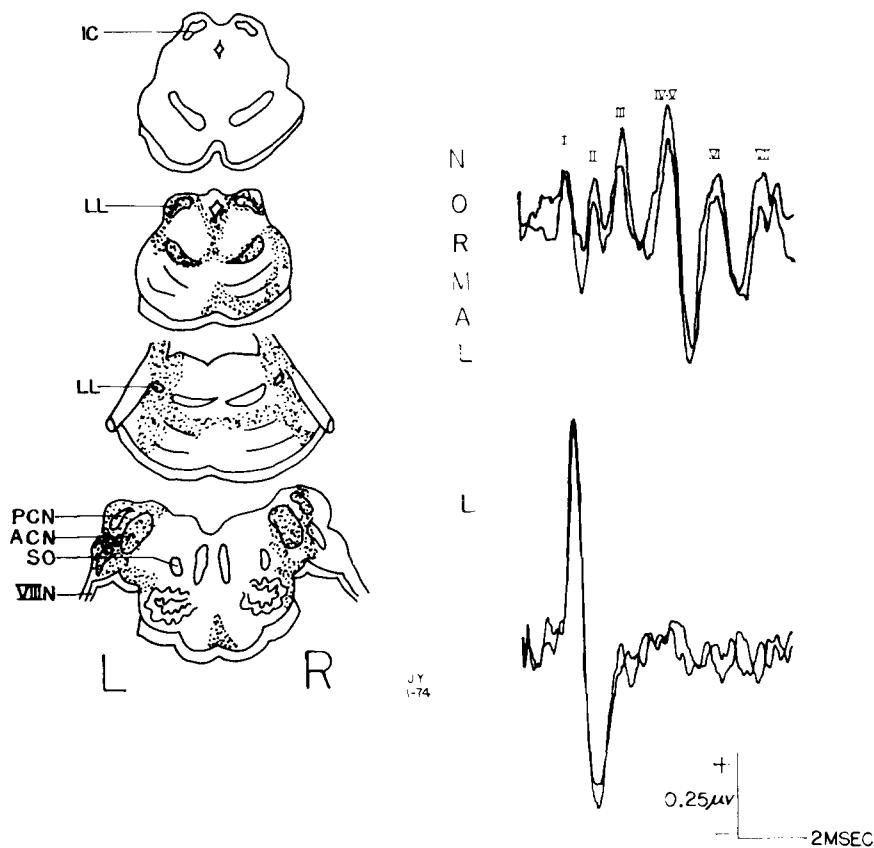


Fig. 8. The distribution of neuropathology and auditory brainstem responses in a patient with anoxic brain damage. The most rostral section was not available for study.

of these changes were found in periaqueductal gray matter, both lateral and medial lemnisci, and lateral and inferior border of the right basis pontis (Fig. 8). In the caudal pons, the lateral lemnisci, the lateral edges of the tegmentum and a narrow band in the central pons were affected. The vestibular and cochlear nuclei were involved bilaterally. The midbrain was not available for study.

Diagnosis. Anoxic encephalopathy.

Case 10

A 3-month-old baby was found one morning unresponsive. On admission to hospital he was comatose. The pupils were 2 mm and

reacted to light. He was spastic with hyperactive deep tendon reflexes. The EEG consisted of bilateral delta rhythms. The patient remained in coma requiring a respirator and had frequent myoclonic jerks and decerebrate posturing. One month after admission he was still comatose. The pupils were miotic and reacted to light. The oculoccephalic reflexes were intact in the vertical direction but absent in the horizontal plane. There was bilateral extensor rigidity and decerebrate posturing. Two months after admission the patient expired following an unsuccessful attempt to wean him from the respirator. The patient's clinical course had been marked by episodes

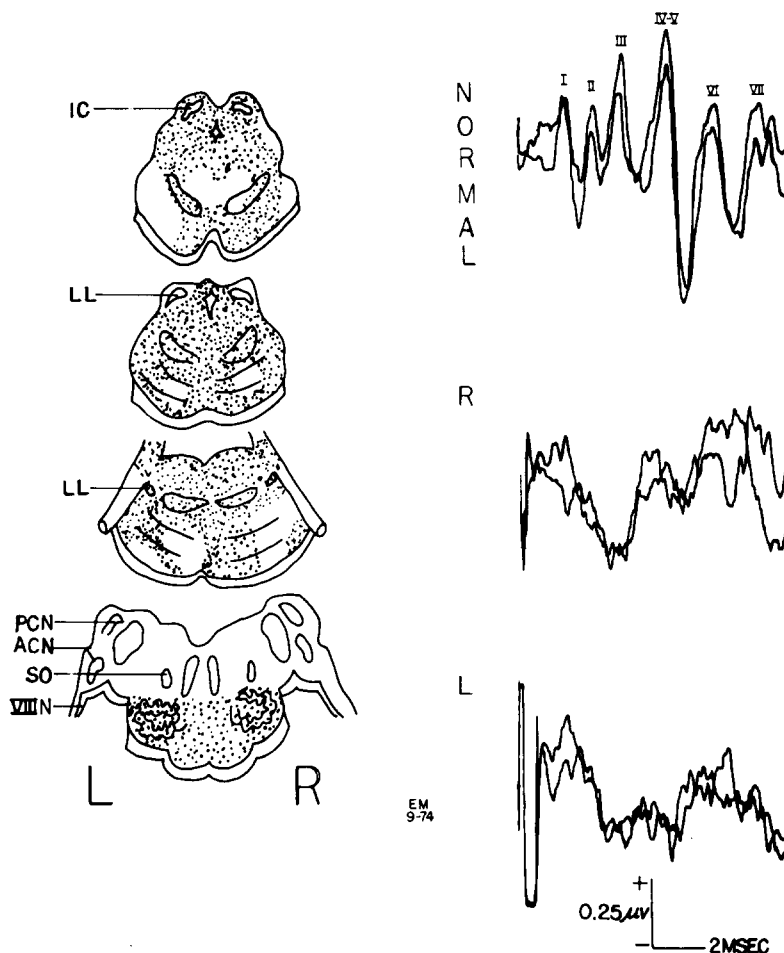


Fig. 9. The distribution of neuropathology and auditory brainstem responses in a patient who survived for 3 months following anoxic brain damage.

of atrial tachycardia, bradycardia, and an inability to maintain adequate ventilation without respirator assistance.

Auditory brainstem responses to monaural signals showed an initial Wave I at the normal latency for a child of this age based on unpublished data from our laboratory (Fig. 9). There are reproducible components in subsequent portions of the response that do not have the usual form and latencies of the normal pattern rendering their designation difficult.

Pathologic description. Except for increased firmness, the brainstem structures were grossly unremarkable. Microscopic examination revealed the complete obliteration of the architecture of the midbrain and pons by reactive astrocytes and macrophages (Fig. 9). In the medulla there was a loss of neurons in the inferior olive. The cochlear and vestibular nuclei and the superior olives were intact. The pyramids were edematous.

Diagnosis. Anoxic encephalopathy; sudden infant death syndrome; status, 2 months post resuscitation.

Comment. The results from these three patients demonstrate that extensive brainstem lesions following anoxia which involve the central auditory pathway are associated with dramatic changes in auditory brainstem responses. Wave I may be of normal amplitude but delayed in latency whereas the subsequent waves are absent (acute anoxia) or extremely distorted in form (recovery from anoxia, Case 10).

Discussion

Results from the series of patients presented in this paper show that lesions of different regions of the brainstem as confirmed at autopsy or time of operation are associated with abnormalities of particular components of the auditory brainstem response. The integrity of the midbrain is essential for the detection of Waves IV through VII (Case 3). Moreover, in one patient with a partial lesion of the inferior colliculus and

tegmentum of the midbrain, the IV—V complex was present but reduced in amplitude compared to the normal pattern (Case 4). When the pathological process was widespread throughout the brainstem or was extramedullary at the entrance of the VIII cranial nerve to the medulla, Wave I was the only component of the response that remained. The exception to this statement was the patient in Case I who had an acoustic neuroma and both Waves I and II were preserved. Thus Wave I (and perhaps II) represent the activity of VIII nerve extrinsic to the brainstem. Finally the occurrence of Waves II and III depended on the intactness of the medullary portion of the auditory pathway including cochlear nucleus, trapezoid body and superior olive.

These conclusions are in general accord with our understanding of the generators of the various auditory brainstem response components derived from recording and ablation studies in experimental animals (Jewett 1970; Lev and Sohmer 1972; Buchwald and Huang 1975).

The latency of Wave I in the far-field response is coincident in time with VIII nerve activity recorded with electrodes placed in proximity to the nerve (Jewett 1970). Wave II occurs when cochlear nucleus is active, Wave III when superior olive is active, Wave IV when lateral lemniscus is active, and Wave V when inferior colliculus is active. The temporal coincidence of the components of the far-field auditory brainstem response with electrical activity recorded directly from various structures in the auditory pathway cannot be assumed to imply a causal relationship between these two phenomena. The relationship must be complex since a brief acoustic signal like a click evokes a sequence of electrical events within each auditory structure that persists for many milliseconds. For instance, a click will evoke in cochlear nucleus a series of potentials that begin at a latency of 2 msec and persist for up to 8 msec. A similar extended sequence of electrical potential can be recorded from each auditory structure within

the brainstem with temporal and amplitude features that are different and unique at each site. The manner in which these various electrical potentials interact and sum in the far-field to produce the auditory brainstem response cannot be assumed to be a simple linear process. Thus, the assumption that Wave III only represents the activity of the superior olive is incomplete. It is more realistic to expect that the activity of the more peripheral sites along auditory pathway, i.e., VIII nerve and cochlear nucleus, interact with the superior olivary potentials to produce the far-field component designated as III. Similar interactions can be assumed to occur in the generation of all of the far-field response components except Wave I which is the initial event in VIII nerve.

The other experimental approach employed to delineate the generators of the far-field auditory brainstem response have relied on acute lesions of different portions of the auditory pathway. Lev and Sohmer (1972) noted in cats that Waves IV and V disappeared following ablation of the inferior colliculus. Recently (Buchwald and Huang 1975) have shown in the cat that: (1) ablation of the inferior colliculus caused a loss of Wave V; (2) ablation of the ventral nucleus of the lateral lemniscus caused a loss of Wave IV; (3) isolation of the cochlear nucleus from the brainstem resulted in preservation of only Waves I and II; (4) isolation of the VIII nerve from the brainstem resulted in the preservation of only Wave I; and (5) the death of the animal was accompanied by the loss of all components. The effects of this sequence of lesions on the far-field auditory brainstem responses are essentially similar to the results described in the patient material in this paper.

Waves VI and VII are prominent components of the auditory brainstem response derived from human subjects but are absent or difficult to define in records from both cats (Jewett 1970) and rats (Jewett and Romano 1972). The basis for this distinction is not clear. We have not yet defined a set of lesions in our human material in which Waves

VI and VII were specifically altered in the presence of normal Waves I through V.

The abnormalities of auditory brainstem responses described in the present series of patients are gross and involve either the loss or the marked attenuation of various components. These easily distinguished response alterations probably reflect the extensive and destructive nature of the pathological processes. It is likely that the fine details of amplitude or latency of the various components will also be altered by more restricted lesions of the brainstem. We hope that the response changes described in this study will encourage others to examine auditory brainstem responses in more detail in other clinical disorders of brainstem function.

Summary

Far-field auditory brainstem responses were recorded in ten patients in whom the distribution of pathology was defined at autopsy or at operation. The response normally consists of seven components in the initial 10 msec following click signals. Interruption of auditory pathway at the junction of VIII nerve with brainstem results in loss of response components after Wave I. Interruption of auditory pathway at the midbrain results in loss of response components after Wave III. We conclude that Wave I reflects activity of VIII nerve, Waves II and III reflect activity of cochlear nucleus, trapezoid body, and superior olive and Waves IV and V reflect activity of lateral lemniscus and inferior colliculus. The generators of Waves VI and VII were not defined.

Résumé

Corrélation entre les sièges confirmés des lésions neurologiques et les anomalies des réponses auditives du tronc cérébral transmises à distance

Les réponses auditives du tronc cérébral, transmises à distance, sont enregistrées chez

10 malades chez lesquels la topographie des atteintes pathologiques est précisé par autopsie ou par intervention. La réponse consiste normalement en sept composantes au cours des 10 msec initiales après les signaux à type de click. L'interruption de la voix auditive à la jonction de la VIII paire crânienne avec le tronc cérébral résulte en une perte des décomposantes de la réponse au-delà de l'onde 1. L'interruption de la voix auditive au niveau du mésocéphale résulte en la perte des composantes de la réponse consécutives à l'onde 3. Les auteurs concluent que l'onde 1 reflète l'activité de la VIII paire, les ondes 2 et 3 reflétant l'activité du noyau cochléaire, du corps trapézoïde et de l'olive supérieure, et les ondes 4 et 5 l'activité du lemniscus latéral et du cellulus inférieur. Les générateurs des ondes 6 et 7 n'ont pas été identifiés.

References

- Buchwald, J. and Huang, C-M. Far-field acoustic response: Origins in the cat. *Science*, 1975, 189: 382-384.
- Hecox, K. and Galambos, R. Brainstem auditory evoked responses in human infants and adults. *Arch. oto-laryngol. (Stockh.)*, 1974, 99: 30-33.
- Jewett, D.L. Volume conducted potentials in response to auditory stimuli as detected by averaging in the cat. *Electroenceph. clin. Neurophysiol.*, 1970, 28: 609-618.
- Jewett, D.L. and Romano, M.N. Neonatal development of auditory system potentials averaged from the scalp of rat and cat. *Brain Res.*, 1972, 36: 101-115.
- Jewett, D.L. and Williston, J.S. Auditory evoked far-fields averaged from the scalp of humans. *Brain*, 1971, 94: 681-696.
- Lev, A. and Sohmer, H. Sources of averaged neural responses recorded in animal and human subjects during cochlear audiometry (electrocochleogram). *Arch. klin. exp. ohr.-, nas.-, u. Kehlk.-Heilk.*, 1972, 201: 79-90.
- Sohmer, H., Feinmesser, M. and Szabo, G. Sources of electrocochleographic responses as studied in patients with brain damage. *Electroenceph. clin. Neurophysiol.*, 1974, 37: 663-669.
- Starr, A. Clinical relevance of auditory brainstem responses. In J.E. Desmedt (Ed.), *Evoked responses*. Elsevier, Amsterdam, 1976, in press.
- Starr, A. and Achior, J. Auditory brainstem responses in neurological disease. *Arch. Neurol. (Chic.)*, 1975, 32: 761-768.