

# UC San Diego

## UC San Diego Previously Published Works

### Title

Clinical applications of aqueous angiography in glaucoma.

### Permalink

<https://escholarship.org/uc/item/49k5v8s5>

### Journal

Indian Journal of Ophthalmology, 72(Suppl 4)

### Authors

Beri, Nitika

Bukke, Anand

Gupta, Ashi

et al.

### Publication Date

2024-07-01

### DOI

10.4103/IJO.IJO\_3220\_23

Peer reviewed

## Clinical applications of aqueous angiography in glaucoma

Nitika Beri, Anand Naik Bukke, Ashi Gupta, Alex S Huang<sup>1</sup>, Dewang Angmo, Namrata Sharma, Tanuj Dada

Aqueous humor outflow (AHO) pathways are the main site of resistance causing elevated intraocular pressure in glaucoma, especially primary open-angle glaucoma patients. With the recently introduced technique of aqueous angiography (AA); functional, real time assessment of AHO from proximal (trabecular meshwork) to distal pathways under physiological conditions has been made possible. AHO pathways are segmental, and AA can identify high-flow region (increased angiographic signals) and low flow region (decreased angiographic signals) in an individual. With the introduction of canal-based minimally invasive glaucoma surgeries (MIGS), the assessment of AHO can help guide the placement of stents/incisions during MIGS procedures. This can allow individualized and targeted MIGS procedures in glaucoma patients for better results. Based on the density of AHO pathways visualized on AA, surgeons can decide whether to perform MIGS or conventional glaucoma surgery for improved outcomes for the patient. Immediate intraoperative assessment for functionality of the MIGS procedure performed is possible with AA, allowing for surgical adjustments of MIGS procedure in the same sitting, if needed. This review provides a summary of the studies performed with AA to date, with a special focus on Indian patients. It covers the basics and clinical applications of AA for improving surgical outcomes in glaucoma patients.

**Key words:** Aqueous angiography, aqueous humor outflow pathways, clinical application, individualised and targeted MIGS, MIGS

Glaucoma is an acquired progressive optic neuropathy, which is currently the leading cause of irreversible blindness. The global burden of this disease is estimated to be 111.8 million by 2040.<sup>[1]</sup> The inflow and outflow of aqueous humor from the eye determine the intraocular pressure (IOP). Aqueous humor is produced by the pars plicata part of the ciliary body, and it flows into the posterior chamber of the eye and then into the anterior chamber through the pupil. Pathways for aqueous humor drainage are the conventional (trabecular) and uveoscleral pathways, and they represent 70%–90% and 10%–30% of total outflow, respectively.<sup>[2]</sup> In the conventional pathways, aqueous humor flows through the trabecular meshwork (consisting of uveal, corneoscleral, and juxtacanalicular components), into the Schlemm's canal and then into collector channels and episcleral veins. From episcleral veins, the aqueous then joins the venous blood and flows to the superior and inferior ophthalmic veins, which in turn drain to the cavernous sinus. From the cavernous sinus, venous blood drains to the internal jugular vein and ultimately to the right atrium.

One of the modifiable parameters to prevent glaucoma progression is to decrease IOP. Resistance in the aqueous humor outflow (AHO) pathways is an important cause of elevated IOP, especially in patients who have primary open-angle glaucoma. With the advent of canal-based minimally invasive glaucoma surgery (MIGS), the study of AHO has become a critical issue

as it can potentially guide the placement of stents/implants or goniotomy/trabeculotomy incisions during surgery. This review covers the basics of aqueous angiography (AA) and outlines the clinical applications of this new investigation for improving surgical outcomes in glaucoma patients.

### Basics of AA

*AHO pathways: Structure and function*

Spectral domain anterior segment optical coherence tomography (ASOCT) allows for the structural assessment of AHO pathways.<sup>[3,4]</sup> However, functional assessment of AHO has not been possible until recently, and now, we can visualize the actual flow of aqueous. For functional assessment of dynamic AHO, we require the use of tracers such as soluble dyes or fluorescent microspheres.<sup>[5-8]</sup> AA has been developed with the goal of real-time functional assessment of the AHO pathways from trabecular meshwork to distal AHO pathways with the target to make it translatable to clinical settings.<sup>[9-14]</sup>

*Basic principle of AA*

AHO pathways are evaluated by introducing tracers like fluorescein and indocyanine green (ICG) dye into the anterior chamber. These tracers are commonly used during retinal vascular angiography for routine clinical care of patients with retinal diseases.<sup>[15,16]</sup> In AA, these tracers are injected into the

#### Access this article online

**Website:**  
<https://journals.lww.com/ijo>

**DOI:**  
10.4103/IJO.IJO\_3220\_23

#### Quick Response Code:



Dr Rajendra Prasad Centre for Ophthalmic Sciences, AIIMS, Delhi, India, <sup>1</sup>Hamilton Glaucoma Centre, The Viterbi Family Department of Ophthalmology, Shiley Eye Institute, University of California, San Diego, CA, USA

**Correspondence to:** Dr. Tanuj Dada, Room Number 485, 4<sup>th</sup> Floor, Dr Rajendra Prasad Centre for Ophthalmic Sciences, AIIMS, Ansari Nagar, Delhi - 110 029, India. E-mail: tanujdada@gmail.com

**Received:** 09-Dec-2023

**Revision:** 03-Feb-2024

**Accepted:** 16-Feb-2024

**Published:** 16-Apr-2024

This is an open access journal, and articles are distributed under the terms of the Creative Commons Attribution-NonCommercial-ShareAlike 4.0 License, which allows others to remix, tweak, and build upon the work non-commercially, as long as appropriate credit is given and the new creations are licensed under the identical terms.

**For reprints contact:** WKHLRPMedknow\_reprints@wolterskluwer.com

**Cite this article as:** Beri N, Bukke AN, Gupta A, Huang AS, Angmo D, Sharma N, *et al.* Clinical applications of aqueous angiography in glaucoma. Indian J Ophthalmol 2024;72:S553-60.

anterior chamber, from where they can enter the AHO pathways and be imaged using commercial fluorescence cameras like the Spectralis HRA+OCT FLEX module (Heidelberg Engineering, Heidelberg, Germany). Circumferential (360°), real-time AHO pathways can be imaged, and AHO can be evaluated objectively using special imaging software. High versus low flow regions can be distinguished, and areas with no visible flow can be documented. In eyes with overall poor outflow, trabecular MIGS may not be a good option and implants like Xen gel Stent/PreserFlo microshunt or a trabeculectomy may be a better option. This may allow for MIGS procedures to be individualized. AA may also aid in assessing the functionality of MIGS (aqueous outflow by AHO pathways post-MIGS) like iStent Inject post procedure and allow corrective surgical adjustments in the same sitting if required.

#### *Anterior segment angiography*

Anterior segment angiography (ASA) can also be performed using the same preparation as for retinal vascular angiography. For assessment of the anterior segment vasculature, iris fluorescein angiography, scleral angiography, and angiography of conjunctival vessels have been described in literature.<sup>[17]</sup> They differ from posterior segment retinal vascular angiography in that an additional anterior segment lens attachment is used for imaging the anterior segment vasculature (iris, conjunctival, and scleral vasculature) after intravenous injection of dye.<sup>[17-19]</sup>

The key difference between ASA and AA is that the dye is introduced into the anterior chamber in AA (and not intravenously as done for ASA) during an incisional surgery, and flow of the dye shows AHO channels as opposed to anterior segment blood vessels imaged in ASA.<sup>[9-14]</sup>

#### *Optical coherence tomography angiography*

Another common modality that images flow and has received considerable interest in recent times is optical coherence tomography angiography (OCTA). It is important to clarify that AA is not OCTA and to understand the differences. OCTA works on the principle of identifying blood vessels by detecting changes in OCT reflectance signals induced by blood flow.<sup>[20]</sup> Red blood cells (RBCs) create an OCT reflectance. In an otherwise motionless eye, the only cells that move are RBCs. Thus, specialized analysis of standard OCT B-scans with well-established algorithms exist to identify the motion of blood flow. This has been well studied in the posterior segment vasculature.<sup>[20]</sup> OCTA has demonstrated decreased perfusion of the optic nerve head and macular region in glaucoma.<sup>[21-23]</sup>

The challenge faced by the anterior segment and AHO is that proximal AHO channels contain aqueous and not blood. It is not until AHO pathways join episcleral veins that vessels contain both aqueous and blood cells and hence can be well distinguished by OCTA. In a recent study by Akagi *et al.* (2018),<sup>[12]</sup> anterior segment OCTA (conjunctival and intrascleral vasculature) was compared with AA in healthy patients. They found that deeper OCTA signal correlated well with episcleral veins seen in AA, but OCTA did not image AHO pathways proximal to episcleral veins. Therefore, OCTA visualizes anterior segment blood flow (and the junction where the aqueous flow joins the blood flow), such that anterior segment OCTA is not suitable for comprehensive imaging of the entire AHO pathways from Schlemm's canal to episcleral veins.

To visualize the entire conventional AHO pathways, alternative agents (gold nanorods or lipid emulsions) have

been used to generate OCTA signals at the Schlemm's canal and beyond in *ex vivo* studies on eyes.<sup>[24,25]</sup> While OCTA can be used, the disadvantage is that this approach is still invasive and requires the introduction of contrast agents. Furthermore, no suitable exogenously delivered OCTA contrast agent has been developed and studied in the eyes of human patients.

Ultimately, a visualization technique that can demonstrate native aqueous is the best. While aqueous is invisible, molecules (such as vitamin C) are found in higher concentration in aqueous than in serum and could serve as a candidate target for developing noninvasive AHO imaging. Unfortunately, vitamin C does not have unique characteristics that can be easily imaged. If it did, then noninvasive and physiologic imaging of both proximal and distal AHO pathways could be possible.<sup>[26]</sup>

#### **Imaging of AHO pathways with AA in Humans**

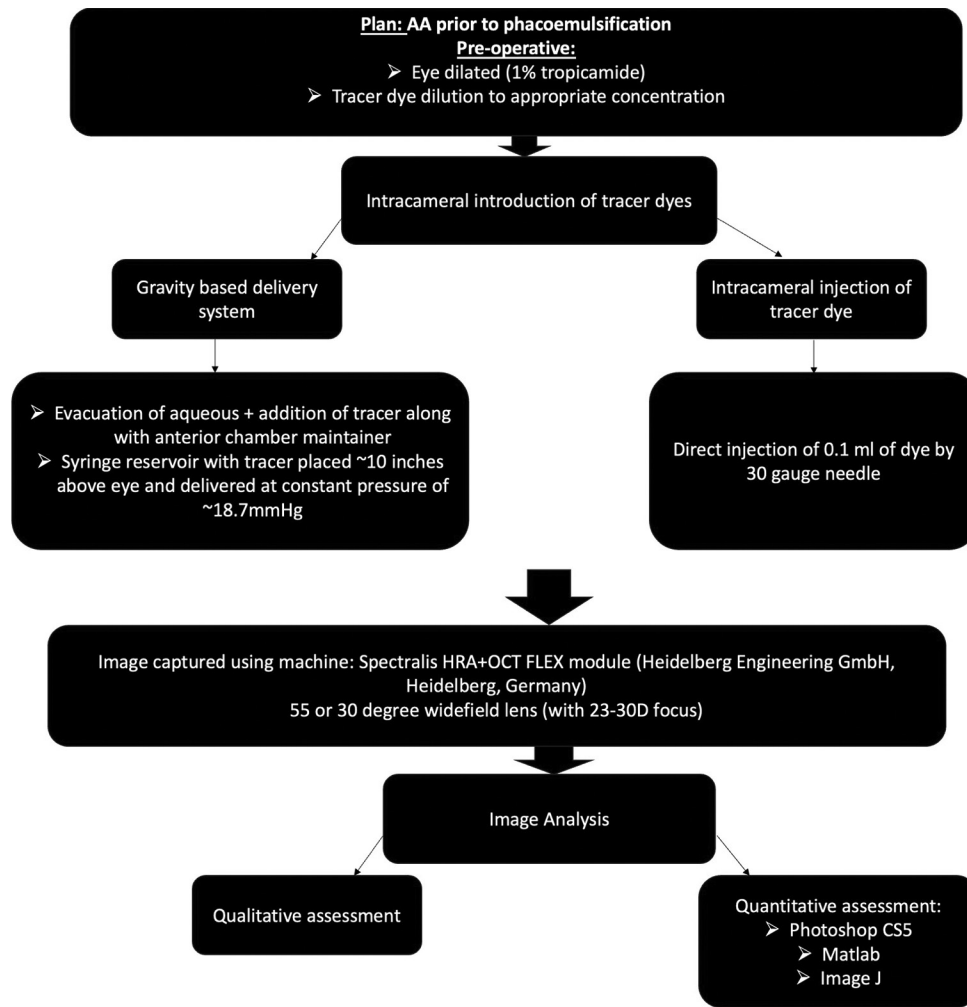
##### *AA with a gravity-based delivery system*

AA is performed before phacoemulsification with the tracer dye, which also acts as a capsular stain to aid capsulorrhexis [Flowchart 1]. All patients are preoperatively dilated with topical tropicamide (1%). A 1-mm side port is created at the temporal limbus, through which a Lewicky anterior chamber maintainer is inserted. Aqueous humor is evacuated using a syringe, followed by addition of tracer (ICG or fluorescein). The tracer is placed in a syringe reservoir with a three-way stop cock situated ~10 inches above the eye to provide a gravity-delivered constant pressure of ~18.7 mmHg. The Spectralis HRA+OCT FLEX module device is used to capture AA images. A 55° wide-field lens (with a 23–30 D focus) is used to bring the anterior chamber and limbus into focus in infrared mode [Flowchart 1]. The AA images are then captured on angiographic mode, ICG, or fluorescein, depending on the tracer used. After completion of AA, the tracer is irrigated out from the anterior chamber using balanced salt solution (BSS), followed by viscoelastic insertion. The standard steps of phacoemulsification are then performed.<sup>[9-11]</sup>

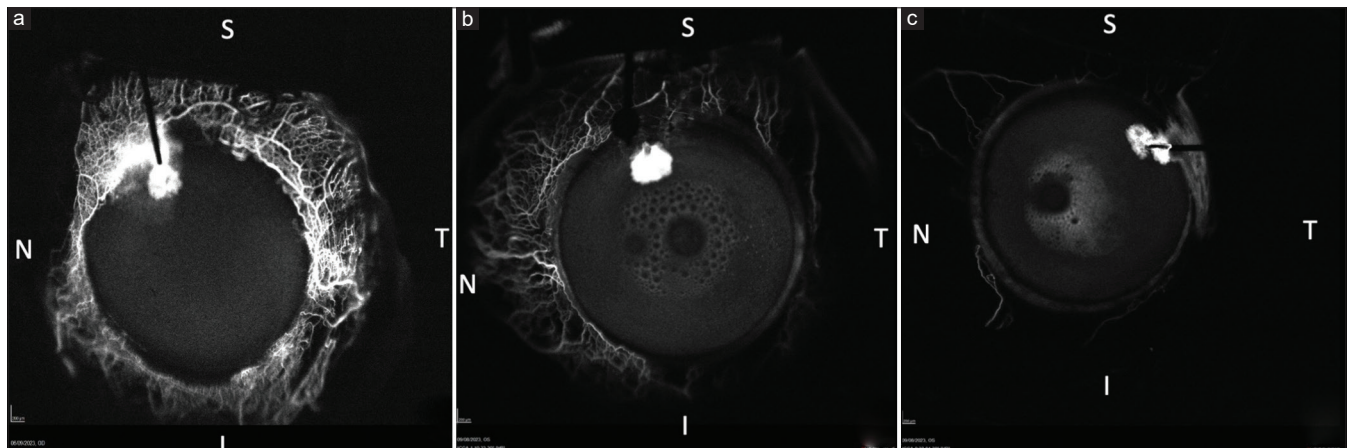
##### *AA with intracameral (IC) bolus of tracer: The India experience*

While the method described above is the originally described AA method and variations (such as using two ports) exist, the challenge is that setting up a perfusion system is time-consuming and requires additional staff in the operating room.<sup>[11]</sup> Therefore, an alternative approach of direct application into the anterior chamber using a 30-gauge needle was performed by the author (TD) [Flowchart 1]. All patients planned for AA were prepared for phacoemulsification using dilating drops (tropicamide 1%) followed by topical anesthesia (0.5% proparacaine hydrochloride). ICG dye (0.1 ml of 0.1%) was injected (with a 30-gauge needle in a 1-ml syringe) into the anterior chamber at the 12 o'clock position (superior limbus), and imaging was done using the machine as described above. We used a 30° lens for better magnification and resolution instead of the 55° lens. After washing the tracer, standard steps of phacoemulsification were followed. Fig. 1 depicts the patterns of AHO pathways seen while performing AA using this setup.

We found this technique (IC injection of ICG dye) for AA to be time-saving with an easier setup and less chance of dye leakage. An important step is to release some aqueous when the initial 30-gauge needle is inserted to mitigate IOP elevation during tracer injection. A drawback of IC injection of the dye



Flowchart 1: Steps of aqueous angiography technique



**Figure 1:** Patterns of aqueous outflow pathways seen by aqueous angiography in humans (I = inferior, N = nasal, S = superior, T = temporal). (a) 360° flow in a nonglaucomatous patient. (b) Aqueous flow in moderate POAG, good flow seen in nasal and superior quadrants. Decreased aqueous flow seen in temporal and inferior quadrants. (c) Aqueous flow in advanced POAG. Nasal and superior quadrants showing decreased aqueous flow. No flow seen in temporal and inferior quadrants. (Dye leak seen in superotemporal quadrant around the injection site is an artifact). POAG = primary open-angle glaucoma

versus gravity-based trocar system is that the former is less reproducible and less physiologic compared to the latter. A comparison between the two techniques has been done

by Burn *et al.* (2020)<sup>[27]</sup> in live canines and good results were obtained with the IC technique with minimal alterations in aqueous and IOP.

AA has also been used to assess the functionality of MIGS procedures like iStent inject at our center. After insertion of iStent inject, AA was performed, which showed flow through the device, confirming its functionality [Fig. 2]. The advantage of performing AA post-MIGS is that surgical adjustments can be made during the same sitting in the case of inadequate functional flow.

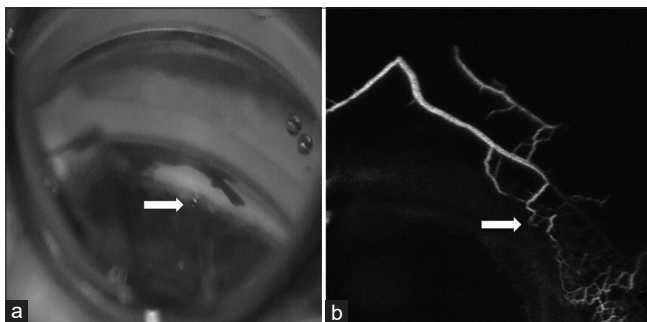
#### Tracer dyes used

The reason why AA uses fluorescein and ICG is that both ICG dye (0.5%) and fluorescein dye (2%) have been used extensively in the past for angiographic assessment of posterior segment vessels after intravenous delivery.<sup>[15,28]</sup> Thus, use of these tracers has been well studied and is safe. Furthermore, both have been used for anterior capsular staining in phacoemulsification for over a decade. Their safety and efficacy in phacoemulsification surgery have been well proven in literature as dyes for anterior capsular staining.<sup>[29,30]</sup>

Regarding concentration, both these dyes have been studied for AA. In the enucleated eyes, 0.25%–0.4% of ICG and 2%–2.5% of fluorescein dye have been used.<sup>[27,31–34]</sup> The solvent is BSS. ICG dye is available in the powdered form and requires dilution with sterile water for injection to reach a concentration of 0.5%. Performing a skin hypersensitivity test for the above dyes is at the discretion of the surgeon as these dyes are injected in the anterior chamber instead of the bloodstream and no study of AA or on anterior capsular staining by these dyes has reported hypersensitivity reactions.<sup>[10,11,29,30,33]</sup> In live humans, 0.4%–0.5% of ICG and 2% of fluorescein dye have been used for AA.<sup>[9–12,14]</sup> A lower concentration of ICG (0.25%) has also been demonstrated successful AA in live dogs.<sup>[27]</sup> Recently, at our center, 0.1% of ICG has also been successfully used for AA. Depending on the source and the manufacturer, ICG can cause less staining of endothelium, lens, and vitreous compared to fluorescein and is thus the preferred agent for AA.

#### Image analysis

Qualitative and quantitative analyses have been performed by authors for AHO pathways captured by AA [Flowchart 1]. In earlier studies, Photoshop CS5 software was used and pixel intensity was calculated in all four quadrants.<sup>[31,33,35]</sup> In 2018, Huang *et al.*<sup>[10]</sup> used MATLAB software and calculated pixel intensity at 15, 40, and 45 pixel increments from the limbus. In 2019, Huang *et al.*<sup>[11]</sup> calculated the ratio of normalized signal



**Figure 2:** Functionality of iStent Inject confirmed by aqueous angiography. (a) Gonioscopic view of angle, with the arrow pointing at the iStent inject inserted. (b) Aqueous angiography image corresponding to the site of iStent inject inserted, with the arrow pointing toward the collector channel through the device, confirming its functionality

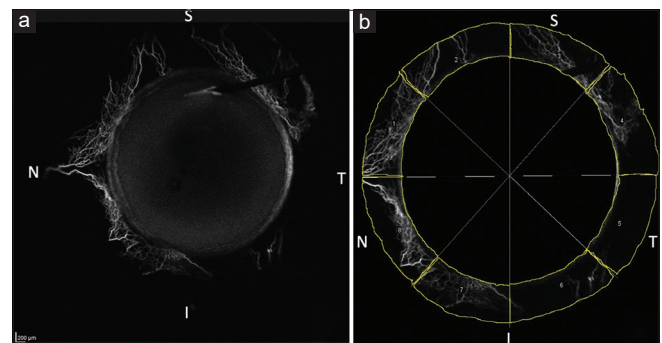
intensity at 60 s to compare the pixel intensity in all quadrants. Telle *et al.*<sup>[34]</sup> set the baseline sensitivity to 50 and calculated the signal (high or low) based on it for image analysis. In the study by Burn *et al.*,<sup>[36]</sup> two individuals performed data analysis and calculated the time for initial fluorescence, the number and caliber of AHO pathways, presence of circumferential vessels, or any complex branching. Movement of aqueous was also qualified as pulsatile, turbulent, or demonstrating laminar flow. Interobserver variation was also noted.

In our center in India, we used the ImageJ software publicly available from the National Institutes of Health (<https://imagej.nih.gov/ij/download.html>) and divided the eye into eight sectors of 45° each [Fig. 3]. Mean pixel intensity for each sector was calculated and compared for analysis [Fig. 3]. This software has also been used for image analysis by Snyder *et al.*<sup>[37]</sup> in their AHO study on *ex vivo* eyes of cats. A limitation of using this technique for quantitative analysis of images by AA is that in eyes with small palpebral apertures, it is difficult to visualize all the quadrants simultaneously as the superior and inferior quadrants are covered by eyelids. The palpebral aperture in Indian eyes is adequate, and mostly, simultaneous imaging is possible for all four quadrants. To overcome this limitation, we can use a self-retaining universal Barraquer eye speculum for improved exposure and a 55° wide-field lens for capturing the images.

#### Review of studies on AA

##### AA in enucleated eyes (*ex vivo*)

To establish the safety and clinical utility of AA technique, this procedure was first performed in enucleated animal and human eyes. Saraswathy *et al.*<sup>[33]</sup> performed fluorescein AA and concurrent OCT in pig ( $n = 46$ ) and human ( $n = 6$ ) enucleated eyes. Fluorescent dextrans were introduced into the eye for further histologic analysis of angiographically positive and negative areas. They found that AHO showed segmental patterns around the limbus. Angiographically positive area demonstrated intrascleral lumen on OCT and had greater fluorescent dextran deposition. Another study by Huang *et al.*,<sup>[35]</sup> published in March 2016, used both fluorescein (2.5%) and ICG dye (0.4%) individually and sequentially in enucleated bovine eyes ( $n = 31$ ). This was the first study to use ICG for AA and showed that ICG maintained better intraluminal presence.<sup>[35]</sup> This could be because ICG is more bound to proteins and has higher molecular weight compared to fluorescein. This was also the first study to use two dyes sequentially.<sup>[35]</sup> Around the



**Figure 3:** Image analysis using ImageJ software. (I = inferior, N = nasal, S = superior, T = temporal). (a) Image taken during aqueous angiography used for image analysis. (b) Pixels calculated for each of the eight sectors for quantitative analysis

same time, another study was published by Huang *et al.*<sup>[31]</sup> in March 2016 on enucleated human eyes and used ICG AA to identify regions devoid of angiographic signal. In these eyes, trabecular bypass or sham trabecular bypass was performed. All eyes underwent sequential fluorescein AA after their respective procedures. Concurrent OCT for structural analysis of AHO and fixable fluorescent dextrans for histologic analysis were used as well. They found that trabecular bypass led to an increased angiographic signal postprocedure in regions that initially had low angiographic outflow.<sup>[31]</sup> Similar to previous studies,<sup>[33,35]</sup> AA correlated with intrascleral lumens on OCT and angiographically positive regions had greater fluorescent dextran deposition in the nearby trabecular meshwork.<sup>[31]</sup> Table 1 summarizes the details of flow patterns of the above studies.

Cat and dog eyes have also been studied using AA. In 2019, Snyder *et al.*<sup>[37]</sup> studied enucleated eyes of cats ( $n = 9$  [normal = 4 and congenital glaucoma = 5]). ICG AA and/or fluorescein AA was performed to identify high- and low-flow regions. ASOCT and histologic analysis using hematoxylin and eosin stain or immunolabeling for vascular markers were performed in these regions. They found that the number of intrascleral vessels was the same in both normal and congenital glaucoma groups, but scleral vessels were located more posterior to the limbus in cat congenital glaucoma eyes.<sup>[37]</sup> Separately, glaucoma dogs were studied as well. In enucleated eyes of canines with primary angle-closure glaucoma, minimal or no AA signal and collapsed scleral lumens were seen on OCT and histopathology.<sup>[34]</sup>

Recently, AA was used to evaluate surgical methods in enucleated postmortem human and porcine eyes. The main question was whether to target MIGS to baseline high- or low-flow regions.<sup>[32]</sup> Porcine ( $n = 14$ ) and human ( $n = 13$ )

enucleated eyes underwent fluorescein AA, and baseline high- and low-flow areas were identified. Goniotomies were then performed in either baseline high- or low-flow regions in eyes from each species. Sequential AA using ICG dye was performed to assess changes to postprocedure AHO patterns. Aqueous humor dynamics were also measured before and after surgery. The authors found that targeting low-flow regions yielded higher increase in outflow facility and IOP reduction.<sup>[32]</sup> Tables 2 and 3 give a summary of the flow details of the above-mentioned studies.

In all the above studies, the enucleated eyes were oriented by inferior oblique muscle insertion and pre-perfused using BSS via Lewicky anterior chamber maintainer.<sup>[31-35,37]</sup> ICG or fluorescein dye was injected IC at a constant pressure (10–18 or 30 mmHg over 30 min). The images were captured using an angiographer (Spectralis HRA+OCT FLEX Module) and analyzed using computer software.<sup>[31,33,35,37]</sup>

#### AA in live animals

Before performing AA in live humans, AA was first tested (in the year 2017) in living non-human primates ( $n = 6$ ) to establish its safety.<sup>[38]</sup> After anesthesia and placement of superior and inferior corneal traction sutures, ICG AA or fluorescein AA was performed individually or sequentially. Unlike previous studies in enucleated eyes,<sup>[31-35,37]</sup> where 360° imaging could be acquired in a single frame, live eyes have eyelids; hence, the eyes had to be rotated using traction sutures to capture 360° AHO imaging. This study demonstrated that AA could be performed *in vivo* and showed segmental, pulsatile, and dynamic AHO.<sup>[38]</sup> Both ICG and fluorescein dyes could be used, and angiographically positive signal colocalized with intrascleral vessels on ASOCT.<sup>[38]</sup>

**Table 1: Aqueous outflow pattern in eyes without glaucoma using aqueous angiography**

Studies	Eye	Dye used	Significant findings
Saraswathy <i>et al.</i> (2016) <sup>[33]</sup>	<i>Ex vivo</i> pig and human	Fluo (2.5%)	-AHO is segmental -Angiographically positive regions demonstrated intrascleral lumen on OCT -Angiographically positive regions had greater fluorescent dextran deposition in adjacent TM
Huang <i>et al.</i> (2016) <sup>[35]</sup>	<i>Ex vivo</i> bovine	ICG (0.4%) and fluo (2.5%)	-ICG maintained better intraluminal presence and AA signal -Segmental angiographic outflow patterns were seen in an additional species
Huang <i>et al.</i> (2016) <sup>[31]</sup>	<i>Ex vivo</i> human	ICG (0.4%) and fluo (2.5%)	-Trabecular bypass (as opposed to sham surgery) led to increased angiographic signal postprocedure
Huang <i>et al.</i> (2017) <sup>[38]</sup>	<i>In vivo</i> primates	ICG (0.4%) and fluo (2.5%)	-AHO is segmental, dynamic, and pulsatile - Both ICG and fluo AA showed similar angiographic pattern - Angiographically positive signal co-localized with episcleral veins on OCT
Huang <i>et al.</i> (2017) <sup>[9]</sup>	<i>In vivo</i> human	ICG (0.4%)	-AA in living humans -Nasal signal the strongest -AHO was segmental, pulsatile, and dynamic -Correlated with ASOCT
Huang <i>et al.</i> (2018) <sup>[10]</sup>	<i>In vivo</i> human	Fluo (2%) and ICG (0.4%)	-Fluo dye can also be used for AA in living humans -Sequential angiography is possible in living humans
Akagi <i>et al.</i> (2018) <sup>[12]</sup>	<i>In vivo</i> human	ICG (0.4%)	-Compared to OCTA, AA and OCTA showed similar patterns when imaging episcleral veins
Burn <i>et al.</i> (2020) <sup>[27]</sup>	<i>Ex vivo</i> and <i>in vivo</i> canine	ICG (0.25%) and fluo (2%)	-Compared to scleral angiography, AA and scleral angiography also showed similar patterns when imaging episcleral veins -Found that intracameral bolus injection of dye can be better than gravity-fed trocar system in this species

AA=aqueous angiography, AHO=aqueous humor outflow, ASOCT=anterior segment optical coherence tomography, fluo=fluorescein, ICG=indocyanine green, OCT=optical coherence tomography, OCTA=optical coherence tomography angiography, TM=trabecular meshwork

**Table 2: Aqueous outflow pattern in glaucoma eyes by aqueous angiography**

Studies	Eye	Diagnosis	Dye used	Significant findings
Snyder <i>et al.</i> (2019) <sup>[37]</sup>	<i>Ex vivo</i> cat	Congenital glaucoma and normal	ICG (0.4%) and fluo (2.5%)	-Number of intrascleral vessels same in both normal and congenital glaucoma groups - Scleral vessels were located more posterior to the limbus in congenital glaucoma group
Telle <i>et al.</i> (2022) <sup>[34]</sup>	<i>Ex vivo</i> canine	PACG and normal	Fluo (2.5%) and ICG (0.4%)	-PACG eyes showed minimal or no AA signal with collapsed scleral lumens on OCT and histopathology
Burn <i>et al.</i> (2022) <sup>[36]</sup>	<i>In vivo</i> canine	Glaucoma and normal	ICG (0.25%)	Laminar flow and smaller lumen vessels were observed in glaucoma eyes

AA=aqueous angiography, AHO=aqueous humor outflow, Fluo=fluorescein, ICG=indocyanine green, OCT=ocular coherence tomography, PACG=primary angle-closure glaucoma

**Table 3: Aqueous angiography-guided surgery**

Studies	Eye	Diagnosis	Dye used	Significant findings
Huang <i>et al.</i> (2019) <sup>[11]</sup>	<i>In vivo</i> human	Glaucoma	Fluo (2%) and ICG (0.4%)	-ICG AA identified high- and low-flow areas -TMB (iStent) placed in high- and low-flow areas -Low-flow areas showed new recruitment of AHO pathways -High-flow areas showed earlier recruitment
Dada <i>et al.</i> (2022) <sup>[13]</sup>	<i>In vivo</i> human	Pseudophakic glaucoma	ICG (0.5%)	-ICG AA identified site of high-flow areas -BANG performed -Found increased AHO
Dada <i>et al.</i> (2023) <sup>[14]</sup>	<i>In vivo</i> humans	POAG	ICG (0.5%), Fluo (2%)	-ICG AA identified low-flow temporal area -BANG performed - Found recruitment of AHO in temporal low-flow area
Strohmaier <i>et al.</i> (2023) <sup>[32]</sup>	<i>Ex vivo</i> human and porcine	Normal eyes	Fluo (2.5%) and ICG (0.4%)	-Fluo AA identified low- and high-flow areas -Goniotomies performed in both areas -Found that targeting TM bypass to low-flow areas yielded higher increase in outflow facility and IOP reduction

AA=aqueous angiography, AHO=aqueous humor outflow, BANG=bent ab interno needle goniotomy, fluo=fluorescein, ICG=indocyanine green, OCT=ocular coherence tomography, POAG=primary open-angle glaucoma, TM=trabecular meshwork, TMB=trabecular microbypass

In 2020, Burn *et al.*<sup>[27]</sup> performed ICG AA along with scleral angiography in live dogs ( $n = 12$ ). They suggested that ICG can be delivered in the anterior chamber via IC bolus injection of ICG. Scleral angiography exhibited similar patterns as AA.<sup>[27]</sup> In continuation of their previous work, Burn *et al.*,<sup>[36]</sup> in 2022, compared normotensive ( $n = 4$ ) and hypertensive glaucomatous ( $n = 6$ ) eyes of dogs with AA, scleral angiography, and ASOCT. They found that normotensive eyes showed turbulent dye movement compared to laminar flow in hypertensive glaucomatous eyes. No delayed filling was seen in hypertensive glaucomatous eyes, but smaller vessel lumens were seen.<sup>[36]</sup> Tables 1 and 2 give a summary of the flow patterns of the above studies.

### AA in live humans

#### AA in normal humans (without glaucoma)

In 2017, Huang *et al.*<sup>[9]</sup> performed AA in live humans for the first time using ICG (0.4%) dye in normal patients undergoing routine cataract surgery. ASOCT was also performed. The results of the study proved that AA is possible in eyes of living human subjects and compatible with successful phacoemulsification without surgical complications.<sup>[9]</sup> It confirmed that AHO is segmental, pulsatile, and dynamic in humans. Angiographic positive signal also correlated with intrascleral lumens seen on ASOCT.<sup>[9]</sup> In a companion study by Huang *et al.*,<sup>[10]</sup> in 2018, the authors showed successful use of fluorescein dye (2%) for AA in living human subjects also undergoing routine cataract surgery. AA technique was

compared with noninvasive OCTA by Akagi *et al.* (2018)<sup>[12]</sup> and it was found that angiographically positive patterns seen by AA were similar to episcleral veins seen on anterior segment OCTA images [Table 1]. However, these images were from different subjects, and therefore, further studies are needed to compare the two techniques in the same patient for a more direct comparison.

#### AA in glaucoma patients

In 2019, Huang *et al.*<sup>[11]</sup> used sequential AA in glaucoma patients to assess changes in AHO pathways after trabecular microbypass (TMB) surgery (iStent inject). TMB procedure in high-flow regions showed faster recruitment of AHO pathways, whereas in low-flow regions, the surgery showed new recruitment of aqueous channels. All surgeries were placed on the nasal side of the eye, which is typical for trabecular MIGS. In studies by Dada *et al.*<sup>[13,14]</sup> in glaucoma patients, bent needle ab interno goniotomy was performed in high-flow regions, which led to AHO increase and recruitment of new AHO pathways in baseline low-flow regions. Notably, Dada *et al.*<sup>[14]</sup> performed the surgery in the temporal side of the eye, which normally shows lesser AHO. Complementing the above study by Huang *et al.*,<sup>[11]</sup> this work showed that temporal low-flow regions can be rescued as well. In general, the temporal side of the eye has lesser AHO; therefore, temporal surgery may be an alternative approach to target baseline low-flow regions as the nasal high-flow regions already have optimal/maximal flow, which may not further increase after surgery. In addition,

performing a procedure in high-flow region carries a risk of wound healing and scarring, which may ultimately adversely impact outflow in a region where it was optimal. Overall, these findings introduce a new era of targeted and individualized MIGS procedures for glaucoma patients [Table 3].

### Clinical significance of AA and the future

AA has shown that AHO in humans is segmental, which allows for mapping of high-flow region (increased angiographic signals) and low-flow region (decreased angiographic signals) along the limbus.<sup>[9-14]</sup> A remaining unanswered question in live humans is whether to perform MIGS in high- or low-flow region to make surgery more successful. Various studies have shown and hypotheses have been given in the past that an MIGS procedure in high-flow regions may be better as it allows access to known AHO pathways. However, there may be a limit to AHO improvement as the flow there is already high. Alternatively, an MIGS procedure in a low-flow region may provide better results in terms of new recruitment of AHO pathways.<sup>[9-11]</sup> The study by Huang *et al.*<sup>[11]</sup> showed TMB in high-flow regions leads to earlier recruitment of aqueous channels and newer recruitment in low-flow regions. Dada *et al.*<sup>[14]</sup> showed similar results, but also included the temporal side of the eye. Strohmaier *et al.*<sup>[32]</sup> provided quantitative rigor by showing that targeting TMB to low-flow regions yielded a greater increase in outflow facility and reduction of IOP. However, this study was performed in enucleated postmortem eyes. Further studies on patients will need to be performed in future to answer this question.

The finding of AHO being pulsatile points to change in aqueous outflow with the cardiac cycle.<sup>[9-11,39-41]</sup> Hence, systemic conditions of hypertension and the heart may also affect IOP regulation. Further studies are required to study the relationship between AHO and cardiovascular parameters.

AHO has also been proven to be dynamic as the AA signal can arise in regions without initial signal and diminish in regions with initial signal.<sup>[9-11]</sup> This points to potential local regulation of AHO that may reside at the level of trabecular meshwork or more distal aqueous and episcleral vessels. Further understanding of this local regulation or receptors is necessary and may lead to identification of new targets and methods to lower IOP.<sup>[2,42]</sup>

The advantages of AA are that tracers used in the technique (ICG and fluorescein) can double as capsular stains for phacoemulsification.<sup>[29,30]</sup> The entry wound for introduction of tracers can also be used as the second instrument side port for phacoemulsification. Thus, no additional incisions are typically required. With future studies, we hope to be able to understand the cause of inconsistencies in IOP-lowering treatment, especially for MIGS, which are the new-generation antiglaucoma surgeries. It is possible that MIGS procedures can be targeted to certain locations of the eye for better outcomes. The functionality of MIGS procedures performed can be evaluated on the table, and surgical adjustments can be made if required in the same sitting. With better understanding of AHO pathways, newer treatment modalities can also be developed to lower IOP.

### Adverse effects and limitations of AA

The major drawback of AA is that it is invasive and requires sterile operating theatre (OT) conditions. Due to ethical reasons,

without an indication for intraocular surgery, AA is difficult to perform, hence making it challenging to study AHO using AA in a longitudinal study with follow-up assessment. The technique of AA is also not completely physiologic, as aqueous normally enters the eye posterior to the iris, but in AA, the tracer is injected in the anterior chamber. Clinically, the risk: benefit ratio of injecting the dye in the ciliary sulcus is too high, as in a phakic patient, it can lead to serious visual complications like vitreous hemorrhage, hyphema, and lens capsular rupture.

The quantification of AHO by AA is also in the early stages and requires further refinement and automation before it can be widely used objectively. The other limitations of AA are the use of dilating drops which can alter the trabecular meshwork capacitance with potential consequences on angiographic signal. Elevated IOP from either (a) application of lid speculum or (b) injection of tracer dye by IC bolus and the use of ocular anesthetic agents can also affect the angiographic AHO signal. For pseudophakic patients, potential staining of the intraocular lens, posterior capsule, and anterior vitreous phase must be evaluated as well. Depending on the pharmaceutical source, it has also been observed that corneal staining with fluorescein has been noted to be much more than with ICG in cases of sequential AA, and this variability must be better understood.

## Conclusions

The technique of AA has evolved from *ex vivo* enucleated animal and human eyes to eyes of live animals and humans. AA's safety and clinical use have been well established in literature from living vertebrates (dogs and cats) to non-human primates to humans. AA has opened a new avenue for targeted and individualized MIGS procedures and may aid in the decision of the type of MIGS to be used, the exact placement of MIGS, functionality of MIGS procedures, and comparison of different MIGS procedures regarding their impact on AHO. The functional and real-time assessment of AHO in humans by AA will improve our understanding of both the physiology and pathology of aqueous outflow channels and help us to devise new treatment modalities for individualized targeted lowering of IOP in the near future.

### Acknowledgement

Council of Scientific and Industrial Research, Human Resource Development's general support is acknowledged.

**Financial support and sponsorship:** For the author, Alex S Huang, funding for his work on aqueous angiography has come from National Institutes of Health, Bethesda, MD (grant numbers R01EY030501 [ASH] and an unrestricted grant from Research to Prevent Blindness [New York, NY] University of California, San Diego [UCSD]).

**Conflicts of interest:** There are no conflicts of interest.

## References

1. Tham YC, Li X, Wong TY, Quigley HA, Aung T, Cheng CY. Global prevalence of glaucoma and projections of glaucoma burden through 2040: A systematic review and meta-analysis. *Ophthalmology* 2014;121:2081-90.
2. Goel M, Picciani RG, Lee RK, Bhattacharya SK. Aqueous humor dynamics: A review. *Open Ophthalmol J* 2010;4:52-9.
3. Kagemann L, Wollstein G, Ishikawa H, Nadler Z, Sigal IA, Folio LS, *et al.* Visualization of the conventional outflow pathway in the living human eye. *Ophthalmology* 2012;119:1563-8.
4. Li P, Shen TT, Johnstone M, Wang RK. Pulsatile motion of the trabecular



- meshwork in healthy human subjects quantified by phase-sensitive optical coherence tomography. *Biomed Opt Express* 2013;4:2051-65.
5. Chang JY, Folz SJ, Laryea SN, Overby DR. Multi-scale analysis of segmental outflow patterns in human trabecular meshwork with changing intraocular pressure. *Journal of ocular pharmacology and therapeutics* 2014;30:213-23.
  6. Battista SA, Lu Z, Hofmann S, Fredro T, Overby DR, Gong H. Reduction of the available area for aqueous humor outflow and increase in meshwork herniations into collector channels following acute IOP elevation in bovine eyes. *Invest Ophthalmol Vis Sci* 2008;49:5346-52.
  7. Vranka JA, Bradley JM, Yang YF, Keller KE, Acott TS. Mapping molecular differences and extracellular matrix gene expression in segmental outflow pathways of the human ocular trabecular meshwork. *PLoS One* 2015;10:e0122483.
  8. Keller KE, Bradley JM, Vranka JA, Acott TS. Segmental versican expression in the trabecular meshwork and involvement in outflow facility. *Invest Ophthalmol Vis Sci* 2011;52:5049-57.
  9. Huang AS, Camp A, Xu BY, Penteadó RC, Weinreb RN. Aqueous angiography: Aqueous humor outflow imaging in live human subjects. *Ophthalmology* 2017;124:1249-51.
  10. Huang AS, Penteadó RC, Saha SK, Do JL, Ngai P, Hu Z, *et al.* Fluorescein aqueous angiography in live normal human eyes. *J Glaucoma* 2018;27:957.
  11. Huang AS, Penteadó RC, Papoyan V, Voskanyan L, Weinreb RN. Aqueous angiographic outflow improvement after trabecular microbypass in glaucoma patients. *Ophthalmol Glaucoma* 2019;2:11-21.
  12. Akagi T, Uji A, Huang AS, Weinreb RN, Yamada T, Miyata M, *et al.* Conjunctival and intrascleral vasculatures assessed using anterior segment optical coherence tomography angiography in normal eyes. *Am J Ophthalmol* 2018;196:1-9.
  13. Dada T, Bukke AN. Aqueous angiography guided ab interno trabecular surgery for open-angle glaucoma. *BMJ Case Rep* 2022;15:e248261.
  14. Dada T, Bukke AN, Huang AS, Sharma N, Verma S. Recruitment of temporal aqueous outflow channels after bent needle ab-interno goniotomy demonstrated by aqueous angiography. *J Glaucoma* 2023;32:e15-8.
  15. Brubaker RF. Flow of aqueous humor in humans [The Friedenwald Lecture]. *Invest Ophthalmol Vis Sci* 1991;32:3145-66.
  16. Desmettre T, Devoisselle JM, Mordon S. Fluorescence properties and metabolic features of indocyanine green (ICG) as related to angiography. *Surv Ophthalmol* 2000;45:15-27.
  17. Marvasti AH, Berry J, Sibug ME, Kim JW, Huang AS. Anterior segment scleral fluorescein angiography in the evaluation of ciliary body neoplasm: Two case reports. *Case Rep Ophthalmol* 2016;7:30-38.
  18. Brancato R, Bandello F, Lattanzio R. Iris fluorescein angiography in clinical practice. *Surv Ophthalmol* 1997;42:41-70.
  19. Alsagoff Z, Chew PT, Chee CK, Wong JS, Aung T. Indocyanine green anterior segment angiography for studying conjunctival vascular changes after trabeculectomy. *Clin Exp Ophthalmol* 2001;29:22-6.
  20. Hagag AM, Gao SS, Jia Y, Huang D. Optical coherence tomography angiography: Technical principles and clinical applications in ophthalmology. *Taiwan J Ophthalmol* 2017;7:115-29.
  21. Jia Y, Wei E, Wang X, Zhang X, Morrison JC, Parikh M, *et al.* Optical coherence tomography angiography of optic disc perfusion in glaucoma. *Ophthalmology* 2014;121:1322-32.
  22. Wang X, Jiang C, Ko T, Kong X, Yu X, Min W, *et al.* Correlation between optic disc perfusion and glaucomatous severity in patients with open-angle glaucoma: An optical coherence tomography angiography study. *Graefes Arch Clin Exp Ophthalmol* 2015;253:1557-64.
  23. Jiang C, Sun X. Primary angle-closure glaucoma. In: Huang D, Lumbroso B, Jia Y, Waheed NK, editors. *Optical Coherence Tomography Angiography of the Eye*. Thorofare, NJ, USA: Slack; 2017.
  24. Gottschalk HM, Wecker T, Khattab MH, Fischer CV, Callizo J, Rehfeldt F, *et al.* Lipid emulsion-based OCT angiography for *ex vivo* imaging of the aqueous outflow tract. *Invest Ophthalmol Vis Sci* 2019;60:397-406.
  25. Chen J, Huang H, Zhang S, Chen X, Sun X. Expansion of Schlemm's canal by travoprost in healthy subjects determined by fourier-domain optical coherence tomography. *Invest Ophthalmol Vis Sci* 2013;54:1127-34.
  26. Huang AS, Francis BA, Weinreb RN. Structural and functional imaging of aqueous humour outflow: A review. *Clin Exp Ophthalmol* 2018;46:158-68.
  27. Burn JB, Huang AS, Weber AJ, Komáromy AM, Pirie CG. Aqueous Angiography in Normal Canine Eyes. *Transl Vis Sci Technol* 2020;9:44.
  28. Guyer DR, Puliafito CA, Monés JM, Friedman E, Chang W, Verdooner SR. Digital indocyanine-green angiography in chorioretinal disorders. *Ophthalmology* 1992;99:287-9.
  29. Xiao Y, Wang YH, Fu ZY, Hong H. Staining the anterior capsule with indocyanine green or trypan blue for capsulorhexis in eyes with white cataract. *Int Ophthalmol* 2004;25:273-6.
  30. Sharma N, Pangtey MS, Dada VK. Experience with indocyanine green dye. *J Cataract Refract Surg* 2001;27:1342.
  31. Huang AS, Saraswathy S, Dastiridou A, Begian A, Mohindroo C, Tan JC, *et al.* Aqueous angiography-mediated guidance of trabecular bypass improves angiographic outflow in human enucleated eyes. *Invest Ophthalmol Vis Sci* 2016;57:4558-65.
  32. Strohmaier CA, Wanderer D, Zhang X, Agarwal D, Toomey CB, Wahlin K, *et al.* Greater outflow facility increase after targeted trabecular bypass in angiographically determined low-flow regions. *Ophthalmol Glaucoma* 2023;S2589-4196(23)00110-2.
  33. Saraswathy S, Tan JC, Yu F, Francis BA, Hinton DR, Weinreb RN, *et al.* Aqueous angiography: Real-time and physiologic aqueous humor outflow imaging. *PLoS One* 2016;11:e0147176.
  34. Telle MR, Snyder KC, Oikawa K, Nilles JP, Gehrke S, Teixeira LBC, *et al.* Development and validation of methods to visualize conventional aqueous outflow pathways in canine primary angle closure glaucoma. *Vet Ophthalmol* 2022;25 (Suppl 1):84-95.
  35. Huang AS, Saraswathy S, Dastiridou A, Begian A, Legaspi H, Mohindroo C, *et al.* Aqueous angiography with fluorescein and indocyanine green in bovine eyes. *Transl Vis Sci Technol* 2016;5:5.
  36. Burn JB, Huang AS, Weber A, Komáromy AM, Pirie CG. Aqueous angiography in pre-glaucomatous and glaucomatous ADAMTS10-mutant canine eyes: A pilot study. *Vet Ophthalmol* 2022;25 (Suppl 1):72-83.
  37. Snyder KC, Oikawa K, Williams J, Kiland JA, Gehrke S, Teixeira LBC, *et al.* Imaging distal aqueous outflow pathways in a spontaneous model of congenital glaucoma. *Transl Vis Sci Technol* 2019;8:22.
  38. Huang AS, Li M, Yang D, Wang H, Wang N, Weinreb RN. Aqueous angiography in living nonhuman primates shows segmental, pulsatile, and dynamic angiographic aqueous humor outflow. *Ophthalmology* 2017;124:793-803.
  39. Johnstone MA, Martin E, Jamil A. Pulsatile flow into the aqueous veins: Manifestations in normal and glaucomatous eyes. *Exp Eye Res* 2011;92:318-27.
  40. Li P, Reif R, Zhi Z, Martin E, Shen TT, Johnstone MA, *et al.* Phase-sensitive optical coherence tomography characterization of pulse-induced trabecular meshwork displacement in *ex vivo* nonhuman primate eyes. *J Biomed Opt* 2012;17:076026.
  41. Johnstone MA. The aqueous outflow system as a mechanical pump: Evidence from examination of tissue and aqueous movement in human and non-human primates. *J Glaucoma* 2004;13:421-38.
  42. Carreon T, van der Merwe E, Fellman R, Johnstone M, Bhattacharya SK. Aqueous outflow—A continuum from trabecular meshwork to episcleral veins. *Prog Retin Eye Res* 2017;57:108-33.