

# UC Davis

## UC Davis Previously Published Works

### Title

Influence of clipping on bacterial contamination of canine arthrocentesis sites before and after skin preparation

### Permalink

<https://escholarship.org/uc/item/4b32s4qs>

### Journal

Veterinary Surgery, 49(7)

### ISSN

0161-3499

### Authors

Lavallée, Justin M  
Shmon, Cindy  
Beaufrère, Hugues  
et al.

### Publication Date

2020-10-01

### DOI

10.1111/vsu.13468

Peer reviewed

## ORIGINAL ARTICLE

# Influence of clipping on bacterial contamination of canine arthrocentesis sites before and after skin preparation

Justin M. Lavallée DVM, MSC<sup>1</sup> | Cindy Shmon DVM, DVSc, DACVS<sup>1</sup> |  
Hugues Beaufrère DVM, PhD, DACZM, DABVP (Avian), DECZM (Avian)<sup>2</sup> |  
Manuel Chirino-Trejo DVM MSc, PhD<sup>3</sup> | Kathleen Linn DVM, MS, DACVS<sup>1</sup>

<sup>1</sup>Department of Small Animal Clinical Sciences, Western College of Veterinary Medicine, University of Saskatchewan, Saskatoon, Saskatchewan, Canada

<sup>2</sup>Department of Clinical Studies, Ontario Veterinary College, University of Guelph, Guelph, Ontario, Canada

<sup>3</sup>Department of Veterinary Microbiology, Western College of Veterinary Medicine, University of Saskatchewan, Saskatoon, Saskatchewan, Canada

## Correspondence

Justin M. Lavallée, Department of Small Animal Clinical Sciences, Western College of Veterinary Medicine, University of Saskatchewan, 52 Campus Dr, Saskatoon, S7N 5B4, Saskatchewan, Canada.  
Email: jml172@mail.usask.ca

## Funding information

The Companion Animal Health Fund

## Abstract

**Objective:** To determine the influence of hair removal as part of the aseptic skin preparation of canine arthrocentesis sites and to characterize the bacterial flora remaining after aseptic skin preparation.

**Study design:** Randomized controlled trial.

**Study population:** Thirteen shorthaired beagle-cross dogs.

**Methods:** A coin toss was used to randomly determine to have one carpus, elbow, tarsus, and stifle clipped. The contralateral side was left unclipped. Aseptic skin preparation was performed on all sites with 4% chlorhexidine followed by 70% isopropyl alcohol. The skin of each site was sampled for aerobic and anaerobic bacterial cultures before and after aseptic skin preparation. Bacterial cultures were submitted for laboratory testing to determine the colony-forming units (CFU) of bacteria and bacterial species isolated for each site.

**Results:** Each group (clipped and unclipped) included 52 sites. Aseptic skin preparation reduced bacterial CFU in both groups. There was no association between values for CFU per milliliter after skin preparation of dogs and side ( $P = .07$ ), joint ( $P = .71$ ), pre-aseptic skin preparation CFU ( $P = .94$ ), or clipping ( $P = .42$ ). *Staphylococcus* spp were the most common of the bacterial species cultured.

**Conclusion:** In clean shorthaired dogs without visible evidence of dermatological disease, leaving arthrocentesis sites unclipped rather than performing traditional surgical clipping did not result in increased bacterial skin counts after aseptic skin preparation.

**Clinical significance:** In this study we did not find evidence to support that clipping of canine arthrocentesis sites is required for effective aseptic skin preparation. A prospective clinical trial is required to determine whether a change in practice would be associated with increased morbidity.

## 1 | INTRODUCTION

Arthrocentesis is a common procedure in small animal practice. Joint fluid collection for cytology, culture, and other more advanced diagnostic testing is indicated for painful and inflamed joints, shifting leg lameness, and fevers of unknown origin.<sup>1,2</sup> Joint injections of local anesthetic can aid lameness localization. Different medications may be injected into the joint for local effect.<sup>1</sup>

Recognized complications of arthrocentesis include hemoarthrosis, intra-articular injury, and lameness.<sup>1-3</sup> Septic arthritis is also listed as a potential complication in man, horses, and dogs.<sup>1,2,4-8</sup> Septic arthritis is rare after joint injections in people, with a reported rate of 0.001% to 0.037%.<sup>9,10</sup> A 0.078% rate of septic arthritis is reported in horses after joint injections through unclipped hair.<sup>11</sup> There have been no reports of septic arthritis in dogs after arthrocentesis alone. A 1.3% infection rate was reported in a report of one study referencing unpublished data on 154 joints after joint injections with hyaluronic acid or corticosteroids, but joint surgery had been performed on many of these dogs prior to joint injection.<sup>6</sup>

The most common bacterial flora of canine skin are various *Staphylococcus* spp, *Micrococcus* spp, and *Corynebacterium* spp.<sup>12-15</sup> In clinical cases of canine septic arthritis, the route of infection is hematogenous or by direct penetration of joints through surgery or trauma.<sup>11,16-18</sup> Bacteria reported to cause septic arthritis include *Staphylococcus pseudointermedius* and *S aureus*,  $\beta$ -hemolytic streptococci, and gram-negative species.<sup>16,17,19-21</sup>

Descriptions of clinical procedures such as venipuncture, fine needle aspirates, cystocentesis, or skin biopsy for dermatologic disease advise only an alcohol swab for skin preparation.<sup>2,3,15,22,23</sup> Clipping and aseptic preparation of canine arthrocentesis sites remains the recommended practice in dogs and cats.<sup>1-3,24,25</sup> It may be easier for novice clinicians to visualize landmarks if the site is clipped, but, in the authors' experience, the local anatomy is readily palpable. The role of aseptic skin preparation is to remove transient bacterial species and decrease resident flora and delay their repopulation<sup>4,26</sup> to minimize the potential that skin bacteria will be injected into the joint. Many solutions can achieve appropriate reduction of microorganisms, but 4% chlorhexidine and 70% isopropyl alcohol are commonly recommended.<sup>26-30</sup> No evidence-based inquiries have been made into whether clipping is required for canine arthrocentesis site preparation, so it continues to be the standard of care.<sup>1</sup>

Current recommendations are different for horses. Researchers in one study found that povidone iodine preparation of the arthrocentesis sites with the hair left in situ produced residual bacterial counts similar to those

obtained after aseptic skin preparation with the hair clipped.<sup>4</sup> Other researchers using sham arthrocentesis procedures in live and cadaveric equine joints found that new 20-gauge needles placed quickly through unclipped hair produced less joint contamination compared with other protocols. Larger needles (16 and 18 gauge), spinal needles, clipped or shaved hair, and reuse of needles increased the odds ratios of tissue and hair contamination of joints.<sup>5,31,32</sup> Clinical texts now recommend that arthrocentesis sites not be clipped in horses.<sup>33,34</sup>

Hair removal for arthrocentesis in dogs has its disadvantages. Dogs may lick and self-traumatize sites where clipping has caused alterations of skin microbiome and superficial irritation, leading to erythema and dermatitis.<sup>35</sup> Owners may object to the esthetics of hair removal, especially if multiple joints are sampled or repeated sampling is required. Hair regrowth may be prolonged. Procedural times could be decreased if hair removal was not required for effective site preparation. Finally, because hair removal prior to arthrocentesis sites is not standard of care in horses because of increased intra-articular debris and possible increased risk of infection, examination of this question in dogs is warranted.<sup>4,5,31,32</sup>

The objective of this study was to determine the influence of clipping on bacterial decontamination of canine arthrocentesis sites after aseptic skin preparation. A secondary objective was to determine whether bacterial species remaining on the skin after site preparation were the ones commonly associated with cases of bacterial synovitis. We hypothesized that there would be no difference in surface bacterial numbers after aseptic preparation between joint sites that were clipped and those that were not clipped. We also hypothesized that *Staphylococcus* spp. would be the most common post-skin preparation isolate.

## 2 | MATERIALS AND METHODS

### 2.1 | Study design

This study was conducted in accordance with and approved by the University of Saskatchewan Animal Research Ethics Board (animal use protocol No. 20180038). Thirteen shorthaired beagle-cross dogs were used. Dogs were housed at the University of Saskatchewan Animal Care Unit in independently climate controlled indoor/outdoor runs, with climate controlled through a heating, ventilating, and air conditioning system with radiant heating. Access to the outdoors was provided at will during the study period.

Dogs were evaluated for general health by physical examination, complete blood count, biochemical panel,

urinalysis, and fecal examination. They were excluded when there was evidence of a visibly dirty hair coat, external parasites, skin lesions over the proposed arthrocentesis site, or they had received oral or topical antibiotics within 2 weeks of the study. Samples were collected while dogs were sedated or anesthetized for another research project. Bilateral carpi, elbows, stifles and tarsi were studied in each dog. A coin toss was used to determine whether joints on the right or left were clipped. Each dog had an approximately 2- × 2-cm patch of hair removed from one carpus, elbow, stifle, and tarsus by using a No. 40 clipper blade. Blades were wiped with alcohol and air dried between uses. The contralateral side was not clipped. All sites were wiped with dry gauze to remove gross surface debris and loose hair.

Swabs for aerobic and anaerobic cultures were collected from each of the eight sites before skin preparation. One investigator (J.M.L.) collected all samples to standardize the acquisition technique. Each culture swab was aseptically premoistened with 0.15 mL of sterile saline. With the investigator wearing sterile gloves, an aerobic culture swab (BBL CultureSwab; Becton Dickenson and Company, Sparks, Maryland) and an anaerobic culture swab (BBL Vacutainer; Becton Dickenson and Company) were placed in the center of each site and rotated 360° with firm pressure before being placed in a sterile container. For sampling of nonclipped sites, the hair was parted, and the moistened swab was placed on the skin underneath the hair before rotating it 360°.

Sterile gloves were worn during the skin preparations and sample collections. Each clipped and nonclipped site was individually prepared by scrubbing the clipped area or equivalently sized unclipped site by using sterile gauze sponges with 4% chlorhexidine (Germi-Stat gel 4%; Ceva Animal Health, Cambridge, Ontario, Canada) and sterile saline for 3 minutes. Residual solution was removed with a sterile sponge, and 70% isopropyl alcohol (isopropyl rubbing alcohol 70%; RW Consumer Products, Winnipeg, Manitoba, Canada) was applied to the site. After the alcohol had dried, aerobic and anaerobic cultures were taken from the center of each site by using the previously described technique.

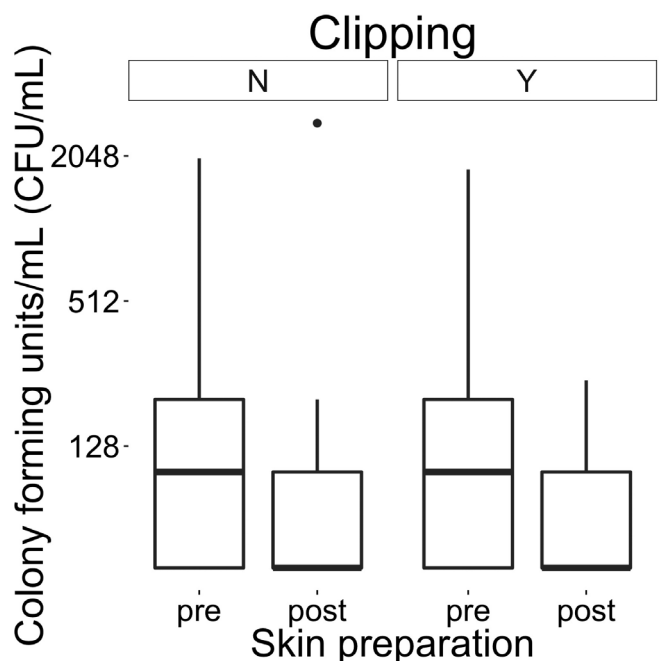
Culture swabs were submitted to Prairie Diagnostic Services (University of Saskatchewan, Saskatoon, Saskatchewan, Canada) for quantitative analysis. Culture methods are performed routinely at this laboratory by using American Association of Veterinary Laboratory Diagnosticians standards, and similar methodologies are described in other reports.<sup>4,27,36</sup> Bacterial colony-forming units (CFU) per milliliter was determined for the pre-aseptic skin preparation and post-aseptic skin preparation cultures for clipped and nonclipped sites. For each

swab, 10 µL of peptone water was added to the swab, and the samples were vortexed. Then, 100-µL samples of two serial dilutions (1:10 and 1:100) were plated on blood agar with CO<sub>2</sub> and MacConkey agar plates. Samples were incubated for 48 hours before the total bacterial count of each sample was determined. Bacterial identification was performed by using a matrix-assisted laser desorption/ionization-time of flight mass spectrophotometer (MALDI-TOF; Bruker, Milton, Ontario, Canada) when growth was present, and genus and species of bacteria were reported. When the MALDI-TOF did not report a conclusive identification, classical biochemical identification techniques were performed. In these cases, only the genus was determined.

## 2.2 | Statistical analysis

A priori power calculation based on the data reported by Hague et al<sup>4</sup> was performed by using  $\beta = .2$  and  $\alpha = .05$  in OpenEpi (Open Source Epidemiologic Statistics for Public Health; www.openepi.com.). According to the power calculation, a minimum of 37 members (ie, joints) per group was required for this study to detect statistical differences between groups.

Normality of the data was assessed with a Shapiro-Wilk test. To assess the association between variables and



**FIGURE 1** Side by side box plot of colony-forming units per milliliter (log scale) for clipped and nonclipped arthrocentesis sites before and after skin preparation. N, no; post, post aseptic; pre, pre aseptic; Y, yes

CFU after skin preparation, a linear mixed model was used. The linear mixed model takes into account cluster correlated data. The model was fitted with CFU after skin preparation as the outcome variable. Independent variables included the side (right or left), specific joint (carpi, elbows, stifles, and tarsi), CFU before skin preparation, and clipping (yes or no). The interactions between these variables were considered fixed effects. Dogs were the random variable. The model assumptions and fit were assessed graphically for linearity of the residuals, homoscedasticity of the residuals, and normality of the residuals. Log transformation of the outcome variable did not improve the fit of the model and was therefore not used. Poisson mixed regression models for count data were also

attempted but did not converge. Statistical analysis was performed in R (R Development Core Team [2018], R Foundation for Statistical Computing, Vienna, Austria. <https://www.R-project.org/>). An  $\alpha$  of .05 was considered significant.

### 3 | RESULTS

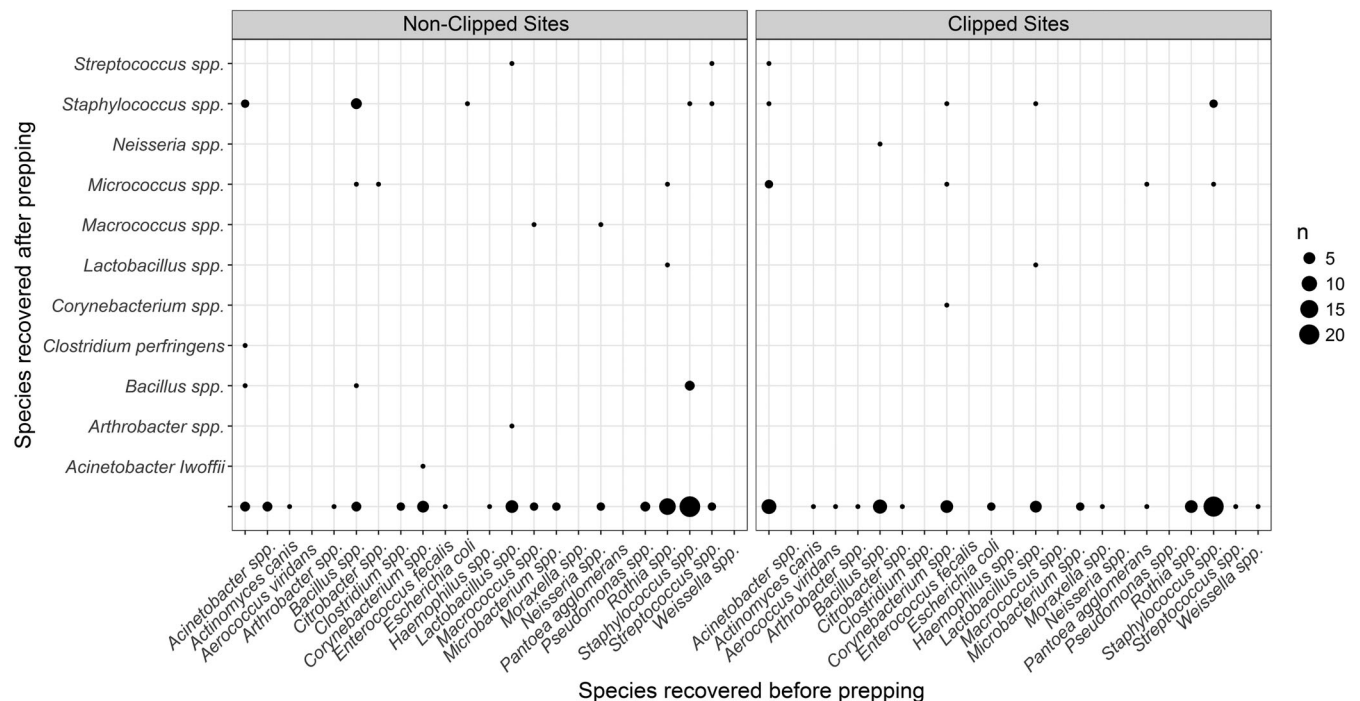
The mean body weight was 12 kg (range, 9-16). No dog had received oral or topical antibiotics for at least 2 weeks before this study. All dogs were healthy and clean, with no evidence of external parasites or dermatologic disease at physical examination. All eight joints of interest were included for each of thirteen dogs (n = 52 per group).

The bacterial CFU per milliliter were not normally distributed according to assessment with the Shapiro-Wilk test. The median bacterial CFU per milliliter present on the skin before preparation was 120 CFU/mL (range, 0-2200) for clipped sites and 130 CFU/mL (range 0-2000) for the nonclipped sites. The median CFU per milliliter after skin preparation for clipped sites was 0 CFU/mL (range, 0-240) and 0 CFU/mL (range 0-200) for nonclipped sites (Figure 1). There was no association between the CFU per milliliter after skin preparation of

**TABLE 1** Summary of the individual *P*-values of each of the explanatory variables tested

Variable tested	<i>P</i> -value
Side	.07
Joint type	.71
Pre-preparation CFU/mL	.94
Clipping	.42

Note: Statistical significance set at  $P \leq .05$ .  
Abbreviation: CFU, colony-forming unit.



**FIGURE 2** Scatter plot of the range of bacterial species co-isolated before and after aseptic preparation of the arthrocentesis sites for all (clipped and nonclipped) arthrocentesis sites. Species from clipped and nonclipped sites are presented separately. Species listed on the x-axis were recovered before surgical preparation and those on the y-axis were recovered after skin preparation. Size of the dots/circles corresponds to the number of times each species was cultured



**TABLE 2** Frequency that bacterial genera were cultured before and after skin preparation for all joints<sup>a</sup>

Bacteria	Absolute	Percentage
<b>Pre-skin preparation</b>		
<i>Staphylococcus</i> spp	52	33.5
<i>Lactobacillus</i> spp	15	9.7
<i>Corynebacterium</i> spp	15	9.7
<i>Bacillus</i> spp	10	6.4
<i>Micrococcus</i> spp	9	5.8
Other	54	34.8
<b>Post-skin preparation</b>		
<i>Staphylococcus</i> spp	11	29.7
<i>Micrococcus</i> spp	6	16.2
<i>Bacillus</i> spp	5	13.5
<i>Streptococcus</i> spp	4	10.8
<i>Lactobacillus</i> spp	2	5.4
Other	9	24.3

<sup>a</sup>Clipped and nonclipped arthrocentesis sites.

dogs and side, specific joint, pre-aseptic skin preparation CFU per milliliter, or clipping (Table 1).

More than 20 different species of bacteria were isolated from the sites before skin preparation. *Staphylococcus* spp, *Lactobacillus* spp, and *Corynebacterium* spp were the most common isolates (Figure 2). Bacteria isolated after skin preparation yielded 18 different species of bacteria. *Staphylococcus epidermidis*, *Micrococcus* spp, and *Bacillus* spp were most commonly recovered. The number of times bacterial species were isolated before and after skin preparation is presented in Table 2. The organisms recovered before skin preparations were commensal and environmental bacteria. After skin preparation, all but three *Streptococcus* spp were considered environmental.

During statistical analysis, one outlier was removed. The tarsus of the 10th dog had 40 CFU/mL before preparation and 2800 CFU/mL after preparation. This was a nonclipped site.

## 4 | DISCUSSION

In this randomized controlled trial of healthy shorthaired dogs without dermatologic disease, we did not find evidence to support that clipping of canine arthrocentesis sites is required for effective aseptic skin preparation. *Staphylococcus* spp was the most common isolate before and after aseptic skin preparation. This allowed us to accept both of our hypotheses that surface bacterial

numbers would not be different between the two groups and that *Staphylococcus* spp. predominated.

We did not find that hair clipping increased CFU on the skin before skin preparation, a difference from what was seen in horses.<sup>4</sup> Although it was not statistically significant, pre-preparation CFU per milliliter tended to be lower for clipped sites in our study. A difference was not detected in the CFU per milliliter among various joints tested, which was counter to findings in horse studies in which more distal joints had higher bacterial counts.<sup>4</sup> This may reflect differences in housing environments between horses and dogs. However, CFU per milliliter after skin preparation of arthrocentesis sites in our dogs were similar to those found in horses.<sup>27</sup>

Bacterial counts before skin preparation in this study were similar to or higher than those found in other canine studies, although different preparation solutions were used.<sup>12,13,28,35</sup> Bacterial reduction was not always complete. Similar results have been observed in canine studies in which different preparation techniques were compared.<sup>12,28-30,35</sup> We used a moist swab placed on the skin and rotated with firm pressure in contrast to the impression technique in which culture plates are gently pressed directly onto the skin. We could not identify any studies in which the two skin sample collection methods were directly compared, but environmental studies in which the techniques were compared have provided evidence that both methods of sample collection provide equivalent results.<sup>37,38</sup> The swab method is considered more appropriate for uneven surfaces, which is why it was used in our study.<sup>37,38</sup> Differences in anatomical location and methodology make direct comparisons between our study and other canine studies difficult<sup>12,13,28</sup> because, in those other studies, larger sites on the trunk were cultured in a surgical setting by using surgical caps, masks, and (in two studies), surgical drapes.<sup>12,13,28</sup>

Chlorhexidine diluted with saline solution is as effective an antiseptic as chlorhexidine diluted with sterile water.<sup>39</sup> Chlorhexidine (4%) in saline followed by a 70% ethyl alcohol rinse that is allowed to dry is an accepted standard for aseptic skin preparation in many species, including dogs.<sup>26-30,35,40</sup> Human guidelines increasingly accept waterless hand rubs for presurgical hand washing because they are as effective as chlorhexidine and less traumatizing to the hands of surgical personnel.<sup>41</sup> Evaluation of products for animal site preparation in veterinary medicine is ongoing, but no difference has yet been identified in residual CFU per milliliter when any other product has been compared to traditional chlorhexidine-based site preparation.<sup>13,28</sup> Alcohol-based solutions are also considered easier to use.<sup>13</sup> These findings lead us to

conclude that arthrocentesis site preparation with waterless preparation products warrants further consideration.

Bacteria surviving skin preparation may be introduced into the joint by the needle. In horses, it is reported that a minimum of 33 CFU per milliliter must be introduced into a joint to cause septic arthritis.<sup>4,27</sup> After equine arthrocentesis site preparation, mean CFU per milliliter is 28.67 to 109.80 CFU/mL,<sup>27</sup> and, despite this, infection rates after arthrocentesis and joint injection remain low.<sup>11,27</sup> In a recent in-vitro study, researchers noted that lower skin bacterial numbers and smaller gauge needles were less likely to lead to bacterial translocation into tissues.<sup>42</sup> The number of skin bacteria transposed into a joint with a single needle puncture is unknown. Some postpreparation culture numbers in our study exceeded 33 CFU/mL, but there are no canine studies in which the infection rates in healthy joints are correlated with numbers of surface bacteria present. It is also unknown whether preexisting conditions such as osteoarthritis, polyarthritis, joint surgery, or immunosuppression would change these numbers.<sup>3,16</sup>

Various bacterial species have been implicated in cases of canine septic arthritis, including *S pseudointermedius*, *S aureus*,  $\beta$ -hemolytic streptococci, and *Escherichia coli*.<sup>16,17,19-21</sup> Multitudes of commensal and environmental bacterial species were cultured in this study, including *Micrococcus* spp, *Lactobacillus* spp, *Bacillus* spp, and *Corynebacterium* spp. *Staphylococcus* spp was the most common isolate in our study, both before and after site preparation. Noncoagulase positive *Staphylococcus* spp are rarely pathogenic,<sup>43</sup> and only one species of coagulase positive *Staphylococcus* (*S pseudointermedius*) was identified. It was not detected after skin preparation. Both preparation techniques investigated in our study were effective in eliminating *Staphylococcus* spp. Only three potential joint pathogens were recovered after skin preparation, two in the unclipped group and one in the clipped group. *Streptococcus* spp were identified on four sites. One was not  $\beta$ -hemolytic, and the others were not characterized beyond the genus, so it is unknown whether they were joint pathogens. No other known pathogens were isolated in either group.

In horses, more debris enters the joint when the arthrocentesis site has been clipped than when it has not been clipped.<sup>5,31,32</sup> The introduction of potential niduses for bacterial growth may increase the potential for infection.<sup>5</sup> If the same holds true for dogs, it might be prudent to discontinue clipping arthrocentesis sites in dogs. Given the lack of reported complications associated with arthrocentesis in dogs, however, it is unclear how clinically important this concern might be without additional study.

No cases of septic arthritis secondary to arthrocentesis (alone) have been reported in dogs. In neither a review of retrospective studies of aseptic arthritis nor an August 2019 search of PubMed (<https://pubmed.ncbi.nlm.nih.gov/>) did we discover any cases of this complication. Terms relevant to dogs (dog, dogs, canine, canines, or canis), arthrocentesis (arthrocentesis, joint taps, joint aspirates, joint injections) and septic arthritis (septic arthritis, joint sepsis, infectious arthritis) were searched in original titles, terms, abstracts, and key words. The searches were linked with Boolean terms ([dog OR dogs OR canine OR canines OR canis] AND [arthritis OR septic arthritis OR infective arthritis OR joint sepsis] AND [arthrocentesis OR joint tap OR joint aspirate OR joint injection]).

Current recommendations to clip arthrocentesis sites before aseptic skin preparation reflect attempts to avoid joint sepsis and improve visualization of landmarks.<sup>1</sup> Clipping may aid the novice clinician in identifying anatomic landmarks; however, in our experience, clinicians tend to base arthrocentesis on joint manipulation and landmark palpation. The requirement to clip likely reflects the perception that effective site preparation requires the hair first to be removed. This is not supported by evidence in other species<sup>4,44,45</sup> or the results of this study.

Clipping the skin can cause abrasions, erythema, and changes to the microbiome of the skin as well as promote acral lick dermatitis and bacterial skin infections.<sup>35</sup> Delayed hair regrowth may accompany endocrinopathies and various drug regimens, such as corticosteroid therapy, used for treatment of polyarthritides.<sup>46</sup> Owners often dislike the clipping of multiple sites because cosmetic appearance is important to them. Procedural and sedation times are likely to be shortened if hair removal is not required. These reasons make foregoing clipping before arthrocentesis site preparation attractive if it can be done safely. Because arthrocentesis in small animals is often performed in inflamed joints and potentially immunocompromised animals, a prospective clinical trial in healthy and diseased dogs would be required to ensure minimal morbidity.

This study has several limitations. Dogs assessed in this study were homogenous with respect to length of hair coat, cleanliness, and housing. All were young beagle-cross dogs with a healthy short summer coat housed in a university research facility. Our findings may not apply to breeds with longer and/or thicker coats or preexisting dermatitis. During statistical analysis, one outlier was removed. The tarsus of dog 10 had 40 CFU/mL before skin preparation and 2800 CFU/mL after preparation. This was a nonclipped site. It is unclear why such a dramatic increase of CFU was noted after skin preparation because no skin injury had been noted, but a sampling error (ie, swab contaminated during sample

collection) or sample identification error was suspected. Because our study was based on bacterial cultures of the skin, some organisms may have missed being detected. A technique such as polymerase chain reaction would be more sensitive for detecting other infectious organisms, but it would detect both viable and nonviable infectious organisms. Aerobic and anaerobic bacterial cultures were chosen to determine viable CFU that could cause septic arthritis. This was performed with the understanding that some detection of fastidious bacteria could be missed with traditional culturing techniques. Detection of fungi and viruses would also be missed, but these organisms rarely cause septic arthritis in dogs.<sup>16,47</sup>

In conclusion, the results of this study do not support the practice of clipping canine arthrocentesis sites before aseptic skin preparation. Skin preparation with 4% chlorhexidine followed by 70% alcohol yielded similar reductions in bacterial counts when clipping was performed compared with when clipping was not performed in beagle-cross dogs with a healthy short summer coat housed in a university research facility. A randomized controlled clinical trial in which outcomes are compared in dogs that have their sites clipped or not clipped is required to determine whether hair clipping affects joint morbidity.

## ACKNOWLEDGMENTS

**Author Contributions:** Lavallée J, DVM, MSc: Participated in the study conception, grant application, research design, data collection and interpretation as well as manuscript preparation and revision; Shmon C, DVM, DVSc, DACVS: Participated in the study conception, grant application, research design, data collection and interpretation as well as manuscript preparation and revision; Beaufrère H, DVM, PhD, DACZM, DABVP (Avian), DECZM (Avian): Participated in interpretation of data, manuscript preparation and revision; Chirino-Trejo M, DVM, MSc, PhD: Participated in interpretation of data, manuscript preparation and revision; Linn K, DVM, MS, DACVS: Participated in the study conception, grant application, research design, data collection and interpretation as well as manuscript preparation and revision.

The authors thank B. Ambros DrMedVet, MVetSc, DECVAA, DACVAA for assistance in monitoring sedation and general anesthesia for the study dogs as well to veterinary students D. Oster and E. Csopak for their assistance in data acquisition and patient management during the study period. The Companion Animal Health Fund provided financial support of this study.

## CONFLICT OF INTEREST

The authors declare no conflicts of interest related to this report.

## REFERENCES

- Torres BT, Duerr FM. Arthrocentesis technique. In: Duerr FM, ed. *Canine Lameness*. 1st ed. Hoboken, NJ: John Wiley & Sons; 2020:93-104.
- Taylor S, ed. *Small Animal Clinical Techniques*. 2nd ed. St Louis, MO: Elsevier; 2016.
- Côté E. Arthrocentesis. In: Côté E, ed. *Clinical Veterinary Advisor*. 3rd ed. St Louis, MO: Elsevier; 2015:1100.
- Hague BA, Honnas CM, Simpson RB, Peloso JG. Evaluation of skin bacterial flora before and after aseptic preparation of clipped and nonclipped arthrocentesis sites in horses. *Vet Surg*. 1997;26(2):121-125.
- Adams SB, Moore GE, Elrashidy M, Mohamed A, Snyder PW. Effect of needle size and type, reuse of needles, insertion speed, and removal of hair on contamination of joints with tissue debris and hair after arthrocentesis. *Vet Surg*. 2010;39(6):667-673.
- Nganvongpanit K, Boonsri B, Sripratak T, Markmee P. Effects of one-time and two-time intra-articular injection of hyaluronic acid sodium salt after joint surgery in dogs. *J Vet Sci*. 2013;14(2):215-222.
- Soontornvipart K, Kohout P, Proks P. Septic arthritis in dogs: a retrospective study of 20 cases (2000-2002). *Acta Vet Brno*. 2003;72(3):405-413.
- Morrow M. Urinary tract infection as nidus for systemic spread and septic arthritis. *Can Vet J*. 1999;40(9):666-668.
- Bettencourt RB, Linder MM. Arthrocentesis and therapeutic joint injection: an overview for the primary care physician. *Prim Care*. 2010;37(4):691-702.
- Geirsson AJ, Statkevicius S, Vikingsson A. Septic arthritis in Iceland 1990-2002: increasing incidence due to iatrogenic infections. *Ann Rheum Dis*. 2008;67(5):638-643.
- Steel CM, Pannirselvam RR, Anderson GA. Risk of septic arthritis after intra-articular medication: a study of 16,624 injections in Thoroughbred racehorses. *Aust Vet J*. 2013;91(7):268-273.
- Boucher C, Henton MM, Becker PJ, Kirberger RM, Hartman MJ. Comparative efficacy of three antiseptics as surgical skin preparations in dogs. *Vet Surg*. 2018;47(6):792-801.
- Asimus E, Palierne S, Blondel M, et al. Comparison of hydroalcoholic rubbing and conventional chlorhexidine scrubbing for aseptic skin preparation in dogs. *Vet Surg*. 2019;48(8):1466-1472.
- Rodrigues Hoffmann A, Patterson AP, Diesel A, et al. The skin microbiome in healthy and allergic dogs. *PLoS One*. 2014;9(1):1-12.
- Miller W, Griffin C, Campbell K. Bacterial skin diseases. In: Miller W, Griffin C, Campbell K, eds. *Muller and Kirk's Small Animal Dermatology*. 7th ed. St Louis, MO: Elsevier; 2013:184-222.
- Innes JF. Arthritis. In: Johnson S, Tobias K, eds. *Veterinary Surgery Small Animal*. 2nd ed. St Louis, MO: Elsevier; 2018:1265-1299.
- Marchevsky AM, Read RA. Bacterial septic arthritis in 19 dogs. *Aust Vet J*. 1999;77(4):233-237.
- Fitch RB, Hogan TC, Kudnig ST. Hematogenous septic arthritis in the dog: results of five patients treated nonsurgically with antibiotics. *J Am Anim Hosp Assoc*. 2003;39(6):563-566.



19. Bennett D, Taylor DJ. Bacterial infective arthritis in the dog. *J Small Anim Pract.* 1988;29(4):207-230.
20. Benzioni H, Shahar R, Yudelevitch S. JM. Bacterial infective arthritis of the coxofemoral joint in dogs with hip dysplasia. *Vet Comp Orthop Traumatol.* 2008;21(03):262-266.
21. Clements DN, Owen MR, Mosley JR, Carmichael S, Taylor DJ, Bennett D. Retrospective study of bacterial infective arthritis in 31 dogs. *J Small Anim Pract.* 2005;46(4):171-176.
22. Thoday KL. Investigative techniques in small animal clinical dermatology. *Br Vet J.* 1981;137(2):133-154.
23. Withrow S, Vail DM, Page R. Diagnostic cytopathology in clinical oncology. In: Withrow S, Vail DM, Page R, eds. *Withrow & MacEwen's Small Animal Clinical Oncology.* 5th ed. St Louis, MO: Elsevier/Saunders; 2013:111.
24. Dear JD. Arthrocentesis and arthroscopy. In: Ettinger S, Feldman E, Cote E, eds. *Textbook of Veterinary Internal Medicine.* 8th ed. St Louis, MO: Elsevier; 2010:364-365.
25. Brinker WO, Piermattei DL, Flo GL. Orthopedic examination and diagnostic tools. In: Brinker WO, Piermattei DL, Flo GL, eds. *Handbook of Small Animal Orthopedics and Fracture Treatment.* 4th ed. Philadelphia, PA: Saunders; 2006:3-24.
26. Pelosi A. The operating room. In: Johnson S, Tobias K, eds. *Veterinary Surgery Small Animal.* 2nd ed. St Louis, MO: Elsevier; 2018:177-192.
27. Zubrod CJ, Farnsworth KD, Oaks JL. Evaluation of arthrocentesis site bacterial flora before and after 4 methods of preparation in horses with and without evidence of skin contamination. *Vet Surg.* 2004;33(5):525-530.
28. Maxwell EA, Bennett RA, Mitchell MA. Efficacy of application of an alcohol-based antiseptic hand rub or a 2% chlorhexidine gluconate scrub for immediate reduction of the bacterial population on the skin of dogs. *Am J Vet Res.* 2018;79(9):1001-1007.
29. Osuna DJ, DeYoung DJ, Walker RL. Comparison of three skin preparation techniques. Part 2: clinical trial in 100 dogs. *Vet Surg.* 1990;19(1):20-23.
30. Osuna DJ, DeYoung DJ, Walker RL. Comparison of three skin preparation techniques in the dog. Part 1: experimental trial. *Vet Surg.* 1990;19(1):14-19.
31. Waxman SJ, Adams SB, Moore GE. Effect of needle brand, deedle bevel grind, and silicone lubrication on contamination of joints with tissue and hair debris after arthrocentesis. *Vet Surg.* 2015;44(3):373-378.
32. Wahl K, Adams SB, Moore GE. Contamination of joints with tissue debris and hair after arthrocentesis: the effect of needle insertion angle, spinal needle gauge, and insertion of spinal needles with and without a stylet. *Vet Surg.* 2012;41(3):391-398.
33. Moyer W, Schumacher J, Schumacher J, eds. *Equine Joint Injection and Regional Anesthesia.* 5th ed. Chadds Ford, PA: Academic Veterinary Solutions; 2011.
34. Kaneps AJ. Arthrocentesis. In: Wilson D, ed. *Clinical Veterinary Advisor: The Horse.* 1st ed. St Louis, MO: WB Saunders; 2012:664-665.
35. Messiaen Y, Maclellan JD, Pelsue DH. Evaluation of the number of colony forming units on the skin of dogs after clipping the hair with two sizes of clipper blades. *Am J Vet Res.* 2019;80(9):862-867.
36. Scharf VF, Lewis ST, Wellehan JF, et al. Retrospective evaluation of the efficacy of isolating bacteria from synovial fluid in dogs with suspected septic arthritis. *Aust Vet J.* 2015;93(6):200-203. <https://onlinelibrary.wiley.com/doi/abs/10.1111/avj.12328>.
37. Salo S, Laine A, Alanko T, Sjöberg AM, Wirtanen G. Validation of the microbiological methods hygicult dipslide, contact plate, and swabbing in surface hygiene control: a Nordic collaborative study. *J AOAC Int.* 2000;83(6):1357-1365.
38. Niskanen A, Pohja MS. Comparative studies on the sampling and investigation of microbial contamination of surfaces by the contact plate and swab methods. *J Appl Bacteriol.* 1977;42(1):53-63.
39. Vintimilla DR, Chambers L, Mauffrey C, Parry JA. Just add water? Chlorhexidine's antimicrobial properties are minimally affected by dilution in saline compared to water. *Eur J Orthop Surg Traumatol.* 2020;30(4):613-615.
40. Stinner DJ, Krueger CA, Masini BD, Wenke JC. Time-dependent effect of chlorhexidine surgical prep. *J Hosp Infect.* 2011;79(4):313-316.
41. Ho Y-H, Wang Y-C, Loh E-W, Tam K-W. Antiseptic efficacies of waterless hand rub, chlorhexidine scrub, and povidone-iodine scrub in surgical settings: a meta-analysis of randomized controlled trials. *J Hosp Infect.* 2019;101(4):370-379.
42. Smyth TT, Chirino-Trejo M, Carmalt JL. In vitro assessment of bacterial translocation during needle insertion through inoculated culture media as a model of arthrocentesis through cellulitic tissue. *Am J Vet Res.* 2015;76(10):877-881.
43. Becker K, Heilmann C, Peters G. Coagulase-negative staphylococci. *Clin Microbiol Rev.* 2014;27(4):870-926.
44. Sebastian S. Does preoperative scalp shaving result in fewer postoperative wound infections when compared with no scalp shaving? A systematic review. *J Neurosci Nurs.* 2012;44(3).
45. Broekman MLD, van Beijnum J, Peul WC, Regli L. Neurosurgery and shaving: what's the evidence? *J Neurosurg.* 2011;115(4).
46. Huang HP, Yang HL, Liang SL, Lien YH, Chen KY. Iatrogenic hyperadrenocorticism in 28 dogs. *J Am Anim Hosp Assoc.* 1999;35(3):200-207.
47. Bufalari A, Maggio C, Moretti G, et al. Management of *Candida guilliermondii* joint infection in a dog (clinical report). *Acta Vet Scand.* 2016;58(1).

**How to cite this article:** Lavallée JM, Shmon C, Beaufrère H, Chirino-Trejo M, Linn K. Influence of clipping on bacterial contamination of canine arthrocentesis sites before and after skin preparation. *Veterinary Surgery.* 2020;49:1307-1314. <https://doi.org/10.1111/vsu.13468>